



HAL
open science

Unusual rupture of the middle finger flexor digitorum superficialis tendon in a climber: Biomechanical analysis

H Caso, Laurent Vigouroux, T Valerio, B Goislard de Monsabert, C Jaloux, R Legré

► To cite this version:

H Caso, Laurent Vigouroux, T Valerio, B Goislard de Monsabert, C Jaloux, et al.. Unusual rupture of the middle finger flexor digitorum superficialis tendon in a climber: Biomechanical analysis. *Hand Surgery and Rehabilitation*, 2021, 40, pp.643 - 649. 10.1016/j.hansur.2021.04.007 . hal-03644263

HAL Id: hal-03644263

<https://hal.science/hal-03644263>

Submitted on 19 Apr 2022

HAL is a multi-disciplinary open access archive for the deposit and dissemination of scientific research documents, whether they are published or not. The documents may come from teaching and research institutions in France or abroad, or from public or private research centers.

L'archive ouverte pluridisciplinaire **HAL**, est destinée au dépôt et à la diffusion de documents scientifiques de niveau recherche, publiés ou non, émanant des établissements d'enseignement et de recherche français ou étrangers, des laboratoires publics ou privés.

Original article

Unusual rupture of the middle finger flexor digitorum superficialis tendon in a climber: Biomechanical analysis

Rupture atypique du tendon flexor digitorum superficialis du majeur chez un grimpeur: analyse biomécanique

H. Caso ^{a,*}, L. Vigouroux ^b, T. Valerio ^b, B. Goisard de Monsabert ^b, C. Jaloux ^a, R. Legré ^a

^a Department of Hand and Reconstructive Surgery, La Timone Hospital, Assistance Publique des Hôpitaux de Marseille, 264 Rue Saint Pierre, 13005 Marseille, France

^b Aix-Marseille University, CNRS, ISM, 163 Avenue de Luminy, CP 910, 13288 Marseille Cedex 09, France

ARTICLE INFO

Article history:

Received 15 February 2021

Received in revised form 9 April 2021

Accepted 14 April 2021

Available online xxx

Keywords:

Sport climbing

Tendon rupture

Modeling

Tendon force

Mots-clés:

Escalade

Rupture tendineuse

Modélisation

Force

ABSTRACT

Sport climbing is increasingly popular and consultations by climbers in hand surgery departments are on the increase. The pathologies related to this sport concern essentially the pulley system, tendons being rarely affected. We report the case of a male climber who presented an atypical rupture of the flexor superficialis tendon in his left middle finger sustained when using an atypical climbing grip technique: the “hook grip”. This consists in extension of the metacarpophalangeal joints and maximal flexion of the proximal interphalangeal joints with force exerted only on middle phalanx of the middle finger. A biomechanical analysis using finger musculoskeletal modeling was performed to compare the hook grip to other grips, and the patient’s recovery performance was assessed. Adapted functional treatment with physiotherapy seems to have been a good option for the treatment of this atypical lesion since the patient recovered normal use of his finger in daily life. He recovered maximal force in climbing holds. The biomechanical analysis confirmed that the atypical “hook grip” was likely at the origin of the rupture, since flexor digitorum superficialis tendon force for this grip is greater than in other climbing grip techniques. The “hook grip” seems to be dangerous and should be used cautiously by climbers to prevent similar pathology. Additionally, the patient should henceforth be careful when climbing, since the biomechanical model showed that the remaining flexor digitorum profundus tendon was overused.

RÉSUMÉ

L'escalade est de plus en plus populaire et les consultations des grimpeurs dans les services de chirurgie de la main sont en augmentation. Les pathologies liées à ce sport concernent essentiellement le système des poulies, les tendons étant rarement atteints. Nous décrivons le cas d'un grimpeur masculin qui a présenté une rupture atypique du tendon flexor digitorum superficialis du majeur gauche lors de l'utilisation d'une prise d'escalade sportive atypique - la “prise en crochet”. Cette dernière est caractérisée par une extension des articulations métacarpo-phalangiennes et une flexion maximale des articulations interphalangiennes proximales avec des forces appliquées uniquement sur la phalange moyenne du majeur. Une analyse biomécanique utilisant un modèle musculosquelettique des doigts a été réalisée pour évaluer cette prise par rapport à d'autres, et une évaluation des performances de récupération du patient a été réalisée. Le traitement fonctionnel par kinésithérapie semble être une bonne option pour le traitement de cette lésion atypique en raison de la récupération de la fonction du doigt du patient dans sa vie quotidienne. Le patient a récupéré une force maximale sur les prises. L'analyse biomécanique a confirmé que la prise atypique “en crochet” était certainement à l'origine de cette lésion au vu des forces exercées sur le tendon lors de cette prise en comparaison avec les autres. La

* Corresponding author.

E-mail address: hugo.caso@ap-hm.fr (H. Caso).

<https://doi.org/10.1016/j.hansur.2021.04.007>

“prise en crochet” semble être dangereuse et devrait être utilisée avec prudence par les grimpeurs pour prévenir cette pathologie. De plus, notre patient devra être prudent dans sa pratique de l’escalade en raison de l’hyperutilisation des ongles et du *flexor digitorum profundus* objectif évalué par le modèle biomécanique.

1. Introduction

Sport climbing is becoming increasingly popular, with an increasing number of participants accompanied by a steep increase in the overall level of practice [1]. Climbing consists in moving on vertical or overhanging walls using hands and feet to grasp various holds [2,3]. This requires high-intensity forces exerted by the hand, fingers or fingertips on climbing holds, the depth of which is frequently just a few millimeters [4]. Climbers may sometimes execute moves with a single arm and the force intensities at the hold/finger interface can exceed body weight when executing certain dynamic movements [5].

Many injuries occur during sport climbing [6,7]. The finger position associated with the exerted force results in excessive tension in the tendons, and in particular in the flexor tendons of the distal and middle phalanges [8]. These tendons are held close to the bone by a thickened fibrous sheath or “pulley”; if tension in the tendon is too great, since the tendon is connected to the pulley it may cause it to rupture [4,9]. Broken pulleys are the most common injuries in climbers. Tendonitis is also reported, but very little is known about rupture of the finger flexor tendons [10,11]. Even for activities other than climbing, tendon rupture is rare, and is located predominantly at the distal insertion of the flexor digitorum profundus (FDP) tendon [12–14]. The single report of flexor digitorum superficialis (FDS) involvement was made recently by Schweizer and Bayer, who observed disruption of one of the two tendon slips, in two climbers and one judoka [15].

Whatever the nature of the finger injury during climbing, the grip techniques used are the predominant causal factors. In the literature [16] two main types of grip technique are described and analyzed: crimp and slope (Fig. 1). They are distinguished by the articular angles of the 3 finger joints. The crimp grip involves hyperextension of the distal interphalangeal joint (DIP) and significant flexion of the proximal interphalangeal joint (PIP) while the metacarpophalangeal joint (MCP) remains slightly flexed. The thumb may be positioned on the other fingers (full crimp) or not (half crimp). By modeling the musculoskeletal system of the fingers, several studies provided explanations and quantifications for the high number of reported pulley ruptures associated with this grip technique [17]. The slope grip, on the other hand, involves 40°–70° DIP flexion and slight flexion of the PIP and the MCP. These two techniques are used alternatively by climbers depending on the shape of the hold, the climbing

movement and/or the climber's individual preference. Though much less frequent than these two typical grips, an almost infinite number of alternative techniques, not necessarily known or classified in the literature, are possible, by varying the ranges of motion of the 15 joints of the 5 fingers. One such is a grip technique with fingers positioned like a “hook”. With this technique, the DIP and PIP joints are almost fully flexed while the MCP is in neutral position (Fig. 1). This technique (here referred to as the “hook” grip) can be used on holes (such as rings), with the holding force exerted on the middle phalanges while the distal phalanges remain free in the hole. It may also be used on micro-holds (a few millimeters deep) to exert force longitudinally to the distal phalanx with the nails (here referred to as the “nail” grip). This posture is less common than the slope grip and crimp grip but is nevertheless used by some climbers. As it is not usual and no typical injuries have been reported with its use, no studies have investigated this specific technique.

In the present study we conducted a detailed analysis of full flexor digitorum superficialis (FDS) tendon rupture in an intermediate level sport climber [18]. We considered that the case required in-depth investigation for three reasons. Firstly, to our knowledge, no full FDS tendon rupture in sport climbing has been analyzed in the literature, whereas several cases seem to have occurred in the community without publication of case reports. Secondly, the rupture occurred when the climber used a hook finger grip technique, for which little information can be found in the literature. Thirdly, treatment resulted in complete recovery, thus suggesting a way to treat this type of injury. The study first presents the case and treatment report with an evaluation of performance recovery. Additionally, a biomechanical analysis using finger musculoskeletal modeling was performed, comparing the hook grip to other grips, estimating of the new biomechanical functioning of the patient's musculoskeletal system.

2. Patient and methods

2.1. Case report

The case report concerns a 28-year-old male climber (175 cm, 69 kg, hand length: 18.5 cm) who presented FDS tendon rupture in the middle finger of the left hand. The patient was a right-handed non-smoker, working as a dentist and practicing climbing twice a

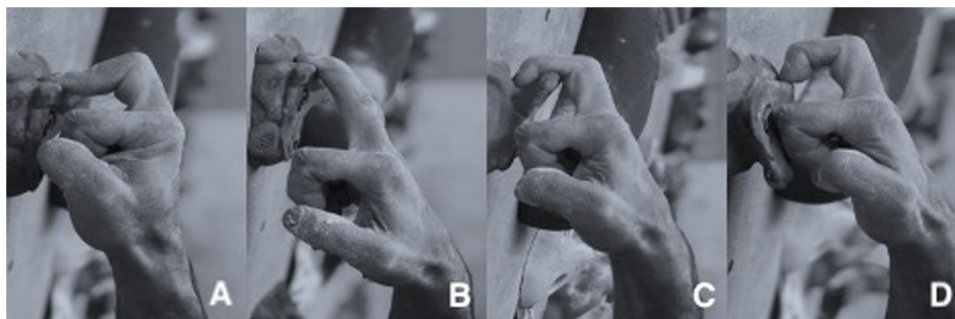


Fig. 1. Photos of finger hold grip techniques used during climbing. The crimp (A) and slope (B) techniques are frequently used, while the hook (C) and nail (D) techniques are rare. Finger force is exerted on the pulp of the finger for the crimp and slope grips, and on the middle phalanx for the hook grip and on the fingertip for the nail grip.

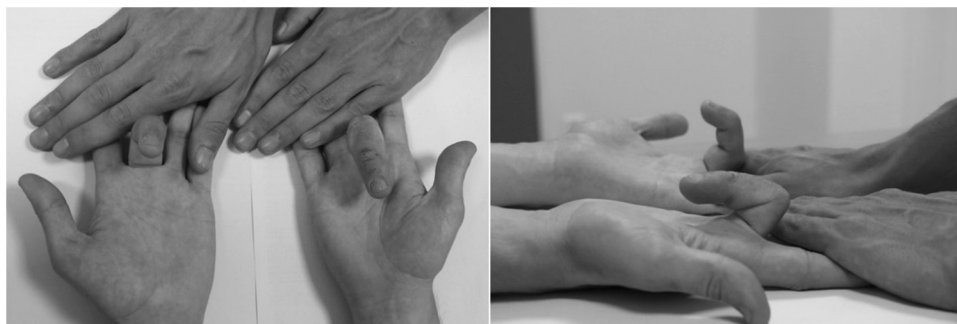

Fig. 2. Clinical diagnosis of the left (injured) and right (asymptomatic) hands. The picture illustrates the limited range of motion of the left PIP joint and the deficit of the FDS tendon.

week at an intermediate level according to the Draper et al. classification [19] (6c red-point level on the UIAA grade scale). The patient had no diseases, did not report any previous trauma concerning his left hand, and was not taking any drugs (corticosteroids or fluoroquinolones).

While applying maximum force with his left hand during a climb, the patient felt and heard an audible snap in his middle finger, accompanied by intense pain which caused him to fall. According to the patient, the configuration used at the moment of injury corresponded to the “hook” grip, with force principally exerted on the middle phalanx. The pain forced him to stop the session and cease any climbing for several days. As the symptoms persisted, he decided to consult an orthopedic surgeon. At the initial consultation (Day +20), the patient reported slight pain in the proximal phalanx of his middle finger. His only functional complaint was loss of strength, but which did not prevent him carrying out occupational and everyday activities. A diagnosis of pulley A2 rupture was first considered, but examination found a real deficit in the FDS tendon of the middle finger with functional FDP tendon and did not find any bowstring or spring effect (Fig. 2).

The clinical suspicion of tendon rupture was strengthened by ultrasonography, which confirmed a distal rupture in the FDS tendon by absence of insertion onto the middle phalanx (Fig. 3) and hematic effusion in the sheath distal to the PIP joint. This suspicion was confirmed on MRI, showing FDS tendon rupture at the distal insertion, while the pulleys and the FDP tendon appeared to be unaffected. No signs of traumatic or degenerative osteoarticular lesions in the finger, hand or wrist were observed on X-ray.

Because his everyday life was not really impacted, and after discussion with the surgeon, the patient decided to undergo functional treatment based on physiotherapy rather than surgery. Functional treatment was based on conservation of range of motion and combatting stiffness for three weeks, followed by progressive strength training.

The patient never interrupted his dental activity during the treatment. At 4 months, he was able to climb again, and at 6 months suffered only from loss of strength associated with discomfort in the middle finger. At 8 months, he performed the tests described in the current study.

2.2. Recovery evaluation and biomechanical analysis of the hook grip

This section comprises several parts addressing the various study aims. Firstly, to evaluate recovery, tests of finger force on a 12 mm climbing hold were performed for both right and left hands. To understand the biomechanics of the hook grip, an elite sport climber was asked to reproduce the hook grip which had led to the rupture, and other classical sport climbing grip techniques for comparison. Then, a musculoskeletal model of the hand was used to evaluate the tendon forces exerted by the elite climber

during each grip. Additionally, simulations of these tendon forces with a detached middle-finger FDS tendon were made to evaluate the musculoskeletal functioning of a middle finger with an injured FDS tendon.

2.3. Materials

We attempted to locate the actual hold being used at the moment of injury, so as to optimize the biomechanical tests and better understand the injury mechanism. However, the particular hold had been specifically designed at the gym and was lost. It was therefore reproduced by ABS (acrylonitrile butadiene styrene) 3D

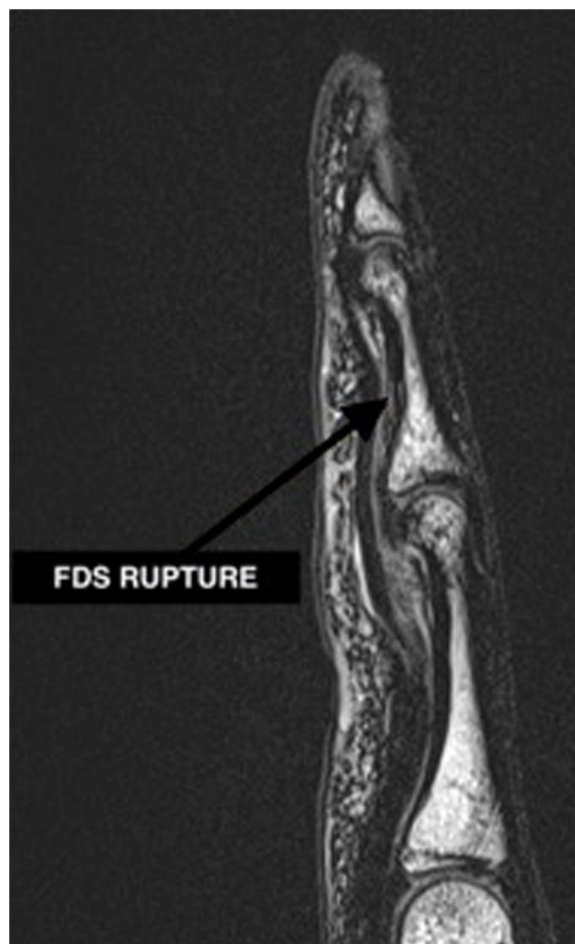

Fig. 3. MRI of the middle finger of the left hand. The arrow indicates the site of the FDS rupture.




Fig. 4. CAD drawing of the specific hold that led to the injury. CAD was based on the patient's description and memory. Frontal view (left) and upper-rear view (right).

printing (Ultimaker[®], S5, Utrecht, Netherlands) from 3D models designed using SolidWorks[®] software (Dassault Systèmes SE[®], Vélizy-Villacoublay, France) based on descriptions given by the patient (Fig. 4).

The climbing hold reproduction was then fixed to a specific instrumented hangboard device fitted with force sensors (SmartBoard[®], Peypin d'Aigues, France). This system was based on a vertical force platform fitted with 4 vertical 1D strain-gauge sensors recording the vertical force applied by the finger at 50 Hz with an accuracy of 0.8 N. Data were transferred via Bluetooth to a tablet and exported for data processing. A smartphone camera (Samsung A8[®], 2224 × 1080 pixels, 25 Hz) was placed in the sagittal plane perpendicular to the wall to identify the joint posture.

2.4. Procedures

After warming up, the patient was asked to perform a maximum force grip with both right and left hands, to evaluate his rehabilitation 8 months after injury. For safety purposes, the tasks were performed with the 4 fingers simultaneously, and the hook and nail grips were avoided.

After warm-up, the right-handed elite climber (41 years old, height 177 cm, weight 72 kg, hand length: 19.2 cm; 8c+ red-point level on the UIAA grade scale) was asked to apply maximum effort using four different finger techniques with the middle finger only: crimp, slope, hook (with force exerted on the middle phalanx) and nail grip (with force exerted by the tip of the distal phalanx close to the nail, directed along the longitudinal axis of the distal phalanx). The elite climber was asked to perform maximum strength tests for five seconds per grip, with the right hand. An elite climber was chosen for this test in order to accurately adjust the finger grip according to the requirements of the crimp, slope, hook and nail grips as described by the patient and the experimental team. Moreover, given his level, we assumed that he was experienced and robust enough to endure the required grip techniques, including the culprit hook grip.

The tests were carried out on the 12-mm deep hold of the SmartBoard for the crimp, slope and nail grips, while the printed hook hold (Fig. 4) was used for the hook grip and nail grip. The hold was located 1.8 m from the ground and the subject was standing with arm raised: the wrist was close to its neutral position, while the elbow and shoulder joints were extended. Each trial was separated by a one-minute rest and the subject alternated between

left and right hands. Two trials were carried out for each grip technique.

2.5. Data analysis

The maximum grip force exerted during each test was evaluated using an averaged window (250 ms) centered on the peak force. The captured images were used to determine the angular position of the MCP, PIP and DIP joints using Kinovea[®] software (0.7.10).

A previously developed musculoskeletal model of the finger [17] was modified to determine the tendon forces developed during each tested grip. Briefly this model consisted in solving the tendon redundancy problem using numerical optimization based on muscle stress criteria while respecting the static mechanical equilibrium at each finger degree of freedom [20]. Inputs for the model comprised fingertip force and joint angles measured during the experiment, while outputs were tendon forces. This inverse dynamic approach then assumes that the external moments produced by the fingertip force at the level of the joints are balanced by muscle action. The overall model of the hand with 43 muscles and 23° of freedom was considered, although the external grip force was exerted only in the middle finger [21]. Three different versions of the model were used in the study: the Healthy Model without injury; the 1st Injured Model, in which the FDS tendon is fully detached and has no action on the joints; and the 2nd Injured Model, in which the FDS tendon is partially reinserted at the level of the proximal phalanx and still has an influence on the MCP joint. For the latter, we modeled conserved FDS tendon actuation at the MCP joints equivalent to half its initial moment arm. Using these models, the total of 43 tendon forces were estimated for each condition but, for clarity in the current study, only the results of forces exerted in the FDP and FDS tendons of the middle finger are presented. Tendon force/fingertip force ratios were also computed to evaluate the grips' effectiveness.

2.6. Data analysis

The four-finger maximum force exerted by the patient during crimp and slope grips was compared between left and right hands to evaluate their recovery, assessed on Wilcoxon test. The significance threshold was set at 0.05. The maximum grip forces exerted on the holds by the elite climber, the force of the middle FDS tendons and the tendon force/grip force ratios of the middle

FDS and FDP were qualitatively compared between the 4 grip techniques. Results for FDP and FDS tendon force and ratios were also compared between the Healthy Model and the two Injured Models to evaluate the new configuration of the patient's musculoskeletal system.

3. Results

3.1. Patient's recovery

The maximum grip force achieved by the patient 8 months after injury is presented in Fig. 5. Maximum grip force was 304.2 ± 21.0 N for the right hand and 295.4 ± 55.2 N for the left hand with the Slope grip, and 334.9 ± 15.5 N and 324.7 ± 3.9 N respectively with the Crimp grip. The Wilcoxon test showed no significant difference between right and left hands or between Crimp and Slope grips ($p = 0.84$).

3.2. Comparison of grip techniques

Fig. 6 shows the maximum grip force exerted by the elite climber according to the four grip techniques tested. Compared with the Crimp grip, force was -19.4% with the Slope grip, -42.1% with the Nail grip and $+114.6\%$ with the Hook grip.

Fig. 7 shows the forces exerted in the FDP and FDS tendon for the middle finger during the four tested grips. FDS tendon force ranged from 172.2 N for the Crimp grip to 878.2 N for the Hook grip: i.e., $+568.3\%$ higher with the Hook grip than with the Crimp grip; it was respectively $+95.5\%$ and $+116.9\%$ higher with Slope and the Nail grips. FDP tendon force was higher during Crimp and Slope

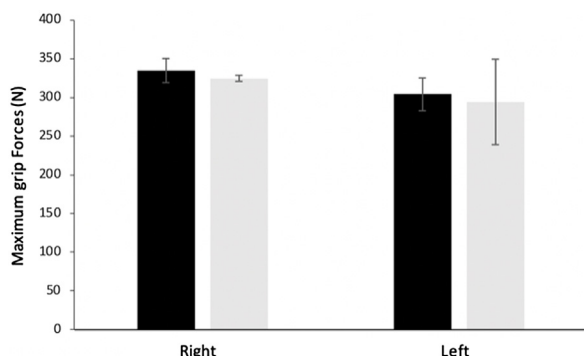


Fig. 5. Maximum grip forces applied by the patient after 8 months' recovery with the four fingers simultaneously in the Crimp (black) and Slope (white) grips. The left and right hands did not show any significant difference.

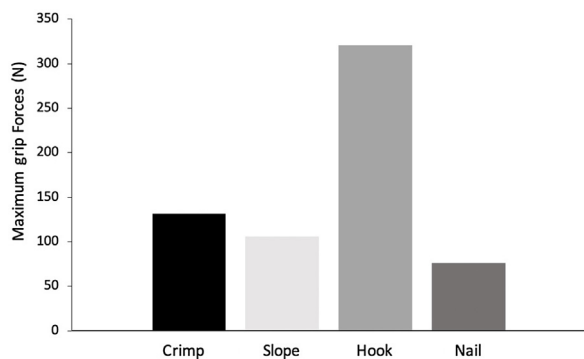


Fig. 6. Maximum grip forces exerted by the elite climber with the right hand during the Crimp, Slope, Hook and Nail grip techniques. Hook and Nail techniques were reproduced according to the patient's description and experimenter's indications.

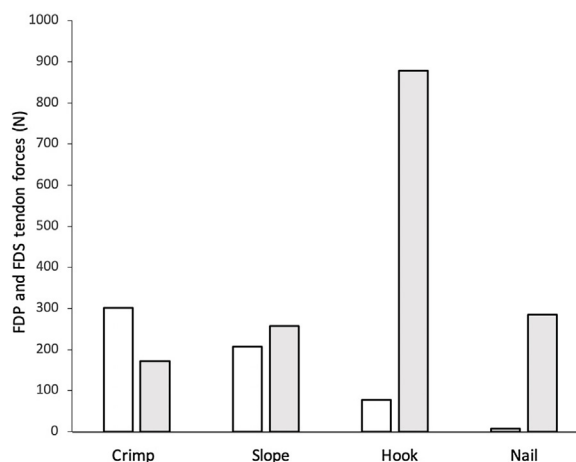


Fig. 7. FDS (gray) and FDP (white) tendon forces estimated during the Crimp, Slope, Hook and Nail grips. The tendon forces were estimated by the musculoskeletal model, using the grip forces and the finger joint angles of the elite climber as inputs.

grips (302.3 N and 207.1 N respectively) than during Hook (77.9 N) and Nail grips (7.4 N).

Fig. 8 shows the tendon force/grip force for the FDS and FDP tendons for the 4 tested grips: for the Crimp grip, 1.3 for the FDS and 2.3 for the FDP; for the Slope grip, 2.4 and 1.9 respectively; for the Hook grip, 2.7 and 0.2; and for the Nail grip, 3.7 and 0.1.

3.3. Simulation of injured musculoskeletal systems

Simulating the same grip techniques with the 1st and 2nd Injured Models (without FDS or with diminished FDS, respectively), the musculoskeletal model estimated that FDS tendon force was null for all grips. The FDP tendon force ranged from 215.4 N with the Nail grip to 507.9 N for the Hook grip, with 441.4 N and 472.5 N for the Crimp and Slope grips, respectively. FDP tendon force/grip force ratios were 3.4, 4.5, 1.6 and 2.8 for both versions of the model with the Crimp, Slope, Hook and Nail grips, respectively.

4. Discussion

In the literature, there are several case reports of FDS tendon rupture during activities other than climbing [22–29]. Boyes et al. [30] performed a literature review of spontaneous flexor tendon rupture and found that 12% of reported ruptures involved only the FDS tendon ($n = 9/80$); 10% occurred in the middle finger. Treatment is not consensual. Some authors try primary repair

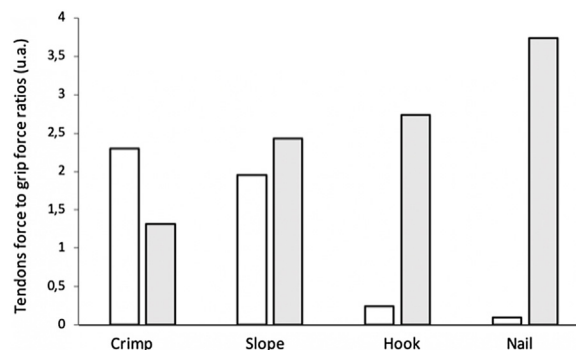


Fig. 8. FDS (gray) and FDP (white) tendon force/grip force ratios estimated during the Crimp, Slope, Hook and Nail grips. These tendon forces were estimated using the musculoskeletal model, using the grip forces and joint angles of the elite climber as input.

[27,28], others resection [22–24,29], while others prefer functional treatment with physiotherapy [26,27,30] with equally disparate results. Faced by the unusual diagnostic delay in the present case, it seemed reasonable to us to first attempt functional treatment with a patient who presented few symptoms 20 days after the injury. The strategy was then to consider surgery with resection of the FDS and more or less extensive capsulectomy only if no improvement was observed with physiotherapy [31]. Eight months after injury, the patient was tested for maximum grip force with left and right hands. The prime objective of this study was to report the case, evaluate the patient's recovery and analyze the specific injury.

4.1. Injury and recovery analysis

Whichever the tested grip (Crimp or Slope), the patient did not present any force deficit between the left and right hands. Considering the patient's level before injury, it could be reasonably assumed that he had balanced capacity between the left and right hand, as demonstrated by Bolen et al. [4]. The similar left- and right-hand performances after 8 months thus suggest that his musculoskeletal system adapted to the lack of FDS tendon insertion in the middle finger. This was confirmed by the fact that, by this stage, the patient did not feel any pain in the finger during everyday activities or climbing. He also recovered his previous level of climbing performance. These results reflect the effectiveness of the functional treatment, allowing gradual recovery of capacity while deprived of FDS tendon function in the middle finger. Several hypothetical adjustment strategies can be considered to explain this recovery. Firstly, the patient may be using a different distribution of force between the fingers in the grip. When using all 4 fingers simultaneously, he could alter the finger force distribution in his left hand as compared with the usual distribution described in the literature [32]. For example, force could be distributed mainly between the other 3 fingers: index, ring and little. This would compensate for the strength deficit of the middle finger due to the absence of the FDS tendon. Additional measurements of force exerted by each finger would be required to confirm this hypothesis. Nevertheless, the fact that the patient did not feel any discomfort in everyday activities suggests that this phenomenon is limited. Another plausible hypothesis is that the middle finger was actuated differently by muscles once the FDS tendon was no longer exerting any force: the subject would adopt a different muscle distribution to produce the same external performance. The results of the 1st and 2nd Injured Models showed that the muscle forces in this case would mainly be redistributed in the FDP tendon with extremely high FDP tendon force and ratios. Based on a study of the mechanical properties of the FDP muscle, the maximum breaking point for this muscle is 548 N [33], which is a value close to those estimated on the Injured Models. Thus, if this assumption is true, it can be assumed that the FDP muscle inserting into the left middle finger presents a high risk of injury during activities such as climbing. If the subject overuses the FDP muscle of the left middle finger with repeated cycles, the excessive tension could lead to an injury of the same type as that already produced with the FDS. Finally, a third hypothesis is that the remaining FDS tendon may have created healing links, with fibrosis at the level of the upstream joint (MCP). In this kind of attachment, the tendon would still exert a mechanical action at the MCP (without, however, acting on the PIP). Considering an FDS capacity diminished by half at the MCP joint, the second Injured Model showed that, even in this case, the FDP tendon would be overused. This means that FDS tendon force is mainly required at the PIP joint for climbing grips and, once compensated for by additional FDP tendon force, the FDS tendon is of little use at the level of the MCP joint.

Nevertheless, to confirm these hypotheses it would be necessary to perform additional measurements, especially of the

force exerted by each finger. It is also essential to perform further MRI scans of the current state of the FDS muscle and its potential reattachment. This will make it possible to know exactly what action on the FDS and which hypothesis should be favored among all those presented above. Whatever the hypothesis, our results indicate an increased risk of injury to the FDP of the left middle finger during the practice of sport climbing. These conclusions have thus been communicated to the patient and he has been advised to avoid strong grip force on small holds with his right hand in order to prevent such a scenario.

4.2. Hook and nail grip analysis

The second objective of this study was to investigate the risk/benefit ratio of using the nail or hook grip techniques for healthy climbers, and to assess the intensity of FDS and FDP tendon force. Results for grip force showed that the elite climber exerted strong grip force with the hook grip and less force with the nail grip. This suggests that the nail grip is very specific, giving rise to poor performance, which probably explains why it is not often used by climbers, except for micro-holds where only the fingertip can exert force. Moreover, for this grip, the model showed very unfavorable tendon force/grip force ratios, resulting in poor effectiveness. Nevertheless, the tendon force of both the FDS and the FDP was low during this grip, in accordance with the low grip force. Although some doubts persist, this confirms that our patient was probably not using the nail grip at the moment of injury but rather the hook grip. It was important to clarify this point, since, given the configuration of the culprit hold, it was possible that part of the force would be exerted by the fingertip. The hook grip, in contrast, appears to be a stronger full grip. This better performance is because the point where the force is exerted is in the middle phalanx. This reduces the net joint moment at the DIP and other joints, allowing better muscle performance. Nevertheless, this involves forces in the FDS tendon that are greater than the tendon can support [33], assuming that the FDP and FDS tendons have similar rupture thresholds. The results showed that the FDS tendon force/grip force ratios with this grip are higher than in the crimp and slope grips, confirming the risky configuration of the hook grip for the FDS tendon. This phenomenon is thus probably the mechanical explanation for our patient's FDS rupture. Consequently, even if the hook grip provides very high grip force, it should be avoided, as it actuates the FDS in a way that could easily lead to injury. In situations where there is no choice, climbers should be advised to actuate the whole finger, including the tip, so as to actuate the FDP tendon: this "artificial" co-contraction could help the FDS tendon to balance the PIP joint.

The present study had certain limitations. The musculoskeletal model was based on anthropometric data and generic assumptions about the functioning of the central nervous system, which led to inaccuracy. Moreover, for safety, we did not ask the patient to perform every grip with only one finger, which also limited the results. Another limitation was that our musculoskeletal model did not consider the complex interactions between flexor tendons and pulleys and between the FDS and FDP tendons [34–36]. We assume that these limitations do not cast doubt on our conclusions, but further studies should be conducted, with a representative sample of sport climbers and an accurate model of the mechanical loads and interactions acting at the FDS insertion.

5. Conclusion

The present study reports an original case of injury during sport climbing, with mechanical explanations and clarifications concerning this type of injury and the patient's recovery.

Conservative treatment gave positive results, although our results showed that the patient should avoid further overuse of the remaining FDP tendon during climbing practice. Additionally, our analysis pointed out that “hook” and “nail” grips impose high loads on the FDS tendons. This information needs to be considered by trainers and climbers in order to prevent FDS rupture.

Human and animal rights

The authors declare that the work described has been carried out in accordance with the Declaration of Helsinki of the World Medical Association revised in 2013 for experiments involving humans as well as in accordance with the EU Directive 2010/63/EU for animal experiments.

Conflict of interest

The authors declare that they have no known competing financial or personal relationships that could be viewed as influencing the work reported in this paper.

Funding

This work did not receive any grant from funding agencies in the public, commercial, or not-for-profit sectors.

References

- [1] Jones G, Schöffl V, Johnson MI. Incidence, diagnosis, and management of injury in sport climbing and bouldering: a critical review. *Curr Sports Med Rep* 2018;17:396–401.
- [2] Quaine F, Martin L, Leroux M, Bianchi JP, Allard P. Effect of initial posture on biomechanical adjustments associated with a voluntary leg movement in rock climbers. *Arch Physiol Biochem* 1996;104:192–9.
- [3] Watts PB, Daggett M, Gallagher P, Wilkins B. Metabolic response during sport rock climbing and the effects of active versus passive recovery. *Int J Sports Med* 2000;21:185–90.
- [4] Bollen SR, Gunson CK. Hand injuries in competition climbers. *Br J Sports Med* 1990;24:16–8.
- [5] Bourdin C, Teasdale N, Nougier V, Bard C, Fleury M. Postural constraints modify the organization of grasping movements. *Hum Mov Sci* 1999;18:87–102.
- [6] Forrester JD, Tran K, Tennakoon L, Staudenmayer K. Climbing-related injury among adults in the United States: 5-year analysis of the national emergency department sample. *Wilderness Environ Med* 2018;29:425–30.
- [7] Gneccchi S, Moutet F. Escalade: pathologies de la main et des doigts. Paris: Springer; 1991.
- [8] Vigouroux L, Quaine F, Labarre-Vila A, Moutet F. Estimation of finger muscle tendon tensions and pulley forces during specific sport-climbing grip techniques. *J Biomech* 2016;39:2583–92.
- [9] Tropet Y, Menez D, Balmat P, Pem R, Vichard P. Closed traumatic rupture of the ring finger flexor tendon pulley. *J Hand Surg Am* 1990;15:745–7.
- [10] Schöffl V, Heid A, Küpper T. Tendon injuries of the hand. *World J Orthop* 2012;3:62–9.
- [11] Cole KP, Uhl RL, Rosenbaum AJ. Comprehensive review of rock-climbing injuries. *J Am Acad Orthop Surg* 2020;28:e501–9.
- [12] Takami H, Takahashi S, Ando M. Rupture of the flexor digitorum profundus tendon in the palm caused by repeated, chronic direct trauma. *J Hand Surg Am* 1993;18:65–7.
- [13] Naam NH. Intratendinous rupture of the flexor digitorum profundus tendon in zones II and III. *J Hand Surg Am* 1995;20:478–83.
- [14] Pierrart J, Leclercq C. Unusual rupture of a flexor profundus tendon in a rock climber. *Chir Main* 2012;31:202–5 [in French].
- [15] Schweizer A, Bayer T. Closed disruption of a single flexor digitorum superficialis tendon slip: 3 cases. *Hand Surg Rehabil* 2019;38:121–4.
- [16] Schweizer A. Biomechanical properties of the crimp grip position in rock climbers. *J Biomech* 2001;34:217–23.
- [17] Vigouroux L, Quaine F, Pacllet F, Colloud F, Moutet F. Middle and ring fingers are more exposed to pulley rupture than index and little during sport-climbing: a biomechanical explanation. *Clin Biomech* 2008;23:562–70.
- [18] Caso H, Mayoly A, Curvale C, Kachouh N, Legré R. Rupture atypique d'un tendon fléchisseur superficiel chez un grimpeur. *Hand Surg Rehabil* 2018;37:397.
- [19] Draper N, Gilles D, Schöffl V, Fuss KF, Watts P, Wolf P, et al. Comparative grading scales, statistical analyses, climber descriptors and ability grouping: International Rock-Climbing Research Association Position Statement. *Sports Technol* 2015;8:88–94.
- [20] Vigouroux L, Quaine F, Labarre-Vila A, Amarantini D, Moutet F. Using EMG data to constrain optimization procedure improves finger tendon tension estimations during static fingertip force production. *J Biomech* 2007;40:2846–56.
- [21] Goislard De Monsabert B, Rossi J, Berton E, Vigouroux L. Quantification of hand and forearm muscle forces during a maximal power grip task. *Med Sci Sports Exerc* 2012;44:1906–16.
- [22] Cheriyan T, Neuhaus V, Mudgal C. Isolated closed rupture of the flexor digitorum superficialis tendon. *Indian J Plast Surg* 2012;45:583–5.
- [23] Praveen B, Vivekanand C, Sabapathy RS. Spontaneous rupture of one slip of flexor digitorum superficialis causing triggering. *Indian J Plast Surg* 2014;47:272–3.
- [24] Stern JD, Mitra A, Spears J. Isolated avulsion of the flexor digitorum superficialis tendon. *J Hand Surg Am* 1995;20:642–4.
- [25] Martinache X, Cognet JM, Schernberg F. Spontaneous rupture of the flexor digitorum superficialis tendon of the index and middle fingers: the pen sign. *Chir Main* 2009;28:330–3.
- [26] Tos P, Catalanó F. Spontaneous rupture of the flexor superficialis tendon of ring finger: a case report and review of literature. *Musculoskelet Surg* 2011;95:245–6.
- [27] Folmar RC, Nelson CL, Phalen GS. Ruptures of the flexor tendons in hands of non-rheumatoid patients. *J Bone Joint Surg Am* 1972;54:579–84.
- [28] Courtney MJ, MacIndoe NL. Isolated traumatic avulsion of the flexor digitorum superficialis tendon: a case report and review of this condition. *Hand Surg* 2000;5:81–4.
- [29] Ferraro SP, Schenck RR. Isolated closed rupture of the bony insertion of the flexor digitorum superficialis tendon: an unusual case. *J Hand Surg Am* 1998;23:837–9.
- [30] Boyes JH, Wilson JN, Smith JW. Flexor tendon ruptures in the forearm and hand. *J Bone Joint Surg Am* 1960;42:637–46.
- [31] Alsaadi Y, Alhassan TS, Alfawzan MF, Aldekhayel S, Almeshal OM. A successful surgical treatment of a closed rupture of flexor digitorum superficialis in surgeon's hand. A case report and review of literature. *Int J Surg Case Rep* 2020;67:235–8.
- [32] Quaine F, Vigouroux L, Martin L. Effect of simulated rock-climbing finger postures on force sharing among the fingers. *Clin Biomech* 2003;18:385–8.
- [33] Felder JJ, Guseila LM, Saranathan A, Shary TJ, Lippitt SB, Elias JJ. Mechanical properties of the flexor digitorum profundus tendon attachment. *J Hand Microsurg* 2016;5:54–7.
- [34] Walbeehm ET, McGrouther DA. An anatomical study of the mechanical interactions of flexor digitorum superficialis and profundus and the flexor tendon sheath in zone 2. *J Hand Surg Br* 1995;20:269–80.
- [35] Moor BK, Nagy L, Snedeker JG, Schweizer A. Friction between finger flexor tendons and the pulley system in the crimp grip position. *Clin Biomech* 2009;24:20–5.
- [36] Schweizer A, Frank O, Ochsner PE, Jacob HAC. Friction between human finger flexor tendons and pulleys at high loads. *J Biomech* 2003;36:63–71.