

SEBILLAUD, P., E. BERGER, K. HOU, G. GUEGUEN, Z. JING, X. PEIXOTO, J. KEUTE & T. DEVIÈSE. 2022. Catholic-Confucian Mortuary Practices in a Rural Manchurian Cemetery. *Historical Archaeology* 56: 1–31. <https://doi.org/10.1007/s41636-022-00330-x>.
<https://link.springer.com/article/10.1007/s41636-022-00330-x>

Catholic-Confucian Mortuary Practices in a Rural Manchurian Cemetery

Pauline Sebillaud & Elizabeth Berger & Kan Hou & Gwendal Gueguen & Zhongwei Jing & Xavier Peixoto & Jennifer Keute & Thibaut Devière

Abstract: Catholic missionaries were active among rural populations in Manchuria, in northeast China, around the turn of the 20th century. Their presence influenced everything from the role of women in religious and family life, to the adoption of new material culture, to local burial customs. This investigation of the Pianliancheng cemetery in Jilin Province, in use from the 1890s to the 1930s, reveals the material and embodied traces of this history. Archaeological, bioarchaeological, and historical evidence for cultural hybridization and transnational connections are presented. Specific findings include the history of individual Catholic priests in the mission, the hybridization of Catholic and Confucian burial practices by the Chinese converts, material connections to Chinese immigrant communities abroad, the labor burden and nutritional status of various members of the community, the continuation of foot binding in rural Manchuria, and the influence of conversion on gender roles and family life.

Resumen : Los misioneros católicos estaban activos entre las poblaciones rurales de Manchuria, en el noreste de China, a principios del siglo XX. Su presencia influyó en todo, desde el papel de la mujer en la vida religiosa y familiar hasta la adopción de una nueva cultura material y en las costumbres funerarias locales. Esta investigación del cementerio de Pianliancheng en la provincia de Jilin, en uso desde la década de los 1890 hasta la de los 1930, revela las huellas materiales y encarnadas de esta historia. Se presentan evidencias arqueológicas, bioarqueológicas e históricas de hibridación cultural y conexiones transnacionales. Los hallazgos específicos incluyen la historia de sacerdotes católicos individuales en la misión, la hibridación de las prácticas funerarias católicas y confucianas por parte de los conversos chinos, las conexiones materiales con las comunidades de inmigrantes chinos en el extranjero, la carga laboral y el estado nutricional de varios miembros de la comunidad, la continuación de vendaje de pies en la zona rural de Manchuria y la influencia de la conversión en los roles de género y la vida familiar.

Résumé : Vers le début du 20^{ème} siècle, les missionnaires catholiques étaient actifs au sein des populations rurales de Mandchourie, dans le Nord-Est de la Chine. Leur présence a exercé une influence considérable, notamment sur le rôle des femmes au sein de la vie religieuse et familiale, l'adoption d'une nouvelle culture matérielle et les coutumes funéraires locales. Cette étude portant sur le cimetière de Pianliancheng dans la province du Jilin, utilisé des années 1890 jusqu'aux années 1930, met en évidence les traces matérielles de cette histoire. Les données archéologiques, bioarchéologiques et historiques dévoilent une hybridation culturelle et des connexions transnationales. Ces découvertes mettent en lumière l'histoire individuelle de prêtres catholiques et de leur mission, l'hybridation des pratiques funéraires catholiques et confucéennes au sein des convertis chinois, des connexions matérielles aux communautés de migrants chinois à l'étranger, les conditions de travail et l'alimentation des différents membres de la communauté, la pérennité de la pratique du

bandage des pieds dans les campagnes de Mandchourie et l'influence des conversions dans les dynamiques des genres et la vie familiale.

Keywords: Chinese archaeology . northeast China . funerary archaeology . osteoarchaeology . Catholic missionaries

Due to the lack of personal voices from rural converts, who constituted the majority of the Chinese Christian population in the nineteenth century, the story of Chinese Catholic women, especially those in rural society, has been unknown for too many years. (J. Li 2013:31)

1. Introduction

In the second half of the 19th and the first half of the 20th centuries, religious and political life in China were rapidly evolving and ever more complex. This was a consequence of overpopulation, repeated disasters and upheavals, including decay of government authority, and incursions by hostile or extractive foreign powers (J. Lee and Campbell 2007). These processes, furthermore, are reflected on a local scale through historical documents, material culture, and human remains.

This project explores the political and religious context of Pianliancheng (Figs. 1, 2), a late 19th-century Catholic cemetery discovered in northeast China, in the region known as Manchuria, and the impact of Catholic conversion on the local population. During a salvage excavation of the cemetery, archaeologists made a surprising discovery: a medal of the Immaculate Conception (also called a “Miraculous Medal”) (Fig. 3) inscribed, in French: Ô MARIE CONÇUE SANS PÉCHÉ PRIEZ POUR NOUS\QUI AVONS RECOURS À VOUS¹. Research into the local archives of Lishu District (Bai 1934) and of the Paris Foreign Missions (Société des Missions-étrangères de Paris [SMEP] 1871–1941) led to the identification of the creator of the cemetery as the French priest Armand Joseph Déan (1866–1899), who asked to be buried among the Catholic community he built at Lishu. This indicates that the Pianliancheng cemetery likely belonged to the Christian community of Lishu around the turn of the 20th century. Remarkably, Father Déan appears in both the French and the Chinese historical records, which document the beginning and end of his life at opposite ends of Eurasia.

Here, archaeological, bioarchaeological, and archival materials are used to reconstruct the ways the local rural Manchurian population negotiated the tensions between their new Catholic faith and their traditional Confucian social structures and ritual life by hybridizing their mortuary rites and other practices. Further, this article investigates how this hybridization process impacted their material conditions, such as the status and labor requirements of different members of the community, particularly women. This is accomplished through four primary lines of evidence: both Chinese and French historical texts that recount the history of the Catholic mission in Manchuria, archaeological analysis of hybrid mortuary practices, analysis of mortuary objects, and bioarchaeological analysis of health and status from human skeletal remains.

1.1 Social and Historical Context

The period in question includes the end of the last dynasty, the Qing (1644–1911), followed by the Republican period (1912–1949). This era was rife with rebellions (e.g., the

¹ O Mary, conceived without sin, pray for us who have recourse to you.

Boxer Rebellion of 1899–1901), plagued by institutional decay and the lawlessness of warlords and bandits in the countryside, and beset by foreign incursions (Fairbank 1978; Fairbank and Liu 1980; J. Lee and Campbell 2007:47). In the cities, nationalist reformers embraced some aspects of Western science, technology, and political ideas (Fairbank 1983), and an industrial business class emerged (Bergère 1992). However, a general level of poverty characterized rural Chinese society, as the population doubled in the century between 1750 and 1850 (Banister 1992). As a result, the people suffered shortages, famine, epidemics, and inflation.

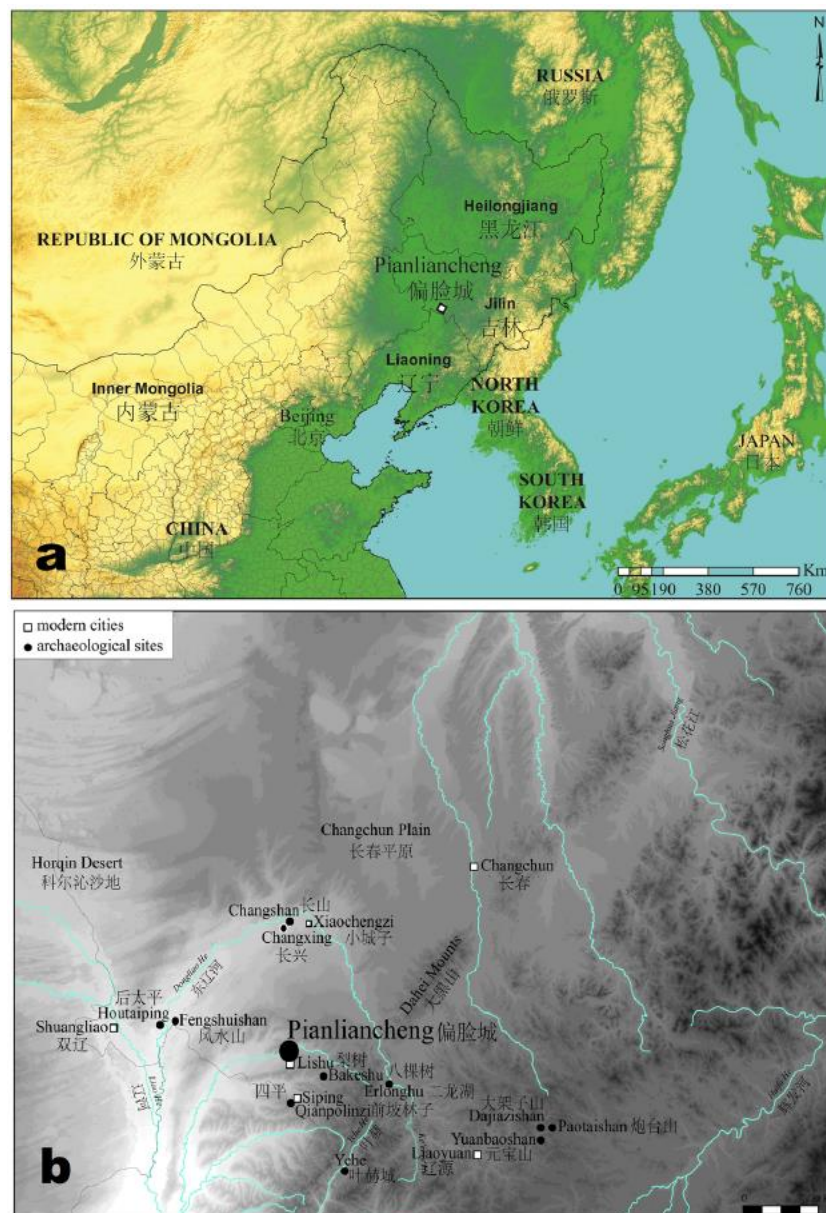

Fig. 1 Location of the Pianliancheng site (a) and surrounding archaeological sites (b). (Maps by Pauline Sebillaud, 2019.)

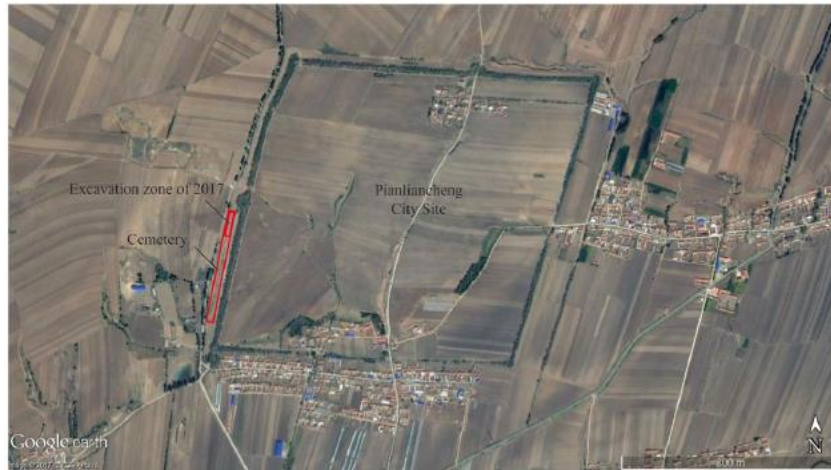

Fig. 2 Location of the Western cemetery on a satellite map of the Pianliancheng site. (Satellite photo from Google Earth, drawing by Pauline Sebillaud, 2018.)



Fig. 3 The “Miraculous Medal.” (Photo by Pauline Sebillaud, 2017.)

1.1.1 Gender

The traditional society of China was deeply Confucian at the time, and rites of marriage and burial were highly important for social cohesion. This patriarchal system also imposed a heavy burden of labor on women, whose role was to uphold the family’s economic and social standing. This gender inequity extended to mortuary rites as well (Liu 1999; Hu 2016). Women joined their husbands’ families after marriage, did not transmit their family name, did not get their own funerary epitaphs, and are mentioned in genealogy texts mostly as wives and daughters, who are sometimes only mentioned by their birth order and not their names. Women were not seen as full members of a bloodline and therefore were rarely granted the full status of ancestors through complete burial rituals (Watson and Rawski 1988:48) and were excluded from certain ancestor-veneration rituals from very early on (Liu 1999). The traditional link between the burials of husband and wife even influenced Chinese American funerary customs: some people’s remains were exhumed and returned to their natal families in China, but married women’s remains were not, as they were considered part of their husbands’ families in America (Smits 2008:119).

Pianliancheng also presents a unique opportunity to better understand foot binding, a centuries-old practice that was slowly coming to an end while the cemetery was in use. In much of traditional rural China, this permanent alteration of female bodies was performed on daughters by their mothers when they were quite young (4–8 years old) and was a prerequisite for marriage (Lau 2008). The practice affected their gait and mobility, and their overall health

(Gu et al. 2015), but most women with bound feet still performed basic activities and work. This phenomenon has been studied extensively by historians (Blake 1994:676–712; Gao 1995; Turner 1997; Wang 2000; Ko 2005; Lau 2008:206), while research on human skeletal remains has just begun (Zhao, Guo, Hao et al. 2017; Zhu et al. 2017; Berger et al. 2019; C. Lee and Sun 2019; Zhao, Guo, Xiao et al. 2020).

Skeletally, foot binding affected mainly the bones of the foot, especially the metatarsals and phalanges, which became abnormally short and thin. The specific features of bound feet during the Ming and Qing dynasties included reduced size and weight of all foot bones, with the effect more pronounced in the metatarsal bones and phalanges, and most pronounced in the lateral rays; alteration, especially narrowing, of tarsal bones; reduction and reorientation of trabeculae in tarsal bones; and underdevelopment of lower-leg musculature and more gracile lower-leg bone geometry (Zhao Guo, Hao et al. 2017; Zhu et al. 2017; Berger et al. 2019; C. Lee and Sun 2019; Zhao, Guo, Xiao et al. 2020).

The practice of foot binding was deeply anchored in traditional society, originating in the upper classes, but eventually spreading to all classes. The tightest binding was found among upperclass women, who lived a sequestered life and did not have to perform manual labor. By the Qing period, lower-class women would also have their feet bound, but because they were still expected to be economically productive, either by spinning and weaving at home or by laboring in the field, their bindings were often looser. In addition to great regional variation in the popularity and method of binding, there were also ethnic divisions. For instance, the binding was largely absent among Manchu women even when it was very widespread among the Han (Lau 2008:206). The practice was officially banned in 1902, but continued in the countryside for several more decades.

1.1.2 Nationality

The region in question, although located in northeast China, was mostly affiliated with Han Chinese cultural tradition. The population of northeast China was complex, composed of Manchu clan members, descendants of Han Chinese resettled from Shandong to the northeast by the government in the late 17th century (Campbell and J. Lee 2003:9), and Mongols, all administratively organized according to the banner system (Elliott et al. 2016; S. Chen 2017). During the Qing Dynasty (mid-17th century), the Manchus of northeast China ruled over the empire, but they were not numerous. Rising population in the Zhili region (modern Hebei and Shandong), floods, and droughts pushed more people to migrate north, and migrants eventually made up most of northeast China's rural population (J. Lee and Campbell 2007:6–7; B. Chen et al. 2018). By the late 19th century in this part of Jilin, the people and culture associated with the Manchu nationality did not have a strong presence. According to Catholic mission documents:

“Manchus have gradually disappeared and become naturalized among the Han. Although the Manchus have historically won wars due to their ability in fighting and martial arts, and have been able to rule China, the Han group has the upper hand in terms of customs, language and traditions” [translation by Pauline Sebillaud]. (Launay 1905:20)

It is not entirely surprising, therefore, that the Pianliancheng cemetery contains evidence of Han rather than Manchu traditions. The presence of bound feet certainly suggests a Han identity (Levy 1992; Wang 2000; Ko 2005; Lau 2008).

1.1.3 Traditional Chinese Mortuary Practices

Textual records provide a strong basis for comparison with traditional Chinese mortuary practices (Watson and Rawski 1988; Chung and Wegars 2005). In late imperial China, rituals associated with marriages and deaths were a “cultural cement” for this complex, multiethnic

society (Watson and Rawski 1988:7). The variations on traditional practices in northern China all contained common material elements. These included a coffin, a carefully prepared burial site, and grave clothes that were often prepared beforehand. After death, the body was prepared with a pillow under the head and was exposed for viewing for a set period of time before burial (Watson and Rawski 1988:38–39).

Archaeological comparisons, on the other hand, are difficult, since only a few Qing-period cemeteries have been excavated and published. Some of these are located in northeast China, though much archaeological research in the region is primarily focused on the identification of minority ethnic groups rather than analyzing burial traditions (Hulunbei'er meng wenwu guanli zhan 2000; Qiqiha'er shi wenwu guanlizhan 2005; Heilongjiang sheng wenwu kaogu yanjiusuo [HSWKY] 2010; Huo and Fu 2014). At one site, six Qing tombs with lacquered wooden coffins and gilded bronze hairpins were discovered (HSWKY 2012). South of Harbin, in Wuchang City, a late Qing settlement has been excavated and published, which is, to our knowledge, the only archaeological report about civilian architecture of this period (HSWKY 2015). In Jilin Province, three small cemeteries have been published and identified as family cemeteries of commoners from the Qing Dynasty or the late Qing to the Republican period (Jilin sheng wenwu kaogu yanjiusuo [JSWKY] and Yushu shi bowuguan [YSB] 2008, 2010; JSWKY2016). Finally, two Jesuit missionary cemeteries near Beijing have been documented, but not excavated (Malatesta and Gao 1995; Ming and We 2007). Their headstones show that these burials belonged to foreign Jesuit priests of the 17th to early 20th centuries.

Another significant source of data on contemporaneous burial practices comes from the burials of Chinese people who migrated to North America that have been studied from historical and archaeological perspectives (Abraham and Wegars 2003). This research offers substantial information on Chinese funerary customs at the turn of the 20th century:

“Immigrants shared many customs, among them the practice of secondary and occasionally tertiary burial. ... Primary burials were unmarked, with only a labeled brick or stone placed in the coffin to aid bone identification later on. Seven to ten years after the initial burial had taken place, the bones themselves were dug up, cleansed, and placed in a labeled ceramic urn, or *jinta* (*chint'a*), which could then be placed in an alternative location or simply replaced at the location of the initial burial”. (Kraus-Friedberg 2008:129)

In general, Chinese American funerary customs included elements of Confucianism, Daoism, and Buddhism, but not Christianity. Distraction or discouragement of unwelcome spirits was accomplished with music, incense burning, and by setting off firecrackers (Smits 2008:115).

1.1.4 Catholic Missionaries in Manchuria

The Missions-étrangères de Paris (MEP)² was entrusted with the apostolic vicariate of Manchuria in 1839 (Launay 1905:40), and, at the very end of the 19th century, hundreds of French missionaries were sent to China, some of them to Manchuria. Manchuria was the largest of the Chinese vicariates of the MEP and was divided into two vicariates in 1898: Southern Manchuria encompassed Liaoning Province and the southern part of Jilin Province, and Northern Manchuria, an area where missionaries had been active since the 1840s, was an immense region corresponding to the northern part of Jilin Province and today's Heilongjiang Province (Launay 1905:120–121). Unlike the Jesuits during the 16th and 17th centuries, who aimed their proselytizing at aristocrats and the elite, the MEP missionaries were sent to the countryside to baptize as many individuals as they could and establish rigorous ritual practices.

² Paris foreign missions.

This was a French colonial strategy in China, grounded in an ideology of Christian imperialism. Through the creation of new social groups and categories, the French hoped to exert influence on power relations, ethnicity, and so forth in the land where their missionaries were established (Lawrence and Shepherd 2006:73,85). Mission work, in fact, was conceived and justified as a way to compensate for British economic domination in China. British domination was the grounds for M. de Lagrené, French diplomat under Louis-Philippe, to argue for the intrusion of France into the religious affairs of China and the freedom of movement for the missionaries inside the country (Charbonnier 2002:201–202).

Within this context of forced contact with foreign powers, some of the rural population of Manchuria chose to convert to Catholicism. This choice had consequences for their material conditions, especially influencing the social roles, health, and labor requirements of different genders, as well as their burial practices. Given the subsequent disappearance of Catholicism and Catholic missionaries from rural Manchuria, archaeological and archival remains are the best avenue to reconstruct this history. As the people buried at Pianliancheng followed Catholic practices while still abiding by many traditional Confucian social strictures, the site contains evidence of the religious, social, and material trappings of the local population's conversion.

1.2 Cultural Hybridization

There were many processes at work in the settling of the French missionaries in Manchuria, the rural Manchurians' adoption of Catholic practices, and the local use of foreign manufactured goods. Primarily, the site represents a process of cultural hybridization, though in this case transnationalism and globalization were also at work.

Hybridity and hybridization constitute an area of archaeological theory that has been applied in a range of ways and with a range of meanings. Mostly derived from postcolonial theory (Bhabha 2004; Silliman 2013), the term is considered by some to be problematic or vague, hence the use of others: "entanglement" (Stockhammer 2012), "ethnogenesis" (Card 2013), "acculturation," "syncretism," "creolization," "bricolage," etc. (Liebmann 2013).

Each of these terms has specific connotations and its appropriate applications. Here we employ the term "hybridization" in a narrow sense to mean the bringing together, over a discrete time period, of material forms and religious practices from disparate cultural contexts. However, hybridization is not merely the mixing of discrete forms or aesthetic elements from different cultural spheres, but the practice of bringing these elements together to form new cultural spheres. Hybridization implies agency, as all cultural reproduction entails agency; it is a "process and a practice," and not a "label or category" (Silliman 2013:493). Its interpretative strength comes from its implication of a power imbalance and counterhegemonic resistance on the part of the people carrying out the hybridization (Liebmann 2013). It is a negotiation and is therefore generally bidirectional (Card 2013; Klaus 2013; X. Wu 2013).

Funerary rites are particularly revealing of hybridization because they reflect economic, religious, and other elements of social change (Klaus 2013). Graves are "mutually intelligible hybrid idioms" (Klaus 2013:227) that would have bound the Manchurians and the missionaries together into a shared ritual community.

The case at Pianliancheng, however, is distinct from many published cases because it was a temporary encounter. The Manchurian Catholic mission ended in 1947, and Catholicism disappeared from Manchuria. Pianliancheng, therefore, is an example of time-limited hybridization that was later abandoned and erased. Silliman (2012) advocates a definition of hybridization "between the *longue durée* and the *short purée*"—as not only a discrete mixing event, but also a long-term process of survival, in some cases stretching into the present day. In Australia, aboriginal people have a hybrid identity based in a shared

history with colonists (Byrne 2013). In the Andes, biological blending of Catholic colonists and indigenous people was the precursor to permanent hybrid practices (Klaus 2013). The rural Manchurian Catholics, in contrast, were a transitory formation that did not survive the closing of the mission and never developed such an enduring shared identity with the missionaries.

Furthermore, in Manchuria, the act of hybridization seems to have been unidirectional. Throughout the encounter, the colonial party—the missionaries—resisted hybridization with the locals, as opposed to missionaries’ conduct in other well-documented cases, for example, Spanish colonizers in Latin America (Deagan 2003). Though the Manchurian missionaries never expected to return to France, their correspondence and reports to the MEP make clear that they actively resisted adapting their lives to local conditions, such as food, drink, and furniture. Rather than hybridization, they, more accurately, participated in transnationalism and consciously worked to maintain bonds of kinship, politics, and culture with their distant home (Schmidt et al. 2011:15).

Finally, both the Chinese and French members of the Manchurian Catholic community experienced the globalization of material culture. At Pianliancheng the presence of manufactured objects from elsewhere in the world reflects the community’s participation in a shared set of material culture, aesthetics, practices, knowledge, etc., not bounded by national identities, but rather circulating on a global scale (Hodos 2009, 2016). As will be discussed below, these objects also tied the people of Pianliancheng to transnational Chinese communities abroad that shared material culture, languages, and burial customs.

2. Materials and Methods

2.1 Historical Materials and Methods

Archival research was undertaken first in the Chinese local gazetteers and then in the MEP publications and archives. The French civil archives also contained enough data to find Armand-Joseph Déan’s remaining family members, who had, by chance, preserved his personal letters describing his missionary work in rural Manchuria.

Written records about 19th-century rural Manchuria are rare. The only available texts from Lishu are the “local gazetteers” (*difangzhi* 地方志 or *xianzhi* 县志). These official records, written during the Republican period by local elites under the sponsorship of local officials, contain copious information on local administration, economies, and culture (Wilkinson 2000:154–156). The *Lishu xianzhi* (Lishu local gazetteer) was authored by Bai Yongzhen and dates from 1934, after the establishment of the Pianliancheng cemetery, though while it was still in active use. The work of Christian missionaries is mentioned in the chapter about religion and religious architecture (Bai 1934:316,463).

In addition to historical records, we consulted the modern “cultural gazetteers” (*wenwuzhi* 文物志). These were intended to be published by each district throughout the country, compiling the results of the National Cultural Survey of the 1980s, and are also very rich in information that has never been published elsewhere. The *Lishu xian wenwuzhi* (Lishu cultural gazetteer) contains a description of the mission’s church building complex, which was still partly standing in the 1980s (Jilin sheng wenwu zhi bianweihui [JSWZB] 1984:158).

European sources about the activities of the MEP missionaries in rural Manchuria are numerous and were mainly published by the Société des Missions-étrangères de Paris (SMEP) itself for almost a century (SMEP 1871–1941; Gibert 1934; Tiedemann 2010). The annual *compte rendu*, or annual reports, allow us to reconstruct the journey of the priests of Lishu, especially the first, Armand Joseph Déan (Fig. 4).

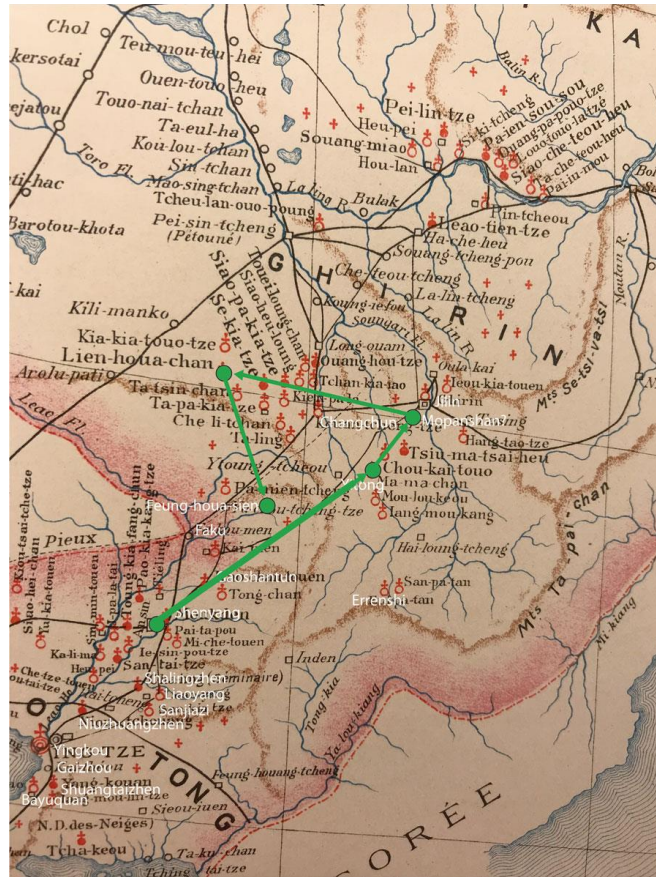


Fig. 4 Map of the MEP in Manchuria with A. J. Déan's travels.
(Map from Launay [1890:23], drawing by Pauline Sebillaud, 2018.)

2.2 Archaeological Materials and Methods

Pianliancheng is a city site from the Liao-Jin period (A.D. 916–1234) located in Lishu District, southwest Jilin Province, northeast China (Fig. 1). The 12 m high wall enclosure, with a perimeter of 4 km and surrounded by a 20 m moat, is one of the best-preserved medieval city sites in Manchuria. In summer 2017, outside the west gate, in a field running along the enclosure ditch, graves were exposed and threatened by heavy rain. The provincial archaeology institute interviewed local community members and determined that none identified as descendants of the people buried in this area. They therefore carried out a salvage excavation over 20 days on a 1000 m² portion (out of a total of about 10,000 m²) of this cemetery (Figs. 2, 5).

Archaeology on recent history is not often conducted in China. Recent historical archaeology anywhere in the world is a “collision” between different scholarly disciplines: between scholarship and community memory, and between the agendas of various power structures, both locally and globally (Shepherd 2013:425). Especially, given Pianliancheng's association with foreign influence at a recent, tumultuous time in Chinese history, it is unlikely such a project would have been prioritized if not for this serendipitous discovery.

In the field, each tomb was excavated and the soil sifted; each burial was drawn and photographed for a vertical view and photographed in detail to create a 3-D model by photogrammetry. Control points measured with a total station were used to complete 3-D models at a 1:1 scale. Each skeleton was recorded in situ by a bioarchaeologist and properly bagged. Field information was entered into a database. Coins unearthed from the burials were examined by a numismatist (Jankowski and Sebillaud 2018).

Extrapolation of the spatial distribution of the cemetery would indicate that the whole cemetery contained about 180 to 200 burials. A total of 39 burials were excavated in 2017.

They were numbered M1–M39 (Fig. 5) following Chinese archaeological convention, where “M” stands for *muzang* 墓葬 (burial).

The contents of five porcelain and glass containers found at the cemetery were sampled by the excavators. The five containers selected for this study include a small blue-and-white porcelain jar recovered in burial M33, a white glass square jar from burial M14, a small blue glass bottle found at the feet of the occupant of burial M6, a brown glass bottle with an inscription from burial M2, and a blue-and-white porcelain bowl from burial M2. Residues, when present, were scraped from the bottoms of the objects using a clean scalpel, and, when possible, adjacent sediment was also collected for comparative analysis. All residue and sediment samples were analyzed by gas chromatography/mass spectrometry (GC/MS) to identify traces of organic materials.

2.3 Bioarchaeological Materials and Methods

To better understand the health of this rural Manchurian community at the turn of the 20th century and the cultural identity (e.g., through foot binding) of the people buried in this cemetery, a macroscopic bioarchaeological analysis was also carried out. Most of the skeletal remains were moderately well preserved, with most elements present, but cortical surfaces and epiphyses damaged. Sex was estimated using nonmetric features of the cranium and pelvis (Buikstra and Ubelaker 1994; White and Folkens 2005; Klales et al. 2012). Age at death was estimated using the morphology of the pubic symphyseal face (Brooks and Suchey 1990), sternal rib ends (Iscan 1991), medial clavicle (Langley-Shirley and Jantz 2010), and auricular surface (Buckberry and Chamberlain 2002).

Pathological lesions and morphological changes were observed macroscopically. Recorded lesions included several nonspecific markers of illness and physiological stress. First, linear enamel hypoplasia (LEH) is a nonspecific stress marker caused by an interruption to growth in childhood, possibly related to malnutrition, parasitic infection, or infectious disease, and appears as a linear defect in the dental enamel, most often on the anterior dentition (Larsen 2015).

Cribriform orbitalia (CO) and porotic hyperostosis (PH) are porosity caused by expansion of the inner bone table of the eye orbits and skull vault. The conditions have traditionally been linked to dietary iron-deficiency anemia, though other causes have also been suggested, such as megaloblastic anemia from parasitic infection (Walker et al. 2009). As the distinct etiology of the two conditions is still being debated, for this study they have been combined into a category of “cranial porosity” and taken to indicate nonspecific metabolic disease in childhood.

Periosteal new bone formation is a nonspecific lesion that indicates the presence of systemic inflammation or infection. The condition creates a striated layer of new bone, most commonly in the legs, especially on the tibiae. An active lesion at death means the individual died while still experiencing an active infection or inflammation. If the condition had begun healing at the time of death, this indicates the infection or inflammation had ended and the patient survived the physiological insult, suggesting lower frailty or susceptibility to death (DeWitte 2014).

Other conditions recorded include degenerative joint disease and spinal degeneration, indicative of labor and mechanical stress, and oral health conditions, which correspond to diet and oral hygiene.

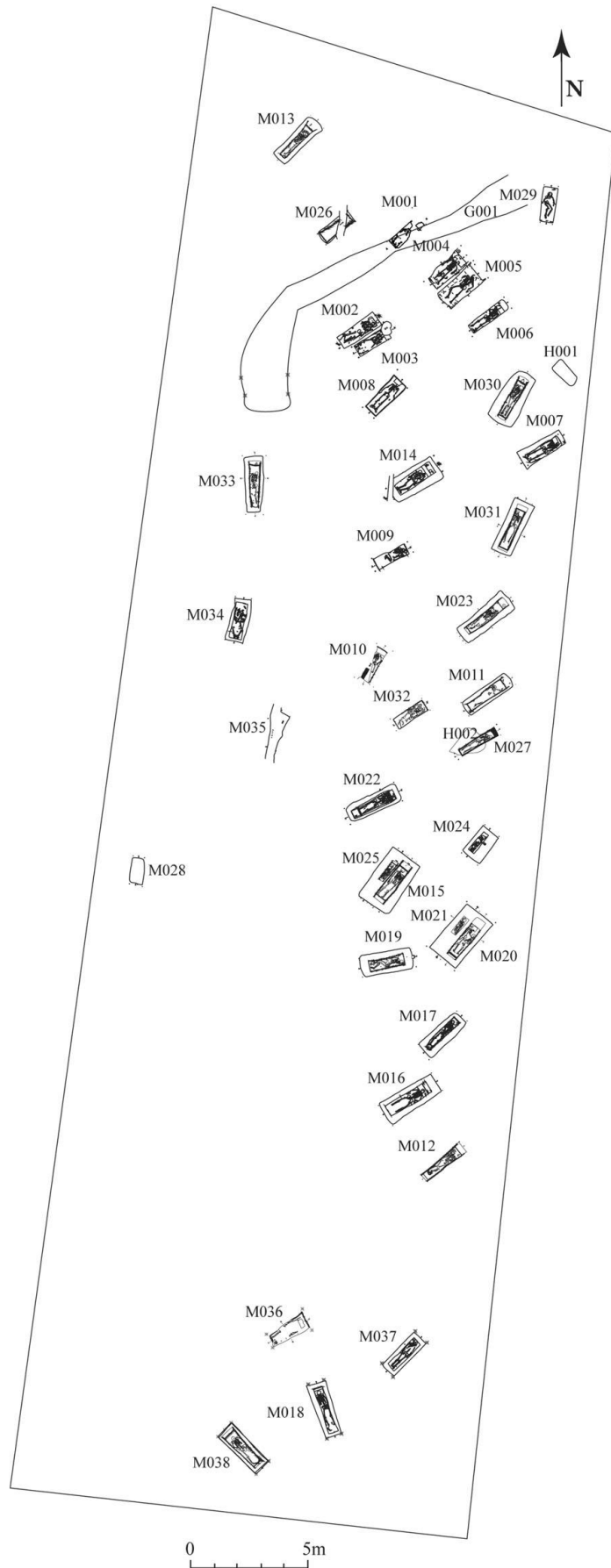


Fig. 5 Map of the Pianliancheng cemetery (M39 is in the southern excavation zone, not on this map).
 (Map by Pauline Sebillaud, 2017.)

3. Historical Findings

3.1 Chinese Texts

Local gazetteers allow us to reconstruct the history of the French priests in Lishu District. Mentions of Catholicism in Lishu begin in 1895, when a French priest with the Chinese name “De Yuese” came to Lishu and built a church, but died of disease not long after (Bai 1934:315,463; JSWZB 1984:518). This almost certainly refers to Armand Joseph Déan: “Yuese” is the traditional translation of Joseph. His curate, Li Xuelin, whose convert name was “Mao Lin” in Chinese and “Maurice Li” in French, was killed by bandits near Pianliancheng in the midst of the unrest of the early 1900s (Bai 1934:316,463). During the Boxer Rebellion, the missionaries were persecuted, and most of northeast China’s churches were burned down.

The subsequent priests in Lishu were three French men (whose Chinese names were “Gong,” “Ge,” and “Tan”). They were followed by Chinese priests (Wang Nuose, Xia Chengyi, Pang Feili, and Zhang Caibai) until 1928, when the mission was entrusted to priests of the Canadian Missions-étrangères du Québec (whose Chinese names were “Xia Jianxiu” and “Ming Ruose”) and their Chinese curates. The mission was definitively shut down in 1947 by the war and the rise of communism. The Lishu church was partly destroyed and became the dormitory of the district’s school; the last buildings were destroyed in the 1990s (JSWZB 1984:518).

Using money from the MEP, the missionaries were required to build two schools, one for boys and one for girls; a church; and their residence at each mission. These buildings, financed by a foreign organization on Chinese land, and thus different from the remittance economy (Byrne 2016a, 2016b; Voss, Kennedy, Tan et al. 2018), have often not been preserved. Chinese historical records do provide a description of the relatively small missionary church building at Lishu, which represented an incursion of Western culture through its architectural features. According to the *Lishu xian wenwuzhi* (cultural gazetteer of Lishu District) (JSWZB 1984), this church was “a long Western-style brick-and-stone building with a cement-and-steel structure, 30 m long by 9 m wide, with a front wall 8.5 m high and a back wall 6 m high, a simple slope roof and eight windows. The entrance had a porch with a 10 m high bell tower [translation by Pauline Sebillaud]” (JSWZB 1984:518).

3.2 French Texts

Armand Joseph Déan was born in Saint-Germain-en-Coglès, a village of rural northern Brittany, in 1866. After two years of study in the seminary of the MEP in Paris, near the Chapel of the Medal of the Immaculate Conception, he was ordained as a priest and sent to Manchuria. After arriving in the city of Shenyang, he studied Chinese in a place that the MEP documents refer to as “Chou-kai-touo” (located between Yitong and Shuangyang) in Jilin Province for a year. Then, he became the curate of the priest at Mouo-pan-chan (Mopanshan). In 1892, he was put in charge of Leenhua-cha (Lianhuashan) District, where a rebellion against the local administration’s raising of taxes left him alone to protect the village from looting by the army. After the Sino-Japanese War (1894–1895), Déan was sent to Lishu to establish a Catholic community. Assisted by his local curate, Li Xuelin, he baptized hundreds of converts at a rate of about a hundred each year. In 1899 he contracted smallpox, died on 11 January, and was buried among his neophytes on 13 January (SMEP 1900:327–329).

Li Xuelin remained in charge until he was killed in July 1900. A Father Conraux was then sent to Lishu during the difficult years of the 1900s, where he was helped by Carrère, his curate (SMEP 1903:80). Conraux became sick and died in Hong Kong in 1905 (SMEP

1906:47). The district was then taken over by Carrère, assisted by Darles (SMEP 1908:79–80), until 1909, when the French missionaries were recalled (SMEP 1909:58) (Table 1).

The letters of Father Déan, retained by his family, provide a more personal window into his life in Manchuria. The letters make it clear that he struggled with Chinese food, made French alcohol himself, showed workers how to build Western-style furniture, and would go to Changchun to buy coffee. He thus resisted hybridization with the local community, maintaining his “Frenchness” through the material goods he consumed.

Table 1 Names and dates of French priests who went to Lishu

Chinese name	French name	At Lishu	Dates
De Yuese 德约瑟	Armand Joseph Déan	1895-1899	1866-1899 (Lishu)
Li Xuelin 李学林	Maurice Li (Chinese curate)	1896-1900	? -1900 (Lishu)
Gong 龚	Louis Conraux	1900-1905	1852-1905 (Hong Kong)
Ge 葛	Jean-Baptiste Carrère	1902-1909	1876-1916 (Anglet)
Tan 谭	Henri François Darles	1906-1908	1881-1960 (Montbeton)

4. Archaeological Findings

The burials at Pianliancheng were all furnished with wooden coffins, which were in varying states of preservation (Fig. 6). Most of them were oriented with the head of the deceased to the northeast. All the burials contained a single individual, mostly in supine position, though eight individuals do appear to be in paired or joint burials: M2/M3 and M4/M5 were notably close together, and M25/M15 and M20/M21 were in separate coffins but in the same pit, with one buried first and later moved aside for the addition of the second coffin. Most had a pillow made of soil under the head (28 of 39, 71%), and many had a cavity at the head of the coffin containing a porcelain bowl (15 of 39, 38%), all of them blue and white, half with bamboo patterns, half with other traditional motifs (double lines, a fu character, or a landscape) (Fig. 7).

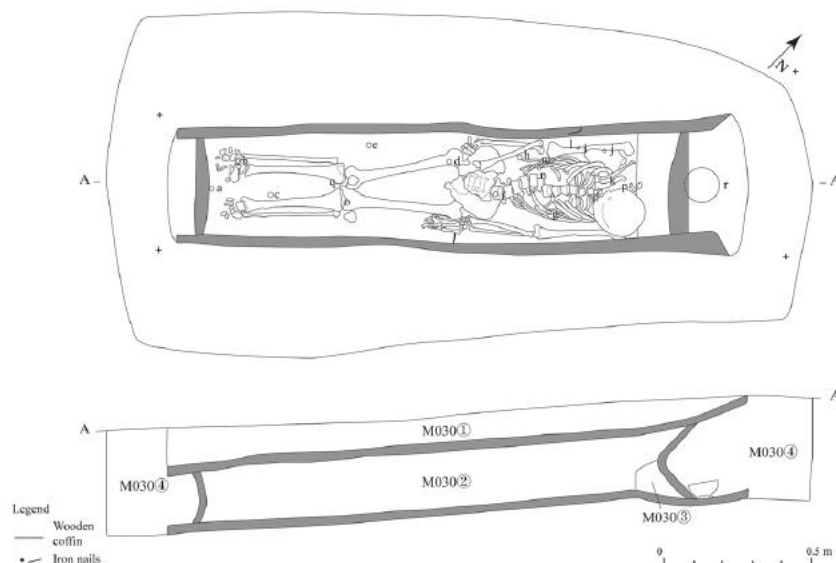


Fig. 6 Tomb M30: (a–h, l, m, p, r), bronze coins; (i, j), bronze spherical buttons; (k), porcelainware bowl; (n–o), bronze ornament (not pictured); (p), iron implement; and (q), string.

(Drawing by Pauline Sebillaud, 2017.)



Fig. 7 Bowls from the Pianliancheng cemetery. Tomb numbers: M30 (a), M38 (b), M039 (c), M14 (d), M23 (e), M22 (f), M19 (g), M2 (h), and M4 (i).
(Photos by Pauline Sebillaud, 2017.)

These burials yielded over 450 artifacts (bronze coins, porcelain items, buttons and ornaments, glass jars, etc.). In burial M14 was a glass bottle, the shape of which is usually identified as a pharmacy jar, and a glass bottle inscribed: 外科一品 (*waike yipin*, external medicine) was found in burial M22. In addition to a few coins, buttons, and sometimes a porcelain bowl, five of the 39 individuals in this sample were also found with simple metal hairpins. The occupant of burial M33 also had a gold earring, and the woman in burial M31, who had bound feet, also had shoe ornaments composed of a bronze spring and plastic beads.

Analysis of the coins and other objects indicates that these burials date from the 1890s to the 1930s. The burials can be divided into two types according to their depth, stratigraphy,

preservation, and artifacts, with the deeper burials belonging to an early phase (ca. 1890s–1910s) and the shallow ones to a later phase (ca. 1910s–1930s).

The residue analyses of five vessels revealed a very low preservation of organic material. Organic residues are usually better preserved in the matrix of porous ceramics, which the residues can penetrate (Evershed 2008; Roffet-Salque et al. 2017). Here, all the objects investigated are nonporous. Both residue and sediment samples mainly yielded mid- to long-chain free fatty acids, which are not indicative of any specific source. The residue from the small blue glass bottle (M6), however, also yielded short-chain free fatty acids, which are indicative of a degraded lipidic substance that was contained in the bottle. Based on the shape of the bottle, it was likely a perfume bottle. Interestingly, the molecule miliacin was identified in the residues of the brown glass bottle (M22) and in both the residue and the sediment from the small blue-and-white porcelain jar (M33). This compound is a pentacyclic triterpenoid that can be used as a biomarker for millet (Heron et al. 2016). Millet is known to have been used for pharmaceutical treatments (Q. Wu and Liang 2018). Millet wine was used internally and externally, often as a solvent to extract pharmacologically active drugs and as a preservation agent (Xia 2013).

5. Bioarchaeological Findings

Thirty-six of the thirty-nine burials excavated yielded skeletal remains. Bioarchaeological analysis of the skeletal remains from the cemetery can provide more insight into the life and health of the people who were buried here, especially when contextualized within the complete set of archaeological data derived from the site. Other than signs of spinal degeneration, none of the health measures or paleopathological lesions discussed below exhibit statistically significant differences between the sexes (Table 2), possibly due to the small sample size.

Two-thirds of the analyzed individuals are women, most of whom died before reaching the age of 30 (all but one of them before 50), and a third are men, most of whom were over 30, and most of these over 40 (Table 3) (Figs. 8, 9). The women, therefore, had a lower average age at death than the men. Although joint burials are traditionally thought to belong to a husband and wife, the rare joint burials from this sample (four in total) do not confirm this assumption. Of the joint burials at the cemetery, the paired graves M2/M3 contained only women, graves M25/M15 contained only men, and only graves M4/M5 and M20/M21 each contained one man and one woman.

Table 2 Nonspecific markers of health and activity

	Male	Female	Total (including individuals of unknown sex)
LEH1	1/7 (14.3%); 6 unobservable	10/15 (66.7%); 5 unobservable	11/24 (45.8%); 13 unobservable
Cranial porosity ²	6/10 (60.0%); 2 unobservable	7/15 (46.7%); 6 unobservable	13/26 (50.0%); 11 unobservable
Periostitis on leg bones ³	9/12 (75.0%); 0 unobservable	12/21 (57.1%); 0 unobservable	21/34 (61.8%); 3 unobservable
Spinal degeneration ^{4*}	10/12 (83.3%); none unobservable	3/10 (30.0%); 5 unobservable	13/23 (56.5%); 6 unobservable
Degenerative joint disease (extraspinal) ⁴	7/11 (63.6%); 1 unobservable	5/11 (45.5%); 4 unobservable	12/23 (52.2%); 6 unobservable

¹number with observable anterior dentition

²number with observable cranial bones

³number with observable cortical surfaces on leg bones

⁴number of adults with any DJD with observable joint surfaces; also excluding joint changes secondary to TB infection

*Significant a $p < 0.05$ level (The chi-square statistic 6.4182, p-value 0.011295; Fisher exact test statistic value 0.0274)

Table 3 Sex and age at death

	0-5 years	6-12 years	13-18 years	19-35 years	36-50 years	Over 50 years	Total
Male				1	4	5	10
Female			6	9	4	1	20
Indeterminate			3	3			6
Total			9	13	8	6	36

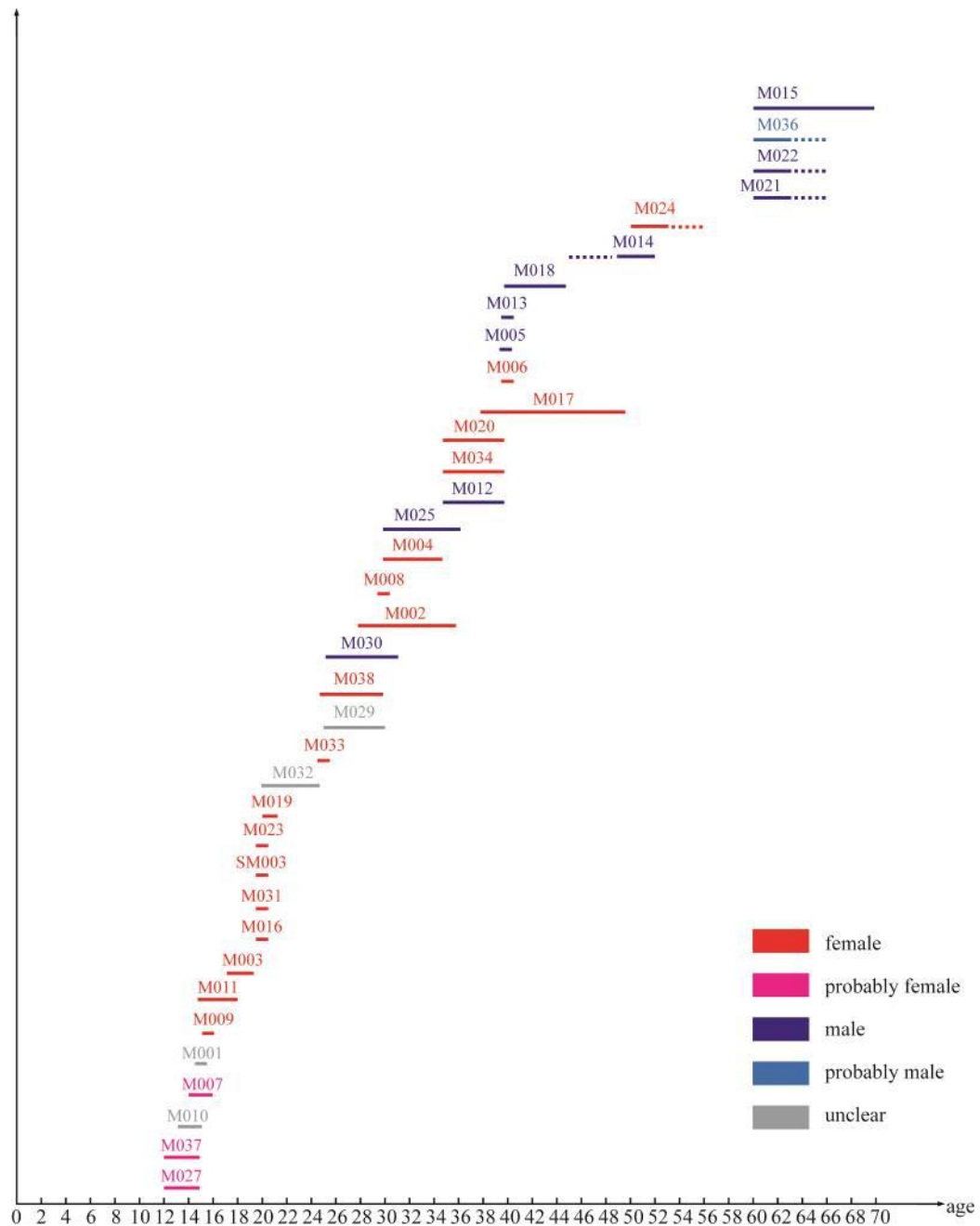


Fig. 8 Graph of age and sex distribution in the excavated sample.
(Graphic by Hou Kan and Pauline Sebillaud, 2018.)

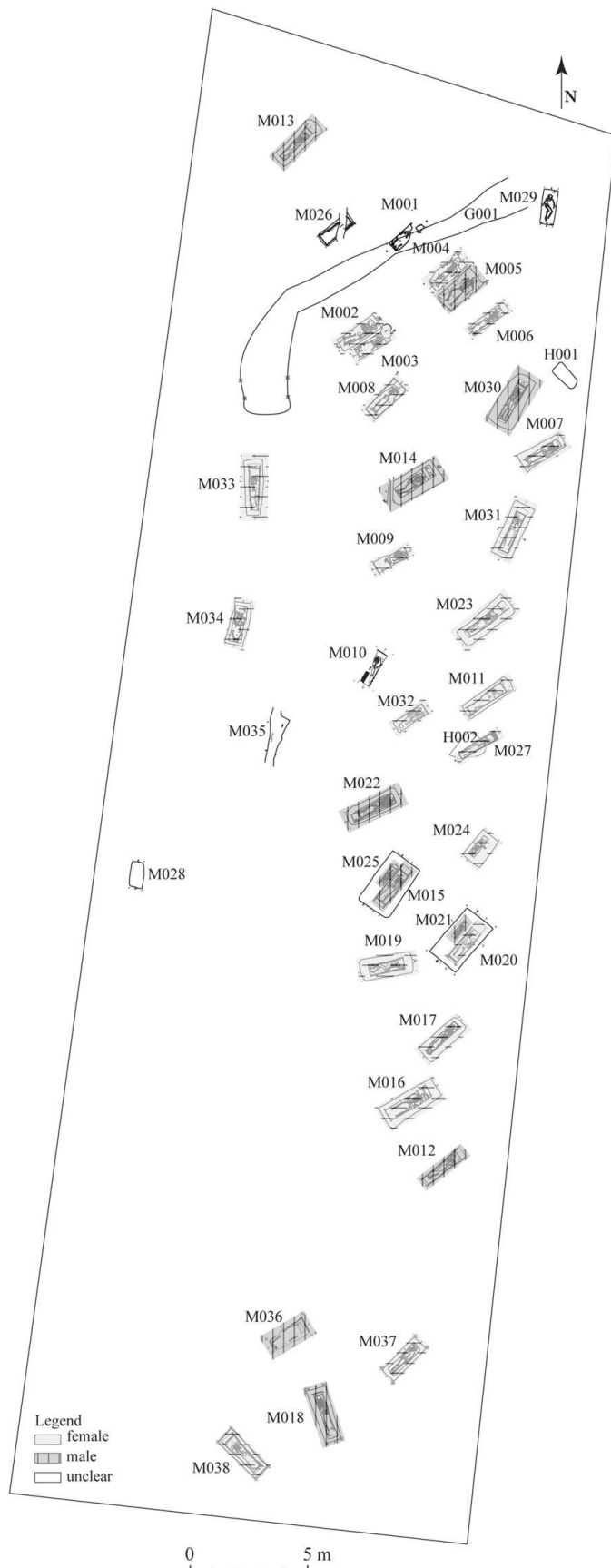


Fig. 9 Spatial distribution of male and female burials.
 (Drawing by Hou Kan and Pauline Sebillaud, 2018.)

5.1 Overall Health Status

The sample yielded a large number of nonspecific traits linked to physiological stress, which seem to indicate the presence of much infectious and metabolic disease (Table 2). LEH was present in 45.8% (11 of 24) of the individuals with observable anterior dentition. Most of the women (10 of 15 observable) showed signs of LEH, with only 1 male out of 7 observable exhibiting LEH (M30). There could be several reasons for this discrepancy. First of all, about half the male individuals (6 of 13) did not have observable anterior dentition, either because of postmortem damage or because of antemortem tooth loss correlated with advanced age. By contrast, only a quarter (5 of 20) of the female individuals had unobservable anterior dentition.

The sample also includes many individuals with cranial porosity (13 of 26, 50.0%), all well-healed, as this would have developed in childhood. Both males and females have high frequencies of the condition. The occurrence of new striated periosteal bone on the leg bones was high, observable in 61.8% of the sample. Twenty-one of thirty-four individuals with observable cortical surfaces on the leg bones, the most common site of periosteal new bone formation, had lesions that were in the process of healing at the time of death, though one appeared recently active. In terms of localized infections, the occupant of burial M2 exhibits a thickening of the right fibula at midshaft that may indicate an infection, and the occupant of M14 may have had maxillary sinusitis, or infection and inflammation of the bony sinus in the cavity of the maxilla bone of the face.

In terms of oral health, only 2 individuals (1 male and 1 female) out of 31 with observable teeth had dental caries, and 6 out of 30 had calculus (2 of 9 males and 4 of 18 females). A more systematic study of oral health would be needed to draw conclusions about diet and health from the teeth.

5.2 Infectious and Metabolic Diseases

Among the specific infectious diseases that are observable on dry bone, the most common in this sample is tuberculosis. One likely case of tuberculosis was found in burial M15, in a male individual. This individual displayed destructive lesions in the hips, spine, wrists, upper arms, tibiae, and feet. The occupant of M16, a female individual, had destructive and porous lesions in the spine and hip bones, as well as periosteal new bone on the pleural surfaces of the ribs. Tuberculosis was the likely cause of death for this individual. The female individual in grave M19 has the most lesions indicative of tuberculosis and has been sampled for future DNA analysis. The individual's spine, hand bones, rib pleural surfaces, and rib heads all show destructive lesions. Periosteal new bone was observed on the right hip bone and the right side of the sacrum, and there was a lacelike appearance on the posterior surface of the sternal body. The individuals from M16 and M19 were oriented in the same direction and buried close to each other and to M15. The occupants of these three burials all showed signs of tuberculosis, and the proximity of their burials may indicate a close social relationship that had afforded an opportunity for disease transmission.

There was ossification of ligaments on the anterior side of the lower thoracic spine of the male individual in M12, possibly diffuse idiopathic skeletal hyperostosis (DISH), a condition that causes ossification of soft tissue in the spine. DISH has no clear etiology, though it is thought to be metabolic in origin (Rogers and Waldron 2001). This individual also had a pathological lesion on the right leg, indicating inflammation or infection in the soft tissue. Individual M4 also showed possible signs of DISH.

Other individuals in the cemetery have lesions that were not specific enough for a differential diagnosis, but which might suggest infectious or metabolic disease. For example, the vertebral bodies of the occupant of burial M39, including the sacrum and sternal body, have a lace-like appearance on the posterior surface. The sacrum and tibia of the occupant of

burial M21 have extensive new bone and ligamentous ossification, and this individual's pelvis and vertebrae have proliferative and destructive lesions. The acetabular fossa of the individual from burial M31 has a large number of porous features as well.

5.3 Degeneration and Trauma

Most individuals had some degenerative joint disease, including mild lipping in one or more joints, and vertebral wedging, beginning in young adulthood. However, marked degeneration only occurred in individuals of more advanced age. Joint degeneration outside the spine, including ossification of ligaments and tendons, lipping, porosity, and eburnation, occurred in 12 of 23 individuals (52.2%). Spinal degeneration included compression fractures, wedged vertebrae, and osteophytes, and occurred in 13 of 23 individuals (56.5%). Severe joint degeneration was only observed in men who died after the age of 30, and, overall, male individuals tended to have more degenerative joint disease, especially in the spine (83.3% of males vs. 30.0% of females).

The older individuals, most of them male, show many degenerative joint changes, such as osteoarthritis, pronounced vertebral wedging, and soft-tissue ossification. Some individuals have lesions associated with carrying heavy objects, such as degenerative disc disease in the spine (e.g., M18, a male). The spine of M21 suffered from a combination of degenerative disc disease and vertebral osteophytes.

All the cases of trauma observed at Pianliancheng were likely related to activity or accident. A fifth metacarpal bone of M21 has a healed fracture that caused a slight palmar curve to the bone. All the other fractures at the site involve wedging or crushing of vertebral bodies, indicating mechanical strain or trauma to the spine. As with joint degeneration, older male individuals show the largest number of vertebral compression fractures, though some young women also had vertebral wedging (Table 4).

Table 4 Vertebral compression fractures and wedging by sex and age

	13-18	19-35	36-50	50+
Male		3	2	3
Female		3		

5.4 Congenital Abnormalities

Some phenomena associated with midline abnormalities have been found in this sample. For example, the individual in burial M15 has a metopic suture, and the first sacral vertebra is slightly lumbarized. Two other individuals (M23, M39) also had vertebral segment shifts, and one (M30) had a failure of fusion in the lamina of vertebrae T11 and T12. These are genetic traits, significant mainly for determining the degree of relatedness within a population, and, other than in the case of burial M38, they likely had no adverse effects.

The case of the individual in M38 is quite rare. This is a female individual, in her 20s at the time of death, with a clear cranial dysraphism, which is most likely a meningocele near bregma. The lesion appears as a wide depression, with a hole in the center, on the top of the head. This is clearly a developmental anomaly and not a case of trauma or surgery because of the smooth edges, location along the suture, and depressed shape (Stewart 1975; Verano 2016). Such an abnormality involves the failure of the cranial bones to form and fuse properly, leaving a bulge of meninges (and in the case of encephaloceles, actual brain tissue) protruding outside the skull. In life, it would appear as a bump on the head, covered in skin and hair along with the rest of the cranial vault. This case is the 9th or 10th case of cranial dysraphism reported in the published archaeological record from anywhere in the world (Halling and Seidemann 2018). Encephaloceles are typically fatal in infancy, and meningoceles, if uncorrected, can also be fatal; they can develop from maternal folic-acid deficiency, though

there is not a known cause in every case (Barnes 2008). Furthermore, this lesion's location on the frontal bone is rare. As this lesion could be deadly, the fact that this woman survived into her 20s is notable: since her birth, her skull would have always had a prominent spherical protuberance of soft tissue, and, in order to continue living for so many years, she must have been given protection and care as a child.

5.5 Body Modification

Six individuals showed signs of flattening of the posterior part of the skull, which is explained by the traditional custom of tightly swaddling newborns and putting them to sleep on a hard surface (Zhao, Zeng et al. 2017). This head shape is still found in many people in China today.

Pianliancheng also yielded some sets of female remains whose feet had the typical suite of characteristics found in bound feet. The skeletal remains excavated at Pianliancheng therefore reveal the impact on women's bodies of the final era of the foot-binding custom in rural Manchuria. Only 16 female individuals' foot bones were complete enough to observe, and 11 were well preserved enough to measure. Of these, five likely cases of foot binding were found, meaning that foot binding impacted 31.3% of the sample. Different degrees of foot binding were found: some female foot bones were unmodified; some foot bones were intermediate, possibly indicating that the foot had been bound for some time, but then "let out" after the practice was banned; and some foot bones were completely modified in the typical bound-foot pattern described above (e.g., M2, M23, and M31).

6. Discussion

6.1 Hybridization of Mortuary Practices

The presence of a "Miraculous Medal" at Pianliancheng, its location near the residence of the French priests (Bai 1934:518), and its proximity to the Catholic church in Lishu City indicate that the missionaries likely consecrated the cemetery as a sacred space, through land purchase and benediction, to make it suitable for their converts. Alongside the Catholic traits of the burials, however, there is also evidence of hybridization and the presence of traditional Confucian customs.

In terms of Catholic traits, the Pianliancheng burials are notably minimal or modest: the wooden coffins are composed of plain thin poplar boards, with indications of saddle-roof-shaped lids in the best-preserved cases. This is in contrast to the thick, high-quality wood (Korean pine, hongsong 红松), usually painted or lacquered, found in traditional family cemeteries in northeast China (JSWKY 2016). The funerary offerings (a single porcelain bowl in 11 out of 39 tombs, and a few coins in most of the burials), as with the elements of the clothing (e.g., buttons) (Fig. 10), are also quite simple compared to artifacts from documented average-status or lower-elite burials (HSWKY 2012; JSWKY 2016). The hairpins found at Pianliancheng (5 of 39 graves) were fewer in number and more modest than the hairpins usually found in late 19th-century traditional family cemeteries in Manchuria (JSWKY and YSB 2010; Huai'an shi bowuguan 2012; HSWKY 2012). Furthermore, Pianliancheng has a spatial organization of two long lines in a long rectangular field, whereas traditional contemporaneous cemeteries are organized as a triangle (de Groot 1894:375; Launay 1905:103; JSWKY and YSB 2010; JSWKY 2016). Finally, the burials are mostly single interments rather than joint burials.




Fig. 10 Types of buttons discovered in the Pianliancheng cemetery: (a) spherical bronze button, (b) cloth button, (c) round flat bronze button, (d) shell button, (e) Prosser button, and (f) rubber button. (Drawings by Li Penghui and Chen Xiaofei, photos by Pauline Sebillaud, 2017.)

Confucian traditions at the site include the pillow under the head of the deceased (Watson and Rawski 1988), detected in 26 out of 39 burials. Labeled bricks to mark primary burials are also widely found in culturally Chinese archaeological contexts (Schmidt et al. 2011), including at Pianliancheng (burial M24). At Pianliancheng, “good luck tokens,” or auspicious symbols to accompany the body, were found inside the burials, including nails, coins, eggs, and grain. They were likely meant to ward off spirits (Smits 2008:115), though this is emphatically non-Christian and would have run contrary to the prescriptions of the MEP.

Klaus (2013:228) writes of the Catholic missions in the Andes: “Andean concepts about sacred spaces and death, in particular, seem to have been resituated to the Catholic universe, but only after political and social changes that may have created a broad, more stable, and regional metaidentity that altered the structure of their gene pool.” By contrast, the rural Chinese Catholics of Manchuria adopted some elements of Catholic burial practices while also maintaining a number of their own, such as the abovementioned tokens, that indicate a different spiritual “universe.” It is unclear, therefore, whether their concepts of death and sacredness were entirely resituated to Catholicism. They began the process of hybridization of ritual practices, but the process was truncated by the end of the Catholic mission in Manchuria and the banning of religious practice after the rise of communism.

In many parts of the world, the fine-grained historical reconstructions provided by archaeology can reveal uncomfortable ambiguities about a colonial past (Moshenska 2013:360–361). In 2017, local Chinese community members said they had no previous knowledge of the Pianliancheng cemetery, which was in use until the 1930s, though they do admit flattening burial mounds in this same field in the 1970s during the Cultural Revolution. It seems evidence of the missionaries’ presence was being erased in the second half of the 20th century, which might explain this community memory lapse. Even if some local people remembered or were aware of the missionaries, they seem to prefer to forget, and this destruction and forgetting is one more clue that the cemetery was considered aberrant or nontraditional.

One prominent material symbol of the missionaries’ presence was their church and auxiliary buildings, built using a Western architectural idiom and serving as a potent and sacred symbol of their connection to France and the Catholic Church. Similar to burial practices, it is a highly visible, “mutually intelligible hybrid idiom” (Klaus 2013:227). Architecture, however, is subject to the construction of new uses and meanings (Klaus 2013):

as mentioned above, auxiliary buildings were later repurposed as a dormitory and ultimately destroyed.

We have so far mainly addressed the experiences and hybridizing practices of the Chinese converts buried at Pianliancheng. The experience of the French priests, meanwhile, is somewhat more obscured by time. None of the human remains in the Pianliancheng cemetery could be definitively identified as those of Father Déan or the other foreign missionaries, so their experience in Manchuria can only be gleaned from correspondence. Through his efforts to acquire Western furniture, alcohol, coffee, etc., as well as his ongoing correspondence with his family and the church in France, Déan maintained his position as part of a transnational community or corridor (Schmidt et al. 2011; Byrne 2016a, 2016b). It is likely that the missionaries' religious colonial purpose immigrating to Manchuria led them to resist hybridization. The *Règlement de la mission de Mandchourie* of the MEP advised missionaries to wear "the secular costume, conforming to the one worn by honest Chinese. ... The long black toga will advantageously replace the ecclesiastical habit which one would wear in France." However, traditional European long black cassocks, similar to that worn by Déan in his photographic portrait taken before he left Paris in 1890, were worn by the MEP priests in China in many group pictures from the end of the 19th century (SMEP 1882:21).

Further discouraging hybridization, missionaries in China faced a range of threats and dangers. Especially away from port cities, they "had little protection, and were often targets of antiforeign sentiment whipped up by local officials" (Lau 2008:207). This could explain the presence of the cemetery and rectory at Pianliancheng, an out of- the-way location 5 km outside Lishu City, at that time named Fenghua Xian or Maimaijie, on the site of a medieval city site that was not in use at the time except as a hiding place for criminals, according to local oral history gathered from modern-day residents during the excavation.

6.2 Embodied Experience of Hybridization: Bioarchaeological Findings

During this period, in rural northeast China, access to medical treatment was extremely rare. Only some missionaries and private doctors were able to provide medical services. The only hospitals were located in large cities and were managed by the railway companies. They were controlled by the Russians north of Changchun and by the Japanese south of Changchun. Even when medical care was available, the cost was particularly high (DuBois 2014), so civilians living near Pianliancheng generally could not afford it.

On the whole, the health status of the population recovered by the 2017 excavation of the Pianliancheng cemetery is consistent with records from this period, when infectious diseases and nutritional inadequacy were common, especially among rural communities in Manchuria. However, these phenomena do not account for the notable proportion of young female individuals in the mortuary sample.

6.2.1 Demographics

There were differences between the sexes at Pianliancheng in terms of mortality. Demographic statistical analysis of the population of 19th-century northeast China by J. Lee and Campbell (2007:60–61) shows that life expectancy at birth for women was in the upper 20s, and for men was in the lower 30s. At Pianliancheng, the men died somewhat later than this. In addition, it was typical to see higher mortality among females in both adolescence and young adulthood (up to 44 years of age) in historical populations (J. Lee and Campbell 2007:71). The younger average age at death among the women at Pianliancheng is consistent with this historical finding.

Apart from the juvenile individuals for whom sex could not be estimated, the male individuals in this sample were all over 30 years of age at death, and all the individuals over 40 were men except one (M24, the only woman who was over 50 years of age at death).

Three men were over 60 years old. This greater age at death among the men may indicate a longer lifespan, meaning greater resistance to disease, lower physical frailty, or better access to care and higher living standards (J. Lee and Campbell 2007). The lower age at death among women could reflect poorer health, poorer nutrition, or mortality from child bearing, though there is no direct skeletal or documentary evidence of this. In particular, if the women buried in their own graves at Pianliancheng were unmarried (discussed below), their lower average age at death could reflect general health disparities and not obstetric deaths.

Nine individuals buried in the cemetery were adolescents, with an estimated age at death between 12 and 18 years of age, including six females or probable females, and three whose sex could not be estimated. This represents nearly a quarter of the sample. They exhibit typical signs of physiological stress: one of the nine has periosteal new bone on the leg bones; one has periosteal new bone and LEH; one has LEH and cranial porosity; and one has periosteal new bone, LEH, and cranial porosity. The other five have no visible lesions, though four of these are poorly preserved and too damaged to assess. This sample size is too small for a statistical comparison, though the adolescents do not exhibit pathological lesions categorically different from the rest of the population.

No individuals under 12 years of age at death were found, which might correspond to the age before which they were considered to be adults or full Catholic converts. The *Règlement* states an age of 10 years for girls and 12 years for boys to be engaged to be married, which might indicate when they were considered adults by the church (SMEP 1882:31–32).

There were clear sex differences in morbidity as well. Overall, the men buried at Pianliancheng suffered more mechanical degenerative conditions, perhaps partly due to their greater average age at death. On the other hand, the women suffered from more infectious and inflammatory processes, growth disruptions in childhood, and early mortality.

Men had more extensive degenerative joint disease throughout the skeleton, though only spinal degeneration reached the level of statistical significance. This could indicate that they performed a greater number of heavy tasks involving weight bearing, though the greater severity could also be due to the greater average age at death among the male individuals. Two male individuals in the cemetery stand out for their lack of skeletal markers of heavy labor: the occupants of burials M22 and M30. Individual M22, who died at over 60 years of age, had severe degenerative lesions on the cervical vertebrae, but, on the whole, had no traces of hard physical labor on the rest of his skeleton. This burial contained the small cylindrical brown glass bottle with the inscription “external medicine,” placed next to a white-glazed stoneware bowl. The skeleton of individual M30 also did not have indicators of physical work on his bones, though he was quite young (25–31 years old), so they may simply not have formed yet. His burial goods were slightly richer than most of the other burials, including a larger number of coins (11) and higher quality bronze spherical buttons, possibly indicating a higher status.

6.2.2 Health Status

The population at Pianliancheng seems to have faced conditions that caused physiological stress, such as malnutrition or a high infectious-disease burden, particularly as children. The observation of LEH alone cannot accurately determine the cause of the growth disruption, but it can be inferred that the individual suffered from biological stress or poor health in childhood. In this sample, the proportion of LEH (45.8%) is high, though not unusually so: the elite, rural, late Ming Dynasty (late 16th to early 17th centuries) cemetery of Xuwucun near Xi’an in central China had an LEH frequency of 52.4% (Elizabeth Berger 2020, pers. comm.), and the mixedstatus urban 18th- to 19th-century English cemeteries described by Yaussy (2019) have a frequency of 64.2%.

A far higher percentage of female individuals suffered from LEH, though this did not reach the level of statistical significance. The males tended to be older at death, so were missing more of their anterior dentition. It must also be noted that LEH is only visible on those who survived childhood health insults and reached adulthood, and therefore could be interpreted as an indication of physiological robustness or lack of frailty (Wood et al. 1992). However, the high frequency of LEH does indicate the population faced frequent stressors, and the early life stress that caused the LEH may be related to increased frailty in adulthood and early mortality (Steckel 2005). Though the male sample is small, the female sample clearly shows a very high frequency of LEH, possibly related to the abovementioned younger average age at death (L. Zhou and Corruccini 1998).

Likewise, the high frequency of cranial porosity at the site (50%) is a sign of poor overall health and possibly of malnutrition. The finding of periosteal new bone formation also indicates that the population faced a high frequency of infectious and inflammatory conditions. The 61.8% of individuals observed at Pianliancheng with periosteal new bone is quite high; for instance, it is higher than that of any group from the urban Bronze Age site of Anyang other than those without lineage connections who were buried in refuse pits (Zhang et al. 2016).

6.2.3 Specific Infectious Diseases

Infectious disease was common in northeast China during the late Qing Dynasty and the Republican period. According to the literature, tuberculosis, cholera, typhoid fever, and smallpox were the most common afflictions. The pneumonic plague that began in northern Heilongjiang in 1910 spread, following the railway lines, to major cities in northeast and north China in 1911 (DuBois 2014). In most cases, however, these diseases run their course very quickly, so no traces can be observed on human bones (Dutour et al. 1998; Buikstra 2019).

Tuberculosis clearly was a common disease at the time, highly prevalent among males (J. Lee and Campbell 2007:63,76,147–148), and was sometimes chronic, allowing it to be observed on bones. The presence of likely tuberculosis cases at Pianliancheng is therefore not surprising. Moreover, the excess mortality of adolescent and young women is sometimes attributed to infectious diseases, especially tuberculosis, accentuated by the fact that the differential household resources allocated to women further reduced their resistance to infection (J. Lee and Campbell 2007:72–73).

These findings should be compared with the health status of other 19th-century cemeteries of civilian, lowstatus individuals in China. Unfortunately, no precisely comparable sample exists, as historical bioarchaeology in China is still a very small field. Some comparisons can be made with sites elsewhere in the world, however.

6.2.4 Comparative Samples

Bioarchaeologists have found that, in the industrial era, age, sex, and socioeconomic status were not directly correlated with health measures, but interacted in complex ways to expose individuals to some insults but not others. Some of this research has been done on cemeteries of converts in Catholic missions. In one case in the United States, Stojanowski and Larsen (2013) applied fine-grained spatial and biodistance analysis to reconstruct kinship relationships and burial practices in several 17th-century Spanish mission cemeteries in Florida. They found that particular markers of stress and disease clustered within native families, perhaps reflecting lifestyle and status. At first, after contact, measures of health did not show dramatic change, but later there was increasing morbidity, mortality, and demographic collapse. That example is from a mission context quite different from that of Pianliancheng, being earlier and also involving settler colonization and labor extraction rather

than only missionizing, but provides an interesting comparative example for the historical convert population at Pianliancheng, which also suffered from high rates of physiological stress and nutritional deficiencies.

Nineteenth- and early twentieth-century Chinese immigrants abroad provide another source of comparative bioarchaeological data. Studies of a sample of 13 male Chinese immigrants interred in Nevada between 1885 and 1923 (Harrod et al. 2012; Harrod and Crandall 2015) found every individual had some evidence of physiological stress or mechanical strain (enamel hypoplasias, cranial porosity, periosteal new bone, or enthesal changes associated with labor), and one likely had tuberculosis. These individuals would have been born and lived in southern China before immigrating and exhibit the same markers of low status and heavy workload as the individuals at Pianliancheng. One difference is the widespread evidence of trauma in the Nevada individuals, likely due to interpersonal violence: all had nonlethal injuries, and two had fatal trauma.

6.3 Gender in a Rural Manchurian Catholic Community

The women in convert communities were not full equals to male converts, as shown by details of the *Règlement*. For example, on consent in engagements, the *Règlement* states: “Girls’ silence, when they are questioned but ashamed to answer, must be interpreted as true consent” (SMEP 1882:32). Overall, though, the influence and policies of the MEP missionaries, as seen in their texts and as prescribed in their *Règlement*, shows a vision of gender relations very distinct from that of the local Chinese.

It is quite notable that the majority of the Pianliancheng burials are individual interments rather than the joint burials common in Chinese tradition. Only two burials are male-and-female joint burials, so the majority of the women were buried in single graves. This is notable because, through most of Chinese history, women were buried with their husbands, and, in late imperial northeast China, virtually all women married by age 30, and only 1 in 20 was unmarried at 25 (J. Lee and Campbell 2007:86–87). Therefore, the number of single female burials at Pianliancheng, females who mostly died before 30, is notable. It is possible that the Catholic practice of individual interment overrode the traditional practice of joint burial for women. Other possible explanations are that these women were not married or were married to men who were not buried with them, perhaps because the men were buried elsewhere or because they died without access to burial, for instance, in war.

Historical records on Chinese Catholic communities and the preponderance of female burials at Pianliancheng (two-thirds of the total) suggest it is most likely these women were unmarried. Women converts were important in rural Catholic communities and often made up a majority of the communities. J. Li (2015) explains the importance of local women and their work in rural Catholic communities founded by the French priests of the MEP. The general level of literacy was very low in the rural population and almost nil for women (Morgan 2004): it was widely felt that women did not need to learn to read (Voss 2018a:118). However, in Catholic communities, women learned to read and write through catechism study, and, if they became “Virgins of the MEP,” they could help by teaching the girls’ school classes (J. Li 2015). In order to become a “Virgin,” a woman’s family had to prove that she had a certain amount of money allocated to her personally so she could support herself without being married, she had to have her own room in the family house, and she had to make a vow of celibacy (SMEP 1882). These women could have chosen to become nuns, but becoming Virgins of the MEP instead allowed them to stay with their families, a clever arrangement that accorded with the values of traditional Confucian society. As in monastic vows, the virgins renounced their sexuality, but, contrary to monastic vows, they reaffirmed their personality, acquired private property, maintained family relationships, and obtained a new social status (Gilchrist 1994:18–19).

The fact that they did not marry, however, was still at odds with the deeply patriarchal society. The fact that their families had to allocate a room and money to them personally, and not use this money for their marriage, ran contrary to the denial of women's property rights in late imperial China (S. Chen et al. 2012). The labeled brick of burial M24 (*Cui Xi zhi wei* 崔喜之位 “Here rests Cui Xi”) does not mention the woman by the traditional combination of her family name with the suffix *shi* 氏 (“spouse”), but her actual full name (Cui Xi), which is exceptional and suggests she was not married. The fact that most of the burials are individual also suggests most of these women were not married.

If the women buried at Pianliancheng were unmarried, they may have employed a strategy of hybridization to increase their status, combining elements of their traditional patrilocal family structure with their newly independent role in the Catholic community. In addition to the single burials of women being notable, the overall sex and age distribution is also surprising. Based on morphological assessment of the skeletons, of the 39 burials excavated at Pianliancheng, two-thirds are women. By contrast, in traditional lineage cemeteries, women were generally not a majority, as their funerary treatment was not emphasized by the needs of the patrilocal lineage system to accrue good luck through burial placement (Kraus-Friedberg 2008:129).

The presence of foot binding further indicates the hybridization of women's status in the convert community. It is a thoroughly Chinese traditional practice, but is not inconsistent with the presence of the Catholic missionaries, who were not permitted to interfere in the private lives and bodily practices of the locals. The Catholic Church opposed foot binding in principle, seeing it as one of the symbols of the backwardness of Chinese society (and referred to it as “disabled women's feet” [SMEP 1882:14]). However, they knew that the tradition of gender inequality was deeply rooted in China's traditional Confucian society (J. Li 2015) and made the pragmatic choice to allow it to continue. The attitude of British missionaries, by contrast, was staunchly against foot binding, and they fought actively in the cities against this practice, deeply influencing Chinese reformers on this question (Lau 2008).

Archaeological evidence attests that, despite the official ban of this practice in 1902, its abolishment remained theoretical for most women. Most still practiced binding, other than women at the two ends of the social hierarchy, i.e., daughters of poor farmers or of an “enlightened reformer's family” (Elisseeff 2006:16). There were many reasons for the persistence of foot binding in rural areas, such as the maintenance of Han cultural identity and aesthetic standards as a form of resistance to Manchu political domination. However, recent research suggests that this custom also had certain economic reasons: to encourage girls to be productive in their spinning and sewing (Brown and Satterthwaite-Phillips 2018). Bossen and Gates (2017) present interviews with 1,700 women collected over 20 years of ethnographic fieldwork that show a link between the decline of foot binding and the progress of industrialization in different regions of China from the late Qing Dynasty to the Republican period. The development of industrial fiber, silk, and cloth production, and transportation is directly correlated with the gradual disappearance of foot binding, as it reduced the need for home piecework production.

Though Pianliancheng is a small attritional sample spanning several decades, its 31.3% foot-binding frequency is consistent with the downward trend in foot binding during this period. The frequency is low compared to other published Qing Dynasty skeletal samples, most of which found foot binding in all female skeletons of the Qing period (Zhu et al. 2017; C. Lee and Sun 2019; Zhao, Guo, Xiao et al. 2020). The phasing out of the practice here could be due to the influence of the European missionaries or possibly to the rise of industrial clothing production, as in other rural communities, since machine-made clothing was found at Pianliancheng (see below).

6.4 Materiality of Migrant Communities

The material objects in the graves at Pianliancheng connect the Chinese people buried there to migrant communities around the world. While a few recent Chinese projects have focused on late 19th- and early 20th-century remains (C. Zhou and Feng 2016; HSWKY et al. 2018), more research has been done on Chinese migrants' lives (Voss 2005; Ross 2015) and funerary customs in the U.S., Canada, Australia, and New Zealand (Abraham and Wegars 2003; Chung and Wegars 2005; Kraus-Friedberg 2008; Smits 2008). These occasionally focus on skeletal remains (Schmidt 2009; Schmidt et al. 2011; Harrod et al. 2012; Harrod and Crandall 2015). Many of the projects find links between the migrants and the regions they come from in China, exploring how they formed transnational communities (Byrne 2016a, 2016b; Voss 2016; Voss, Kennedy, Tan et al. 2018; Voss, Kennedy, and Tan 2019).

Research on Chinese American cemeteries also sheds light on the long-distance exchanges of manufactured goods, such as those found at Pianliancheng. For instance, buttons were discovered in more than half the burials at Pianliancheng (23 of 39, 59%) (Fig. 10), which reveals a changing mix of Chinese- and Western-style clothing. In the earliest graves, the individuals were buried dressed in the traditional Chinese long dress, which was usually made of a dark-colored cloth closed in an L or straight shape on the chest with spherical metallic or cloth buttons (though cloth is rarely preserved). In the later tombs, individuals were buried in more Westernstyle clothes, closed in straight lines and, at least partially, industrially made, with round buttons (of mother-of pearl, clay, or black rubber) with two or four holes in the center. Among the round buttons, white Prosser buttons were discovered in two burials. These pressed clay and feldspar buttons were industrially produced in England after 1840 and produced on a massive scale in France by the Briare manufactory from 1872 until the 1940s (Marcel 1994). This is the most common type of button found in European burials at the turn of the 20th century (Sprague 2002), and some have also been found in Chinese-migrant railroad work camps in California (Voss 2018b:291). They show how some products of the Industrial Revolution spread rapidly around the world through a process of globalization, reaching as far as rural Manchuria, with the adoption of Western-style garments.

Bowls similar to those found at Pianliancheng are commonly found at Qing-period sites in northeast China (Shenyang shi wenwu kaogu yanjiusuo 2007, 2011; HSWKY 2015; JSWKY 2016), but also at Chinese diaspora sites in North America (Choy 2014:3, fig. 1; Ross 2015:177, fig. 5; Voss 2018b:292, fig. 2b) as well as in late 19th-century villages in Guangdong in southern China. Most were produced in Gaopizhen in eastern Guangdong (Voss, Kennedy, Tan et al. 2018:416, figs. 5b, 5e, 6a). The bamboo-pattern bowls from Pianliancheng are huikeqi (coarse, yellow-gray porcelain with bamboo patterns) (Z. Li 1990), probably produced in the minyao (private kilns) of Gaopizhen or of the Jingdezhen region, although further research into northeast China's minyao would be needed to distinguish between locally produced tableware and that imported from southern China. The bamboo-pattern bowls also seem to have been commonly used by Chinese laborers throughout the American West between about 1850 and 1910 (Smits 2008:116). The other complete bowls found at Pianliancheng seem to be more recent and could have come from various industrial kilns in China. One is decorated with a "Double Happiness" motif, one with a landscape design, one is plain with two lines, and one is plain white. In the Chinese section of Lone Fir Cemetery in Oregon, excavators found vessels, including cups, jars, bottles, and bowls, that would likely have been used as graveside offerings to the dead or possibly for feasting by the living (Smits 2008:117). These vessels are similar to the simpler bowls found at Pianliancheng. In addition, placing coins in burials was a traditional custom in this period, seen in Pianliancheng and other Qing Dynasty burials in northeast China (Jankowski and Sebillaud 2018), as well as in the diasporic Chinese burials from Carlin, Nevada (Schmidt et al. 2011).

The plastic beads found in burial M31 could not have been produced earlier than the early 1920s and were widely commercialized only during the 1940s (Dikötter 2007:227,263), which is notable because the woman in this grave also had bound feet, a relatively late example. In burial M22, the small, cylindrical, brown glass bottle with the “external medicine” inscription is similar to glass medicine vials recovered at an historical Chinese American cemetery in Portland (Smits 2008:118), and identical specimens have been found at the prison and laboratory for bacteriological experiments led by the Japanese army in the 1930s in Harbin (HSWKY et al. 2018).

The aforementioned “Miraculous Medal” (Fig. 3) was found in burial M14 and was certainly the most unusual object found in the grave. The other artifacts from the burial were typical for the cemetery: seven bronze spherical buttons, four bronze coins, one porcelain bowl, and a square-shaped, opaque white *pâte de verre* glass bottle with a screw lid. Millions of copies of this medal, most of which were, in fact, oval-shaped, had been produced since 1832 to commemorate the apparition of the Virgin Mary to Catherine Labouré at the Couvent des Soeurs de la Charité de Saint Vincent de Paul in Paris (on the rue du Bac, a few steps from the MEP seminary). This discovery led us to the historical sources that identified the creator of the cemetery as the French missionary Armand Joseph Déan. The spherical buttons indicate that the individual in burial M14 was wearing a traditional Chinese long robe. This does not rule out the individual being Father Déan, as the MEP regulations, mentioned above, did exhort missionaries to adopt local dress. However, the occupant of this burial was almost certainly over 40 at the time of his death, and Déan died at 33. Therefore, the burial occupant’s identity could not be definitively determined, whether Armand Joseph Déan, one of the other French priests, one of their Chinese vicars, or simply someone to whom the medal was offered.

7. Conclusion

The detailed archaeological analysis presented here is important because the MEP’s project in Manchuria was, for the most part, ephemeral. Catholic communities persist today in a few places in what used to be the Manchuria Mission, like Bajiazi, and there are large cathedrals in the main cities, such as Shenyang, Jilin, and Changchun, but their history is rarely studied and is often forgotten by locals. The Pianliancheng cemetery attests to the existence of a forgotten community and international exchange of objects and ideas that created new social structures that were mostly disrupted by political events of the mid-20th century.

This first archaeological glance at a Catholic community in rural Manchuria reveals a process of hybridization by the local Chinese converts, evident in their mortuary practices and in the social place occupied by women. The MEP opened a transnational corridor (Byrne 2016a, 2016b) between France and rural Manchuria, and the Pianliancheng cemetery became a spiritual “in-between” space (Byrne 2016b) encompassing local funerary practices and imported beliefs. The discovery of industrial products also shows that this rural hinterland, far away from the large coastal cities, was, in fact, integrated into global commercial webs.

The Pianliancheng project represents the first archaeological analysis of remains from this particular type of Sino-French context. It also provides data on a little-studied type of migration during the late 19th and early 20th centuries: Europeans into China. The Pianliancheng project is unique in Chinese archaeology as well, because it involved systematic excavation of recent historical remains, provides data related to relations with foreigners and foreign ideology, and incorporates analysis of recent human skeletal remains. The late Qing Dynasty and the Republican period (late 19th–early 20th centuries) are traditionally not considered part of the field of archaeological research in China, so remains

from this period are considered minor finds and are rarely excavated and even more rarely published. If they are excavated, it is often through rushed salvage excavations.

Chinese archaeological reports (short preliminary reports called “jianbao,” as well as book-length reports) have so far approached burials as containers for objects that are the focus of numerous studies. Trying to place an analysis of the deceased and the practices of the living at the center of Chinese mortuary archaeology will be a slow process. As a step in this direction, the Chinese monograph report on the Pianliancheng cemetery presents all the bioarchaeological data, including both paleopathology and taphonomy for each burial, “out of the appendix” (Buikstra 1991) and in the body of the text (Sebillaud and Jing 2021).

This research constitutes a multidisciplinary history of a community. The always-wished-for alliance between archaeology and historical documents in China has been rather successful and essential in this case, and may also be critical for future instances of excavations yielding remains from the late 19th to the beginning of the 20th centuries.

Acknowledgments: We would like to thank the Jilin Province Archaeological Institute for allowing us to participate in the analysis of the Pianliancheng cemetery, and the anonymous reviewers for their comments and suggestions. We also would like to thank Brigitte Appavou for giving us access to the MEP Archives in Paris, François-Xavier Lemerrier for opening the Archives de la Maison diocésaine de Rennes, and the Déan family for giving us access to his correspondence.

References

Abraham, Terry, and Priscilla Wegars.

2003 Urns, bones and burners: overseas Chinese cemeteries. *Australasian Historical Archaeology* 21: 58–69.

Bai, Yongzhen 白永贞.

1934 *Lishu xianzhi* 梨树县志 (Local Gazetteer on Lishu District). Jilin sheng renmin chubanshe, Lishu, PRC.

Banister, Judith.

1992 A Brief History of China’s Population. In *The Population of Modern China*, David Yaukey and Dudley L. Poston, editors, pp. 51–57. Springer, Boston, MA.

Barnes, Ethne.

2008 Congenital Anomalies. In *Advances in Human Palaeopathology*, Ron Pinhasi and Simon Mays, editors, pp. 329–362. John Wiley and Sons, Hoboken, NJ.

Bhabha, Homi K.

2004 *The Location of Culture*. Routledge, London.

Berger, Elizabeth, Liping Yang, and Wa Ye.

2019 Foot Binding in a Ming Dynasty Cemetery near Xi’an, China. *International Journal of Paleopathology* 24: 79–88.

Bergère, Marie-Claire.

1992 *L’âge d’or de la bourgeoisie chinoise 1911-1937*. Flammarion, Paris, France.

Blake, C. Fred.

1994 Foot-Binding in Neo-Confucian China and the Appropriation of Female Labor. *Signs* 19: 676–712.

Bossen, Laurel, and Hill Gates.

2017 *Bound Feet, Young Hands: Tracking the Demise of Footbinding in Village China*. Stanford University Press, California.

Brooks, Sheilagh, and Judy M. Suchey.

1990 Skeletal age determination based on the os pubis: A comparison of the Acsádi-Nemeskéri and Suchey-Brooks methods. *Human Evolution* 5, 3:227–238.

Brown, Melissa J., and Damian Satterthwaite-Phillips.

2018 Economic Correlates of Footbinding: Implications for the Importance of Chinese Daughters' Labor. *PLOS ONE* 13, 9.

Buckberry, Jo L., and Andrew T. Chamberlain.

2002 Age estimation from the auricular surface of the ilium: a revised method. *American Journal of Physical Anthropology* 119: 231–239.

Buikstra, Jane E.

1991 Out of the Appendix and into the Dirt: Comments on Thirteen Years of Bioarchaeological Research. In *What Mean these Bones? Studies in Southeastern Bioarchaeology*, Mary L. Powell, Patricia S. Bridges, and Ann M. Wagner, editors, pp. 172–188, University of Alabama Press, Tuscaloosa.

2019 *Ortner's Identification of Pathological Conditions in Human Skeletal Remains*. 3rd edition, Academic Press Inc, San Diego, CA.

Buikstra, Jane E., and Douglas H. Ubelaker.

1994 *Standards for Data Collection from Human Skeletal Remains*. Arkansas Archaeological Survey, Fayetteville, AK.

Byrne, Denis.

2013 Difference. In *The Oxford Handbook of the Archaeology of the Contemporary World*. Paul Graves-Brown, Rodney Harrison, and Angela Piccini, editors, pp. 289–305. Oxford University Press, Oxford, UK.

2016a Heritage corridors: transnational flows and the built environment of migration. *Journal of Ethnic and Migration Studies* 42, 14: 2360–2378.

2016b The need for a transnational approach to the material heritage of migration: The China–Australia corridor. *Journal of Social Archaeology* 16, 3: 261–285.

Campbell, Cameron, and James Lee.

2003 Social Mobility from a Kinship Perspective: Rural Liaoning, 1789–1909. *International Review of Social History* 48, 1: 1–26.

Charbonnier, Jean.

2002 *Histoire des Chrétiens de Chine*. Les Indes Savantes, Paris, France.

Chen, Bijia, Cameron Campbell, and Hao Dong.

2018 Interethnic Marriage in Northeast China, 1866–1913. *Demographic Research* 38: 929–966.

- Chen, Shuang.
2017 *State-Sponsored Inequality: The Banner System and Social Stratification in Northeast China*. Stanford University Press, Palo Alto, California.
- Chen, Shuang, James Lee, and Cameron Campbell.
2012 Socio-economic Status and Marriage in Northeast China, 1749-1912. In *Franz van Poppel: A Sort of Farewell*, Beekink Erik and Evelien Walhout, editors, pp. 54–57. Nederlands Interdisciplinair Demografisch Instituut, Amsterdam, Netherlands.
- Choy, Philip P.
2014 Interpreting “Overseas Chinese” Ceramics Found on Historical Archaeology Sites: Manufacture, Marks, Classification, and Social Use. *Society for Historical Archaeology Research Resources*. Electronic document, <https://sha.org/assets/documents/Choy%20-%20pottery%20research%20-%20final%20version.pdf>. Accessed July 10, 2020.
- Chung, Sue Fawn, and Priscilla Wegars.
2005 *Chinese American Death Rituals: Respecting the Ancestors*. Altamira Press, Lanham, MD.
- de Groot, Johann Jacob Maria.
1894 *The Religious System of China*. Vol. 2. Brill, Leiden, Netherlands.
- Deagan, Kathleen.
2003 Colonial origins and colonial transformations in Spanish America. *Historical Archaeology* 37, 4: 3–13.
- DeWitte, Sharon N.
2014 Differential survival among individuals with active and healed periosteal new bone formation. *International Journal of Paleopathology* 7: 38–44.
- Dikötter, Frank.
2007 *Things Modern: Material Culture and Everyday Life in China*. C. Hurst & Company Limited, USA.
- DuBois, Thomas David.
2014 Public Health and Private Charity in Northeast China, 1905–1945. *Frontiers of History in China* 9, 4: 506–533.
- Dutour, Olivier, Michel Signoli, Silvi Bello, and György Palfy.
1998 Paleoepidemiology of Infectious Diseases: New Challenges. *Homo* 12: 21.
- Elliott, Mark Christopher, Cameron Campbel, and James Lee.
2016 A Demographic Estimate of the Population of the Qing Eight Banners. *Études Chinoises: Bulletin de l'Association Française d'Études Chinoises* 35, 1: 9–39.
- Elisseeff, Danielle.
2006 *XXe siècle, La grande mutation des femmes chinoises*. Bleu de Chine, Paris, France.
- Evershed, Richard P.

2008 Organic Residue Analysis in Archaeology: the Archaeological Biomarker Revolution. *Archaeometry*, 50, 6: 895–924.

Fairbank, John K.

1978 *The Cambridge History of China Volume 10 Late Ch'ing, 1800-1911, Part I*. Cambridge University Press, Cambridge, UK.

1983 *The Cambridge History of China Volume 12 Republican China 1912-1949, Part I*. Cambridge University Press, Cambridge, UK.

Fairbank, John K., and Kwang-Ching Liu.

1980 *The Cambridge History of China Volume 11 Late Ch'ing, 1800-1911, Part II*. Cambridge University Press, Cambridge, UK.

Gao, Hongxing 高洪兴.

1995 *Chanzu Shi* 缠足史 (History of Footbinding). Shanghai Wenyi Chubanshe, Shanghai, PRC.

Gibert, Lucien.

1934 *Dictionnaire historique et géographique de la Mandchourie*. Imprimerie de la Société des Missions-Etrangères, Hong Kong.

Gilchrist, Roberta.

1994 *Gender and Material Culture: The Archaeology of Religious Women*, Routledge, Londong, UK.

Gu, Yaodong, Qichang Mei, Justin Fernandez, Jianshe Li, Xuejun Ren, and Neng Feng.

2015 Foot Loading Characteristics of Chinese Bound Feet Women: A Comparative Analysis. *PLoS ONE* 10, 4.

Halling, Christine L., and Ryan M. Seidemann.

2018 A Probable Example of Cranial Dysraphism from New Orleans, Louisiana. *International Journal of Osteoarchaeology* 28, 4: 470–474.

Harrod, Ryan P., Jennifer L. Thompson, and Debra L. Martin.

2012 Hard Labor and Hostile Encounters: What Human Remains Reveal about Institutional Violence and Chinese Immigrants Living in Carlin, Nevada (1885–1923). *Historical Archaeology* 46, 4: 85–111.

Harrod, Ryan P., and John J. Crandall.

2015 Rails Built of the Ancestors' Bones: The Bioarchaeology of the Overseas Chinese Experience. *Historical Archaeology* 49, 1: 148–161.

Heilongjiang sheng wenwu kaogu yanjiusuo 黑龙江省文物考古研究所 (HSWKY).

2010 Heilongjiang sheng Nehe shi Dulabenqian Qing dai muzang 黑龙江省讷河市都拉本浅清代墓葬 (The Qing Dynasty Burial Dulabenqian, in Nehe City, Heilongjiang Province). *Beifang wenwu* 2: 23–24.

2012 Heilongjiang sheng Qiqihaer shi Naimenqin yizhi fajue jianbao 黑龙江省齐齐哈尔市奈门沁遗址发掘简报 (Preliminary Excavation Report on the Naimenqin Site, in Qiqiha'er City, Heilongjiang Province). *Beifang wenwu* 3: 50–54.

2015 Heilongjiang sheng Wuchang shi Lalin jichang Qing dai yizhi fajue jianbao 黑龙江省五常市拉林机场清代遗址发掘简报 (Preliminary Excavation Report on the Qing Period Site of Lalin Airport in Wuchang City, Heilongjiang Province). *Beifang wenwu* 4: 49–52.

Heilongjiang sheng wenwu kaogu yanjiusuo 黑龙江省文物考古研究所 (HSWKY), Qin Hua Rijun di qisanyi budui zuizheng chenlieguan 侵华日军第七三一部队罪证陈列馆, Ha'erbin gongye daxue tumu jianzhu gongcheng xueyuan 哈尔滨工业大学土木建筑工程学院, and Dongbei shifan daxue lishi wenhua xueyuan 东北师范大学历史文化学院.

2018 *Qin Hua Rijun di qisanyi budui jiu zhi xijun shiyanshi ji teshe jianyu* 侵华日军第七三一部队旧址细菌实验室及特设监狱 (The Bacteriological Laboratory and Special Prison of the 731 Regiment of the Japanese Occupation Army in China). Kexue chubanshe, Beijing, PRC.

Heron, Carl, Shinya Shoda, Adrià Breu Barcons, Janusz Czebreszuk, Yvette Eley, Marise Gorton, Wiebke Kirleis, Jutta Kneisel, Alexandre Lucquin, Johannes Müller, Yastami Nishida, Joon-ho Son, and Oliver E. Craig.

2016 First molecular and isotopic evidence of millet processing in prehistoric pottery vessels. *Scientific reports* 6: 1–9.

Hodos, Tamar.

2009 Colonial Engagements in the Global Mediterranean Iron Age. *Cambridge Archaeological Journal* 19, 2: 221–241.

2016 Globalization: Some basics. An introduction to The Routledge Handbook of Archaeology and Globalization. In *The Routledge Handbook of Archaeology and Globalization*, Tamar Hodos, editor, pp. 3–11. Taylor and Francis, London, UK.

Hu, Anning.

2016 Ancestor Worship in Contemporary China: An Empirical Investigation. *China Review* 16, 1: 169–186.

Huai'an shi bowuguan 淮安市博物馆 (HSB).

2012 Huai'an Chuzhou Xiangyu huanyuan Ming Qing muzang qun fajue jianbao 淮安楚州翔宇花园明清墓葬群发掘简报 (Preliminary Excavation Report of the Ming and Qing Burial Group at Xiangyu huayuan, Chuzhou, Huaian). *Dongnan wenhua* 1: 60–67.

Hulunbei'er meng wenwu guanli zhan 呼伦贝尔盟文物管理站 (HMWGZ).

2000 Neimenggu Moli Dawo'erzu zizhiqi Tengke xiang Qing dai muzang qingli jianbao 内蒙古莫力达瓦达斡尔族自治旗腾克乡清代墓葬清理简报 (Preliminary Excavation Report on the Qing Dynasty Tombs of Tengke, in the Autonomous Daur Banner of Moli, Inner Mongolia). *Beifang wenwu* 2: 50–53.

Huo, Xiaodong 霍晓东, and Weiguang Fu 傅惟光.

2014 Qiqiha'er Fulaerji Laolongtou Qing dai Dawo'erzu muzang 齐齐哈尔富拉尔基老龙头清代达斡尔族墓葬 (A Tomb of a Qing Dynasty Daur at Laolongtou, Fula'erji, Qiqiha'er). *Beifang wenwu* 1: 53–54.

Iscan, Mehmet Y.

1991 The aging process in the rib: An analysis of sex- and race-related morphological variation. *American Journal of Human Biology* 3: 617–623.

Jankowski, Lyce, and Pauline Sebillaud.

2018 Mission archéologique franco-chinoise dans le Nord-Est de la Chine : découvertes monétaires en contexte funéraire sur le site de Pianliancheng. *Bulletin de la Société française de numismatique* 73/08: 387–392.

Card, Jeb J.

2013 Introduction. In *The Archaeology of Hybrid Material Culture*, Jeb J. Card, editor, pp. 1–21. Southern Illinois University Press, Carbondale, Illinois.

Jilin sheng wenwu zhi bianweihui 吉林省文物志编委会 (JSWZB).

1984 *Lishu xian wenwuzhi* 梨树县文物志 (Cultural Gazetteer of Lishu District). Jilin sheng wenwu zhi bianweihui, Changchun, PRC.

Jilin sheng wenwu kaogu yanjiusuo 吉林省文物考古研究所 (JSWKY).

2016 Jilin sheng Nong'an xian Kujindui gucheng xinanjiao 'Dianjiangtai' de fajue 吉林省农安县库尔金堆古城址西南角“点将台”的发掘 (The Excavation of the 'Dianjiangtai' at the South-west Corner of the Ancient City of Kujindui in Nong'an District, Jilin Province). *Beifang wenwu* 1: 12–18.

Jilin sheng wenwu kaogu yanjiusuo 吉林省文物考古研究所 (JSWKY) and Yushu shi bowuguan 榆树市博物馆 (YSB).

2008 Changchun shi Yushu Hanjiatun mudi fajue jianbao 长春市榆树韩家屯墓地发掘简报 (Preliminary Excavation Report of the Hanjiatun Cemetery, Yushu, Changchun City). *Bowuguan yanjiu* 3: 71–74.

2010 Jilin sheng Yushu shi Shangtaizi muqun fajue baogao 吉林省榆树市上台子墓群发掘报告 (Excavation Report on the Burial Group of Shangtaizi in Yushu City, Jilin Province). *Beifang wenwu* 1: 20–28.

Klales, Alexandra R., Stephen D. Ousley, and Jennifer M. Vollner.

2012 A revised method of sexing the human innominate using Phenice's nonmetric traits and statistical methods. *American Journal of Physical Anthropology* 149, 1:104–114.

Klaus, Haagen D.

2013 Hybrid cultures . . . and hybrid peoples: Bioarchaeology of genetic change, religious architecture, and burial ritual in the colonial Andes. In *The Archaeology of Hybrid Material Culture*, Jeb J. Card, editor, pp. 207–238. Souther Illionis University Press, Carbondale, Illinois.

Ko, Dorothy.

2005 *Cinderella's Sisters: A Revisionist History of Footbinding*. University of California Press, Berkeley, CA.

Kraus-Friedberg, Chana.

2008 Transnational Identity and Mortuary Material Culture: The Chinese Plantation Cemetery in Pāhala. *Hawai'i Historical Archaeology* 42: 123–135.

Langley-Shirley, Natalie, and Richard L. Jantz.

2010 A Bayesian approach to age estimation in modern Americans from the clavicle. *Journal of Forensic Sciences* 55, 3: 571–583.

Larsen, Clark Spencer.

2015 *Bioarchaeology: Interpreting Behavior from the Human Skeleton*. Cambridge Studies in Biological and Evolutionary Anthropology. 2 ed. Cambridge University Press, Cambridge, UK.

Lau, Bryony.

2008 The Limits of the Civilizing Mission: A Comparative Analysis of British Protestant Missionary Campaigns to End Footbinding and Female Circumcision. *Social Sciences and Missions* 21: 193–227.

Launay, P. Adrien.

1890 *Atlas des Missions de la Société des Missions Etrangères*. Desclée de Brouwer, Paris, France.

1905 *La Mission de Mandchourie*. Société des Missions Etrangères, Maison Alfred Mame et Fils, Paris, France.

Lawrence, Susan, and Nick Shepherd.

2006 Historical Archaeology and Colonialism. In *The Cambridge Companion to Historical Archaeology*, Dan Hicks, and Mary C. Beaudry, editors, pp. 69-86. Cambridge University Press, Cambridge, UK.

Lee, Christine, and Lei Sun.

2019 A Bioarchaeological and Biocultural Investigation of Chinese Footbinding at the Xuecun Archaeological Site, Henan Province, China. *International Journal of Paleopathology* 25: 9–19.

Lee James Z., and Cameron D. Campbell.

2007 *Fate and Fortune in Rural China: Social Organization and Population Behavior in Liaoning 1774-1873*. Cambridge University Press, Cambridge, UK.

Levy, Howard S.

1992 *The Lotus Lovers: The Complete History of the Curious Erotic Custom of Footbinding in China*. Prometheus Books, Amherst, NY.

Li, Ji.

2013 Chinese Christian Virgins and Catholic Communities of Women in Northeast China. *The Chinese Historical Review* 20, 1: 16–32.

2015 *God's Little Daughters - Catholic Women in Nineteenth-Century Manchuria*. University of Washington Press, DC.

Li, Zhensheng 李镇生.

1990 “Huikeqi” ci de qinghua zhuangshi 灰可器’瓷的青花装饰 (Decorative patterns of the *huikeqi* porcelain). *Jingdezhen taoci* 1: 39–40.

Liebmann, Matthew.

2013 Parsing Hybridity: Archaeologies of Amalgamation in Seventeenth Century New Mexico. In *The Archaeology of Hybrid Material Culture*, Jeb J. Card, editor, pp. 25–49. Southern Illinois University Press, Carbondale, Illinois.

Liu, Li.

1999 Who were the ancestors? The origins of Chinese ancestral cult and racial myths. *Antiquity* 73: 602–613.

Malatesta, Edward J., and Zhiyu Gao.

1995 *Departed, Yet Present - Zhalan, The Oldest Christian Cemetery in Beijing*. Instituto Cultural de Macau, Ricci Institute, University of San Francisco, Macao, PRC.

Marcel, Sarah Elizabeth.

1994 Buttoning Down the Past: A Look at Buttons as Indicators of Chronology and Material Culture. *University of Tennessee Honors Thesis Projects*.

Ming, Xiaoyan 明晓艳, and Yangbo Wei 魏扬波.

2007 *Lishi yizong: Zhengfusi Tianzhujiào mudi* 历史遗踪：正福寺天主教墓地 (Historical Traces : The Catholic Cemetery of Zhengfusi). Wenwu chubanshe, Beijing, PRC.

Morgan, Stephen L.

2004 Economic growth and the biological standard of living in China, 1880–1930. *Economics & Human Biology* 2, 2: 197–218.

Moshenska, Gabriel

2013 Conflict. In *The Oxford Handbook of the Archaeology of the Contemporary World*, Graves-Brown Paul, Rodney Harrison, and Piccini Angela, editors, pp. 351-363, Oxford University Press, Oxford, UK.

Qiqiha'er shi wenwu guanlizhan 齐齐哈尔市文物管理站 (QSWG).

2005 Qiqiha'er shi Jianhua qu Hongguang cun Qing dai fuqi hezang mu fajue jianbao 齐齐哈尔市建华区红光村清代夫妻合葬墓发掘简报 (Preliminary Report of the Qing Dynasty Man and Wife Joined Burials of Hongguang Village, in Jianhua, Qiqiha'er City). *Beifang wenwu* 3: 37–40.

Roffet-Salque, Mélanie, Julie Dunne, David T. Altoft, Emmanuelle Casaniva, Lucy J.E. Cramp, Jessica Smyth, Helen L. Whelton, Richard P. Evershed.

2017 From the inside out: Upscaling organic residue analyses of archaeological ceramics. *Journal of Archaeological Science: Reports* 16: 627–640.

Rogers, Juliet, and Tony Waldron.

2001 DISH and the monastic way of life. *International Journal of Osteoarchaeology* 11, 5: 357–365.

Ross, Douglas Edward.

2015 Barkerville in Context: Archaeology of the Chinese in British Columbia. *BC Studies: The British Columbian Quarterly* 185: 161–192.

Schmidt, Ryan W.

2009 Perimortem Injury in a Chinese American Cemetery: Two Cases of Occupational Hazard or Interpersonal Violence. *The Internet Journal of Biological Anthropology* 3, 2. Electronic document, <http://ispub.com/IJBA/3/2/13579>. Accessed July 10, 2020.

Schmidt, Ryan W., Noriko Seguchi, and Jennifer Thompson.

2011 Chinese immigrant population history in North America based on craniometric diversity. *Anthropological Science*, 119, 1: 9–19.

Shenyang shi wenwu kaogu yanjiusuo 沈阳市文物考古研究所 (SSWKY).

2007 Faku faxian Qing dai zaoqi yizhi 法库发现清代早期遗址 (The Discovery of an Early Qing Site in Faku). In *Shenyang kaogu wenji (1)* 沈阳考古文集 (一), pp. 199–202. Wenwu chubanshe, Beijing, PRC.

2011 *Shenyang Bawangsi diqu kaogu fajue baogao* 沈阳八王寺地区考古发掘报告 (Excavation Report on the Bawangsi Area in Shenyang). Liaohai chubanshe, Shenyang, PRC.

Shepherd, Nick.

2013 Contemporary Archaeology in the Postcolony; Disciplinary Entrapments, Subaltern Epistemologies. In *The Oxford Handbook of the Archaeology of the Contemporary World*. Paul Graves-Brown, Harrison Rodney, and Angela Piccini, editors, pp. 425–436. Oxford University Press, Oxford, UK.

Silliman, Stephen W.

2012 Between the longue durée and the short purée. In *Decolonizing Indigenous Histories: Exploring Prehistoric/Colonial Transitions in Archaeology*. Maxine Oland, Siohan M. Hart, and Liam Frink, editors, pp. 113–131. University of Arizona Press, Tucson, Arizona.

2013 What, where, and when is hybridity. In *The Archaeology of Hybrid Material Culture*, Jeb J. Card, editor, pp. 486–500. Southern Illinois University Press, Carbondale, Illinois.

Smits, Nicholas J.

2008 Roots Entwined: Archaeology of an Urban Chinese American Cemetery. *Historical Archaeology* 42: 111–122.

Sprague, Roderick.

2002 China or Prosser Button Identification and Dating. *Historical Archaeology* 36, 2: 111–127.

Société des Missions étrangères de Paris (SMEP).

1882 *Règlement de la mission de Mandchourie adopté à la réunion générale des missionnaires. Année 1881*. Imprimerie de l'Œuvre de Saint-Paul, Paris, France. <http://gallica.bnf.fr/ark:/12148/bpt6k3753912>. Accessed January 25, 2020.

1871-1941 *Compte-rendu des travaux - Société des missions étrangères*. Maison Alfred Mame et Fils, Paris, France. 66 years of publication are available online on the French National Library website: Gallica <http://gallica.bnf.fr/ark:/12148/cb328700176/date&rk=107296;4>. Accessed January 25, 2020.

Steckel, Richard H.

2005 Young Adult Mortality Following Severe Physiological Stress in Childhood: Skeletal Evidence. *Economics and Human Biology* 3: 314–328.

Stewart, T. Dale.

1975 Cranial Dysraphism Mistaken for Trephination. *American Journal of Physical Anthropology* 42, 3: 435–437.

Stockhammer, Philipp W.

2012 Conceptualizing Cultural Hybridization in Archaeology. In *Conceptualizing Cultural Hybridization : A Transdisciplinary Approach*, pp. 43–58. Springer, Berlin, Germany.

Stojanowski, Christopher M., and Clark Spencer Larsen.

2013 *Mission Cemeteries, Mission Peoples: Historical and Evolutionary Dimensions of Intracemetery Bioarchaeology in Spanish Florida. Bioarchaeological Interpretations of the Human Past: Local, Regional, and Global Perspectives*. University Press of Florida, Gainesville.

Tiedemann, Rolf Gerhard (editor).

2010 *Handbook of Christianity in China Volume Two: 1800-Present*. Brill, Leiden, Netherlands.

Turner, Christena L.

1997 Locating Footbinding: Variations across Class and Space in Nineteenth and Early Twentieth Century China. *Journal of Historical Sociology* 10: 444–479.

Verano, John W.

2016 Differential Diagnosis: Trepanation. *International Journal Paleopathology* 14: 1–9.

Voss, Barbara L.

2005 The Archaeology of Overseas Chinese Communities. *World Archaeology* 37, 3: 424–439.

2016 Towards a Transpacific Archaeology of the Modern World. *International Journal of Historical Archaeology* 20, 1: 146–174.

2018a Every Element of Womenhood with which to Make Life a Curse or Blessing. *Journal of Asian American Studies* 21, 1: 105–134.

2018b The Archaeology of Precarious Lives - Chinese Railroad Workers in Nineteenth-Century North America. *Current Anthropology* 39, 3: 287–313.

Voss, Barbara L., J. Ryan Kennedy, Selia Jinhua Tan, and Laura W. Ng.

2018 The Archaeology of Home: Qiaoxiang and Nonstate Actors in the Archaeology of Chinese Diaspora. *American Antiquity* 83, 3: 407–426.

Voss, Barbara L., J. Ryan Kennedy, and Selia Jinhua Tan.

2019 *The Transnational Lives of Chinese Migrants: Material Culture Research from a Guangdong Province Qiaoxiang*. Electronic document, https://cangdong.stanford.edu/sites/g/files/sbiybj11666/f/the_transnational_lives_of_chinese_migrants_-_april_2019.pdf. Accessed July 11, 2020.

Walker, Philip L., Rhonda R. Bathurst, Rebecca Richman, Thor Gjerdrum, and Valerie A. Andrushko.

2009 The Causes of Porotic Hyperostosis and Cribra Orbitalia: A Reappraisal of the Iron-deficiency-anemia Hypothesis. *American Journal of Physical Anthropology* 139, 2: 109–125.

Wang, Ping.

2000 *Aching for Beauty: Footbinding in China*. University of Minnesota Press, Minneapolis.

Watson, James L., and Evelyn S. Rawski (editors).

1988 *Death Ritual in Late Imperial and Modern China*. University of California, Berkeley.

White, Tim D., and Peter A. Folkens.

2005 *The Human Bone Manual*. Elsevier, London, UK.

Wilkinson, Endymion.

2000 *Chinese History, a Manual*. Harvard University Asia Center, Cambridge, UK.

Wood, James, George Milner, Henry Harpending, and Kenneth Weiss.

1992 The Osteological Paradox: Problems of Inferring Prehistoric Health from Skeletal Samples. *Current Anthropology* 33, 4: 343–370.

Wu, Qunli, and Xiaochun Liang.

2018 Food Therapy and Medical Diet Therapy of Traditional Chinese Medicine. *Clinical Nutrition Experimental* 18: 1–5.

Wu, Xiaolong.

2013 Cultural hybridity and social status: elite tombs on China's Northern Frontier during the third century BC. *Antiquity* 87: 121–136.

Xia, Xun-Li.

2013 History of Chinese Medicinal Wine. *Chinese Journal of Integrative Medicine* 19, 7: 549–555.

Yaussy, Samantha L.

2019 The intersections of industrialization: Variation in skeletal indicators of frailty by age, sex, and socioeconomic status in 18th- and 19th-century England. *American Journal of Physical Anthropology* 170, 1: 116–130.

Zhang, Hua, Deborah C. Merrett, Zhichun Jing, Jigen Tang, Yuling He, Hongbin Yue, Zhanwei Yue, and Dongya Y. Yang.

2016 Osteoarchaeological studies of human systemic stress of early urbanization in late Shang at Anyang, China. *PLoS One* 11.

Zhao, Yongsheng 赵永生, Lin Guo 郭林, Daohua Hao 郝导华, Baolei Li 李宝垒, and Wen Zeng 曾雯.

2017a Shandong Diqu Qing Mu Zhong Nüxing Jumin De Chanzu Xianxiang 山东地区清墓中女性居民的缠足现象 (A Study of the Foot-Binding Phenomenon of Qing Dynasty Females in Shandong Province). *Acta Anthropologica Sinica* 36(3): 344–358.

Zhao, Yongsheng 赵永生, Wen Zeng 曾雯, Chengmin Wei 魏成敏, Xinyue Zhang 张馨月, and Kai Lü 吕凯.

2017b Dawenkou wenhua jumin zhenbu bianxing yanjiu 大汶口文化居民枕部变形研究 (Research on Skull Deformation on People from the Dawenkou Culture), *Dongnan wenhua* 3: 64–72.

Zhao, Yongsheng, Lin Guo, Yuni Xiao, Yueming Niu, Xiaowen Zhang, Deliang He, and Wen Zeng.

2020 Osteological Characteristics of Chinese Foot-Binding in Archaeological Remains. *International Journal of Paleopathology* 28: 48–58.

Zhou, Chunbing 周春水, and Lei Feng 冯雷.

2016 Liaoning Dandong yihao chenchuan shuixia kaogu diaocha 辽宁‘丹东一号’沉船水下考古调查 (Archaeological Underwater Survey on the Dandong 1 shipwreck, Liaoning). In *2015 Zhongyao kaogu faxian 2015 中国重要考古发现* (Important Archaeological Discoveries in China in 2015), pp. 176–180. Wenwu chubanshe, Beijing, PRC.

Zhou, Liming, and Robert S. Corruccini

1998 Enamel Hypoplasias Related to Famine Stress in Living Chinese, *American Journal of Human Biology* 10, 6: 723–733.

Zhu, Hong 朱泓, Kan Hou 侯侃, Xiaoyi Wang 王晓毅.

2017 Cong shengwu kaogu xue jiaodu kan Shanxi Yuci Ming Qing shiqi pingmin de liang xing chayi 从生物考古学角度看山西榆次明清时期平民的两性差异 (Gender Differences among the Civilians in the Ming Dynasty and the Qing Dynasty in Yuci, Shanxi from the Perspective of Bioarchaeology). *Jilin Daxue Shehui Kexue Xuebao* 57(4): 117–124.