HAL open science

Cerebellar swelling after surgery for medulloblastoma with leptomeningeal dissemination in children. A case based-update

Julien Todeschi, Irène Stella, Natacha Entz-Werle, Hugo Andres Coca, Anthony Joud, Pascal Chastagner, François Proust, Olivier Klein

To cite this version:

Julien Todeschi, Irène Stella, Natacha Entz-Werle, Hugo Andres Coca, Anthony Joud, et al.. Cerebellar swelling after surgery for medulloblastoma with leptomeningeal dissemination in children. A case based-update. Neurochirurgie, 2021, 67 (2), pp.145-151. 10.1016/j.neuchi.2020.11.015 . hal-03637864

HAL Id: hal-03637864

https://hal.science/hal-03637864v1

Submitted on 4 Apr 2023

HAL is a multi-disciplinary open access archive for the deposit and dissemination of scientific research documents, whether they are published or not. The documents may come from teaching and research institutions in France or abroad, or from public or private research centers.

L'archive ouverte pluridisciplinaire **HAL**, est destinée au dépôt et à la diffusion de documents scientifiques de niveau recherche, publiés ou non, émanant des établissements d'enseignement et de recherche français ou étrangers, des laboratoires publics ou privés.

Distributed under a Creative Commons Attribution - NonCommercial 4.0 International License

Version of Record: https://www.sciencedirect.com/science/article/pii/S002837702030480X
Manuscript_776ab83c874654737604223aa8e5b58c

CEREBELLAR SWELLING AFTER SURGERY FOR MEDULLOBLASTOMA WITH LEPTOMENINGEAL DISSEMINATION IN CHILDREN. A CASE BASED-UPDATE.

J. Todeschi [1,2], I. Stella[1], N. Entz-Werle[3-4], HA. Coca[2], A. Joud[1], P. Chastagner[5], F. Proust[2], O. Klein[1]

[1]Department of Pediatric Neurosurgery, Nancy University Hospital, University of Lorraine, France.

[2]Department of Neurosurgery, Strasbourg university hospitals. University of Strasbourg, France.

[3]Department of Pediatric Onco-Hematology, Strasbourg University hospital, France.

[4] UMR CNRS7021, Laboratory of Bioimaging and Pathologies, University of Strasbourg, France

[5]Department of Pediatric Oncology, Nancy University Hospital, University of Lorraine, France.

Corresponding author: TODESCHI Julien MD

E-mail address: julien.tod@gmail.com (J. Todeschi)

Hôpital d'Enfants, rue du Morvan – 54511 Vandoeuvre-les-Nancy Cedex

Abstract word count: 206

Text word count: 2296

Number of references: 18

Number of tables and/or figures (total): 5

Number of videos: 0

Keywords: Medulloblastoma; Leptomeningeal diffusion; cerebellar swelling; Upward herniation

© 2020 published by Elsevier. This manuscript is made available under the Elsevier user license
https://www.elsevier.com/open-access/userlicense/1.0/

Abbreviations:

- LCA: large cell anaplastic medulloblastoma
- LMD: Leptomeningeal dissemination
- CT: computerized tomography
- MRI: magnetic resonance imaging
- CSF: CerebroSpinal Fluid
- EVD: external ventricular drain
- GCS: Glasgow Coma Scale
- PFT: posterior fossa tumor
- SHH: Sonic HedgeHog
- GCS: Glasgow Coma Scale
- BBB: blood-brain barrier
- VPFs: vascular permeability factors
- VPS: ventriculoperitoneal shunt
- GTR: gross total resection

ABSTRACT

Object

Despite the improvement in the overall management of medulloblastomas in recent years, certain phenomena and in particular post-operative cerebellar swelling remain an enigma. This rare complication, little described in the literature, is nonetheless life-threatening for the patients.

Case reports

We report our experience about two children who developed severe cerebellar swelling with hydrocephalus and upward herniation soon after a gross total resection of a fourth ventricle medulloblastoma by a telo-velar approach. Despite rapid management of ventricular dilation and optimal medical intensive treatment of intracranial hypertension, both children died quickly after the surgery. Pathological examination analyses were in favor of anaplastic/large cell medulloblastoma.

Discussion

Diffuse cerebellar swelling with upward herniation may occur postoperatively in young children with anaplastic/large cell medulloblastoma with leptomeningeal spread. In the literature, only 4 cases have been so far described with delayed onset of symptoms. Two children survived with an aggressive management (decompressive surgery and early radio-chemotherapy).

Conclusion

Cerebellar swelling is an unrecognized and sudden complication of posterior fossa surgery for metastatic anaplastic medulloblastoma with leptomeningeal dissemination in young children. An initial less invasive surgical approach could be considered in such cases, in order to

prevent this complication with potentially tragic issue, and which cannot be managed with a CSF shunt alone.

INTRODUCTION

Medulloblastoma is the most common malignant brain tumor (WHO grade 4) of the posterior fossa in children [1], commonly rising from inferior cerebellar vermis and extending into the fourth ventricle. Mortality rate and overall outcome of these patients improved dramatically during the last decades due to increased knowledge on histo-molecular subgrouping [1], as well as the identification of high-risk groups (e.g. leptomeningeal dissemination at diagnosis, postoperative residual disease greater than 1.5 cm2 or anaplastic histology, age less than 2 years) [2-5]. It led to a better comprehension of tumor behavior and better selection of treatment strategies.

Therapeutic management of medulloblastomas is multidisciplinary, starting in almost all cases by surgical resection, even in case of leptomeningeal spread if a tumor mass is identified, followed by adjuvant chemotherapy and, depending on the age, craniospinal radiotherapy [6].

The quality of resection seems to play a crucial role to optimize the prognosis of children, and it should to be as complete as possible [7]. However, it is possible in rare cases that surgery might be deleterious more than useful and potentially lead to fatal complications.

We report two cases of surgical resection of large cell/anaplastic medulloblastoma (LCA) with leptomeningeal dissemination (LMD) at diagnosis, rapidly complicated by cerebellar swelling with fatal upward herniation.

On the basis of our experience, and after a review of the literature, we propose an in-depth examination of the clinical profile and initial radiological characteristics, trying to identify patients at high risk for such complication.

CASE- REPORTS

Case 1

A 2-year-old child with no previous medical history was referred to emergency department complaining for headache and morning vomiting lasting 2 weeks. The initial clinical examination revealed cerebellar ataxia without any other neurological deficit. A brain MRI (Magnetic Resonance Imaging) and CT-scan (Computerized Tomography-scan) were [Figure 1] showed a 17-mm-solid mass probably, originating from the vermis and extending into the 4th ventricle. Intense linear contrast enhancement limited to posterior fossa was also observed on contrasted T-1weighted sequences, evoking a LMD [see Figure 1 white arrows]. A minimal tri-ventricular dilation was also observed, but without sign of transependymal resorption. In this context, a first-line surgical resection without prior CSF (CerebroSpinal Fluid) diversion was decided. Surgical resection was performed without particular complications apart from a slight tension at the opening of the dura mater controlled by cisterna magna opening. It consisted of a telovelar approach without resection of the posterior arch of C1 or the need for EVD. The tight closure of the dura mater with rigid fixation of the bony flap was realized.

An extubation in intensive care unit was rapidly possible. At 24 hours, the patient presented arterial hypertension, tachycardia, respiratory distress and consciousness disorder. An orotracheal intubation was urgently decided and the CT-scan objectified a malignant edema of posterior fossa associated with obstructive hydrocephalus. An EVD (External Ventricular Drain) was put in emergency to control hydrocephalus [see Figure 2] combined with intravenous corticosteroid therapy of 2 mg / kg. However, a refractory convulsive state required deep sedation and anti-epileptic drugs. CT-scan and MRI performed 2 days after the EVD revealed a reduced ventricular size but a persistent massive cerebellar edema with major brainstem compression. Despite optimal medical treatment for intracranial hypertension, the clinical condition deteriorated with appearance of GCS (Glascow Coma Scale) 3, bilateral

reactive mydriasis and absence of brainstem reflexes. The transcranial doppler confirmed diffuse cerebral hypoperfusion, while brain CT-scan showed a whole brain edema with loss of white/gray matter differentiation. The child died 6 days after the PFT (Posterior Fossa Tumor) surgery. The histological conclusions were in favor of an LCA medulloblastoma without any features of Sonic HedgeHog (SHH) pathway activation. Molecular biology associated to this worst outcome pathology a *CMYC* amplification, but not *TP53* mutation.

Case 2

A 7-year-old boy without relevant medical history was admitted with the diagnosis of PFT. An MRI was performed subsequently to 5-day lasting vomiting and headache, associated to recent confusion and gait disturbances. Neurological examination at admission found a GCS 15 with mild cerebellar syndrome (dysmetria, gait instability), but no motor impairment or ocular disturbances. Cerebral MRI with contrast-enhanced T1-weighted sequences showed a 2 x 2 cm enhancing mass in fourth ventricle, with subsequent hydrocephalus, but without hindbrain herniation [see Figure 3]. There were no macroscopic metastatic locations along the whole neuraxis, but subtle linear folia enhancement of cerebellum [see Figure 3 white arrows].

Due to the reassuring clinical status, a ventriculostomy was not performed and the patient was operated few days later for PFT removal.

The surgery was uneventful. A mild tension was noted at dura opening, rapidly released after cisterna magna opening, and diffuse leptomeningeal tumor spread was observed on cerebellar hemispheres. The posterior arch of C1 was removed. Due to the absence of tension at the end of the intervention, as well as the possibility to perform à satisfying dural suture, duraplasty was not necessary; bone flap was placed over the dura without solid fixation, assured by biologic glue. Rapidly after operation, the patient was awake and spoke fluently. At 12 hours, a sudden clinical deterioration was observed. EVD shunt was put in emergency combined

with intravenous corticosteroid therapy of 1 mg / kg, as cerebral CT-scan showed acute hydrocephalus associated with posterior fossa swelling and brainstem compression. Nevertheless, neurological status was already severely impaired, with rapid onset of neurogenic pulmonary edema and secondary cardiac dysfunction. Aminic drugs support and intensive care allowed systemic improvement and a neuroprotective respiratory assistance was maintained. A contrast-enhanced MRI showed a major increase of leptomeningeal neoplastic dissemination on cerebellum reaching the supra tentorial compartment and associated with a persistent posterior fossa swelling [see Figure 4]. Chemotherapy, associating one intraventricular injection of Thiotepa and intravenous Temozolomide, was rapidly begun, but without any benefit on neurological status. The patient died on post-operative day 15. Pathological analyses were in favor of LCA with neither WNT nor SHH involvement. Unfavorable biological markers (*CMYC* amplification and *TP53* deletion) were present.

DISCUSSION

We reported two cases of massive cerebellar swelling with acute hydrocephalus appearing early after PFT resection in children aged 2 and 7 years, respectively.

Acute (and sometimes delayed) hydrocephalus is a well-known complication after surgery for PFT, especially when lesion invades the fourth ventricle . Post-resection hydrocephalus rate in the pediatric population has been reported between 10 to 40% of cases [8, 9] with an estimated appearance time of 17.9 ± 16.7 days [10]. Medulloblastoma, metastatic disease and young age at diagnosis are known risk factor of post-operative hydrocephalus, needing shunt placement [8-11]. The cut-off age varies among series, being estimated at 2, 3 or 10 years [10]. When comparing molecular subgroups, Schneider et al. found that Group 4 medulloblastomas carry the higher risk to post-operative shunt need (43%), followed by SHH group and Group 3 (29%)[12].

While the obstructive origin of PFT-related hydrocephalus seems to be obvious in the pre-operative stage, it is more difficult to assess the precise physiopathology in post-operative patients, especially when gross total resection has been achieved. The communicating pattern, linked to inflammatory reaction or tumor dissemination in metastatic cases has often been evoked with a slow onset several days after the PFT surgery. In our case reports, we described an unfavorable evolution in early post-operative period leading to consider obstructive scenario rather than communicating one, even if there were no evidence of hemorrhagic complication on CT-scans. Hindbrain compression, caused by cerebellar swelling, was present in the 2 cases [Figures 2 and 4]. In the second case, it was also associated with a massive and rapid leptomeningeal tumor spread.

Only 4 other cases were discussed in previous publications and are summarized in Table1, letting us hypothesizing that this type of complication is probably rare (or rarely described) and little is known about it. Raghu et al. [Table1] reported a similar scenario of cerebellar swelling with leptomeningeal neoplastic dissemination at 36 post-operative days in a 4-year-old already shunted child [13]. The child presented also a massive LMD at diagnosis. A rapid therapeutic management with chemotherapy led to improve cerebellar swelling in about 7 days. Shapiro et al. [Table 1] reported an analogous case of a 3-year-old boy who benefited from a Ventriculo-Peritoneal Shunt (VPS) few days after PFT surgery. In fact, one week later, he presented a severe clinical deterioration due to cerebellar swelling. Emergency radiotherapy allowed to improve both clinical status and posterior fossa edema [6]. Likewise, 2 cases have been described by Ogiwara et al. in 2011 [Table 1]. Two 2-year-old boys, already treated for hydrocephalus with EVD, showed a sudden deterioration of consciousness due to cerebellar edema respectively at post-operative day 35 and 15. Posterior fossa decompression and emergency chemotherapy were efficient life-saving procedures only in one case, while the other child rapidly died [14].

In all of these described cases, leptomeningeal neoplastic spread was evident at diagnosis and pathological results were in favor of LCA. No further precision about molecular biology are reported by authors.

All these cases seem to demonstrate that acute hydrocephalus is not the main cause of deterioration in children operated on for fourth ventricle lesion with diffuse spread pattern at diagnosis. One can assume that sudden clinical postoperative impairment is rather caused by cerebellar swelling. Furthermore, previous temporary or definitive shunt placement has been suspected by the same authors to even worsen brainstem compression by increasing upward herniation of cerebellar vermis.

Thus, posterior fossa edema might be taken into account as a medulloblastoma's characteristic complication in children who had an initial disseminated pattern in the posterior fossa - and especially in the more aggressive subtypes like LCA histology. Raghu et al suggested that LMD is a determinant factor in the pathogenesis of the described phenomena, as it produces/induces/favors an increasing perilesional vasogenic edema after blood-brain barrier (BBB) surgical disruption, thus creating a venous drainage obstruction [13]. It has already been described that metastatic tumor cells might express a vascular permeability factor (VPF), which is associated with a subsequent vasogenic edema [15]. Disruption of BBB and this secretion of VPF by lymphocytes infiltrating metastatic tumors might be responsible for the worsening of cerebellar swelling [16].

The hypothesis that the cerebellar swelling is a direct consequence of the surgical approach remains to be considered. Moreover, the possibility of an ischemic vascular etiology contributing to cerebellar swelling cannot be ruled out, but in our cases it doesn't seem to be the first hypothesis, as postoperative MRI did not show any ischemic event.

Regarding therapeutic option, one cannot conclude proposing the best way treatment on the basis of a few cases reports. Nevertheless, one can speculate about such bad experiences in

order to better face up similar cases and to avoid fatal complications.

For the cited authors, initial less invasive surgical procedures (needle biopsy or minimal leptomeningeal samples) might be considered in order to reduce cerebellar exposure and to avoid this life-threatening complication. In 2 out of 5 treated cases, a rapid post-biopsy chemo-radiotherapy seemed to be effective on disease progression control and could be associated with a delayed surgery to afford in a second time a complete removal of the residual mass. If biopsy is not possible, another strategy proposed is to carry out emergency induction chemotherapy if a CSF sample shows tumor cells (example after CSF diversion). Nevertheless, even if a limited biopsy is less aggressive than a gross total removal with retraction of infiltrated cerebellar hemispheres, it is not certain that it would not result in the same consequences.

If a total resection is planned, particular attention to all events that might increase edema must be paid. A CSF shunt procedure (EVD or VCS) associated with preventive large duraplasty without bone placement and opening of C1 arch in order to limit brainstem compression due to cerebellar swelling should be considered. Moreover, the use of spatula must be limited, venous coagulation avoided and aggressive post op antiedema treatment undertaken. In our two cases, neither preoperative status nor intraoperative event prompted us to put an EVD or to perform preventive enlargement of the posterior fossa. The combination of high dose IV corticosteroid therapy should also be considered, eventually prior to surgery, as in our cases, post-operative steroid therapy didn't change clinical course.

If acute cerebellar swelling installed, standard medical therapies against intracranial hypertension (osmotherapy, cerebral perfusion pressure optimization, mild hyperventilation, barbiturate coma, corticosteroid therapy) must be started urgently in the intensive care unit. In case of failure, a decompressive craniectomy with duroplasty and eventually minimal cerebellar resection, in combination with an EVD, can also be discussed, in order to reduce

fossa posterior hypertension [17]. In our cases, rapid post-operative manifestation did not let us the opportunity to treat the patients more aggressively.

Chemotherapy and radiotherapy in emergency scenario have also been invoked and used with apparent benefit in the cited cases; nevertheless, their effectiveness cannot be confirmed due to the paucity of cases reported. Moreover, as local edema is a known effect of radiotherapy [18], risk of posterior fossa swelling aggravation should be kept in consideration.

This complication remains probably underestimated or little described in the literature and it is difficult to define the best management basing on a few series of cases. However, in the case of tumors of the 4th ventricle, a rigorous analysis of pre-operative MRI scan for signs of atypical cerebellar swelling / cerebellar leptomeningeal spread should be performed and warns about possible postoperative serious complication.

CONCLUSION

Cerebellar swelling seems to be a sudden, but little-known complication of posterior fossa surgery for anaplastic medulloblastoma metastatic with leptomeningeal dissemination in the cerebellum in young children. The clinical aggravation is mainly due to brainstem compression rather than ventricular dilation and an early CSF shunt seems not preventing this aggressive tumor presentation. In order to prevent this complication, a less invasive procedure (needle biopsy or minimal meningeal sampling), followed by a rapid chemo-radiotherapy initiation and a delayed surgery of the residual mass can be considered.

Disclosure of interest: the authors report no conflict of interest concerning the material or methods used in this study or the findings specified in this paper.

LEGENDS:

Figure 1: Pre-operative brain MRI (Magnetic resonance Imaging) with gadolinium injection in case 1: T1-weighted (a and b) and T2 FLAIR (c and d) sequences show a midline lesion extending into the fourth ventricle and associating to diffuse linear cerebellar enhancement in favor of a leptomeningeal dissemination (white arrows).

Figure 2: T1-weighted (a, b and c) and FLAIR (b) MRI at post-operative day 3 confirming the gross total resection of the lesion. Cerebellar herniation and brainstem compression were observed and due to diffuse bilateral cerebellar swelling. Upward herniation can be appreciated on sagittal sequences (c and d).

Figure 3: Pre-operative brain MRI T1-weighted images with subtle contrast enhancements in case 2: 2 x 2 cm fourth ventricular mass is noted (a, b and c), causing initial ventricular dilation but not cerebellar herniation. Subtle contrast uptake in cerebellar folias can be seen (white arrows), without evident metastatic dissemination in the cortical sulci (d).

Figure 4: Cerebral MRI T1 images with subtle contrast enhancements: diffuse and major tumor leptomeningeal enhancement in supra (d) and sub-tentorial regions (a, b and c) with GTR (Gross Total Resection) of the tumor lesion. There is also a diffuse swelling of the cerebellum, pressing the brainstem forward. To be noted: upward and tonsillar herniations.

Table 1: Evolution and clinical, radiological and therapeutic characteristics of all cases associated with cerebellar swelling after surgical resection in the literature.

REFERENCES

[1] Louis DN, Perry A, Reifenberger G, von Deimling A, Figarella-Branger D, Cavenee WK, et al. The 2016 World Health Organization Classification of Tumors of the Central Nervous System: a summary. Acta Neuropathol. 2016;131:803-20.
[2] Eberhart CG, Kepner JL, Goldthwaite PT, Kun LE, Duffner PK, Friedman HS, et al. Histopathologic grading of medulloblastomas: a Pediatric Oncology Group study. Cancer. 2002;94:552-60.
[3] Ellison DW, Kocak M, Dalton J, Megahed H, Lusher ME, Ryan SL, et al. Definition of disease-risk stratification groups in childhood medulloblastoma using combined clinical, pathologic, and molecular variables. J Clin Oncol. 2011;29:1400-7.
[4] Narayan V, Sugur H, Jaiswal J, Arvinda HR, Arivazhagan A, Somanna S, et al. Medulloblastoma: Distinctive Histo-Molecular Correlation with Clinical Profile, Radiologic Characteristics, and Surgical Outcome. Pediatr Neurosurg. 2019;54:329-40.
[5] Huang PI, Lin SC, Lee YY, Ho DM, Guo WY, Chang KP, et al. Large cell/anaplastic medulloblastoma is associated with poor prognosis-a retrospective analysis at a single institute. Childs Nerv Syst. 2017;33:1285-94.
[6] Shapiro RH, Chang AL. Urgent radiotherapy is effective in the treatment of metastatic medulloblastoma causing symptomatic brainstem edema. Pediatr Blood Cancer. 2011;57:1077-80.
[7] Lannering B, Rutkowski S, Doz F, Pizer B, Gustafsson G, Navajas A, et al. Hyperfractionated versus conventional radiotherapy followed by chemotherapy in standard-risk medulloblastoma: results from the randomized multicenter HIT-SIOP PNET 4 trial. J Clin Oncol. 2012;30:3187-93.

[8] Foreman P, McClugage S, 3rd, Naftel R, Griessenauer CJ, Ditty BJ, Agee BS, et al. Validation and modification of a predictive model of postresection hydrocephalus in pediatric patients with posterior fossa tumors. J Neurosurg Pediatr. 2013;12:220-6.
[9] Riva-Cambrin J, Detsky AS, Lamberti-Pasculli M, Sargent MA, Armstrong D, Moineddin R, et al. Predicting postresection hydrocephalus in pediatric patients with posterior fossa tumors. J Neurosurg Pediatr. 2009;3:378-85.
[10] Won SY, Dubinski D, Behmanesh B, Bernstock JD, Seifert V, Konczalla J, et al. Management of hydrocephalus after resection of posterior fossa lesions in pediatric and adult patients-predictors for development of hydrocephalus. Neurosurg Rev. 2019.
[11] Lin CT, Riva-Cambrin JK. Management of posterior fossa tumors and hydrocephalus in children: a review. Childs Nerv Syst. 2015;31:1781-9.
[12] Schneider C, Ramaswamy V, Kulkarni AV, Rutka JT, Remke M, Tabori U, et al. Clinical implications of medulloblastoma subgroups: incidence of CSF diversion surgery. J Neurosurg Pediatr. 2015;15:236-42.
[13] Raghu ALB, Kandasamy J, Brougham M, Gallo P, Sokol D, Hughes MA. Delayed diffuse cerebellar swelling after resection of medulloblastoma: case report and review of literature. Childs Nerv Syst. 2017;33:2047-9.
[14] Ogiwara H, Dipatri AJ, Jr., Bowman RM, Tomita T, Alden TD. Diffuse postoperative cerebellar swelling in medulloblastoma: report of two cases. Childs Nerv Syst. 2011;27:743-7.
[15] Bruce JN, Criscuolo GR, Merrill MJ, Moquin RR, Blacklock JB, Oldfield EH. Vascular permeability induced by protein product of malignant brain tumors: inhibition by dexamethasone. J Neurosurg. 1987;67:880-4.
[16] Vaquero J, Zurita M, Oya S. Expression and significance of vascular permeability factor in tumour infiltrating lymphocytes of brain metastases. Acta Neurochir (Wien). 2001;143:153-7.
[17] Amar AP. Controversies in the neurosurgical management of cerebellar hemorrhage and infarction. Neurosurg Focus. 2012;32:E1.
[18] Tanguturi SK, Alexander BM. Neurologic Complications of Radiation Therapy. Neurol Clin. 2018;36:599-625.

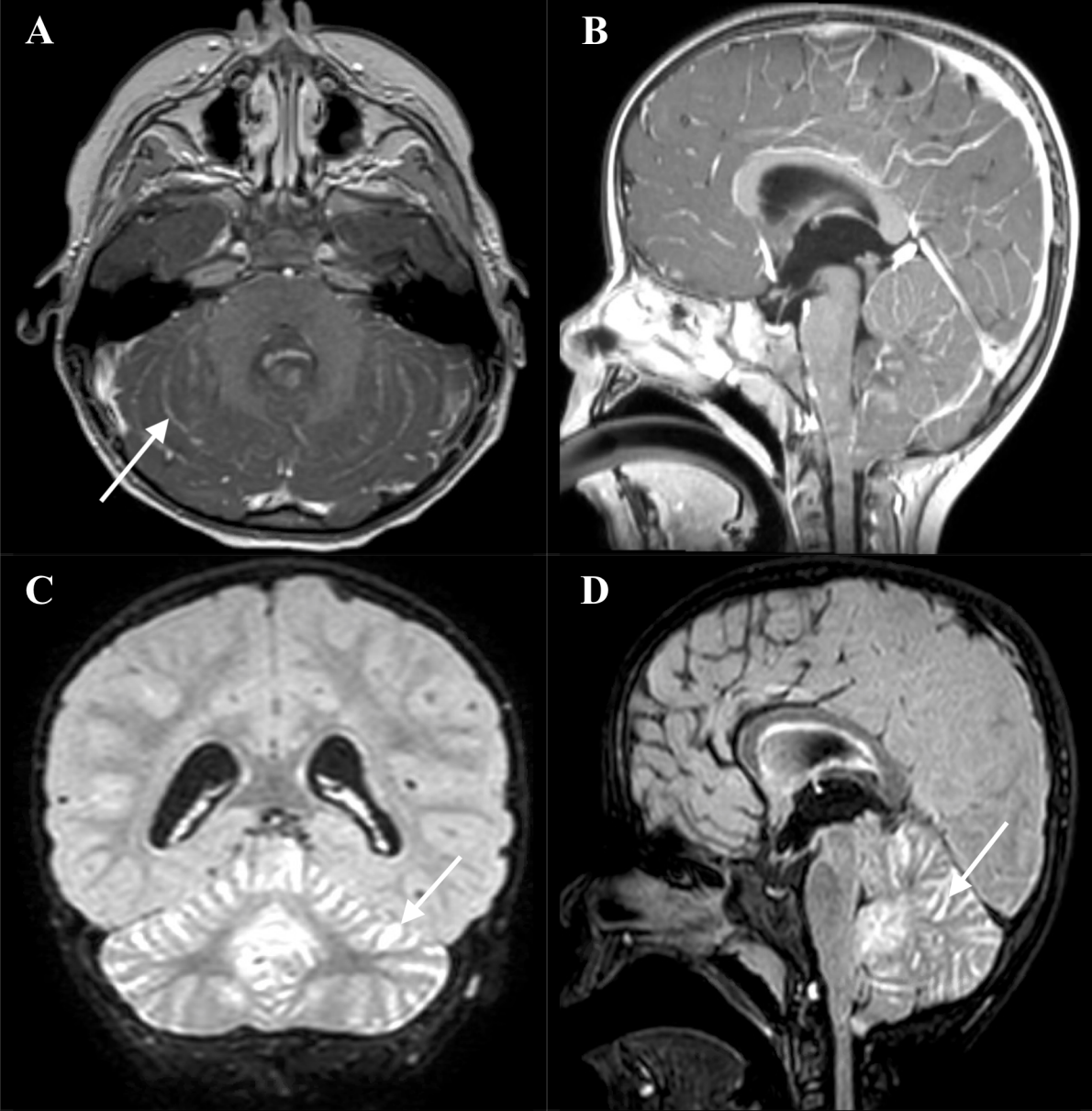
A
B
C
D

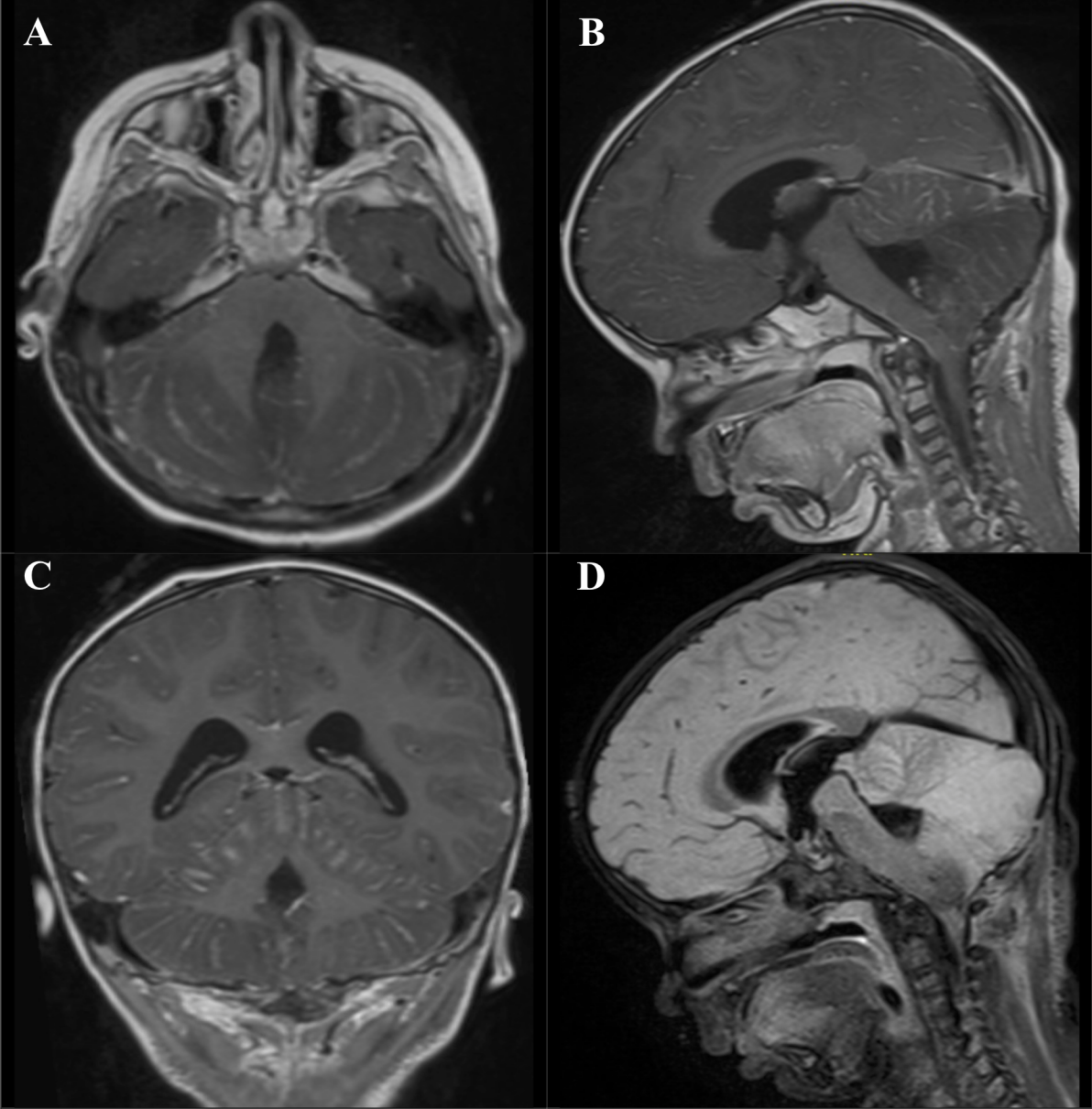
A
B
C
D

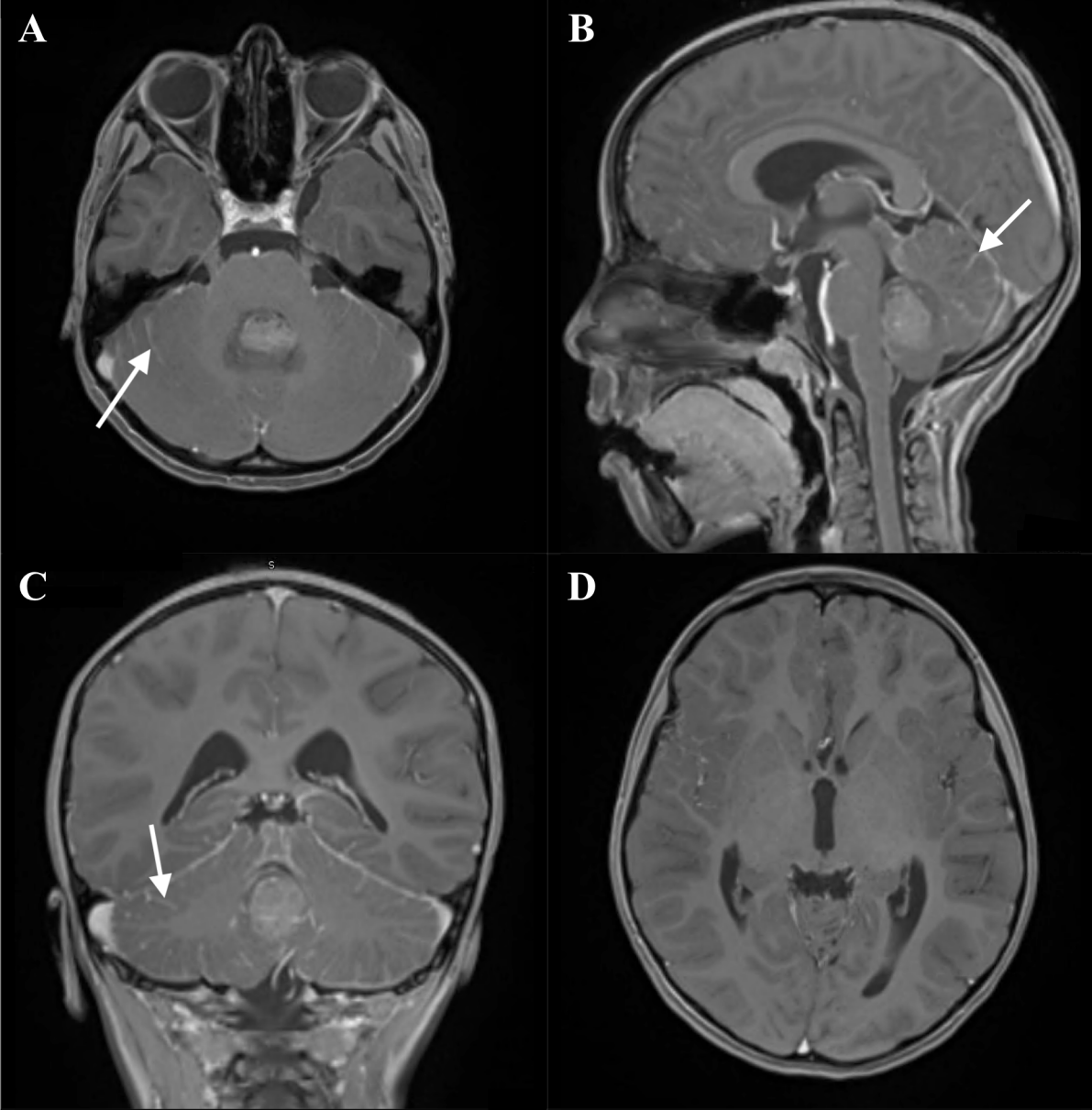
A
B
C
D

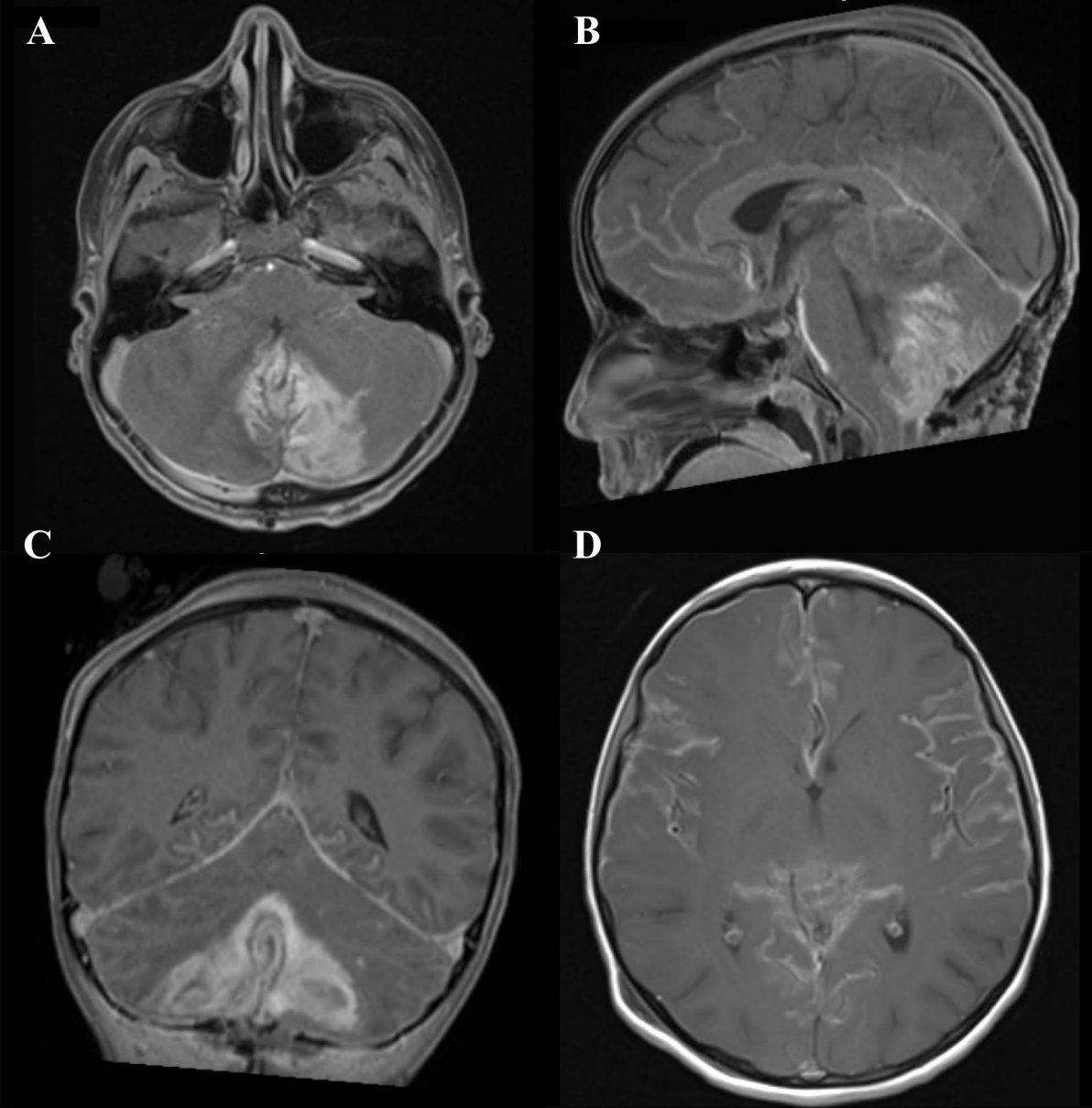
A
B
C
D

Authors	Age / sex	localization of metastases	Initial treatment for hydrocephalus	Surgical Treatment	postoperative hydrocephalus and treatement	Histology	Time to onset	complementary treatment (outside corticosteroid or mannitol)	outcome
Raghu et al. 2017 [13]	4 years / M	Leptomeningeal	no	GTR	Yes / VPS	LCA	41 days	CT (carboplatin and etoposide)	death at 41 weeks
Shapiro et al. 2011 [6]	3 years / M	Leptomeningeal + spinal cord	no	GTR	Yes / VPS	LCA	13 days	RT to the brain and cervical spine + concurrent CT (vincristine)	followed by 21 months and is fine
Ogiwara et al. 2011 [16]	31 months / M	Leptomeningeal	EVD	GTR	Yes / EVD	LCA	16 days	posterior fossa decompression + CT (cisplatin, vincris- tine, cyclophosphamide, and etoposide)	alive on the 79th day / sent to rehabilitation
	32 months / M	Leptomeningeal	EVD	GTR	Yes / VPS	LCA	35 days	posterior fossa decompression	death at 2 months
Current cases	2 years / F	Leptomeningeal + spinal cord	no	GTR	Yes / EVD	LCA	1 day	no	death at 6 days
	7 Years / M	Leptomeningeal	no	GTR	Yes / EVD	LCA	1 day	CT(intraventricular Thiotepa ; Temozolomide)	death at 15 days

M: male; F: female; RT: radiotherapy; CT: chemotherapy; GTR: gross total resection; VPS: ventriculoperitoneal shunt; EVD: External ventricular drain, LCA large cell anaplastic medulloblastoma

Table 1: Evolution and Characteristics (clinical, radiological and therapeutic) of cases of cerebellar swelling after surgical resection