



HAL
open science

Surgical approach of ectopic maxillary third molar avulsion: Systematic review and meta-analysis

R. Courtot, Laurent Devoize, A. Louvrier, B. Pereira, J. Caillet, C. Meyer, I. Barthélémy, A. Depeyre

► To cite this version:

R. Courtot, Laurent Devoize, A. Louvrier, B. Pereira, J. Caillet, et al.. Surgical approach of ectopic maxillary third molar avulsion: Systematic review and meta-analysis. *Journal of Stomatology, Oral and Maxillofacial Surgery*, 2021, 122 (1), pp.77-82. 10.1016/j.jormas.2020.06.015 . hal-03626164

HAL Id: hal-03626164

<https://hal.science/hal-03626164v1>

Submitted on 13 Feb 2023

HAL is a multi-disciplinary open access archive for the deposit and dissemination of scientific research documents, whether they are published or not. The documents may come from teaching and research institutions in France or abroad, or from public or private research centers.

L'archive ouverte pluridisciplinaire **HAL**, est destinée au dépôt et à la diffusion de documents scientifiques de niveau recherche, publiés ou non, émanant des établissements d'enseignement et de recherche français ou étrangers, des laboratoires publics ou privés.



Distributed under a Creative Commons Attribution - NonCommercial 4.0 International License

Surgical approach of ectopic maxillary third molar avulsion: systematic review and meta-analysis

List of authors

Romain Courtot ^{a, b} (MD), Laurent Devoize ^{a, c, d} (MD, PhD), Aurélien Louvrier ^{f, g, h} (MD, PhD student), Bruno Pereira ^e (PhD), Julia Caillet (MD) ^{a, b}, Christophe Meyer ^{f, g, i} (MD, PhD), Isabelle Barthélémy ^{a, b, d} (MD, PhD), **Arnaud Depeyre** ^{a, b, j, k, l} (MD, MsC, PhD student)

List of affiliations

^a Oral and Maxillofacial Department, Estaing Hospital, CHU Clermont-Ferrand, F-63003 Clermont-Ferrand, France

^b Université d'Auvergne, Faculty of Medicine, F- 63001, Clermont-Ferrand, France

^c Université d'Auvergne, Faculty of Dental Surgery, F-63100, Clermont-Ferrand, France

^d Inserm U1107 Neuro-Dol, Trigeminal Pain and Migraine, Faculty of Dental Surgery, F-63100 Clermont-Ferrand, France

^e Clermont-Ferrand, Biostatistics unit (clinical research and Innovation Direction), Clermont-Ferrand, France

^f Department of Oral and Maxillofacial Surgery, University Hospital of Besançon, Boulevard Fleming, 25030 Besançon Cedex, France.

^g University of Franche-Comté, Faculty of Medicine, 19 rue Ambroise Paré, 25000 Besançon, France.

^h University of Bourgogne Franche-Comté, INSERM, EFS BFC, UMR1098, Interactions Hôte-Greffon-Tumeur/Ingénierie Cellulaire et Génique, F-25000 Besançon, France.

ⁱ Nanomedicine Lab, Imagery and Therapeutics, EA 4662, Medical Faculty, University of Franche-Comté, 19 rue Ambroise Paré, 25000 Besançon, France.

^j Université d'Auvergne, Laboratoire CROC EA 3847, Faculty of Dental Surgery, F-63100, Clermont-Ferrand, France.

^k Univ. Lille, INSERM, CHU Lille, U1008 – Controlled Drug Delivery Systems and Biomaterials, F-59000 Lille, France

^l Cabinet Maxillo-Facial Privé de Saint-Etienne, Hôpital Privé de la Loire, Ramsay GDS, 39 Boulevard de la Palle, 42100 Saint Etienne, France

Corresponding author

Arnaud Depeyre MD, MsC. PhD student

Service de Chirurgie Maxillo-Faciale et Stomatologie, Hôpital Estaing, CHU Clermont-Ferrand, 1 Place Lucie Aubrac, 63003 Clermont-Ferrand Cedex 1, France

Phone : +33 473 750 102 ; Fax : +33 473 750 103

Cabinet Maxillo-Facial Privé de Saint-Etienne, Hôpital Privé de la Loire, 39 Boulevard de la Palle, F-42100, Saint Etienne, France

Phone : +33 477 330 778 ; e-mail : depeyrearnaud@gmail.fr

Word count : 1863

Abstract

Ectopic maxillary third molars (EMTM) are extracted mainly by the Caldwell-Luc technique but also by nasal endoscopy. There is currently no consensus on the treatment of this eruption and its management is heterogeneous and multidisciplinary.

Two literature searches were performed with no time restrictions via Pubmed. In the first, we used the keywords "ectopic AND third molar" and in the second the keywords "dentigerous cyst AND ectopic third molar". For both articles, epidemiological, symptomatic, radiological and surgical data were recorded.

Overall, 33 eligible articles were identified involving 39 cases of EMTM. 79% of patients were symptomatic. 87% of the teeth were associated with a dental cyst. In only 13% of cases was the location of the tooth in the sinus specified in the three planes of the space. Surgery was performed in 77% of patients by the Caldwell-Luc technique, by nasal endoscopy in 10% and by the Le Fort I approach in 3%.

The indications for avulsion of EMTM are symptomatic patients or asymptomatic patients with an associated cyst. The intra-sinusal location of the tooth is not a factor in the choice of technique used, which depends rather on the individual skills of the surgeon. Although for a trained operator the Le Fort I osteotomy is an easy procedure, its interest in the treatment of EMTM is limited owing to the rare but potentially severe complications involved.

Keywords: ectopic third molar, maxillary, wisdom tooth, dentigerous cyst, surgical approach, systematic review

1) Introduction

The first report of an ectopic maxillary third molar (EMTM) was made in 1952 by Isasi Garcia et al. (1). EMTMs account for 30% of all ectopic third molars

compared to 70% in the mandible, and affect twice as many men as women. In adults, they are most often responsible for clinical signs of infection such as pain, swelling and/or abscesses. In rare cases, they can also be unexpectedly discovered during routine radiological examination.

Until 1991 and the advent of endoscopic nasal surgery, surgical treatment was only performed by the Caldwell-Luc oral approach. Since 1991, these are the only two techniques cited in published case reports. Although techniques have evolved in recent years there is currently no consensus on the surgical treatment of patients with symptomatic EMTM, whose management is divided between ear, nose and throat (ENT) specialists and oral and maxillofacial surgeons (OMFS) depending on their specialty and work practices.

The main aim of this work was to identify the best surgical approach and technique according to the location of the EMTM. Surgical indications were also specified according to the clinical and paraclinical context.

2) **Materials and Methods**

The study was performed according to Prisma recommendations. Two literature searches without time restrictions were made via Pubmed. In the first, we used the keywords "ectopic AND third molar". Articles focusing on dental cysts were associated with EMTM. A second search was then conducted using the keywords "dentigerous cyst AND ectopic third molar". Inclusion criteria were human clinical use and English as the language of publication. For each selected article, the following data were extracted:

- type of study (case report or case series),

- sex and age,
- tooth number (18 or 28),
- symptoms,
- location of the EMTM:
 - o extra-sinusal,
 - o intra-sinusal using the three dimensions of the space to determine its accessibility,
- presence of an associated cyst,
- type of anesthesia,
- surgical approach,
- postoperative complications.

The statistical analyses, which were mainly descriptive, were performed with Stata software (version 13, StataCorp, College Station, US). Categorical data are presented as number of patients and percentages and continuous data (i.e. age of patients) as median and interquartile range (IQR).

3) **Results**

After removal of duplicates 206 articles were collected, of which 39 were selected. Abstracts unavailable online, those concerning animal experiments and pure research papers were excluded. Articles dealing with mandibular ETM or other ectopic teeth or related to benign tumors such as ameloblastoma of the jaws were also excluded. After a further reading, 6 articles that did not mention surgical treatment or approach were excluded thus leaving 33 eligible papers (please insert Figure 1), of

which 31 were case reports and 2 case series (please insert Table 1). In all, 39 cases of EMTM were analyzed.

All data are given in Table 2 (please insert Table 2). 22 teeth were 18, 17 were 28. There were 20 male and 13 female patients (3:2 ratio). The median age was 25 [19-37] years with a range from 14 to 78 years.

Clinically, 79% of the ETM cases were symptomatic. The three most frequent symptoms were swelling (57%), chronic infection manifesting as a purulent posterior or anterior nasal discharge (53%) and local pain (51%), followed by headache (18%) and a sensation of a feeling of heaviness in the sinus (15%).

In 33 patients a 3D examination was performed and in the other 6 only 2D X-ray. The location of the tooth in the sinus was specified in a tridimensional space in only 13% of patients compared to 67% in two dimensions of space and 20% in a single plane. A dentigerous cyst associated with the tooth was found in 87% of patients.

General anesthesia was performed in 36% of patients and local anesthesia in 28%. One (3%) patient had surgery under neuroleptanalgesia. In 33% of cases, the type of anesthesia was not specified.

For the surgical procedure, the Caldwell-Luc approach was used in 77% of cases and associated with trans-oral endoscopy in 10% of other cases. For the remaining patients, nasal endoscopy was performed alone in 10% while in 3% (1 patient) the Le Fort I osteotomy approach was used.

Finally, 97% of patients had no postoperative complications. The only reported postoperative incident (3%) was recurrence of a fistulated maxillary cyst in the oral cavity 6 months after a Caldwell-Luc procedure.

4) **Discussion**

There are currently two reliable surgical procedures for the treatment of EMTM, the Caldwell-Luc technique and nasal endoscopy. Indications for avulsion of EMTM are symptomatic patients or asymptomatic patients with an associated cyst.

The symptoms of EMTM are various but three are found in half of patients and lead to significant morbidity: local pain, swelling and anterior or posterior nasal discharge. This triad is characteristic of chronic infection of the ETM and/or the associated cyst. Other rare symptoms can occur, but with a worse prognosis, particularly in the event of orbital or cranial invasion, resulting in a decrease in intraocular hypertension, hyposmia, bleeding or empyema (2–4). The after-effects can be severe and lead to blindness (5). The presence of these symptoms requires urgent surgical care. The chronic evolution of a possible associated cyst represents also a surgical indication with a minimally invasive approach that is easy for a trained operator and can be performed under local anesthesia.

There is still debate about interventions for asymptomatic EMTM without an associated cyst (6). Regular clinical and radiological monitoring is required if no symptomatic or orthodontic arguments are found. There is no place for medical treatment alone.

The first case of EMTM was reported in 1952. Since then the number of publications has grown exponentially, up to the most recent, which dates from 2019. Much progress was made in imaging techniques over this period and the availability of 3D examinations greatly increased. From Waters radiography and profile radiographs with Lipiodol injection to CT scans, the quality of radiological diagnosis has improved

considerably (7). In recent years, 3D examinations such as Cone-Beam have made it possible to locate intra-sinus teeth in three spatial dimensions, a procedure that could not have been performed with 2D imaging.

The Caldwell-Luc technique, first described in 1893, is the classic surgical approach to the maxillary sinus. Since 1991 and the advent of endoscopy, the procedure can be performed in a less invasive and therefore less morbid way, especially when done transnasally. In all cases documented over more than a century the technique has been reported as successful. Le Fort I osteotomy for the sinus approach is invasive and unjustified for this isolated condition despite it being the preferred surgical procedure for dentoskeletal dysmorphia requiring associated maxillary orthognathic surgery, since avulsion of the ETM can be done at the same time.

Endoscopic lower meatotomy involves opening of the maxillary sinus via its lower ostium. The main intraoperative accidents are damage to the tear duct, and more seriously and rarely, hemorrhage or orbital gap, which can lead to blindness. From a functional point of view, the most damaging postoperative complications are intra-nasal synechiae. They are rare and can be treated secondarily (8).

Caldwell-Luc's procedure is a method of approaching the anterior wall of the maxillary sinus by the canine fossa. Frequently, postoperative edema and subcutaneous emphysema are present. The main complications are lesion of the infraorbital nerve, dental pain, bleeding and fistula formation (8).

According to Matheny K. et al. (9), most ENT professionals agree that the Caldwell-Luc approach is no longer a first-line technique for maxillary sinusitis but is considered in the event of failed nasal endoscopy. However, the morbidity of the

Caldwell-Luc technique depends much more on the surgeon's experience than on the procedure itself, mainly on protection of the infra-orbital nerve and visual control inside the sinus. For this reason, the use of an intraoral endoscope is an interesting option for any surgeon whose training does not include endonasal endoscopy. However, it is difficult to objectively compare the effectiveness of these two techniques because of biases related to the inter-individual variability of patients and practitioners.

K. Ikeda et al. (10) looked at criteria such as blood loss, duration of intervention and hospitalization, and were significantly in favor of nasal endoscopy techniques for the treatment of chronic sinusitis refractory to medical treatment. M. Närkiö-Mäkelä et al. (11) found a complication rate of 4.4% for hemorrhage or infection in 159 patients operated on by the Caldwell-Luc approach, compared to 2.6% for chronic dacryocystitis in 78 nasal endoscopies. The re-intervention rate was 5.9% for the Caldwell-Luc group and 22.5% for the nasal endoscopy group. This four-fold lower recurrence rate justifies the use of the Caldwell-Luc technique in preference to nasal endoscopy. The authors reported no major complications. However, their study also included patients treated for chronic sinusitis, which is not really comparable to cystic enucleation with tooth extraction.

Le Fort 1 osteotomy was first used in 1921. The procedure is performed to correct dento-skeletal anomalies and entails inherent and various risks (12). In their prospective study involving 1000 patients over a 9-year period, Kramer et al. (13) reported complications in 6.4% of patients of varying type and severity, which included anatomical complications such as septal deviation, pseudarthrosis, poor jaw repositioning, oral or nasal hemorrhages, septic complications such as mucosal or cerebral abscesses, ischemic complications such as gingival necrosis, otological

complications such as tubal dysfunction, and neurological complications such as oculomotor paralysis or blindness. For a trained operator, Le Fort I osteotomy is an easy procedure involving rare but potentially serious complications.

In one case (14), this approach was justified by the tooth position, the size of the associated cyst and the presence of a bone wall inside the sinus. Its value in the treatment of EMTM is limited in view of the morbidity of the technique. In similar cases, most authors use the Caldwell-Luc approach.

Only in 13% of the cases was the precise location of the tooth indicated in the three planes of the space. In 85% of the clinical cases, a CT scan was performed. We were therefore unable to statistically test the link between the location of the ETM and the surgical technique used. Among all the documented cases, the only complication recorded was a recurrence of the cyst associated with a fistula 6 months after surgery. It is noteworthy, however, that follow-up was mostly very short.

Despite the lack of data provided by the authors on anesthesia methods (33%), it emerges that 36% of patients were operated under general anesthesia, which, while comfortable for the patient and the surgeon holds significant risks. Of note, all patients operated under local anesthesia (28%) had the Caldwell-Luc approach. In contrast, nasal endoscopy requires general anesthesia.

Oral surgeons, maxillofacial surgeons and ENT specialists can all be involved in the management of EMTM. The intra-sinusal location of the tooth does not play a role in the choice of technique used, which is dictated more by the individual skills of each surgeon. Nasal endoscopy, when controlled by an appropriate technical platform, is possible by a trained operator, but the open approach of the Caldwell-Luc technique,

especially when associated with oral endoscopy, remains the gold standard surgical approach.

Disclosure of interest

The authors declare that they have no competing interest.

References

1. Isasi Garcia A, Campmajo Tornabell A. Maxillary sinusitis due to ectopic wisdom tooth. *Acta Otorinolaryngol Iber Am.* 1952;3(4):197-201.
2. Hasbini AS, Hadi U, Ghafari J. Endoscopic removal of an ectopic third molar obstructing the osteomeatal complex. *Ear Nose Throat J.* sept 2001;80(9):667-70.
3. Sivolella S, Ricci S, Busca M, Stellini E, Valente M. Maxillary dentigerous cyst associated with an ectopic third molar in the maxillary sinus: a literature review and report of six consecutive cases. *Oral Surg.* 2014;7(S1):72-8.
4. Kara MI, Yanik S, Altan A, Oznalcin O, Ay S. Large dentigerous cyst in the maxillary sinus leading to diplopia and nasal obstruction: case report. *J Istanbul Univ Fac Dent.* 2015;49(2):46-50.
5. Savundranayagam A. A migratory third molar erupting into the lower border of orbit causing blindness in the left eye. *Aust Dent J.* déc 1972;17(6):418-20.
6. Viterbo S, Griffa A, Boffano P. Endoscopic removal of an ectopic tooth in maxillary sinus. *J Craniofac Surg.* janv 2013;24(1):e46-48.
7. Crolius WE. Dentigerous cyst with an aberrant third molar in the maxillary sinus. *Oral Surg Oral Med Oral Pathol.* janv 1958;11(1):31-3.
8. Delbet C, Barthélémy I, Teitelbaum J, Devoize L. Mycoses aspergillaires des sinus maxillaires. *EMC (Elsevier Masson SAS, Paris), Médecine buccale,* 28-275-1-10, 2011.
9. Matheny KE, Duncavage JA. Contemporary indications for the Caldwell-Luc procedure. *Curr Opin Otolaryngol Head Neck Surg.* févr 2003;11(1):23-6.
10. Ikeda K, Hirano K, Oshima T, Shimomura A, Suzuki H, Sunose H, et al. Comparison

of complications between endoscopic sinus surgery and Caldwell-Luc operation. *Tohoku J Exp Med.* sept 1996;180(1):27-31.

11. Närkiö-Mäkelä M, Qvarnberg Y. Endoscopic sinus surgery or Caldwell-Luc operation in the treatment of chronic and recurrent maxillary sinusitis. *Acta Oto-Laryngol Suppl.* 1997;529:177-80.

12. Buchanan EP, Hyman CH. LeFort I Osteotomy. *Semin Plast Surg.* août 2013;27(3):149-54.

13. Kramer F-J, Baethge C, Swennen G, Teltzrow T, Schulze A, Berten J, et al. Intra- and perioperative complications of the LeFort I osteotomy: a prospective evaluation of 1000 patients. *J Craniofac Surg.* nov 2004;15(6):971-979.

14. Massereau E-A, Revol P, Chossegros C-M, Romeu M, Caquant L. Dent de sagesse ectopique intrasinusienne : voie d'abord par ostéotomie de Le Fort I. *Médecine Buccale Chir Buccale.* 1 avr 2015;21(2):109-13.

15. Thakur G, Nair PP, Thomas S, Ahuja R, Kothari R. Dentigerous cyst associated with ectopic maxillary third molar in maxillary antrum. *BMJ Case Rep.* 12 mai 2011;2011.

16. Buyukkurt MC, Omezli MM, Miloglu O. Dentigerous cyst associated with an ectopic tooth in the maxillary sinus: a report of 3 cases and review of the literature. *Oral Surg Oral Med Oral Pathol Oral Radiol Endod.* janv 2010;109(1):67-71.

17. Bello SA, Oketade IO, Osunde OD. Ectopic 3rd molar tooth in the maxillary antrum. *Case Rep Dent.* 2014;2014:620741.

18. Demirtas N, Kazancioglu HO, Ezirganli S. Ectopic tooth in the maxillary sinus diagnosed with an ophthalmic complication. *J Craniofac Surg.* juill 2014;25(4):e351-352.

19. Kasat VO, Karjodkar FR, Laddha RS. Dentigerous cyst associated with an ectopic

third molar in the maxillary sinus: A case report and review of literature. *Contemp Clin Dent.* juill 2012;3(3):373-6.

20. Mohan S, Kankariya H, Harjani B, Sharma H. Ectopic third molar in the maxillary sinus. *Natl J Maxillofac Surg.* juill 2011;2(2):222-4.

21. Guruprasad Y, Chauhan DS, Kura U. Infected dentigerous cyst of maxillary sinus arising from an ectopic third molar. *J Clin Imaging Sci.* 2013;3(Suppl 1):7.

22. N S M, Krishnamoorthy B, J K S, Bhai P. Diagnostic CBCT in dentigerous cyst with ectopic third molar in the maxillary sinus-A case report. *J Clin Diagn Res JCDR.* juin 2014;8(6):ZD07-09.

23. Kumar A, Srivastava RK, Saxena A, Khanna R, Ali I. Removal of infected maxillary third molar from the infra-temporal fossa by Caldwell Luc procedure - Rare case report with literature review. *J Clin Diagn Res JCDR.* déc 2016;10(12):ZD01-3.

24. Rai A, Rai NJ, Rai MA, Jain G. Transoral removal of ectopic maxillary third molar situated superiorly to maxillary antrum and posteroinferiorly to the floor of orbit. *Indian J Dent Res Off Publ Indian Soc Dent Res.* déc 2013;24(6):756-8.

25. Mermoud M, Broome M, Hoarau R, Zweifel D. Facial pain associated with CPAP use: Intra-sinus third molar. Case report *Otolaryngol.* 2014;2014:837252.

26. Asnani S, Mahindra U, Rudagi BM, Kini Y, Kharkar VR. Dentigerous cyst with an impacted third molar obliterating complete maxillary sinus. *Indian J Dent Res Off Publ Indian Soc Dent Res.* déc 2012;23(6):833-5.

27. Srinivasa Prasad T, Sujatha G, Niazi TM, Rajesh P. Dentigerous cyst associated with an ectopic third molar in the maxillary sinus: a rare entity. *Indian J Dent Res Off Publ Indian Soc Dent Res.* sept 2007;18(3):141-3.

28. Büyükkurt MC, Tozoglu S, Aras MH, Yolcu U. Ectopic eruption of a maxillary third molar tooth in the maxillary sinus: a case report. *J Contemp Dent Pract.* 15 août 2005;6(3):104-10.
29. Emanuelli E, Borsetto D, Brunello G, Sivolella S. Endoscopy-assisted removal through combined lower and middle meatotomies of an ectopic upper third molar in the sinus associated with a dentigerous cyst. *Oral Maxillofac Surg Cases.* 1 mars 2018;4(1):23-31.
30. Misiewicz RF, Petros GJ. Ectopically displaced third molar tooth. *Oral Surg Oral Med Oral Pathol.* déc 1971;32(6):996.
31. Meara JG, Brown MT, Caradonna D, Varvares MA. Massive, destructive, dentigerous cyst: A case report. *Otolaryngol--Head Neck Surg Off J Am Acad Otolaryngol-Head Neck Surg.* juill 1996;115(1):141-4.
32. Marini E. Treatment of giant maxillary dentigerous cyst and ectopic third molar with piezoelectric surgery. *Italian Journal of Dental Medicine.* Vol 2/4-2017:131-136
33. Kayabasoglu G, Karaman M, Kaymaz R, Nacar A. A Rare Entity Causing Chronic Snusitis: Ectopic Tooth in Maxillary Sinus. *Electron J Gen Med.* 7 janv 2015;12(1):86-9.
34. Abdollahifakhim S, Mousaviagdas M. Ectopic molar with maxillary sinus drainage obstruction and oroantral fistula. *Iran J Otorhinolaryngol.* juin 2013;25(72):187-92.
35. Chuong R. Dentigerous cyst involving maxillary sinus: report of case. *J Am Dent Assoc* 1939. juill 1984;109(1):59-60.
36. Golden AL, Foote J, Lally E, Beideman R, Tatoian J. Dentigerous cyst of the maxillary sinus causing elevation of the orbital floor. Report of a case. *Oral Surg Oral Med Oral Pathol.* août 1981;52(2):133-6.
37. Sinha A, Mishra A, Anusha, Sinha PM. Ectopic third molar in maxillary sinus: A rare

case report J Indian Acad Oral Med Radiol 2017;29:341-4

38. Funderburg JC. Endoscopic extraction of an ectopic third molar. Mil Med. août 1992;157(8):431-2.
39. Di Pasquale P, Shermetaro C. Endoscopic removal of a dentigerous cyst producing unilateral maxillary sinus opacification on computed tomography. Ear Nose Throat J. nov 2006;85(11):747-8.
40. Lamb JF, Husein OF, Spiess AC. Ectopic molar in the maxillary sinus precipitating a mucocele: a case report and literature review. Ear Nose Throat J. août 2009;88(8):E6-11.
41. Micozkadioglu SD, Erkan AN. Endoscopic removal of a maxillary dentigerous cyst. B-ENT. 2007;3(4):213-6.

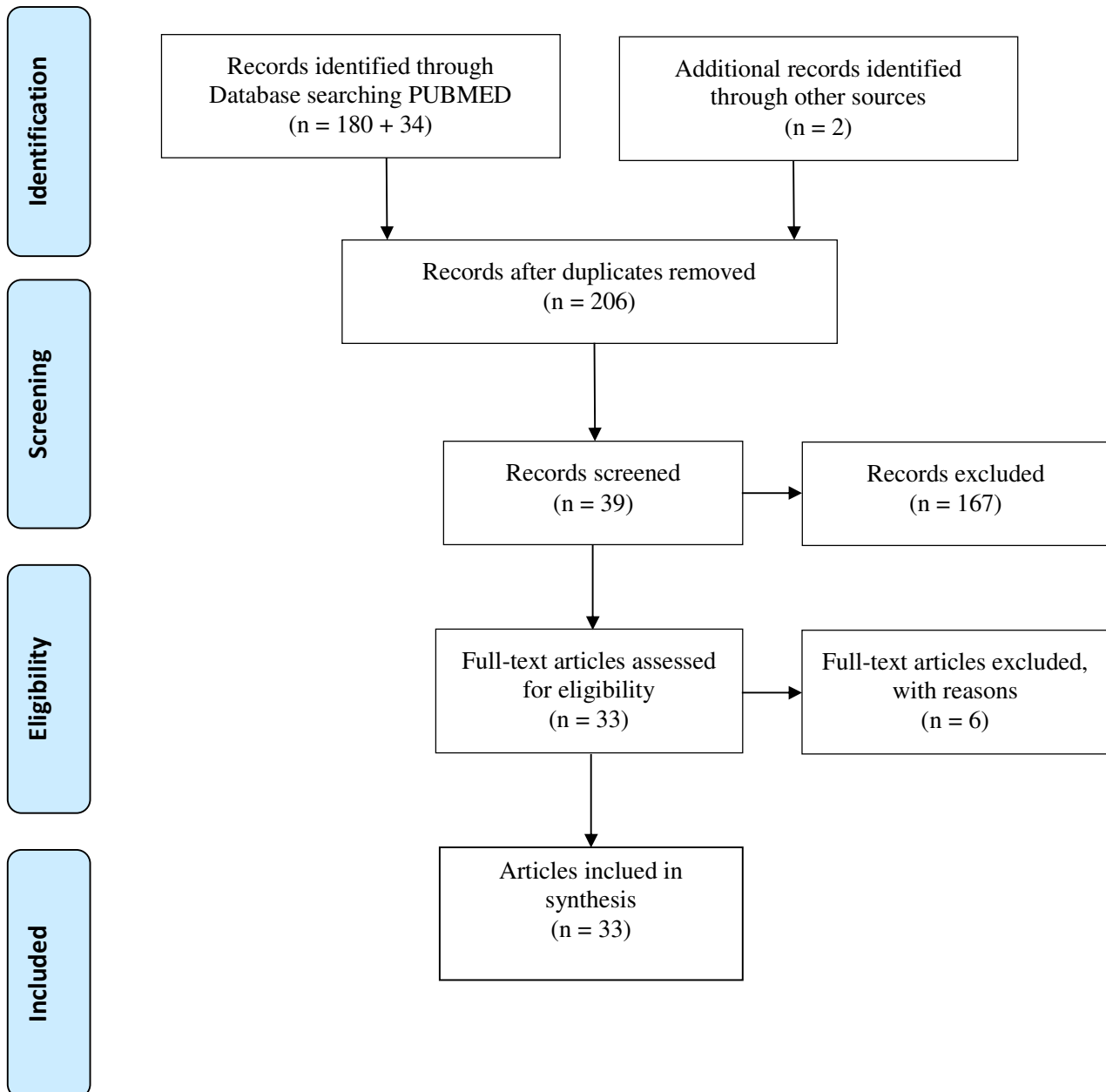
Figure Captions

Figure 1: Flow Chart Diagram (PRISMA)

Table 1: Data extracted from articles

Table 2: Main results

PRISMA Flow Diagram



From: Moher D, Liberati A, Tetzlaff J, Altman DG, The PRISMA Group (2009). Preferred Reporting Items for Systematic Reviews and Meta-Analyses: The PRISMA Statement. PLoS Med 6(7): e1000097. doi:10.1371/journal.pmed1000097

For more information, visit www.prisma-statement.org.

Title	Type of study	Sex/age	Teeth	Symptoms	Imaging/Cyst	Extraction method	Complications
Thakur et al. [1]	Case Report	Man (M) 25 Years Old (YO)	28	Infection Cough Local pain	Floor Cyst	Local anaesthesia (AL) + Caldwell-Luc (CL)	No
Massereau et al. [2]	Case Report	M 26 YO	18	Swelling Infection	Posterior Roof	General anaesthesia (AG) + Le Fort I Osteotomy	No
Buyukkurt et al. [3]	Case Series	Woman (W) 19 YO M 30 YO	28	Swelling	1) Roof + medial + cyst 2) Floor + posterior + lateral + cyst	AL + CL	No
Seidu et al. [4]	Case Report	M 17 YO	18	Swelling Local pain Infection	Posterior Lateral	AG + CL	No
Demirtas et al. [5]	Case Report	M 19 YO	18	Local pain Feeling of fullness Blurred vision	Roof Medial Cyst	CL	No
Kasat et al. [6]	Case Report	M 22 YO	18	Infection Swelling	Posterior Roof Cyst	CL	No
Mohan et al. [7]	Case Report	W 28 YO	28	Infection Swelling Pain	Superior Medial Cyst	Sédation + CL	No
Guruprasad et al. [8]	Case Report	W 21 YO	18	Swelling Infection	Floor Lateral Cyst	AG + CL	No

Mamatha et al. [9]	Case Report	M 17 YO	28	Infection Local pain Swelling	Roof Lateral Medial Cyst	AG + CL	No
Kumar et al. [10]	Case Report	M 22 YO	28	Feeling of fullness Headache Local pain	Posterior Lateral Cyst	AG +CL	No
Rai et al. [11]	Case Report	W 46 YO	28	Pain Swelling Watering from the left eye	Roof Posterior Cyst	AG + CL	No
Viterbo et al. [12]	Case Report	M 29 YO	18	No	Roof Posterior	AG + CL	No
Mermod et al. [13]	Case Report	M 74 YO	28	Local pain	Floor Posterior Lateral	AL + CL	No
Asnani et al. [14]	Case Report	W 28 YO	18	Swelling Infection Headache	Roof Medial Cyst	AG + CL	No
Srinivasa et al. [15]	Case Report	M 45 YO	18	Infection Pain Swelling	Anterior Superior	AG + CL	No
Hasbini et al. [16]	Case Report	M 21 YO	28	Nasal obstruction Facial fullness Hyposmia Headaches	Anterior Roof Medial Cyst	Nasal endoscopy	No
Büyükkurt et al. [17]	Case Report	M 31 YO	28	Headache Infection	Cyst Medial	AL + CL	No
Emanuelli et al. [18]	Case Report	M 40 YO	28	Infection Swelling	Medial Floor Cyst	Nasal endoscopy + AG	No
William et al. [19]	Case Report	M 19 YO	18	Swelling	Roof	CL	No
Robert et al. [20]	Case Report	M 17 YO	18	Local pain	Superior Medial	CL	No

Sivolella et al. [21]	Case Series	3 M 3 W 14-65 YO	4*18 2*28	5 asymptomatic 1 Infection (empyema)	28: Roof + lateral, Floor + lateral 18: Floor + lateral Cyst	AL + CL	No
Meara et al. [22]	Case Report	M 78 YO	18	Swelling Feeling of fullness Infection Bleeding	Posterior Lateral Floor Cyst	CL	6 months, a recurrence of the oroantral fistula and cyst
Marini et al. [23]	Case Report	W 40 YO	18	Swelling Infection Temporomandibular Arthralgia Trismus Headache	Posterior Roof Cyst	AG + CL	No
Kayabasoglu et al. [24]	Case Report	W 46 YO	18	Nasal obstruction Infection Local pain	Floor Cyst	AG + CL + Endoscopy	No
Abdollahifakhim et al. [25]	Case Report	M 17 YO	18	Infection Feeling of fullness Halitosis Posterior nasal discharge Local pain Swelling	Roof Medial Cyst	CL + Endoscopy	No
Chuong et al. [26]	Case Report	M 16 YO	28	Halitosis	Medial Posterior Cyst	CL	No
Golden et al. [27]	Case Report	W 37 YO	28	Local pain Infection	Roof Medial Cyst	AG + CL	No
Sinha et al. [28]	Case Report	W 25 YO	18	Local pain Swelling	Anterior Roof Cyst	CL	No

Kara et al. [29]	Case Report	W 16 YO	18	Local pain Swelling Nasal obstruction Intraocular hyperpressure	Roof Cyst	AG + CL	No
Funderburg et al. [30]	Case Report	W 18 YO	28	Local pain Infection	Posterior	CL + Endoscopy	No
Di Pasquale et al. [31]	Case Report	W 14 YO	28	No	Cyst Medial	Nasal Endoscopy	No
Lamb et al. [32]	Case Report	M 41 YO	18	No	Anterior Medial Cyst	CL	No
Micozkadioglu et al. [33]	Case Report	W 24 YO	18	Headache Local pain Swelling	Cyst Floor	Nasal Endoscopy	No

Table 1: Data extracted from articles

DATA	RESULTS n (%)
Demographics	
<i>Sex H/F</i>	20 (61%) / 13 (39%)
<i>Median age</i>	25
Clinics and paraclinics	
Teeth	
18	22 (56%)
28	17 (44%)
Clinicals signs	
<i>Local pain</i>	17 (52%)
<i>Swelling</i>	19 (58%)
<i>Infection</i>	18 (53%)
Radiological localisation	
<i>3 dimensions (3D)</i>	5 (13%)
<i>2D</i>	26 (67%)
<i>1D</i>	8 (20%)
Cyst	34 (87%)
Surgicals	
Anaesthesia	
<i>Local</i>	11 (28%)
<i>General</i>	15 (28%)
<i>Neuroleptanalgesia</i>	1 (3%)
<i>Unknown</i>	12 (33%)
Surgical approach	
<i>Caldwell-Luc</i>	30 (77%)
<i>Caldwell-Luc with trans-oral endoscopy</i>	4 (10%)
<i>Nasal Endoscopy</i>	4 (10%)
<i>Le Fort I osteotomy</i>	1 (3%)
Complications	1 (3%)

Table 2: Main results