



**HAL**  
open science

## A proof-of-concept augmented reality system in oral and maxillofacial surgery

Nathalie Pham Dang, Kilian Chandelon, Isabelle Barthélémy, Laurent Devoize, Adrien Bartoli

### ► To cite this version:

Nathalie Pham Dang, Kilian Chandelon, Isabelle Barthélémy, Laurent Devoize, Adrien Bartoli. A proof-of-concept augmented reality system in oral and maxillofacial surgery. *Journal of Stomatology, Oral and Maxillofacial Surgery*, 2021, 122 (4), pp.338-342. 10.1016/j.jormas.2021.05.012 . hal-03626159

**HAL Id: hal-03626159**

**<https://hal.science/hal-03626159>**

Submitted on 16 Oct 2023

**HAL** is a multi-disciplinary open access archive for the deposit and dissemination of scientific research documents, whether they are published or not. The documents may come from teaching and research institutions in France or abroad, or from public or private research centers.

L'archive ouverte pluridisciplinaire **HAL**, est destinée au dépôt et à la diffusion de documents scientifiques de niveau recherche, publiés ou non, émanant des établissements d'enseignement et de recherche français ou étrangers, des laboratoires publics ou privés.



Distributed under a Creative Commons Attribution - NonCommercial 4.0 International License

## TITLE PAGE

A proof-of-concept augmented reality system in oral and maxillofacial surgery.

Authors list: Nathalie Pham Dang 1,2,3, M.D., PhD, Professor, Kilian Chandelon 2,

Isabelle Barthélémy<sup>1,3</sup> MD, PhD, Professor, Department Head, Laurent Devoize 3,4 D.D.S.,  
Ph.D., Professor, Department Head

Adrien Bartoli 2 PhD, Professor, Department Head.

1 Department of Oral and Maxillofacial surgery, NHE – CHU de Clermont-Ferrand,  
Université d’Auvergne, Clermont-Ferrand, 63003, France.

2 CNRS EnCov

3UMR Inserm/UdA, U1107, Neuro-Dol, Trigeminal Pain and Migraine, Université  
d’Auvergne, Clermont-Ferrand, 63003, France.

4 Department of Odontology, CHU de Clermont-Ferrand, Université d’Auvergne, Clermont-  
Ferrand, 63003, France.

Correspondance: Nathalie PHAM DANG, M.D., Ph.D.

Department of Oral and Maxillofacial surgery, Université d’Auvergne, NHE – CHU de  
Clermont-Ferrand, 1 place Lucie Aubrac, 63000 Clermont-Ferrand, France.

Phone: +33473750102, Fax: +33473750103

E-mail: [nphamdang@chu-clermontferrand.fr](mailto:nphamdang@chu-clermontferrand.fr)

Abstract count: 208

Word counts: 2151

Figure counts: 5

Reference counts: 21

### **Keywords**

Maxillofacial surgery; Augmented reality; Computer-assisted surgery; Dental; Jaw cyst.

**Knowledge Transfer Statement:** The results of this study can be used by clinicians when deciding which approach they wish to use when planning placement of mini-dental implants in an individual's edentulous mandible. With consideration of cost and patient preference, this information could lead to more appropriate therapeutic decisions

## **A proof-of-concept augmented reality system in oral and maxillofacial surgery.**

### **Abstract**

Background: The advent of digital medical imaging, medical image analysis and computer vision has opened the surgeon horizons with the possibility to add virtual information to the real operative field. For oral and maxillofacial surgeons, overlaying anatomical structures to protect (such as teeth, sinus floors, inferior and superior alveolar nerves) or to remove (such as cysts, tumours, impacted teeth) presents a real clinical interest.

Material and methods: Through this work, we propose a proof-of-concept markerless augmented reality system for oral and maxillofacial surgery, where a virtual scene is generated preoperatively and mixed with reality to reveal the location of hidden anatomical structures intraoperatively. We devised a computer software to process still video frames of the operating field and to display them on the operating room screens.

Results: Firstly, we give a description of the proposed system, where virtuality aligns with reality without artificial markers. The dental occlusion plan analysis and cusps detection allow us to initialise the alignment process. Secondly, we validate the feasibility with an experimental approach on a 3D printed jaw phantom and an ex-vivo pig jaw. Thirdly, we evaluate the potential clinical benefit on a patient.

Conclusion: this proof-of-concept highlights the feasibility and the interest of augmented reality for hidden anatomical structures visualisation without artificial markers.

### **Keywords**

Maxillofacial surgery; Augmented reality; Computer-assisted surgery; Dental; Jaw cyst.

## **Introduction**

Oral and maxillofacial surgery concerns both tumoral, functional and aesthetic disorders. In all these situations noble structures (including the teeth, nerves and bones) must be protected to ensure a functional and aesthetic result. Virtual Reality (VR) and planification based on 3D virtual models are a good technical assistance to improve quality and rapidity of the surgery. Yet, in practice, it is not enough [1]. Projection of anatomical structures and tumours in real time on the patient would be a very helpful assistance. Augmented Reality (AR) is thus a promising approach. Over the past ten years, the technology has emerged in the field of medicine for medical education, surgical training and surgical interventions [2].

From a general perspective, implementing AR requires three key elements: 1) a camera to film the surgical site, 2) a method to solve the virtual-to-real alignment problem and 3) a means to display the AR results to the surgical team. In endoscopic surgery, one already has a camera and a screen in place, and only the alignment problem is to be solved, as shown in the existing endoscopic AR solutions [3,4]. In contrast, in oral and maxillofacial surgery, the operative field has to be adapted to add a camera and a screen. Existing methods use artificial markers to align the virtual 3D model reconstructed from CT with intraoral images [5–7] and anatomical landmarks to perform surgical navigation [6,8,9]. Some other methods use stereoscopic video analysis [10,11] to achieve intraoperative 3D surface reconstruction, replacing the markers by surface curvature analysis [6,12–15]. These methods require very accurate 3D models and often fail owing to the limited quality offered by the current stereoscopic 3D reconstruction technology.

We propose a novel proof-of-concept AR system for bony head and neck parts. The system can use a CT scan and/or an 3D intraoral scan (IOS) as preoperative data. Our proposed alignment method has been developed without the need for fiducial markers. Specifically, it uses the dental cusps as anatomical landmarks to align the preoperative virtual 3D model to

the intraoperative camera image. Concretely, our system provides visual augmentations on a still image of the operating field, as and when requested by the surgeon, assisting them in visualising hidden anatomical structures such as tumours, nerves and tooth roots. A software with Graphical User Interface was developed as well. We then performed trials to study the technical feasibility and clinical interest of AR guidance in oral and maxillofacial surgery.

## **Materials and Methods**

We propose a five steps workflow (fig.1), which resolves five identified technical issues. The output of the workflow is the camera image overlaid with visual augmentations.

### **Step 1: creating the virtual preoperative 3D model of the patient's oral anatomy**

Preoperatively, a CT scan or a cone-beam was performed. In order to have well detailed dental cusps and patient occlusion, an intraoral 3D scan is secondly undertaken.

The 3D intraoral mesh and the bone reconstruction obtained from the CT scan were fused to generate a detailed preoperative 3D model using a rigid transformation between the two-point clouds and a semi-automatic alignment done. First, an initial transformation matrix was manually obtained. Second, the Iterative Closest Point (ICP) algorithm is run to refine the transformation by automatically minimising the quadratic distance between the two-point clouds [16]. The segmentation of the relevant anatomical structure is then made during surgical planning with the open-source software 3D Slicer.

### **Step 2: intraoperative video acquisition and camera calibration**

We suspend a Nikon DSLR camera protected by a sterile drape to a ceiling arm above the patient head. Only the camera lens was out of the drape. This simple setup respects the aseptic conditions of the operating room and limits the footprint.

Camera calibration consists in determining the parameters of the mathematical relation which relates the coordinates of a point in the 3D real environment and its coordinates in the intraoperative 2D image. We have used the open-source computer vision library OpenCV [17]. It contains an implementation of the ChAruCo pattern and of the calibration method by Zhang [18]. In this method, the key idea is to take photos of the ChAruCo calibration pattern and after processing, the camera parameters modelling the relationship between the real 3D world and the camera image are determined.

### **Step 3: landmarks extraction**

We propose to use dental cusps as natural landmarks to solve the alignment problem in maxillofacial surgery. Teeth are rigidly linked to the mandible and the maxillary, follow the mandible mobilisation and the spee curve has a three-dimensional disposition. The system implementation allows one to manually mark at least 6 dental cusps on the preoperative model and then on the intraoperative image by clicking them in pairs.

### **Step 4: pose estimation**

Pose estimation consists in finding a rigid transformation mapping points from the preoperative 3D model to the camera. This transformation represents the sought alignment. Pose can be estimated from corresponding point-pairs, which in our system are the dental cusps of step 3. At least three point-pairs are needed to perform pose estimation but more stable results are obtained when more are used. Concretely, we use an algorithm named PnP (Perspective-n-Points), whose inputs are n 3D-2D point-pairs and output is the sought pose,

consisting of a 3D rotation and translation. We use the OpenCV implementation of PnP (OpenCV).

### **Step 5: augmented reality rendering**

We render the augmented reality by making visible the preoperative 3D model overlay on the real intraoperative 2D camera view. Taking into account the pose estimate, the points of the preoperative 3D virtual model are projected to the image plane by perspective projection, which is assembled from the camera calibration and alignment parameters of steps 2 and 4. Concretely, we used OpenCV to implement this step.

### **Experimental graphical user interface**

To make the workflow usable for a surgeon a GUI (Graphical User Interface) was developed by using graphical components from the open-source libraries Qt, OpenCV and VTK (Visualization Tool Kit). The user imports the planification model, calibrates the camera, labels the dental cusps and then runs the process to generate the visual augmentation (fig. 2)

## **Results**

We carried out several experiments on three types of models: phantom, animal and human.

### **First model: phantom mandible model**

A maxillo-mandibular 3D ABS (Acrylonitrile Butadiene Styrene) printed model extracted from a patient CT scan slices serves as phantom. The model is monochromatic, well-lit and motionless. It allows us to test pose estimation and virtual rendering. AR makes it possible to identify the inferior alveolar nerve path on the mandible. After manually mark 8 point of



interest on the preoperative model, the nerve trajectory projected on the phantom successfully starts from the mandibular foramen to the mental foramen (fig. 3).

### **Second model: ex-vivo porcine head model**

For a greater realism, an ex-vivo pig head model was scanned with a Siemens SOMATOM Definition AS machine, following the conventional radiology protocol to perform bone segmentation. The model was placed and illuminated by an operative room lighting system. We used 7 pig dental cusps to serve as landmarks. This more realistic situation creates a compelling test case. Indeed, tissues of various colours and consistency are always present on the bone parts, which generates dimensional and colorimetric differences compared to the preoperative model. We chose the inferior alveolar foramina as the anatomic points to highlight with AR. Two mental foramina were precisely augmented. One foramen was well identified and the second was in contact with the nerve emergence (fig. 4).

### **Third model: real clinical conditions experiments**

To complete the experimental part, we decided to test on a patient with a maxillary cyst in contact with the root of tooth 23. In this case, the surgery was not planned using AR but we carried out offline postoperative tests. The operative room was organised with the calibrated camera above the surgical field and a screen to render AR. We planned the maxillary cyst location and checked whether the drilled surgical bone merged with the planning. Intraoperative views were augmented with the planification model. The 2D and 3D occlusal lines correspond and the preoperative planification model overlays the hole performed by the surgeon to extract the cyst. AR in this situation was considered precise enough to align dental cusps and to adapt the 2D projection on the natural curvature of the dental arch (fig. 5). The

highlighted area of interest is larger than the bone removed by the surgeon because it includes all the cyst observed on the CT scan slices.

## **Discussion**

Throughout this work we present an AR proof-of-concept system for oral and maxillofacial surgery. In this project, AR screen rendering and markerless alignment methods were the two main elements.

Some AR projects use smart glasses to display visual augmentations [19,20]. In our situation and as agreed with surgeons we retained AR screen rendering for the three following reasons: 1- smart glasses are heavy and bulky, the surgeon comfort could be altered, especially as they need AR during a short surgery time; 2- with glasses, AR is only reserved for the device wearer, whereas in our system the information can be projected on several operative room screens; 3- glasses are closed to the operative field and could be poorly affected by projections. Even though smart glasses have great interest we decided to preserve surgeon's comfort and medical team information sharing by using screens.

Markerless alignment methods are a real challenge but are clinically interesting [13]. They do not require external devices to perform alignment tasks and do not need special surgical equipment. As the patient is the alignment device, it is not necessary to regularly check the accuracy of the alignment. The weak aspect of using the dental cusps is that it cannot be used with toothless patients.

The quality of the results was clinically objectivated according to oral and maxillofacial surgeons. But a quantitative evaluation will have to be performed in order to determine precisely the system's metrological characteristics and improve the software.

At this stage, other improvements can be made. Preoperative model generation could be assisted by deep learning to save operator time during CT scan segmentation stages.

Landmark detection is manually performed but if automated it could display visual augmentations in real time and not only on still frames. For now, the surgeon has to take a small amount of time in order to capture a picture and analyse it.

To improve this work, we will include more patients to repeat what we performed with the third model and establish performance statistics.

## **Conclusion**

AR is increasingly present in the operating room. For oral and maxillofacial surgery, this is only the beginning. At this work stage, our proof-of-concept system made it possible to highlight the clinical gain and technical feasibility. But there are many prospects for improvement in order to make the system usable in routine procedures and compliant with regulatory requirements. The major points for future development are the automatic detection of the anatomical landmarks (the dental cusps) to enable AR on live video, the improvement of visual augmentation rendering, the quantification of AR precision and the inclusion of additional patients to extend the feasibility results of our clinical model.

**Acknowledgments:** Acknowledgments to EMERGENCE CAP 20-25 for their support.

Author's contribution:

Nathalie Pham Dang: Contributed to conception, design, data acquisition, analysis and interpretation, drafted and critically revised the manuscript and gave final approval.

Kilian Chandelon: Contributed to conception and design, contribute to data acquisition, analysis and interpretation, draft the manuscript, critically revised the manuscript, gave final approval.

Isabelle Barthélémy: Contributed to design and interpretation, drafted the manuscript, critically revised the manuscript and gave final approval.

Laurent Devoize: Contributed to conception and design, contribute to data acquisition, analysis and interpretation, draft the manuscript, critically revised the manuscript and gave final approval.

Adrien Bartoli: Contributed to conception and design, contribute to data acquisition, analysis and interpretation, draft the manuscript, critically revised the manuscript and gave final approval.

All authors gave their final approval and agree to be accountable for all aspects of the work

**Declaration of Conflicting Interests:**

The Authors declare that there is no conflict of interest

## References

1. Ayoub A, Pulijala Y. The application of virtual reality and augmented reality in Oral & Maxillofacial Surgery. *BMC Oral Health*. 2019;8;19(1):238.
2. Kwon H-B, Park Y-S, Han J-S. Augmented reality in dentistry: a current perspective. *Acta Odontol Scand*. 2018;76(7):497–503.
3. Collins T, Pizarro D, Gasparini S, Bourdel N, Chauvet P, Canis M, et al. Augmented Reality Guided Laparoscopic Surgery of the Uterus. *IEEE Trans Med Imaging*. 2021;40(1):371–80.
4. Quero G, Lapergola A, Soler L, Shahbaz M, Hostettler A, Collins T, et al. Virtual and Augmented Reality in Oncologic Liver Surgery. *Surg Oncol Clin N Am*. 2019;28(1):31–44.
5. Zhang W, Wang X, Zhang J, Shen G. Application of preoperative registration and automatic tracking technique for image-guided maxillofacial surgery. *Comput Assist Surg (Abingdon)*. 2016;21(1):137–42.
6. Metzger MC, Rafii A, Holhweg-Majert B, Pham AM, Strong B. Comparison of 4 registration strategies for computer-aided maxillofacial surgery. *Otolaryngol Head Neck Surg*. 2007;137(1):93–9.
7. Zhu M, Liu F, Chai G, Pan JJ, Jiang T, Lin L, et al. A novel augmented reality system for displaying inferior alveolar nerve bundles in maxillofacial surgery. *Sci Rep*. 2017;15;7:42365.
8. Kang S-H, Kim M-K, Kim J-H, Park H-K, Park W. Marker-free registration for the accurate integration of CT images and the subject's anatomy during navigation surgery of the maxillary sinus. *Dentomaxillofac Radiol*. 2012;41(8):679–85.

9. Pepe A, Trotta GF, Mohr-Ziak P, Gsaxner C, Wallner J, Bevilacqua V, et al. A Marker-Less Registration Approach for Mixed Reality-Aided Maxillofacial Surgery: a Pilot Evaluation. *J Digit Imaging*. 2019;32(6):1008–18.
10. Suenaga H, Tran HH, Liao H, Masamune K, Dohi T, Hoshi K, et al. Vision-based markerless registration using stereo vision and an augmented reality surgical navigation system: a pilot study. *BMC Med Imaging*. 2015;15:51.
11. Wang J, Shen Y, Yang S. A practical marker-less image registration method for augmented reality oral and maxillofacial surgery. *Int J Comput Assist Radiol Surg*. 2019;14(5):763–73.
12. Kilgus T, Heim E, Haase S, Prüfer S, Müller M, Seitel A, et al. Mobile markerless augmented reality and its application in forensic medicine. *Int J Comput Assist Radiol Surg*. 2015;10(5):573–86.
13. Wang J, Suenaga H, Yang L, Kobayashi E, Sakuma I. Video see-through augmented reality for oral and maxillofacial surgery. *Int J Med Robot*. 2017;13(2).
14. Kim BC, Lee CE, Park W, Kang SH, Zhengguo P, Yi CK, et al. Integration accuracy of digital dental models and 3-dimensional computerized tomography images by sequential point- and surface-based markerless registration. *Oral Surg Oral Med Oral Pathol Oral Radiol Endod*. 2010;110(3):370–8.
15. Destrez R, Albouy-Kissi B, Treuillet S, Lucas Y. Automatic registration of 3D dental mesh based on photographs of patient's mouth. *Comput Methods Biomech Biomed Eng Imaging Vis*. 2019;7(5–6):604–15.
16. Besl PJ, McKay ND. Method for registration of 3-D shapes. In: *Sensor fusion IV: control paradigms and data structures*. International Society for Optics and Photonics; 1992. p. 586–606.
17. OpenCV. Open Source Computer Vision Library. 2015.

18. Zhang Z. A flexible new technique for camera calibration. *IEEE Trans Pattern Anal Machine Intell.* 2000;22(11):1330–4.
19. Maruyama K, Watanabe E, Kin T, Saito K, Kumakiri A, Noguchi A, et al. Smart Glasses for Neurosurgical Navigation by Augmented Reality. *Oper Neurosurg (Hagerstown).* 2018;15(5):551–6.
20. Matsukawa K, Yato Y. Smart glasses display device for fluoroscopically guided minimally invasive spinal instrumentation surgery: a preliminary study. *J Neurosurg Spine.* 2020;1–6.

### **Captions to illustrations:**

Figure 1: Augmented reality workflow.

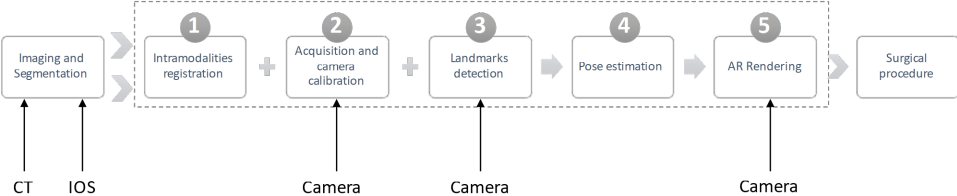
Figure 2: Proposed Graphical User Interface showing the setting, the preoperative calibration, the pre-operative planification with marker localisation and the intraoperative view before augmented reality alignment.

Figure 3: Application of augmented reality on a mandibular ABS phantom: A: presentation of the preoperative identification of the inferior alveolar nerve path on the 3D CT-scan reconstruction, B: identification of 8 landmarks on the virtual reconstructed mandible to solve the alignment problem, C: visual augmentation of the inferior alveolar nerve in blue projected on the mandible phantom which progress from the mandibular foramen to the mental foramen

Figure 4: Augmented reality application on an ex-vivo porcine model, A: preoperative identification of the two left inferior alveolar nerve foramina and a tooth on a CT-scan reconstruction, B: Identification of 8 landmarks on the virtual reconstructed mandible of the pig, C: visual augmentations in blue of two mental foramina and a dental cusp projected on the pig jaws with one foramen well identified and the second identification was in contact with the nerve emergence.

Figure 5: Application of augmented reality on maxillary, A: Cone beam axial slide of the patient showing the maxillary cyst, its extension and the proximity with the root of tooth 13; B: Preoperative maxillary planification with identification of the cyst's sides, limits of the cyst was delineated on each axial slide of the cone beam and then overlap to obtain the 3D planification, C: identification of 8 landmarks on the virtual reconstructed maxillary, D: Visual augmentation of the maxillary cyst in red on the patient, with a well adaptation of the 2D projection on the natural curvature of the dental arch.





Maxillofacial Surgery Augmented Reality

EnCov MSurgery AR

SETTINGS CALIBRATION PREOPERATIVE INTRAOPERATIVE

**CALIBRATION**

Method:

Calibration path:

Pattern height:  Pattern width:

Square length:  Marker length:

Blur Threshold value:  Processing rate:

**SENSOR**

Preset:

Stream path:

Sensor height:  Sensor width:

Frame height:  Frame width:

Focal length:  Frame rate:

**PREOPERATIVE**

Preoperative model:

**INTRAOPERATIVE**

Intraoperative models:

Recording path:

Recording FPS:

Use calibration:

Kilian CHANDELON  
ENC OV - 2020

Maxillofacial Surgery Augmented Reality

EnCov MSurgery AR

SETTINGS CALIBRATION PREOPERATIVE INTRAOPERATIVE

**SETTINGS**

**CALIBRATION**

**PREOPERATIVE**

**INTRAOPERATIVE**



Nb Images: 28

Nb Images selected: 28

Error: 0.36 px

Fx	Fy	Cx	Cy
0.15 %	0.22 %	0.52 %	1.84 %

START

Kilian CHANDELON  
ENC OV - 2020

Maxillofacial Surgery Augmented Reality

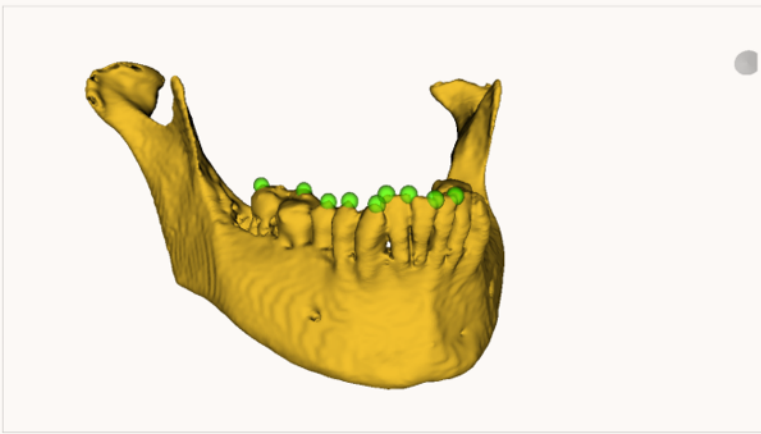
EnCov MSurgery AR

SETTINGS CALIBRATION PREOPERATIVE INTRAOPERATIVE

**PREOPERATIVE VIEW**

RELOAD

Nb points selected: 9



**SETTINGS**

**CALIBRATION**

**PREOPERATIVE**

**INTRAOPERATIVE**


Kilian CHANDELON  
ENC OV - 2020

Maxillofacial Surgery Augmented Reality

EnCov MSurgery AR

SETTINGS CALIBRATION PREOPERATIVE INTRAOPERATIVE

**INTRAOPERATIVE VIEW**



Flip View

Record Live View

STOP

CAPTURE

PROCESSING

Nb points selected: 11

Auto Processing Stream

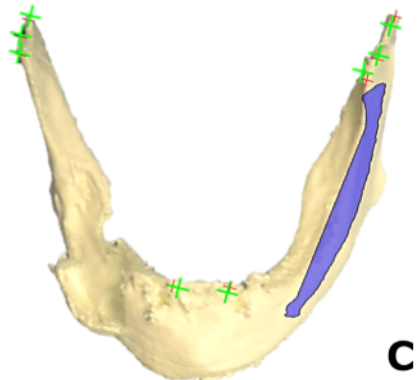
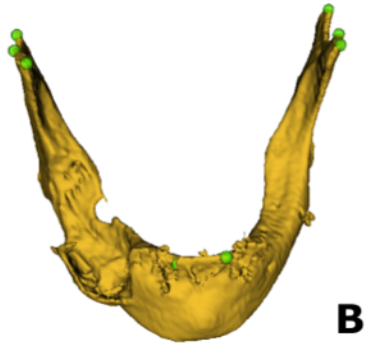
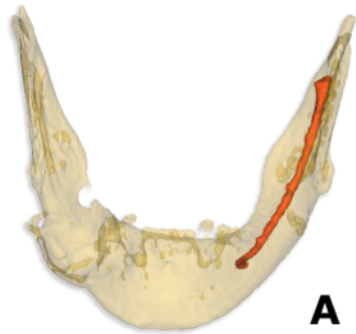
**SETTINGS**

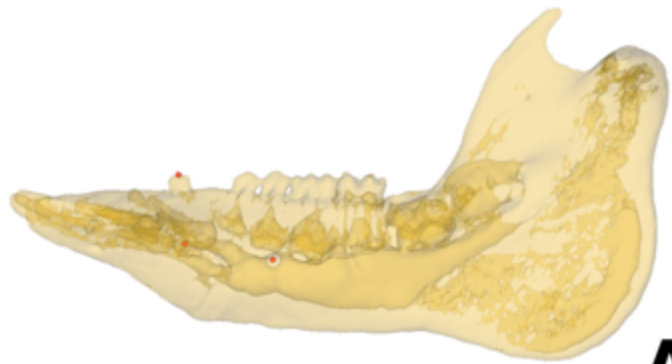**CALIBRATION**

**PREOPERATIVE**

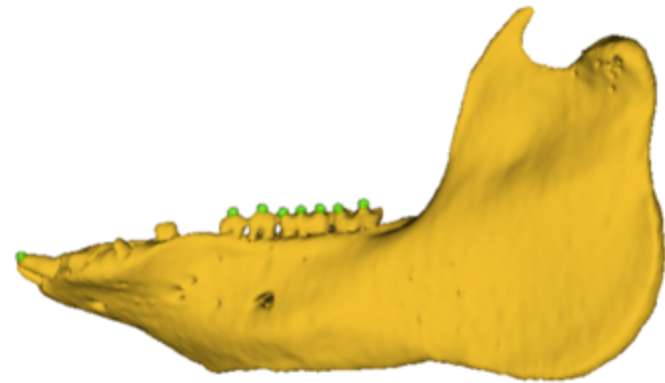
**INTRAOPERATIVE**

Kilian CHANDELON  
ENC OV - 2020

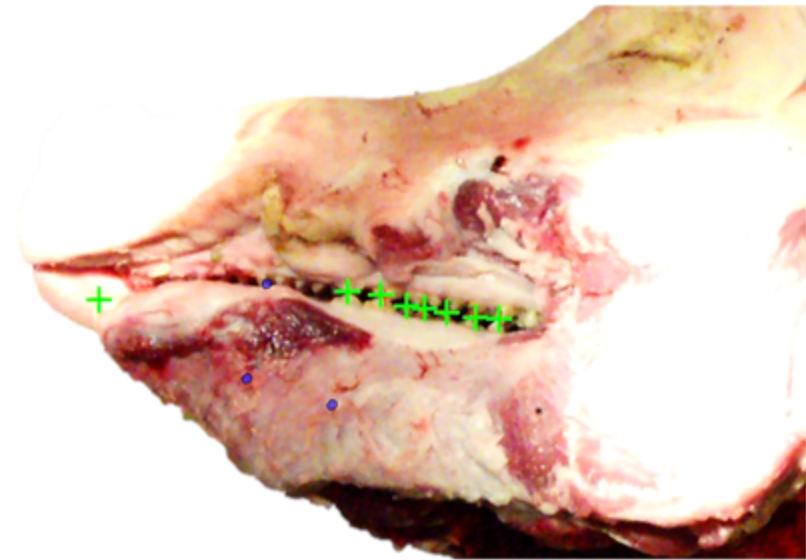



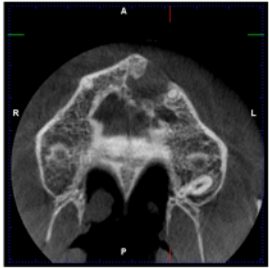
**A**



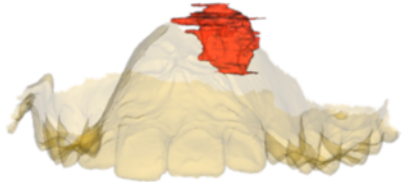**B**



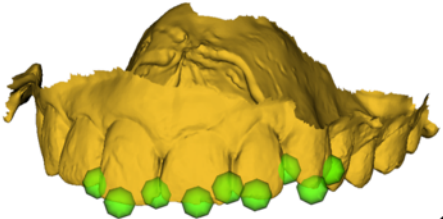
**C**



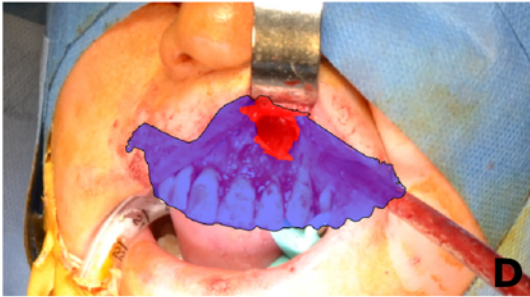
**A**



**B**



**C**



**D**