



HAL
open science

Minimally invasive treatment of aneurysmal bone cysts: systematic literature review

Jérôme Cottalorda, Djamel Louahem Sabah, Pauline Joly Monrigal, Clément
Jeandel, Marion Delpont

► To cite this version:

Jérôme Cottalorda, Djamel Louahem Sabah, Pauline Joly Monrigal, Clément Jeandel, Marion Delpont. Minimally invasive treatment of aneurysmal bone cysts: systematic literature review. *Orthopaedics & Traumatology: Surgery & Research*, 2022, 108 (4), pp.103272. 10.1016/j.otsr.2022.103272 . hal-03621331

HAL Id: hal-03621331

<https://hal.science/hal-03621331>

Submitted on 3 Nov 2022

HAL is a multi-disciplinary open access archive for the deposit and dissemination of scientific research documents, whether they are published or not. The documents may come from teaching and research institutions in France or abroad, or from public or private research centers.

L'archive ouverte pluridisciplinaire **HAL**, est destinée au dépôt et à la diffusion de documents scientifiques de niveau recherche, publiés ou non, émanant des établissements d'enseignement et de recherche français ou étrangers, des laboratoires publics ou privés.

Minimally invasive treatment of aneurysmal bone cysts: Systematic literature review

Jérôme Cottalorda*, Djamel Louahem Sabah, Pauline Joly Monrigal, Clément Jeandel, Marion Delpont

Centre Hospitalier Universitaire Lapeyronie, 371, avenue de Doyen Gaston Giraud, 34295 Montpellier cedex 5, France

A B S T R A C T

Introduction: The optimal treatment of aneurysmal bone cysts (ABC) remains controversial. Surgery has long been considered as the treatment that yields the best outcomes. Some authors now prefer using less invasive options as the primary treatment. The primary objective of this systematic literature review was to determine if treatments that are less invasive than surgery are also effective in curing the ABC. The secondary objective was to determine the respective role of each treatment in the therapeutic arsenal.

Hypothesis: Less invasive treatments can replace surgery as the base treatment for ABC.

Patients and methods: A PubMed® search was carried out for this review. The inclusion criteria were ABC treatment without cyst removal, case series, clinical case reports, reviews, publication in French or English. Excluded were articles that described the results of surgical treatment only, cranial or maxillo-facial cysts, secondary ABC, duplicates, no abstract available. Based on the first six items of the “MINOR criteria”, we selected 42 studies. For each selected study, we analyzed the number of cases, clinical response to treatment, radiological healing, recurrence or failure rate, complications and side effects of the treatment.

Results: This review found that less invasive treatments generate results that are at least as good as surgery, often with fewer complications. Thus, in certain cases, these treatments can be recommended as first-line therapy. This category includes selective arterial embolization, sclerotherapy (alcohol, polidocanol) and injection of demineralized bone matrix.

Discussion: Selective arterial embolization yields good results. While this is a difficult, operator-dependent technique that is not suitable for all ABCs (no identifiable feeding vessel), we recommend it as the primary treatment for spinal ABCs. For ABCs in other locations, sclerotherapy can be used as the primary treatment. However, this treatment becomes inconvenient if the number of injections is too high. Radiation therapy is not a first-line treatment because of its side effects. Bisphosphonates and denosumab can be used when the other treatments are contraindicated.

Keywords:

Aneurysmal bone cyst
Selective arterial embolisation
Sclerotherapy
Denosumab
Bisphosphonates

1. Introduction

Aneurysmal bone cyst (ABC) is a benign bone tumor that makes up about 1% of all bone tumors [1–4]. ABCs mainly affect adolescents and young adults [2,5,6]. The femur (22%), tibia (17%), spine (15%), humerus (10%), pelvis (9%) and fibula (9%) are the most common locations [1]. A specific chromosomal translocation, 17p11-13 or 16q22 involving TRE17/USP6 (ubiquitin-specific protease) has been described in 70% of primary ABC cases [7]. The remaining 30% are ABCs secondary to hemorrhage because of a pre-existing tumor, such as simple bone cyst, chondroblastoma,

giant cell tumor (GCT), osteoblastoma, chondromyxoid fibroma, non-ossifying fibroma, fibrous dysplasia or telangiectatic osteosarcoma (TOS) [1,2,6,8–10]. The natural history of ABC has four phases: lysis, expansion, stabilization and healing [3]. Healing can occur spontaneously or after biopsy, but this is rare [11].

ABC is a highly aggressive benign lesion, making for difficult treatment [2,12]. For many years, the standard treatment was curettage ± adjuvants ± bone graft [13,14]. Given that the mean recurrence rate after curettage ± graft is about 30% [13], any non-invasive treatment that is equal or better than this rate could be recommended as an alternative to surgery, if the side effects are acceptable. Some authors recommend bone resection because of the low recurrence rate, but there is considerable morbidity associated with this treatment. Several authors [3,9,15] have recently recommended that the first-line therapy be sclerotherapy

* Corresponding author.

E-mail address: jerome.cottalorda@gmail.com (J. Cottalorda).

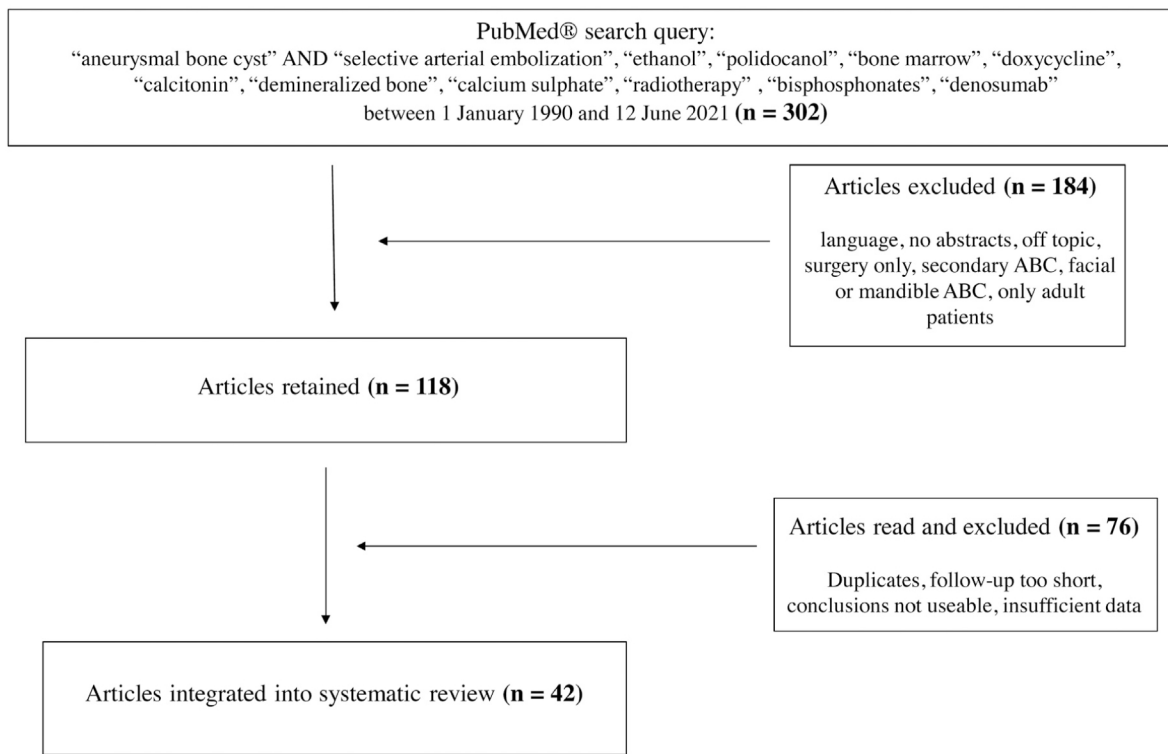


Fig. 1. Flow chart summarizing our literature review.

or selective arterial embolization (SAE), or even pharmacological treatments instead of curettage or surgical resection. These treatments are said to be as effective as surgery with fewer complications in some cases [2,15]. The primary objective of this systematic literature review was to determine if less invasive treatments are as effective as surgery in terms of outcomes and complications and if they can be recommended as the primary treatment for ABC. The secondary objective was to determine the respective role of each treatment in the therapeutic arsenal.

2. Methods

A PubMed® search was done for this systematic literature review of articles published between January 1, 1990 and June 12, 2021. The inclusion criteria were:

- treatment of ABC without removal of the cyst;
- case series, case reports or reviews;
- study published in French or English.

Studies were excluded when:

- the results were only for surgical treatment;
- it featured cranial or maxillofacial cysts;
- secondary ABC;
- duplicate data;
- no abstract was available.

Based on the first six items of the “MINOR criteria”, we selected 42 studies (see flowchart, Fig. 1).

For each selected study, we analyzed the number of cases, clinical response to treatment, radiological healing, recurrence or failure rate, complications and side effects of the treatment. The results of these treatments are presented below.

3. Results

3.1. Selective arterial embolization (SAE)

The aim of SAE is to block the tumor's blood flow without affecting the blood flow to neighboring structures [10,16]. SAE can be used as an adjuvant to reduce perioperative bleeding, especially in locations where a tourniquet cannot be used. SAE can also be used as the primary treatment for ABC in locations that are difficult to access surgically (spine, pelvis) and where postoperative complications can be very serious [15,16]. The posterior elements are often involved in spinal ABCs. At a minimum, curettage involves resecting a facet joint, or even more, which often requires surgical stabilization. When there is no pathological fracture and/or neurological deficit, SAE can be as effective as curettage while being less invasive [4]. It is possible to combine SAE with sclerotherapy [17] to increase the effectiveness of the treatment. Three studies were done at the Rizzoli Orthopedic Institute in Italy [12,14,15]. We selected two of them [12,15] that did not have overlapping patients (uncertain about one patient). The results are summarized in Table 1.

Given the progress in endovascular techniques, some authors use SAE as the primary treatment [4]. However, this technique is difficult and surgeon-dependent [15]. SAE is not always feasible because of the relationship with spinal cord vascularization, no feeding vessel can be identified or there are too many afferent pedicles. Complications related to ischemia can affect neurological or visceral structures [16]. At the spinal level, it is crucial to avoid the artery of Adamkiewicz. Another limitation of SAE is the need to perform multiple CT angiography scans with patients being exposed to considerable radiation each time [12]. Every patient must be informed of the risk of undergoing multiple SAE sessions if the cyst recurs or does not heal. If SAE fails, other treatments are still possible.

Table 1
Results of SAE.

Authors	No. patients	Mean patient age	Mean follow-up	Number of SAE	Clinical response	Radiological healing	Recurrence or failure	Side effects
Rossi [15]	102 SAE technically feasible in 88 patients (86%) SAE not technically feasible in 14% of cases (no identifiable feeder artery; artery of Adamkiewicz present)	16 years (3–60)	7 years (2.5–13)	1.4 (1–3)	82% pain completely eliminated after one SAE (57%), two SAE injections (19%) or three SAE injections (6%)	82% radiological healing after one SAE (57%), two SAE injections (19%) or three SAE injections (6%)	18% (recurrent pain, no radiological healing) More frequent recurrences in patients < 15 years and cysts > 6 cm	4 patients Skin necrosis (2), paresthesia of sciatic nerve (1), pseudoaneurysm of femoral artery in catheterization zone (1)
Terzy [12] ABC of the spine	23	23.7 years (6–43)	36.3 months (5–120)	4.1 (1–10)	73.9% (17 patients)	85% (45 patients)	26% did not respond to SAE with clinical progression and radiological worsening	0

3.2. Sclerotherapy

Sclerotherapy purposefully damages the endothelium of the blood vessels, triggering a cascade of coagulation events, which results in a clot [2,18,19]. Even aggressive ABC can be treated by sclerotherapy. Several sclerosing agents can be used.

3.2.1. Alcohol ± Surgiflo

Absolute alcohol is a sclerosing agent used for venous and lymphatic malformations. The dose of the 96% alcohol solution is limited to 1 ml/kg because in children, higher doses can cause serious symptoms [20]. Most authors carry out alcohol sclerotherapy 1 month after the biopsy, once they are certain that the bone breach created by the biopsy has healed, to prevent leakage of the alcohol into the neighboring tissues [20]. Alcohol can be used in combination with SURGIFLO® (a fibrosis inducing agent used for hemostasis when treating arteriovenous malformations) [9]. The results of the main studies about this treatment are summarized in Table 2. In the study by Ghanem et al. [9], only two patients (12.5%) needed a second injection to achieve local control.

3.2.2. Polidocanol

Polidocanol is a sclerosing agent used for the treatment of varicose veins [2]. Approximately 1 ml of polidocanol 3% is injected for every 1 cm³ of lesion volume [18]. Potential complications include hypopigmentation, necrosis at the injection site due to extravasation, pulmonary embolism, osteomyelitis and allergic reactions [18]. Prevention of extravasation is key for preventing complications [18]. Gupta et al. [22] reported one case of potentially deadly hypersensitivity in a 3-year-old child after intracystic injection of polidocanol. Two studies were done at the same healthcare facility [18,23]. Since we could not determine whether the patients overlapped, we retained only one study [18] in Table 3. Varshney et al. [23] compared sclerotherapy with polidocanol ($n=47$) to extended curettage and bone grafting ($n=47$). Polidocanol had a cure rate of 93% versus 85% for curettage. Surgery caused more complications and yielded worse outcomes. The authors concluded that sclerotherapy was less invasive and safer than surgery [23].

3.2.3. Others

3.2.3.1. Ethibloc. While injections of Ethibloc® are effective, this product is no longer available. Ethibloc® was associated with several complications: local cellulitis, cutaneous fistula, bone necrosis,

abscess, pulmonary embolism and even one death due to cerebellum infarct [2,13].

3.2.3.2. Calcium sulfate. Clayer [26] proposed doing percutaneous aspiration in 15 patients who had an ABC, combined with intracystic injection of an aqueous calcium sulfate solution. The minimum follow-up was 2 years. The calcium sulfate was completely resorbed in 8 weeks. Two patients had a recurrence.

3.2.3.3. Calcitonin ± corticosteroids. Intracystic injection of calcitonin blocks the activity of osteoclasts and/or contributes to the formation of trabecular bone in the fibrous septa of ABC [27]. Methylprednisolone has an angiostatic and anti-fibroblastic effect. Gladden et al. [28] hypothesized that the combination of methylprednisolone and calcitonin could be synergistic for curing ABC. The results of these studies are summarized in Table 4.

3.2.3.4. Doxycycline. The presence of giant cells in the ABC expressing the osteolytic component of osteoclasts with a high level of matrix metalloproteinases (MMP-9 and MMP-10). Doxycycline, which is typically used as an antibiotic, has anti-cancer properties through inhibition of MMPs and osteoclastic activity along with induction of osteoclastic apoptosis [30]. Two studies were done at the same healthcare facility with patient overlap [30,31], thus we selected only one study for our analysis. Shiels and Mayerson [30] reviewed 20 patients (mean age: 10 years) who had an ABC. Doxycycline (20 mg/mL) was mixed with 25% albumin to obtain a stable emulsion that was injected in the ABC. This treatment was always effective but up to 14 injections were needed for the cyst to heal. One-quarter of patients needed at least 10 injections for local control to be achieved. If general anesthesia is needed to inject this product in children, this must be taken into consideration when selecting a treatment. One patient presented with skin necrosis secondary to product extravasation. Woon et al. [32] treated 7 patients (mean age: 14 years). Signs of healing were observed in 6 out of 7 children after the first injection. Three of seven children had a second injection. According to these authors, the ideal scenario is to do one injection then wait 12 months to evaluate the result, because healing can take a long time. That study was limited by the small number of patients.

Twenty-five patients who had a spinal ABC with stable spine, without neurological deficits (or only very minor ones) were included in a comparative study [33]. Fourteen had a percutaneous

Table 2
Results of alcohol sclerotherapy.

Authors	No. patients	Mean patient age	Mean follow-up	Mean no. injections	Clinical response	Radiological healing	Recurrence	Minor side effects
Ulici [20]	17	11 years (6–16)	11 months (6–19)	2.4 (2–3)	100%	100%	0	Local induration (1), hypopigmentation at injection site (1), local inflammatory reaction (1), vertigo (2), considerable post-injection pain (2), genu varum deformity (1) Bradycardia during injection (1)
Hardy [21]	55	9.6 years (1–15)	50.9 months (16–117)	1.7 (1–4)	67% (36 patients) Factors for poor response: male sex, younger age	85% (45 patients)	0	0
Ghanem [9] Alcohol + Surgiflo	16	9.5 years (5–13)	35.6 months (24–71)	1.1 (1–2)	100%	68.7%	0	0

Table 3
Results of polidocanol sclerotherapy.

Authors	No. patients	Mean age	Mean follow-up	Mean No. injections	Clinical response	Radiological healing	Recurrences	Minor side effects
Rastogi [18]	72	15.6 years (3–38)	34 months (26.5–80)	3 (1–5)	84.5% (73.4% to 100%)	76.6% (61.9% to 93.2%)	2.8% (2 patients)	Local induration (18), hypopigmentation at injection site (3), local inflammation (1), vomiting (1)
Puri [24]	55	20 years (1–54)	62 months (20–111)	2 (1–5)	80%	80%	9% (4 patients)	0
Brosjö [19]	38	16 years (3–26)	17 months (4–37)	4 (1–11)	97% (37 patients)	97% (37 patients)	0	3 cases of minor local inflammation
Batisse [25]	9	11.9 years (5–17)	22 months (3–48)	1.2 (1–2)	100%	Complete (5) Partial (4)	0	Skin erythema (1)

Table 4
Results of calcitonin.

Authors	No. patients	Mean patient age	Mean follow-up	No. injections	Clinical response	Radiological healing	Recurrences	Side effects
Szendrői [29] Calcitonin alone	7	16 years (15–20)	12 months (11–14)	13.8 (10–15)	?	Completely healed (3), healed with residual subchondral cysts (3)	1 patient	Vomiting (1), convulsions (1) (same patient)
Chang [27] Calcitonin + corticosteroids	8	19 years (12–25)	16 months (1–93)	1.4 (1–3)	75% (6 of 8 patients): symptoms completely eliminated 25% (2 patients): symptoms partially eliminated	50% (4 patients)	4 patients	0
Oliveira [8] Calcitonin + methylprednisolone	47	17.5 years (4–54)	45.5 months	2.8 (1–7)	91.4%	83.7%	10.6% (5 patients)	0

injection of doxycycline while 11 were operated. In the doxycycline group, the tumor shrunk in all patients with neurological recovery. There was no difference in terms of the recurrences and complications between the two groups.

3.3. Autologous bone marrow ± demineralized bone matrix

Barbanti-Brodano et al. [34] reported on two patients (14 and 16 years) who had an ABC in C2, which is impossible to treat by

SAE. These ABCs were treated by injecting autologous bone marrow concentrate inside the cyst.

According to Docquier and Delloye [3], an appropriate stimulus can shift the ABC from its osteolytic resorption phase to a reconstruction phase, which is sometimes seen clinically, spontaneously or after biopsy. Since the stromal cells in the cysts are capable of osteogenesis, introducing an osteoinductive substance in the cyst can stop the active growth phase (resorption) and trigger the stabilization phase (osteogenesis). For this induction to

Table 5
Results of bisphosphonates.

Authors	No. patients and location	Mean age	Mean follow-up	Number of treatment cycles	Clinical response	Radiological healing	Recurrence or failure	Side effects
Simm [40]	1	8 years	3 years	7	Favorable	Yes	0	0
Zoledronic acid	ABC in sacrum			(over 2 years)				
Cornelis [38]	9	15.5 years	53.6 months	2.5 (1–4)	Complete elimination of pain: 7 patients	Complete (2) and partial (5) ossification	Two failures requiring surgery	0
Kieser [39]	C2, C4, C6 (2), L1, femoral shaft, acetabulum, sacrum (2)	(7–22)	(8–72)					
Pamidronate (1 mg/kg) (6 patients) or zoledronate (4 mg) (3 patients)								

happen, tumor curettage must not be done. Instead, the tumor tissue inside the ABC is preserved so that its intrinsic osteogenic potential can be harnessed to help with healing. Docquier and Delloye [3] use allogenic, partially demineralized bone matrix that has an osteogenic effect. These allogenic bone chips are mixed with autogenic bone graft to obtain a paste that is introduced inside the cyst cavity. The ABC cells are an adequate stimulus to induce repair. Given that no curettage is done, this treatment eliminates the need for extensive surgery and blood loss. Thus it is well suited to difficult locations such as the pelvis. Thirteen patients have been treated with this technique: five had no previous surgery, one had failed SAE and seven had failed prior surgical treatment. At a mean follow-up of 3.9 years, 11 patients had healed. The recurrence rate (15%, 2/17 patients) was similar to surgical treatment.

Cevolani et al. [35] described treating 21 patients with a single injection of autologous bone marrow mixed with demineralized bone matrix and platelet-rich fibrin. They compared this treatment with curettage plus grafting. Among the 21 patients who received an injection, 17 (80%) healed with no additional treatment. Among the 239 patients treated with curettage plus grafting, 177 (74%) healed with no additional treatment. The recurrence risk was similar for the two methods (25%). The authors [35] recommend this treatment for primary ABCs.

3.4. Radiotherapy

3.4.1. Conventional radiotherapy

Radiotherapy is effective at inducing ossification in the ABC. However, this treatment is associated with a risk of radio-induced sarcoma, acute leukemia, growth disturbances, impaired gonad function, myelopathy and iatrogenic vertebral deformities, thus is not recommended as the first-line therapy [2,3,14,34]. Modern techniques may cause less damage than earlier ones [2,36,37], but this must be confirmed with longer follow-up studies.

3.4.2. Phosphorus

Bush et al. [5] described doing an intralesional injection of phosphorus³², a drug used to treat rheumatoid synovitis and recurrent hemarthrosis in persons with hemophilia. Phosphorus³² has a half-life of 14.3 days. It emits beta particles and has a penetration of 2.8 millimeters. Five patients who had an ABC (4 spinal, 1 acetabulum) were treated with this method. Three of them had more than 2 years of follow-up. Only one injection was needed in four patients. A second injection was needed 6 months later in the fifth patient. In one case (acetabulum lesion), the product diffused into the systemic circulation. At the latest review (1 year, 5 months), there did not appear to be any sequelae associated with this complication.

3.5. Emerging pharmacological treatments

3.5.1. Bisphosphonates

Bisphosphonates such as zoledronic acid inhibit osteoclastic activity. They have been used successfully to treat various bone tumors: simple bone cyst, fibrous dysplasia, GCT, Langerhans cell histiocytosis, chronic recurrent multifocal osteomyelitis. Bisphosphonates also have antineoplastic properties as they induce apoptosis, inhibit tumor cell adhesion and invasion, and inhibit angiogenesis [2,38]. According to Kieser et al. [39], bisphosphonates can be the treatment of choice for spinal ABC, except in cases of instability or progressive neurological deficit where surgery remains preferable. Two studies were done at the same healthcare facility with overlapping patients [38,39]. We grouped these two studies while eliminating duplicates. The results are summarized in Table 5.

3.5.2. Denosumab

Denosumab (Prolia®) is a human monoclonal antibody (IgG2) that specifically binds to RANKL (*receptor activator of nuclear factor- κ B ligand*) with high affinity, preventing activation of the RANK receptor located on the surface of osteoclasts and their precursors [2]. Blocking the RANK/RANKL interaction inhibits the formation, function and survival of osteoclasts and reduces bone resorption in cortical and trabecular bone. Denosumab is an anti-osteoclastic treatment used not only to treat postmenopausal osteoporosis but also bone metastases, multiple myeloma and GCT. Calcium and vitamin D supplementation is strongly recommended during the treatment to avoid severe hypocalcemia. Several publications show the efficacy of denosumab for achieving re-ossification of the ABC [41]. A few rare side effects have been described: infection, skin reactions and osteonecrosis at the jaw. The long-term effects of denosumab on a growing skeleton are still not known [2]. Alhmaid and Abu-Zaid [42] did a literature review on the efficacy and safety of this treatment for ABC. They reviewed 10 clinical cases [42] and two small case series (9 patients each) [41,43]. We added two newer case series to the analysis (6 and 5 patients, respectively) [44,45]. In all, 41 patients were analyzed. Most of the patients were less than 18 years of age ($n = 30$). Most of the ABC were in the spine ($n = 16$) and the sacrum ($n = 7$). Nearly all of them had a good clinical ($n = 35/39$) and radiological response ($n = 36/41$). The mean follow-up in these studies ranged from 2 to 48 months. The side effects reported were hypocalcemia ($n = 3$), hypercalcemia ($n = 5$), vomiting ($n = 2$), moderate fatigue ($n = 1$) and moderate back pain ($n = 1$).

4. Discussion

Even if x-rays and MRI can be suggestive of ABC, they are not sufficient to establish a firm diagnosis [46]. A surgical biopsy or fine-needle aspiration biopsy (less effective [47]) are necessary, especially when the ABC is secondary to a malignant tumor

[3,4,10,47]. For non-surgical treatments, our radiologist performs a fine-needle aspiration biopsy.

ABC is a highly aggressive benign lesion, making for difficult treatment [2,12]. Good results can be achieved with various treatments. Few bony tumors have the option of so many effective treatments. The optimal treatment is still debated and greatly depends on the experience and preferred practices of the surgeon and hospital facility [2]. For many years, the recommended treatment was curettage ± bone grafting of the resultant void. The recurrence rate in 669 cases of ABC treated by curettage ± graft was 31% [13]. Several authors report using adjuvant treatments to reduce this recurrence rate: alcohol, bone cement, liquid nitrogen, argon beam coagulation, high-speed burring [10]. Resection has lowest recurrence rate – 7 out of 175 resections – with all the recurrences occurring for marginal resections, none for wide excisions [13]. En bloc resection is a high morbidity surgery (bleeding, post-operative pain, growth disturbance, muscle loss, limited joint range of motion) and can be considered excessive for a benign lesion. Also, local reconstruction may be needed.

This review shows that treatments without resection or curettage of the ABC are, in some cases, as effective or even more effective than conventional curettage in terms of results and recurrences. Thus, in certain cases, these treatments can be recommended as first-line therapy. SAE, sclerotherapy with alcohol or polidocanol and DBM injection fall within this category. These less invasive treatments produce results that are at least as good as surgery, often with fewer complications.

Although SAE generates good results, this is a difficult, surgeon-dependent technique that is not suitable for all ABCs (no identifiable feeder vessel, artery of Adamkiewicz present). SAE can be the primary treatment for a spinal ABC without instability or neurological deficit. Selective angiography beforehand is needed to prevent spinal cord ischemia. The morbidity of SAE is less than with surgery. The limitations of SAE are the need to repeat the embolization and the irradiation of patients [14]. In the meta-analysis by Schmitt Cruz et al. [48], the recurrence risk was 19%. For some authors, SAE is the first step of a secondary surgical procedure.

Many authors now consider sclerotherapy [3,9,18,21] as the first-line therapy to try with ABC since it is safe, as effective as surgery, does not leave any scars and is less aggressive [20]. In the meta-analysis by Schmitt Cruz et al. [48], the mean local control rate was 91% with no need for sophisticated equipment and few complications. The weakness of this meta-analysis was that studies often provide overall results without separating out the results of different types of sclerotherapy. In a case series of 70 injections of polidocanol in pediatric patients by Jasper et al. [49], the local control rate was 83%. Puthoor et al. [50] found equivalent results for the treatment of ABC by polidocanol or curettage plus grafting. The major drawback of these injections is the need to repeat the treatment. Injection of alcohol in combination with SURGIFLO® appears to be the most promising (healing in 87.5% with a single injection).

Since curettage is not needed, introducing autologous bone marrow and DBM in the cyst avoids the need for extended surgery and blood loss, which makes this technique very appealing for difficult to access locations.

Other treatments require longer follow-up and larger studies to evaluate their results: calcium sulfate, calcitonin (the re-injection rate in some studies is prohibitive), doxycycline. Some highly effective techniques should only be used in very select cases. This is the case of radiation therapy. There are plenty of other effective treatments for ABC, thus this technique is not preferred as it has considerable side effects in children. While treatment with phosphorus³² appears promising, it needs to be evaluated in larger studies.

Lastly, some treatments reserved for cases where the more “conventional” techniques (SAE, sclerotherapy, surgery) cannot be used, e.g., bisphosphonates and denosumab [38]. Denosumab can be proposed in very specific instances after a multidisciplinary team meeting [41]. The long-term effects of these treatments must still be determined.

If an ABC is discovered because of a pathological fracture, which is very rare compared to simple bone cysts, there are two different scenarios. The first is a non-displaced fracture (fissure). When possible, the fracture is treated conservatively; once healed, we apply our standard ABC protocol (biopsy plus non-surgical treatment). If the fracture is displaced, depending on the location, we will perform a biopsy then surgical fixation.

According to Terzi et al. [12], signs that favor healing are peripheral re-ossification of the cyst, reduction of the tumor volume, intra-cystic ossification and elimination of pain. Rastogi et al. [18] proposed a radiological classification to determine the result:

- degree 1, residual lesion <25%, excellent result;
- degree 2, residual lesion between 25% and 50%, good result;
- degree 3, residual lesions between 50% and 75%, poor result;
- degree 4, residual lesions >75%, no response to treatment.

Most authors contend that 2 years of follow-up of the ABC is needed to rule out a recurrence [51]. Many times, residual subchondral cysts persist after the ABC has healed, which is suggestive of a recurrence, but the natural history many years later shows that the radiological status does not change [51]. Sometimes, one must insert a pause before reoperating on a patient [51].

The main limitation of our analysis is that most of the included studies were retrospective. There are larger case series relative to case reports, which obviously do not have the same scientific weight. In some studies, the follow-up was too short (<2 years). Also, it is impossible to categorize the lesions since most of the published studies did not classify their lesions. No matter the treatment of an inactive ABC, the result will be good without recurrence. It is vital to exclude cases of inactive ABC to be able to objectively evaluate the recurrence rate of a treatment method. Some good results can be overestimated because of the presence of multiple cases of inactive ABC in the series.

5. Conclusion

Since ABC mainly affects children and adolescents, it is preferable to avoid an “aggressive” surgery for this benign lesion that can heal spontaneously. Some newer treatments can now be considered as first-line therapies at the same level as surgery for the treatment of ABCs. This is the case for SAE when it can be done. This is also the case of certain types of sclerotherapy (alcohol, polidocanol), as long as one recognizes the need for repeat injections (1 to 4, on average). But if the number of injections is too high, it represents a major disadvantage of this treatment. Radiotherapy cannot be considered as a primary treatment given its side effects. Bisphosphonates and denosumab can be used when the other treatments are contraindicated. Surgery (curettage or resection) remains an option, with some teams using it as the first-line treatment. This is the case when the facility does not have the possibility of doing embolization or intracystic injections (no interventional radiology team) or when non-invasive treatment methods have failed. A combination of two treatments is possible: for example, SAE before surgery to reduce the risk of bleeding. At our hospital, sclerotherapy and SAE are the primary treatments after biopsy (Fig. 2). The description of a few cases of spontaneous healing, or after biopsy (even for active or aggressive lesions), has led us to wait 3 months after the biopsy – when possible – before treating the ABC.

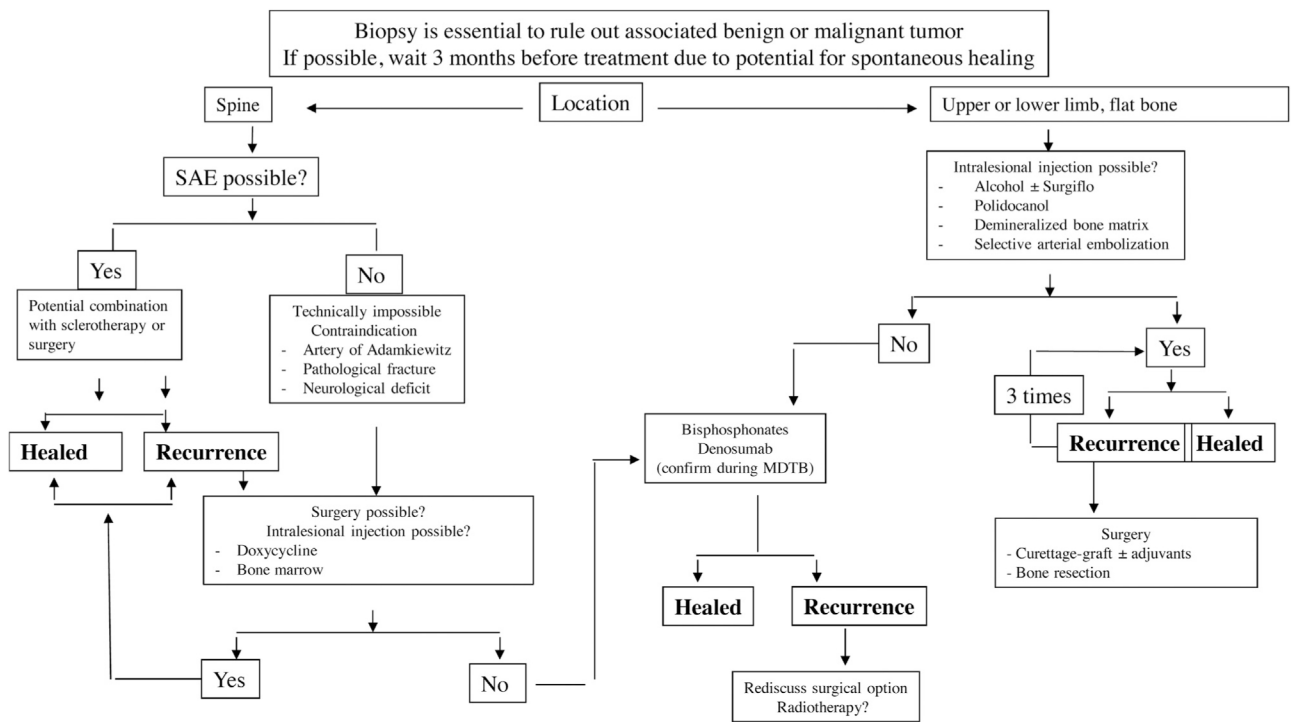


Fig. 2. Decision tree used at our hospital (MDTB: multidisciplinary tumor board meeting).

Disclosure of interest

The authors declare that they have no competing interest.

Funding

None.

Author contributions

JC and DL wrote the article, CJ did the literature review, PJM read and corrected the article, MD finalized the article. All authors read and approved the final version of the article.

References

- Cottalorda J, Kohler R, Sales de Gauzy J, Chotel F, Mazda K, Lefort G, et al. Epidemiology of aneurysmal bone cysts in children: a multicenter study and literature review. *J Pediatr Orthop B* 2004;13:389–94.
- Park HY, Yang SK, Sheppard WL, Hegde V, Zoller S, Nelson S, et al. Current management of aneurysmal bone cysts. *Curr Rev Musculoskelet Med* 2016;9:435–44.
- Docquier PL, Delloye C. Treatment of aneurysmal bone cysts by introduction of demineralized bone and autogenous bone marrow. *J Bone Joint Surg Am* 2005;87:2253–8.
- Boriani S, De Lure F, Campanacci L, Gasbarrini A, Bandiera S, Biagini R, et al. Aneurysmal bone cyst of the mobile spine: report on 41 cases. *Spine (Phila Pa 1976)* 2001;26:27–35.
- Bush CH, Adler Z, Drane WE, Tamurian R, Scarborough MT, Gibbs CP. Percutaneous radionuclide ablation of axial aneurysmal bone cysts. *AJR* 2009;194:W84–90.
- Mascard E, Gomez-Brouchet A, Lambot K. Bone cysts: unicameral and aneurysmal bone cyst. *Orthop Traumatol Surg Res* 2015;101:S119–21.
- Panoutsakopoulos G, Pandis N, Kyriazoglou I, Gustafson P, Mertens F, Mandahl N. Recurrent t(16;17)(q22;p13) in aneurysmal bone cysts. *Genes Chromosomes Cancer* 1999;26:265–6.
- Oliveira MBDR, Meohas W, Silva RR, Medeiros F, Derr V, Hsi BL, et al. Percutaneous treatment of aneurysmal bone cyst with calcitonin and methylprednisolone. *Acta Ortop Bras* 2018;26:314–9.
- Ghanem I, Nicolas N, Rizkallah M, Slaba S. Sclerotherapy using Surgiflo and alcohol: a new alternative for the treatment of aneurysmal bone cysts. *J Child Orthop* 2017;11:448–54.

- Cottalorda J, Bourelle S. Modern concepts of primary aneurysmal bone cyst. *Arch Orthop Trauma Surg* 2007;127:105–14.
- Louahem D, Kouyoumdjian P, Ghanem I, Mazeau P, Perrochia H, L'Kaissi M, et al. Active aneurysmal bone cyst in children: possible evolution after biopsy. *J Child Orthop* 2012;6:333–8.
- Terzi S, Gasbarrini A, Fuiano M, Barbanti Brodano G, Ghermandi R, Bandiera S, et al. Efficacy and safety of selective arterial embolization in the treatment of aneurysmal bone cyst of the mobile spine: a retrospective observational study. *Spine (Phila Pa 1976)* 2017;42:1130–8.
- Cottalorda J, Bourelle S. Current treatments of primary aneurysmal bone cyst. *J Pediatr Orthop B* 2006;15:155–67.
- Amendola L, Simonetti L, Simoes CE, Banderia S, De Lure F, Boriani S. Aneurysmal bone cyst of the mobile spine: the therapeutic role of embolization. *Eur Spine J* 2013;22:533–41.
- Rossi G, Mavrogenis AF, Facchini G, Bartalena T, Rimondi E, Renzulli M, et al. How effective is embolization with N-2-butyl-cyanoacrylate for aneurysmal bone cysts? *Int Orthop* 2017;41:1685–92.
- Green JA, Bellemore MC, Marsden FW. Embolization in the treatment of aneurysmal bone cysts. *J Pediatr Orthop* 1997;17:440–3.
- Guarnieri G, Ambrosiano G, Vassallo P, Granato F, Setola FR, Greco B, et al. Combined percutaneous and endovascular treatment of symptomatic aneurysmal bone cyst of the spine: clinical six months. Follow-up of six cases. *Neuroradiol J* 2012;23:74–84.
- Rastogi S, Varshney MK, Trikha V, Khan SA, Choudhury B, Safaya R. Treatment of aneurysmal bone cysts with percutaneous sclerotherapy using polidocanol. A review of 72 cases with long-term follow-up. *J Bone Joint Surg Br* 2006;88:1212–6.
- Brosjö O, Pechon P, Hesla A, Tsagozis P, Bauer H. Sclerotherapy with polidocanol for treatment of aneurysmal bone cysts. Good results in 37 of 38 consecutive patients. *Acta Orthop* 2013;84:502–5.
- Ulici A, Florea DC, Carp M, Ladaru A, Tevanov I. Treatment of the aneurysmal bone cyst by percutaneous intracystic sclerotherapy using ethanol ninety five percent in children. *Int Orthop* 2018;42:1413–9.
- Marie-Hardy L, El Sayed L, Alves A, Brunelle F, Ouchrif Y, Naggara O, et al. Percutaneous alcohol-based sclerotherapy in aneurysmal bone cyst in children and adolescents. *Orthop Trauma Surg Res* 2020;106:1313–8.
- Gupta G, Pandit RS, Jerath N, Narasimhan R. Severe life-threatening hypersensitivity reaction to polidocanol in a case of recurrent aneurysmal bone cyst. *J Clin Orthop Trauma* 2019;10:414–7.
- Varshney MK, Rastogi S, Khan SA, Trikha V. Is sclerotherapy better than intralesional excision for treating aneurysmal bone cysts? *Clin Orthop Relat Res* 2010;468:1649–59.
- Puri A, Hegde P, Gulia A, Parikh M. Primary aneurysmal bone cyst. *Bone Joint J* 2020;102:186–90.
- Batiste F, Schmitt A, Vendevue T, Herbreteau D, Bonnard C. Aneurysmal bone cyst: a 19-case series managed by percutaneous sclerotherapy. *Orthop Trauma Surg Res* 2016;102:213–6.

- [26] Clayer M. Injectable form of calcium sulphate as treatment of aneurysmal bone cysts. *ANZ J Surg* 2008;78:366–70.
- [27] Chang CY, Kattapuram SV, Huang AJ, Simeone FJ, Torriani M, Bredella MA. Treatment of aneurysmal bone cysts by percutaneous CT-guided injection of calcitonin and steroid. *Skeletal Radiol* 2017;46:35–40.
- [28] Gladden ML, Gillingham BL, Hennrikus W, Vaughan LM. Aneurysmal bone cyst of the first cervical vertebrae in a child treated with percutaneous intralesional injection of calcitonin and methylprednisolone. A case report. *Spine (Phila Pa 1976)* 2000;25:527–30.
- [29] Szendroi M, Antal I, Liszka GY, Konya A. Calcitonin therapy of aneurysmal bone cysts. *J Cancer Res Clin Oncol* 1992;119:61–5.
- [30] Shiels WE, Mayerson JL. Percutaneous doxycycline treatment of aneurysmal bone cysts with low recurrence rate: a preliminary report. *Clin Orthop Relat Res* 2013;471:2675–83.
- [31] Shiels WE, Bebe AC, Mayerson JL. Percutaneous doxycycline treatment of juxtaphyseal aneurysmal bone cysts. *J Pediatr Orthop* 2016;36:205–12.
- [32] Woon JTK, Hoon D, Graydon A, Flint M, Doyle AJ. Aneurysmal bone cyst treated with percutaneous doxycycline: is a single treatment sufficient? *Skeletal Radiol* 2019;48:765–71.
- [33] Liu X, Han SB, Si G, Yang SM, Wang CM, Jiang L, et al. Percutaneous albumin/doxycycline injection versus open surgery for aneurysmal bone cysts in the mobile spine. *Eur Spine J* 2019;28:1529–36.
- [34] Barbanti-Brodano G, Girolami M, Ghermandi R, Terzi S, Gasbarrini A, Bandiera S, et al. Aneurysmal bone cyst of the spine treated by concentrated bone marrow: clinical cases and review of the literature. *Eur Spine J* 2017;26(Suppl 1):158–66.
- [35] Cevalani L, Campanacci L, Sambri A, Lucarelli E, De Paolis M, Donati DM. Is percutaneous injection of bone marrow concentrate, demineralized bone matrix and PRF an alternative to curettage and bone grafting for treating aneurysmal bone cyst? *J Tissue Eng Regen Med* 2021;15:269–78.
- [36] Feigenberg SJ, Marcus Jr RB, Zlotecki RA, Scarborough MT, Berrey BH, Enneking WF. Megavoltage radiotherapy for aneurysmal bone cysts. *Int J Radiat Oncol Biol Phys* 2001;49:1243–7.
- [37] Zhu S, Hitchcock KE, Mendenhall WM. Radiation therapy for aneurysmal bone cysts. *Am J Clin Oncol* 2017;40:621–4.
- [38] Cornelis F, Truchetet ME, Amoretti N, Verdier D, Fournier C, Pillet O. Bisphosphonate therapy for unresectable symptomatic benign bone tumors: a long-term prospective study of tolerance and efficacy. *Bone* 2014;58:11–6.
- [39] Kieser DC, Mazas S, Cawley DT, Fujishiro T, Tavaloro C, Boissiere L, et al. Bisphosphonate therapy for spinal aneurysmal bone cysts. *Eur Spine J* 2018;27:851–8.
- [40] Simm PJ, O'Sullivan M, Zacharin MR. Successful treatment of a sacral aneurysmal bone cyst with zoledronic acid. *J Pediatr Orthop* 2013;33:e61–4.
- [41] Palmerini E, Ruggieri P, Angelini A, Boriani S, Campanacci D, Milano GM, et al. Denosumab in patients with aneurysmal bone cysts: a case series with preliminary results. *Tumori J* 2018;104:344–51.
- [42] Alhumaid I, Abu-Zaid A. Denosumab therapy in the management of aneurysmal bone cysts: (pas d'espace avant les deux points) a comprehensive literature review. *Cureus* 2019;11:e3989.
- [43] Kurucu N, Akyuz C, Ergen FB, Yalcin B, Kosemehmetoglu K, Ayvaz M, et al. Denosumab treatment in aneurysmal bone cyst: Evaluation of nine cases. *Pediatr Blood Cancer* 2018;65:e26926.
- [44] Dürr HR, Grahneis F, Baur-Melnyk A, Knösel T, Birkenmaier C, Jansson V, et al. Aneurysmal bone cyst: results of an off-label treatment with Denosumab. *BMC Musculoskelet Disord* 2019;456:1–6.
- [45] Raux S, Bouhamama A, Gaspar N, Brugières L, Entz-werlé N, Mallet C, et al. Denosumab for treating aneurysmal bone cysts in children. *Orthop Traumatol Surg Res* 2019;105:1181–5.
- [46] Mahnken AH, Nolte-Ernsting CCA, Wildberger JE, Heussen N, Adam G, Wirtz DC, et al. Aneurysmal bone cyst: value of MR imaging and conventional radiography. *Eur Radiol* 2003;13:1118–24.
- [47] Creager AJ, Madden CR, Bergman S, Geisinger KR. Aneurysmal bone cyst: fine-needle aspiration findings in 23 patients with clinical and radiologic correlation. *Am J Clin Pathol* 2007;128:740–5.
- [48] Schmitt Cruz G, Cuevas Suarez CE, Aitken Saavedra JP, Giorgis R, Kishimoto Teixeira MR, Gomes Muniz FWM. Percutaneous treatments of primary aneurysmal bone cysts: systematic review and meta-analysis. *Eur J Orthop Surg Traumatol* 2021, <http://dx.doi.org/10.1007/s00590-021-02893-6>.
- [49] Jasper J, Van der Heijden L, Van Rijswijk CSP, Van de Sande MAJ. Efficacy of sclerotherapy with Polidocanol (Ethoxysclerol) in primary aneurysmal bone cysts in children and adolescents. *J Pediatr Orthop* 2021, <http://dx.doi.org/10.1097/BPO.0000000000001839>.
- [50] Puthoor D, Francis L, Ismail R. Is sclerotherapy with polidocanol a better treatment option for aneurysmal bone cyst compared to conventional curettage and bone grafting? *J Orthop* 2021;25:265–70.
- [51] Cottalorda J, Louahem D, Jeandel C, Delpont M. Kyste osseux anévrysmal. *EMC Appareil Locomoteur* 2021:1–12 [Article 14-771].