



HAL
open science

Prostate Bed Delineation Guidelines for Postoperative Radiation Therapy: On Behalf Of The Francophone Group of Urological Radiation Therapy

Sophie Robin, Marjory Jolicoeur, Samuel Palumbo, Thomas Zilli, Gilles Crehange, Olivier de Hertogh, Talar Derashodian, Paul Sargos, Carl Salembier, Stéphane Supiot, et al.

► To cite this version:

Sophie Robin, Marjory Jolicoeur, Samuel Palumbo, Thomas Zilli, Gilles Crehange, et al.. Prostate Bed Delineation Guidelines for Postoperative Radiation Therapy: On Behalf Of The Francophone Group of Urological Radiation Therapy. *International Journal of Radiation Oncology, Biology, Physics*, 2021, 109 (5), pp.1243-1253. 10.1016/j.ijrobp.2020.11.010 . hal-03612750

HAL Id: hal-03612750

<https://hal.science/hal-03612750>

Submitted on 15 Mar 2023

HAL is a multi-disciplinary open access archive for the deposit and dissemination of scientific research documents, whether they are published or not. The documents may come from teaching and research institutions in France or abroad, or from public or private research centers.

L'archive ouverte pluridisciplinaire **HAL**, est destinée au dépôt et à la diffusion de documents scientifiques de niveau recherche, publiés ou non, émanant des établissements d'enseignement et de recherche français ou étrangers, des laboratoires publics ou privés.



Distributed under a Creative Commons Attribution - NonCommercial 4.0 International License

**PROSTATE BED DELINEATION GUIDELINES FOR
POSTOPERATIVE RADIOTHERAPY, ON BEHALF OF THE GFRU
(FRANCOPHONE GROUP OF UROLOGICAL RADIOTHERAPY)**

Sophie ROBIN, MD¹, Marjory JOLICOEUR, MD², Samuel PALUMBO, MD³, Thomas ZILLI,
MD⁴, Gilles CREHANGE, MD PhD⁵, Olivier DE HERTOIGH, MD⁶, Talar DERASHODIAN,
MD², Paul SARGOS, MD⁷, Carl SALEMBIER, MD⁸, Stéphane SUPIOT, MD, PhD⁹,
Corina UDRESCU, PhD¹, Olivier CHAPET¹ MD, PhD.

- 1. Radiation Oncology Department, Centre Hospitalier Lyon Sud, Pierre Benite, France*
- 2. Radiation Oncology Department, Charles LeMoyne Hospital, CISSS Montérégie-centre, Montréal, Canada*
- 3. Radiation Oncology Department, CHU UCL Namur – Sainte Elisabeth, Namur, Belgium.*
- 4. Radiation Oncology Department, Geneva University Hospital, Geneva, Switzerland and Faculty of Medicine, Geneva, Switzerland*
- 5. Radiation Oncology Department, Institut Curie, Saint-Cloud, France.*
- 6. Radiation Oncology Department, CHR Verviers East Belgium, Verviers, Belgium*
- 7. Radiation Oncology Department, Jewish General Hospital, McGill, Montreal, Canada*
- 8. Department of Radiotherapy, Europe Hospitals Brussels, Belgium.*
- 9. Radiation Oncology Department, Institut de Cancérologie de l'Ouest, Nantes Saint-Herblain, France and CRCINA CNRS Inserm, University of Nantes and Angers, Nantes, France*

Corresponding Author:

Pr. Olivier CHAPET

Service de Radiothérapie Oncologie

Centre Hospitalier Lyon Sud

165 Chemin du Grand Revoyet

69495 PIERRE BENITE, FRANCE

Phone number: +33 4 78 86 42 51

Fax: +33 4 78 86 42 65

E-mail: olivier.chapet@chu-lyon.fr

Short Running Title: GFRU prostate bed radiotherapy guidelines

Number of pages:

Title page and additional information: 2 pages

Abstract: 1 page

Manuscript: 24 pages

Number of tables: 1

Number of figures: 4

Word count

Abstract: 267 words

Manuscript: 3845 words

Conflict of interest: The authors report no conflict of interest.

Funding: None

Acknowledgements: we would like to express our gratitude to all the colleagues and members of the GFRU, the Francophone Group of Urological Radiotherapy.

ABSTRACT

Purpose: Prostate bed (PB) irradiation is considered the standard post-operative treatment after radical prostatectomy (RP) for tumors with high-risk features and/or persistent PSA, or for salvage treatment in case of biological relapse. Four consensus guidelines have been published to standardize practices and reduce the inter-observer variability in PB delineation, however with discordant recommendations. In order to improve the reproducibility in the PB delineation, the Francophone Group of Urological Radiotherapy (GFRU – *Groupe Francophone de Radiothérapie Urologique*) worked to propose a new and more reproducible consensus guideline for PB clinical target volume (CTV) definition.

Methods and Materials: A four-step procedure was used. First, a group of 10 GFRU prostate experts evaluated the four existing delineation guidelines for post-operative radiotherapy (EORTC, FROGG, RTOG, and PMH) in order to identify divergent issues. Second, datasets of 50 magnetic resonance imaging (MRI) studies (25 after RP and 25 with an intact prostate gland) were analyzed to identify the relevant anatomical boundaries of the PB. Third, a literature review of surgical, anatomical, histological, and imaging data was performed to identify the relevant PB boundaries. Fourth, a final consensus on PB-CTV definition was reached among experts.

Results: Definitive limits of the PB-CTV delineation were defined, using easily visible landmarks on computed tomography scans (CT). The purpose was to ensure a better reproducibility of PB definition for any radiation oncologist even without experience in post-operative radiotherapy.

Conclusions: New recommendations for PB delineation based on simple anatomical boundaries and available as a CT image atlas are proposed by the GFRU. Improvement in uniformity in PB-CTV definition and treatment homogeneity in the context of clinical trials are expected.

INTRODUCTION

Radical prostatectomy (RP) is one of the standard treatments for localized prostate cancer [1]. However, approximately one third of patients experience a biological recurrence within the decade following surgery [2,3].

Salvage radiotherapy is recommended for the management of biochemical relapse after RP [2-5]. The clinical target volume (CTV) for post-operative radiotherapy is the prostate bed (PB), sometimes extended to the pelvic lymph nodes [6]. However, after surgery, the delineation of the CTV is complex and subject to large intra- and inter-observer variations [7]. Four guidelines are already available, in order to assist the radiation oncologist with the delineation of the PB [8-11]. Nevertheless, these guidelines differ in several major points, such as the borders of the PB at the apex or at the base, limiting therefore an overall contouring agreement among the radiation oncology community. Moreover, use of modern imaging techniques like multiparametric magnetic resonance imaging (mpMRI) and more recently prostate-specific membrane antigen (PSMA) PET/CT have been implemented in the restaging workflow of relapsing prostate cancer, with a clear impact on treatment volume delineation [12-14].

The GFRU identified the need to generate new recommendations for PB delineation and a consensual atlas based on simple and reproducible anatomical landmarks, easy to be identified on planning computed tomography (CT) datasets.

MATERIALS AND METHODS

A group of 10 GFRU prostate radiation oncologists' experts (4 from France, 3 from Belgium, 1 from Switzerland, and 2 from Quebec-Canada) worked together for the definition of the PB, following a four-step procedure:

Step 1: PB delineation guidelines review

Four existing guidelines for PB-CTV delineation were analyzed: the European Organization for Research and Treatment of Cancer (EORTC) [9]; the Faculty of Radiation Oncology Genito-Urinary Group (FROGG) [10]; the Radiation Therapy Oncology Group (RTOG) [8]; and the Princess Margaret Hospital (PMH) [11] consensus guidelines. For the definition of each anatomical boundary of the PB, the four guidelines were compared and variations in PB definition were identified (*Table 1*).

Step 2: Literature review

The methodology used in this study was based on a critical, not systematic, review of the literature of the last three decades up to March 2020, on PubMed, to collect surgical, radiological, anatomical and/or histological information likely to help finding an accurate and converging definition of the delineation limits of the PB differing between the four guidelines.

Step 3: Magnetic resonance imaging (MRI)-based analysis of PB boundaries

For each boundary of the PB delineation, the GFRU group performed an analysis of 50 prostate T2-MRI series. Twenty-five patients have already had a prostatectomy and 25 different patients had an intact prostate gland.

Step 4: Consensus on PB definition and CT image

Based on the analysis of these four guidelines, the review of the literature and the analysis of the MRI acquisitions, a final consensus on limits for PB-CTV definition was reached among the 10 GFRU experts and a CT image atlas was proposed (maximum thickness of 3 mm for the continuous CT scan slices with an injection of contrast agent). The final consensus on these guidelines was established among the panelists after several meetings conducted from 2016 to prepare the GFRU contouring workshops.

RESULTS

INFERIOR LIMIT

Existing guidelines

Two landmark structures are commonly used to define the inferior limit of the PB-CTV delineation: the vesico-urethral anastomosis (VUA) with an additional margin below it [8,10,11] and the penile bulb [9-11]. The recommended limit to define the PB-CTV apex ranges on the different guidelines between 5 and 12 mm below the VUA. The distance from the cranial part of the penile bulb to the inferior limit of the PB-CTV also ranges from a minimum of one CT slice (thickness not defined) up to 15 mm.

Analysis of the literature

Urethrography has been used to define the prostate apex by providing a clear visualization of the penile urethra to the point where it enters the urogenital diaphragm [15]. The penile bulb, an easily identifiable soft tissue structure, lying immediately below the urogenital diaphragm of the pelvic floor, can be used as a surrogate landmark for the prostate apex [16,17]. Studies correlating the penile bulb location with the prostate apex, suggest an average distance between the two structures of 15 mm based on the MRI imaging [17]. Incorporation of this average distance into treatment planning has been associated with satisfactory target coverage of the apical region of the prostate [18].

Lock *et al.* compared on 10 patients the relative accuracy of urethrogram or penile bulb delineation as surrogate markers for the prostate apex [19]. The authors showed that the penile bulb can be used to identify the prostate apex, and that the measurements between the penile bulb and the apex are consistent between patients and through the course of treatment. Penile bulb can be reliably contoured between observers, ensuring a localization of the prostate apex comparable to urethrography [19].

MRI analysis

Apex-penile bulb distance

The distance between the prostate apex and the penile bulb measured on the 25 prostate T2-MRI acquisitions was on average 6.7 mm (range, 4.7-11 mm) (*Figure 1*). All the measurements were inferior to 15 mm in contrast with the results of the literature [17]. Using the EORTC definition (where the apex was localized at 15 mm from the

penile bulb) [9], the PB-CTV would not be correctly covered at the apex for all the 25 patients. For the three other guidelines [8,10,11], the first slice of PB-CTV corresponds to the first slice above the penile bulb. Assuming that the slice thickness of the planning CT does not exceed 5 mm, the PB-CTV apex would be correctly covered for all cases analyzed.

VUA-penile bulb distance

The distance between the VUA and the penile bulb was measured on the 25 post-operative T2-MRI acquisitions (*Figure 1*). This distance ranged from 10.3 mm to 27 mm, with an average of 18.4 mm. In the PMH, FROGG, and RTOG guidelines, the inferior limit of the PB-CTV is defined at 8 mm, 5-6 mm, and 8-12 mm below the VUA, respectively [8,10,11]. According to these three guidelines, on the 25 post-operative T2-MRI series, the most inferior slice of the PB-CTV delineation would be on average 9.6 mm (range, 2.3-19 mm), 12.1 mm (range, 4.8-21.5 mm), and 7.6 mm (range, 0.3-17 mm) above the penile bulb, respectively (*Figure 2*). In the present analysis on the 25 post-operative MRI acquisitions, major discrepancies compared to existing guidelines were demonstrated.

GFRU analysis

Identification of the VUA is not easy on CT imaging because of the postsurgical rearrangements and requires the use of an intravenous injection of contrast. Moreover, according with the measures above, there is some variability in the distance between the VUA and the penile bulb on post-prostatectomy MRI. Consequently, the current

definitions of the apex based on VUA (PMH, FROGG and RTOG) could be inappropriate to systematically cover the inferior limit of the PB-CTV as it has already been shown by Manji *et al.* [20].

The penile bulb is a structure easily identified on the CT imaging even without contrast injection and its position remains stable after RP. By starting the delineation of PB-CTV 5 mm above the penile bulb, the apical part of the PB-CTV was correctly covered on all 25 analyzed prostate MRI acquisitions.

GFRU definition

At its most inferior part the PB_CTV lies between the inferior limit located 5mm above the penile bulb. The posterior limit is represented by the anterior wall of the rectum or of the anal canal. The lateral and anterior limits are the pelvic muscles or the insertion of the corpora cavernosa (*Figure 4A*). These limits are in correlation with the other guidelines.

MIDDLE SECTION

Existing guidelines

The four guidelines propose very similar limits to delineate the middle section of the PB-CTV: the pubic symphysis anteriorly, the levator ani or the obturator internus muscles laterally, and the anterior rectal wall posteriorly [8-11]. A small variation is proposed by the RTOG and FROGG guidelines [8,10], which suggest that the posterior limit of the PB-CTV needs to be concave on both side of the rectum to better include the rectoprostatic angles [8,10].

Analysis of the literature

Nevoux *et al.* performed a quantitative tissue analysis of prostate cancer foci in an unselected series of 96 cysto-prostatectomy specimens [21]. They showed that 75% of the tumors are located in the peripheral zone [21]. In the middle part of the prostate, the tumors of more than 0.5 cc are mainly located in the peripheral zone and more specifically in the two posterolateral areas [21]. When target volumes were delineated using the RTOG guideline, the CTV coverage was marginal in the posterolateral regions near to the rectum and the mesorectal fascia [8]. In another series analyzing 121 surgical specimens, the extracapsular extension occurred postero-laterally along the neurovascular bundle in all analyzed cases [22]. These results clearly support the need to have a concave delineation of the posterior limit of the PB-CTV on both sides of the rectum.

MRI analysis

A specific-analysis of the available T2-MRI series was not found to be relevant for the delineation of the middle section of the PB-CTV.

GFRU analysis

Anteriorly and laterally, the four guidelines converge on similar recommendations based on the anatomical definition of the structures surrounding the prostate. Posteriorly,

the anterior rectal wall represents the limit. Based on the review of the literature, the two posterolateral recto-prostatic angles need to be included in the PB-CTV volume.

GFRU definition

In the middle section, the posterior limit of the PB-CTV is the anterior border of the rectum including the posterolateral angles on both sides of the rectum of 5 mm. The experts considered that it is a reasonable compromise to cover the risk of relapse and to limit the irradiation of the rectal wall. The lateral limits are the internal borders of the levator ani or of the obturator internus muscles. The muscles should not be included in the PB-CTV. The anterior limit is represented by the posterior border of the pubic symphysis (*Figure 4B, C*).

ANTERIOR UPPER LIMIT

Existing guidelines

Based on the EORTC guidelines [9], the anterior upper limit of the PB-CTV should include “the VUA and the urethral axis”. In the PMH and RTOG guidelines, this limit is represented by the top of the edge of the pubic bone [8,11]. In the FROGG guidelines [10], from the lower border of the PB-CTV to 3cm superior, the anterior border of the PB-CTV is the posterior aspect of the symphysis pubis. In these last three guidelines [8,10,11], at least 1.5 cm of the bladder neck must be included in the delineation (up to 2 cm in the RTOG guideline) [8].

Analysis of the literature

Based on the Nevoux *et al.* study [21], no significant tumor (> 0.1cc) is generally found on the pathological RP specimen in the upper anterior third of the prostate.

MRI analysis data based on the guidelines

On the 25 prostate MRI acquisitions, the length of contact between the prostate and the pubic bone was measured and the ratio between the length of this contact and the total length of the pubic bone was calculated. The ratio varied from one patient to another from 17% to 90%. However, in 80% of cases, this percentage was inferior to 66% (*Figure 3*).

GFRU analysis

In a study by Freitag *et al.*, 119 patients with biochemical recurrence after RP were restaged both with hybrid ^{68}Ga -PSMA-11-PET/CT_{low-dose} and PET/MRI including a multiparametric MRI (mpMRI) protocol of the PB [23]. The authors observed that the detection rate of local recurrences using the PET-component was significantly influenced by the proximity to the bladder, with the risk to miss relapses due to the ^{68}Ga -PSMA residual urinary radioactivity [23]. These findings were confirmed by another study by Achard *et al.* suggesting the added value of mpMRI imaging for the detection of PB recurrences compared to standard whole body hybrid ^{18}F -choline PET/MRI protocols [24]. Compared to PET, mpMRI was able to detect more local relapses (17 vs 14 patients over 58 analyzed), mostly located in the anastomotic region, the bladder neck and the SV bed [24].

In a systematic literature review concerning the current role of mpMRI in the detection of locoregional recurrence, Barchetti *et al.* reported that after RP, the most common site of local recurrence is the vesico-urethral anastomosis around the urinary bladder and/or membranous urethra [25]. Other common sites of local recurrence are retrovesical (between the urinary bladder and rectum), within retained SVs, at the anterior or lateral surgical margins of the prostatectomy bed (e.g., abutting the levator ani muscles) and at the resection site of the vas deferens [25].

Similar results were observed by Zilli *et al.* in a series of 171 prostate cancer patients relapsing after RP and restaged with an endorectal MRI before salvage radiotherapy [26]. Among the 131 patients with a positive MRI imaging, the perianastomotic (35.9%) and the bladder neck region (33.6%) were the most common sites of local recurrence, followed by penile bulb (19%) and the SV bed (3.8%) [26].

Based on the above studies, on the Nevoux *et al.* study [21] and the analysis on the 25 MRI acquisitions, the use of the top of the edge of the pubic bone as upper anterior limit of the PB-CTV seems to be a quite generous landmark. An upper limit located at 2/3 of the pelvic bone (closer to the FROGG definition [10]) appears a reasonable solution to cover the area at risk of relapse and to limit the volume of bladder included in the high-dose volume. In the three guidelines [8,10,11], a length of 1.5 cm of the bladder neck has to be included in the PB-CTV. This rule is necessary to cover the VUA and the interface between the prostate and the bladder. In the FROGG guideline [10], the PB-CTV must be extended by at least 3 cm from the lower slice of delineation. This minimal length is reasonable according to the size of the prostate and the necessity to cover at least 1.5 cm of bladder neck.

GFRU definition

Delineation of the upper anterior limit of the PB-CTV must fulfill three criteria (Figure 4D, E):

Criteria n°1: At least 1.5 cm of the bladder neck must be included in the PB-CTV.

Criteria n°2: The PB-CTV must cover the posterior border of the pubic bone on at least 2/3 of its length.

Criteria n°3: At least 3 cm are necessary between the lower and upper slices of delineation of the PB-CTV along the pubic bone.

When the three criteria are fulfilled, the anterior delineation of the CTV along the pubic bone is discontinued.

SEMINAL VESICLES BED

Existing guidelines

In the EORTC guidelines [9], delineation of the seminal vesicles (SV) bed is recommended only in case of SV invasion on the surgical specimen. The PB-CTV includes the original location of the SV. In the PMH guidelines [11], the PB-CTV is delineated up to the *vas deferens* (5 mm above the inferior border of the *vas deferens*) and must include all the surgical clips. The FROGG guidelines use the same limits but specify that residual SV must be included in the volume [10]. Lastly, in the RTOG guidelines the PB is delineated up to the *vas deferens*, or 3 to 4 cm above the top of the pubic symphysis and includes SV remnants if pathologically involved [8].

Analysis of the literature

In several studies on MRI analysis, the rate of involvement of the bottom of the SV is very low, ranging between 0% and 13%. In the Samaratunga *et al.* study, 16% of the SV invasions were located in the distal third of the SV [27]. Kestin *et al.* measured the length of cancer involvement from the prostate to the SV junction [28]. On the 81 pathologic specimens analyzed in this study, the risk of SV involvement beyond 2 cm was approximately 1% [28]. In another study on 71 patients treated with RP, 12 patients (17%) had a SV involvement but none of them had a pathological involvement of the last 1 cm of the SV [29].

MRI analysis

The distance between the distal part of the SV and the top of the pubic bone is used in the RTOG guidelines [8]. This definition is by far the easiest to apply. In the 25 prostate MRI acquisitions, the distance between the extremity of the SV and the top of the pubic symphysis was measured on average at 26.4 mm [range, 3-56.2 mm]. This distance was less than 4 cm and 3 cm in 84% and 76% of the cases, respectively.

GFRU analysis

The *vas deferens* arises from the testicle, following the epididymal canal and it ends at the confluence of the SV and the ejaculatory duct. The union between the *vas deferens* and the neck of the SV forms the ejaculatory duct at the base of the prostate. Using the *vas deferens* to define the upper border of the SV bed might present some

limitations:

- 1- The *vas deferens* is not always visible on the planning CT.
- 2- The surgical section of *vas deferens* may vary from a surgery (and surgeon) to another.
- 3- The *vas deferens* may retract upward and backward after RP.

For these reasons, *vas deferens* may not be the most appropriate anatomical landmark to define the upper limit of the delineation of the SV bed. According to the analysis of the 25 MRI acquisitions and the review of the literature, the RTOG definition [8] based on the top of pubic bone (+ 3cm) seems accurate, and highly reproducible.

GFRU definition

1. If SV are pathologically involved (*Figure 4F, I, J*):

The superior limit of delineation of the SV bed is defined at 3 cm above the top of the pubic symphysis. This limit can be extended up to 4 cm in case of involvement of the last third of the SV on the histopathological specimen. The posterior limit is the anterior border of the mesorectum. The GFRU recommends the inclusion of the posterior third of the bladder wall (with a thickness of 1cm) to better encompass the the SV bed. The lateral limits are the internal obturator muscles.

2. If SV are not pathologically involved (*Figure 4E, G, H*):

In order to cover the prostate-SV junction, the superior border of the SV bed is maintained to the first 1 cm above the pubic symphysis, keeping the same anterior, posterior and lateral limits used in case of SV involvement.

Considering the minimal risk of pathological involvement of the bottom part of the SV, the superior border limit of the SV bed can be reduced in order to respect the dose constraints to the rectum and the bladder.

DISCUSSION

Based on the existing literature, postoperative RT for prostate cancer is associated with a large interobserver variability in the PB-CTV contouring [30]. Systematic errors in PB-CTV definition may impact the final dosimetry and treatment delivery by translating into possible underdosage of the target and/or overdosage of the healthy tissues [30]. International guidelines have been developed to assist radiation oncologists in standardizing the contouring process and potentially reducing its variability [8-11].

Why is a new guideline necessary?

The present GFRU analysis of the existing guidelines shows some large variations in the limits of delineation of the PB-CTV which may induce significant variations in the doses delivered to the target and to the organs at risk [31]. Differences in methodology used for defining the PB-CTV in the four guidelines can explain this variability. The EORTC guidelines do not provide a precise description of the methodology used [9]. The PMH guidelines have been generated evaluating data based on the topography of the post-RP relapses, as well as based on radiological anatomy and surgical findings [11]. The FROGG guidelines are the result of an expert's debate on the PMH contouring atlas [10]. The RTOG atlas uses an algorithm to determine the PB-CTV borders taking into

consideration the site of post-RP relapse combined with surgical and anatomical data [8].

In the Malone *et al.* study [32], the four consensus guidelines were compared in 20 patients in terms of treatment volumes and organs at risk irradiation. The PB-CTV differed significantly between the four guidelines, allowing a potential impact on long-term clinical outcome and treatment-related toxicity [32]. The PB-CTV volume defined using the EORTC guidelines was significantly smaller than the CTVs defined using the other recommendations, with a more limited coverage of the PB in the anterior and superior directions [32]. In another study, Ost *et al.* analyzed the inter-observer variability in contouring the PB-CTV according to the EORTC guidelines [33]. They showed only a moderate observer agreement for both the PB-CTV (mean kappa, 0.49; range, 0.35–0.62) and the SV bed (mean kappa, 0.42; range, 0.22–0.59) [33].

Taking into consideration limitations and divergences of the existing guidelines, the GFRU defined the need for a new guideline and atlas, able to limit the inter-observer variations with well-defined anatomical limits easily identified by any physician.

Why a guideline based on CT imaging?

Matching postoperative MRI and CT may be challenging due to anatomical variations in the PB shape between the two exams. Based on these considerations, the GFRU experts' panel estimates that a guideline based on only one single imaging modality is more adapted to homogenize contouring of the PB-CTV among the radiation oncology community. As observed by Barkati *et al.* using the RTOG guidelines, defining the PB-CTV based on CT imaging resulted in a statistically significant lower inter-observer variability (mean dice similarity coefficient: 0.76) compared to a MRI-based

contouring (mean dice similarity coefficient: 0.66) [34]. The increasing use of mpMRI for restaging and radiotherapy planning, along with the diffusion among the radiation oncology community of educational platforms for contouring, are both expected to reduce this interobserver variability in PB definition.

What are the interests of this new guideline?

We applied a three-step methodology was applied based on the analysis of the existing guidelines and their discordances, on a review of the literature, and on the study of 50 MRI datasets. This guideline, written by experts in the field of prostate radiotherapy, is based on simple anatomical structures easy to be identified on a planning CT: the penile bulb, the bladder, the rectum, the mesorectum, the pubic symphysis, and the pelvic muscles. Anatomical boundaries more difficult to be identified on CT imaging or associated with a variable position in the pelvis (such *vas deferens* or the VUA) were avoided.

We acknowledge that a stronger methodology based on a systematic review of the literature, a larger panel of experts including specialists from other disciplines, and integration of agreement measures among the panelists, would have provided more robustness to our guidelines. However, a validation analysis of our consensus guidelines is actually ongoing using the available datasets from three contouring workshops organized annually from 2017 by the GFRU.

CONCLUSIONS

New recommendations for PB-CTV delineation based on simple anatomical boundaries and available as a CT image atlas are proposed by the GFRU for

postoperative prostate radiotherapy. Improvement in uniformity in PB-CTV definition and treatment homogeneity in the context of clinical trials are expected. Further validation of these consensus guidelines is ongoing based on the data of several contouring workshops organized by the GFRU with radiation oncologists from France, Belgium, Switzerland, and Morocco.

References

1. Hamdy FC, Donovan JL, Lane JA, et al. 10-year outcomes after monitoring, surgery, or radiotherapy for localized prostate cancer. *N Engl J Med* 2016;375:1415-1424.
2. Cornford P, Bellmunt J, Bolla M, et al. Eau-estro-siog guidelines on prostate cancer. Part ii: Treatment of relapsing, metastatic, and castration-resistant prostate cancer. *Eur Urol* 2017;71:630-642.
3. Pisansky TM, Thompson IM, Valicenti RK, et al. Adjuvant and salvage radiation therapy after prostatectomy: Astro/aua guideline amendment, executive summary 2018. *Pract Radiat Oncol* 2019;9:208-213.
4. Carrie C, Magne N, Burban-Provost P, et al. Short-term androgen deprivation therapy combined with radiotherapy as salvage treatment after radical prostatectomy for prostate cancer (getug-afu 16): A 112-month follow-up of a phase 3, randomised trial. *Lancet Oncol* 2019;20:1740-1749.
5. Shipley WU, Seiferheld W, Lukka HR, et al. Radiation with or without antiandrogen therapy in recurrent prostate cancer. *N Engl J Med* 2017;376:417-428.
6. Pollack A, Karrison TG, Balogh AG, et al. Short term androgen deprivation therapy without or with pelvic lymph node treatment added to prostate bed only salvage radiotherapy: The nrg oncology/rtog 0534 ssport trial 2018;102:1605.

7. Latorzeff I, Sargos P, Loos G, et al. Delineation of the prostate bed: The "invisible target" is still an issue? *Front Oncol* 2017;7:108.
8. Michalski JM, Lawton C, El Naqa I, et al. Development of rtog consensus guidelines for the definition of the clinical target volume for postoperative conformal radiation therapy for prostate cancer. *Int J Radiat Oncol Biol Phys* 2010;76:361-368.
9. Poortmans P, Bossi A, Vandeputte K, et al. Guidelines for target volume definition in post-operative radiotherapy for prostate cancer, on behalf of the eortc radiation oncology group. *Radiother Oncol* 2007;84:121-127.
10. Sidhom MA, Kneebone AB, Lehman M, et al. Post-prostatectomy radiation therapy: Consensus guidelines of the australian and new zealand radiation oncology genito-urinary group. *Radiother Oncol* 2008;88:10-19.
11. Wiltshire KL, Brock KK, Haider MA, et al. Anatomic boundaries of the clinical target volume (prostate bed) after radical prostatectomy. *Int J Radiat Oncol Biol Phys* 2007;69:1090-1099.
12. Amzalag G, Rager O, Tabouret-Viaud C, et al. Target definition in salvage radiotherapy for recurrent prostate cancer: The role of advanced molecular imaging. *Front Oncol* 2016;6:73
13. Mottet 2020 : <http://uroweb.org/guidelines/compilations-of-all-guidelines/>
14. Bhargava P, Ravizzini G, Chapin BF and Kundra V. Imaging biochemical recurrence after prostatectomy: Where are we headed? *AJR* 2020;214:1248-1258.
15. Schild SE, Wong W. The role of retrograde urethrography in the planning of prostate cancer radiotherapy. *Med Dosim* 1997;22:83-86.

16. Li XM, Gao XS, Guo XM, et al. Using ct imaging to delineate the prostatic apex for radiation treatment planning. *Chin J Cancer* 2010;29:914-922.
17. Plants BA, Chen DT, Fiveash JB, et al. Bulb of penis as a marker for prostatic apex in external beam radiotherapy of prostate cancer. *Int J Radiat Oncol Biol Phys* 2003;56:1079-1084.
18. Milosevic M, Voruganti S, Blend R, et al. Magnetic resonance imaging (mri) for localization of the prostatic apex: Comparison to computed tomography (ct) and urethrography. *Radiother Oncol* 1998;47:277-284.
19. Lock MI, Heinrichs A, Bhattacharya G, et al. The utility of penile bulb contouring to localise the prostate apex as compared to urethrography. *J Med Imaging Radiat Sci* 2018;49:76-83.
20. Manji M, Crook J, Schmid M, et al. Target volume definition for post prostatectomy radiotherapy: Do the consensus guidelines correctly define the inferior border of the ctv? *Rep Pract Oncol Radiother* 2016;21:525-531.
21. Nevoux P, Ouzzane A, Ahmed HU, et al. Quantitative tissue analyses of prostate cancer foci in an unselected cystoprostatectomy series. *BJU Int* 2012;110:517-523.
22. Chao KK, Goldstein NS, Yan D, et al. Clinicopathologic analysis of extracapsular extension in prostate cancer: Should the clinical target volume be expanded posterolaterally to account for microscopic extension? *Int J Radiat Oncol Biol Phys* 2006;65:999-1007.
23. Freitag MT, Radtke JP, Afshar-Oromieh A, et al. Local recurrence of prostate cancer after radical prostatectomy is at risk to be missed in ⁶⁸Ga-PSMA-11-PET of

- PET/CT and PET/MRI: comparison with mpMRI integrated in simultaneous PET/MRI. *Eur J Nucl Med Mol Imaging* 2017;44(5):776-87.
24. Achard V, Lamanna G, Denis A, et al. Recurrent prostate cancer after radical prostatectomy: restaging performance of 18F-choline hybrid PET/MRI. *Med Oncol* 2019;36:67.
25. Barchetti F and Panebianco V. Multiparametric MRI for recurrent prostate cancer post radical prostatectomy and postradiation therapy. *BioMed Res Int* 2014:316272.
26. Zilli T, Jorcano S, Peguret N, et al. Results of dose-adapted salvage radiotherapy after radical prostatectomy based on an endorectal MRI target definition model. *Am J Clin Oncol* 2017;40:194-9.
27. Samaratunga H, Samaratunga D, Perry-Keene J, et al. Distal seminal vesicle invasion by prostate adenocarcinoma does not occur in isolation of proximal seminal vesicle invasion or lymphovascular infiltration. *Pathology* 2010;42:330-333.
28. Kestin L, Goldstein N, Vicini F, et al. Treatment of prostate cancer with radiotherapy: Should the entire seminal vesicles be included in the clinical target volume? *Int J Radiat Oncol Biol Phys* 2002;54:686-697.
29. Korman HJ, Watson RB, Civantos F, et al. Radical prostatectomy: Is complete resection of the seminal vesicles really necessary? *J Urol* 1996;156:1081-1083.
30. Foppiano F, Franzone P, Bertoni F, et al. Airo pros 01– 04 multi-centric study in contouring ctv for conformal radiotherapy after radicalprostatectomy. *Int J Radiat Oncol Biol Phys* 2006;66:S358.

31. Croke J, Malone S, Roustan Delatour N, et al. Postoperative radiotherapy in prostate cancer: The case of the missing target. *Int J Radiat Oncol Biol Phys* 2012;83:1160-1168.
32. Malone S, Croke J, Roustan-Delatour N, et al. Postoperative radiotherapy for prostate cancer: A comparison of four consensus guidelines and dosimetric evaluation of 3d-crt versus tomotherapy imrt. *Int J Radiat Oncol Biol Phys* 2012;84:725-732.
33. Ost P, De Meerleer G, Vercauteren T, et al. Delineation of the postprostatectomy prostate bed using computed tomography: Interobserver variability following the eortc delineation guidelines. *Int J Radiat Oncol Biol Phys* 2011;81:e143-149.
34. Barkati M, Simard D, Taussky D, et al. Magnetic resonance imaging for prostate bed radiotherapy planning: An inter- and intra-observer variability study. *J Med Imaging Radiat Oncol* 2016;60:255-259.

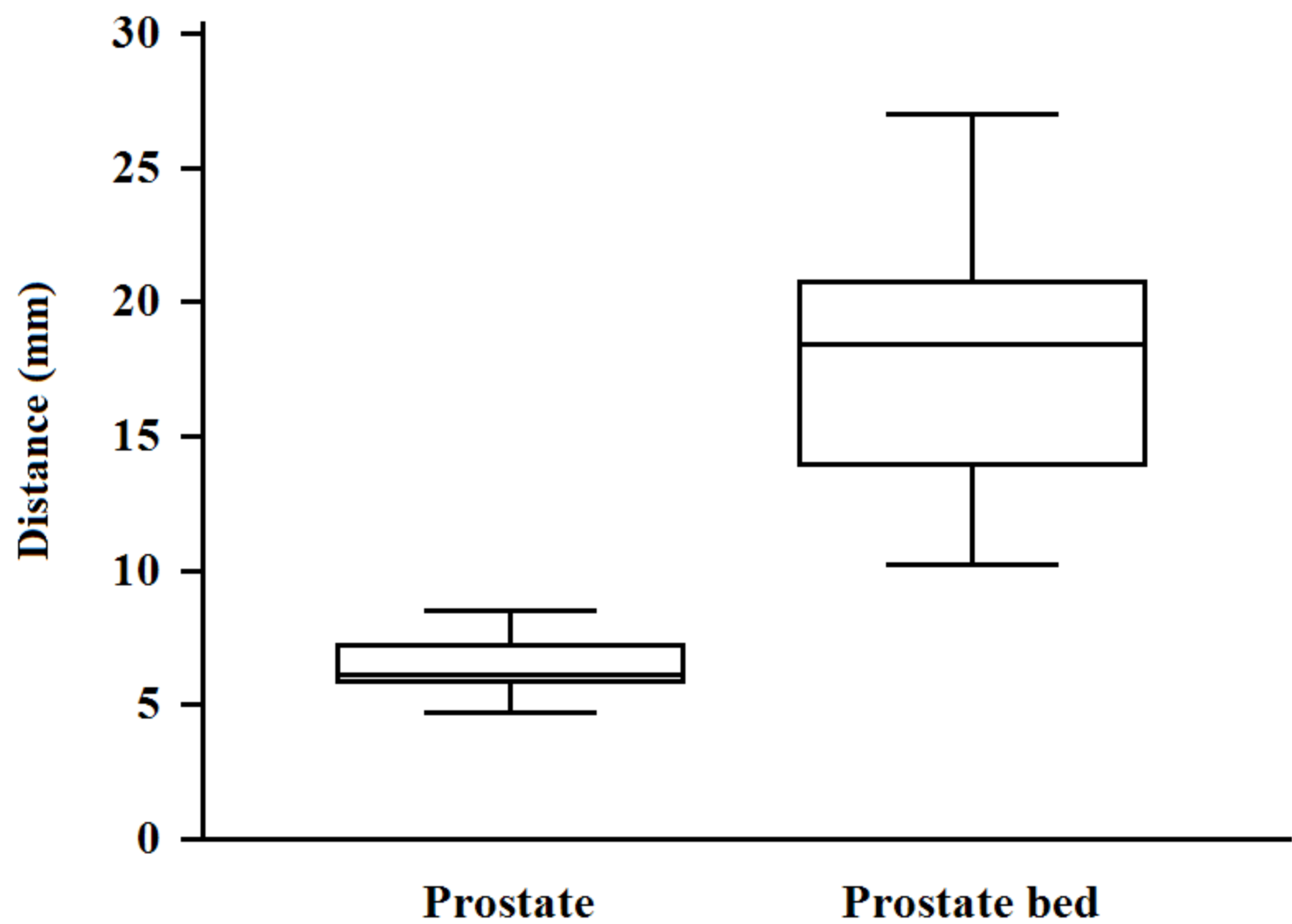
Figure legends

Figure 1. Average distance with range (in mm) between the penile bulb and the apex on 25 prostate magnetic resonance imaging (MRI) studies (left), and between the penile bulb and the vesico-urethral anastomosis on 25 post-operative MRI (right).

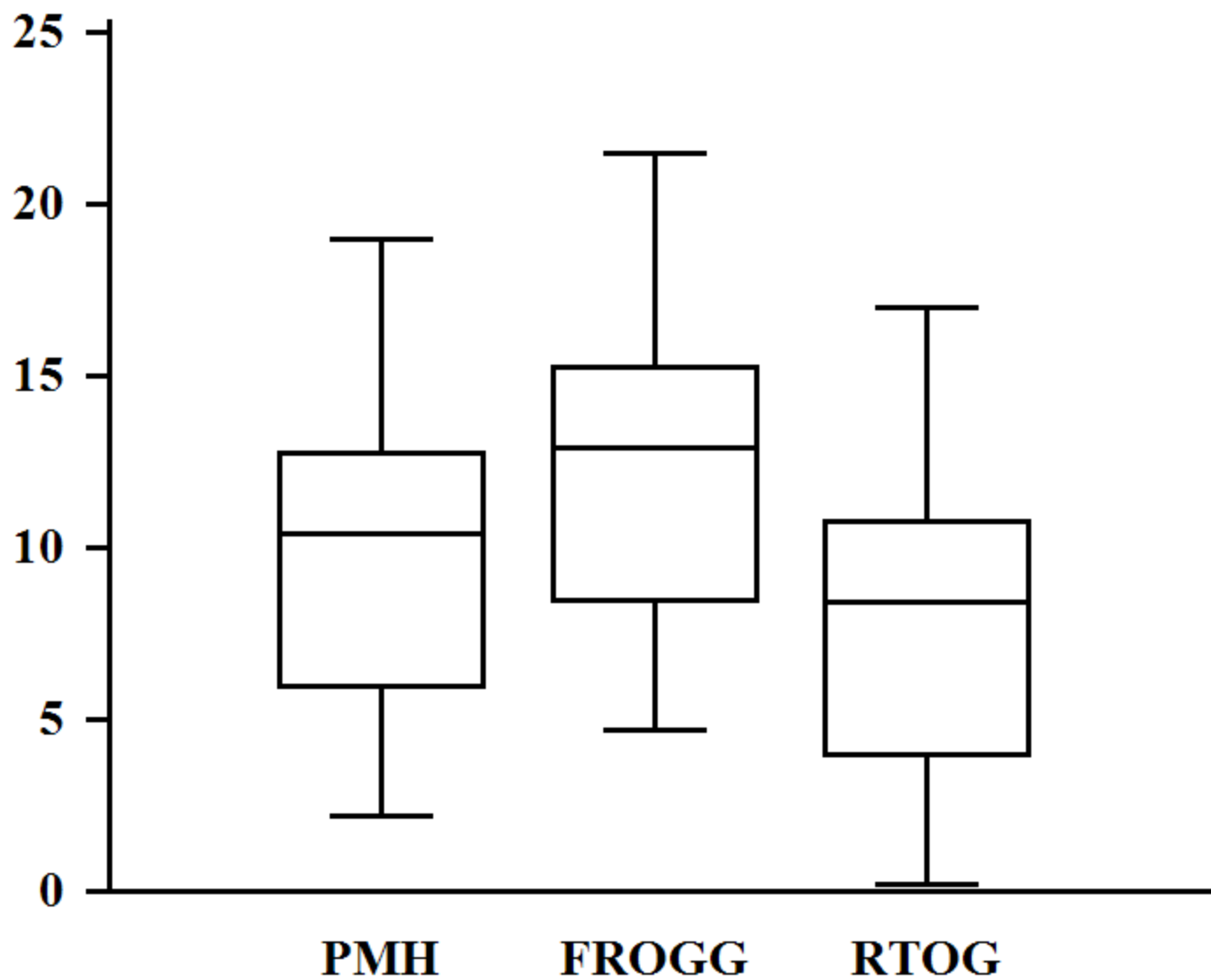
Figure 2. Average distance with range (in mm) between the inferior border of the prostate bed and the penile bulb on 25 post-operative MRI studies as defined by the Princess Margaret Hospital (PMH) [11], Faculty of Radiation Oncology Genito-Urinary Group (FROGG) [10], and Radiation Therapy Oncology Group (RTOG) [8] guidelines.

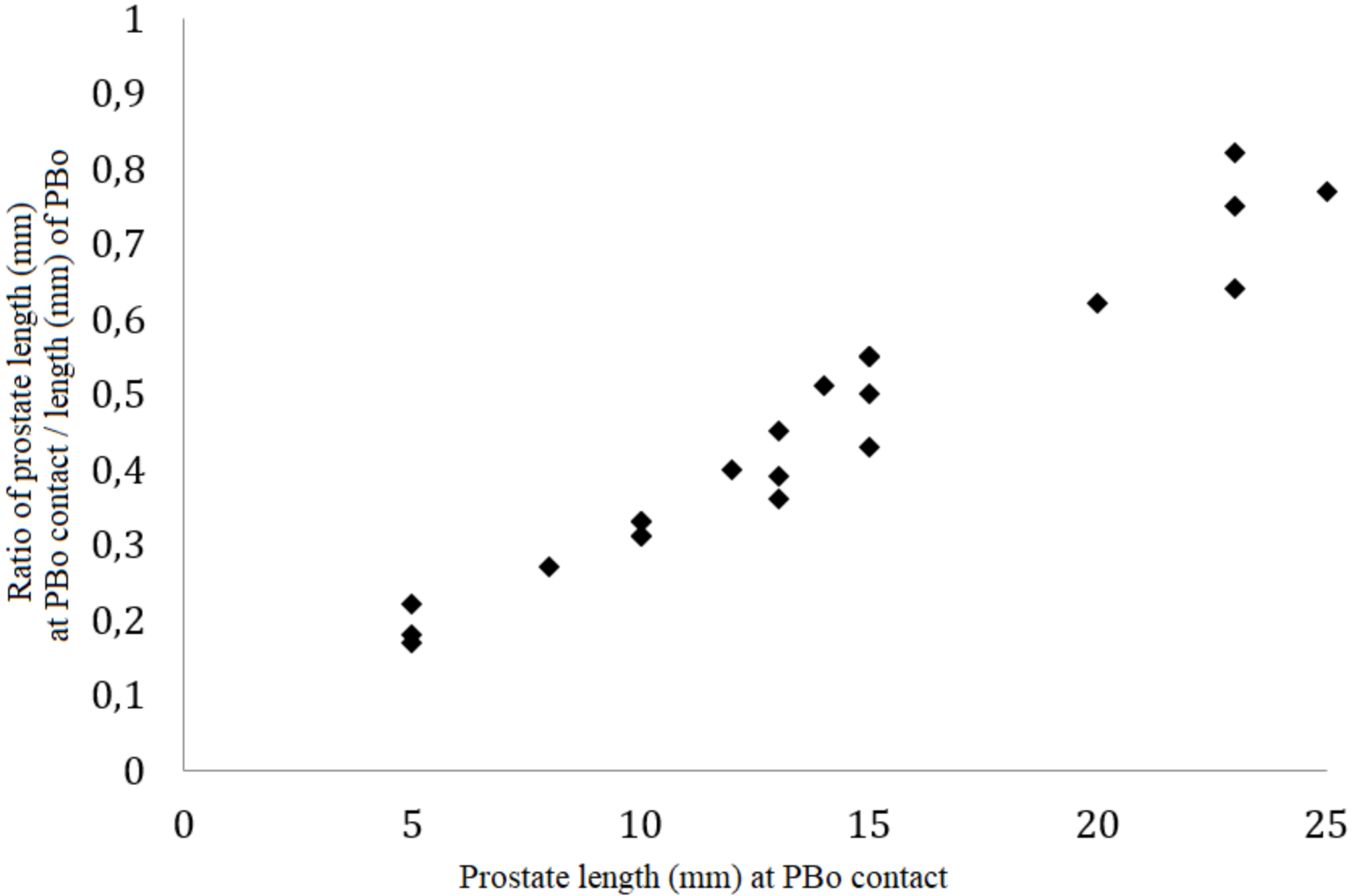
Figure 3. Ratio of the length (in mm) of the prostate in contact with the pubic bone (PBo) and the total length (in mm) of the PBo as measured on 25 prostate MRI studies.

Figure 4. Computed tomography-based atlas for prostate bed clinical target delineation based on the GFRU consensus guidelines.



Distance (mm)





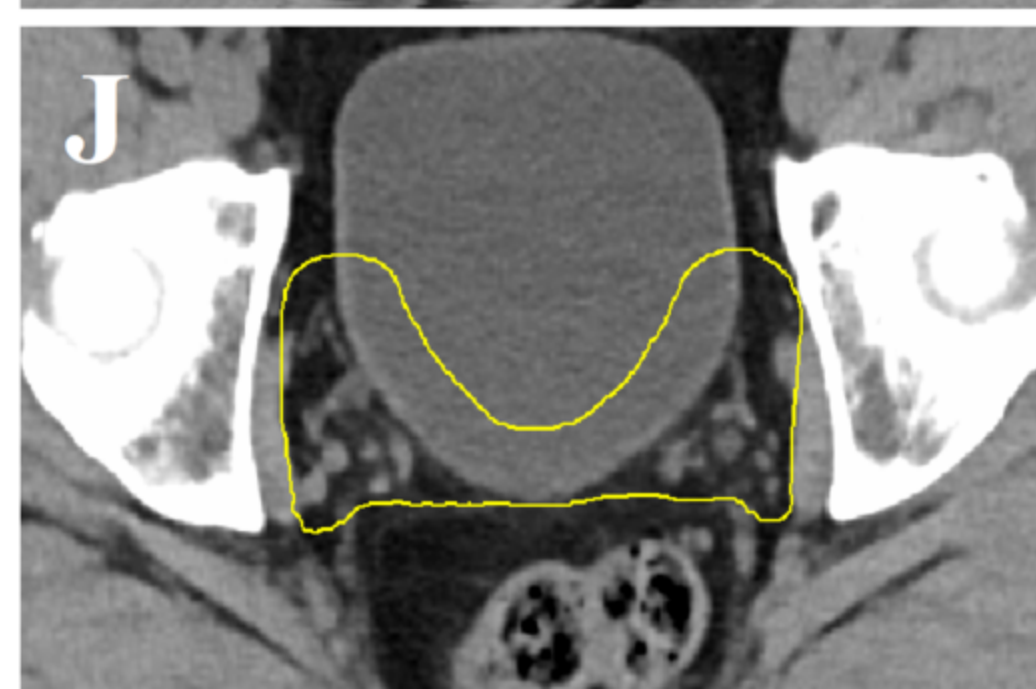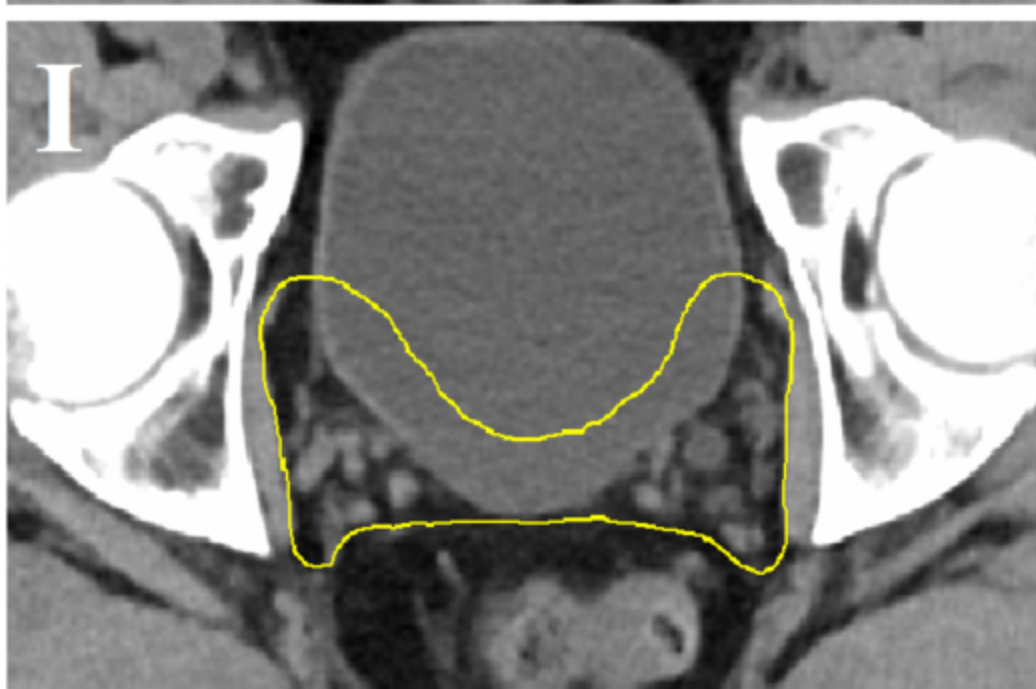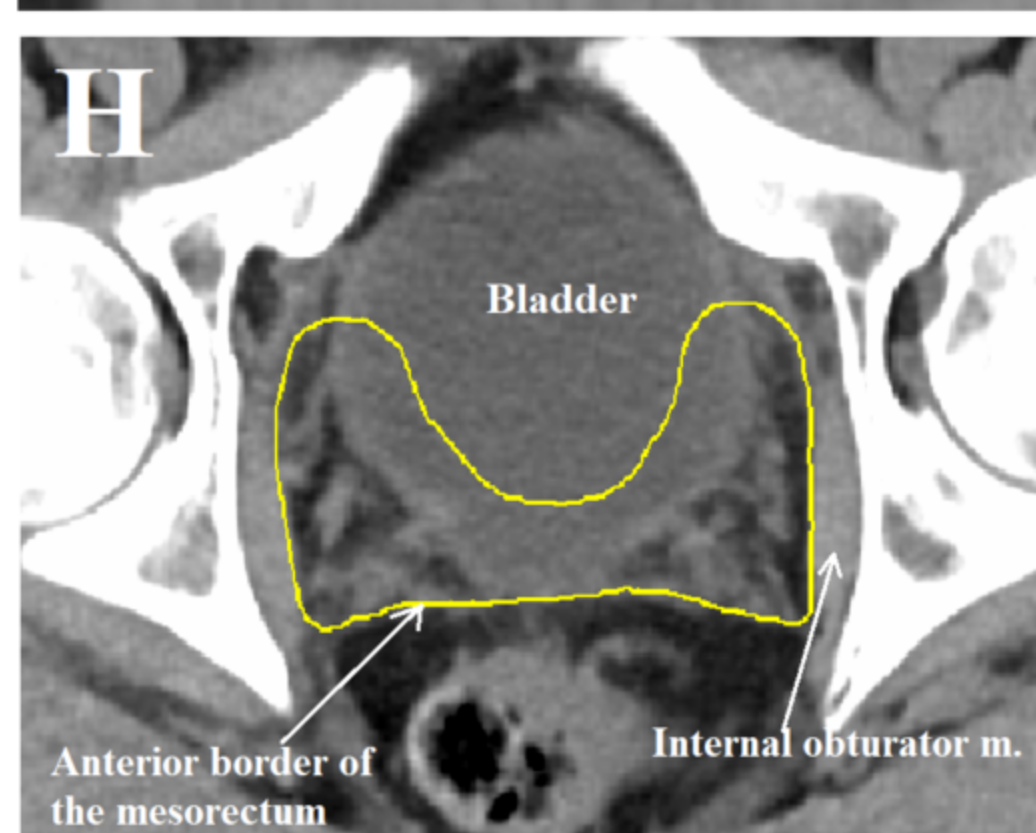
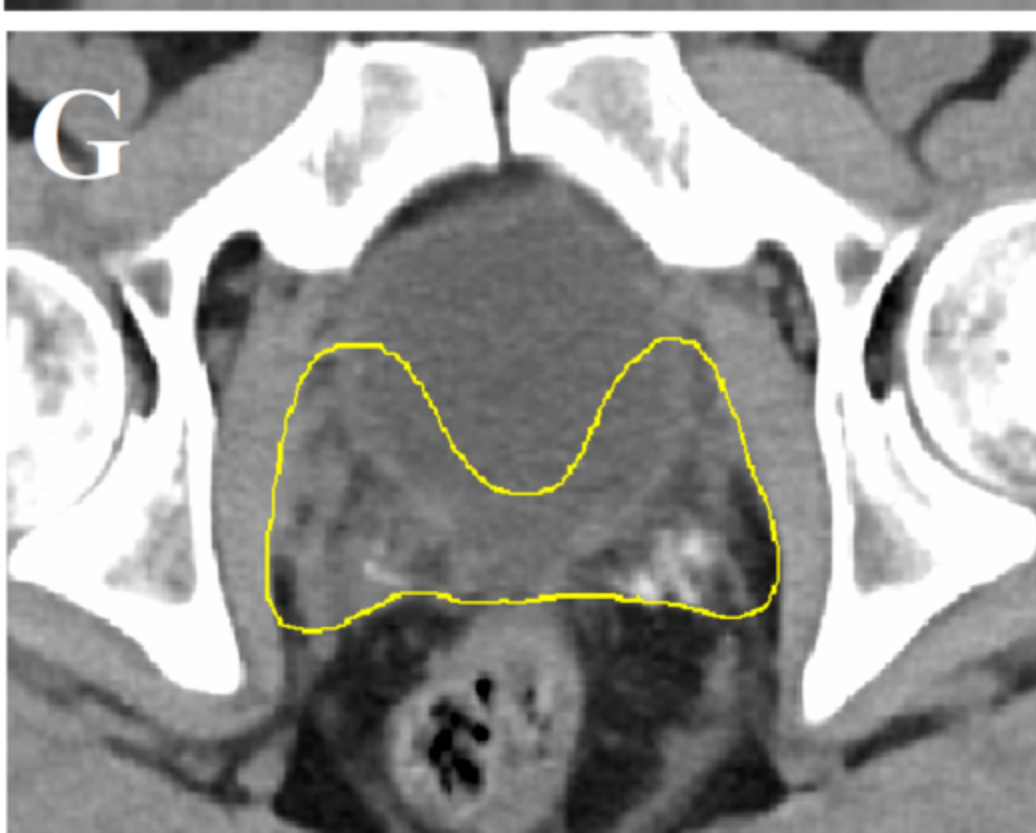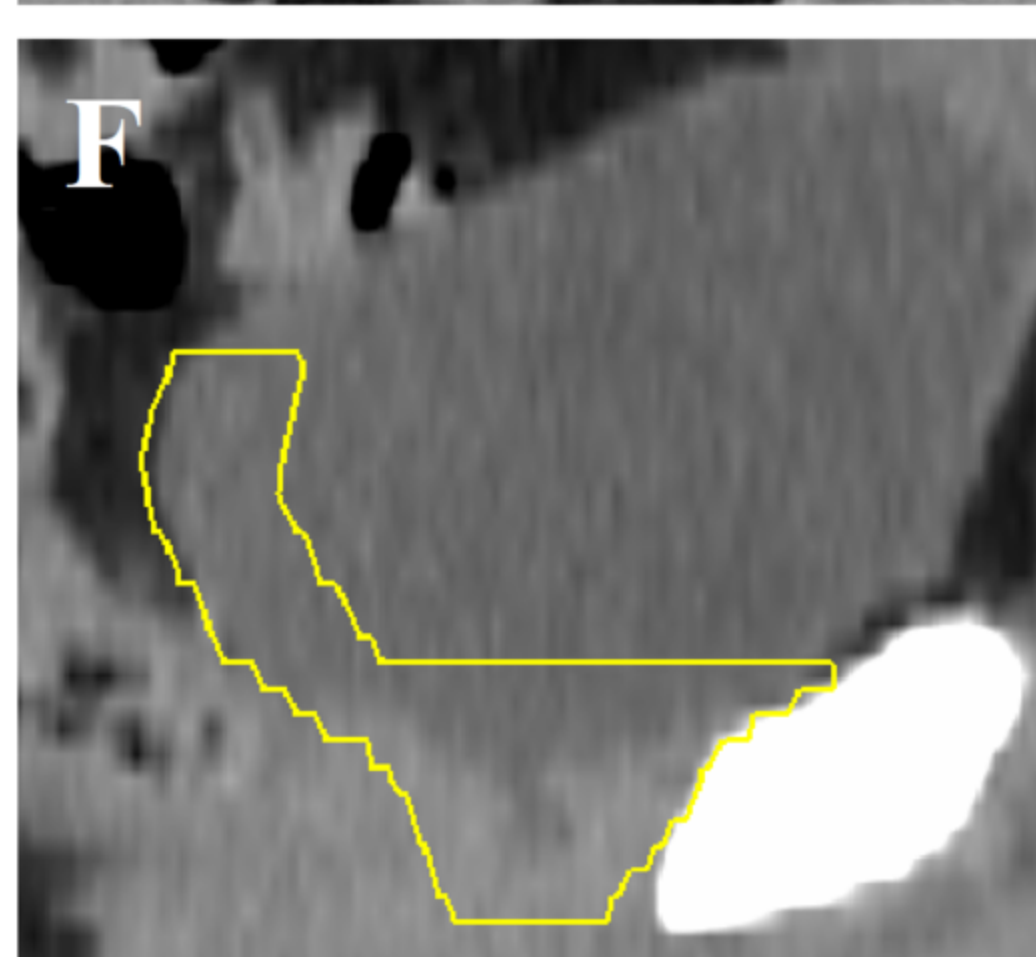
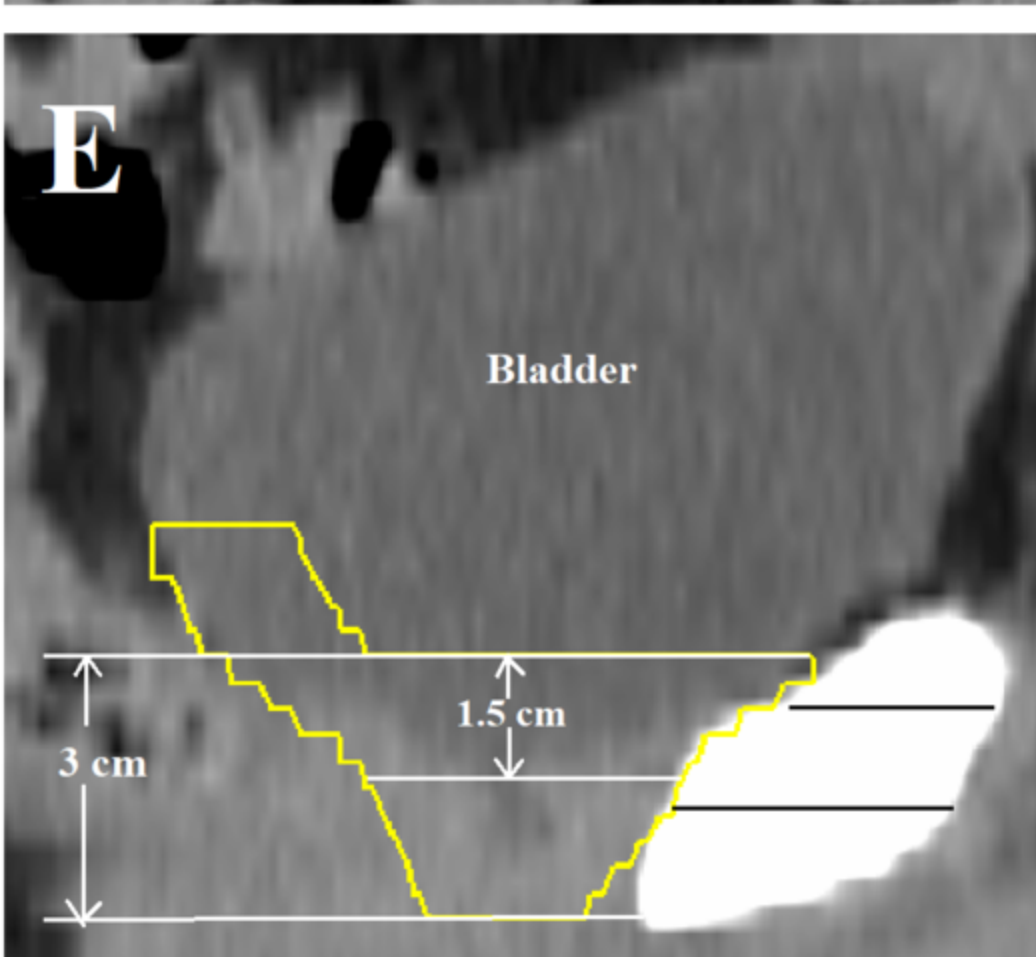
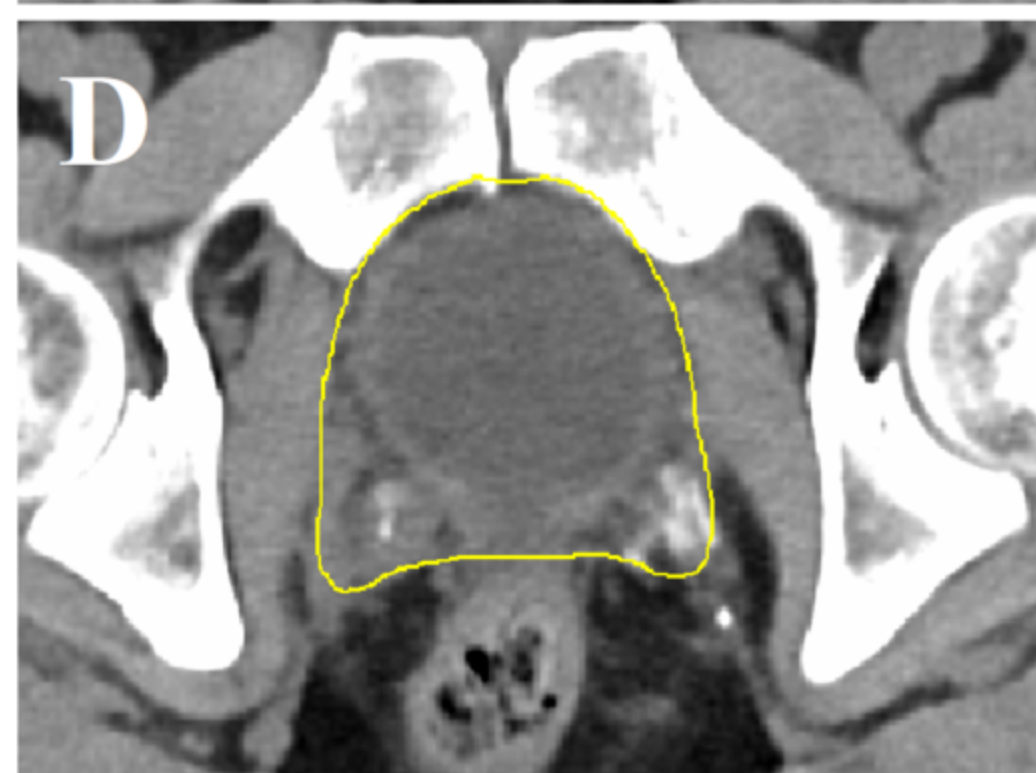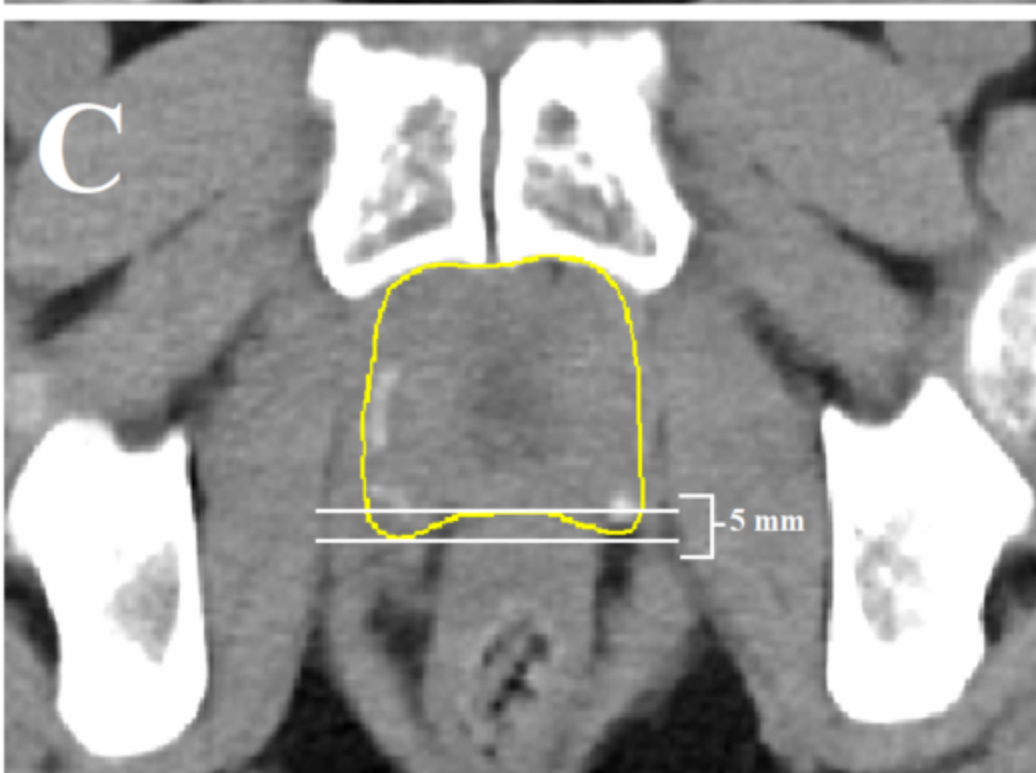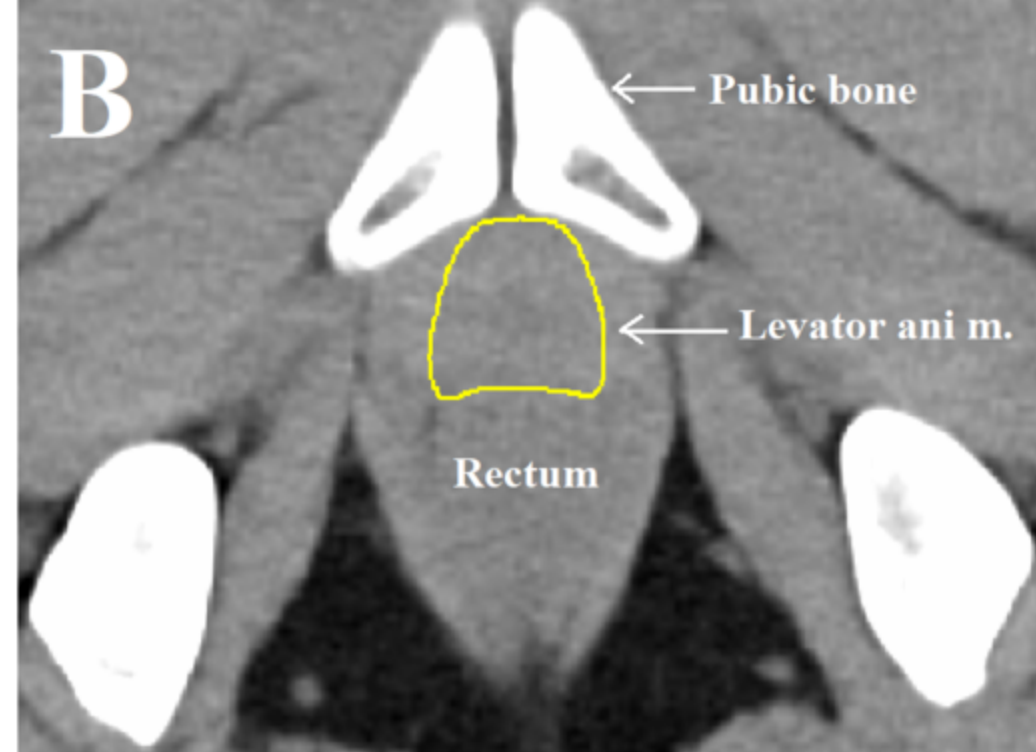


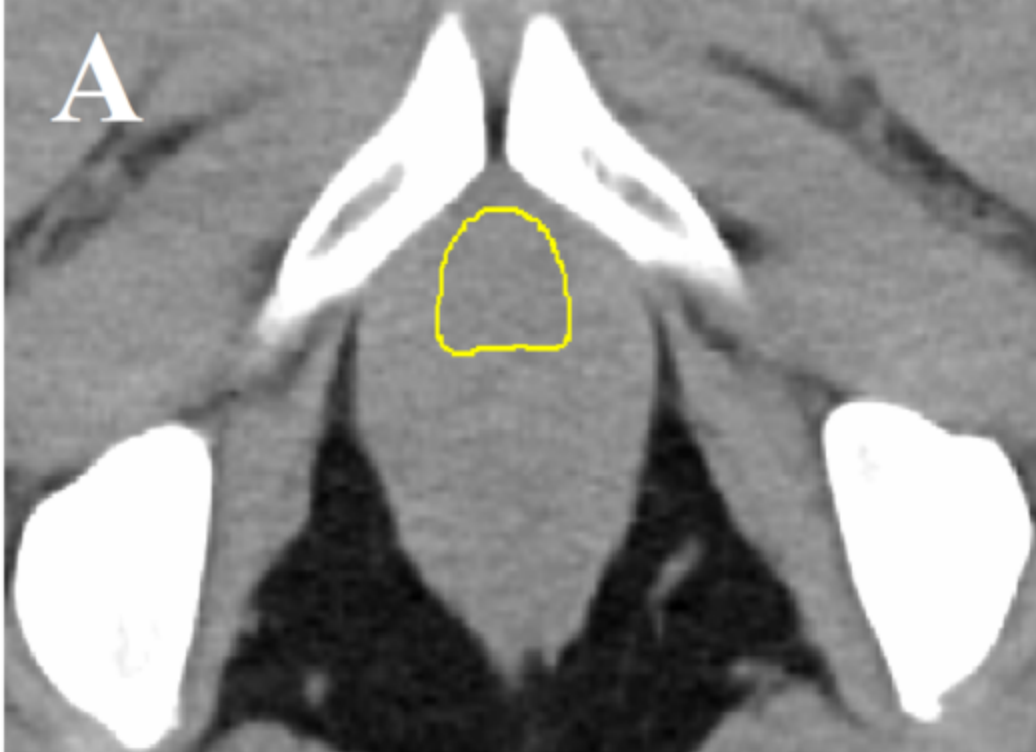Table 1. Consensus guidelines for post-operative prostate bed clinical target delineation.

	Inferior border	Anterior border	Lateral border	Posterior border	Superior border
EORTC [9]	Including the apex. 15 mm cranially from the penile bulb.	Including the anastomosis and the urethral axis.	Up to the neurovascular bundles (if removed : up to the ilio-obturatoric muscles).	Up to but not including the outer rectal wall. Cranially including the most posterior part of the bladder neck	Include the bladder neck. For patients with invasion of the seminal vesicles, the prostate bed including the apex and the original location of the seminal vesicles.
PMH [11]	8mm below the vesicourethral anastomosis or the top of the penile bulb.	-Caudal boundary : Posterior edge of the symphysis pubis up to the top of the symphysis pubis. -Cranial boundary : The posterior 1.5 cm of the bladder wall.	-Cranial boundary : The sacro-recto-genitopubic fascia, lateral to the neurovascular structures. At the cranial aspect of the CTV, it is not necessary to extend to the obturator muscle. -Caudal boundary : the medial border of the levator ani and obturator internus.	-Cranial boundary : the mesorectal fascia. -Caudal boundary : the anterior border of the rectal wall and levator ani.	The superior surgical clips (if present) or 5mm above the inferior border of the <i>vas deferens</i> . Retained seminal vesicles were included when pathologically involved.
FROGG [10]	5-6mm below the vesicourethral anastomosis but should extended lower to include all surgical clips inferiorly. When the anastomosis is not clearly defined, the inferior border will be the slice above the penile bulb.	-From the lower border of the CTV to 3cm superior, the anterior border of the CTV is the posterior aspect of the symphysis pubis. -More superiorly, the anterior border of the CTV encompasses the posterior 1.5cm of the bladder.	The medial border of the levator ani muscle or obturator internus muscle.	The space delineated by the levator ani and anterior rectal wall is at risk of recurrence and should be encompassed in the CTV if rectal dose constraints allow. Ensure a minimum 2 cm margin from the posterior extent of the CTV to the posterior rectal wall to prevent the entire circumference of rectum receiving the full radiation dose. More superiorly, the posterior border of the CTV is the anterior mesorectal fascia.	The superior border should encompass all of the vesicle seminal bed as defined by non-vascular clips and should include the distal portion of the <i>vas deferens</i> (usually visualised superiorly as thin, horizontal cylindrical structures). If the seminal vesicles are pathologically involved by tumour, ensure any residual vesicles are also included in CTV.

<p>RTOG [8]</p>	<p>8-12 mm below vesicourethral anastomosis. May include more if concern for apical margins (respecting penile bulb).</p>	<p>-Below the superior edge of the symphysis pubis : Posterior edge of pubic bone.</p> <p>-Above the superior edge of the symphysis pubis : Posterior 1-2cm of bladder wall.</p>	<p>-Above the superior edge of the symphysis pubis : Sacrorectogenitopubic fascia. If concern about extraprostatic disease at base may extend to obturator internus.</p> <p>-Below the superior edge of the symphysis pubis : Levator ani muscles, obturator internus muscles.</p>	<p>-Above the superior edge of the symphysis pubis : Mesorectal fascia.</p> <p>-Below the superior edge of the symphysis pubis : Anterior rectal wall. May need to be concave around lateral aspects.</p>	<p>Level of cut end of <i>vas deferens</i> or 3-4 cm above top of symphysis. Vas may retract postoperatively. Include seminal vesicle remnants if pathologically involved.</p>
<p>GFRU</p>	<p>5 mm above the PB. The posterior limit is the anterior wall of the rectum or of the anal canal. The lateral and anterior limits are the pelvic muscles or the insertion of the corpus cavernosum.</p>	<p>Delineation of the upper anterior limit of the PB-CTV must fulfill three criteria : -At least 1.5 cm of the bladder neck must be included in the PB-CTV. -The PB-CTV must cover the posterior border of the pubic bone on at least 2/3 of its length. -At least 3 cm are necessary between the lower and upper slices of delineation of the PB-CTV along the pubic bone. When the three rules criteria are fulfilled, the anterior delineation of the CTV along the pubic bone is discontinued.</p>	<p>Internal borders of the levator ani or obturator internus muscles. The muscles are not included in the volume of delineation.</p>	<p>The anterior border of the rectum including the posterolateral angles in both sides of the rectum in 5 mm.</p>	<p>-If SV are pathologically involved : The superior limit of delineation of the SV bed is defined at 3 cm above the top of the pubic symphysis. This limit can be extended up to 4 cm in case of involvement of the last third of the SV on the histopathological specimen. The GFRU recommends the inclusion of the posterior third of the bladder wall (with a thickness of 1cm) to better encompass the the SV bed.</p> <p>-If SV are not pathologically involved : The superior border of the SV bed is reduced to the first 1 cm above the pubic symphysis, keeping the same anterior, posterior and lateral limits used in case of SV involvement.</p>