



**HAL**  
open science

# Detection of Myocardial Infarction by Cardiac Magnetic Resonance in Embolic Stroke Related to First Diagnosed Atrial Fibrillation

Adrien Artus, Romain Didier, Margaux Blain, Pierre Comby, Thibault Leclercq, Hugo Debeaumarché, Frédéric Ricolfi, Marianne Zeller, Yannick Bejot, Alexandre Cochet, et al.

## ► To cite this version:

Adrien Artus, Romain Didier, Margaux Blain, Pierre Comby, Thibault Leclercq, et al.. Detection of Myocardial Infarction by Cardiac Magnetic Resonance in Embolic Stroke Related to First Diagnosed Atrial Fibrillation. *Journal of Stroke and Cerebrovascular Diseases*, 2021, 30 (6), pp.105753. 10.1016/j.jstrokecerebrovasdis.2021.105753 . hal-03611687

**HAL Id: hal-03611687**

**<https://hal.science/hal-03611687>**

Submitted on 24 Apr 2023

**HAL** is a multi-disciplinary open access archive for the deposit and dissemination of scientific research documents, whether they are published or not. The documents may come from teaching and research institutions in France or abroad, or from public or private research centers.

L'archive ouverte pluridisciplinaire **HAL**, est destinée au dépôt et à la diffusion de documents scientifiques de niveau recherche, publiés ou non, émanant des établissements d'enseignement et de recherche français ou étrangers, des laboratoires publics ou privés.



Distributed under a Creative Commons Attribution - NonCommercial 4.0 International License

## Detection of myocardial infarction by cardiac magnetic resonance in embolic stroke related to first diagnosed atrial fibrillation

Adrien Artus<sup>a</sup>, Romain Didier<sup>a</sup>, Margaux Blain<sup>a</sup>, Comby Pierre<sup>b</sup>, Thibault Leclercq<sup>a,b</sup>, Hugo Debeaumarché<sup>a</sup>, Frédéric Ricolfi<sup>b</sup>, Marianne Zeller<sup>c</sup>, Yannick Bejot<sup>d</sup>, Alexandre Cochet<sup>b</sup>, Yves Cottin<sup>a,\*</sup>

<sup>a</sup> Department of Cardiology, Dijon University Hospital, 21000 Dijon, France;

<sup>b</sup> Department of Imagery, Dijon University Hospital, 21000, France;

<sup>c</sup> PEC2 Research Team, EA 7460, Department of Health Sciences, University of Burgundy, 21000 Dijon, France;

<sup>d</sup> Department of Neurology, Dijon University Hospital, 21000, France;

\*Correspondence: [yves.cottin@chu-dijon.fr](mailto:yves.cottin@chu-dijon.fr);

Tel.: +33-380293536

Fax: +33-380293879

**Key words** : Atrial fibrillation, Ischemic stroke, myocardial infarction, myocardial injury.

Dr Adrien Artus<sup>a</sup>, [adrien.artus@chu-dijon.fr](mailto:adrien.artus@chu-dijon.fr), 03 80 29 30 31,

Dr Romain Didier<sup>a</sup>, [romain.didier@chu-dijon.fr](mailto:romain.didier@chu-dijon.fr) 03 80 29 30 31

Dr Margaux Blain<sup>a</sup>, [margaux.blain@chu-dijon.fr](mailto:margaux.blain@chu-dijon.fr) 03 80 29 30 31

Dr Comby Pierre<sup>b</sup>, [comby.pierre@chu-dijon.fr](mailto:comby.pierre@chu-dijon.fr) 03 80 29 30 31

Dr Thibault Leclercq<sup>a,b</sup>, [thibault.leclercq@chu-dijon.fr](mailto:thibault.leclercq@chu-dijon.fr) 03 80 29 30 31

Dr Hugo Debeaumarché<sup>a</sup>, [hugo.debeaumarche@chu-dijon.fr](mailto:hugo.debeaumarche@chu-dijon.fr) 03 80 29 30 31

Pr Frédéric Ricolfi<sup>b</sup>, [frederic.ricolfi@chu-dijon.fr](mailto:frederic.ricolfi@chu-dijon.fr) 03 80 29 30 31

Pr Marianne Zeller<sup>c</sup>, [marianne.zeller@chu-dijon.fr](mailto:marianne.zeller@chu-dijon.fr) 03 80 29 30 31

Pr Yannick Bejot<sup>d</sup>, [yannick.bejot@chu-dijon.fr](mailto:yannick.bejot@chu-dijon.fr) 03 80 29 30 31

Pr Alexandre Cochet<sup>b</sup>, [alexandre.cochet@chu-dijon.fr](mailto:alexandre.cochet@chu-dijon.fr) 03 80 29 30 31

Pr Yves Cottin, [yves.cottin@chu-dijon.fr](mailto:yves.cottin@chu-dijon.fr) +33-380293536

## **Abstract**

### **Introduction**

Elevated troponin levels are found in a significant number of patients who are diagnosed with acute embolic stroke (AES) after first diagnosed atrial fibrillation (AF). These myocardial injuries, which are known as cardiocerebral infarction (CCI), are potentially caused by coronary embolism and correspond to simultaneous cardiac and cerebral embolisms. However, this severe condition remains poorly understood. In this prospective study, we aimed to investigate the prevalence and the cardiac magnetic resonance (CMR) characteristics of CCI.

**Materials and methods** Consecutive patients with first diagnosed AF hospitalized for AES in a neurovascular intensive care unit from 2019 to 2020 were included. Troponin Ic kinetic were measured <72h, MRI and coronary angiography or CT scan were performed <7 days after admission. Patients with significant coronary lesions were excluded.

**Results** During the study period, 1150 patients with strokes were hospitalized in the neurovascular intensive care unit (ICU). Of these patients, 955 had an ischemic stroke and 97 had a transient ischemic attack. Among the 44 patients with AES and with first diagnosed AF, 34 patients underwent CMR and CMR analysis identified 12 MI. A significant rise in troponin ( $>0.10 \mu\text{g/L}$ ) was observed in 35% of the total population (12/34 patients). More specifically, a rise was seen in 23% of the AES without MI group, 58 % of the AES with MI. In addition, coronary embolism was identified in 3 patients who underwent coronary angiography (3/12) and MI was often (30%) localized in infero-latero-medial and infero-apical segments. Most AES were localized in the superficial sylvian territory.

**Conclusion** We found a high prevalence of CMR-confirmed double embolization sites in the acute phase of an embolic stroke. Further studies are required to better characterize the pathophysiology, clinical course and prognostic value of CCI. Moreover, optimal management strategies, including antiplatelet therapy, remain to be determined.

**Key words :** Atrial fibrillation, Ischemic stroke, myocardial infarction, myocardial injury.

## **Introduction**

Systemic arterial emboli resulting from atrial fibrillation (AF) can affect multiple vascular territories, including the brain (acute embolic stroke (AES)), the eyes, the kidneys, the digestive system, the spinal cord and peripheral arteries of the lower limbs, and to a lesser extent the upper limbs (1-3, 39, 40).

However, coronary emboli as a cause of associated AES and acute myocardial infarction (MI) has not been well described, and the diagnosis of coronary emboli (CE) remains difficult despite a proposed diagnostic tool based on angiographic and clinical criteria (Table 1) (4,5). In a retrospective study including 1 776 patients with acute MI, 2.9% were related to CE (mainly caused by atrial fibrillation), infectious endocarditis, myxoma, or thrombosis on the mechanical valves (5).

In the absence of coronary lesions on coronary angiography, cardiac magnetic resonance imaging (CMR) with gadolinium injection and late enhancement sequence analysis can be used to obtain a diagnosis of MI, in particular in CE-related MI. CMR analysis also helps to identify the presence of other embolization sites in agreement with the Shibata criteria, which underline the importance of evaluating concomitant criteria on several sites (e.g. myocardium and brain) (Table 1) (5, 16). Moreover, CMR analysis provides key information relative to the temporality of myocardial necrosis, distinguishing between the acute phase and older sequelae.

The concept of cardio-cerebral infarction (CCI), which is considered a rare event during which a double embolism concomitantly causes AES and CE-related MI, has not been thoroughly investigated, though case reports have been published (39). In these studies, the localization of cardiac and cerebral embolisms was based on the co-occurrence of signs of ischemic stroke and clinical or ECG signs of MI, which led to emergency coronary angiography. However, to the best of our knowledge, no prospective study has been performed on systematic screening for acute dual cardiac and cerebral embolism.

In patients with AES, using CMR-based diagnosis, the goals of our prospective single-center study were:

- 1 / to assess the prevalence of CCI
- 2 / to characterize myocardial and brain injuries associated with dual embolism.

## **Material and methods**

### **Study population**

All consecutive patients with AES, i.e. ischemic stroke related to first diagnosed AF (43), hospitalized in the neurovascular intensive care unit (ICU) of the Dijon Bourgogne University Hospital from January 2019 to June 2020. Acute ischemic stroke and AES were defined according to TOAST criteria (6).

The exclusion criteria were as follows:

- Contraindication to CMR (non-MRI compatible pacemaker, patient unable to hold breath for at least 10 seconds, claustrophobia)
- History of coronary artery disease, stented or under medical treatment.
- Chronic anticoagulants and/or anti-platelet medications before admission.
- Coronary stenosis >25% on coronary angiography or cardiac CT.

## **Methodology**

On admission to the neurovascular ICU, patients underwent clinical examination. Continuous ECG monitoring was obtained for at least 72H (PHILIPS intellivue MP5), and blood samples were taken every 8H for 72H for kinetic analysis of the troponin Ic levels (VISTA SIEMENS, ULN > 0.10 µg/L).

“First diagnosed AF” was defined as AF not diagnosed in the patient’s past medical history, irrespective of its duration or the presence/severity of AF-related symptoms (43). Paroxysmal AF terminates spontaneously or with intervention within 7 days of onset, and persistent AF is continuously sustained beyond 7 days (43).

### **Cardiac MRI acquisition protocol and acute MI definition**

Patients meeting the inclusion criteria underwent CMR within 7 days of AES and  $3 \pm 5$  days after admission. CMR was performed on a 1.5-T Magnet (Siemens Area, Siemens Medical Solutions, Germany) using a phased-array thoracic coil. The patient was placed in the supine position and images were acquired under cardiac gating. CMR images were acquired in the 4-chamber, 2-chamber, 3-chamber planes and in the short-axis orientation.

To evaluate left ventricular function, cine-CMR was performed using a breath-hold, ECG-gated trueFISP sequence, (TR/TE: 3.7/1.6 ms, FA: 65°, FOV: 350 × 420 mm<sup>2</sup>, acquisition matrix: 192 × 256 to 244 × 256). A series of short-axis slices (thickness: 5 mm, interslice gap: 10 mm) covered the left ventricle from the base of the heart to the apex.

T2-weighted (T2-TIRM) sequences were acquired first on the long-axis and then on the short-axis planes (29, 30).

Late gadolinium-enhanced (LGE) images were acquired 10 minutes after a bolus injection of 0.1 mmol/Kg Gd-DOTA into a brachial vein. A segmented T1-weighted Phase-Sensitive Inversion Recovery (PSIR) sequence was used and the image planes were the same as those for the cine-MRI (thickness of 5 mm with an interslice gap of 10 mm). Short axis slices, then horizontal and vertical long-axis slices were also obtained (sequence parameters were TR/TE: 7.3/3.4 ms, FA: 15°, FOV: 350 × 420 mm<sup>2</sup>, acquisition matrix: 192 × 240). The end-diastolic phase was chosen to set the acquisition window. The extent of myocardial involvement was quantified using a simplified visual quantitative score (SQS) of LGE (10) with the 17-segment LV division of the American Heart Association. Segments with LGE were scored according to the

number of quartiles involved (1-25%, 26-50%, 51-75%, and 76 to 100%). CMR results were finally expressed as the percentage of LV myocardium involved calculated by adding the 17 segment scores (LGE extent =  $n\% \text{ VG} = (\text{addition of 17 segment scores} / 68) * 100$ ). Each case was also classified according to the predominant location of LGE: infero-lateral, antero-septo-apical or diffuse (7, 8, 9, 10, 29, 30).

Acute MI was defined by the presence of a myocardial T2 hypersignal greater in extent than the contrast enhancement obtained after injection of gadolinium in the PSIR sequence. The MI sequelae was defined by the presence of a T2 myocardial hypersignal less than or equal in extent to the contrast taken obtained after injection of gadolinium in the PSIR sequence.

### **Coronary Computed Tomography Angiography**

For patients who did not undergo a coronary angiography in the acute phase, a computed tomography (CT) (Siemens Somatom Force, twin-tube, 192 strips) was performed with injection of iodinated contrast dye (Iomeron 400, flow rate 5ml/sec, volume 70ml). A first acquisition (without injection, according to the "Auto Spiral" protocol: retrospective multiphasic acquisition of 60% to 80% of the phase, synchronized with the ECG), allowed the analysis of the ventricle (mass, end-diastolic volume, tele systolic and diastolic volume, left ventricular ejection fraction (LVEF)) (31). A second acquisition, in spiral mode with dose optimization activated (Care DOSE 4D and Care kV) [ECG modulation between 30% and 80% then reconstruction phase with proposal of the best diastolic phase (Best diastole) and the best systolic phase (best systole)] made it possible to carry out a multiphasic reconstruction in steps of 10%.

### **CMR and Coronary Computed Tomography Angiography analysis**

CMR and CT scans were interpreted independently by two investigators in cardiac cross-sectional imaging. Interpretations were performed without knowledge of clinical status and with a systematic review.

### **Statistical analysis**

Based on CMR criteria and ECG/biological/clinical signs of acute MI, patients were classified into 2 groups: a) absence of any kind of MI, neither acute MI nor MI sequela, namely the "AES without MI" group ; b) acute MI and/or MI sequelae, namely the "AES with MI e" group (figure 1).

Our study is descriptive and due to the small numbers, no statistical analysis is presented.

### **Results**

During the study period, 1 150 patients with stroke were hospitalized in the neurovascular ICU at the Dijon Bourgogne University Hospital. Of these patients, 955 had an ischemic stroke and 97 had a transient ischemic attack (Figure 1). Among the 44 patients with AES from embolic cause with first diagnosed AF, 34 patients underwent CMR (Figure 1). CMR analysis identified 12 MI, including 6 patients with MI sequelae and 6 patients with acute MI.

### **Characteristics of the population**

Table 2 shows the patient characteristics on admission. Median age was 77 years, and 44% of the population was female. Most patients had dyslipidemia (26%) or hypertension (62%) (Table 2). A significant rise in troponin ( $> 0.10 \mu\text{g/L}$ ) was observed in 35% of the total population (12/34 patients). More specifically, a significant rise was observed in 23% of patients with AES without MI, 58% of AES with MI (Table 2). The mean NIHSS of the all population was 9 (10 in patient with AES without MI and 7 in patient with AES and MI).

Our study included only first diagnosed atrial fibrillation. Paroxysmal AF was observed in 74% of the total population, and 73% for the AES without MI and 75 % for AES with MI. In addition, persistent AF (continuously sustained for at least 7 days after admission), was observed in 26% of the total population (Table 2).

Most had stroke locations in the superficial sylvian territory (Table 3).

### **Cardiac Magnetic Resonance**

Median LVEF was 54%, and LVEF was 54% and 52% for the AES without MI and AES with MI, respectively (Table 3). The results for CMR are shown in Table 3. More importantly, the extent of the infarcts was very limited, with an average of  $1.14 \pm 1.21$  segments (Table 3).

### **Sequelae of strokes**

Cerebral imaging showed sequelae of ischemic stroke in 21% of the total population, and 23% of the AES without MI and 17 % of AES with MI, respectively (Table 3).

## **Discussion**

In this prospective observational study conducted in patients with AES related to newly diagnosed atrial fibrillation, we have demonstrated that the frequency of simultaneous cardiac and cerebral ischemia according to the Shibata criteria is 35 % (12/34 patients) (5, 28).

### **Simultaneous cardio-cerebral embolization**

In the retrospective study published by Shibata et al including 1 776 patients who presented with MI, the etiology was identified as one or more coronary emboli on coronary angiographic data in 52 patients, among whom 15% also presented a cerebral embolic localization (5). In another study from Popovic et al, which included 1 232 consecutive patients who presented an acute coronary syndrome with ST segment elevation, the authors identified 53 patients who met the criteria for coronary embolism, among whom only 9 patients (17%) presented with extracardiac embolism (14). It should also be noted that in this cohort, atrial fibrillation was the most common etiology for coronary embolism (15 patients; 28.3%) (14).

The higher prevalence observed in the current study could be explained by: 1) the exclusive selection of patients with AES related to newly diagnosed atrial fibrillation, 2) the systematic performance of a cardiac MRI, the reference method in the diagnosis of MI with a sensitivity close to 100%, 3) the mode of entry into the study of Shibata or Popovic was a symptomatic MI without a systematic search for ischemic stroke, 4) the inclusion of coronary embolism only according to the Shibata criteria (concomitant systemic embolization) and therefore in relation to AF, there were only 3 cases in which angiography confirmed with certainty the diagnosis of coronary emboli.

In addition, in the study by Shibata et al and the clinical cases of "cardiocerebral infarction" in the literature, patients are described as presenting signs of cerebrovascular stroke with clinical presentation and electrocardiographic signs that lead to an emergency coronary angiography (5, 12, 15, 17, 28, 32-38).

In our study, only two cases of acute coronary syndrome with ST segment elevation were detected. This result is in agreement with the largest series so far, published in 2007 in "Stroke" by Algahtani et al, which included all 860 043 patients from a US national database who presented with AES. The authors identified 573 MI, which made up 1.6% of the study population (13). It should be noted that 80% of myocardial infarction patients presented NSTEMI while only 20% had STEMI (13).

Coronary emboli are probably underestimated for 4 major reasons: a) the disappearance of visualized CEs due to ischemic stroke therapy: anticoagulation +/- thrombolysis; b) the diagnosis of NSTEMI is difficult and in the acute stage of AES, changes in the ST segment are frequent (24%) and coronary angiography is generally not performed (18-21); c) distal coronary emboli leading to very limited coronary imaging (5) (14); and d) in our study, coronary angiography was not systematic and was done in only 44% of patients; a CT scan was performed the other patients (85%) to eliminate coronary artery disease. However, CT has not been shown to be of interest for the detection of coronary embolism and in particular if the emboli are distal. In addition, coronary embolism is not the only etiology responsible for myocardial injury in the acute phase of ischemic stroke linked to AF: type II infarction linked to tachy-arrhythmia or brady-arrhythmia is a differential diagnosis (4).

### **Cardiac Magnetic Resonance**

In our CMR analyses, the myocardial infarction was more frequently observed on the latero-apical and infero-latero-median segments and was not very extensive, with less than 2 segments involved. These data confirm the distal character of coronary embolism. There are few studies on coronary embolism in the literature, and most of these studies are based only on angiographic data (5) (14). For example, the Shibata cohort demonstrates a homogeneous distribution of coronary emboli over the three coronary arteries (5). However, a recent review of clinical cases with coronary emboli highlights that the right coronary artery or the circumflex coronary artery is affected in 8 out of 15 clinical cases, and is thus mainly responsible for lower myocardial infarction (15).



## **Coronary and brain reperfusion strategy**

Due to the rarity of this "cardiocerebral infarction" syndrome, no recommendations have been published to date. The initial treatment for stroke consists of intravenous thrombolysis (rtPA), which is recommended when patients are treated within 4h30 following signs of cerebral infarction, associated in some cases with mechanical thrombectomy (23). The treatment of acute coronary syndromes such as STEMI or specific NSTEMI is still to perform a coronary angiography within 120 minutes of the first medical contact (24). Although intravenous thrombolysis can be used in MI, at different doses and times, its administration is associated with an increased risk of cerebral hemorrhagic transformation. Recent work published in *Frontiers in Neurology* (25) outlined a management algorithm based on: 1) the patient's hemodynamic status and the presence of STEMI signs on ECG 2) the indication for cerebral thrombectomy, 3) damage to the right insular cortex.

## **Myocardial and cerebral sequelae**

Our study also highlights a high percentage of stroke sequelae, 23 % of patients already had an ischemic stroke sequela without MI, 17 % of patients already have stroke sequelae and acute stroke with MI.

Our data confirm that there is a long period of silent AF before the diagnosis is obtained, and that during this period silent ischemic episodes can occur in the brain, as well as in the myocardium.

To date, there are no published studies relative to the prognosis of patients with "cardiocerebral infarction". However, there are retrospective studies in the literature concerning patients admitted for ischemic stroke and who, on follow-up, presented with MI. One study from 2017 using American national registry data over a period of 10 years reported that 1.6% of patients with a history of AES developed MI (out of approximately 800 000 patients) (13). In addition, this study found that the presence of post-stroke MI was associated with an increased mortality and a 50% increase in the rehospitalization rate (13).

## **Limitations of the study**

The limited power of our study did not allow us to establish significant risk factors for cerebral and cardiac embolic injury, and because we recruited in a single center, only 34 patients were included in the study. In addition, it is not uncommon for the diagnosis of embologenic supra-ventricular arrhythmia to be established up to 3 months after a stroke. It should be noted that our population presented newly diagnosed AF, and while coronary embolism seemed to be the most frequent etiology, it was only demonstrated in three patients. The ischemic CMR abnormalities found may also be the consequence of type II infarction with, for example, a spasm, or linked to tachyarrhythmia, but myocardial imaging currently does not make it possible to differentiate between the various mechanisms.

## **Conclusion**

Simultaneous cardio-cerebral embolization is not uncommon, as suggested by a prevalence of 35% in our prospective cohort of patients with AES and newly diagnosed AF. This is the first prospective study to use

systematic cardiac MRI to look for symptomatic or asymptomatic MI. Systematic cardiac MRI in this specific population confirms that ischemic myocardial damage is underestimated, but further studies are needed to determine if the presence of a "cardiocerebral infarction" is only related to CE and if it reflects an increased cardiac risk and/or cerebral risk. There is the additional question of appropriate therapeutic strategies, particularly the need for specific anti-coagulation.

### **Funding**

This work was supported by the Dijon Bourgogne University Hospital, the *Association de Cardiologie de Bourgogne*, and by grants from the *Agence Régionale de Santé de Bourgogne Franche-Comté*, and from the Regional Council of Bourgogne Franche-Comté.

### **Acknowledgments**

We would like to thank Mrs. Suzanne Rankin for proofreading the manuscript.

### **References**

- 1) Kirchhof P, Benussi S, Kotecha D, et al. 2016 ESC Guidelines for the management of atrial fibrillation developed in collaboration with EACTS. *Eur J Cardiothorac Surg* 2016; 50: e1–e88.
- 2) Lupercio F, Riuz JC, Briceno DF, et al. Left atrial appendage morphology assessment for risk stratification of embolic stroke in patients with atrial fibrillation: A meta-analysis. *Heart Rhythm* 2016.03.042
- 3) Bekwelem W, Connolly SJ, Halperin JL, et al. Extracranial Systemic Embolic Events in Patients With Nonvalvular Atrial Fibrillation *Circulation*, 2015;132:796-803
- 4) Hartikainen TS, Sörensen NA, Haller PM, et al. Clinical application of the 4th Universal Definition of Myocardial Infarction. *Eur Heart J* 2020; 41: 2209–2216.
- 5) Shibata T, Kawakami S, Noguchi T, et al. Prevalence, Clinical Features, and Prognosis of Acute Myocardial Infarction Attributable to Coronary Artery Embolism. *Circulation* 2015; 132: 241–250.
- 6) Adams HP, Bendixen BH, Kappelle LJ, et al. Classification of subtype of acute ischemic stroke. Definitions for use in a multicenter clinical trial. TOAST. Trial of Org 10172 in Acute Stroke Treatment. *Stroke* 1993; 24: 35–41.
- 7) Huttin O, Mandry D, Eschalier R, et al. Cardiac remodeling following reperfused acute myocardial infarction is linked to the concomitant evolution of vascular function as assessed by cardiovascular magnetic resonance. *J Cardiovasc Magn Reson* 2017; 19: 2.
- 8) Assomull RG, Lyne JC, Keenan N, et al. The role of cardiovascular magnetic resonance in patients presenting with chest pain, raised troponin, and unobstructed coronary arteries. *Eur Heart J* 2007; 28: 1242–1249.
- 9) Comte A, Lalande A, Walker PM, et al. Visual estimation of the global myocardial extent of hyperenhancement on delayed contrast-enhanced MRI. *Eur Radiol* 2004; 14: 2182–2187.

- 10) Cochet AA, Lorgis L, Lalande A, et al. Major prognostic impact of persistent microvascular obstruction as assessed by contrast-enhanced cardiac magnetic resonance in reperfused acute myocardial infarction. *Eur Radiol* 2009; 19: 2117–2126.
- 11) Rioufol G, Zeller M, Dentan G, et al. Predictors and prognosis for complex coronary lesions in patients with acute myocardial infarction: data from RICO survey. *Am Heart J* 2007; 154: 330–335.
- 12) Abe S, Tanaka K, Yamagami H, et al. Simultaneous cardio-cerebral embolization associated with atrial fibrillation: a case report *BMC Neurology* 2019 ; 19:152
- 13) Alqahtani F, Aljohani S, Tarabishy A, et al. Incidence and Outcomes of Myocardial Infarction in Patients Admitted With Acute Ischemic Stroke. *Stroke* 2017; 48: 2931–2938.
- 14) Popovic B, Agrinier N, Bouchahda N, et al. Coronary Embolism Among ST-Segment-Elevation Myocardial Infarction Patients: Mechanisms and Management. *Circ Cardiovasc Interv* 2018; 11: e005587.
- 15) Daoud H, Abugroun A, Erramilli S, et al. Acute Coronary Syndrome (ACS) due to Coronary Artery Embolism in a Patient with Atrial Fibrillation, *Case Rep Cardiol* 2019 ; 9347198
- 16) Dastidar AG, Baritussio A, De Garate E, et al. Prognostic Role of CMR and Conventional Risk Factors in Myocardial Infarction With Nonobstructed Coronary Arteries. *JACC Cardiovasc Imaging* 2019; 12: 1973–1982.
- 17) Pierik R, Algra A, van Dijk E, et al. Distribution of Cardioembolic Stroke: A Cohort Study. *CED* 2020; 49: 97–104.
- 18) Jensen JK, Bak S, Flemming Højlund-Carlsen P, et al. Prevalence of electrocardiographic ST-T changes during acute ischemic stroke in patients without known ischemic heart disease. *Int J Cardiol* 2008; 128: 137–138.
- 19) Kerr G, Ray G, Wu O, et al. Elevated troponin after stroke: a systematic review. *Cerebrovasc Dis* 2009; 28: 220–226.
- 20) Yaghi Shadi, Chang Andrew D., Ricci Brittany A., et al. Early Elevated Troponin Levels After Ischemic Stroke Suggests a Cardioembolic Source. *Stroke* 2018; 49: 121–126.
- 21) Barber M, Barlow N, Macfarlane PW, et al. Elevated troponin levels are associated with sympathoadrenal activation in acute ischaemic stroke. *Cerebrovascular Diseases* 2007; 23: 260–266.
- 22) Zhao Y-H, Gao H, Pan Z-Y, et al. Prognostic Value of NT-proBNP After Ischemic Stroke: A Systematic Review and Meta-analysis of Prospective Cohort Studies. *J Stroke Cerebrovasc Dis* 2020; 29: 104659.
- 23) Powers WJ, Derdeyn CP, Biller J, et al. 2015 American Heart Association/American Stroke Association Focused Update of the 2013 Guidelines for the Early Management of Patients With

Acute Ischemic Stroke Regarding Endovascular Treatment: A Guideline for Healthcare Professionals From the American Heart Association/American Stroke Association. *Stroke* 2015; 46: 3020–3035.

- 24) Ibanez A, James S, Aewall S et al, 2017 ESC Guidelines for the management of acute myocardial infarction in patients presenting with ST-segment elevation *European Heart Journal* 2018, 119–177
- 25) Kijpaisalratana N, Chutinet A, Suwanwela NC et al. Hyperacute Simultaneous Cardiocerebral Infarction: Rescuing the Brain or the Heart First? *Front Neurol* 2017; 8: 664.
- 26) Amarenco P, Lavallée PC, Monteiro Tavares L et al. Five-Year Risk of Stroke after TIA or Minor Ischemic Stroke *N Engl J Med* 2018; 378:2182-2190
- 27) Fernández-Jiménez R, Barreiro-Pérez M, Martín-García A, et al. Dynamic Edematous Response of the Human Heart to Myocardial Infarction: Implications for Assessing Myocardial Area at Risk and Salvage. *Circulation*. 2017;136(14):1288-300
- 28) Kolodgie Frank D., Virmani Renu, Finn Alope V., et al. Embolic Myocardial Infarction as a Consequence of Atrial Fibrillation. *Circulation* 2015; 132: 223–226
- 29) Friedrich MG, Sechtem U, Schulz-Menger J, et al. Cardiovascular magnetic resonance in myocarditis: A JACC White Paper. *J Am Coll Cardiol* 2009; 53: 1475–1487.
- 30) Abdel-Aty H, Boyé P, Zagrosek A, et al. Diagnostic performance of cardiovascular magnetic resonance in patients with suspected acute myocarditis: comparison of different approaches. *J Am Coll Cardiol* 2005; 45: 1815–1822.
- 31) Nuss FMA, Budde RPJ, van Dijkman ED, et al. Prognostic Value of Subclinical Coronary Artery Disease in Atrial Fibrillation Patients Identified by Coronary Computed Tomography Angiography. *Am J Cardiol* 2020; 126: 16–22.
- 32) Chlapoutakis GN, Kafkas NV, Katsanos SM, et al. Acute myocardial infarction and transient ischemic attack in a patient with lone atrial fibrillation and normal coronary arteries. *Int J Cardiol* 2010;139:e1-4.
- 33) Hashimoto O, Sato K, Numasawa Y, et al. Simultaneous onset of myocardial infarction and ischemic stroke in a patient with atrial fibrillation: multiple territory injury revealed on angiography and magnetic resonance. *Int J Cardiol* 2014; 172: e338-340.
- 34) Kim H-L, Seo J-B, Chung W-Y, et al. Simultaneously Presented Acute Ischemic Stroke and Non-ST Elevation Myocardial Infarction in a Patient with Paroxysmal Atrial Fibrillation. *Korean Circ J* 2013; 43: 766–769.
- 35) Kleczyński P, Dziewierz A, Rakowski T, et al. Cardioembolic acute myocardial infarction and stroke in a patient with persistent atrial fibrillation. *Int J Cardiol* 2012; 161: e46-47.

- 36) Maciel R, Palma R, Sousa P, et al. Acute stroke with concomitant acute myocardial infarction: will you thrombolysed? *J Stroke* 2015; 17: 84–86.
- 37) Omar HR, Fathy A, Rashad R, et al. Concomitant acute right ventricular infarction and ischemic cerebrovascular stroke; possible explanations. *Int Arch Med* 2010;3:25.
- 38) Tokuda K, Shindo S, Yamada K, et al. Acute Embolic Cerebral Infarction and Coronary Artery Embolism in a Patient with Atrial Fibrillation Caused by Similar Thrombi. *J Stroke Cerebrovasc Dis* 2016; 25: 1797–1799.
- 39) Mione V, Yao H, Laurent G, et al. Simultaneous cardiocerebral embolization in patients with atrial fibrillation. *Arch Cardiovasc Dis*. November 2020.
- 40) Hindricks G, Potpara T, Dagres N, et al. ESC Scientific Document Group. 2020 ESC Guidelines for the diagnosis and management of atrial fibrillation developed in collaboration with the European Association of Cardio-Thoracic Surgery (EACTS). *Eur Heart J*. 2020

ACA: anterior cerebral artery;

CE: coronary artery embolism;

CMR: Cardiac Magnetic Resonance

CT: computed tomography;

Cx: circumflex;

DES: drug-eluting stent;

ECG: electrocardiogram;

IS: ischaemic stroke;

LAD: left anterior descending;

MCA: middle cerebral artery;

MI: myocardial infarction;

N/A: not available;

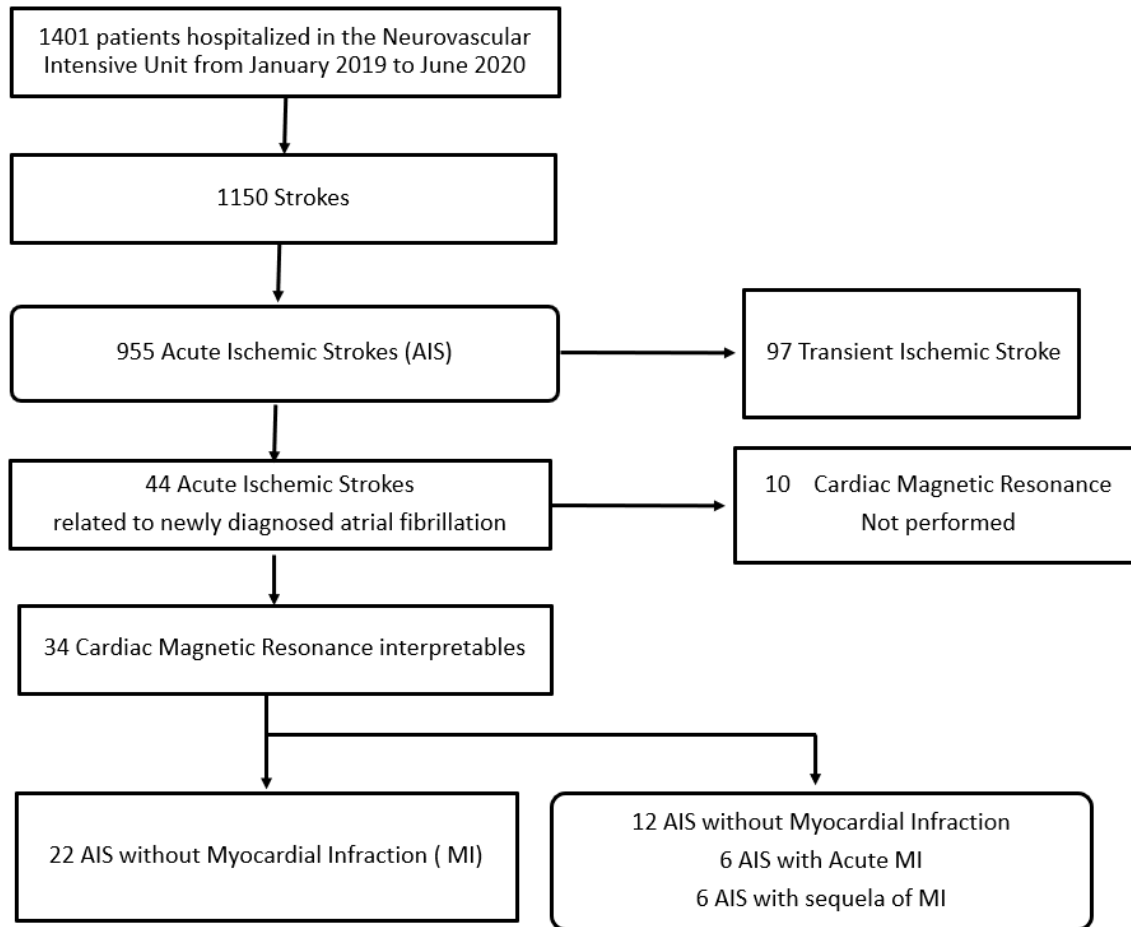
NSTEMI: non-ST-segment elevation myocardial infarction;

RCA: right coronary artery;

STEMI : ST-segment elevation myocardial infarction;

tPA: tissue plasminogen activator;

**Figure 1. Flow chart**



**Table 1.** Proposed criteria for the clinical diagnosis of coronary artery embolism according to Shibata et al (4)

Major criteria

- ☒ Angiographic evidence of coronary artery embolism and thrombosis without atherosclerotic components
- ☒ Concomitant coronary artery embolization at multiple sites\*
- ☒ Concomitant systemic embolization without left ventricular thrombus attributable to acute myocardial infarction

Minor criteria

- ☒ <25% stenosis on coronary angiography, except for the culprit lesion
- ☒ Evidence of an embolic source based on transthoracic echocardiography, transesophageal echocardiography, computed tomography, or MRI
- ☒ Presence of embolic risk factors: atrial fibrillation, cardiomyopathy, rheumatic valve disease, prosthetic heart valve, patent foramen ovale, atrial septal defect, history of cardiac surgery, infective endocarditis, or hypercoagulable state

Definite CE : Two or more major criteria, or One major criterion plus  $\geq 2$  minor criteria, or Three minor criteria

Probable CE : One major criterion plus 1 minor criterion, or Two minor criteria

CE indicates coronary artery embolism; and NCVS, National Cerebral and Cardiovascular Center.

\*Indicates multiple vessels within 1 coronary artery territory or multiple vessels in the coronary tree.



**Table2.** Baseline characteristics of patients with acute embolic stroke according to myocardial infarction status (n(%), or median (IQR)) to the nearest whole number

<b>Characteristics</b>	<b>All population N=34</b>	<b>AES without MI N=22</b>	<b>AES with MI N=12</b>
<b>Clinical</b>			
Female,	15 (44 %)	11 (50 %)	4 (33 %)
Age, years	77 (67-85)	76 (68-85)	77 (54-91)
<b>Risk Factors</b>			
Diabetes	9 (26%)	4 (18 %)	5 (42 %)
Smoking	3 (9%)	1 (5 %)	2 (17 %)
Dyslipidemia	9 (26%)	4 (18 %)	5 (42 %)
Hypertension	21 (62 %)	13 (59 %)	8 (67 %)
<b>Type of first diagnosed AF</b>			
Paroxysmal AF	25 (74 %)	16 (73 %)	9 (75 %)
Persistent AF	9 (26%)	6 (27 %)	3 (25%)
<b>Cardiac Injury Parameters</b>			
Troponin, µg/L	0.04 (0.02-0.44)	0.02 (0.02-0.07)	29.5 (11.6-36)
Troponin > 0.10 µg/L,	12 (35 %)	5 (23 %)	7 (58 %)
STEMI	2 (6 %)	0 (0 %)	2 (17%)
Coronary Computed Tomography Angiography	29 (85 %)	13 (59 %)	6 (50 %)
Coronary Angiography	15 (44 %)	9 (41 %)	6 (50 %)
Coronary artery embolism	3 (9 %)	0 (0 %)	3 (25%)

AES: acute embolic stroke; AF : atrial fibrillation; STEMI : ST-segment elevation myocardial infarction; MI : myocardial infarction.

**Table 3.** CMR parameters (mean +/- SD or median (IQR)), to the nearest whole number

	<b>All population N=34</b>	<b>AES without MI N=22</b>	<b>AES with MI N=12</b>
<b>Brain lesion location</b>			
Superficial Sylvian	16 (47 %)	10(45 %)	7 (58 %)
Profound Sylvian	1 (3 %)	1 (4.5 %)	0 (0 %)
Sylvian total	4 (12 %)	3 (14%)	1 (8%)
Frontal	8 (24 %)	5 (23 %)	3 (25%)
Occipital	2 (6 %)	2 (9 %)	0 (0 %)
Cerebellar	1 (3 %)	1 (4%)	0 (0 %)
Multiple	1 (3 %)	0 (0 %)	1 (8 %)
<b>Cardiac parameters</b>			
LVEF MRI, %	54 (45-65)	54 (44-66)	52 (28-60)
EDV, mL/m <sup>2</sup>	66 (59-82)	63 (56-67)	88 (62-114)
EDS, mL/m <sup>2</sup>	32 (23-40)	25 (21-38)	37 (34-62)
LV mass, g/m <sup>2</sup>	69 (59-93)	67 (59-81)	88 (55-109)
Number of segments			1.14 ± 1.21
<b>Sequelae images of the stroke</b>			
Without stroke sequela,	27 (79%)	17 (77%)	10 (83%)
With stroke sequela,	7 (21%)	5 (23%)	2 (17%)

AES: acute embolic stroke; MI : myocardial infraction; EDV : end diastolic volume ; ESV : end systolic volume ; LV mass : left ventricular mass ; LVEF: Left ventricular ejection fraction; MRI: magnetic resonance imaging