



Renal artery reimplantation for secondary hypertension due to diaphragmatic crus compression: a case report and literature review.

Youcef Lounes, Lucien Chassin-Trubert, Kheira Hireche, Léonore Freycon-Tardy, Mariama Akodad, Ludovic Canaud, Pierre Alric

► To cite this version:

Youcef Lounes, Lucien Chassin-Trubert, Kheira Hireche, Léonore Freycon-Tardy, Mariama Akodad, et al.. Renal artery reimplantation for secondary hypertension due to diaphragmatic crus compression: a case report and literature review.. *Annals of Vascular Surgery - Brief Reports and Innovations*, 2022, pp.100056. 10.1016/j.avsurg.2022.100056 . hal-03605991

HAL Id: hal-03605991

<https://hal.science/hal-03605991>


Submitted on 31 May 2022

HAL is a multi-disciplinary open access archive for the deposit and dissemination of scientific research documents, whether they are published or not. The documents may come from teaching and research institutions in France or abroad, or from public or private research centers.

L'archive ouverte pluridisciplinaire **HAL**, est destinée au dépôt et à la diffusion de documents scientifiques de niveau recherche, publiés ou non, émanant des établissements d'enseignement et de recherche français ou étrangers, des laboratoires publics ou privés.



Distributed under a Creative Commons Attribution 4.0 International License



Renal artery reimplantation for secondary hypertension due to diaphragmatic crus compression: A case report and literature review.

Youcef Lounes^{a,b,*}, Lucien Chassin-Trubert^a, Kheira Hireche^a, Léonore Freycon-Tardy^a, Mariama Akodad^{b,c}, Ludovic Canaud^{a,b}, Pierre Alric^{a,b}

^a Dept of Vascular and Thoracic Surgery, Univ Montpellier, CHU Montpellier, Montpellier, France

^b PhyMedExp, Univ Montpellier, CNRS, INSERM, CHU Montpellier, Montpellier, France. Montpellier, France

^c Department of Cardiology, Arnaud de Villeneuve Hospital, Montpellier, France

Abbreviations

CT	Computed Tomography
LRA	Left Renal Artery
RA	renal artery
RRA	Right Renal Artery
SMA	superior mesenteric artery

Introduction

Renal artery compression due to a diaphragmatic crus entrapment is the second cause of renal stenosis after fibrodysplasia in the young population. This rare condition represents only 1.4% of secondary hypertension in that population (1). High origin and prominent diaphragmatic crus are often retrieved, leading to a compression of the renal artery (RA) at its origin defined as the median arcuate syndrome. The origin of this disease may be explained by abnormalities of cephalad migration of the kidneys during the fetus's life (2). Although rare, this compression leads to a focal stenosis causing severe hypertension. Typical clinical presentation is incidental finding of severe and resistant hypertension in a young patient with no other cardiovascular risk factors. Different treatment modalities have been described in the literature as open, laparoscopic liberation or endovascular stenting of the RA, but no recommendations exist for this rare pathology. Taking all these considerations together, we report a case of direct re-implantation of the renal artery and discuss the review of the literature.

Case report

A 31-year-old male was admitted for dysphagia and shortness of breath. Asthma and eosinophilic esophagitis were diagnosed. During clinical examination, his systolic blood pressure was 210 mmHg without related symptoms. Consequently, he underwent several explorations including doppler ultrasound showing a flow acceleration over 300 m/sec in the proximal part of the left RA without direct visualization of the stenosis. Resistance index was 0.5 for the left side and 0.65 for the right; the left kidney measured 10.5 cm and the right 12 cm. The computed

tomography (CT)-scan confirmed the diagnosis of critical stenosis with the objectivation of a diaphragmatic crus entrapment and a high origin of the left RA, between the coeliac trunk and the superior mesenteric artery (SMA) (Fig. 1). Despite a progressive escalation of antihypertensive medications over a period of 3 years, the patient remained hypertensive with a four drug combination including Ramipril, Metoprolol, Hydrochlorothiazide and Amlodipine. The renal function was normal, and he had no other cardiovascular risk factor. After a multidisciplinary meeting, an angiogram and potential left RA angioplasty was decided. The angiogram did not allow to highlight clear stenosis, despite respiratory maneuvers. Invasive measurement of arterial pressure difference between the aorta and the renal artery was not deemed necessary as the significant stenosis was previously confirmed on CT and doppler. An angioplasty with a 6 mm non-compliant balloon in the proximal part of the LRA discovered the stenosis with rapid recoils precluding a stent placement (video 1). To ensure long-term permeability and avoid a stent placement, we decided, after evaluation of the benefits and risks of all different treatments, to perform a surgical decompression of the LRA. A median supra-umbilical laparotomy was performed and the aorta, the left renal vein, as well as the superior mesenteric were dissected. The section of the diaphragmatic crus that compressed the left RA was realized. The stenosis of the LRA was critical despite the application of local papaverine (Fig. 2A). Due to the excess length of the artery, we performed a resection of the stenosis and direct reimplantation of the left RA in the aorta in the same site of its origin with a 6-0 prolene (Fig. 2B). A 12 min supra-mesenteric aortic clamping was performed to realize the anastomosis with recovery of a normal pulsatile left RA. The outcomes were uneventful with rapid ambulation of the patient and hospital discharge at day 5. The blood pressure normalized immediately after the surgery with the discontinuation of all antihypertensive medications. The post-operative doppler ultrasound showed a perfect permeability of the left RA with no residual stenosis and a resistance index of 0.6. Renal function was normal, we observed an increase of the left kidney size (11.5 cm) at 3-month follow-up, and treatment by aspirin was prescribed for a 6-month duration. Clinical, US-doppler and CT scan follow-up showed no restenosis or hypertension recurrence up to 3-year follow-up (Fig. 3).

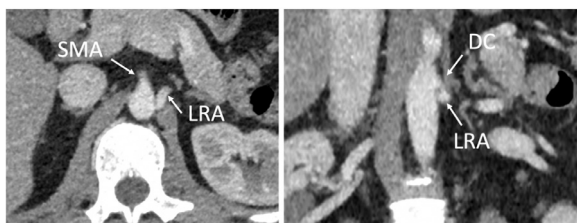
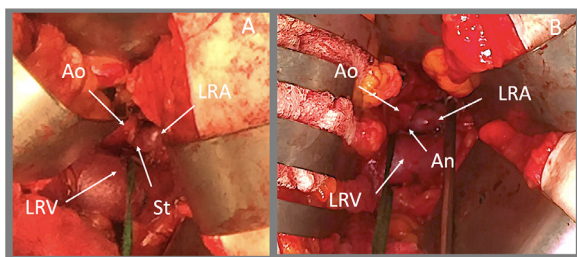
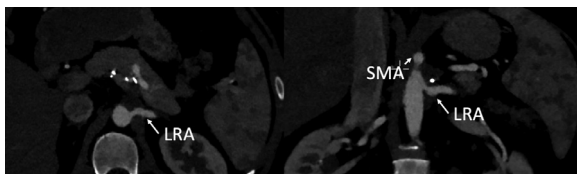
* Corresponding author.

E-mail address: youcef.lounes@gmail.com (Y. Lounes).

Table 1

Literature review of all renal artery entrapments treated surgically. This table describes demographics, type of treatments, success, and follow-up.

Author	Year	age	sex	Laterality	First Treatment	Second reconstruction	resolution	Follow-up (month)
D'Abreu ³	1962	50	M	Bilateral	Open liberation	–	Yes	9
D'Abreu ³	1962	32	M	Left	Open liberation	–	Yes	4
Lampe ⁵	1965	28	M	Right	Graft Bypass	–	Yes	2
Villanueva ⁶	1972	–	–	–	Open liberation	–	–	–
Silver ²	1976	24	M	Left	Open liberation	–	Yes	–
Silver ²	1976	4	M	Left	Vein patch	–	Yes	–
Silver ²	1976	33	F	Right	Open liberation	–	No	–
Spies ⁷	1987	20	M	Left	Vein Patch	–	Yes	11
Clement ⁸	1990	26	F	Left	Open liberation	–	Yes	–
Vahdat ⁹	1991	23	–	Right	Saphenous bypass	Open Liberation	Yes	–
Bacourt ¹⁰	1992	21	M	Left	Open liberation	–	Yes	48
Kopecky ¹¹	1997	50	F	Left	Open liberation	–	Yes	6
Baguet ¹²	2003	74	M	Left	RA Stenting	RA Reimplantation	Yes	2
Thony ⁴	2005	68	F	Left	RA stenting	–	No	6
Thony ⁴	2005	–	–	–	RA stenting	–	No	6
Deglise ¹³	2007	39	M	Bilateral	RA stenting (Left)	Graft bypass (Left)	Yes	6
						RA reimplantation (Right)	Yes	
Gaebel ¹⁴	2009	19	F	Left	RA angioplasty	Open liberation	Yes	
Boufi ¹⁵	2010	56	F	Left	RA stenting	Graft Bypass	Yes	18
Bünger ¹⁶	2010	26	M	Left	Laparoscopic liberation	–	Yes	–
Song ¹⁷	2011	23	M	Bilateral	Auto transplantation (Left)	–	Yes	18
					Open liberation (Right)			
Rafiq ¹⁸	2018	21	M	Right	RA stenting	–	Yes	0,5
Mirza ¹⁹	2020	20	M	Left	Open liberation	–	Yes	17
Mirza ¹⁹	2020	65	F	Bilateral	Laparoscopic liberation	–	Yes	–

**Fig. 1.** focal stenosis due to a compression of the diaphragmatic crus.**Fig. 2.** intra operative photo showing the persistent stenosis and the post stenosis dilatation of the left renal artery (A) . Direct reimplantation of the left renal artery (B). Ao: aorte, LRV: left renal Vein, LRA : left renal artery, St : stenosis, An : anastomosis.**Fig. 3.** Post-operative CT showing the resolution of the left renal stenosis.

Discussion

In 5–10% of cases, hypertension is related to a renal stenosis (1). However, depending on the age, the large majority of those stenosis are

due to atherosclerosis or fibrodysplasia. Noilan et al. found that 1.4% of secondary hypertension may be related to an external compression of the RA by the diaphragmatic crus. This pathology has been described for the first time in 1962 by d'Abreu and Strickland (3) in London, United Kingdom. Since then, 24 cases of surgical treatments have been published in the literature. Thony *et al.* described a series of 15 cases with a mean age of 65 yo and a majority of female ($n = 9$) (4). The clinical presentation was mainly isolated hypertension ($n = 7$) but hypertension associated with renal insufficiency or abdominal aortic aneurysm or superior mesenteric artery aneurysm without hypertension were also observed. The right RA was involved in most cases ($n = 11$) with no bilateral RA involvement cases. CT-scan or Magnetic Resonance Imaging appear as the key for the diagnosis but may overestimate the stenosis as the images are taken during blocked inspiration (4). Conversely, angiogram may underestimate the stenosis regarding its proximity to the aortic wall and the potential difficulty to achieve a favorable angulation. Overall, doppler or pressure measurements are required to confirm the stenosis and the functional impact.

A literature review of surgical management is summarized in Table 1 (5–19).

Over the treated and collected cases, the mean age was younger than in the series published by Thony *et al.* with a male predominance (14 males and 7 females) (Table 1). Moreover, in this series, the left RA was involved in the large majority of cases ($n = 18/22$), and bilateral stenoses in 4 cases (3,13,17,19). Multiple visceral arteries stenosis were associated in 7 patients (9–13,16,17), with median accurate syndrome with celiac trunk stenosis, a compression of the SMA or all visceral arteries. The clinical presentation was systematically a resistant hypertension, in the majority without related symptoms.

Several surgical modalities have been described in the literature (Table 1). Endovascular treatments may be a seducing option but may not provide favorable long-term results. Complications as persistent stenosis (4), secondary restenosis and stent fracture have been described (4,13,15). Balloon-expandable stent may be associated with better results (4,18), although the resolution of the hypertension was observed in only one case with only 2 weeks of follow-up.

Liberation of the external compression is, in the authors opinion, a fundamental requirement for a suitable outcome. Indeed, in the majority of cases ($n = 14/20$; 70%), a surgical liberation of the diaphragmatic crus

was sufficient to obtain a complete resolution of the symptomatology. In rare cases (2), the resolution of high blood pressure was incomplete, despite the absence of residual stenosis. The authors explained that the failure to normalize the blood pressure was due to another etiology of hypertension. A stenosis can still be present after the liberation of the RA (30%). In those cases, different surgical reconstruction techniques have been described including vein patch ($n = 2$) (2,7) or auto-transplantation (17). In this case, direct re-implantation was successfully performed with no complications and satisfying midterm follow-up. Only few cases of direct RA re-implantation for this etiology were reported; Baguet *et al.* had to resect partially the origin of the RA to retrieve a stent priorly placed (12), and Deglise *et al.* realized a re-implantation for a persistent stenosis of the right RA (13). A supra-mesenteric aortic clamping was necessary to realize the anastomosis but for a very short time without the need of nephropexia. We believe that doing one anastomosis with a short clamping time may offer the best outcomes for the kidney. Vein patch have also been described in the literature with favorable outcomes but extended access to the renal artery is required.

In our case, laparotomy was preferred as re-implantation or bypass to the RA was considered less challenging thought a laparotomy than a retroperitoneal access. Indeed, the prediction of length and kinking of the bypass is difficult to appreciate after releasing the retractors. Laparoscopic liberation can offer a minimally invasive solution with safe and promising results (19). However, we observe a decreasing number of vascular surgeons that are trained for laparoscopic procedures. Moreover, this procedure would need to be associated to another surgical procedure in case of persistent renal stenosis. A RA stenting might offer a complementary minimally invasive solution, but no description of these procedures association was made in the literature. Besides, a surgical repair may offer a more durable patency than stenting in this young population (10,15) without the need of a prolonged anti-platelet treatment.

Sparse alternative treatment modalities as botulinum toxin injection into the diaphragmatic crus have been described with temporary effective results (20). This treatment may be a solution to delay the surgical treatment in pregnancy or other conditions.

Conclusion

Renal stenosis caused by a diaphragmatic entrapment is a rare cause of renovascular hypertension. Surgical liberation with or without arterial reconstruction seems to offer the better results. We present a case of such pathology successfully treated by surgical decompression and direct re-implantation of the renal artery with satisfying short and long-term outcomes.

Supplementary Material

Video 1 : Attempt of angioplasty with a 5 mm balloon, it is clearly seen that the stenosis is still present with a visible print during deflation of the balloon.

Declaration of Competing Interest

Canaud reports a relationship with Medtronic Inc that includes: consulting or advisory.

Supplementary materials

Supplementary material associated with this article can be found, in the online version, at doi:[10.1016/j.avsur.2022.100056](https://doi.org/10.1016/j.avsur.2022.100056).

References

- Noilhan C, Barigou M, Bieler L, Amar J, Chamontin B, Bouhanick B. Causes of secondary hypertension in the young population: A monocentric study. *Ann Cardiol Angeiol*. 2016 Jun;65(3):159–164.
- Silver D, Clements JB. Renovascular hypertension from renal artery compression by congenital bands. *Ann Surg*. 1976 Feb;183(2):161–166.
- D'Abreu F., Strickland B.. Developmental renal-artery stenosis. *Lancet*. 1962 Sep 15;280(7255):517–21.
- Thony F, Baguet J-P, Rodiere M, Sessa C, Janbon B, Ferretti G. Renal artery entrapment by the diaphragmatic crus. *Eur Radiol*. 2005 Sep 1;15(9):1841–1849.
- Lampe WT. Renovascular hypertension. A review of reversible causes due to extrinsic pressure on the renal artery and report of three unusual cases. *Angiology*. 1965 Nov;16(11):677–689.
- Villanueva A, Nuñez RV, Baltar L, Ruibal G. Arterial hypertension and extrinsic renal artery compression: case report. *J Cardiovasc Surg*. 1972 Dec;13(6):617–619.
- Spies JB, LeQuire MH, Robison JG, Beckett WC, Perkinson DT, Vicks SL. Renovascular hypertension caused by compression of the renal artery by the diaphragmatic crus. *AJR Am J Roentgenol*. 1987 Dec;149(6):1195–1196.
- Clément C, Ruiz R, Costa-Foru B, Nicaise H. Extrinsic compression of the renal artery by diaphragmatic crus. *Ann Vasc Surg*. 1990 May 1;4(3):305–308.
- Vahdat O, Creemers E, Limet R. [Stenosis of the right renal artery caused by the crura of the diaphragm. Report of a case]. *J Mal Vasc*. 1991;16(3):304–307.
- Bacourt F, Depondt JL, Lacombe P, Mignon E. [Compression of the left renal artery by the diaphragm]. *J Mal Vasc*. 1992;17(4):315–318.
- Kopecky KK, Stine SB, Dalsing MC, Gottlieb K. Median arcuate ligament syndrome with multivessel involvement: diagnosis with spiral CT angiography. *Abdom Imaging*. 1997 Jun;22(3):318–320.
- Baguet JP, Thony F, Sessa C, Mallion JM. Stenting of a renal artery compressed by the diaphragm. *J Hum Hypertens*. 2003 Mar;17(3):213–214.
- Dégise S, Corpataux J-M, Haller C, Binaghi S, Meuwly J-Y, Qanadli SD. Bilateral renal artery entrapment by diaphragmatic crura: a rare cause of renovascular hypertension with a specific management. *J Comput Assist Tomography*. 2007 Jun;31(3):481–484.
- Gaebel G, Hinterseher I, Saeger HD, Bergert H. Compression of the left renal artery and celiac trunk by diaphragmatic crura. *J Vasc Surg*. 2009 Oct 1;50(4):910–914.
- Boufi M, Orsini B, Bianca D, Hartung O, Brunet P, Alimi YS. Renal artery thrombosis caused by stent fracture: the risk of undiagnosed renal artery entrapment. *Ann Vasc Surg*. 2010 Oct;24(7) 954.e5-8.
- Bünger CM, Schareck W, Klar E, Kröger J-C. Laparoscopic treatment of renal artery entrapment. *J Vasc Surg*. 2010 Nov 1;52(5):1357–1361.
- Song X, Liu Q, Zheng Y, Liu C, Liu D, Ji Z. Surgical treatment of renal artery compression by diaphragmatic crus. *Ann Vasc Surg*. 2012 Feb;26(2) 276.e11-16.
- Rafiq S, Ilyas M, Gojwari T. A crus-cial discovery: secondary hypertension. *Am J Med*. 2018 Mar;131(3):257–259.
- Mirza AK, Kendrick ML, Bower TC, DeMartino RR. Renovascular hypertension secondary to renal artery compression by diaphragmatic crura. *J Vasc Surg Cases Innov Tech*. 2020 Jun;6(2):239–242.
- Bilici A, Karcaaltincaba M, Ilica AT, Bukte Y, Senol A. Treatment of hypertension from renal artery entrapment by percutaneous CT-guided botulinum toxin injection into diaphragmatic crus as alternative to surgery and stenting. *AJR Am J Roentgenol*. 2007 Sep;189(3):W143–W145.