



**HAL**  
open science

## **A review of diabetic retinopathy: Datasets, approaches, evaluation metrics and future trends**

Dimple Nagpal, S Panda, Muthukumaran Malarvel, Priyadarshini Pattanaik,  
Mohammad Zubair Khan

### ► **To cite this version:**

Dimple Nagpal, S Panda, Muthukumaran Malarvel, Priyadarshini Pattanaik, Mohammad Zubair Khan. A review of diabetic retinopathy: Datasets, approaches, evaluation metrics and future trends. Journal of King Saud University - Computer and Information Sciences, 2021, <10.1016/j.jksuci.2021.06.006>. <hal-03596516>

**HAL Id: hal-03596516**

**<https://hal.science/hal-03596516v1>**

Submitted on 3 Mar 2022

**HAL** is a multi-disciplinary open access archive for the deposit and dissemination of scientific research documents, whether they are published or not. The documents may come from teaching and research institutions in France or abroad, or from public or private research centers.

L'archive ouverte pluridisciplinaire **HAL**, est destinée au dépôt et à la diffusion de documents scientifiques de niveau recherche, publiés ou non, émanant des établissements d'enseignement et de recherche français ou étrangers, des laboratoires publics ou privés.



Distributed under a Creative Commons CC BY-NC-ND 4.0 - Attribution - Non-commercial use - No Derivative Works - International License



Contents lists available at ScienceDirect

# Journal of King Saud University – Computer and Information Sciences

journal homepage: [www.sciencedirect.com](http://www.sciencedirect.com)

## A review of diabetic retinopathy: Datasets, approaches, evaluation metrics and future trends

Dimple Nagpal<sup>a</sup>, S.N. Panda<sup>a</sup>, Muthukumar Malarvel<sup>b</sup>, Priyadarshini A Pattanaik<sup>c</sup>,  
Mohammad Zubair Khan<sup>d</sup>

<sup>a</sup>Chitkara University, Institute of Engineering and Technology, Chitkara University, Punjab, India

<sup>b</sup>Department of Computer Science and Engineering, Hindustan Institute of Technology & Science, India

<sup>c</sup>Image and Information Processing Department, IMT Atlantique, LaTIM Inserm U1101 Brest 29238, France

<sup>d</sup>Dept. of Computer Science, College of Computer Science & Engineering, Taibah University, Madinah, Saudi Arabia

### ARTICLE INFO

#### Article history:

Received 4 February 2021

Revised 1 June 2021

Accepted 14 June 2021

Available online xxxx

#### Keywords:

Diabetic retinopathy

Screening

Datasets

diagnosis of DR

Evaluation metrics

Future trends

### ABSTRACT

Diabetic Retinopathy (DR) is the condition caused due to uncontrolled diabetes that can lead to vision impairment. It greatly affects the retinal blood vessels and diminishes the fundus light-sensitive inner coating. Early diagnosis and regular screening of this disease are essential for prompt processing through artificial intelligence techniques. This paper targets assessing the latest techniques for screening and diagnosing DR, including 94 articles based on the Detection and grading of DR. For every analyzed approach, tables are summarized detailing imaging procedure used, datasets, performance metrics used. The research gaps are also highlighted in this paper. Despite the consistent progression and methods actualized in this field, a couple of issues actually should be centered on. The noise and contrast of the image in Image enhancement are still in the infancy stage for high resolution. This study covers a review of existing image techniques, the gold standard and private datasets available, performance measures used for detection and grading of DR. Now the future research focuses on the amalgamation of the dataset as well as techniques to make the generalized technique for detecting the lesion in DR through an automated system. Moreover, various research gaps have also been taken into account for further research. This review is beneficial to the researchers working in the field of medical imaging to screen and diagnose diseases.

© 2021 The Authors. Production and hosting by Elsevier B.V. on behalf of King Saud University. This is an open access article under the CC BY-NC-ND license (<http://creativecommons.org/licenses/by-nc-nd/4.0/>).

### Contents

1. Introduction . . . . .	00
2. Research Methodology . . . . .	00
2.1. Retinal datasets . . . . .	00
2.2. DR detection techniques . . . . .	00
2.2.1. Microaneurysms detection . . . . .	00
2.2.2. Hemorrhages detection . . . . .	00
2.2.3. Exudates detection . . . . .	00
2.3. Performance evaluation metrics . . . . .	00
2.3.1. Sensitivity/Recall/True positive rate . . . . .	00
2.3.2. Specificity/True negative rate . . . . .	00

Peer review under responsibility of King Saud University.



Production and hosting by Elsevier

<https://doi.org/10.1016/j.jksuci.2021.06.006>

1319-1578/© 2021 The Authors. Production and hosting by Elsevier B.V. on behalf of King Saud University.

This is an open access article under the CC BY-NC-ND license (<http://creativecommons.org/licenses/by-nc-nd/4.0/>).

2.3.3.	False positive rate. . . . .	00
2.3.4.	False-Negative rate (FNR). . . . .	00
2.3.5.	Accuracy . . . . .	00
2.3.6.	AUC . . . . .	00
2.3.7.	F1-score. . . . .	00
2.3.8.	Error rate. . . . .	00
2.3.9.	Positive predictive value (Precision) . . . . .	00
2.3.10.	Kappa score. . . . .	00
3.	Comparison of existing DR detection techniques. . . . .	00
4.	Research gaps and future direction. . . . .	00
4.1.	Applicability of Machine learning . . . . .	00
4.2.	Selection of OCT for screening DR . . . . .	00
4.3.	Insights for storing clinical data. . . . .	00
4.4.	Artificial intelligence research in DR resulting in the effectiveness of automatic grading (Joshi and Karule, 2017). . . . .	00
4.5.	Applicability of the algorithm should be narrowed down. . . . .	00
4.6.	Removing the heterogeneity between specific studies such as medical science and computer sciences. . . . .	00
4.7.	Affordability of diagnosing the disease for cost-effective treatment . . . . .	00
4.8.	Performing systematic progression and regression of various lesions for identifying the risk of rapid progression (Sivaprasad and Pearce, 2019). . . . .	00
4.9.	Risk stratification, prediction can be done to determine new biomarkers and determinants for DR . . . . .	00
5.	Conclusion . . . . .	00
	Declaration of Competing Interest . . . . .	00
	References . . . . .	00

## 1. Introduction

The inability of the body to manage the generated insulin leads to diabetes. There are two categories of diabetes, particularly type I and type II diabetes. Type I diabetes is inevitable, and the cause is not known while type II diabetes can be diagnosed by the symptoms present in retinal images. Type II diabetes can be detected by diverse symptoms such as microaneurysms (MAs), Hemorrhages (HEMs), exudates (EXs), cotton wool spots (CWs), etc. When left untreated for more than 5 years and above, it can lead to Diabetic Retinopathy (DR) in ophthalmology (Singh and Dutta, 2017; Williams et al., 2004)

DR produces immutable vision loss revealed in adolescence and declining years. It is projected to attain 191 million by 2030 (Leontidis et al., 2017; Mookiah et al., 2013). The vision loss can significantly be reduced by detecting it in the early stages (Kaur and Mittal, 2018; Khojasteh et al., 2018). DR progression can be controlled by reducing the risk factors mainly hypertension (Nagpal et al., 2021) and hyperglycemia. It can be detected either manually or automatically through Computer-Aided Diagnosis (CAD). The manual inspection of the retinal images is time-consuming. The doctor-to-patient ratio is 1:10,000, so it is difficult for the ophthalmologist to manually detect disease for every patient (Soomro, 2019). The CAD has played a vital role in analyzing medical imaging since 1982 (Soomro et al., 2017; Dai et al., 2019). DR can be detected and graded according to the morphological changes that appeared in the retina due to a prolonged period of diabetes. Detection of morphological changes that include MicroAneurysms (MAs), Hard EXudates (HEX), Soft Exudates (SE) or cotton wool spots, Hemorrhages (HEM), macula, optic disk, optic nerve head, increase in the blood vessel in fundus images is still a tedious task. These morphological changes can be detected either by manual inspection or CAD that can help the ophthalmologist to identify the problem. The morphological changes can be defined in different categories.

The changes that include the detection of increased blood vessels come under the category of proliferative diabetic retinopathy. While the other, which consists of detecting lesions in the form of

HEM, MAs, hard exudates, soft exudates, comes under the category of Non-Proliferative Diabetic Retinopathy (NPDR). So the early diagnosis of DR can be done with the help of CAD through fundus imaging. There are various steps for the detection of DR by fundus images, such as pre-processing, segmentation of images, analysis, and grading of the image according to the disease's severity (Ting, 2019). The severity of the disease can be found out by grading as shown in Table 1. Fig. 1(a–f) shows the various stages of DR. In the early detection of DR, there are no changes observed in the retinal images, while in mild NPDR, the visibility of microaneurysms is there in one of the four quadrants. In moderate NPDR, microaneurysms, hemorrhages, and exudates are present in fundus images. Severe NPDR has the presence of venous beading, microvascular abnormalities occur in the retina, which ultimately leads to the formation of new blood vessels known as neovascularization in PDR.

The purpose of this work was to provide a brief overview of diverse imaging modalities, datasets, and the literature behind detecting the lesions for diagnosing diabetic retinopathy. Although there have been some systematic reviews and meta-analyses for

**Table 1**  
Grading of Diabetic Retinopathy.

Grade	Clinical features	Category
0	No symptoms observed	No Diabetic Retinopathy
1	Presence of MAs in one of the four quadrants	Mild NPDR
2	MAs, dot and blot HEM, HEX, cotton wool spots	Moderate NPDR
3	Intraretinal microvascular abnormalities (in 1 quadrant), Definite venous beading (in 2 quadrants), Intraretinal HEM (>= 20 in each quadrant)	Severe NPDR
4	Neovascularization	PDR
	Vitreous/pre-retinal hemorrhage	

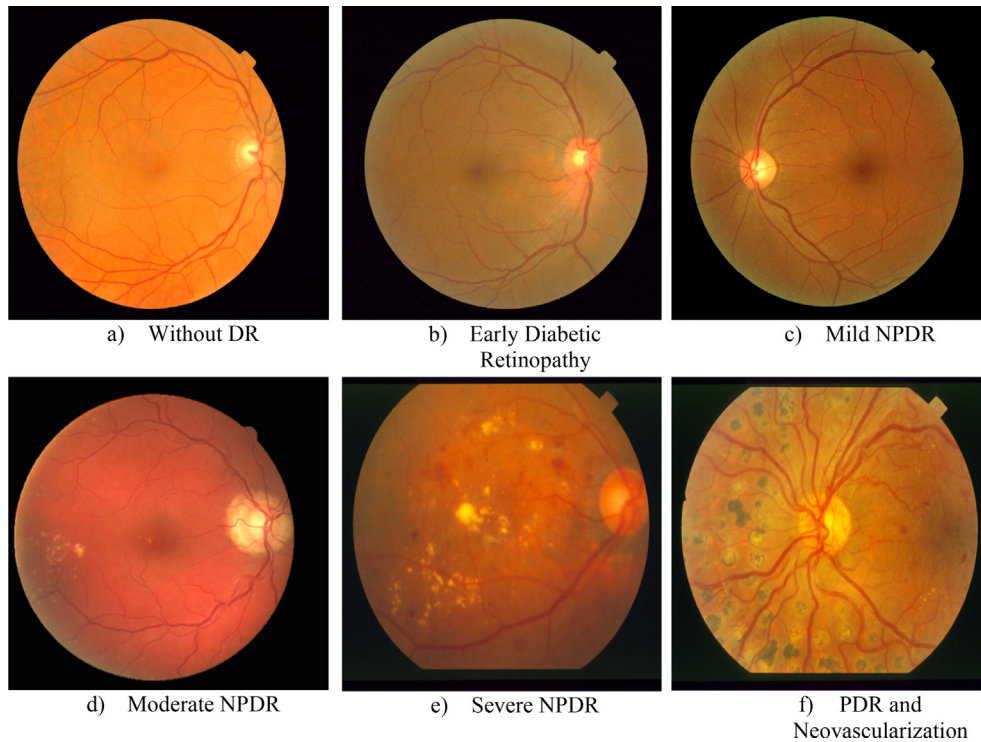


Fig. 1. Stages of DR (Mansour, 2018).

DR, these studies either focus on the single lesion or retinal structures such as blood vessels or focus on AI-based framework to detect DR. Systematic evidence that summarizing the state of the art literature for diagnosing DR along with future gaps has been lacking. Therefore, we conducted a systematic state-of-the-art review for diagnosing DR. The findings in the manuscript should be served as a reference for researchers seeking elaborative research focussing on clinical signs of DR.

In this work, the literature carried out by various researchers on pathological signs of DR has been studied. The rest of the paper is structured as follows. Research methodology containing information about datasets, DR detection techniques and performance metrics have been explained in Section 2. The comparison of existing techniques in Section 3. Research gaps and future directions have been discussed in Section 4 followed by the conclusion in Section 5.

## 2. Research Methodology

This section describes the discussion about diverse retinal datasets, techniques used for diagnosing DR, and performance metrics to evaluate the fundus images. The basic components involved in CAD systems are shown in Fig. 2.

### 2.1. Retinal datasets

In clinical optometry, diverse imaging modalities such as Optical Coherence Tomography (OCT), Fundus Images, and Fluorescein angiography, scan, and ultrasonography have been used for retinal imaging as described in Table 2. While OCT detects retinal vascular abnormality (Kaizu, 2019), fundus images capture the retina's interior part, namely OD, macula, blood vessels. Fluorescein angiography detects the leakage of retinal vasculature. Fundus images can be captured in two ways. One way of capturing the fundus image is dilating the retina with tropicamide (eye drops) and capturing the image known as Mydriatic fundus images. Simultaneously,

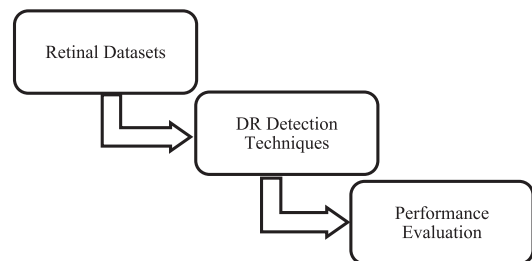


Fig. 2. Basic flowchart for CAD system.

the other way of capturing the fundus image is through the direct ophthalmoscope known as Non-Mydriatic images. The diagnosis of early treatment of DR (Nagpal et al., 2021) can help the patient abate the risk of vision loss. In this paper, we will be focussing on fundus images. There are various retinal signs for detecting DR explained in the next section.

Through imaging modalities, retinal images can be taken from the fundus camera which can reach the internal surface of the retina, blood vessel, posterior pole, OD, and macula. There are widely accessible databases, as shown in Table 3, for research on medical image analysis of DR. Through these datasets, algorithms can be accessible for automatic screening and analysis of various retinal diseases (Amin et al., 2016). Automatic DR screening through multiple algorithms can be performed to accurately diagnosis retinal disease. The decision to select the dataset for performance analysis of developed classifiers should ensure the disease's correct diagnosis. As per the literature, the authors will be focussing on the generalized algorithm through the amalgamation of various datasets (Figueiredo et al., 2015). The datasets focus mostly on specific regions or single DR symptoms, such as retinal vascular segmentation and optic nerve segmentation. Still, there is a need to diagnose DR in a generalized way. Table 3 illustrates

**Table 2**  
Various types of imaging modalities in DR.

Imaging Modalities	Categories	Description	Constraints
Fundus Images	Standard, Widefield, Stereoscopic	<ul style="list-style-type: none"> <li>- To monitor the progression and improvement of diabetic retinopathy.</li> <li>- Screening of DR.</li> </ul>	<ul style="list-style-type: none"> <li>- Evaluation of retinal thickening is not possible.</li> <li>- Visualization of retinal neovascularisation is not possible (Salz and Witkin, 2015).</li> </ul>
FFA	Hypofluorescence, ultra-widefield fluorescein angiography	<ul style="list-style-type: none"> <li>- Neovascularisation in DR can be detected</li> </ul>	<ul style="list-style-type: none"> <li>- Short-term nausea and iodine allergy can be perceived due to the dye injected into the eye (Gajree et al., 2016)</li> </ul>
OCT	Enhanced Depth Imaging OCT, Spectral Domain OCT, Time Domain OCT, Swept-source OCT	<ul style="list-style-type: none"> <li>- To calculate the thickness of retinal vasculature.</li> <li>- It can detect different layers of the retina and micro-anatomical features of the retina</li> </ul>	<ul style="list-style-type: none"> <li>- To visualize the vessel leakage</li> <li>- The field of view is minimum (Saeed and Oleszczuk, 2016).</li> </ul>
B-Scan	-	<ul style="list-style-type: none"> <li>- The posterior vitreous damage and the vitreous hemorrhage have been visible in this.</li> <li>- It is effective if the retinal detachment is present</li> </ul>	<ul style="list-style-type: none"> <li>- If the media is not lucid, the imaging of diabetic retinopathy is not useful.</li> </ul>

the various gold standard dataset available for training and testing the model. However, different private datasets such as RIM-ONE, SCES, SEED DB, NeuB1 (Wei Shao and Huang, 2019), FAZ (Foveal Avascular Zone), Tianjin Medical University Metabolic Diseases Hospital, SGHS hospital, CLEOPATRA, Jichi Medical University, Moorfields Eye Hospital, Singapore National Diabetic Retinopathy Screening Program, Hospital of Puerta del Mar, Spain (HUPM) (Abbas et al., 2017), Cádiz, Spain, Lotus Eye Care Hospital Coimbatore, Department of Ophthalmology, Kasturba Medical College, Manipal, India (KMCM) (Ganesan et al., 2014) can also be used for diagnosing the disease (Arcadu et al., 2019; Mateen et al., 2020; Salz and Witkin, 2015; Salamat et al., 2019).

## 2.2. DR detection techniques

Retinal signs help diagnose DR. Various approaches have been implemented so far, for identifying retinal features. The extensive study for diagnosing various pathological signs in DR has been discussed in the following subsections. Fig. 3 shows the techniques of retinal signs present in DR.

### 2.2.1. Microaneurysms detection

Microaneurysms (MAs) are the swollen capillaries caused by the weakening of vessel walls secondary to diabetic Mellitus (Chudzik et al., 2018). These are the earliest abnormality of DR that appeared as small red rounded dots, having a diameter of 10–100  $\mu\text{m}$ . These can be found anywhere in the form of cluster, isolated, or within the diabetic macula as shown in Fig. 4. It causes leakage of the blood vessels (Benzamin and Chakraborty, 2018). The disease's progression leads to the appearance of other pathological signs such as HEX, HEM (Savelli et al., 2020; Xue et al., 2019). Following is the work done used to detect MAs in fundus images. A survey has been described to review the teams that participated in the Retinopathy Online Challenge (ROC), MAs challenge are described. Different teams used different techniques that are displayed in Table 4 (Porwal, 2020).

Detection of MAs in fundus images has been done by a screening system that can extract features and texture characteristics using Local Neighbourhood Differential Coherence Pattern (LNDPC), and Feed Forward Neural Network (FFNN) has been developed. The method is analyzed on dataset ROC and AGAR300 and achieves a Free-response Receiver Operating Characteristic (FROC) score of 0.481/0.442 respectively (Jeba Derwin, 2020).

**2.2.1.1. Support Vector Machine.** Detection of MAs using patches in the DIARETDB1 dataset has been proposed. The input dimensional-

ity can be removed by applying principal component analysis and random forest techniques, which achieves the AUC of 0.985 and F measure of 0.926 (Cao et al., 2018). The method has been validated on the ROC dataset. The author also proves the SVM's efficiency is more in terms of sensitivity and noise features than Neural Network. The feature extraction and grading of different features can be done with more performance metrics like Sensitivity, Specificity, etc. While the authors in (Sudha et al., 2018) have done the detection by extraction of the lesion using graph cut segmentation, SVM and PCA have been used for classification and severity of DR. The method is implemented on the lab dataset. It achieves the sen/spec of 94.44/87.5 respectively.

**2.2.1.2. Convolution Neural Network.** The authors in (Savelli et al., 2020) focus on detecting the lesion in medical images that are based on the multi-context ensemble of CNN. This method has been implemented on image patches using multi-depth CNN and combined. Local features and the lesion's surrounding context has been used to identify the abnormalities. The method was implemented on datasets INbreast and E-opththa focussing on microcalcification detection in mammograms and MAs' detection in ocular fundus images (Savelli et al., 2020). The red lesion detection by integrating domain knowledge with deep learning has been proposed by (Orlando et al., 2018). Ensemble vectors have been used by expanding the features learned from CNN and handcrafted features. The detection of the true lesion has been done by implementing a Random forest classifier. This method has been analyzed on DIARETDB1 and E-opththa dataset and attains the AUC/sen of 0.8932/0.9109 in the screening of DR in the Messidor Dataset (Orlando et al., 2018). A framework for the detection of MAs using multi-sieving CNN and image to text-mapping feature space has been developed. The expert knowledge has been extracted from the clinical report through various data mining techniques and the mapping of visual features is done in semantic profiles. The combination of textual information and retinal images is used to get a high rate of detection accuracy rate. Some issues related to retinal images such as misleading visual cues, unbalanced datasets, varying imaging conditions have been overcome by combining multimodality and multi-sieving classification approach. The authors have implemented the framework on DIARET DB1 dataset and achieves the recall/ precision/acc/f1 score of 0.878/ 0.997/ 0.961/ 0.934 respectively. This framework is generic and can be implemented to detect different types of lesions in DR (Dai, 2018). Fuzzy image processing and deep learning have been employed for the detection of microaneurysms in (Rahim et al., 2020). The pre-processing is done by fuzzy image processing

**Table 3**  
Databases for detecting DR.

S. No.	Dataset	No. of Images	Capturing Device	Field of View	Resolution	Motivation
1.	MESSIDOR (Messidor – ADCIS, 2020)	1200 fundus images	3CCD camera mounted on a Topcon TRC NW6 non-mydiatic retinograph	45	1440*960, 2240*1488 or 2304*1536 pixels.	Detection of Lesions
2.	MESSIDOR-2 (Pires et al., 2019)	1748 fundus images	Topcon TRC NW6 non-mydiatic fundus camera	45	1440*960, 2240*1488 or 2304*1536 pixels.	Detection of Lesion
3.	EYEPACS (Gulshan, Dec. 2016)	9963 fundus images	Centervue DRS, Optovue iCam, Canon CR1/DGi/CR2, and Topcon NW	45	–	Screening of DR
4.	ImageRet (DIARET DB0 (DIARETDB0, 2020) (DIARET DB1 (DIARETDB1, 2020)	DIARET DB0 120 fundus images; Diaret DB1 189 fundus images	Digital Fundus Camera	50	1500*1152	Detection of Lesions
5.	DriDB (DRiDB image dataset, 2020)	50 fundus images	Zeiss VISUCAM 200 camera	45	720 × 576	Detection of lesion
6.	DRIONS -DB (DRIONS-DB Retinal Image Database, 2020)	110 fundus images	HP-PhotoSmart-S20 high-resolution scanner	–	600x400 pixels	Detection of OD
7.	DRIVE (Niemeijer et al., 2004)	40 color fundus images 20 training images	Canon CR5 non-mydiatic 3CCD camera	45	768*584	Detection of lesions
8.	STARE (The STARE Project, 2020)	400 fundus images	Topcon TRV-50 fundus camera	35	605 × 700 pixels	Detection of exudates and HEM
9.	e-ophtha (E-ophtha - ADCIS, 2020)	47 fundus images with exudates 35 fundus images without lesions. 148 images with MAs and small HEM 233 fundus images with no lesions	OPHDIAT	45	1440 × 960 pixels to 2544 × 1696 pixels.	Detection of Exudates and MAs
10.	CHASE-DB1 (Mo and Zhang, 2017)	28 fundus Images	Nidek NM-200-D	30	1280x 960	Retinal Vessel Segmentation
11.	HEI-MED (Giancardo et al., 2012)	169 fundus images 115 abnormal 54 healthy	Zeiss Visucam PRO fundus camera	45	2196 × 1958	Detection of exudates
12.	Review (Khan et al., 2019)	16 fundus images	Canon EOS D30	50	3584 × 2438, 1360 × 1024, 2160 × 1440	Segmentation of retinal vessels
13.	DRISHTI-GS (Sivaswamy et al., 2014)	101 fundus images 50 training fundus images 51 testing fundus images	–	30	2047 × 1760 pixels	Segmentation of ONH
14.	ARIA (Arunkumar and Karthigaikumar, 2017)	212 color fundus images: 92 (AMD), 59 (DR), 61 (normal) images	Zeiss FF450 + fundus camera	50	768 × 576	Detection of diabetes and age-related macular degeneration.
15.	ViCAVR (Khitran et al., 2015)	58 fundus images	TopCon non-mydiatic camera NW100		768x584	Retinal vessel and compute A/V ratio
16.	ROC (MAs) (Chudzik et al., 2018)	100 fundus images	Canon CR5-45-NM camera	45	768 × 576, 1058 × 1061, and 1389 × 1383	Detection of MAs
17.	High-Resolution Fundus (HRF) Image Database (Guo and Peng, 2020)	66 fundus images	Canon CR-1 fundus camera	45	3504 × 2336 pixels	Automatic Segmentation Algorithm
18.	ONHSD (Molina-Casado et al., 2017)	99 fundus images	Canon CR6 fundus camera	45	640 × 480	Detection of optic nerve
19.	DR HAGIS (Holm et al., 2017)	39 fundus images	Canon CR DiGi (Canon Inc., Tokyo, Japan), Topcon TRC-NW6s (Topcon Medical Systems, Oakland, New Jersey), and Topcon TRC-NW8 (Topcon Medical Systems, Oakland, New Jersey)	45	4752 × 3168, 2816 × 1880, 3456 × 2304, 2896 × 1944, 3216 × 2136	DR, age-related macular degeneration, hypertension, and glaucoma detection image system
20.	IDRID (Porwal, 2020)	516 color fundus images	Kowa VX-10α digital fundus camera	50	4288 × 2848	Screening of DR
21.	FIRE (Hernandez-matas et al., 2017)	134 fundus Images	Nidek AFC 210 fundus camera	35	2912 × 2912	Detection of a dark and bright lesion
22.	RODREP (Longitudinal diabetic retinopathy screening, 2020)	1120 fundus images	Topcon TRC-NW65 non-Mydiatic	45	2000 × 1312	Screening of DR

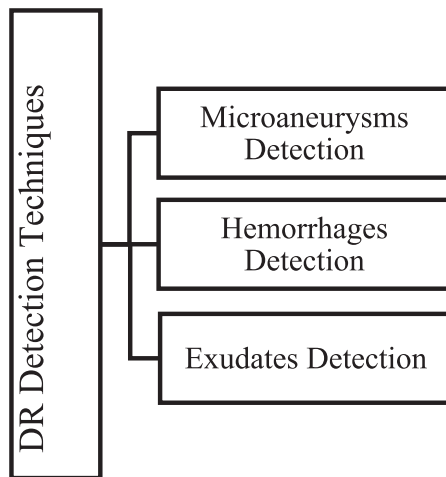


Fig. 3. Retinal signs present in DR.

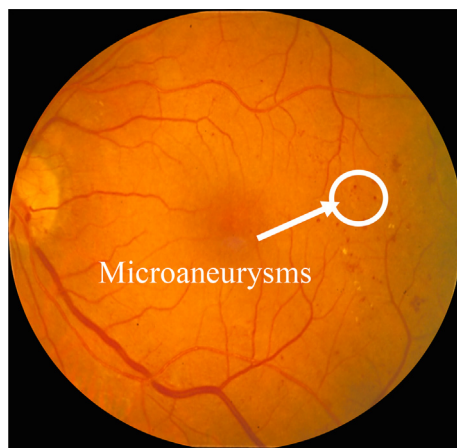


Fig. 4. Presence of MAs in fundus Images.

Table 4  
Different techniques used by teams (Kande et al., 2010).

Method	Team Name	Technique
Method 1	Valladolid	Normalization, candidate extraction, Gaussian models, Vessel segmentation, logistic regression
Method 2	Waikato	Green Plane, Normalization, top hat, morphological reconstruction, Bayesian Classifier
Method 3	Latim	Rotation-symmetric generalized, Gaussian functions, template matching, wavelet transform
Method 4	Ok Medical	Gaussian filter bank, adaptive thresholding, candidate extraction
Method 5	Fujita Lab	Pre-processing, Original double-ring filter, region growing, ANN

techniques and classification is done by the deep neural network. In addition to that, a novel dataset has been proposed for the detection of microaneurysms. Experimental evaluation has been done on the private dataset and the authors concluded that there is an increase in system performance for the detection of microaneurysms. However, by implementing a diverse combination of pre-processing techniques, retinal structure extractions, the existing system can be enhanced.

2.2.1.3. *Deep learning.* Automatic detection of MAs has been proposed using deep learning to handle the previous problems viz

false detection and imbalanced dataset. Two-stage CNN has been implemented to overcome the problem of automatic detection of MAs. The proposed method has been implemented on two datasets, namely ROC and E-Ophtha MA, and attains the AUC for the unbalanced dataset as 0.660 and 0.637 respectively (Eftekhari et al., 2019). The alternatives to AUC have been proposed in (Carrington et al., 2020) for having a more accurate evaluation of deep learning models. The authors in (Aishwarya et al., 2017) had detected the MAs through three classifiers' amalgamation. A hybrid classifier has been proposed that comprises the decision tree, SVM, and Naive Bayes classifier. This classifier has been implemented on the DIARETDB dataset and achieves the acc of 82.2 and sen/spec of 82/82 respectively. The reduction of features can be made by the decision tree method. The gradient weighing technique and adaptive thresholding have been used to extract the MAs candidate followed by local convergence index filters (LCF) for intensity and shape filters. This method has been tested on six gold standard datasets regardless of imaging modalities and resolution which achieves the sensitivity of 0.471 (Dashtbozorg et al., 2018). The comparison for the detection of microaneurysms has been described in Table 5.

### 2.2.2. Hemorrhages detection

The early sign of diabetic retinopathy, which comes after microaneurysms is HEM. HEM is the blood vessel due to breaches in capillaries larger than MAs. There are three types of HEM namely pre-retinal, sub-retinal, retinal, flame, dot, and blot HEM, as shown in Fig. 5(a--f). The HEM shapes are irregular and are increasingly visible with the progression of the disease (Sinthanayothin et al., 2002; Soomro et al., 2017). HEM is the red lesion present in the fundus images. Following is the work done used to detect HEM in fundus images. The review of the detection of HEM in DR has been explained. The shape and number of HEM can determine the severity of the disease. Various algorithms, techniques, and methodologies that can be used to detect the HEM in fundus images have been reviewed (Jitpakdee et al., 2012), as shown in Table 6.

An approach for the detection of HEM has been proposed. The approach consists of various image enhancement methods such as pre-processing, segmentation, determination of HEM regions, and HEM detection with SVM and linear regression techniques. The SVM classifier achieves the sen/spec/acc of 96.7%/94.1%/91.4% respectively (Adem et al., 2019). While the authors in (Murugan, 2019), detected the HEM using motion pattern, green channel extraction, ROI, Radon transform. The proposed technique has been applied to the Messidor dataset and achieves the sen/spec of 97%/98%. The authors in (Mumtaz et al., 2018) diagnosed the HEM by Various methods such as contrast enhancement, and normalization has been applied to enhance the image's quality and thus eliminate the background noise. Segmentation of blood vessels has been done by using scale based method. Then HEM was described using gamma correction and global thresholding technique, the proposed work has been implemented on the DIARETDB1 dataset and achieves the sen/spec of 87%/84% respectively.

Red lesion detection has been proposed using pixel classification and mathematical morphology. Red and green channel has been used for brightness and high contrast respectively. Gray level has been used to distinguish between enhanced red lesion segmentation and background. Matched Filtering and local relative entropy thresholding algorithm have been used in this approach. It achieves the sen/spec of 100%/91% respectively (Kande et al., 2010). Low contrast retinal images have been analyzed by using morphological image processing and K-Means clustering for exudates detection. The proposed algorithm has been compared with hand-drawn ground truth images. It has been analyzed on the

**Table 5**  
MAs Detection in Fundus Images.

Work	Performance Dataset	Testing Dataset	Technique	Performance Evaluation	Upsides	Future Directions
(Savelli et al., 2020)	INbreast and E-ophtha	–	Multi depth CNN	Sen 81:62%	Detection of MAs by using image patches and the multi-context ensemble of CNN	Similar CAD problem can be detected and improvement in performance can be made
(Jeba Derwin, 2020)	ROC	AGAR 300	LNDPC, FFNN	FROC 0.481/0.442	Detection of MAs by improving the luminosity has been done	It can be extended to measure various challenges for diagnosing DR.
(Cao et al., 2018)	DIARET DB1	ROC Dataset	Random Forest, PCA, and SVM	AUC 0.985 F-measure 0.926	Provides generality of the method for detection of MAs	Different Performance metrics can be used to detect Mas To extract and classify various features.
(Sudha et al., 2018)	Lab dataset using a fundus camera	–	SVM, Graphcut, PCA, CLAHE,	sen/spec : 94.44/87.5	This method effectively detect MAs by removing blood vessel	Detection of HEM for increasing performance
(Orlando et al., 2018)	E-ophtha and Diaret DB1	Messidor	CNN, random forest classifier,	Screening Auc/sen 0.8932/0.910 Referral AUC/sen 0.9347/0.972	Detection of the red lesion	Performance analysis can be improved
(Dai, 2018)	Six People's Hospital (Lab data)	DIARETDB1	Multi-sieving CNN(MS-CNN)	recall: 0.878, precision: 0.997 accuracy :0.961 and f1 score :0.934	Generic method irrespective of the challenges faced in the detection of lesion	The efficiency of the framework can be improved. This framework can be extended to detect various lesions.
(Rahim et al., 2020)	Department of Ophthalmology, Melaka Hospital, Malaysia (Private Dataset)	–	Fuzzy pre-processing, CNN	Acc: 66 ± 70%	Improvement in contrast and performance for automatic detection of Mas	A diverse combination of preprocessing techniques can be applied to enhancing the system
(Eftekhari et al., 2019)	ROC and E-Ophtha MA	–	Two-stage CNN	Screening Auc/sen 0.8932 0.9109 Referral AUC/sen 0.9347 0.9721	Detection of MAs	Auto ML method can be implemented to address hyperparameter tuning and imbalance data issue
(Aishwarya et al., 2017)	DiaretDB1	–	SVM, Naïve Bayes, and decision tree	acc of 82.2 and sen/spec of 82/82	Detection of MAs using a hybrid classifier	Automatic detection and grading of DR
(Dashtbozorg et al., 2018)	e-ophtha-MA, ROC and DiaretDB1	e-ophtha MA, DiaretDB1, ROC and MESSIDOR RC-RGB-MA and RCSLO-MA	Gradient Weighing technique, Adaptive thresholding, LCF	Sensitivity: 0.471	This method outperforms on six datasets regardless of imaging modalities and resolution	Detection of Dot HEM and Bright lesion

DIARETDB1 dataset and achieves the sen/spec of 88.34%/99.27% respectively (Biyani and Patre, 2016).

### 2.2.3. Exudates detection

Exudates are the lipids that leak from damaged fluids. These are the second prevalent abnormality in DR, which appears as the small yellowish and white dots formed due to fats and cholesterol deposits, as shown in Fig. 6(a,b). These are the bright features observed in the retina. These are of two types, namely soft exudates (SE) and hard exudates (HEX) (Matsopoulos et al., 1999). While SE appears white, HEX appears yellowish in retinal fundus images (Huan Wang et al., 2000). Following is the work done used to detect exudates in fundus images.

The authors have detected the exudates by using a gray level variation. Detection of the OD has been done by morphological technique, and watershed transformation and exudates can be found by contour using morphological reconstruction techniques. The method has been implemented on Topcon TRC 50 IA retinograph dataset and achieves the sen, predictive value of 92.8/92.4 (Walter et al., 2002). Authors have proposed a technique in (Amin et al., 2018) to automatically detect exudates using various steps such as pre-processing, segmentation, feature extraction, and classification. Initially, adaptive thresholding with mathematical

morphology was applied for the segmentation of the lesion. This technique has been evaluated on 4 datasets as DIARETDB1, Messidor, E-ophtha, and local datasets. The results are 0.99/98.9% AUC / ACC on E-ophtha, 100/100% on local, Messidor, and DiaretDb Dataset. The segmentation of exudates has been proposed by implementing CNN. Various procedures such as OD detection and vessel detection have been combined to have accurate knowledge of the exudates' location. The proposed detection has been implemented on DriDB and achieves the F1 measure of 0.78 (Prentašić and Lončarić, 2016).

The authors have detected HEX with the help of deep CNN. The existing method for detecting the exudates uses manual detection of features. This methodology works well for automatically detecting exudates using DCNN and multi-faceted joint representation. For the segmentation of exudates, mathematical morphology has been used. Then, the candidate's characterization is done using ridge-based regression feature fusion. This method utilizes various features and descriptors to learn the information of exudates. To identify true exudates, a random forest technique has been implemented. The proposed method has been implemented on two datasets HEI-MED and e-ophtha which achieve the F- score/AUC of 0.9326/0.9323 and 0.8929/0.9644 respectively (Wang et al., 2020).

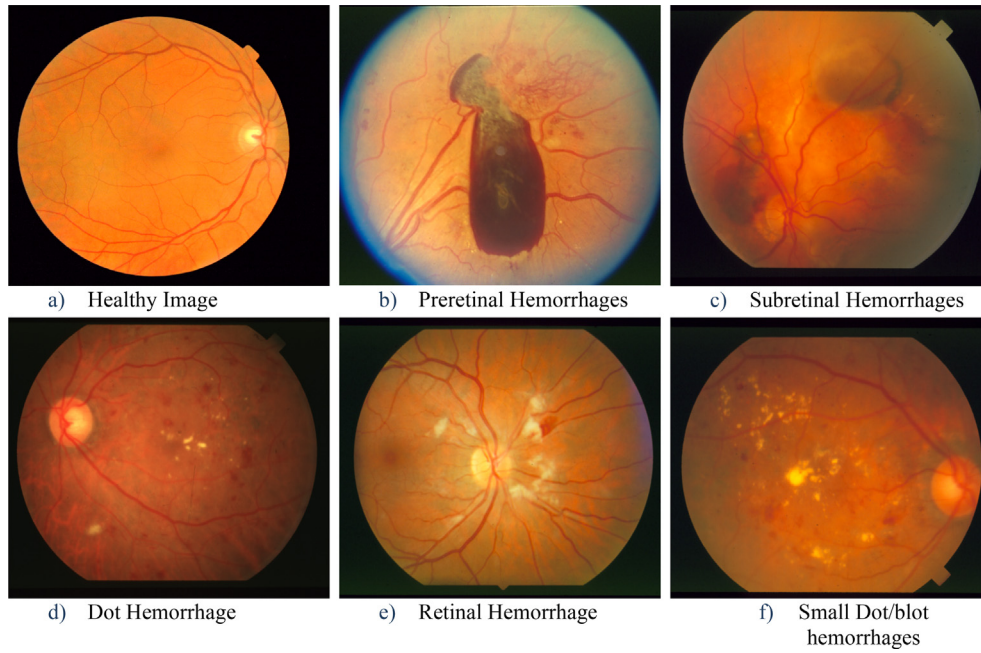


Fig. 5. Types of hemorrhages (Murugan, 2019).

Table 6  
Related Work in HEMs.

Work	Performance Dataset	Technique	Performance Evaluation	Description	Future Directions
(Adem et al., 2019)	Gaziosmanpaşa University Faculty of Medicine's Department of Ophthalmology (Lab Dataset)	Iterative thresholding, Firefly and Particle Swarm, SVM and Linear Classifier	Sen/spec/acc 96.7%/94.1%/91.4%	Detection of HEM using image enhancement techniques	Increasing sensitivity and specificity values.
(Murugan, 2019)	MESSIDOR	motion pattern, green channel extraction, ROI, Radon transform	sen/spec of 97%/98%	Detection of HEM using motion pattern	Deep learning for grading of DR
(Kande et al., 2010)	STARE, DIARETDB, Private eye hospital	Matched Filtering and local relative entropy thresholding algorithm, Red and green channel	Sen/spec 100/91	Detection of HEM	–
(Mumtaz et al., 2018)	DIARETDB1	contrast enhancement and normalization, scale-based method, gamma correction, and global thresholding	Sen/spec 87/84	Detection of HEM	Fine-tuning of results will be done by implementing adaptive thresholding techniques with a supervised method.
(Biyani and Patre, 2016)	DIARETDB1	K-Means Clustering and morphological image processing	Sen/spec: 88.34/99.27	Detection of HEM	Applying machine learning and include other features.

The generalized method for detecting exudates has been proposed for diagnosing DR. Suppression of the retinal vessel has been done using morphological processing and various techniques such as masking, texture enhancement, Adaptive inference system has been implemented to differentiate between normal and pathological structures. The proposed work has been implemented on STARE and Messidor datasets and the classifier achieves the acc of 88% for the Adaptive neuro-fuzzy inference system classifier (Saravanan, 2019). The comparison of various techniques and datasets used so far to detect Exudates has been described in Table 7.

### 2.3. Performance evaluation metrics

The performance for diagnosing the disease and calculating the severity of the disease has been evaluated through various parameters such as true positive (TP), false positive (FP), false negative (FN), and true negative (TN) rates (Khojasteh et al., 2018). Here P

is known as positive prediction (TP + FN), and N is known as negative prediction (TN + FP). There are various performance measures (Soomro, 2019; Salamat et al., 2019).

#### 2.3.1. Sensitivity/Recall/True positive rate

The ratio of correctly detected objects to the total number of objects is known as sensitivity as shown in Eq. (1).

$$Sen = \frac{TP}{P} \quad (1)$$

#### 2.3.2. Specificity/True negative rate

In Equation (2) specificity is defined as the ratio of correctly detected non-objects classes to the total number of object classes.

$$Spec = \frac{TN}{N} \quad (2)$$

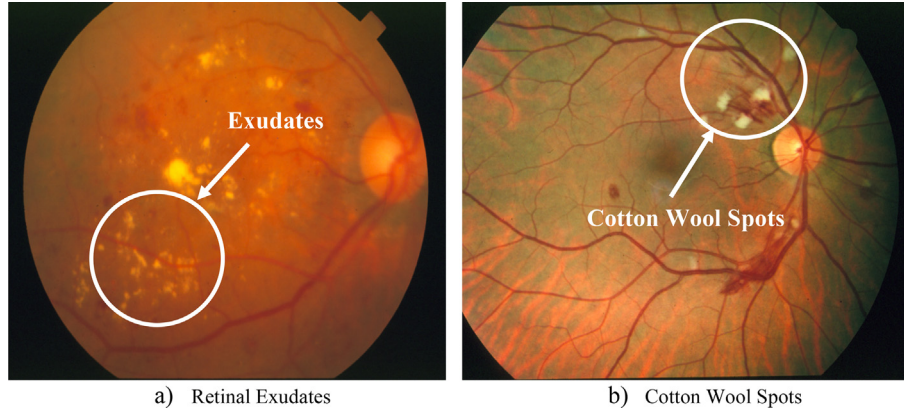


Fig. 6. Retinal fundus images showing exudates (Kaur and Mittal, 2018).

Table 7  
Related Work in Exudates.

Work	Technique	Dataset	Performance analysis	Future directions
(Walter et al., 2002)	Morphological filtering techniques, Watershed transformation	Topcon TRC 50 IA retinograph (own dataset)	Sen 92.8% Mean predictive value of 92.4%.	Detection of macular edema The distinction between hard and SE.
(Amin et al., 2018)	Mathematical morphology, Ensemble, Bayes Net, Naive Bayes	DIARET DB1, DIARETDB1, Messidor, E-ophtha and local datasets	0.99/98.9% AUC /ACC 1.00/100% on local	Detection of different types of lesions.
(Wang et al., 2020)	Deep CNN, Mathematical Morphology, Ridge-based regression feature, Random Forest	e-ophtha HEI-MED	F-score/AUC 0.8929/0.9644 0.9326/0.9323	Detection of different types of lesions.
(Prentašić and Lončarić, 2016)	CNN	DriDB	F1 measure of 0.78	Enhancing the network by using various channels, pre-processing, and post-processing steps.
(Saravanan, 2019)	Masking, Textural enhancement, and Adaptive neuro-fuzzy inference system classifier	STARE and MESSIDOR	88%	Detection of different types of lesions.

### 2.3.3. False positive rate

The ratio of non-correctly detected objects (FP) to the correctly identified non-objects (TN) is known as the false positive rate and it is described in Eqs. (3) and (4).

$$FPR = \frac{FP}{N} \quad (3)$$

or

$$FPR = 1 - Spec \quad (4)$$

### 2.3.4. False-Negative rate (FNR)

FNR is described as the ratio of FN and TP as mentioned in Eq. (5).

$$FNR = 1 - Sen \quad (5)$$

### 2.3.5. Accuracy

The sum of correctly detected objects and non-objects to the sum of the total number of objects is known as accuracy and it is shown in Eq. (6).

$$Acc = \frac{TP + TN}{P + N} \quad (6)$$

### 2.3.6. AUc

Area covered by receiving the operating curve that measures the system sensitivity to detect the output and the equation is shown in (7).

$$AUC = \int_{-\infty}^{\infty} TPR(T)FPR'(T)dT \quad (7)$$

### 2.3.7. F1-score

It divulges the balance between recall and precision.

$$F1 - score = \frac{2 * Precision * Recall}{Precision + Recall} \quad (8)$$

### 2.3.8. Error rate

The sum of not correctly detected objects and non-objects to the sum of the total number of pixels.

$$Er = \frac{FP + FN}{P + N} \quad (9)$$

### 2.3.9. Positive predictive value (Precision)

The probability of correctly detected objects truly has corrected objects.

$$PPV = \frac{TP}{TP + FP} \quad (10)$$

### 2.3.10. Kappa score

Measuring interrater reliability.

$$Kappascore = \frac{Acc - Acc_{prob}}{1 - Acc_{prob}} \quad (11)$$

These performance evaluation metrics help researchers for providing the availability of formulae and for a better understanding of the metrics in the literature.

## 3. Comparison of existing DR detection techniques

After discussing the early signs of DR individually, the performance metrics used in literature, the comparison of DR including all three lesions has been explained as follows. The detection of DR can be done by various retinal signs that have been illustrated in Fig. 7.

The problem of the interpretability of diagnosing and grading DR has been discussed. The inter grader variability (Krause et al., 2017) has been analyzed by cosine similarity for the quality of annotation. The different methods are then compared using logistic regression, namely SASG, SAMG, MAV, and DAAD. The prediction performance is highest in DAAD and SAMG when both prediction performance and grading costs were considered. It achieves an accuracy of 91.2% for DR-related features and 95.6% for DR severity prediction (Wang et al., 2019).

The authors have done the detection of MAs and HEM. The precise segmentation of regions is not required in this method. This method deals with a set of shape features that constitute the shape's development during image flooding. This method has been validated on six datasets and achieves an FROC score of 0.420. The automatic grading and the detection of the bright lesion and small vessels can be done in the future (Seoud et al., 2016). A curvelet-based algorithm has been presented to detect red lesions from retinal images. A new equalization algorithm has been introduced to preclude fovea considering red lesions. A digital curvelet transform has been applied to enhance the image. Separation of lesions has been done by using various thresholds. The proposed algorithm has been implemented on 89 retinal images and achieves the sen/spec of 94/87 to detect red lesions (Esmaeili et al., 2014). Early detection of DR has been done by designing a localization model that uses a patch-based approach. In this, the model's complexity has been reduced while improving the performance by selecting the training patches. The classification has been done using a probability map. The proposed model has been implemented on the DIARET DB1 dataset and achieves the ROC of 0.912 and sen of 0.940 (Dorizzi et al., 2019).

The detection of pathological signs such as MAs, HEM, exudates has been done. Morphological operators and CLAHE and SVM vector are used to grade diabetic retinopathy, which produces the area

under RUC value between normal and mild, mild and moderate, and moderate vs. severe NPDR ratio 0.9106, 0.8372, 0.9750, respectively (Dhara et al., 2015).

Various techniques have been implemented for detecting features viz blobs and blood vessels. The pre-processing of the images has been done by extracting the green channel followed by segmentation using the Otsu algorithm, feature extraction using Hough transform, and classification of detection using an SVM classifier. The proposed algorithm has been implemented in DIARET DB0 Dataset and achieves the sen/spec of 73/70 in blob detection and 77/80 in blood vessel detection (Sakshi Gunde and Gupta, 2020).

This paper implemented the automated severity detection of DR (SDDR) method for checking the severity of DR disease with a dictionary-based approach. This approach combines the pathological representation of an image into a learning outline. The features are created using the point of interest and grouped to create a dictionary. Then coding and pooling method is then applied along with the histogram-oriented gradients for the compressed presentation of features. Radial basis SVM and Neural Network has been used for 5-level classification of images. The method is implemented on the Kaggle National Data Science Bowl dataset and achieves the sen/spec/acc of 95.2%/98.9%/98.3 (Leeza and Farooq, 2019).

Authors in (Hajeb Mohammad Alipour et al., 2012), determined the severity of diabetic retinopathy stages by using fluorescein angiography and color fundus images. A Curvelet-based algorithm has been introduced by authors along with SVM to extract features such as area, the number of microaneurysms, blood vessels, regularity of foveal avascular zone for detecting the severity of DR. For extraction of microaneurysms, blood vessels are extracted and subtracted with the original image. The experimental evaluation has been done on a user-developed dataset (Ophthalmic image processing Medical Image and Signal Processing Research Center, 2021) and achieves the sensitivity and specificity value of 100% for grading. Their future work includes the implementation of various other transforms such as contourlet transform, shearlet transform in place of Curvelet transform.

The detection of DR and maculopathy has been presented in (Rahim et al., 2015) using fuzzy image processing. While maculopathy is essential, an unaffected macula may eventually lead to vision loss. The proposed detection system includes image acquisition, pre-processing through fuzzy techniques, feature extraction followed by classification by various machine learning techniques. The system is implemented on its dataset having 2 categories for classification. The one category with 2 classes has achieved the misclassification error/acc/sen/spec of 0.2539/0.7461/0.4536/0.8403 for binary decision tree and 0.2139/0.7861/0.5572/0.8598 for the k-nearest neighbor. The second category with 10 classes achieved the misclassification error/acc/sen/spec of 0.4395/0.5605/0.4500/0.5956 for binary decision tree and 0.2975/0.7025/0.6500/0.7297 for k-nearest neighbor. The future work focuses on research in machine learning by extracting graphs from images. Four scales grading the severity of DR with the help of CNN have been proposed. A novel dataset has been presented with advantageous labeling for clinical practice. The whole dataset has been transformed into a uniform format with a processing pipeline's help. Inception V-3 model has been implemented to evaluate the performance with various mainstream models. All the trained models have been systematized in the cloud for pilot diagnostic service. The approach achieves an accuracy of 88.72% for grading DR (Gao et al., 2019).

The authors have detected the DR through the ensemble method to classify and encode features. Various CNN models were applied to the Kaggle dataset. This method detects all the stages of DR. The authors explain the accuracy, sensitivity parameters

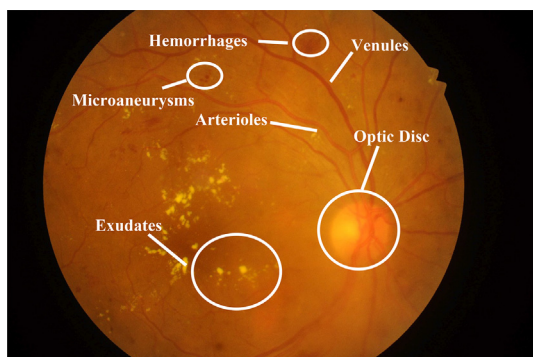


Fig. 7. Fundus Images showing signs of DR (Khojasteh et al., 2018).

according to the severity of classes and outperform the state-of-the-art methods (Qummar, 2019). Various pre-processing methods have done a screening of DR with CLAHE have been discovered, but the method's performance decreases with the increasing no. of classes. CNN has been applied in which transfer learning has been used on Image Net, Google Net, and AlexNet, which achieves the accuracies of 74.5% on 2-ary classification, 68.8% on 3-ary classification, and 57.2% on 4-ary classification models (Carson Lam and MD1, 2017). Classification of fundus images using CNN has been proposed for grading the image according to the severity of the disease. The various layers have been applied to acquire higher accuracy. The proposed Alex net architecture has been tested on the Messidor dataset with the accuracies of 96.6%, 95.6%, 96.2%, 96.6% in stage 3, Stage 2, Stage 1, and healthy images, respectively (Shanthi and Sabeenian, 2019). Image processing and deep learning techniques have been implemented efficiently, for diagnosing diabetic retinopathy and maculopathy. In (Rahim et al., 2019) the authors have improved the classification performance by augmenting the data and using pre-processing techniques. Moreover, the authors also proved that classification models can be improved by applying combinations of pre-processing techniques or by using diverse image augmentation techniques. The proposed techniques have been implemented on the private dataset and achieve an accuracy of 77% approx.

Diagnosis of RDR has been made by obtaining binocular fundus images, and prediction has been made based on the learning correlation. This model achieves the AUC/sen/spec of 0.951%/ 82.2%/ 70.7% which excels in the existing monocular model. In this proposed approach, the transfer learning technique is implemented using CNN with Siamese-like architecture (Zeng et al., 2019).

The author deals with automatic lesion detection by extraction of the vessel and removal of the OD, followed by the pre-processing of the image. The candidate extraction has been done using filtering, and the lesion is detected after post-processing the image. Micro-aneurysms and HEM is the dark lesion and exudates, and cotton wool spots are the bright lesion. The dark lesion from the background curvelet-based edge enhancement has been used. This model achieves an accuracy of 97.71% for detecting diverse types of lesions. The experimental results are Sen/ spec/ acc/ AUC for exudates, MAs; HEM is 97.81/ 98.18/ 98.32/ 0.9684, 95.23/ 95.12/ 97.23/ 0.9443, 97.67/ 97.74/ 96.99/ 0.9665. There is an unwitting selection of the parameters disregarding the image's shape, size, and texture. The falsely detected lesion due to their innate properties can be removed by a morphological operator in post-processing steps (Kar and Maity, 2018). Detection of MAs and grade the retinal images into five groups have been proposed. A novel CNN based deep neural network has been submitted using data augmentation, L2 regularization, and various preprocessing-based methods. It achieves the sensitivity/specificity and AUC score of 98%/94% and 0.844 (Islam et al., 2018). CNN-based network for automatic identification of retinal diseases has been discussed. Data augmentation and elaborated features are used to identify the severity of the disease. This method is implemented on the Kaggle dataset and achieved the accuracy/sensitivity of 75%/95%. Diagnosing and classification of DR have been proposed in this paper. For this, CNN architecture has been used to classify MAs, HEM, and exudates by developing a network. The approach has been evaluated on the Kaggle dataset and achieves the sen/ acc of 95/75 on validation images. The future work will be to have a cleaner dataset to avoid the problem of overfitting and underfitting problem (Pratt et al., 2016). The authors have adopted various models such as GoogleNet, AlexNet, ResNet, and VggNet to classify DR images. The proposed attempt has been implemented on the Kaggle dataset and achieves an accuracy of 95.68% by using transfer learning and hyperparameter tuning of these models (Wan et al., 2018).

The authors have proposed an unprecedented approach based on Deep CNN that uses descriptive features and max-pooling layers that were replaced by fractional pooling for detection of DR. The features of the images are combined and trained using the SVM classifier, which classifies the severity into five classes grouping from level 0–4. An app named “Deep retina” has also been developed that can be equipped with a handheld ophthalmoscope and the person taking fundus images can get instant results. The experimental results on the Kaggle dataset achieve 86.71% for 5-class classification and 91.05 for binary class classification and sensitivity/Specificity for a binary type are 0.8930/0.9089, respectively (Li et al., 2019).

The comparison of various techniques and datasets used so far for the detection has been described in Table 8.

#### 4. Research gaps and future direction

Although a significant amount of research results in novice algorithms for the diagnosis of DR. However, most of the models have not been acquired by National health services.

Various research gaps need to be addressed to automate the system. The research gap and future directions have been described as follows.

##### 4.1. Applicability of Machine learning

The pertinence of machine learning (Chaki et al., 2020) for further research in healthcare settings is necessary, and the utilization of automated screening processes should be there to diagnose the disease in the early stages (Bek, 2014). To find lesions in fundus images and grade these fundus images for disease severity. These identified images can then be referred to human experts for review, reducing their burden, examining time, and avoiding further complications by giving them timely prompt treatment.

##### 4.2. Selection of OCT for screening DR

The adoption of OCT with DR is still in its infancy for screening purposes. However, developing the automated DR classification provides better results in terms of various performance metrics (Kouroupis et al., 2020).

##### 4.3. Insights for storing clinical data

Smart healthcare solutions are available in various ophthalmic practices. However, decision making can be improved by making use of clinical data that has been store electronically in a large amount (Ghosh and Capell, 2016).

##### 4.4. Artificial intelligence research in DR resulting in the effectiveness of automatic grading (Joshi and Karule, 2017)

Challenges exist for DR research in ophthalmology. So, implementing an AI program with DR results in automatic grading of DR. However, the more the number of training images, the better the prediction is obtained. Detection of OD, Blood vessels, etc., to provide a single technique to cover retinal structure and changes (Hogarty et al., 2019). Various imaging modalities do not predominantly capture the peripheral lesions. To improve the outcomes, there is a need for improved detection and classification of DR.

##### 4.5. Applicability of the algorithm should be narrowed down.

The efficiency of the training dataset reduces due to the inordinate dataset. Moreover, external validity should be done on wide

**Table 8**  
Comparison of diverse techniques used in diagnosing DR.

Work	Dataset	MAs	HEM	EX	Technique	Purpose	Performance analysis
(Wang et al., 2019)	Lab Dataset	✓	✓	✓	Cosine Similarity, Logistic Regression	Prediction of severity and grading of DR	91.2% for DR related features 95.6% for DR severity prediction
(Seoud et al., 2016)	Retinopathy Online Challenge (Roch), Diaretddb1, CARA143, Messidor, Erlangen, CARA1006	✓	✓	X	Spatial Calibration, Candidate Extraction	Detection of MAs, HEM	ROC value 0.899
(Esmaeili et al., 2014)	Private Data	✓	✓	x	Curvelet Transformation, Equalisation algorithm	Reduce the complexity of the model while increasing performance	sen/spec of 94/87
(Dorizzi et al., 2019)	DiaretDB1 and Messidor	✓	✓	x	CNN, Probability map		ROC of 0.912 and sen of 0.940
(Dhara et al., 2015)	Messidor	✓	✓	✓	Morphological features, CLAHE, SVM		AUC mild:0.9106 Moderate:0.8372 Severe:0.9750
(Sakshi Gunde and Gupta, 2020)	DIARETDB0	x	x	x	Green Channel, Otsu Algorithm, Circular Hough transform	Detection of DR using blobs and blood vessel	sen/spec of 73/70 in blob detection and 77/80 in blood vessel detection
(Hajeb Mohammad Alipour et al., 2012)	Local dataset	✓	x	✓	CLAHE, Canny edge detector, morphological operators, DCUT, thresholding, Curvelet based enhancement, SVM	Detection and Grading of DR	Sen/spec of 100% in grading
(Rahim et al., 2015)	Eye Clinic, Department of Ophthalmology, Hospital Melaka, Malaysia (Local Dataset)	✓	✓	✓	Grayscale, fuzzy filtering, fuzzy edge detection, Decision tree, K-nearest neighbour	Detection of DR and Maculopathy	Category II misclassification error/acc/sen/spec of 0.4395/0.5605/0.4500/0.5956 for binary decision tree and 0.2975/0.7025/0.6500/0.7297 for k-nearest neighbor
(Gao et al., 2019)	Sichuan Provincial People's Hospital (Lab Dataset)	✓	✓	✓	Inception V-3	Proposed an approach for grading the 4-stage severity of DR	Accuracy:88.72%
(Qummar, 2019)	Kaggle	x	x	x	CNN Models Resnet50, Inceptionv3, Xception, Dense121, Dense169	Classify five stages of DR	–
(Carson Lam and MD1, 2017)	Private Dataset	x	x	x	CNN, transfer learning, googlenet, alexnet	Detection and Grading of DR	74.5% on 2- ary classification, 68.8% on 3-ary classification and 57.2% on 4-ary
(Zeng et al., 2019)	Kaggle diabetic retinopathy competition	x	x	x	Inception V-3, Siamese like network structure	A model is proposed with transfer learning and a Siamese-like structure.	Kappa:0.829 AUC:0.951
(Li et al., 2019)	Kaggle Contests "Identify signs of diabetic retinopathy in eye images"	✓	✓	✓	Deep CNN, SVM, Teaching-Learning Based optimization	Classify 5 stages of DR along with the app	Accuracy 86.71% for 5-stage classification 91.05 for binary classification and sen/spec for binary classification 0.8930/0.9089
(Shanthi and Sabeenian, 2019)	Messidor	✓	✓	✓	CNN, Modified Alexnet Architecture	4-level Grading of DR	Accuracy Stage 3-healthy images 96.6%,95.6%,96.2% and 96.6%
(Kar and Maity, 2018)	DRIVE STARE DIARETDB1 MESSIDOR	✓	✓	✓	Preprocessing, Curvelet Based Edge Enhancement for Dark Lesion, Optimal Bandpass Filter, Matched Filtering, and Laplacian of Gaussian Filtering	Detection of lesion	Sen/spec/acc/AUC for exudates, MAs, HEM are 97.81/98.18/98.32/0.9684,95.23/95.12/97.23/0.9443, 97.67/97.74/96.99/0.9665
(Islam et al., 2018)	Kaggle diabetic retinopathy dataset	✓	x	x	data augmentation, L2 regularization, and various pre-processing based methods	Detection of MAs and grading of DR	sen/spec and AUC score of 98%/94% and 0.844
(Pratt et al., 2016)	Kaggle Dataset	✓	✓	✓	Data Augmentation, CNN	Five –class problem	acc/sen of 75%/95%
(Leeza and Farooq, 2019)	Kaggle National Data Science Bowl	x	x	x	Bag of features, Histogram oriented gradient, speed up robust feature, k-mean clustering	To identify the 5 –class problem	sen/spec/acc of 95.2%/98.9%/98.3
(Wan et al., 2018)	Kaggle	x	x	x	Transfer learning and hyperparameter tuning on CNN Models, Google Net, Alex Net, ResNet, and VggNet	Classify the DR Fundus Images	

demographic images. So the algorithm should be designed so that it may not be broadly applicable. The rapid expansion of this program over the next 5 years into a clinical environment would include a new interpretation of success and a deeper understanding of clinically relevant knowledge in digital imaging (Jordan et al., 2017).

#### 4.6. Removing the heterogeneity between specific studies such as medical science and computer sciences.

AI is a complicated field of research. It can create various science fields such as computer and medical science (Pattanaik et al., 2019; Pattanaik and Swarnkar, 2019). The research associated with the fields is focused and applicable to a particular field. Future research focuses on the amalgamation of both fields to reduce the heterogeneity between the fields.

#### 4.7. Affordability of diagnosing the disease for cost-effective treatment

There are various challenges associated with this disease. However, one such challenge includes the improvement in the screening of DR. Thereafter, cost-effective treatments need the hour to automate the system by extracting the pathologies that appear in the retinal surface. The advancement of community-specific retinal imaging solutions, such as cell phone technology for mHealth, and the enhancement of image quality and diffusion technology promise to resolve the problem of obtaining affordable, high-quality retinal images.

#### 4.8. Performing systematic progression and regression of various lesions for identifying the risk of rapid progression (Sivaprasad and Pearce, 2019)

Present studies focus on NPDR lesions for detecting DR. Additional lesion measurement can be implemented in the current classification system for accurate characterization of NPDR.

#### 4.9. Risk stratification, prediction can be done to determine new biomarkers and determinants for DR

Various other techniques are associated with better visualization of retinal circulation, such as adaptive optics, SS-OCT. Therefore, there is an urge to determine new biomarkers, genetic determinants, and retinal markers to understand pathogenesis better.

## 5. Conclusion

A detailed study has been carried out of almost 94 research articles, summarized as various gold standard datasets, methodologies, and evaluation metrics. This paper's central theme is to learn about existing literature work carried out till date for automatic detection and grading of DR. Initially, various kinds of a lesion such as MAs, HEM, exudates have been discussed along with different approaches found in the literature for detection of these lesions. Comparisons of all the clinical signs have been done to have a precise knowledge of the technique's pros and cons. Finally, the author addresses the research gaps and future direction in DR. It is believed that this review will prove useful for researchers working in medical image analysis. Medical imaging is a prominent area in today's era that the physicians can see the body's insights through various imaging that can be screened and diagnosed through Computer-aided diagnosis (CAD) to ease the doctor for a timely diagnosis as the ophthalmologist to patient ratio is 1:10,000 (Soomro, 2019). Therefore, medical imaging and CAD

are the boom to the society for diagnosis the disease with ease and at a very less time.

## Declaration of Competing Interest

The authors declare that they have no known competing financial interests or personal relationships that could have appeared to influence the work reported in this paper.

## References

- Abbas, Q., Fondon, I., Sarmiento, A., Jiménez, S., Alemany, P., 2017. Automatic recognition of severity level for diagnosis of diabetic retinopathy using deep visual features Cotton wool spots. *Med. Biol. Eng. Comput.* 55 (11), 1959–1974. <https://doi.org/10.1007/s11517-017-1638-6>.
- Adem, K., Hekim, M., Demir, S., 2019. Detection of hemorrhage in retinal images using linear classifiers and iterative thresholding approaches based on firefly and particle swarm optimization algorithms. *Turkish J. Electr. Eng. Comput. Sci.* 27 (1), 499–515. <https://doi.org/10.3906/elk-1804-147>.
- Aishwarya, R., Vasundhara, T., Ramachandran, K.I., 2017. "A hybrid classifier for the detection of microaneurysms in Diabetic Retinal Images". <https://doi.org/10.1007/978-981-10-4220-1>.
- J. Amin, M. Sharif, and M. Yasmin, "A Review on Recent Developments for Detection of Diabetic Retinopathy," vol. 2016, 2016, 10.1155/2016/6838976.
- Amin, J., Sharif, M., Rehman, A., Raza, M., Mufti, M.R., 2018. Diabetic retinopathy detection and classification using hybrid feature set. *Microsc. Res. Tech.* 81 (9), 990–996. <https://doi.org/10.1002/jemt.v81.910.1002/jemt.23063>.
- Arcadu, F., Benmansour, F., Maunz, A., Willis, J., Haskova, Z., Prunotto, M., 2019. "Deep learning algorithm predicts diabetic retinopathy progression in individual patients". *NPJ Digit Med.* 2 (1). <https://doi.org/10.1038/s41746-019-0172-3>.
- Arunkumar, R., Karthigaikumar, P., 2017. Multi-retinal disease classification by reduced deep learning features. *Neural Comput. Appl.* 28 (2), 329–334. <https://doi.org/10.1007/s00521-015-2059-9>.
- Bek, T., 2014. Fine structure in diabetic retinopathy lesions as observed by adaptive optics imaging. A qualitative study. *Acta Ophthalmol.* 92 (8), 753–758. <https://doi.org/10.1111/aos.2014.92.issue-810.1111/aos.12464>.
- Benzamin, A., Chakraborty, C., 2018. "Detection of hard exudates in retinal fundus images using deep learning". 2018 IEEE Int. Conf. Syst. Comput. Autom. Networking, ICSCA. <https://doi.org/10.1109/ICSCAN.2018.8541246>.
- Biyani, R.S., Patre, B.M., 2016. A clustering approach for exudates detection in screening of diabetic retinopathy. In: International Conference on Signal and Information Processing (IconSIP), pp. 1–5. <https://doi.org/10.1109/ICONSIP.2016.7857495>.
- Cao, W., Czarnek, N., Shan, J., Li, L., 2018. Microaneurysm detection using principal component analysis and machine learning methods. *IEEE Trans. Nanobiosci.* 17 (3), 191–198. <https://doi.org/10.1109/TNB.2018.2840084>.
- Carrington, A.M., Fieguth, P.W., Qazi, H., Holzinger, A., Chen, H.H., Mayr, F., Manuel, D.G., 2020. A new concordant partial AUC and partial c statistic for imbalanced data in the evaluation of machine learning algorithms. *BMC Med. Inform. Decis. Mak.* 20 (1). <https://doi.org/10.1186/s12911-019-1014-6>.
- Carson Lam, P., 2017. MD1, Darwin Yi 1, Margaret Guo 2, Tony Lindsey, "Automated Detection of Diabetic Retinopathy Using Deep Learning". *Ophthalmology* 124 (7), 962–969. <https://doi.org/10.1016/j.ophttha.2017.02.008>.
- J. Chaki, S. Thillai Ganesh, S. K. Cidham, and S. Ananda Theertan, "Machine learning and artificial intelligence based Diabetes Mellitus detection and self-management: A systematic review," *J. King Saud Univ. - Comput. Inf. Sci.*, no. xxxx, 2020, 10.1016/j.jksuci.2020.06.013.
- Chudzik, P., Majumdar, S., Calivá, F., Al-Diri, B., Hunter, A., 2018. Microaneurysm detection using fully convolutional neural networks. *Comput. Methods Programs Biomed.* 158, 185–192. <https://doi.org/10.1016/j.cmpb.2018.02.016>.
- Dai, L. et al., 2018. Clinical report guided retinal microaneurysm detection with multi-sieving deep learning. *IEEE Trans. Med. Imag.* 37 (5), 1149–1161. <https://doi.org/10.1109/TMI.2018.2794988>.
- Y. Dai, C. Zhu, X. Shan, Z. Cheng, and B. Zou, "A Survey on Intelligent Screening for Diabetic Retinopathy," vol. 34, no. 2, pp. 120–132, 2019, 10.24920/003587.
- Dashtbozorg, B., Zhang, J., Huang, F., Romeny, B.M.T.H., 2018. Retinal Microaneurysms Detection Using Local Convergence Index Features. *IEEE Trans. Image Process.* 27 (7), 3300–3315. <https://doi.org/10.1109/TIP.2018.2815345>.
- Dhara, A.K., Mukhopadhyay, S., Bency, M.J., Rangayyan, R.M., Bansal, R., Gupta, A., 2015. Development of a screening tool for staging of diabetic retinopathy in fundus images. *Med. Imag. 2015 Comput. Diagnosis* 9414, 94140H. <https://doi.org/10.1117/12.2081113>.
- "DIARETDB0 - Standard Diabetic Retinopathy Database." <https://www.it.lut.fi/project/imageret/diaretdb0/> (accessed Jun. 12, 2020).
- "DIARETDB1 - STANDARD DIABETIC RETINOPATHY DATABASE." <https://www.it.lut.fi/project/imageret/diaretdb1/> (accessed Jun. 11, 2020).
- B. Dorizzi, G. Tozatto, R. Varej, E. Ottoni, and T. Salles, "Diabetic retinopathy detection using red lesion localization and convolutional neural networks ~ o Andre a," vol. 116, no. November 2019, 2020, 10.1016/j.combiomed.2019.103537.
- "DRiDB image dataset - Image Processing Group." [https://ipg.fer.hr/ipg/resources/image\\_database](https://ipg.fer.hr/ipg/resources/image_database) (accessed Jun. 11, 2020).

- “DRIONS-DB Retinal Image Database – bob.db.drionsdb 1.0.1 documentation.” <https://www.idiap.ch/software/bob/docs/bob/bob.db.drionsdb/master/index.html> (accessed Jun. 12, 2020).
- Eftekhari, N., Pourreza, H.R., Masoudi, M., Shirazi, K.G., Saeedi, E., 2019. Microaneurysm detection in fundus images using a two - step convolutional neural network. *Biomed. Eng. Online*, 1–16. <https://doi.org/10.1186/s12938-019-0675-9>.
- “E-ophtha – ADCIS.” <http://www.adcis.net/en/third-party/e-ophtha/> (accessed Jun. 11, 2020).
- M. Esmaili, H. Rabbani, A. M. Dehnavi, and A. Dehghani, “A new curvelet transform based method for extraction of red lesions in digital color retinal images,” no. April 2014, 2010, 10.1109/ICIP.2010.5652820.
- Figueiredo, I.N., Kumar, S., Oliveira, C.M., Ramos, J.D., Engquist, B., 2015. Automated lesion detectors in retinal fundus images. *Comput. Biol. Med.* 66, 47–65. <https://doi.org/10.1016/j.compbiomed.2015.08.008>.
- Gajree, S., Borooah, S., Dhillon, B., 2016. Imaging in diabetic retinopathy: A review of current and future techniques. *Curr. Diabetes Rev.* 13 (1), 26–34. <https://doi.org/10.2174/1573399812666151119144109>.
- U. R. et al. Ganesan, K., Martis, R.J., Acharya, “Computer-aided diabetic retinopathy detection using trace transforms on digital fundus images | SpringerLink,” *Med Biol Eng Comput*, vol. 52, no. 10.1007/s11517-014-1167-5, pp. 663–672, 2014, Accessed: Aug. 06, 2020. [Online]. Available: <https://link.springer.com/article/10.1007/s11517-014-1167-5>.
- Gao, Z., Li, J., Guo, J., Chen, Y., Yi, Z., Zhong, J., 2019. Diagnosis of diabetic retinopathy using deep neural networks. *IEEE Access* 7, 3360–3370. <https://doi.org/10.1109/ACCESS.2018.2888639>.
- Ghosh, K., Capell, B.C., 2016. The senescence-associated secretory phenotype: critical effector in skin cancer and aging. *J. Invest. Dermatol.* 136 (11), 2133–2139. <https://doi.org/10.1016/j.jid.2016.06.621>.
- Giancardo, L., Meriaudeau, F., Karnowski, T.P., Li, Y., Garg, S., Tobin, K.W., Chaum, E., 2012. Exudate-based diabetic macular edema detection in fundus images using publicly available datasets. *Med. Image Anal.* 16 (1), 216–226. <https://doi.org/10.1016/j.media.2011.07.004>.
- Gulshan, V. et al., Dec. 2016. Development and validation of a deep learning algorithm for detection of diabetic retinopathy in retinal fundus photographs. *JAMA – J. Am. Med. Assoc.* 94043 (22), 1–9. <https://doi.org/10.1001/jama.2016.17216>.
- Guo, Y., Peng, Y., 2020. BSCN: bidirectional symmetric cascade network for retinal vessel segmentation. *BMC Med. Imag.* 20 (1), 20. <https://doi.org/10.1186/s12880-020-0412-7>.
- Hajeb Mohammad Alipour, S., Rabbani, H., Akhlaghi, M.R., 2012. Diabetic retinopathy grading by digital curvelet transform. *Comput. Math. Methods Med.* <https://doi.org/10.1155/2012/761901>.
- C. Hernandez-matas, X. Zabulis, A. Triantafyllou, and P. Anyfanti, “FIRE: Fundus Image Registration Dataset,” *J. Model. Ophthalmology* (to appear., 2017, [Online]. Available: <http://www.ics.forth.gr/cvrl/fire/>.
- Hogarty, D.T., Mackey, D.A., Hewitt, A.W., 2019. Current state and future prospects of artificial intelligence in ophthalmology: A review. *Clin. Exp. Ophthalmol.* 47 (1), 128–139. <https://doi.org/10.1111/ceo.2019.47.issue-110.1111/ceo.13381>.
- Holm, S., Russell, G., Nourrit, V., McLoughlin, N., 2017. DR HAGIS – A fundus image database for the automatic extraction of retinal surface vessels from diabetic patients. *J. Med. Imag.* 4, (1). <https://doi.org/10.1117/1.jmi.4.1.014503> 014503.
- Huan Wang, M.L.L., Hsu, W., Goh, K.G., 2000. “An effective approach to detect lesions in color retinal image”. *IEEE Conf. Comput. Vis. Pattern Recognit.* no. 2, 181–186. [https://doi.org/10.1007/978-3-642-25781-0\\_80](https://doi.org/10.1007/978-3-642-25781-0_80).
- S. M. S. Islam, M. M. Hasan, and S. Abdullah, “Deep Learning based Early Detection and Grading of Diabetic Retinopathy Using Retinal Fundus Images,” pp. 1–12, 2018, [Online]. Available: <http://arxiv.org/abs/1812.10595>.
- Jeba Derwin, D. et al., 2020. A novel automated system of discriminating Microaneurysms in fundus images. *Biomed. Signal Process. Control* 58, <https://doi.org/10.1016/j.bspc.2019.101839> 101839.
- P. Jitpakdee, P. Aimanee, and B. Uyyanonvara, “A Survey on Hemorrhage Detection in Diabetic Retinopathy Retinal Images,” pp. 12–15, 2012.
- Jordan, K.C., Menolotto, M., Bolster, N.M., Livingstone, I.A.T., Giardini, M.E., 2017. A review of feature-based retinal image analysis. *Expert Rev. Ophthalmol.* 12 (3), 207–220. <https://doi.org/10.1080/17469899.2017.1307105>.
- S. Joshi and P. T. Karule, “Biomedicine & Pharmacotherapy A review on exudates detection methods for diabetic retinopathy,” *Biomed. Pharmacother.*, vol. 97, no. October 2017, pp. 1454–1460, 2018, 10.1016/j.biopha.2017.11.009.
- Kaizu, Y. et al., 2019. Microaneurysm imaging using multiple en face optical coherence tomography angiography image averaging : Morphology and visualization. *Ophthalmol. Retin.* <https://doi.org/10.1016/j.oret.2019.09.010>.
- Kande, G.B., Savithri, T.S., Subbaiah, P.V., 2010. “Automatic detection of microaneurysms and hemorrhages in digital fundus. Images” 23 (4), 430–437. <https://doi.org/10.1007/s10278-009-9246-0>.
- Kar, S.S., Maity, S.P., 2018. Automatic detection of retinal lesions for screening of diabetic retinopathy. *IEEE Trans. Biomed. Eng.* 65 (3), 608–618. <https://doi.org/10.1109/TBME.2017.2707578>.
- Kaur, J., Mittal, D., 2018. A generalized method for the segmentation of exudates from pathological retinal fundus images. *Biocybern. Biomed. Eng.* 38 (1), 27–53. <https://doi.org/10.1016/j.bbe.2017.10.003>.
- K. B. Khan et al., A review of retinal blood vessels extraction techniques: challenges, taxonomy, and future trends, vol. 22, no. 3. Springer London, 2019.
- Khitran, S., Akram, M.U., Usman, A., Yasin, U., 2015., “Automated system for the detection of hypertensive retinopathy”. 2014 4th Int. Conf. Image Process. Theory, Tools Appl. IPTA. <https://doi.org/10.1109/IPTA.2014.7001984>.
- Khojasteh, P., Aliahmad, B., Kumar, D.K., 2018. Fundus images analysis using deep features for detection of exudates, hemorrhages and microaneurysms. *BMC Ophthalmol.* 18 (1), 1–13. <https://doi.org/10.1186/s12886-018-0954-4>.
- M. Kouroupis, N. Korfiatis, and J. Cornford, Artificial Intelligence A assisted detection of diabetic retinopathy on digital fundus images : concepts and applications in the National Health Service. Elsevier Inc., 2020.
- J. Krause et al., “Grader variability and the importance of reference standards for evaluating machine learning models for diabetic retinopathy,” arXiv. 2017.
- Leeza, M., Farooq, H., 2019. Detection of severity level of diabetic retinopathy using Bag of features model. *IET Comput. Vis.* 13 (5), 523–530. <https://doi.org/10.1049/cvi2.v13.510.1049/iet-cvi.2018.5263>.
- Leontidis, G., Al-Diri, B., Hunter, A., 2017. A new unified framework for the early detection of the progression to diabetic retinopathy from fundus images. *Comput. Biol. Med.* 90, 98–115. <https://doi.org/10.1016/j.compbiomed.2017.09.008>.
- Li, Y.H., Yeh, N.N., Chen, S.J., Chung, Y.C., 2019. Computer-assisted diagnosis for diabetic retinopathy based on fundus images using deep convolutional neural network. *Mob. Inf. Syst.* 1, 2019. <https://doi.org/10.1155/2019/6142839>.
- “Longitudinal diabetic retinopathy screening - Description - Rotterdam Ophthalmic Data Repository.” <http://www.rodrep.com/longitudinal-diabetic-retinopathy-screening-description.html> (accessed Aug. 04, 2020).
- Mansour, R.F., 2018. Deep-learning-based automatic computer-aided diagnosis system for diabetic retinopathy. *Biomed. Eng. Lett.* 8 (1), 41–57. <https://doi.org/10.1007/s13534-017-0047-y>.
- Mateen, M., Wen, J., Hassan, M., Nasrullah, N., Sun, S., Hayat, S., 2020. Automatic detection of diabetic retinopathy: A review on datasets, methods and evaluation metrics. *IEEE Access* 8, 48784–48811. <https://doi.org/10.1109/ACCESS.2020.2980055>.
- Matsopoulos, G.K., Mouravliansky, N.A., Delibasis, K.K., Nikita, K.S., 1999. Automatic retinal image registration scheme using global optimization techniques. *Technology* 3 (1), 47–60.
- “Messidor - ADCIS.” <http://www.adcis.net/en/third-party/messidor/> (accessed Jun. 11, 2020).
- Mo, J., Zhang, L., 2017. Multi-level deep supervised networks for retinal vessel segmentation. *Int. J. Comput. Assist. Radiol. Surg.* 12 (12), 2181–2193. <https://doi.org/10.1007/s11548-017-1619-0>.
- Molina-Casado, J.M., Carmona, E.J., García-Feijóo, J., 2017. Fast detection of the main anatomical structures in digital retinal images based on intra- and inter-structure relational knowledge. *Comput. Methods Programs Biomed.* 149 (October), 55–68. <https://doi.org/10.1016/j.cmpb.2017.06.022>.
- Mookiah, M.R.K., Acharya, U.R., Chua, C.K., Lim, C.M., Ng, E.Y.K., Laude, A., 2013. Computer-aided diagnosis of diabetic retinopathy: A review. *Comput. Biol. Med.* 43 (12), 2136–2155. <https://doi.org/10.1016/j.compbiomed.2013.10.007>.
- Mumtaz, R., Hussain, M., Sarwar, S., Khan, K., Mumtaz, S., Mumtaz, M., 2018. Automatic detection of retinal hemorrhages by exploiting image processing techniques for screening retinal diseases in diabetic patients. *Int. J. Diabetes Dev. Ctries.* 38 (1), 80–87. <https://doi.org/10.1007/s13410-017-0561-6>.
- R. Murugan, “An automatic detection of hemorrhages in retinal fundus images by motion pattern generation,” *Biomed. Pharmacol. J.*, vol. 12, no. 3, pp. 1433–1440, 2019, 10.13005/bpj/1772.
- D. Nagpal, S. N. Panda, and M. Malarvel, “Hypertensive Retinopathy Screening through Fundus Images-A Review,” *Proc. 6th Int. Conf. Inven. Comput. Technol. ICIT 2021*, pp. 924–929, 2021, 10.1109/ICIT50816.2021.9358746.
- Nagpal, D., Panda, S.N., Gupta, N., 2021. Recent advancement for diagnosing diabetic retinopathy. *J. Comput. Theor. Nanosci.* 17 (11), 5096–5104. <https://doi.org/10.1166/jctn.2020.9346>.
- and M. L. M. Niemeijer, J. J. Staal, B. V. Ginneken, “Introduction - drive - Grand Challenge,” 2004. <https://drive.grand-challenge.org/> (accessed Jun. 11, 2020).
- “Ophthalmic image processing Medical Image and Signal Processing Research Center.” <https://misp.mui.ac.ir/fa/پردازش-تصاویر-چشم-بزرگی> (accessed Apr. 14, 2021).
- Orlando, J.L., Prokofyeva, E., del Fresno, M., Blaschko, M.B., 2018. An ensemble deep learning based approach for red lesion detection in fundus images. *Comput. Methods Programs Biomed.* 153, 115–127. <https://doi.org/10.1016/j.cmpb.2017.10.017>.
- Pattanaik, P.A. and Swarnkar, T., “Vision-based malaria parasite image analysis: a systematic review”, *International Journal of Bioinformatics Research and Applications*, Vol. 15, No. 1, pp.1-32, 2019, [doi.org/10.1504/IJBRA.2019.097987](https://doi.org/10.1504/IJBRA.2019.097987)
- Pattanaik, P.A., Wang, Z., Horain, P., 2019. Deep CNN frameworks comparison for malaria diagnosis. arXiv preprint arXiv:1909.02829.
- Pires, R., Avila, S., Wainer, J., Valle, E., Abramoff, M.D., Rocha, A., 2019. A data-driven approach to referable diabetic retinopathy detection. *Artif. Intell. Med.* 96, 93–106. <https://doi.org/10.1016/j.artmed.2019.03.009>.
- Porwal, P. et al., 2020. IDRid: Diabetic Retinopathy – Segmentation and Grading Challenge. *Med. Image Anal.* 59, <https://doi.org/10.1016/j.media.2019.101561> 101561.
- Pratt, H., Coenen, F., Broadbent, D.M., Harding, S.P., Zheng, Y., 2016. Convolutional neural networks for diabetic retinopathy. *Procedia Comput. Sci.* 90 (July), 200–205. <https://doi.org/10.1016/j.procs.2016.07.014>.
- Prenetašić, P., Lončarić, S., 2016. Detection of exudates in fundus photographs using deep neural networks and anatomical landmark detection fusion. *Comput. Methods Programs Biomed.* 137, 281–292. <https://doi.org/10.1016/j.cmpb.2016.09.018>.
- Qummar, S. et al., 2019. A deep learning ensemble approach for diabetic retinopathy detection. *IEEE Access* 7, 150530–150539. <https://doi.org/10.1109/ACCESS.2019.2947484>.

- S. S. Rahim, V. Palade, C. Jayne, A. Holzinger, and J. Shuttleworth, "Detection of Diabetic Retinopathy and Maculopathy in Eye Fundus images using Fundus image processing," vol. 9250, pp. 275–284, 2015, 10.1007/978-3-319-23344-4.
- Rahim, S.S., Palade, V., Almakky, I., Holzinger, A., 2019. Detection of Diabetic Retinopathy and Maculopathy in Eye Fundus Images Using Deep Learning and Image Augmentation. Lect. Notes Comput. Sci. (including Subser. Lect. Notes Artif. Intell. Lect. Notes Bioinformatics) vol. 11713 LNCS, 114–127. [https://doi.org/10.1007/978-3-030-29726-8\\_8](https://doi.org/10.1007/978-3-030-29726-8_8).
- Rahim, S.S., Palade, V., Almakky, I., Holzinger, A., 2020. Fuzzy image processing and deep learning for microaneurysms detection. Lect. Notes Comput. Sci. (including Subser. Lect. Notes Artif. Intell. Lect. Notes Bioinformatics) vol. 12090 LNCS, 321–339. [https://doi.org/10.1007/978-3-030-50402-1\\_19](https://doi.org/10.1007/978-3-030-50402-1_19).
- Saeed, M.U., Oleszczuk, J.D., 2016. Advances in retinal imaging modalities: Challenges and opportunities. World J. Ophthalmol. 6 (2), 10. <https://doi.org/10.5318/wjo.v6.i2.10>.
- Sakshi Gunde, A.A., Gupta, S.D., 2020. Diabetic retinopathy detection using non-mydratric fundus images. Our Herit 1, 141–145.
- N. Salamat, M. M. Saad, A. Rashid, M. M. S. Missen, and A. Rashid, "Diabetic retinopathy techniques in retinal images: A review," Artif. Intell. Med., vol. 97, no. April 2019, pp. 168–188, 2019, 10.1016/j.artmed.2018.10.009.
- Salz, D.A., Witkin, A.J., 2015. Imaging in diabetic retinopathy. Middle East Afr. J. Ophthalmol. 22 (2), 145–150. <https://doi.org/10.4103/0974-9233.151887>.
- R. V. S. Saravanan, "Exudate characterization to diagnose diabetic retinopathy using generalized method," no. 0123456789, 2019.
- Savelli, B., Bria, A., Molinara, M., Marrocco, C., Tortorella, F., 2020. A multi-context CNN ensemble for small lesion detection. Artif. Intell. Med. 103. <https://doi.org/10.1016/j.artmed.2019.101749>
- Seoud, L., Hurtut, T., Chelbi, J., Cheriet, F., Langlois, J.M.P., 2016. Red lesion detection using dynamic shape features for diabetic retinopathy screening. IEEE Trans. Med. Imag. 35 (4), 1116–1126. <https://doi.org/10.1109/TMI.2015.2509785>.
- Shanthi, T., Sabeenian, R.S., 2019. Modified Alexnet architecture for classification of diabetic retinopathy images R. Comput. Electr. Eng. 76, 56–64. <https://doi.org/10.1016/j.compeleceng.2019.03.004>.
- Singh, A., Dutta, M.K., 2017. A robust zero-watermarking scheme for tele-ophthalmological applications. J. King Saud Univ.-Comput. Inform. Sci. <https://doi.org/10.1016/j.jksuci.2017.12.008>.
- S. L. and D. U. C. Sinthanayothin, J. F. Boyce, T. H. Williamson\*, H. L. Cook\*, E. Mensah\*, "Automated detection of diabetic retinopathy on digital fundus images," Diabet Med, vol. 2, no. 19, pp. 105–112, 2002, 10.1109/ICENCO.2012.6487084.
- Sivaprasad, S., Pearce, E., 2019. The unmet need for better risk stratification of non-proliferative diabetic retinopathy. Diabet. Med. 36 (4), 424–433. <https://doi.org/10.1111/dme.13868>.
- J. Sivaswamy, S. R. Krishnadas, G. D. Joshi, M. J. Ujjwal, and S. Tabish, "Drishiti-GS: Retinal image dataset for optic nerve head (ONH) segmentation," 2014 IEEE 11th Int. Symp. Biomed. Imaging, ISBI 2014, pp. 53–56, 2014, 10.1109/isbi.2014.6867807.
- Soomro, T.A. et al., 2019. Deep learning models for retinal blood vessels segmentation: A review. IEEE Access 7, 71696–71717. <https://doi.org/10.1109/ACCESS.2019.2920616>.
- Soomro, T.A., Gao, J., Khan, T., Hani, A.F.M., Khan, M.A.U., Paul, M., 2017. Computerised approaches for the detection of diabetic retinopathy using retinal fundus images: A survey. Pattern Anal. Appl. 20 (4), 927–961. <https://doi.org/10.1007/s10044-017-0630-y>.
- Sudha, S., Srinivasan, A., Devi, T.G., 2018. Automatic detection of microaneurysms in diabetic retinopathy images using graph cut segmentation and SVM classifier with PCA. Int. J. Pure Appl. Math. 119 (15), 3365–3374.
- "The STARE Project." <http://cecas.clemson.edu/~ahoover/stare/> (accessed Jun. 12, 2020).
- Ting, D.S.W. et al., 2019. Deep learning in estimating prevalence and systemic risk factors for diabetic retinopathy: A multi-ethnic study. NPJ Digit. Med., 1–8 <https://doi.org/10.1038/s41746-019-0097-x>.
- Walter, T., Klein, J., Massin, P., Erginay, A., 2002. A contribution of image processing to the diagnosis of diabetic retinopathy – Detection of exudates in color fundus images of the human retina. IEEE Trans. Med. Imaging 21 (10), 1236–1243. <https://doi.org/10.1109/TMI.2002.806290>.
- Wan, S., Liang, Y., Zhang, Y., 2018. Deep convolutional neural networks for diabetic retinopathy detection by image classification. Comput. Electr. Eng. 72, 274–282. <https://doi.org/10.1016/j.compeleceng.2018.07.042>.
- Wang, J., Bai, Y., Xia, B., 2019. Feasibility of diagnosing both severity and features of diabetic retinopathy in fundus photography. IEEE Access 7, 102589–102597. <https://doi.org/10.1109/access.2019.2930941>.
- H. Wang et al., "Hard exudate detection based on deep model learned information and multi-feature joint representation for diabetic retinopathy screening," Comput. Methods Programs Biomed., p. 105398, 2020, 10.1016/j.cmpb.2020.105398.
- D. Z. Wei Shao, Sheng-Jun Huang, Mingxia Liu, "Querying Representative and Informative Super-pixels for Filament Segmentation in Bioimages," IEEE Trans. Comput. Biol. Bioinforma., 2019, Accessed: Jun. 17, 2020. [Online]. Available: <https://ieeexplore.ieee.org/stamp/stamp.jsp?arnumber=8611135>.
- Williams, R., Airey, M., Baxter, H., Forrester, J.K., Kennedy-Martin, T., Girach, A., 2004. Epidemiology of diabetic retinopathy and macular oedema: A systematic review. Eye 18 (10), 963–983. <https://doi.org/10.1038/sj.eye.6701476>.
- Xue, J., Yan, S., Qu, J., Qi, F., Qiu, C., Zhang, H., 2019. Knowledge-Based Systems Deep membrane systems for multitask segmentation in diabetic retinopathy. Knowledge-Based Syst. 183. <https://doi.org/10.1016/j.knosys.2019.104887>
- Zeng, X., Chen, H., Luo, Y., Ye, W., 2019. "Automated diabetic retinopathy detection based on binocular siamese-like convolutional neural network". IEEE Access vol. 7, 30744–30753. <https://doi.org/10.1109/ACCESS.2019.2903171>.