



**HAL**  
open science

## **Changes in quantitative elastography assessment of the adjacent lumbar disc after segmental fixation of the spine: a case description of a burst fracture of L4**

Raphaël Pietton, Raphaël Vialle, Romain Laurent, Wafa Skalli, Claudio Vergari,  
Tristan Langlais

### ► **To cite this version:**

Raphaël Pietton, Raphaël Vialle, Romain Laurent, Wafa Skalli, Claudio Vergari, et al.. Changes in quantitative elastography assessment of the adjacent lumbar disc after segmental fixation of the spine: a case description of a burst fracture of L4. *Quantitative Imaging in Medicine and Surgery*, 2022, 12 (3), pp.2184-2188. <10.21037/qims-21-666>. <hal-03592168>

**HAL Id: hal-03592168**

**<https://hal.science/hal-03592168v1>**

Submitted on 1 Mar 2022

**HAL** is a multi-disciplinary open access archive for the deposit and dissemination of scientific research documents, whether they are published or not. The documents may come from teaching and research institutions in France or abroad, or from public or private research centers.

L'archive ouverte pluridisciplinaire **HAL**, est destinée au dépôt et à la diffusion de documents scientifiques de niveau recherche, publiés ou non, émanant des établissements d'enseignement et de recherche français ou étrangers, des laboratoires publics ou privés.



HAL Authorization



# Changes in quantitative elastography assessment of the adjacent lumbar disc after segmental fixation of the spine: a case description of a burst fracture of L4

Raphaël Pietton<sup>1</sup>, Raphaël Vialle<sup>1</sup>, Romain Laurent<sup>1</sup>, Wafa Skalli<sup>2</sup>, Claudio Vergari<sup>2</sup>, Tristan Langlais<sup>1,2,3,^</sup>

<sup>1</sup>Department of Paediatric Orthopaedics, Sorbonne Université, Armand Trousseau Hospital, Paris, France; <sup>2</sup>Arts et Métiers Institute of Technology, Université Sorbonne Paris Nord, IBHGC - Institut de Biomécanique Humaine Georges Charpak, HESAM Université, Paris, France; <sup>3</sup>Département Orthopédie Pédiatrique, Hôpital des enfants, Toulouse Université, Purpan, Toulouse, France

*Correspondence to:* Dr. Tristan Langlais. Department of Paediatric Orthopaedics, Armand Trousseau Hospital, 26, avenue du Dr Arnold Netter, 75012 Paris, France. Email: tristanlanglais@yahoo.fr.

Submitted Jun 25, 2021. Accepted for publication Oct 25, 2021.

doi: 10.21037/qims-21-666

View this article at: <https://dx.doi.org/10.21037/qims-21-666>

## Introduction

Vertebral burst fractures are usually due to traumatic high-energy distraction of the vertebra. They often require pedicle screw fixation to stabilize the spine during the healing process but once the fusion of the fractured vertebra has occurred, the posterior fixation can be removed or shortened to restore part of the spinal mobility. The importance of sparing fusion levels to ensure optimal functional results has been demonstrated (1,2). In surgical planning, the rule is therefore to ensure the osteosynthesis stability while limiting the number of levels included. Immobilization or fixation of a vertebral segment may be responsible for degeneration of the intervertebral disc and in case of surgical treatment the adjacent disc (3,4). Therefore, we can ask whether removal of a vertebral fixation could decrease the stress on adjacent segments (5). Ultrasound shearwave elastography is a new innovative and non-invasive technique allowing evaluation of soft tissue's elastic modulus through the measurement of shear wave speed (SWS). This non-invasive imaging method has shown its added value in breast (6) or in liver oncology (7) and, more recently, in musculoskeletal pathologies assessment (8). In particular, Langlais *et al.* found that SWS measured in annulus fibrosus was significantly higher in progressive

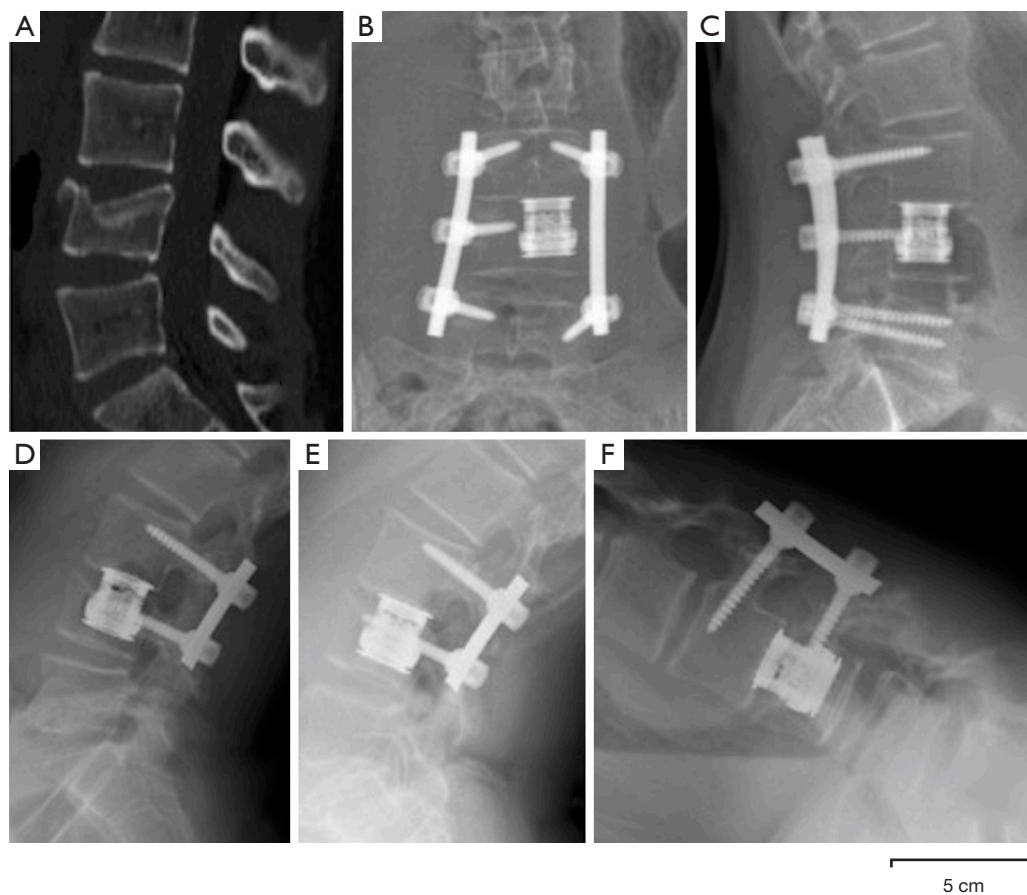
adolescent idiopathic scoliosis than in asymptomatic population (9), which is associated with a stiffer tissue. The same authors defined a corridor of normality (2.3–3.7 m/s) for the asymptomatic population and observed that annulus SWS tended to normalize 1 year after fusion surgery in severe adolescent idiopathic scoliosis. The aim of this case was to analyze the effect of removing the posterior fixation in a case of burst fracture on the mechanical properties of the bridged and adjacent intervertebral discs.

## Case presentation

### *Patient information, diagnosis, and therapeutic intervention*

A 13-year-old female was treated for a burst (Dennis) Type B Fracture at L4 secondary to a 3 m fall in sports climbing activities. Surgical treatment was decided upon as more than one third of the height of the vertebral body is affected. She had no neurological deficit. A transpedicular L4 corpectomy and anterior L3/4 fusion with a cage was performed by posterior approach associated with a posterior L3/5 fixation (10) (*Figure 1*). Postoperative course was uneventful. The patient underwent a rehabilitation protocol with physiotherapy at a rate of 2 sessions per week for 5 weeks. The objective was to rehabilitate walking,

<sup>^</sup> ORCID: 0000-0003-1427-5518.



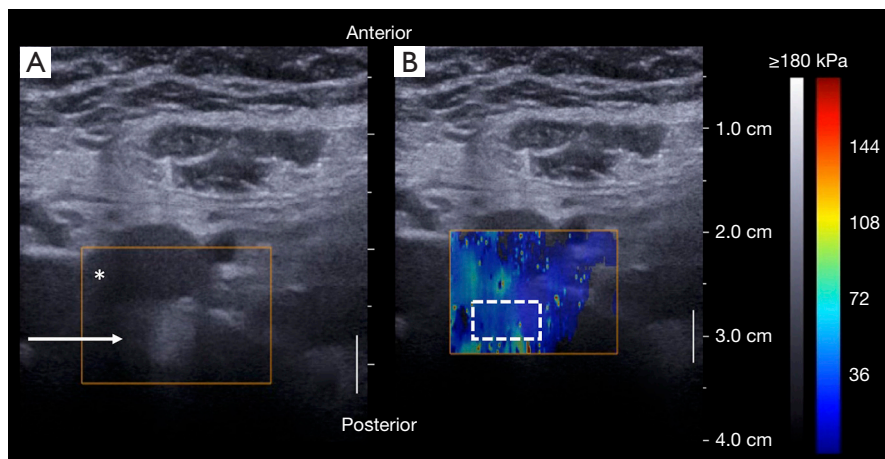
**Figure 1** Pre and postoperative imaging. Preoperative CT (A: lateral view) showed a burst fracture of L4 of type B according to the Dennis classification. Analysis of the L4 vertebra showed that more than one third of the height of the vertebral body is affected. Postoperative X-rays (B: AP view, C: lateral view) after L4 transpedicular corpectomy and posterior fixation with one single posterior approach. Postoperative lateral X-rays after distal removal in standing position (D: lateral view). Extension (E: lateral view) and flexion (F: lateral view) dynamic X-rays show range of mobility in the last two mobile lumbar discs.

reduce pain and improve lumbar mobility. All procedures performed in studies involving human participants were in accordance with the ethical standards of the institutional and/or national research committee(s) and with the Helsinki Declaration (as revised in 2013). Written informed consent was obtained from the patient for publication of this case report and accompanying images. A copy of the written consent is available for review by the editorial office of this journal.

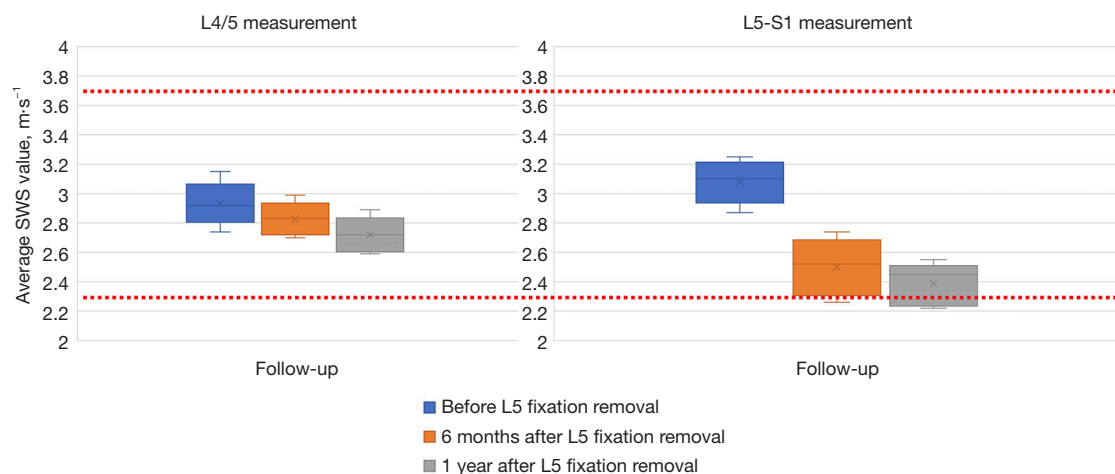
#### ***Timeline and clinical/imagery findings***

After assessment of the L3/4 anterior fusion by a CT-scan at 1 year, the L5 posterior fixation was removed. The patient had not undergone rehabilitation with physiotherapy.

Ultrasound elastography of the anterior annulus fibrosus were performed according to an already validated protocol (9,11) (Figure 2). Shear Wave Speed (SWS) was measured in the anterior part of the annulus fibrosus of L4/5 and L5/S1 discs. Three clips of about 10 s (about 10 elastography frames per clip) were recorded for each disc, i.e., L4/5 and L5/S1. The average SWS value was calculated in each region of interest to obtain a single SWS value (from three clips  $\times$  10 frames = 30 frames per disc) for L4/5 and L5/S1. The size of the region of interest (ROI) was also adapted to the disc and to the elastographic signal, to avoid signal saturation or missing signal. ROI was between 1 and 3 cm<sup>2</sup>. Acquisitions were performed, by the same operator, one year after fracture treatment (before L5 fixation removal), then 6 months and 1 year after L5 fixation removal. Frontal



**Figure 2** Elastography assessment. Example of ultrasound (A) and elastography image (B) of L4/5 intervertebral disc. In the ultrasound image, we could see the aortic bifurcation (\*) and annulus fibrosus lamellae (arrow). The rectangle on elastography image shows the region of interest in the annulus fibrosus. The colouring of the scale bar represents the value of the Young's modulus in Pascal. This value is specified along the scale.



**Figure 3** Box plots represents the SWS value of L4/5 and L5-S1 before and after L5 screws removal. Red dashed lines represent the limits of the corridor of normality (2.3–3.7 m/s).

and lateral X-rays were also acquired at each time point of the treatment. Dynamic flexion-extension bending films were done 1 year after L5 fixation removal. Two years after L5 fixation removal, the patient was symptoms-free and had a normal function. Dynamic X-rays showed a restoration of disc mobility at the L4/5 level without signs of instability or disc degeneration (*Figure 1*). Although SWS was within the normality corridor before removal of L5 fixation, it decreased at 6 months and 1 year after L5 fixation removal (*Figure 3*).

## Discussion

In this case, SWS decreased after screws removal for the two studied disc levels. L4/5 disc was bridged by the posterior instrumentation before removal of the L5 screws, and therefore it remained unloaded. L5/S1 disc, on the other hand, was free; hence, it was likely overloaded before fixation removal, to compensate for the reduced mobility of the instrumented segment. Loadings of both these discs changed towards physiological patterns after L5 fixation

removal. With posterior-only approaches, biomechanical properties variations of the anterior annulus fibrosus may be only due to the removal of L5 fixation.

To perform the procedure, the adolescent should be relaxed, and constant pressure should be applied to the probe to clear the bowel contents and gas. It is advisable to first detect the aortic bifurcation, which corresponds to the L4 vertebra in 64% of subjects (12). Then the probe can slide caudally, to measure L4/5 and L5/S1. The lamellar structure of the annulus fibrosus is only visible if the probe is in the same plane as the disc. The learning curve for *in vivo* annulus fibrosus imaging is not long, but care must be taken to obtain stable and good quality images. A limitation of the technique is that the measurement is only of the anterior part of the annulus fibrosus in the lumbar region. The thoracic cage does not allow us to carry out measurements above L2. The measurements were carried out by the same operator, however there may be intra-operator variations. The feasibility study describing the protocol used in this case found an intra-operator repeatability of 5.0% and an intra-class correlation coefficient greater than 0.9 for each operator (11).

This study demonstrates the feasibility of using shear wave elastography in the pre- and postoperative biomechanical assessment of the lumbar annulus fibrosus. These results suggest that the stress reduction due to the removal of posterior fixation may influence the biomechanical parameters of the intervertebral discs and in particular the properties of the lumbar annulus fibrosus. This is a new point to consider in the advantage/disadvantage discussions of fracture treatment strategy (i.e., corset or osteosynthesis or arthrodesis). This report paves the way for further studies on intervertebral discs biomechanical characterization by elastography in various pathological conditions.

## Acknowledgments

*Funding:* None.

## Footnote

*Conflicts of Interest:* All authors have completed the ICMJE uniform disclosure form (available at <https://dx.doi.org/10.21037/qims-21-666>). RV receives personal fees for consulting agreement from the following companies: Nuvasive, Stryker and EOS imaging. The other authors have no conflicts of interests to declare.

*Ethical Statement:* The authors are accountable for all aspects of the work in ensuring that questions related to the accuracy or integrity of any part of the work are appropriately investigated and resolved. All procedures performed in studies involving human participants were in accordance with the ethical standards of the institutional and/or national research committee(s) and with the Helsinki Declaration (as revised in 2013). Written informed consent was obtained from the patient for publication of this case report and accompanying images. A copy of the written consent is available for review by the editorial office of this journal.

*Open Access Statement:* This is an Open Access article distributed in accordance with the Creative Commons Attribution-NonCommercial-NoDerivs 4.0 International License (CC BY-NC-ND 4.0), which permits the non-commercial replication and distribution of the article with the strict proviso that no changes or edits are made and the original work is properly cited (including links to both the formal publication through the relevant DOI and the license). See: <https://creativecommons.org/licenses/by-nc-nd/4.0/>.

## References

1. Sanchez-Raya J, Bago J, Pellise F, Cuxart A, Villanueva C. Does the lower instrumented vertebra have an effect on lumbar mobility, subjective perception of trunk flexibility, and quality of life in patients with idiopathic scoliosis treated by spinal fusion? *J Spinal Disord Tech* 2012;25:437-42.
2. Connolly PJ, Von Schroeder HP, Johnson GE, Kostuik JP. Adolescent idiopathic scoliosis. Long-term effect of instrumentation extending to the lumbar spine. *J Bone Joint Surg Am* 1995;77:1210-6.
3. Pham MH, Tuchman A, Chen TC, Acosta FL, Hsieh PC, Liu JC. Transpedicular Corpectomy and Cage Placement in the Treatment of Traumatic Lumbar Burst Fractures. *Clin Spine Surg* 2017;30:360-6.
4. Choi W, Song S, Chae S, Ko S. Comparison of the Extent of Degeneration among the Normal Disc, Immobilized Disc, and Immobilized Disc with an Endplate Fracture. *Clin Orthop Surg* 2017;9:193-9.
5. Hashimoto K, Aizawa T, Kanno H, Itoi E. Adjacent segment degeneration after fusion spinal surgery—a systematic review. *Int Orthop* 2019;43:987-93.
6. Cong R, Li J, Guo S. A new qualitative pattern classification of shear wave elastography for solid breast

- mass evaluation. *Eur J Radiol* 2017;87:111-9.
7. Castéra L, Vergniol J, Foucher J, Le Bail B, Chanteloup E, Haaser M, Darriet M, Couzigou P, De Lédinghen V. Prospective comparison of transient elastography, Fibrotest, APRI, and liver biopsy for the assessment of fibrosis in chronic hepatitis C. *Gastroenterology* 2005;128:343-50.
  8. Moreau B, Vergari C, Gad H, Sandoz B, Skalli W, Laporte S. Non-invasive assessment of human multifidus muscle stiffness using ultrasound shear wave elastography: A feasibility study. *Proc Inst Mech Eng H* 2016;230:809-14.
  9. Langlais T, Vergari C, Pietton R, Dubousset J, Skalli W, Vialle R. Shear-wave elastography can evaluate annulus fibrosus alteration in adolescent scoliosis. *Eur Radiol* 2018;28:2830-7.
  10. Agrawal M, Garg M, Kumar A, Singh PK, Satyarthee GD, Agrawal D, Chandra PS, Kale SS. Management of Pediatric Posttraumatic Thoracolumbar Vertebral Body Burst Fractures by Use of Single-Stage Posterior Transpedicular Approach. *World Neurosurg* 2018;117:e22-33.
  11. Vergari C, Dubois G, Vialle R, Gennisson JL, Tanter M, Dubousset J, Rouch P, Skalli W. Lumbar annulus fibrosus biomechanical characterization in healthy children by ultrasound shear wave elastography. *Eur Radiol* 2016;26:1213-7.
  12. Deswal A, Tamang BK, Bala A. Study of aortic- common iliac bifurcation and its clinical significance. *J Clin Diagn Res* 2014;8:AC06-8.

**Cite this article as:** Pietton R, Vialle R, Laurent R, Skalli W, Vergari C, Langlais T. Changes in quantitative elastography assessment of the adjacent lumbar disc after segmental fixation of the spine: a case description of a burst fracture of L4. *Quant Imaging Med Surg* 2022;12(3):2184-2188. doi: 10.21037/qims-21-666