



HAL
open science

Herpes simplex type 1 primo-infection and pregnancy, two cases of intra-uterine infection and revue of the literature

Y Mekki, J.-S Casalegno, Maxime Pichon, M Bouscambert-Duchamp, C Clamadiou, G Billaud, E Frobert, D Combourieu, M Massoud, J Massardier,
et al.

► **To cite this version:**

Y Mekki, J.-S Casalegno, Maxime Pichon, M Bouscambert-Duchamp, C Clamadiou, et al.. Herpes simplex type 1 primo-infection and pregnancy, two cases of intra-uterine infection and revue of the literature. *Références en Gynécologie Obstétrique*, 2014. hal-03591626

HAL Id: hal-03591626

<https://hal.science/hal-03591626>

Submitted on 4 Mar 2022

HAL is a multi-disciplinary open access archive for the deposit and dissemination of scientific research documents, whether they are published or not. The documents may come from teaching and research institutions in France or abroad, or from public or private research centers.

L'archive ouverte pluridisciplinaire **HAL**, est destinée au dépôt et à la diffusion de documents scientifiques de niveau recherche, publiés ou non, émanant des établissements d'enseignement et de recherche français ou étrangers, des laboratoires publics ou privés.

CAS CLINIQUE/CASE REPORT

Herpes simplex type 1 primo-infection and pregnancy, two cases of intra-uterine infection and revue of the literature

Y. Mekki^{1*}, J.-S. Casalegno^{1,2*}, M. Pichon^{1,2}, M. Bouscambert-Duchamp¹, C. Clamadieu⁴, G. Billaud¹, E. Frobert^{1,2}, D. Combourieu³, M. Massoud³, J. Massardier³, P.A. Bolze³, L. Guibaud⁶, F. Plaisant⁴, S. Blanc⁴, A. Buenerd⁵, O. Claris⁴, B. Lina^{1,2}, P. Gaucherand³

¹ Virology departement, – North Center of Biology and Pathology, Lyon, France; ² Lina's Laboratory EA4610 – Virologie et Pathologie Humaine, University Lyon 1, Lyon, France;

³ Gynecology-Obstetric Departement, Hôpital Femme Mère Enfant, Hospices Civils de Lyon, Lyon, France; ⁴ Neonatology Departement, Hôpital Femme Mère Enfant, Hospices Civils de Lyon, Lyon, France; ⁵ Cytopathology Departement, Hôpital Femme Mère Enfant, Hospices Civils de Lyon, Lyon, France; ⁶ Radiology Departement, Hôpital Femme Mère Enfant, Hospices Civils de Lyon, Lyon, France

* **Corresponding authors:** Yahia Mekki, Mail: yahia.mekki@chu-lyon.fr

ABSTRACT: Although 80% of the adult population is seropositive for HSV-1, we describe in this paper two cases of HSV-1 infection *in utero* illustrating the risk of HSV-1 associated with primary infection viremia. Clinical histories of these patients raise concerns with the question of the therapeutic management of gingivostomatitis HSV-1 in pregnant women.

Sixty to eighty percent of the adult population is seropositive for herpes simplex virus type 1 (HSV-1) and 15% for HSV-2. Despite of this important seroprevalence, primary infection of the mother during pregnancy leading to fetal transmission are not rare. Most of HSV infections are neonatal and result from exposure to HSV in the genital tract during delivery [1]. Although *in utero* infection resulting from HSV viremia is rare and barely reported, we report here two

cases of HSV-1 leading to premature labor at 25 WA (week of amenorrhea) and deaths of newborns, that are raising concern on the management of HSV primary infection during pregnancy.

Keywords: Herpès simplex virus type-1 – HSV-1 – Primo-infection – Pregnancy – Intra-uterine infection – Gingivostomatitis

Titre français à venir

RÉSUMÉ : Texte à venir.

Mots-clés : à venir

Cases reports

First case

A 19-year-old woman at 25 WA consulted at gynaecological emergency for premature delivery symptoms. Her pregnancy had been marked by an episode of vaginal and oral candidiasis. After failure of tocolysis and due to a breech presentation, the female child was born by caesarean section. From birth, intrauterine growth retardation (IUGR) was noted. A shiny erythematous skin which bled at the slightest touch and white patches scattered throughout the body (except for the scalp) were observed. Antibiotherapy was introduced for unexplained prematurity. Fluconazole was added quickly due to the maternal vaginitis with *Candida albicans*. Respiratory complications lead to a rapid invasive ven-

tilation. No abnormalities of cardiac and transfontanellar echographies were found. The C-reactive protein (CRP) was 64 mg/L at twelve hours of life (H12). Elevation of transaminases and worsening of thrombocytopenia (33 G/L) were rapidly observed. Severe coagulopathy occurred during the first day (prothrombin rate: 34%, factor V: 24% and fibrinogen: 1.5 g/L). All cultures (blood, placenta and skin biopsy) remained sterile. HSV-1 was found by molecular technique in both eye and nose-throat swabs. Death occurred at H62 after cardiac arrhythmias since H8 (with hyperkalemia), gradual respiratory and hemodynamics deterioration.

Histopathological examination of the skin observed diffuse lesions with thick indurated plaques and a large necrotic calcified sparing of the scalp (Fig. 1a). Splenomegaly and hemorrhagic/necrotic liver

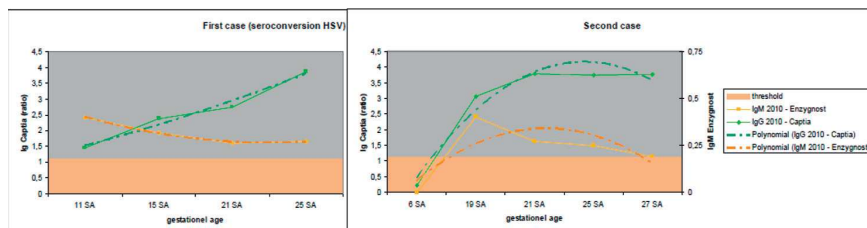
were described without any nuclear inclusions. On the contrary, histological examination of intranuclear inclusions of the placenta was consistent with a viral infection. Moreover a false membrane yellowish covered the eye consistent with conjunctivitis [2].

Retrospective analysis of the mother's previous serum samples showed argument for HSV infection or reinfection, between 11 WA and the birth, with persistent IgM and a HSV-1 viremia. Searches for HSV-1 by PCR in liver and lung necropsies were positive but viral cultures remained negative. These data were resumed in the Table 1. Considering these biological informations, the oral candidosis the patient reported must have been a HSV stomatitis, and had been treated inefficiently by usual fungal-infection treatment.

Herpes simplex type 1 infection and transmission during pregnancy

Table 1. Serological and molecular exploration of the maternal HSV-1 infection

Sampling / date	IgG anti HSV	IgM anti HSV	PCR HSV-1
First case			
Serum 11 WA 03/08/2008	presence of IgG	presence of IgM	Positive
Serum 15 WA 04/07/2008	presence of IgG	presence of IgM	Positive
Serum 21 WA 05/14/2008	presence of IgG	presence of IgM	Positive
Serum 25 WA 06/19/2008	presence of IgG	presence of IgM	/
Second case			
Serum 6 WA 12/09/2009	absence of IgG	absence of IgM	negative
Nasopharyngeal 12 WA 01/23/2010	HSV-1 PCR positive		
Serum 19 WA 03/09/2010	Appearance of IgG	Appearance of IgM	negative
Serum 21 WA 03/23/2010	presence of IgG	presence of IgM	Positive
Amniotic fluid 24 WA 04/13/2010	HSV-1 PCR positive		
Serum 25 WA 04/19/2010	presence of IgG	presence of IgM	Clearance
Serum 27 WA 05/07/2010	presence of IgG	presence of IgM rate limit	Clearance



/: no samples received for molecular analysis. First case: Persistence of IgG and IgM associated with HSV+ PCR between 11 and 25 WA. Second case: Presence of HSV1 in nasopharyngeal swabs at 12 WA, in serum at 21 WA and in amniotic fluid at 24 WA. Appearance and decrease of IgM followed consultation for herpetic gingivostomatitis symptoms

Second case

In January 2010, a 24-year-old woman consulted at gynecological emergency at 12 WA with flu-like symptoms. Due to 2009H1N1 context, viral explorations searching for Influenza virus (IAV) and RSV were performed on nasopharyngeal samples. A symptomatic treatment was initiated. Three months later, she was referred to the prenatal unit at 24 WA for IUGR discovered during ultrasound morphological examination of the second trimester. Control of the echography confirmed the IUGR with good growth kinetics. Fetal eyelids remained open throughout the examination (Fig. 1b). Presence of clots floating was observed in the amniotic fluid (Fig. 1c). Echogenic bowel with small lung calcifications were also observed and could be linked to the absorption of vaginal bleeding the patient has described. Amniotic liquid puncture was performed but researches for metabolic or genetic diseases remained ne-

gative. At 26 WA, during usual monitoring, absence of movement could be detected and, as previously described, the fetus has its eyelids and mouth opened (Fig. 1d). Position was pathologic with lower limbs in extension and higher limbs in flexion. Amniotic fluid was highly "echoic" with the presence of sloping deposits and floating amniotic membranes. A cesarean section was performed at 27 WA because of the observation of an abnormal fetal heart rate. At birth, the child had a massive bullous dermatitis with total peeling (Fig. 1e). Congenital abnormalities of desmosomes were evoked [3]. Severe hypothermia (32° C) was observed. Closure defect of eyelids and mouth and abnormal extension of the limbs were linked to important skin retraction. Severe hypotrophy (670 g) was observed during clinical examination. No microcalcifications of the lung were found on the radiography. The electrolytes and blood count were unremarkable. Researches of metabolic diseases remained ne-

gative as well. Transfontanelar echography confirmed microcephaly without any brain malformation. Congenital aplasia cutis was excluded by histological examination of skin biopsies but was consistent with epidermolysis bullosa [3]. Ophthalmologic examination confirmed the loss of corneal transparency without any retinal disease.

All the HSV researches by PCR performed at birth in eye, throat and skin swabs) were positive for HSV-1. Retrospective analysis of previously taken serum samples showed that the HSV primary infection occurred between the seventh and the 14 WA (Table 1). Retrospective analysis of swabs sampled in January, 2010, by PCR HSV-1 confirmed the diagnosis of congenital infection of primary oral HSV1 and stomatitis during this clinical event was reported by the patient.

Death occurred at day 9 of life in a context of extreme dermatitis and despite of invasive ventilation after decision of "active resuscitation" opposition of the parents.

Discussion and revue of the literature

Brown *et al.* estimated that two percent of women acquire HSV infection during pregnancy: 30% of the infections occur during the first trimester without consequences on the outcome of the pregnancy [1, 4]. However, 19 cases of HSV *in utero* infection were reported in literature during primary infection or more rarely during viral reactivation. The authors described a typical clinical presentation associated with IUGR [5-6]. Atypical cutaneous lesions leading to extensively ulcerative scars at birth, bullous dermatitis, widespread erosions and an absence of vesicles [3, 5, 7-8]. Ballooned and multinucleated giant keratinocytes within necrotic epidermis were consistent with HSV infection at skin biopsy [9]. Neurological complications with microcephaly, *corpus callosum* associated with severe ventriculomegaly leading to severe neurological sequelae were also described [5-10]. Moreover, ophthalmic symptoms were also described as chorioretinitis and microphthalmia [2, 5-7]. Finally, hepatic complications with hepatosplenomegaly or necrosis can occurred [5-6, 8].

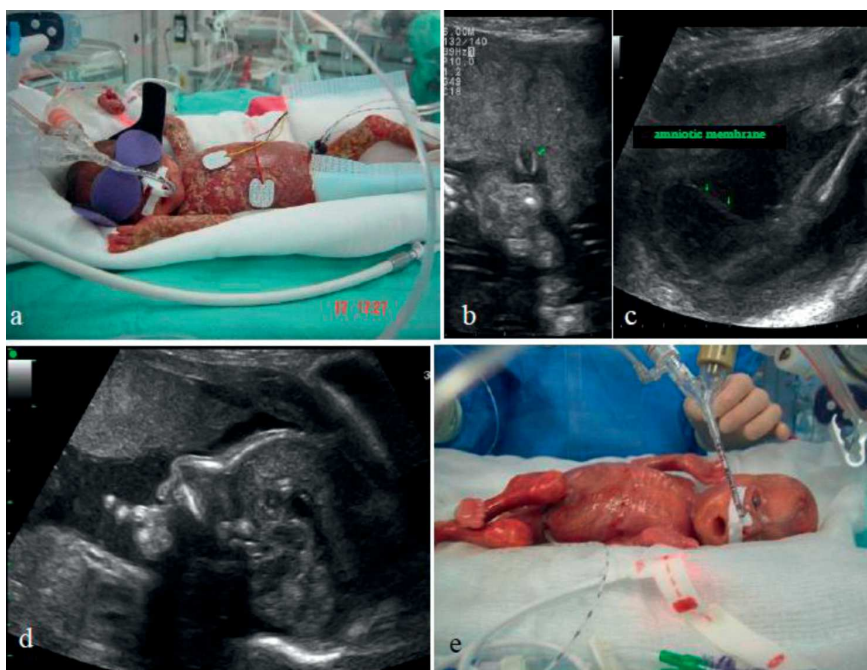


Fig. 1. a – Histopathological examination of the newborn (first case). Diffuse skin lesion (except for the scalp) with thick indurated plaques. Histological analysis showed large necrotic calcified region. False membranes associated with conjunctivitis were observed at the eye level

b – Echographical examination (second case). Foetal eyelids were found open during systematic echography

c – Echographical examination (second case). Fragment of amniotic membrane were found in amniotic fluid

d – Echographical examination (second case). No abnormalities of the central nervous system were found during examination. Eyelids and mouth remain open during examination

e – Histopathological examination of the newborn (second case). Newborn showed complete bullous dermatitis with peeling. Abnormal positions of arm and leg can be explained by important skin retraction

It is important to note that the first case of HSV-1 intrauterine infection was described by Diguët *et al.* in 2006, all case prior to this publication are due to HSV-2 intrauterine infection [6]. Despite of the increased of the incidence of in utero infection (three French cases described since 2006), this modification of epidemiology seems to not have any other clinical impact.

Here we described two cases clinically similar to previously published cases, except for the anamnesis. We reported here the first published cases of foetal infection consecutive to a maternal herpetic gingivostomatitis. These new data lead us to optimize the management of this, usually benign, infection, in pregnant women population [5, 9].

Nevertheless, 64% of the women, who become HSV positive during pregnancy, have subclinical infection [1]. In immuno-

competent patients, viremias occur only during primary HSV infection. These informations highlight the need for early diagnosis (with culture or molecular techniques) of the primary HSV infection, in genital and/or oral spheres, based on oropharyngeal or genital samples analysis. To treat patients with risks of HSV viremia with appropriate treatment (mainly by acyclovir) is fundamental to stop any foetal contamination.

In utero contamination appears mainly during primary infection and is not easy to diagnose, as described in the second case. Seroconversion and persistence of maternal immunoglobulin can be used to help clinicians. The maternofetal transmission, leading to eye and skin severe damage, can occur several weeks after the maternal viremia. Because of that fact, systemic therapy of the mother with acyclovir should be considered [5].

In conclusion, these cases illustrate the risk of HSV infection and viremia that occurring during primary infection and leading to potentially fatal *in utero* infection. Clinical histories of these patients highlight the need for management of the gingivostomatitis, even atypical, of the pregnant woman. They also confirm that it is fundamental to establish etiology of any eruption searching for HSV by serology or direct diagnosis by culture or molecular techniques. Acyclovir used in pregnant women with a HSV reactivation in late pregnancy to prevent neonatal infection is usually a successful therapeutic [11]. Moreover the safety of this molecule has been demonstrated for years in early pregnancy and is effective to prevent *in utero* infection [12]. One problematic remains, as viremia occurs before clinical manifestation of primary maternal infection and so can justify systematic surveillance of serological status of the pregnant woman

Acknowledgments

Financial support

Hospices Civils de Lyon, France

Conflicts of interest

All authors declare no conflict of interest linked to this publication

References

1. Brown ZA, Selke S, Zeh J, Kopelman J, Maslow A, Ashley RL, et al. (1997) The acquisition of herpes simplex virus during pregnancy. *N Engl J Med* 337 (8): 509-15
2. Mets MB, Chhabra MS (2008) Eye manifestations of intrauterine infections and their impact on childhood blindness. *Surv Ophthalmol* 53 (2): 95-111
3. Harris HH, Foucar E, Andersen RD, Ray TL (1986) Intrauterine herpes simplex infection resembling mechanobullous disease in a newborn infant. *J Am Acad Dermatol* 15 (5 Pt 2): 1148-55
4. Brown T, Anand A, Ritchie LD, Clewley JP, Reid TM (1984) Intrauterine parvovirus infection associated with hydrops fetalis. *Lancet Lond Engl* 2 (8410): 1033-4
5. Hoppen T, Eis-Hübinger AM, Schild RL, Enders G, Hansmann M, Rister M, et al. (2001) [Intrauterine herpes simplex virus infection]. *Klin Pädiatr* 213 (2): 63-8
6. Diguët A, Patrier S, Eurin D, Chouchene S, Marpeau L, Laquerrière A, et al. (2006) Prenatal diagnosis of an exceptional intrauterine herpes simplex type 1 infection. *Prenat Diagn* 26 (2): 154-7

Herpes simplex type 1 infection and transmission during pregnancy

7. Hutto C, Arvin A, Jacobs R, Steele R, Stagno S, Lyrene R, et al. (1987) Intrauterine herpes simplex virus infections. *J Pediatr* 110 (1): 97-101
8. Barefoot KH, Little GA, Ornvold KT (2002) Fetal demise due to herpes simplex virus: an illustrated case report. *J Perinatol Off J Calif Perinat Assoc* 22 (1): 86-8
9. Koch LH, Fisher RG, Chen C, Foster MM, Bass WT, Williams JV (2009) Congenital herpes simplex virus infection: two unique cutaneous presentations associated with probable intrauterine transmission. *J Am Acad Dermatol* 60 (2): 312-5
10. Jayaram PM, Wake CR (2010) A rare case of absent corpus callosum with severe ventriculomegaly due to congenital herpes simplex infection. *J Obstet Gynaecol J Inst Obstet Gynaecol* 30 (3): 316
11. Frenkel LM, Brown ZA, Bryson YJ, Corey L, Unadkat JD, Hensleigh PA, et al. (1991) Pharmacokinetics of acyclovir in the term human pregnancy and neonate. *Am J Obstet Gynecol* 164 (2): 569-76
12. Spangler JG, Kirk JK, Knudson MP (1994) Uses and safety of acyclovir in pregnancy. *J Fam Pract* 38 (2): 186-91