



**HAL**  
open science

# Radiographic and Clinical Comparison of Proximal Interphalangeal Joint Arthrodesis Between a Static and Dynamic Implant

Maxime Ferrier, Jean-Camille Mattei, Romain Desmarchelier, Michel-Henri Fessy, Jean-Luc Besse

► **To cite this version:**

Maxime Ferrier, Jean-Camille Mattei, Romain Desmarchelier, Michel-Henri Fessy, Jean-Luc Besse. Radiographic and Clinical Comparison of Proximal Interphalangeal Joint Arthrodesis Between a Static and Dynamic Implant. *Journal of Foot and Ankle Surgery*, 2019, SPECIAL SECTION ON SPORTS MEDICINE, PART TWO, 58 (4), pp.657-662. 10.1053/j.jfas.2018.11.004 . hal-03586897

**HAL Id: hal-03586897**

**<https://hal.science/hal-03586897v1>**

Submitted on 29 Nov 2024

**HAL** is a multi-disciplinary open access archive for the deposit and dissemination of scientific research documents, whether they are published or not. The documents may come from teaching and research institutions in France or abroad, or from public or private research centers.

L'archive ouverte pluridisciplinaire **HAL**, est destinée au dépôt et à la diffusion de documents scientifiques de niveau recherche, publiés ou non, émanant des établissements d'enseignement et de recherche français ou étrangers, des laboratoires publics ou privés.



Distributed under a Creative Commons Attribution - NonCommercial 4.0 International License

## **Radiographic and clinical comparison of PIPJ arthrodesis between a static and dynamic implant**

**Maxime FERRIER<sup>1</sup>, Jean-Camille MATTEI<sup>3,4</sup>, Romain DESMARCHELIER<sup>1,2</sup>, Michel FESSY<sup>1,2</sup>, Jean Luc BESSE<sup>1,2</sup>**

1. Université Lyon 1, IFSTTAR, LBMC UMR-T 9406 - Laboratoire de Biomécanique et Mécanique des Chocs, 69675 Bron Cedex, France

2. Hospices Civils de Lyon, Centre Hospitalier Lyon-Sud, Service de Chirurgie Orthopédique et Traumatologique, 69495 Pierre-Bénite Cedex, France

3. Assistance Publique des Hôpitaux de Marseille, Hôpital Nord de Marseille, Service de Chirurgie Orthopédique des Prs. Curvale et Rochwerger, 13015 Marseille, France.

4. Aix Marseille Université 2, Faculté de médecine de la Timone, Boulevard Jean-Moulin, 13005 Marseille

**Corresponding author: Jean-Camille MATTEI**

Email: [mattei.orthopedie@gmail.com](mailto:mattei.orthopedie@gmail.com)

Hammertoe deformation is a frequent motive of consultation in forefoot surgery and proximal inter-phalangeal (PIP) arthrodesis is a classical treatment for fixed deformation, which tends to be more and more achieved thanks to specific implants.

This work evaluated and compared clinical improvement, radiological fusion and complication rates between dynamic (Difuse®) and static (TinyFix®) implants from Biotech.

95 patients were included (110 feet and 166 toes, 97 static and 69 dynamic implants).

Mean age was 63.6 years ( $\pm$  12.6) in dynamic and 62.3 ( $\pm$  14.01) in static groups. Epidemiological and intra-operative radiological data were collected. Pain, toes deformity, complications and radiological findings (bone fusion and osteolysis) were recorded at 4 months post-operatively and at the last follow-up.

Mean follow-up was 11.5 months [4-28] and implants position was more often satisfying in the dynamic group ( $p=0.01$ ). Fusion rates at 4 months were respectively 67 and 80% in dynamic and static ( $p=0.05$ ). Radiological osteolysis occurred more frequently in dynamic ( $p=0.05$  at 4 months) and pain was still present in 3% in dynamic group at the last follow-up compared to 7% in static group.

Complication rate was 7% in dynamic group (implant fractures) and 4% for the static implant. Revision was more often considered in dynamic group ( $p=0.01$ ).

Static titanium static implant seems superior to dynamic memory shape implant in Nitinol alloy regarding fusion ( $p=0.04$ ), complications ( $p=0.03$ ) and revision rates ( $p=0.01$ ). Literature review seemed to support the good results of Static implants compared to the rest of available arthrodesis implants solutions.

**Keywords:** digital fusion, phalanx, forefoot surgery, toe implant, hammertoe deformation, Inter-phalangeal arthrodesis, dynamic implant, static implant, outcomes, fusion rate, complication rate

**Level of Evidence IV: retrospective case study**

## INTRODUCTION

Hammer and claw toe deformation of lateral toes is a frequent consultation reason in forefoot surgery. Claw position is physiological during walking (anterior gate) (1), however when this deformation becomes permanent dorsal or plantar calluses may appear (2).

The genesis of such deformation implies metatarso-phalangeal complex malfunction worsened by dorsal friction with the shoe (3). When the deformation is reducible, its initial treatment is conservative and may need shoe modification, callus paring and use of plantar orthosis. In case of fixed deformation, functional treatment is most often inefficient, and surgery becomes a necessity. Inter-phalangeal arthrodesis is the main solution and needs bony contact between phalanges with a physiological plantar flexion angle to allow gait contact (4). It had been maintained for a long time with pins, but surgeons seem to use more and more often inter-phalangeal devices, because Kirschner wires need removal, are harder to accept by patients and are thought to have higher complication (around 10% (5,10,15)) and post-operative symptoms persistence (27% (15)) rates.

The goal of this retrospective work was to assess and compare clinical improvement, radiological fusion and complications rates after inter-phalangeal proximal arthrodesis between two implants: dynamic and static

## PATIENTS AND METHODS

**Inclusion criteria:** This was a continuous retrospective series including all patients operated for toe deformation between February 2011 and November 2013 by 2 operators (JLD, RD) of the orthopaedic units, specialized seniors in foot surgery. During this period, every arthrodesis was performed using 2 kinds of implants from Biotech Ortho Company. Implant type decision was based upon ancillary availability. TinyFix® was a static pure Titanium implant (Fig 1) and Difuse® a dynamic shape memory Nitinol TiN alloy implant.

**Series:** During the 23 consecutives inclusion months, 95 patients had a claw or hammer toe(s) corrective surgery with a PIP arthrodesis implant after consultation for forefoot disorder in foot specialized orthopaedics unit in university hospital; 110 feet were operated (166 toes). Mean age was of  $62.8 \pm 13.5$  years [21-86], 11 patients were men (12%) and 84 (88%) women. Aetiologies and surgical technique used in first and lateral rays are exposed in table 1 and 2. Fifteen patients had a bilateral surgery and each patient received the same implant type. Patient with local foot infection were excluded and no internal implant was used in such cases.

Sixty-nine dynamic implants were inserted (42%) and 97 static (58%). Second toe was corrected in 99 cases (61%), the third in 29 (17%), fourth in 19 (11%) and the fifth in 19 (11%).

Concomitant flexor tenotomy was performed in 25 cases (22%), extensors in 11 cases (10%), both in 4 cases (4%) and no additional procedure in 70 cases (64%). Flexor tenotomy was used in case of severe deformity and extensor tenotomy if metatarso-phalangeal joint remained in hyper-extension after PIP arthrodesis.

Both groups were statistically comparable regarding sample size, age ( $p=0.61$ ), sex ( $p=0.37$ ) and etiology ( $p=0.21$ ).

Surgical technique: it was similar in both cases and analogous to classically described techniques (1). A dorsal and transversal approach centered on proximal inter-phalangeal space was performed. Extensor apparatus was transversally cut and arthrolysis with collateral ligaments was done at the same time to expose head of proximal phalanx and base of middle phalanx. Articular surfaces preparation was achieved with oscillating saw to resect head of proximal phalanx and abrade middle phalanx base. Proximal and distal medullar canals were prepared with a dedicated ancillary (3 different lengths). The implant was first inserted in proximal phalange then in the distal one. Intra-operative radiographic control confirmed contact between arthrodesis surfaces (coaptation), implant positioning and absence of complication (Fig 2 and 3). Extensor tendon was carefully stitched to insure implant co-aptation. Further surgical procedures on tendon, lateral metatarsal or first ray were performed at the same time. Weight bearing was entitled straightaway with a postoperative shoe (Sober type) for a month.

Assessment method: all patients had a physical examination with a forefoot plain radiograph (front, side and  $\frac{3}{4}$  views) at 4 months and at the latest follow-up. For each operated toe, pain, toe position, arthrodesis fusion and eventual complication (implant fracture, bone cortex breakage, implant migration) were recorded. Pain was assessed as simple binary question asked to the patient (did he/she feel pain or not) and fusion was achieved if two corticals merged on A/P x-rays. Clinical evaluation was performed by the two senior surgeons previously described (JLB and RD). Radiological assessment was entrusted to another independent surgeon (MF). Radiographs were performed before surgery, intra-operatively and at 21 days, 4 months and one year post-operatively.

Primary aim of the investigation was to evaluate fusion rates and secondarily complication rates.

Statistical analyses were conducted with BioStat TGV® software (<http://marne.u707.jussieu.fr/biostatgv>). A Student t test was used to compare quantitative variables and a Chi2 or Fischer for qualitative analysis. Significance threshold was set at 0.05. Patients signed a consent to participate to the study and the protocol followed Helsinki Ethical criteria.

## **RESULTS**

Mean follow-up was 11.5 months [4-28], 98% of 110 operated feet were reviewed on the 4<sup>th</sup> month (108 feet) and 20 were lost to the latest follow-up (19%). No patient was secondarily excluded.

### Peri-operative radiographs:

Radiographic analysis found 107 well-centered implants (65%), 55 were too proximal (33%), 4 were too distal (2%) with a good coaptation of arthrodesis surfaces in 108 cases (65%) and 12 intra-operative complications (7%): 7 proximal fractures of first phalange and 5 distal fractures in second phalange (table 3).

A statistically significant difference was found in distally or centrally positioned implants for both groups: static implant seemed to be harder to insert in phalanges, with a higher rate of proximal insertion difficulties. However, no difference of coaptation or per-operative complication was found.

#### Complication and revisions:

No statistical difference in complication rates was found between both groups ( $p=0.3$ ), however 3 implants fractures were noticed in 3 dynamic implants (4%).

Revision surgery was more frequent ( $p=0.01$ ) in the dynamic group: 5 further surgeries were needed, essentially for claw deformity recurrence. Implant fractures needed revision in only one case, because of arthrodesis non-union (Fig 4). These results were evaluated at the last follow-up.

#### Clinical and radiographic results:

Pain in toes decreased by 8% between radio-clinical analysis at 4 months and the latest follow-up. Bone union increased by 24%. Osteolysis rate remained stable as well as well-aligned toes whereas claw deformity increased by 3% (no statistical significance, Tables 4 and 5).

There was a significant difference in osseous healing when using static implants compared to delayed healing in dynamic group, at 4 months ( $p<0.001$ ) and on the latest follow-up ( $p=0.04$ , Tables 4 and 5, Fig 5). A statistical link was found in osteolysis risk at 4 months with a lower rate in static implant group ( $p=0.05$ ).

## **DISCUSSION**

Static implant gives significantly better results than dynamic implant (bone fusion, complication rates). These findings were not predictable because the static implant insertion was harder to perform, with lower rates of good radiological positioning. The arthrodesis fusion was quicker and more often obtained with static implant and osteolysis at 4 months was more frequent with dynamic implant use and was always associated with non-union of the arthrodesis. Post-operative complications were comparable between both groups, but the claw deformity recurrence rate was higher in the dynamic group. The principal senior operator abandoned dynamic implant and thus only use static implant.

The high number of toes in both samples in this continuous series, the homogeneity of both groups, with 2 foot-specialized senior operators can be considered as strong points of this work, while its retrospective aspect is a limitation. We made the choice not to use any functional score because the claw treatment was most often associated with correction of other deformities (first ray, lateral metatarsal surgeries: in about half of the cases, first ray pathology is associated with another toe deformity or metatarsalgia (16, 17)).

The dynamic characteristics of the implant might lead to higher rates of osteolysis and non-unions in this group, which could be explained by the Nitinol (TiN) shape memory alloy leading to poorer bone integration than

static pure Titanium implants, known as non-union and implant-fracture risk factors. Three cases of dynamic implant fractures were associated with non-union, necessitating one revision.

Recent literature is scarce comparing clinical and radiological outcomes of toe inter-phalangeal arthrodesis implants. Most studies are comparable to ours regarding samples sizes, follow-up and data collection (Table 6). Smart-Toe® (Stryker) is one of the most frequently reported implants in the literature (4 recent studies between 2013 and 2015). Clinical and radiological outcomes seem to be comparable with ours: radiological fusion rates vary from 68.9 (Scholl and al. (5)) to 96.3% (Khan and al. (6)) versus 67% and 80% for dynamic and static implants in our series, respectively. Guelfi and al. review paper (18) describes a 60.5-100% fusion rate. Literature review found higher pain rates at the latest follow-up in Catena's series (19%) (7) compared to 3% with dynamic implant and 7% with static in our series. Nitinol alloy seems to be linked to a higher implant fracture rate: 1.2% in Kahn and al. series (6) and 20.7% in Scholl and al.'s (5), versus 4% and 0% for dynamic and static in our work, respectively.

In some studies, overall complication rates may be high when using Smart-Toe® implant as shown in Catena and al. (7) study (22% complication rate: infection (5%), wound necrosis (5%), broken implant (5%), migration of implant (5%), cortical disruption (2%)). The StayFuse® implant from Tornier is linked with lower fusion rates : from 60.5% in Ellington and al.'s (8) to 73% in Fazal and al.'s study (9). Integra's Ipp-On® implant seems to offer equivalent radio-clinical results to ours : 83.8% fused on x-ray, 4.7% of patients had pain after one year, 3.2% complication rate and 0.9% of revision surgeries in Coillard and al.'s work (4) (117 patients, 156 toes, 12 months follow-up). Cannulink® implant results described in Richman and al.'s study (15) are also consistent with literature outcomes with 7.7% of patients not completely satisfied by their results (pain) and no revision.

Kirschner wires allow a good arthrodesis fusion rate (81% in Coughlin and al. (10), 82.1% in Scholl and al.'s (5)) compared with previously described implants and complication rate (fracture of the wire, infection, vascular impairment and recurrent deformity) was of 7.1%, 10% and 19% in Scholl (5), Coughlin (10) and Richman (15) and al. studies, respectively. Guelfi and al. work found 3 papers with revision rates ranging from 0 to 10.7%. Richman's mentioned 27% remaining symptomatic and 5% requiring a revision surgery (15), probably because of healing delay or local infection (3%). Larger studies should be performed to assess the interest of IP fusion implant versus K-wire, especially focusing on cost-effectiveness and patient satisfaction (20).

## **CONCLUSION**

The static implant offers higher fusion rate and less complications than the dynamic Nitinol memory shape implant. Literature review seems to support the good results of this static implants compared to the rest of

available arthrodesis implants solutions. Further studies are needed to evaluate and compare these different kind of implants.

Conflict of interest : Jean-Luc Besse is a Biotech-Wright educational consultant.

## REFERENCES

1. Valtin B, Leemrijse, De Prado M, Rabat E. Pathologie des orteils: clinique et traitement chirurgical. In Pathologie du pied et de la cheville. Leemrijse T., Besse JL., Devos Bevernage B., Valtin B. 2<sup>e</sup> édition. Elsevier Masson; 2015. p 315-335.
2. Lelièvre J. Jean Lelièvre,... Pathologie du pied : Physiologie, clinique, traitement médical, orthopédique et chirurgical... 3e édition revue et augmentée. Masson et Cie; 1967.
3. Brahms M. The Small Toes - corns and deformities of the small toes in disorders of the foot and ankle (JAHSS). 1991;1175-228.
4. Coillard J-Y, Petri GJ, van Damme G, Deprez P, Laffenêtre O. Stabilization of proximal interphalangeal joint in lesser toe deformities with an angulated intramedullary implant. *Foot Ankle Int.* 2014;35:401–7.
5. Scholl A, McCarty J, Scholl D, Mar A. Smart toe® implant versus buried Kirschner wire for proximal interphalangeal joint arthrodesis: a comparative study. *J Foot Ankle Surg Off Publ Am Coll Foot Ankle Surg.* 2013;52:580–3.
6. Khan F, Kimura S, Ahmad T, D’Souza D, D’Souza L. Use of Smart Toe© implant for small toe arthrodesis: A smart concept? *Foot Ankle Surg.* 2015;21:108-12.
7. Catena F, Doty JF, Jastifer J, Coughlin MJ, Stevens F. Prospective study of hammertoe correction with an intramedullary implant. *Foot Ankle Int.* 2014;35:319–25.
8. Ellington JK, Anderson RB, Davis WH, Cohen BE, Jones CP. Radiographic analysis of proximal interphalangeal joint arthrodesis with an intramedullary fusion device for lesser toe deformities. *Foot Ankle Int.* 2010;31:372–6.
9. Fazal MA, James L, Williams RL. StayFuse for proximal interphalangeal joint fusion. *Foot Ankle Int.* 2013;34:1274–8.
10. Coughlin MJ. Operative repair of the fixed hammertoe deformity. *Foot Ankle Int.* 2000;21:94–104.
11. Lehman DE, Smith RW. Treatment of symptomatic hammertoe with a proximal interphalangeal joint arthrodesis. *Foot Ankle Int.* 1995;16:535–41.
12. Caterini R, Farsetti P. Arthrodesis of the toe joints with an intramedullary cannulated screw for correction of hammertoe deformity. *Foot Ankle Int.* 2004;25:256–61.
13. Sandhu JS, DeCarbo WT, Hofbauer MH. Digital arthrodesis with a one-piece memory nitinol intramedullary fixation device: a retrospective review. *Foot Ankle Spec.* 2013;6:364–6.
14. Kramer WC, Parman M, Marks RM. Hammertoe Correction With K-Wire Fixation. *Foot Ankle Int.* 2015;36:494-502.
15. Richman SH, Siqueira MB, McCullough KA, Berkowitz MJ. Correction of hammertoe deformity with novel intramedullary PIP fusion device versus K-Wire fixation. *Foot Ankle Int.* 2017, 3\_:174-180



16. Slullitel G, López V, Calvi JP, Seletti M, Bartolucci C, Pinton G. Effect of First Ray Insufficiency and Metatarsal Index on Metatarsalgia in Hallux Valgus. *Foot Ankle Int.* mars 2016;37(3):300-6.
17. Galica AM, Hagedorn TJ, Dufour AB, Riskowski JL, Hillstrom HJ, Casey VA, et al. Hallux valgus and plantar pressure loading: the Framingham foot study. *J Foot Ankle Res.* 20 oct 2013;6:42.
18. Guelfi M, Pantalone A, Daniel JC, Vanni D, Guelfi MGB, Salini V. Arthrodesis of proximal interphalangeal joint for hammertoe: intramedullary device options. *J Orthop Traumatol Off J Ital Soc Orthop Traumatol.* déc 2015;16(4):269-73.
19. Obrador C, Losa-Iglesias M, Becerro-de-Bengoa-Vallejo R, Kabbash CA. Comparative Study of Intramedullary Hammertoe Fixation. *Foot Ankle Int.* avr 2018;39(4):415-25.
20. Albright RH, Waverly BJ, Klein E, Weil L, Weil LS, Fleischer AE. Percutaneous Kirschner Wire Versus Commercial Implant for Hammertoe Repair: A Cost-Effectiveness Analysis. *J Foot Ankle Surg Off Publ Am Coll Foot Ankle Surg.* avr 2018;57(2):332-8.

#### Figures legends




Fig 1: Static and dynamic implants with different lengths and angulations

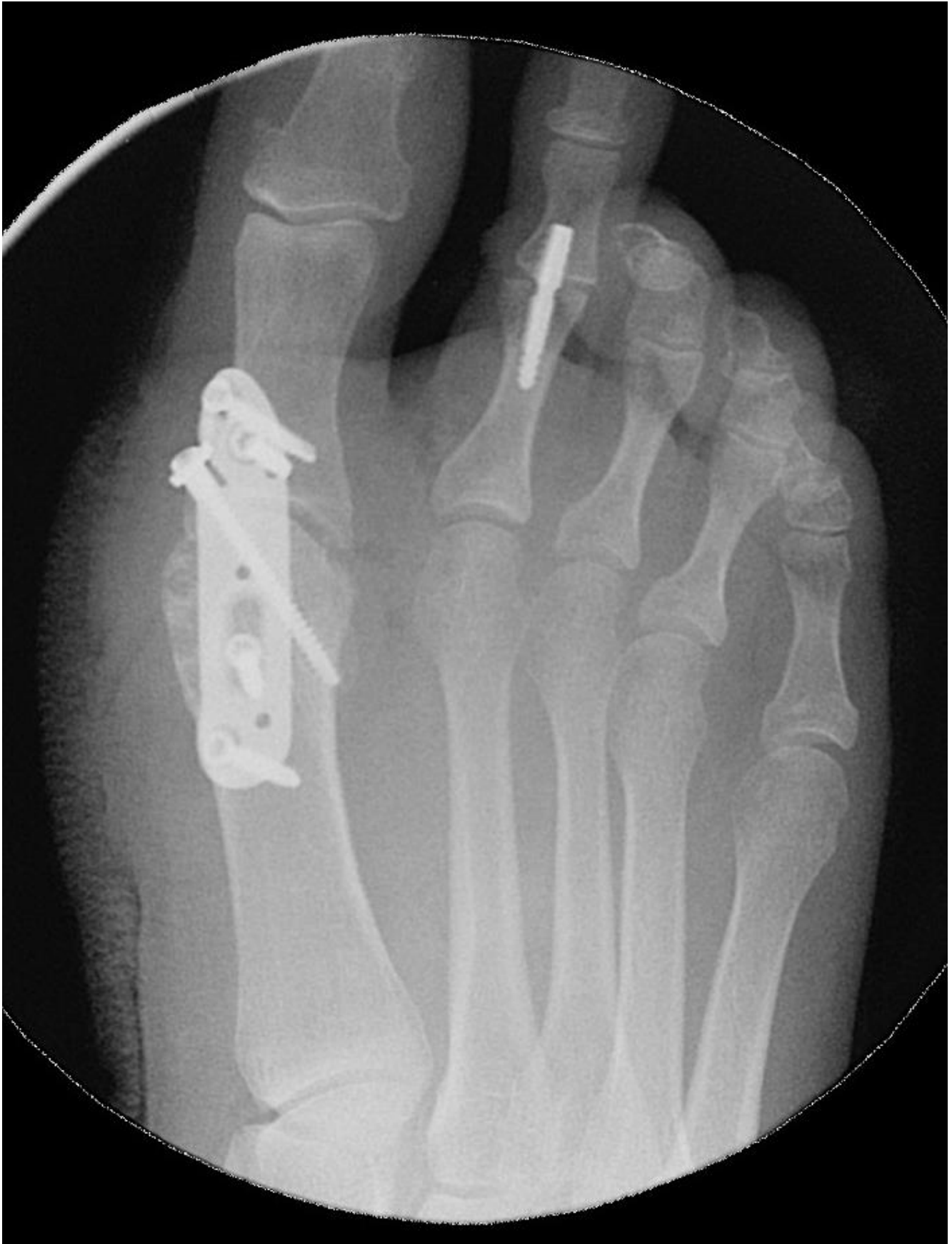

Fig 2: Peri-operative control after static implant positioning

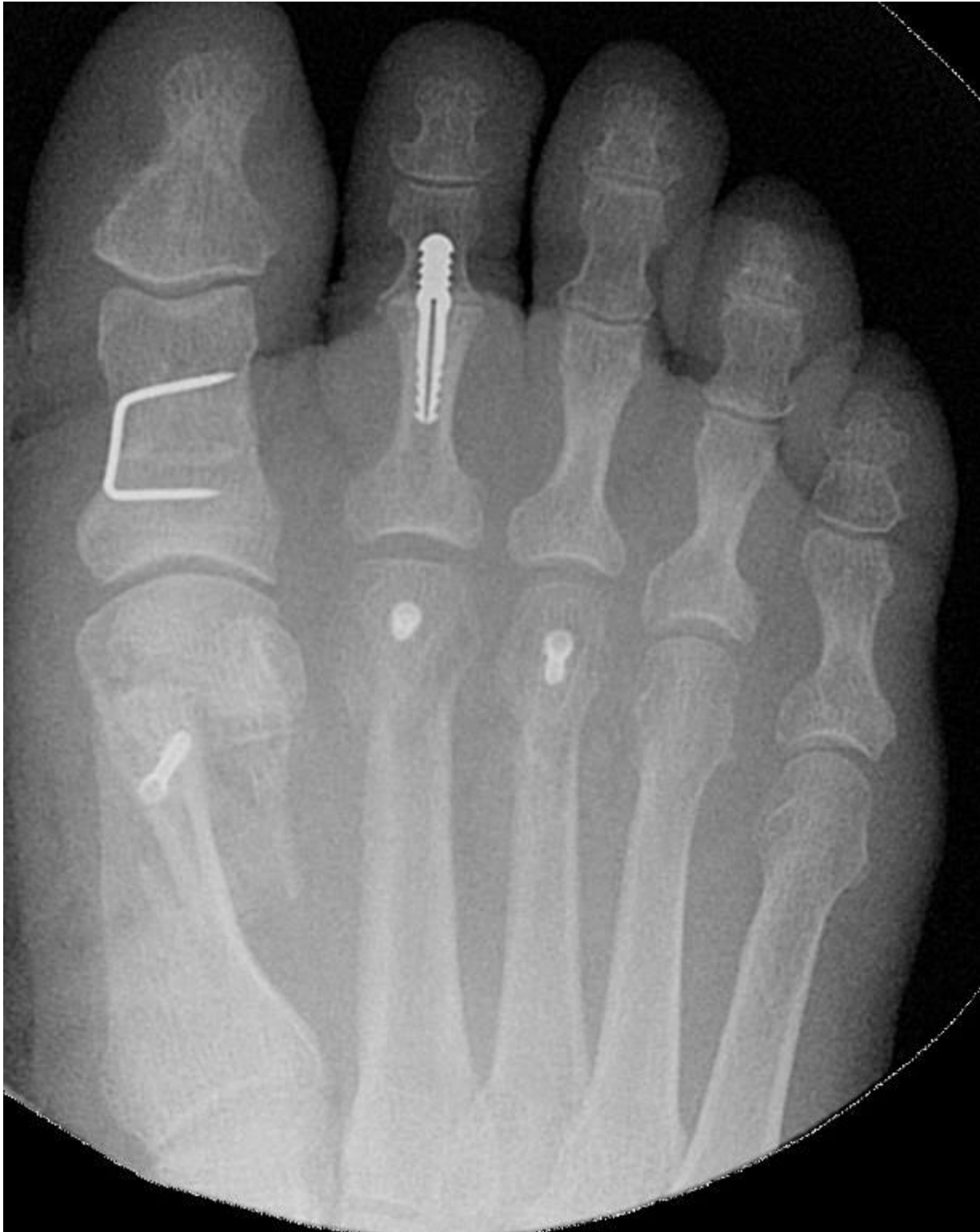

Fig 3: Peri-operative control after dynamic implant positioning

D

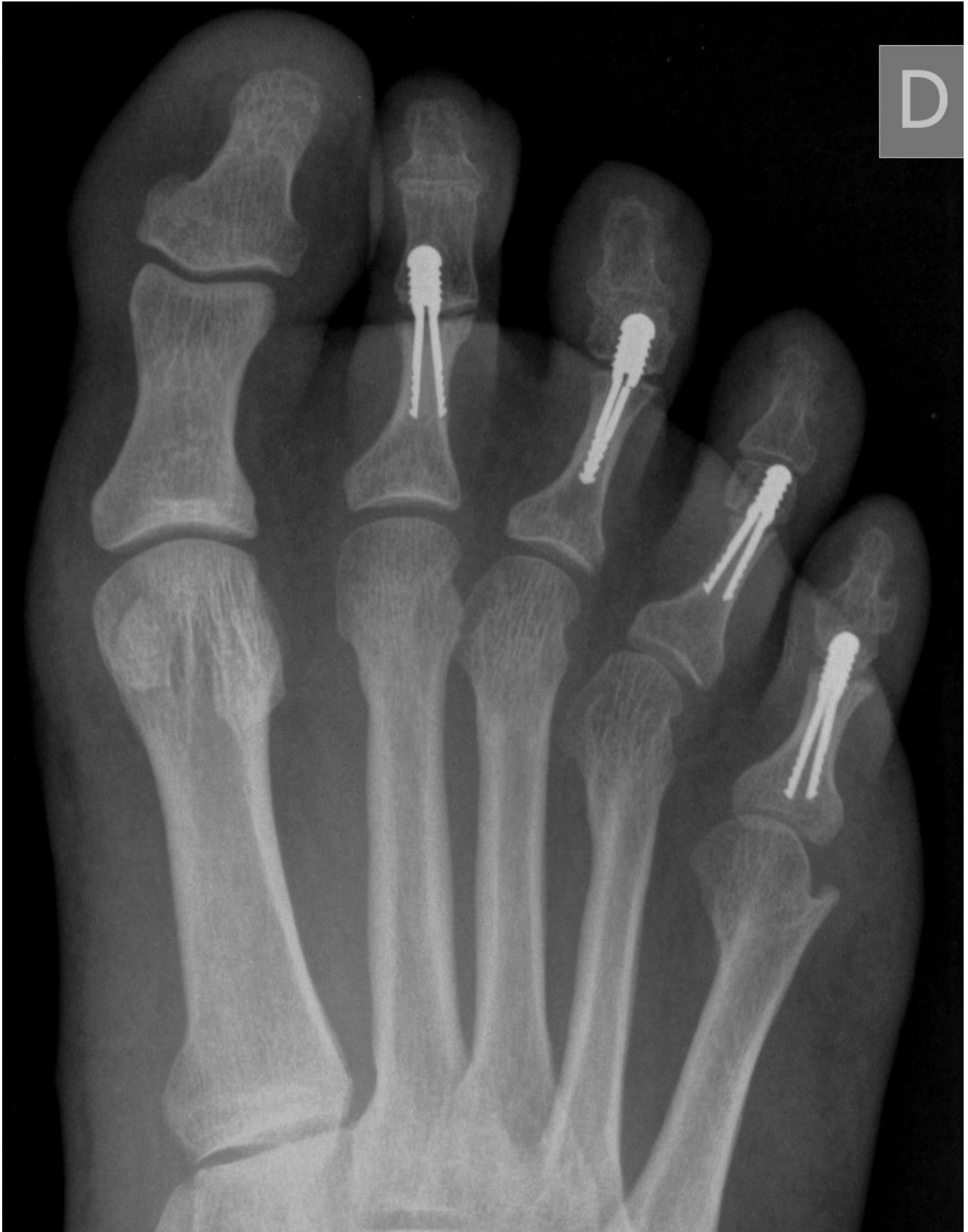

Fig 4: Non-union caused by implant fracture

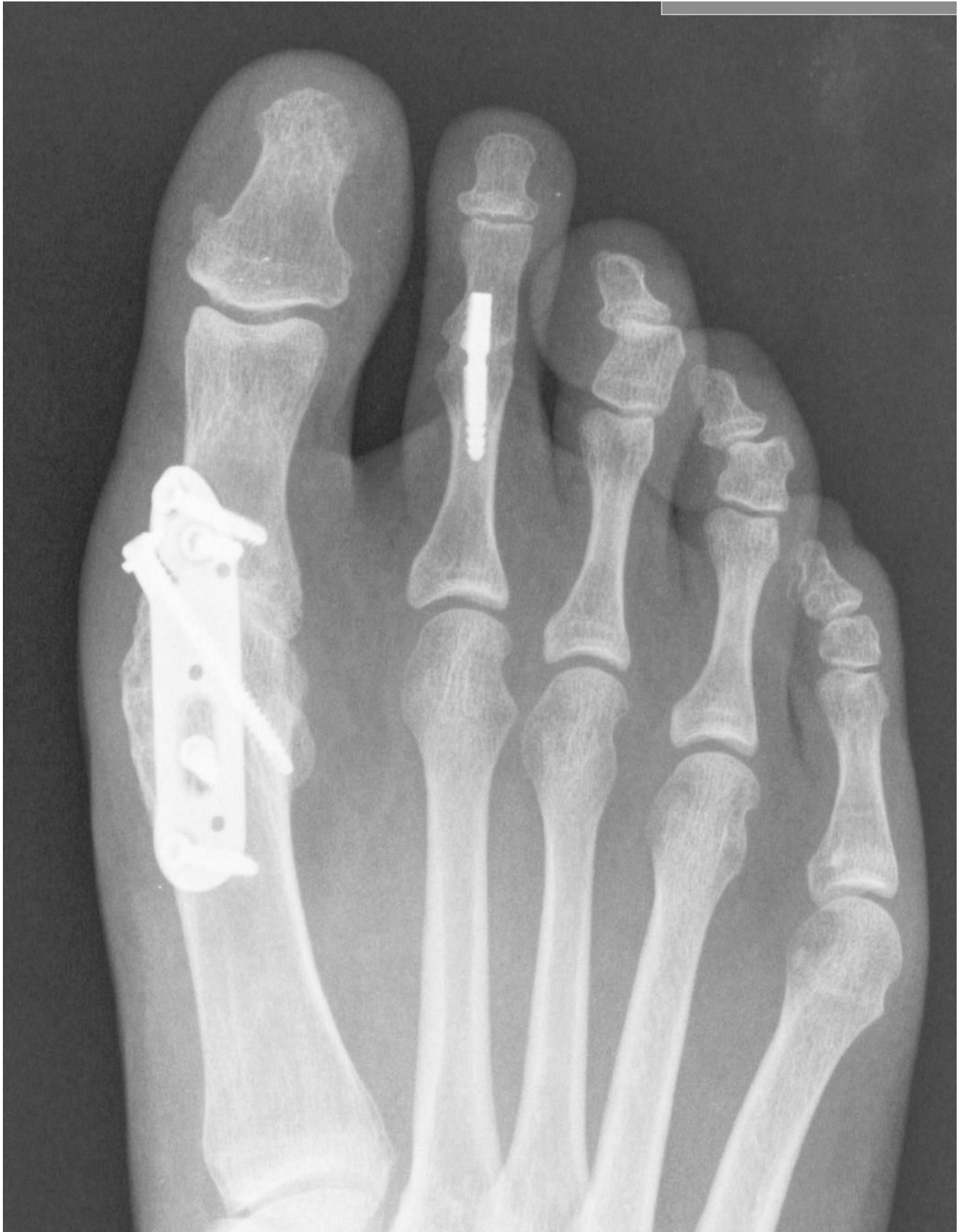

Fig 5: Fusion after one year (static implant)

## Tables legends

Table 1: Aetiologies and treatments

	Series	Dynamic Implant	Static Implant	p
Feet	110	42	68	
Age (years)	62.78 ± 13.45 [21-86]	63.62 ± 12.6 [22-82]	62.26 ± 14.01 [25-88]	0.611
Aetiologies	Hallux Valgus 72% (80) Hallux Rigidus 7% (8) Hammertoes only 12% (13) Rheumatoid arthritis. 3% (3) Neurological 3% (3) Other 3% (3)	Hallux Valgus 67% (28) Hallux Rigidus 12% (5) Hammertoes only 14% (6) Rheumatoid arthritis. 0% (0) Neurological 2% (1) Other 5% (2)	Hallux Valgus 77% (52) Hallux Rigidus Hammertoes only 10% (7) Rheumatoid arthritis. 4.5% Neurological 3% (2) Other 1.5% (1)	0.21

Table 2: Lateral metatarsal surgery types

Lateral metatarsal surgery	Patients (%)
None	42 (38)
Weil M2	20 (18)
Weil M2-M3	38 (35)
Weil M2-M3-M4	1 (1)
Weil M4	1 (1)
DMMO 2-3-4	1 (1)
DMMO 2-3-4-5	1 (1)
Resection-arthroplasty	3 (3)
Other	2 (2)

(DMMO : Distal Metatarsal Mini-invasive Osteotomy)

Table 3: Peri-operative results

Implants	Dynamic Implant N = 69	Static Implant N = 97	<i>p</i>
Centered	75% (52)	57% (55)	0.01
Proximal	22% (15)	41% (40)	0.01
Distal	3% (2)	2% (2)	Ns
Coaptation	67% (46)	64% (62)	Ns
Complication	7% (5)	7% (7)	Ns

Table 4: 4-months results in both groups

Implants	Dynamic Implant N =69	Static Implant N = 97	<i>p</i>
Pain	13% (9)	13% (13)	Ns
Fusion	33% (23)	63% (61)	0.0003
Osteolysis	12% (8)	3% (3)	0.05
Well-aligned	97% (67)	96% (93)	Ns
Valgus deformation	0% (0)	0% (0)	Ns
Varus deformation	3% (2)	4% (4)	Ns
Residual claw toe	0% (0)	4% (3)	Ns

Table 5: last follow-up results in both groups

Implants	Dynamic Implant N =69	Static Implant N = 97	<i>p</i>
Pain	3% (2)	7% (7)	0.31
Fusion	67% (46)	80% (78)	0.04
Osteolysis	12% (8)	4% (4)	0.08
Toe aligned	97% (67)	97% (94)	1
Valgus deformation	0% (0)	0% (0)	1
Varus deformation	3% (2)	3% (3)	1

<b>Residual claw toe</b>	<b>6% (4)</b>	<b>4% (4)</b>	<b>0.72</b>
--------------------------	---------------	---------------	-------------

Table 6: series comparison

Series	Treatment	Patients (toes)	Mean Follow-up (months)	Mean Age	Painful patients % (number)	Fusion % (number)	Complication % (number)	Revision % (number)
Lehman 1995 (11)	Peg	76 (137)	36	60	7% (5)	95% (130)	13% (10)	7% (5)
Coughlin 2000 (10)	K-Wire	63 (118)	61	57	8% (5)	81% (95)	10% (6)	/
Caterini 2004 (12)	Screw	24 (51)	31.2	48	14% (7)	94% (48)	14% (7)	14% (7)
Ellington 2010 (8)	Implant StayFuse	27 (38)	31	62	/	60.5% (23)	16% (6)	8% (3)
Fazal 2013 (9)	Implant StayFuse	140 (150)	18	69.5	4.7% (7)	73% (110)	5.3% (8)	3.3% (4)
Sandhu 2013 (13)	Implant Smart Toe	35 (65)	27	62.2	/	93.8% (61)	6.1% (4)	0% (0)
Scholl 2013 (5)	Implant Smart Toe	/(58)	(8-94)	61.47	/	68.9% (40)	20.7% (12 fractures)	8.6% (5)
Scholl 2013 (5)	K-Wire	/(28)	(8-94)	61.47	/	82.1% (23)	7.1% (2 fractures)	10.7% (3)
Coillard 2014 (4)	Implant Ipp-On	117 (156)	12	65.8	4.7% (6)	83.8% (124)	3.2% (5)	0.9% (1)
Khan 2014 (6)	Implant Smart Toe	82 (82)	6	56.5	8.5% (7)	96.3% (79)	2.4% (2) 1.2% (1 fracture)	/
Catena 2014 (7)	Implant Smart Toe	24 (42)	12	63	12% (5)	81% (34)	26% (11) 5% (2 fractures)	/
Kramer 2015 (14)	K-Wire	876 (2698)	20.8	57.5	/	/	4.5% (121)	3.9% (104)
Richman 2017 (15)	CannuLink	39 (54)	12.9	61.4	7.7% (3)	22.2% (12)	5.6% (2)	0% (0)
Richman 2017 (15)	K-Wire	60 (95)	12.9	61.7	3% (3)	/	12.5% (12)	5.3% (5)
<b>Our Study</b> Dynamic group	Implant Di-Fuse	42 (69)	12.3	63.6	3% (2)	67% (46)	7% (5)	7% (5)



<b>Our Study</b>								
Static group	Implant TinyFix	53 (97)	11	62.3	7% (7)	80% (78)	4% (4)	0% (0)