



HAL
open science

Interaction between posture and maxillomandibular deformity: a systematic review

Adeline Kerbrat, Thomas Schouman, D. Decressain, Philippe Rouch, Valérie Attali

► To cite this version:

Adeline Kerbrat, Thomas Schouman, D. Decressain, Philippe Rouch, Valérie Attali. Interaction between posture and maxillomandibular deformity: a systematic review. *International Journal of Oral and Maxillofacial Surgery*, 2022, 51 (1), pp.104-112. 10.1016/j.ijom.2021.05.003 . hal-03583312

HAL Id: hal-03583312

<https://hal.science/hal-03583312>

Submitted on 21 Feb 2022

HAL is a multi-disciplinary open access archive for the deposit and dissemination of scientific research documents, whether they are published or not. The documents may come from teaching and research institutions in France or abroad, or from public or private research centers.

L'archive ouverte pluridisciplinaire **HAL**, est destinée au dépôt et à la diffusion de documents scientifiques de niveau recherche, publiés ou non, émanant des établissements d'enseignement et de recherche français ou étrangers, des laboratoires publics ou privés.

Interaction between posture and maxillomandibular deformity: a systematic review

A. Kerbrat^{1,2}, T. Schouman^{1,2},
D. Decressain¹, P. Rouch²,
V. Attali^{2,3,4}

¹Service de Chirurgie Maxillo-Faciale, Sorbonne Université, APHP, Hôpital Pitié-Salpêtrière, Paris, France; ²Arts et Métiers Sciences et Technologies, Institut de Biomécanique Humaine Georges Charpak, Paris, France; ³Groupe Hospitalier Universitaire APHP – Sorbonne Université, site Pitié-Salpêtrière, Service des Pathologies du Sommeil (Département R3S), Paris, France; ⁴Sorbonne Université, INSERM, UMRS1158 Neurophysiologie Respiratoire Expérimentale et Clinique, Paris, France

A. Kerbrat, T. Schouman, D. Decressain, P. Rouch, V. Attali: Interaction between posture and maxillomandibular deformity: a systematic review. *Int. J. Oral Maxillofac. Surg.* 2022; 51: 104–112. © 2021 International Association of Oral and Maxillofacial Surgeons. Published by Elsevier Inc. All rights reserved.

Abstract. Maxillomandibular deformity (MMD) and body posture appear to be correlated. However, no systematic literature review of the available evidence to support this correlation has been performed to date. The aim of this study was to conduct a systematic literature review on posture and MMD. This systematic literature review was registered in the PROSPERO database. Systematic searches of the MEDLINE, Scopus, Cochrane Library, and Web of Science databases were performed. In total, 13 clinical studies were included. Nine found a significant association between MMD and body posture or body balance: two studies showed a correlation between increased cervical lordosis and skeletal class III MMD, two studies showed an interaction between mandibular deviation and scoliosis, four studies demonstrated a significant association between lumbar column and pelvis anatomy and MMD, and one study found a correlation between displacement of the centre of mass and MMD. However, the level of evidence is low; the methods used to evaluate body posture and MMD were inconsistent. Orthognathic surgery could modify body posture. Although there seems to be an interaction between body posture and facial deformity, the number of studies is too small and the level of evidence too low to strongly support this association.

Maxillomandibular deformity (MMD) is an incorrect relationship of the jaws that causes malocclusion. In addition to the malocclusion, associated symptoms include a variety of oral function disorders, such as masticatory disorder, mouth breathing, temporomandibular joint disorders, facial asymmetry, and tongue dysfunction¹. Most MMDs are the result of facial skeleton growth

disorders. The prevalence of dental malocclusion is estimated to be between 14% and 23% in the general population². Most malocclusions are treated orthodontically. However, about 2% of patients with malocclusion will eventually require a combination of orthodontic treatment and orthognathic surgery to address the MMD responsible for the malocclusion³.

Postural dysfunction is defined as the inability to maintain, achieve, or restore a state of balance in any posture or during any activity⁴. It is associated with an increased risk of degenerative disc disease⁵, back pain⁶, and a higher risk of falls in elderly people⁷.

To stand and keep an upright position, the human spine comprises successive opposing curves that keep the head and pelvis

vertically aligned⁸. In the case of spine misalignment such as lumbar hyperlordosis or thoracic hyperkyphosis, a compensation mechanism gradually develops as spine imbalance increases⁹. When this compensation mechanism reaches its limit, complications may occur. For example, thoracic hyperkyphosis is related to higher morbidity and mortality rates in the elderly, as it increases the risk of falls related to alterations in body biomechanics⁷. Indeed, Sinaki et al. demonstrated that women with osteoporosis and hyperkyphosis had weaker back extensor strength, weaker lower extremity strength, slower gait, poorer balance, and greater body sway, resulting in a propensity to fall¹⁰. Neurological disorders, such as peripheral neuropathy¹¹, Parkinson's disease¹², and strokes¹³, can also play a part in postural dysfunction resulting from spine misalignment.

There are arguments in favour of a relationship between MMDs and postural dysfunction in children. However, it is unclear whether the postural disorder is a consequence or a cause of the MMD. Muscular dysfunction seems to play a role in this association. The anatomical connections between the mandible and the cervical spine at least, in addition to the high prevalence of MMD in children with scoliosis and functional asymmetry of the trunk muscles, support this hypothesis¹⁴. The upper airway ventilation dysfunction frequently encountered in MMD could also be involved; mouth breathing induces cervical misalignment characterized by a head forward posture with hyperextension of the cervical spine, particularly in chil-

dren exhibiting class II MMD^{15,16} or mandibular retrusion¹⁷. In these skeletal facial types, cervical hyperextension allows for a protruding head position, which increases upper airway volume and facilitates ventilation^{18,19}.

The consequences of this impaired cervical alignment on spine alignment and body balance in children are unknown. In adults, head and cervical postures play an important role in body balance; permanent adjustments of the cervical curvature during standing are needed to preserve an adequate head-to-pelvis alignment, which is critical in maintaining balance⁷ and a head position compatible with a horizontal gaze²⁰. According to the findings in spine misalignment mentioned above, we may suspect a higher prevalence of balance disorders in adult patients presenting an MMD. Some studies have investigated balance-related parameters in MMD cohorts, but it appears that no literature review has specifically focused on the available evidence supporting this association. Therefore, the aims of the present systematic literature review were to assess (1) the interaction between MMD and body posture and/or body balance, and (2) available evidence of any impact of surgical correction of MMD on body posture and/or body balance.

Methods

Search strategy and selection criteria

A systematic literature review was performed according to the PRISMA guide-

lines²¹. Two investigators independently searched for studies in the MEDLINE, Cochrane Library, Scopus, and Web of Science databases. All original articles on posture and MMD in adults, written in English and published from 1900 to March 2020, were included. Studies focusing only on cervical evaluation, case reports, and studies lacking a postural evaluation were excluded. Studies assessing the impact of mandibular positioning (for instance using splints to simulate different occlusal positions) or on patients with class I malocclusions only were also excluded. The search sequence comprised several keywords and medical subject heading (MeSH) terms for a broad coverage of the subject. The search consisted of a combination of the following headlines: (1) postural evaluation, (2) malocclusion. The keywords relating to posture were "posture", "postural evaluation", "postural balance", "postural assessment", and "sagittal balance". The keywords used for MMD were "orthognathic surgery", "malocclusion", "dysgnathia", "jaw abnormalities", "dentofacial deformities", "jaw deformities", and "dysmorphia". The review was registered in the PROSPERO database (number CRD42020160990).

Quality assessment and risk of bias

To evaluate the quality, risk of bias, and applicability of each study, information was collected using a tailored checklist based on the QUADAS-2 tool and recommendations from the *Cochrane Handbook*

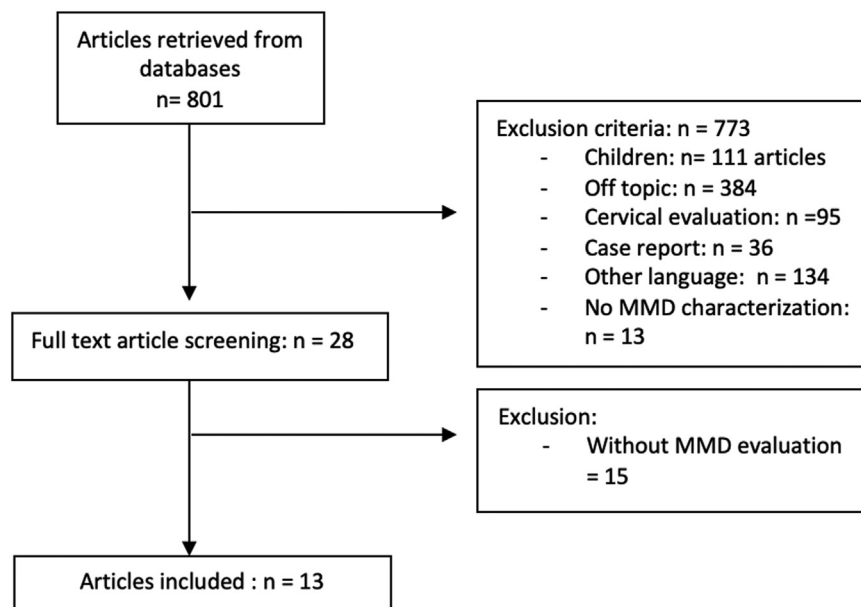


Fig. 1. Flow chart of the article inclusion process.

Table 1. Assessment of bias and applicability of the included studies, using the tailored QUADAS-2 tool.

Author	Risk of bias		Applicability concerns	
	Patient selection	Postural evaluation/index test	Patient selection	Postural evaluation/index test
Iacob et al. 2020 ²³	L	L	L	L
Paya-Argoud et al. 2019 ³⁵	H	L	?	H
Nakashima et al. 2018 ²⁷	?	L	L	L
Kulczynski et al. 2018 ³³	L	?	L	L
Kulczynski et al. 2018 ³⁴	L	?	L	L
Scharmweber et al. 2017 ²⁴	H	?	H	H
Nakashima et al. 2016 ²⁸	?	L	L	L
Zhou et al. 2013 ²⁶	?	?	L	?
Lippold et al. 2007 ³⁰	L	L	L	L
Lippold et al. 2006 ³²	L	L	L	L
Lippold et al. 2006 ³¹	L	L	L	L
Sinko et al. 2006 ²⁹	?	L	?	L
Nobili and Adversi 1996 ²⁵	L	?	L	L

L, low risk of bias;?, unclear risk of bias; H, high risk of bias.

for Systematic Reviews of Diagnostic Test Accuracy (Supplementary Material Table S1)²². If there was insufficient detail reported in the study, the risk of bias was deemed 'unclear'. These decisions were made independently by two of the review authors. Disagreements were resolved by discussion and, when this failed, by consulting a third author for arbitration.

Data extraction

The included articles were reviewed in detail by the two investigators. Data from each study regarding year of publication, number of patients, sex, mean age, population, study design, and outcome were extracted. Additional information about postural assessment methods, primary and secondary outcomes, type of MMD, and orthognathic surgery outcomes were also recorded.

Results

A total of 801 articles were identified in the database research, of which 773 were excluded after title and abstract screening. Fifteen articles were excluded after screening the full text. Finally, 13 clinical studies were included (Fig. 1)²³⁻³⁵.

Quality assessment and risk of bias

None of the included studies enrolled consecutive or randomized patients. Two articles had major selection biases: one study had a male to female sex ratio of 0.16:1 (25 females and four males)²³ and one study included only males²⁴. Four studies used unvalidated postural assess-

ment methods²³⁻²⁶. Four studies did not specify exclusion criteria²⁶⁻²⁹. Two of the 13 clinical studies presented a major risk of bias (selection bias) and poor quality. The 11 remaining studies can be considered of moderate to good quality (Table 1).

MMD evaluation

The methods of evaluation are summarized in Table 2. Four studies characterized MMD based on occlusion only^{23-25,32}. Among them, one study evaluated dental occlusion with dental plaster models²⁴. Five studies investigated craniofacial morphology with X-rays only^{26-28,30,31}. Three studies used postero-anterior radiographs, while two studies used lateral radiographs to perform the cephalometric analysis. However, four studies evaluated MMD on either frontal or sagittal view only, and one relied on both but detailed only the frontal evaluation. The method of evaluation of the MMD was not detailed in four studies^{29,33-35}.

Postural assessment methods

Ten studies evaluated body posture, among which four relied on rastereography²⁹⁻³², two on photogrammetry^{33,34}, and three on X-rays²⁶⁻²⁸. Photogrammetry quantifies the postural assessment by measuring linear distances and angles formed between lines connecting body markers and horizontal or vertical lines on digital photographs, using software specifically designed for this purpose. Rastereography is a simultaneous multi-light-sectioning procedure: 81 light sections are projected on the back of the subject, which produce a unique pattern of

light and heavy lines. The curved surface of the dorsum causes distortion of the lines. The light pattern is recorded with a video camera and a surface shape analysis is performed by computer. For X-ray evaluations, only a frontal chest X-ray was performed in one study in order to search for scoliosis²⁸, while the two remaining studies complemented the postural examination with photographs²⁷ or head X-rays²⁶.

Three studies evaluated body balance using force platforms^{24,25,35}, among which one complemented the postural examination with photographs³⁵.

Interaction between posture and MMD

Among the 10 clinical studies that evaluated the interaction between body posture and MMD, eight found a significant association.

Two studies showed a correlation between increased cervical lordosis and skeletal class III MMD^{33,34}. Regarding the thoracic spine, two studies showed an interaction between mandibular deviation and scoliosis^{26,28}, and one study showed that patients with skeletal class II or class III MMDs presented a more cranial apex of thoracic kyphosis than controls²⁹.

Four studies demonstrated a significant association between lumbar column and pelvis anatomy and MMD. Class III MMD patients had greater pelvic anteversion, greater pelvis tilt, and greater lordosis angles than controls^{29,33}. Class II MMD patients also presented a greater pelvis tilt than controls²⁹. Lippold et al. found that the angle of lumbar lordosis was correlated with cephalometric parameters describing anteroposterior projection of the face³¹. In a second study, the same authors also demonstrated a correlation between pelvic torsion and cephalometric parameters describing anteroposterior projection of the face³⁰. One article found an interaction between head inclination and mandibular deviation²⁷. The results are summarized in Table 3.

Interaction between balance and MMD

Among the three clinical studies including an evaluation of balance^{24,25,35}, two compared patients with class II malocclusion to patients with class III malocclusion. One study found an interaction between malocclusion and balance, with anteriorly displaced centre of mass in subjects with class II malocclusion and posteriorly displaced centre of mass in subjects with class III malocclusion²⁵, while the other clinical study showed no difference between class II and class III patients²⁴. One study evaluated balance in subjects with skeletal class II and

Table 2. Evaluation of maxillomandibular deformity.

Author	Year	Type of maxillo-mandibular deformity evaluation	Parameter	Method of evaluation
Iacob et al. ²³	2019	NA	Skeletal class	NA
Paya-Argoud et al. ³⁵	2020	Clinical evaluation	Dental occlusion	Right and left Angle class
Nakashima et al. ²⁷	2018	PA cephalometric radiographs	Lateral deviation of the mandible	Angle between the vertical axis and Me
Kulczynski et al. ³³	2018	NA	Skeletal class	NA
Kulczynski et al. ³⁴	2018	NA	Skeletal class	NA
Scharnweber et al. ²⁴	2017	Plaster models	Dental occlusion	First molar relation Cuspid relation Overjet and overbite Crossbite Midline shift/deviation
Nakashima et al. ²⁸	2016	NA PA radiographs	Skeletal class Lateral deviation of the mandible	ANB angle Angle between the vertical axis and Me
Zhou et al. ²⁶	2013	PA radiographs	Mandibular deviation	Obvious difference in the lengths of the two mandibular rami, and a vertical distance from the chin ridge to inferior orbital fissure line >2 mm
Lippold et al. ³⁰	2007	Lateral radiographs	Cephalometric analysis	Facial axis: Ba–N/Pt–Gn Mandibular plane angle: P–Or/Me–hT Inner gonial angle: Xi–Spa/Xi–Pm Lower facial height: Xi–DC/Xi–Pm Facial depth: P–Or/N–Po Maxillary position: Ba–N/N–A
Lippold et al. ³²	2006	Clinical evaluation	Dental occlusion	Overjet: class I ‘normal overjet’ 1–3 mm, class II ‘increased overjet’ 4–10 mm, and class III ‘reversed overjet’ <1 mm
Lippold et al. ³¹	2006	Lateral radiographs	Cephalometric analysis	Facial axis: Ba–N/Pt–Gn Mandibular plane angle: P–Or/Me–hT Inner gonial angle: Xi–Spa/Xi–Pm Lower facial height: Xi–DC/Xi–Pm Facial depth: P–Or/N–Po Maxillary position: Ba–N/N–A
Sinko et al. ²⁹	2006	NA	Skeletal class Mandibular asymmetry	NA NA
Nobili and Adversi ²⁵	1996	Clinical evaluation	Dental occlusion	Angle class

A, A-point; ANB, A-point–nasion–B-point; Ba, basion; DC, condyle; Gn, gnathion; hT, horizontal mandibular tangential point; Me, menton; N, nasion; NA, information not available; Or, orbitale; P, porion; PA, postero-anterior; Po, pogonion; Pm, suprapogonion; Pt, foramen rotundum; Spa, anterior nasal spine; Xi, xilion.

class III MMDs before and after surgery; no information is provided in the article on the difference in body balance between the subjects before surgery³⁵. The results are displayed in Table 4.

Impact of orthognathic surgery on body posture and body balance

Four articles evaluated the impact of orthognathic surgery on body posture and balance^{27,29,33,35}; three of them concluded that there was an interaction. The results are found in Tables 3 and 4. Three articles studied the effect of surgery on body posture, while the other assessed the changes in body balance. Sinko et al. found no effect of surgery on posture²⁹,

while Kulczynski et al. demonstrated a significant posterior displacement of the trunk, providing realignment to an almost normal upright posture with correction of the cervical lordosis in skeletal class III patients³³. Head inclination and scoliosis had improved significantly at 1 year after surgery in patients with severe jaw asymmetry. Regarding body balance, stability was improved after orthognathic surgery as measured by spectral power density and centre of pressure velocity³⁵.

Discussion

The aim of this review was to systematically screen the available evidence and

level of evidence regarding the interaction between MMD and body posture and/or body balance in the available literature. Ten of the 13 articles included reported statistically significant correlations. Therefore, interactions between body posture and/or body sway and MMD are highly probable. Moreover, the improvement in body posture noted after orthognathic surgery in two of the studies also supports an interaction between body posture and/or body sway and MMD. However, a large heterogeneity within the studies was observed, regarding the population, body posture assessment methods, MMD evaluation methods, and body posture criteria.

Table 3. Interaction between body posture and maxillomandibular deformity.

Author	Number of patients	Type of MMD/ malocclusion	Number of patients in the control group	Nature of the control group	Postural evaluation method	Main finding
Iacob et al. ²³	10	Abnormal occlusion (class II or class III)	14	Angle class I	PostureScreen software	No significant difference between the two groups
Nakashima et al. ²⁷	45	Non-syndromic patients needing orthognathic surgery	45	Preoperative patients	Chest X-rays Photographs	In the vertebrae deviation group (over 10°), vertebrae deviation tended to decrease after surgery One patient with leftward mandibular deviation tended to incline the head in a cranially right and caudally left (counterclockwise) direction
Kulczynski et al. ³³	16	Class III patients who underwent orthognathic surgery	15	Class III patients not operated yet	Photogrammetry	Significant difference between preoperative and postoperative patients: correction of cervical lordosis Significant difference between preoperative and postoperative patients: greater pelvic anteversion in the control group
Kulczynski et al. ³⁴	40	Class III patients needing orthognathic surgery	NA	No control group, values compared to reference values	Photogrammetry	Decreased cervical lordosis Increased kyphosis Scapular horizontal asymmetry
Nakashima et al. ²⁸	79	Non-syndromic patients needing orthognathic surgery	NA	NA	Chest X-rays	Positive correlation between Cobb's angle and the degree of mandibular deviation in the group with an ANB angle <0
Zhou et al. ²⁶	35	Patients with skeletal mandibular deviation	10	Neutral occlusion, normal facial appearance	Full spine X-rays	Positive correlation between the degree of mandibular deviation and trunk balance Degree of scoliosis higher in the group with mandibular deviation
Lippold et al. ³⁰	53	Patients with class II and III malocclusion Cephalometric analysis	NA	NA	Rastereography	Pelvic torsion is correlated with some cephalometric parameters (the facial axis and the facial depth)
Lippold et al. ³²	84	Patients with class II and class III malocclusion	14	Normal overjet	Rastereography	No significant differences
Lippold et al. ³¹	53	Patients with class II and III malocclusion Cephalometric analysis	NA	NA	Rastereography	Lordotic angle is correlated with some cephalometric parameters (facial axis, inner gonial angle, and mandibular plane angle) Pelvic inclination is correlated with some cephalometric parameters (facial axis, inner gonial angle, mandibular plane angle, and facial depth)
Sinko et al. ²⁹	29	Patients needing orthognathic surgery	12	Normal occlusion and no MMD	Rastereography	The apex of lumbar lordosis was more caudal in class II than in healthy controls The lumbar lordosis angle is more pronounced in class III patients compared to controls The tilt of the iliac crest in patients with class II and III differed minimally but significantly from that of healthy controls

ANB, A-point–nasion–B-point; MMD, maxillomandibular deformity; NA, not applicable.

Table 4. Interaction between body balance and maxillomandibular deformity.

Author	Number of patients	Type of MMD/ malocclusion	Number of patients in the control group	Nature of the control group	Postural evaluation method	Main finding
Paya-Argoud et al. ³⁵	22	Orthognathic surgery was needed to treat dysmorphic jaws in sagittal deformity (class II ($n = 10$), class III ($n = 10$)) or vertical deformity ($n = 2$)	22	Preoperative patients	Photographs Force platform	Surgery significantly improved head orientation when patients were tested in eyes closed and in occlusion condition Surgery had a larger impact on the velocity of the centre of pressure in the resting position condition Spectral power density was significantly decreased after orthognathic surgery
Scharnweber et al. ²⁴	87	Male patients without medical history	NA	Comparison of subgroups according to angle class, overjet or crossbite	Force platform	No statistical difference
Nobili and Adversi ²⁵	50	Patients without medical history	NA	Comparison of subgroups according to Angle class	Force platform	Class II patients have a more anterior displaced posture, class III patients a more posterior displaced posture

MMD, maxillomandibular deformity; NA, not applicable.

Definition of maxillomandibular deformity

In the studies included in this review, there was a lack of consistency in the characterization of MMDs. Numerous classifications are available in the literature, based on various clinical criteria and/or cephalometric analyses and using different cut-offs (the cephalometric analysis of Delaire et al.³⁶, the analysis of Tweed³⁷, and the cephalometric analysis of Sassouni et al.³⁸). Clinical studies evaluating patients with a class I occlusion, as well as studies assessing only the effect of various mandibular positions, were excluded from this review, because they are not representative of MMDs. Four studies included in the review characterized MMD based on dental occlusion only, and four did not specify the method that was used. Finally, only five studies had a high-quality description of the MMD, based on the position and description of the maxillomandibular complex using X-rays (either lateral or postero-anterior cephalograms).

MMD is a very common condition and not all patients presenting with a MMD will request medical attention. Moreover, a wide variety of parameters are used to describe MMDs. It can be challenging to set up control groups meeting the normality criteria for all facial parameters to

compare with an MMD cohort. Only seven studies compared patients with MMDs to a control group.

Definition of postural dysfunction

Postural dysfunction is defined as the inability to maintain, achieve, or restore a state of balance in any posture or during any activity. The neutral body posture is the posture the human body naturally assumes in microgravity³⁹. The investigation of body posture implies the evaluation of the entire vertebral column and of the pelvis. Body balance is a dynamic process associated with maintenance of a specific posture, voluntary movement, and reaction to an external disturbance. It is related to the ability of the human not to fall⁴. Body posture and body balance are connected. To maintain body balance, the projection of the centre of gravity should stay within the base of support. If the body posture is altered, the position of the centre of gravity changes and body balance is modified.

Regarding the evaluation of MMDs, the methods used to assess body posture and/or balance in the current literature review were inconsistent. Six different evaluation methods were used in the 13 articles retrieved: five methods to assess body posture

(photogrammetry, rastereography, chest X-ray, full spine X-ray, and PostureScreen app) and one to evaluate body balance (force platform). Rastereography was the most used evaluation method (four articles). However, the criteria differed in most studies (only two studies evaluated body posture using the same rastereography criteria).

Even though the results appear to support the interaction between body posture and/or body balance and MMD, method inconsistency limits the conclusions. Indeed, the studies included in this review characterized body posture through the assessment of various segments of the spine: two articles reported significant results regarding the cervical spine, three articles regarding the thoracic column, and four articles regarding the lumbar spine and pelvis. To summarize, even if an interaction is highly probable, there is not enough information in the international literature to connect one type of spine pattern with one specific MMD.

Two articles evaluated the interaction of MMD and body sway, with contradictory results: one concluded that there was an interaction²⁵, while the other showed no difference²⁴. In the literature, force platforms are mostly used to evaluate the impact of changing occlusal positions or

occlusal interferences on body balance^{40,41}. Given this very small number of studies, it is impossible to draw any conclusions regarding the suspected impact of MMD on body sway.

Mechanisms of postural dysfunction associated with MMD

Most of the articles retrieved for this review support an interaction between postural dysfunction and MMD. However, nine of the 13 articles did not formulate any hypothesis to explain this interaction.

As suggested by Nakashima et al.²⁷ and Paya-Argoud et al.,³⁵ one hypothesis to explain this interaction is neurophysiological. The mandibular position is believed to be involved in antigravity muscle activity and posture control. Indeed, Wakano et al.⁴² investigated the impact of mandibular deviation on dynamic body balance. They observed that horizontal mandible deviation interfered with upright posture stability on an unstable platform. This suggested that the stomatognathic system affects dynamic balance⁴². Kulczynski et al.³³ considered a neuromuscular hypothesis. The authors suggested that, in patients with skeletal class III, cervical muscles inserted on the mandible are stretched, resulting in increased cervical lordosis. Finally, for Sinko et al.²⁹, subjects presented head forward postures related to mouth breathing, but the authors did not provide details on the mechanism involved.

In our opinion, mouth breathing also seems to play an important part in the interaction between body posture and MMDs. Indeed, numerous articles have demonstrated the impact of mouth breathing on cervical and head postures: mouth breathing is responsible for head forward posture and cervical extension^{43,44}. Mouth breathing is frequent in children with MMD. It requires early orthodontic treatment⁴⁴. If untreated, mouth breathing continues into adulthood⁴⁵. Cervical hyperextension is an adaptive mechanism that increases upper airway volume¹⁸ and facilitates ventilation¹⁹. Moreover, cervical flexion increases the risk of upper airway collapse, while cervical extension increases upper airway stability⁴⁶. This altered posture is also found in patients with anatomical or physiological dysfunctions of the upper airway, such as obstructive sleep apnoea (OSA)⁴⁷. In patients with OSA, the interaction between postural function and ventilation is under cortical control⁴⁷.

If mouth breathing alters cervical and head posture, it also most likely impacts the entire spine. Indeed, the amount of energy required to maintain an upright posture (head aligned with the pelvis) should be as low as possible. Some compensating mechanisms may be activated to maintain the vertical head–pelvis alignment. Cervical hyperextension is compensated by a thoracic kyphosis increase in patients with OSA⁴⁷. Patients with MMD also present altered cervical spine curvatures⁴⁸. Some articles in the current review showed modifications in spine curvature that might amount to compensation mechanisms. Indeed, according to Lippold et al.³¹, pelvic inclination and lordotic angle were correlated with cephalometric parameters. The angle of lumbar lordosis in class III patients also differed significantly from that of class I patients in the study of Sinko et al.²⁹. Moreover, abnormal thoracic curvature (increased thoracic kyphosis) was found in the clinical trial of Kulczynski et al.³⁴ All of these results support the existence of compensating mechanisms in patients with MMD in order to maintain the head–pelvis alignment.

MMDs and altered body posture might have a common origin: altered ventilation. Indeed, MMDs develop during growth as a consequence of several dysfunctions, particularly mouth breathing. MMDs and altered body posture appear to be the two ends of the spectrum of the same adaptive mechanism in response to mouth breathing.

Effect of surgery

Orthognathic surgery aims to correct MMD. In the literature, four articles evaluated the impact of surgery on body posture. The results of three studies showed a correction of postural dysfunction, while the remaining study found no postural adaptation after the surgery.

Orthognathic surgery not only restores facial balance, but also aims to correct such dysfunctions as temporomandibular dysfunction and mouth breathing. The seemingly favourable effect of the surgery on postural dysfunction is an additional argument in favour of the participation of mouth breathing in the development of a postural dysfunction.

In conclusion, despite a low level of evidence, the interaction between body posture and MMD is probable. The positive impact of orthognathic surgery on body posture is an additional argument. More clinical trials are required to conclude with certainty on this interaction and to understand the mechanisms involved.

Funding

Fédération Française d'Orthodontie.

Competing Interests

VA reports personal fees from ADEP Assistance, Resmed, SIRIUS-CUSTOMIZER, outside the submitted work. AK, DD, TS and PR report no conflict of interest.

Ethical Approval

Not relevant.

Patient Consent

Not relevant.

Author contribution form

Appendix A. Supplementary data

Supplementary material related to this article can be found, in the online version, at doi:<https://doi.org/10.1016/j.ijom.2021.05.003>.

References

1. D'Onofrio L. Oral dysfunction as a cause of malocclusion. *Orthod Craniofac Res* 2019;**22**(Suppl 1):43–8. <http://dx.doi.org/10.1111/ocr.12277>.
2. Burgersdijk R, Truin GJ, Frankenmolen F, Kalsbeek H, van't Hof M, Mulder J. Malocclusion and orthodontic treatment need of 15–74-year-old Dutch adults. *Community Dent Oral Epidemiol* 1991;**19**:64–7. <http://dx.doi.org/10.1111/j.1600-0528.1991.tb00111.x>.
3. Proffit WR, Fields HW, Moray LJ. Prevalence of malocclusion and orthodontic treatment need in the United States: estimates from the NHANES III survey. *Int J Adult Orthodon Orthognath Surg* 1998;**13**:97–106.
4. Pollock AS, Durward BR, Rowe PJ, Paul JP. What is balance? *Clin Rehabil* 2000;**14**:402–6. <http://dx.doi.org/10.1191/0269215500cr342oa>.
5. Manns RA, Haddaway MJ, McCall IW, Cassar Pullicino V, Davie MW. The relative contribution of disc and vertebral morphology to the angle of kyphosis in asymptomatic subjects. *Clin Radiol* 1996;**51**:258–62. [http://dx.doi.org/10.1016/s0009-9260\(96\)80342-4](http://dx.doi.org/10.1016/s0009-9260(96)80342-4).
6. Korovessis P, Stamatakis M, Baikousis A. Segmental roentgenographic analysis of vertebral inclination on sagittal plane in asymptomatic versus chronic low back pain patients. *J Spinal Disord* 1999;**12**:131–7.

7. Kado DM, Huang MH, Nguyen CB, Barrett-Connor E, Greendale GA. Hyperkyphotic posture and risk of injurious falls in older persons: the Rancho Bernardo Study. *J Gerontol A Biol Sci Med Sci* 2007;**62**:652–7. <http://dx.doi.org/10.1093/gerona/62.6.652>.
8. Amabile C, Le Huec JC, Skalli W. Invariance of head–pelvis alignment and compensatory mechanisms for asymptomatic adults older than 49 years. *Eur Spine J* 2018;**27**:458–66. <http://dx.doi.org/10.1007/s00586-016-4830-8>.
9. Le Huec JC, Charosky S, Barrey C, Rigal J, Aunoble S. Sagittal imbalance cascade for simple degenerative spine and consequences: algorithm of decision for appropriate treatment. *Eur Spine J* 2011;**20**(Suppl 5):699–703. <http://dx.doi.org/10.1007/s00586-011-1938-8>.
10. Sinaki M, Brey RH, Hughes CA, Larson DR, Kaufman KR. Balance disorder and increased risk of falls in osteoporosis and kyphosis: significance of kyphotic posture and muscle strength. *Osteoporos Int* 2005;**16**:1004–10. <http://dx.doi.org/10.1007/s00198-004-1791-2>.
11. Mustapa A, Justine M, Mohd Mustafah N, Jamil N, Manaf H. Postural control and gait performance in the diabetic peripheral neuropathy: a systematic review. *Biomed Res Int* 2016;**2016**:9305025. <http://dx.doi.org/10.1155/2016/9305025>.
12. Schindlbeck KA, Naumann W, Maier A, Ehlen F, Marzinzik F, Klostermann F. Disturbance of verticality perception and postural dysfunction in Parkinson's disease. *Acta Neurol Scand* 2018;**137**:212–7. <http://dx.doi.org/10.1111/ane.12859>.
13. Verheyden G, Ruesen C, Gorissen M, Brumby V, Moran R, Burnett M, Ashburn A. Postural alignment is altered in people with chronic stroke and related to motor and functional performance. *J Neurol Phys Ther* 2014;**38**:239–45. <http://dx.doi.org/10.1097/NPT.0000000000000054>.
14. Saccucci M, Tettamanti L, Mummolo S, Polimeni A, Festa F, Tecco S. Scoliosis and dental occlusion: a review of the literature. *Scoliosis* 2011;**6**:15. <http://dx.doi.org/10.1186/1748-7161-6-15>.
15. D'Attilio M, Caputi S, Epifania E, Festa F, Tecco S. Evaluation of cervical posture of children in skeletal class I, II, and III. *Cranio* 2005;**23**:219–28. <http://dx.doi.org/10.1179/crn.2005.031>.
16. Smailienė D, Intienė A, Dobradziejutė I, Kuleika G. Effect of treatment with twin-block appliances on body posture in class II malocclusion subjects: a prospective clinical study. *Med Sci Monit* 2017;**23**:343–52. <http://dx.doi.org/10.12659/msm.899088>.
17. Solow B, Siersbaek-Nielsen S. Cervical and craniocervical posture as predictors of craniofacial growth. *Am J Orthod Dentofacial Orthop* 1992;**101**:449–58. [http://dx.doi.org/10.1016/0889-5406\(92\)70119-U](http://dx.doi.org/10.1016/0889-5406(92)70119-U).
18. Solow B, Skov S, Ovesen J, Norup PW, Wildschjødtz G. Airway dimensions and head posture in obstructive sleep apnoea. *Eur J Orthod* 1996;**18**:571–9. <http://dx.doi.org/10.1093/ejo/18.6.571>.
19. Wei W, Huang SW, Chen LH, Qi Y, Qiu YM, Li ST. Airflow behavior changes in upper airway caused by different head and neck positions: comparison by computational fluid dynamics. *J Biomech* 2017;**52**:89–94. <http://dx.doi.org/10.1016/j.jbiomech.2016.12.032>.
20. Hasegawa K, Okamoto M, Hatsushikano S, Shimoda H, Ono M, Homma T, Watanabe K. Standing sagittal alignment of the whole axial skeleton with reference to the gravity line in humans. *J Anat* 2017;**230**:619–30. <http://dx.doi.org/10.1111/joa.12586>.
21. Hutton B, Salanti G, Caldwell DM, Chaimani A, Schmid CH, Cameron C, Ioannidis JPA, Straus S, Thorlund K, Jansen JP, Mulrow C, Catalá-López F, Gøtzsche PC, Dickersin K, Boutron I, Altman DG, Moher D. The PRISMA extension statement for reporting of systematic reviews incorporating network meta-analyses of health care interventions: checklist and explanations. *Ann Intern Med* 2015;**162**:777–84. <http://dx.doi.org/10.7326/M14-2385>.
22. Whiting PF, Rutjes AWS, Westwood ME, Mallett S, Deeks JJ, Reitsma JB, Leeflang MMG, Sterne JAC, Bossuyt PMM. QUADAS-2: a revised tool for the quality assessment of diagnostic accuracy studies. *Ann Intern Med* 2011;**155**:529–36. <http://dx.doi.org/10.7326/0003-4819-155-8-201110180-00009>.
23. Iacob SM, Chisnoiu AM, Lascu LM, Berar AM, Studnicska D, Fluerașu MI. Is PostureScreen Mobile app an accurate tool for dentists to evaluate the correlation between malocclusion and posture? *Cranio* 2020;**38**:233–9. <http://dx.doi.org/10.1080/08869634.2018.1512197>.
24. Scharnweber B, Adjami F, Schuster G, Kopp S, Natrup J, Erbe C, Ohlendorf D. Influence of dental occlusion on postural control and plantar pressure distribution. *Cranio* 2017;**35**:358–66. <http://dx.doi.org/10.1080/08869634.2016.1244971>.
25. Nobili A, Adversi R. Relationship between posture and occlusion: a clinical and experimental investigation. *Cranio* 1996;**14**:274–85. <http://dx.doi.org/10.1080/08869634.1996.11745978.i>.
26. Zhou S, Yan J, Da H, Yang Y, Wang N, Wang W, Ding Y, Sun S. A correlational study of scoliosis and trunk balance in adult patients with mandibular deviation. *PLoS One* 2013;**8**:e59929. <http://dx.doi.org/10.1371/journal.pone.0059929>.
27. Nakashima A, Yamada T, Nakano H, Sugiyama G, Sugi T, Kamata YU, Sumida T, Mori Y. Jaw asymmetry may cause bad posture of the head and the spine—a preliminary study. *J Oral Maxillofac Surg Med Pathol* 2018;**30**:242–6. <http://dx.doi.org/10.1016/j.ajoms.2018.01.001>.
28. Nakashima A, Nakano H, Yamada T, Inoue K, Sugiyama G, Kumamaru W, Nakajima Y, Sumida T, Yokoyama T, Mishima K, Mori Y. The relationship between lateral displacement of the mandible and scoliosis. *Oral Maxillofac Surg* 2016;**21**:59–63. <http://dx.doi.org/10.1007/s10006-016-0607-9>.
29. Sinko K, Grohs JG, Millesi-Schobel G, Watzinger F, Turhani D, Undt G, Baumann A. Dysgnathia, orthognathic surgery and spinal posture. *Int J Oral Maxillofac Surg* 2006;**35**:312–7. <http://dx.doi.org/10.1016/j.ijom.2005.09.009>.
30. Lippold C, Danesh G, Hoppe G, Drerup B, Hackenberg L. Trunk inclination, pelvic tilt and pelvic rotation in relation to the craniofacial morphology in adults. *Angle Orthod* 2007;**77**:29–35. <http://dx.doi.org/10.2319/121205-434R.1>.
31. Lippold C, Danesh G, Schilgen M, Drerup B, Hackenberg L. Relationship between thoracic, lordotic, and pelvic inclination and craniofacial morphology in adults. *Angle Orthod* 2006;**76**:779–85. [http://dx.doi.org/10.1043/0003-3219\(2006\)076\[0779:RBTLAP\]2.0.CO;2](http://dx.doi.org/10.1043/0003-3219(2006)076[0779:RBTLAP]2.0.CO;2).
32. Lippold C, Danesh G, Schilgen M, Drerup B, Hackenberg L. Sagittal jaw position in relation to body posture in adult humans—a rasterstereographic study. *BMC Musculoskeletal Disorders* 2006;**7**:8. <http://dx.doi.org/10.1186/1471-2474-7-8>.
33. Kulczynski FZ, de Oliveira Andriola F, Deon PH, da Silva Melo DA, Pagnoncelli RM. Postural assessment in class III patients before and after orthognathic surgery. *Oral Maxillofac Surg* 2018;**22**:143–50. <http://dx.doi.org/10.1007/s10006-018-0681-2>.
34. Kulczynski FZ, Andriola FO, Deon PH, DADS Melo, Pagnoncelli RM. Postural assessment in class III patients before orthognathic surgery. *J Oral Maxillofac Surg* 2018;**76**:426–35. <http://dx.doi.org/10.1016/j.joms.2017.07.157>.
35. Paya-Argoud M, Tardieu C, Cheynet F, Raskin A, Borel L. Impact of orthognathic surgery on the body posture. *Gait Posture* 2019;**67**:25–30. <http://dx.doi.org/10.1016/j.gaitpost.2018.09.019>.
36. Delaire J, Schendel SA, Tulasne JF. An architectural and structural craniofacial analysis: a new lateral cephalometric analysis. *Oral Surg Oral Med Oral Pathol* 1981;**52**:226–38. [http://dx.doi.org/10.1016/0030-4220\(81\)90252-8](http://dx.doi.org/10.1016/0030-4220(81)90252-8).
37. Tweed CH. The Frankfort–mandibular plane angle in orthodontic diagnosis, classification, treatment planning, and prognosis. *Am J Orthod Oral Surg* 1946;**32**:175–230. [http://dx.doi.org/10.1016/0096-6347\(46\)90001-4](http://dx.doi.org/10.1016/0096-6347(46)90001-4).
38. Sassouni V. A roentgenographic cephalometric analysis of cephalo-facio-dental relationships. *Am J Orthod* 1955;**41**:735–64. [http://dx.doi.org/10.1016/0002-9416\(55\)90171-8](http://dx.doi.org/10.1016/0002-9416(55)90171-8).

39. Kilbom Å., Repetitive work of the upper extremity: Part II—the scientific basis (knowledge base) for the guide. Mital A, Kilbom Å, Kumar S, editors. *Elsevier Ergonomics Book Series*, Vol. 1. Elsevier; 2000. p. 151–78.
40. Ferrario VF, Sforza C, Schmitz JH, Taroni A. Occlusion and center of foot pressure variation: is there a relationship? *J Prosthet Dent* 1996;**76**:302–8. [http://dx.doi.org/10.1016/S0022-3913\(96\)90176-6](http://dx.doi.org/10.1016/S0022-3913(96)90176-6).
41. Marini I, Gatto MR, Bartolucci ML, Bortolotti F, Alessandri Bonetti G, Michelotti A. Effects of experimental occlusal interference on body posture: an optoelectronic stereophotogrammetric analysis. *J Oral Rehabil* 2013;**40**:509–18. <http://dx.doi.org/10.1111/joor.12064>.
42. Wakano S, Takeda T, Nakajima K, Kurokawa K, Ishigami K. Effect of experimental horizontal mandibular deviation on dynamic balance. *J Prosthodont Res* 2011;**55**:228–33. <http://dx.doi.org/10.1016/j.jpor.2011.03.001>.
43. Huggare JA, Laine-Alava MT. Nasorespiratory function and head posture. *Am J Orthod Dentofacial Orthop* 1997;**112**:507–11. [http://dx.doi.org/10.1016/S0889-5406\(97\)70078-7](http://dx.doi.org/10.1016/S0889-5406(97)70078-7).
44. Lee SY, Guilleminault C, Chiu HY, Sullivan SS. Mouth breathing, “nasal disuse,” and pediatric sleep-disordered breathing. *Sleep Breath* 2015;**19**:1257–64. <http://dx.doi.org/10.1007/s11325-015-1154-6>.
45. Milanesi JM, Borin G, Corrêa ECR, da Silva AMT, Bortoluzzi DC, Souza JA. Impact of the mouth breathing occurred during childhood in the adult age: biophotogrammetric postural analysis. *Int J Pediatr Otorhinolaryngol* 2011;**75**:999–1004. <http://dx.doi.org/10.1016/j.ijporl.2011.04.018>.
46. Verin E, Sériès F, Locher C, Straus C, Zelter M, Derenne JP, Similowski T. Effects of neck flexion and mouth opening on inspiratory flow dynamics in awake humans. *J Appl Physiol* 2002;**92**:84–92. <http://dx.doi.org/10.1152/jappl.2002.92.1.84>.
47. Clavel L, Rémy-Neris S, Skalli W, Rouch P, Lespert Y, Similowski T, Sandoz B, Attali V. Cervical spine hyperextension and altered posturo-respiratory coupling in patients with obstructive sleep apnea syndrome. *Front Med (Lausanne)* 2020;**7**:30. <http://dx.doi.org/10.3389/fmed.2020.00030>.
48. Andriola FO, Kulczynski FZ, Deon PH, DADS Melo, Zanettini LMS, Pagnoncelli RM. Changes in cervical lordosis after orthognathic surgery in skeletal class III patients. *J Craniofac Surg* 2018;**29**:e598–603. <http://dx.doi.org/10.1097/scs.0000000000004644>.