



**HAL**  
open science

## Craniosynostosis and oculomotor disorders

F. Dalmas, G. Pech-Gourg, A. Gallucci, D. Denis, D. Scavarda

► **To cite this version:**

F. Dalmas, G. Pech-Gourg, A. Gallucci, D. Denis, D. Scavarda. Craniosynostosis and oculomotor disorders. *Neurochirurgie*, 2020, 66 (2), pp.91-96. 10.1016/j.neuchi.2019.10.010 . hal-03578024

**HAL Id: hal-03578024**

**<https://hal.science/hal-03578024v1>**

Submitted on 29 Nov 2024

**HAL** is a multi-disciplinary open access archive for the deposit and dissemination of scientific research documents, whether they are published or not. The documents may come from teaching and research institutions in France or abroad, or from public or private research centers.

L'archive ouverte pluridisciplinaire **HAL**, est destinée au dépôt et à la diffusion de documents scientifiques de niveau recherche, publiés ou non, émanant des établissements d'enseignement et de recherche français ou étrangers, des laboratoires publics ou privés.



Distributed under a Creative Commons Attribution - NonCommercial 4.0 International License

Craniosynostosis and oculomotor disorders.

F. Dalmás<sup>a</sup>, G. Pech-Gourg<sup>b</sup>, A. Gallucci<sup>c</sup>, D. Denis<sup>a</sup>, D. Scavarda<sup>b</sup>

<sup>a</sup> Department of Ophthalmology, Marseille University Hospital, Marseille, France

<sup>b</sup> Department of Pediatric Neurosurgery, Marseille University Hospital, Marseille, France

<sup>c</sup> Department of Maxillofacial Surgery, Marseille University Hospital, Marseille, France

# CRANIOSYNOSTOSIS AND OCULOMOTOR DISORDERS

## Introduction

Craniosynostosis is a cranial malformation due to premature synostosis of one or more cranial sutures.

It may be simple, due to closure of a single suture, or complex, due to closure of several sutures. It may be associated with facial growth abnormalities, in facio-craniosynostosis. This bone deformity, present at birth, generates skull-brain impingement and complications.

Ophthalmologic complications occur in craniosynostosis, either by direct involvement of the optic nerve or eyeball or indirectly due to raised intracranial pressure [1].

Amblyopia is a public health issue because it leads to definitive loss of vision if treatment is not early and appropriate.

The most frequent ophthalmological complications are oculomotor disorders [1,2], showing prevalence higher than in the general population (4%) [3].

## 1 Clinical diagnosis

### 1.1 Sensorimotor evaluation

#### 1.1.1 Sensorial evaluation

##### - Visual acuity

Physiological visual development in humans continues up to the age of 10-12 years, with extreme vulnerability between 9-12 months of age. Thus, visual acuity does not reach 10/10 before the age of 5-6 years and remains fragile until the age of 10-12 years, requiring monitoring until this age, especially in children with craniosynostosis.

Visual acuity in newborns can only be assessed in terms of visual behavior, fixation, and screening for amblyopia risk factors (refractive error, strabismus).

In older children, visual acuity is assessed on visual acuity scales highlighting and quantifying any amblyopia.

##### - Refraction measurements

Refraction is measured by an automatic refractometer after administration of cycloplegic eye-drops, to highlight amblyogenic refractive anomalies such as astigmatism [4] or anisometropia. Any significant refractive error should be totally corrected from the age of 9 months [5] because of the risk of amblyopia.

The examination must be repeated several times until 10 years of age.

##### - Stereoscopic vision measurement

Stereoscopic vision can be evaluated from the age of 6 months. Various tests such as the Lang test can be used in consultation.

#### 1.1.2 Motor evaluation

This is an important step of the examination because many oculomotor disorders are associated with craniofacial malformations. This evaluation can be performed in newborns.

### **- Torticollis**

Torticollis must be screened for and assessed, because some oculomotor disorders are responsible for permanent torticollis [6].

### **- Oculomotor deviation**

Assessment is made in primary position by the Hirschberg test (corneal reflection), cover test and synoptophore, screening for A or V pattern syndrome. Conjugate eye movement is assessed in all positions of gaze.

The affected eye can be highlighted by this examination, and it is not necessarily on the side of the synostosis [7].

## **1.2 Biomicroscopic examination of the eyeball**

The anterior and posterior segment of each eye should be carefully examined for corneal involvement or papillary pathology of (atrophy, edema).

## **2 Complementary examinations**

Complementary examinations may be carried out to specify or screen for associated pathology.

### **2.1 Fundus photography and anthropometric photography**

Photos allow accurate follow-up by comparative check. Their interest is all the greater as follow-up must be continued until the age of 10 years (fig. 1).

### **2.2 Optical Coherence Tomography (OCT)**

OCT allows measurement of the thickness of the optical fibers and detection of early papilledema or optical atrophy, enabling follow-up of progression thanks to precise comparison of measurements over time.

### **2.3 Fluorescein Angiography**

Fluorescein angiography may be indicated if there is a doubt about papilledema.

Nevertheless, it may be difficult to perform, because of the young age of the child, as it requires cooperation for fixation.

### **2.4 Ocular ultrasonography**

This examination can complete preoperative cerebral imaging, analyzing the various ocular and intra-orbital structures. It can detect muscle abnormalities as excessive thinness or thickness, scar condition and abnormal scleral insertion. Ultrasonography can also guide oculomotor surgery in complex cases.

### **2.5 Cerebral imaging**

Cerebral imaging is systematic in preoperative work-up for craniofacial surgery, studying the various oculomotor axes, their positions in the orbit, insertions and anatomical aspects.

## 3 Oculomotor disorders

Craniosynostosis is frequently associated with oculomotor disorders of orbital or muscular origin. These can also be induced by craniofacial surgery [1]. Therefore, ophthalmic follow-up must be maintained throughout childhood, even in case of normal initial examination.

### 3.1 Horizontal deviation: exotropia and esotropia with or without V-pattern syndrome

#### 3.1.1 Exotropia

Exotropia is a form of strabismus where the eyes are in divergence: it is frequently associated with V-pattern syndrome. It is often found in Crouzon's syndrome [8] and hypertelorism.

#### 3.1.2 Esotropia

Esotropia is a form of strabismus where the eyes are in convergence.

#### 3.1.3 V-pattern syndrome

V-pattern syndrome is a type of strabismus found in the vertical gaze secondary to orbital torsion (extorsion or intorsion) (fig. 2).

**V- pattern with esotropia:** the convergent deviation is greater looking downward than upward.

**V-pattern with exotropia:** the divergent deviation is greater looking upward than directly downward

V pattern syndrome is often found in craniosynostosis [9]. Surgical correction is difficult because it is secondary to deformity of the orbit (torsion), often associated with abnormal oculomotor insertion.

### 3.2 Vertical strabismus: Hypotropia and hypertropia

#### 3.2.1 Hypotropia and Hypertropia

Vertical strabismus is called hypotropia if the eye is deflected downward and hypertropia if upward. Hypertropia is frequently found in anterior plagiocephaly, associated with pseudo-palsy of the superior oblique muscle.

#### 3.2.2 Pseudo-palsy of the superior oblique muscle

Hypofunction of the superior oblique muscle associated with overaction of the inferior oblique muscle characterizes pseudo-palsy of the superior oblique muscle.

In craniosynostosis, it is due to frontozygomatic deformity inducing traction on the muscles and orbital fasciae. There are different degrees of severity, making diagnosis more or less straightforward. It is therefore systematically screened for to prevent or treat amblyopia (6) (fig. 3).

## 4 Craniosynostosis

In simple craniosynostosis, anterior plagiocephaly is the most important source of oculomotor disorder because of its asymmetrical aspect. Other forms of simple craniosynostosis are more often associated with ophthalmologic pathologies such as astigmatism, anisometropia, papilledema or atrophy of the optic nerve.

Syndromic craniosynostosis is also frequently associated with ophthalmologic pathologies.

## 4.1 Simple craniosynostosis

### 4.1.1 Anterior plagiocephaly

Anterior plagiocephaly is frequently associated with strabismus, which can be present before the operation or appear during the postoperative period [1].

Pseudo-palsy of the superior oblique muscle is frequent. The typical picture encountered in severe anterior plagiocephaly [7], or in case of delayed treatment, includes hypofunction of the superior oblique muscle, overaction of the inferior oblique muscle and overaction of the contralateral inferior rectus muscle (figs 4 and 5).

Oblique muscle dysfunction induces laterocollis. Poor management leads to persistence or aggravation of the facial scoliosis during follow-up. Ophthalmological management thus conditions the craniofacial results.

### 4.1.2 Trigenocephaly

Trigenocephaly is less likely to cause oculomotor disorder, because of the symmetrical nature of the deformity. Studies reported 7-15% prevalence [10] [11] of strabismus in children with metopic suture synostosis. This prevalence is lower than in anterior plagiocephaly or complex craniosynostosis but higher than in the general population (4%)[3].

Moreover, hypotelorism and epicanthus often give an impression of convergent strabismus. Oculomotor examination, and in particular study of corneal reflection, confirms absence or presence of strabismus.

This pathology is frequently associated with astigmatism [11] because of the traction exerted by the lateral orbital wall on the eyeball via the oculomotor muscle and orbital fascia.

### 4.1.3 Scaphocephaly

Scaphocephaly is less likely to cause oculomotor disorders than trigonocephaly and anterior plagiocephaly [12]. On the other hand, it is a major source of visual attention disorder, highlighted by the "fixation shift" test, evaluating the direction and latency of saccadic eye movements in response to peripheral visual targets in the lateral field. The high rate of abnormal refixation in infants with scaphocephaly (11 out of 15 infants with scaphocephaly [12]) could be partly explained by the fact that the neurophysiological mechanisms underlying the shift in visual attention are related to parietal lobe function.

However, the main ophthalmological complication to be screened for is papillary edema or papillary atrophy secondary to primary or secondary intracranial pressure elevation [13,14].

### 4.1.4 Brachycephaly

Brachycephaly can be associated with ophthalmological disorders such as pseudo-exorbitis or oculomotor disorders, most frequently exotropia [15].

### 4.1.5 Other simple and complex forms of craniosynostosis

Involvement of one or two coronal sutures leads to oculomotor disorders approximating those found in anterior plagiocephaly and brachycephaly respectively. The main ophthalmological issue in complex craniosynostosis concerns the consequences of raised intracranial pressure.

## 4.2 Syndromic craniosynostosis

The prevalence of strabismus is also very high in syndromic craniosynostosis, and particularly in Crouzon's syndrome. Oculomotor disorders are also found in Pfeiffer's and Apert's syndrome. Other syndromic forms of craniosynostosis do not entail specific or systematic oculomotor disorders.

All syndromic craniosynostoses expose children to ophthalmologic complications, such as increased intracranial pressure [16], papillary edema or atrophic papilla [17].

### 4.2.1 Crouzon's syndrome

In Crouzon's syndrome, strabismus is most often divergent with a V-pattern of orbital extorsion [18], more prominent at the frontal than the maxillary level. The result is a deformation of the musculo-fascial cone outside, with excyclorotation of the eyeball. The action of the rectus muscles is modified, muscle traction becoming oblique because the lateral rectus muscle is attached lower on the sclera than the medial rectus muscle. This extorsion also induces a V-pattern syndrome. When severe hypertelorism is associated, divergent strabismus is frequently present. Other ophthalmological complications are usually found: proptosis, eyeball subluxation, keratitis, and/or papilledema.

### 4.2.2 Pfeiffer's syndrome

Pfeiffer's syndrome shows a high rate of eye complications: oculomotor disorders, proptosis, or refractive errors. Amblyopia and exposure keratitis are secondary complications to be feared and are relatively frequent. One study analyzed a series of 22 patients, finding 55% strabismus and 59% refractive errors [19]. Severe proptosis, excyclotorted eyeball, and strabismus with overelevation in adduction can be present [20]. Multidisciplinary management with an ophthalmology team is essential to manage these ophthalmic manifestations and reduce the prevalence of amblyopia.

### 4.2.3 Apert's syndrome

The ophthalmologic complications rate in Apert's syndrome prior to craniofacial surgery is high [21]: 14% amblyopia, 60% strabismus, 13% exposure keratitis and corneal scarring, 8% optic atrophy. Another study showed that the ophthalmic complication rate remained high even after craniofacial surgery [22]. The hypertelorism associated with Apert's syndrome accounts for the high rate of exotropia [23,24].

Children with Apert's syndrome are at risk of ophthalmological complications and require close follow-up.

### 4.2.4 Other syndromic forms of craniosynostosis

There are no specific oculomotor disorders systematically associated with the other syndromic forms of craniosynostosis.

Polymalformative syndromes may include ocular abnormalities (congenital glaucoma, dysgenesis of the anterior segment, blue sclerae, etc.) and non-specific oculomotor disorders which are the consequence of the syndrome and not of orbital anatomical particularities related to the sutures involved [25–27].

However, many ophthalmologic complications can occur, such as increased intracranial pressure, papillary edema, optic atrophy [16] or visual field loss [17].

## 5 Ophthalmological management

### 5.1 Preventive and curative treatment of amblyopia

Preventive and curative treatment of amblyopia is essential. It must be started without delay when necessary. As soon as an oculomotor disorder is revealed on ophthalmological examination, or when a refractive error is present (severe myopia, severe hyperopia, severe astigmatism, or anisometropia). Ophthalmological prognosis warrants systematic early ophthalmological consultation as soon as simple, complex or syndromic craniosynostosis is diagnosed.

Treatment consists mainly in total optical correction and ocular occlusion. When a patient is at risk of amblyopia, surveillance should be continued after craniofacial surgery and repeated at least once a year until 6 years, even when examination is normal.

### 5.2 Oculomotor surgery

Oculomotor treatment is implemented around the age of 4-6 years, after obtaining isoacuity. It essentially consists in resection, plication, and recession of the various muscles, to restore satisfactory oculomotor balance.

Pseudo-palsy of the superior oblique muscle and V- or A-pattern syndrome are difficult to treat and often require reintervention. They can be treated by weakening the inferior oblique [28,29] or strengthening the superior oblique muscle [30–32], horizontal rectus muscle surgery [33] or a combination of these procedures, depending on the oculomotor evaluation.

The trickiest forms of craniosynostosis are anterior plagiocephaly and syndromic craniosynostosis [18], because different types of strabismus can be associated.

### 5.3 Follow-up

Follow-up is continued until the end of growth of skull and orbits, with close follow-up to avoid any recurrence. Treatment of amblyopia by occlusion can be continued if necessary until this age. Optical correction is maintained as needed.

Reintervention on the oculomotor muscles is not uncommon.

## CONCLUSION

Preoperative and postoperative ophthalmological follow-up is essential. This must be maintained throughout the child's growth, in close collaboration between the craniofacial team and ophthalmologist.

The quality of oculomotor management conditions craniofacial growth, and vice-versa.

The craniofacial team should work in collaboration with a specialized pediatric ophthalmology team.

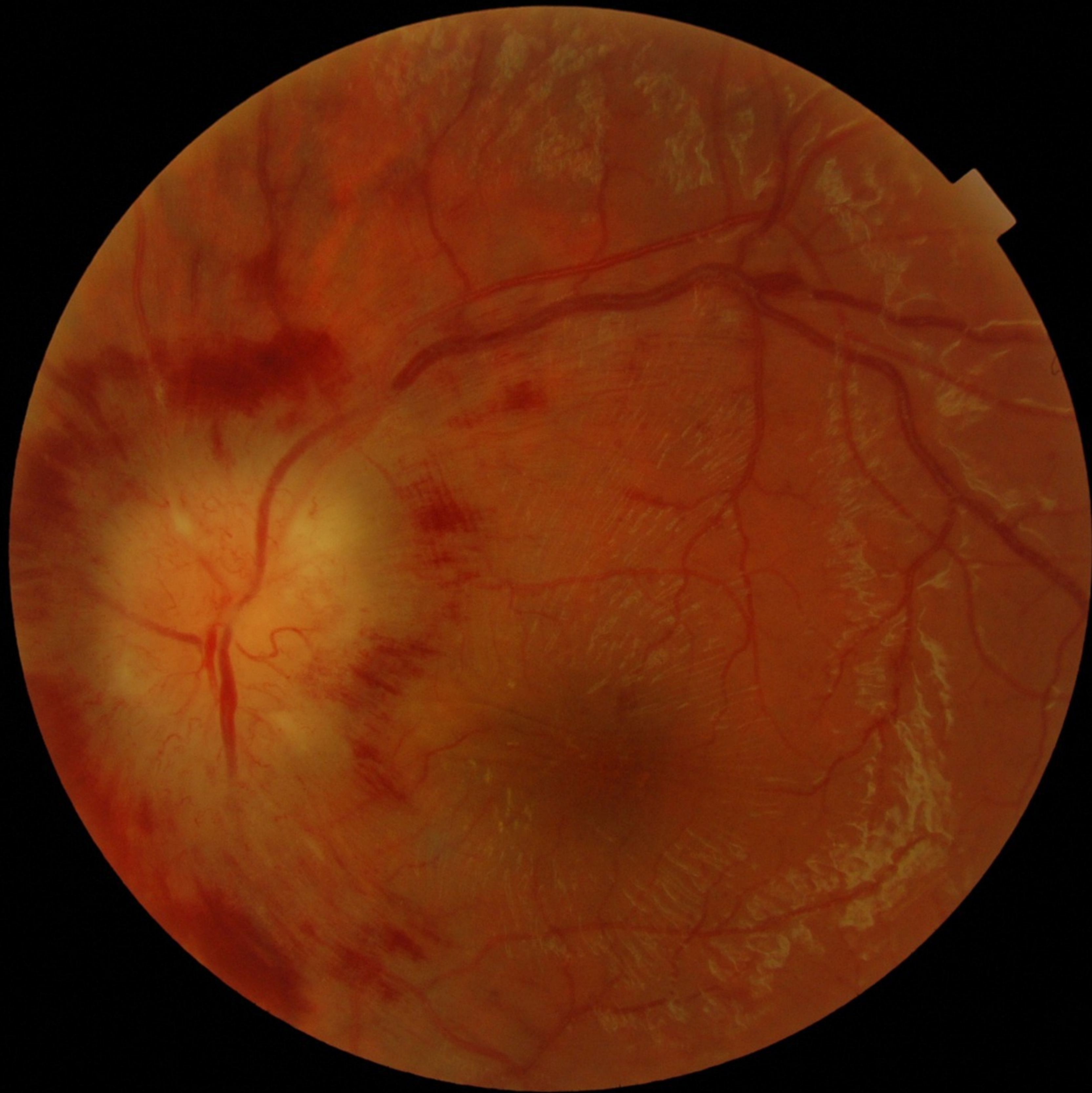In the context of anterior plagiocephaly, for which visual issues are important, our experience prompts us to implement early correction, around the age of 7 months.

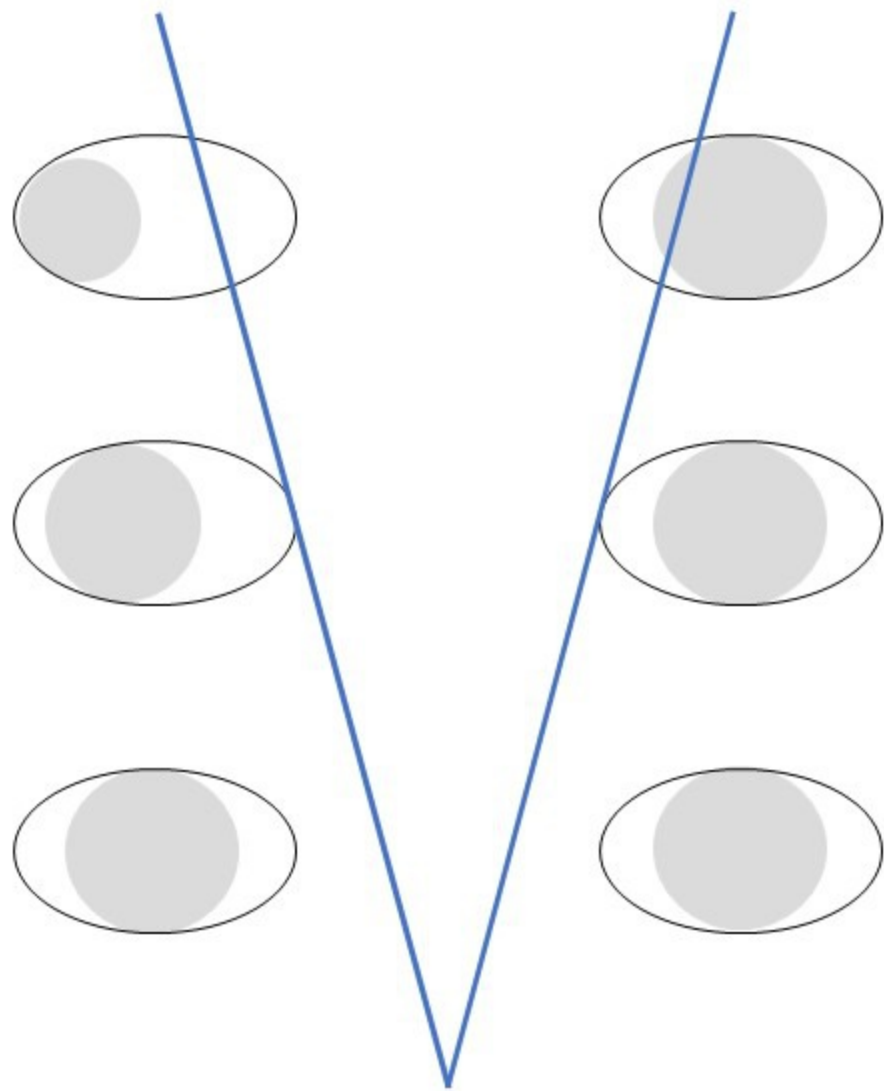
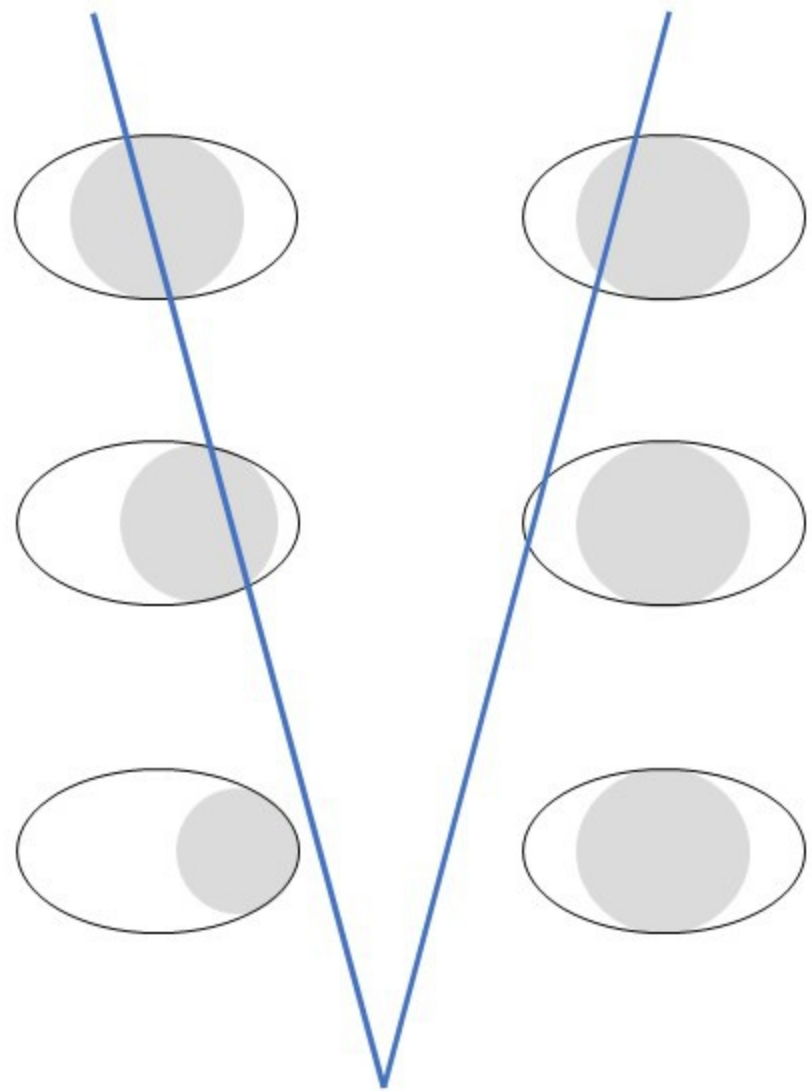


## REFERENCES

- [1] MacKinnon S, Proctor MR, Rogers GF, Meara JG, Whitecross S, Dagi LR. Improving ophthalmic outcomes in children with unilateral coronal synostosis by treatment with endoscopic strip craniectomy and helmet therapy rather than fronto-orbital advancement. *J AAPOS* 2013;17:259–65.
- [2] Diamond GR, Katowitz JA, Whitaker LA, Bersani TA, Bartlett SP, Welsh MG. Ocular and adnexal complications of unilateral orbital advancement for plagiocephaly. *Arch Ophthalmol Chic Ill* 1960 1987;105:381–5.
- [3] Donnelly UM, Stewart NM, Hollinger M. Prevalence and outcomes of childhood visual disorders. *Ophthalmic Epidemiol* 2005;12:243–50.
- [4] Levy RL, Rogers GF, Mulliken JB, Proctor MR, Dagi LR. Astigmatism in unilateral coronal synostosis: incidence and laterality. *J AAPOS* 2007;11:367–72.
- [5] Clergeau G. Infant ametropias and their evolutions (myopia, hyperopia, astigmatism). *Rev Prat* 2007;57:2009–13.
- [6] Gosain AK, Steele MA, McCarthy JG, Thorne CH. A prospective study of the relationship between strabismus and head posture in patients with frontal plagiocephaly. *Plast Reconstr Surg* 1996;97:881–91.
- [7] Macintosh C, Wall S, Leach C. Strabismus in unicoronal synostosis: ipsilateral or contralateral? *J Craniofac Surg* 2007;18:465–9.
- [8] Kreiborg S, Cohen MM. Ocular manifestations of Apert and Crouzon syndromes: qualitative and quantitative findings. *J Craniofac Surg* 2010;21:1354–7.
- [9] Velez FG, Thacker N, Britt MT, Rosenbaum AL. Cause of V pattern strabismus in craniosynostosis: a case report. *Br J Ophthalmol* 2004;88:1598–9.
- [10] Macintosh C, Wells R, Johnson D, Wall S. What are the effects of metopic synostosis on visual function? *J Craniofac Surg* 2011;22:1280–3.
- [11] Denis D, Genitori L, Conrath J, Lena G, Choux M. Ocular findings in children operated on for plagiocephaly and trigonocephaly. *Child's Nerv Syst* 1996;12:683–9.
- [12] Ricci D, Vasco G, Baranello G, Salerni A, Amante R, Tamburrini G, et al. Visual function in infants with non-syndromic craniosynostosis. *Dev Med Child Neurol* 2007;49:574–6.
- [13] Arnaud E, Capon-Degardin N, Michienzi J, Di Rocco F, Renier D. Scaphocephaly part II: Secondary coronal synostosis after scaphocephalic surgical correction. *J Craniofac Surg* 2009;20 Suppl 2:1843–50.
- [14] Cetas JS, Nasseri M, Saedi T, Kuang AA, Selden NR. Delayed intracranial hypertension after cranial vault remodeling for nonsyndromic single-suture synostosis. *J Neurosurg Pediatr* 2013;11:661–6.
- [15] D. Denis, G. Pech-Gourg. *Craniosténoses et Troubles oculomoteurs, Strabologie: Approches diagnostique et thérapeutique*, 3e édition. Strabol. Approch. Diagn. Thérapeutique 3e Édition, Elsevier Health Sciences; 2018.
- [16] Pollack IF, Losken HW, Biglan AW. Incidence of increased intracranial pressure after early surgical treatment of syndromic craniosynostosis. *Pediatr Neurosurg* 1996;24:202–9.
- [17] Liasis A, Walters B, Thompson D, Smith K, Hayward R, Nischal KK. Visual field loss in children with craniosynostosis. *Childs Nerv Syst* 2011;27:1289–96.
- [18] Qiao T, Wang G, Xiong J, Luo W, Chen J. Surgical Treatment of V-pattern Exotropia in Crouzon Syndrome. *J Pediatr Ophthalmol Strabismus* 2015;52:299–304.
- [19] Sharma N, Greenwell T, Hammerton M, David DJ, Selva D, Anderson PJ. The ophthalmic sequelae of Pfeiffer syndrome and the long-term visual outcomes after craniofacial surgery. *J Am Assoc Pediatr Ophthalmol Strabismus* 2016;20:315–9.
- [20] Clark JD, Compton CJ, Tahiri Y, Nunery WR, Harold Lee HB. Ophthalmic considerations in patients with Pfeiffer syndrome. *Am J Ophthalmol Case Rep* 2016;2:1–3.

- [21] Khong JJ, Anderson P, Gray TL, Hammerton M, Selva D, David D. Ophthalmic Findings in Apert Syndrome Prior to Craniofacial Surgery. *Am J Ophthalmol* 2006;142:328–30.
- [22] Khong JJ, Anderson P, Gray TL, Hammerton M, Selva D, David D. Ophthalmic Findings in Apert's Syndrome after Craniofacial Surgery: Twenty-nine Years' Experience. *Ophthalmology* 2006;113:347–52.
- [23] Hsu C-M, Lin M-C, Sheu S-J. Manifested strabismus in a case of Apert syndrome. *J Chin Med Assoc* 2011;74:95–7.
- [24] Ocular Morbidity in the Correction of Orbital Hypertelorism and Dystopia. *Plastic and Reconstructive Surgery* 2017 Apr;139(4):967-975
- [25] Alshamrani AA, Al-Shahwan S. Glaucoma With Crouzon Syndrome. *J Glaucoma* 2018;27:e110.
- [26] Schultz KP, Wiggins CJ, Streff H, Shah VS, Buchanan EP. Syndromic Multisuture Craniosynostosis With Associated Anterior Segment Dysgenesis, Optic Nerve Hypoplasia, and Congenital Glaucoma. *Cleft Palate-Craniofacial* 2019;56:823–6.
- [27] Teebi AS, Druker HA. Brachycephaly, cutis aplasia congenita, blue sclerae, hypertelorism, polydactyly, hypoplastic nipples, failure to thrive, and developmental delay: a distinct autosomal recessive syndrome? *Clin Dysmorphol* 2001;10:69.
- [28] Pott JWR, Godts D, Kerkhof DB, de Faber JTHN. Cyclic esotropia and the treatment of over-elevation in adduction and V-pattern. *Br J Ophthalmol* 2004;88:66–8.
- [29] Clifford L, Roos J, Dahlmann-Noor A, Vivian AJ. Surgical management of superior oblique paresis using inferior oblique anterior transposition. *J AAPOS* 2015;19:406–9.
- [30] Dwivedi R, Marsh IB. Superior oblique tuck: evaluation of surgical outcomes. *Strabismus* 2019;27:24–9.
- [31] Holmes JM, Hatt SR, Leske DA. Superior oblique tucks for apparent inferior oblique overaction and V-pattern strabismus associated with craniosynostosis. *Strabismus* 2010;18:111–5.
- [32] Pineles SL, Velez FG. Anterior superior oblique tuck: an alternate treatment for excyclotorsion. *J AAPOS* 2018;22:393-393.e1.
- [33] Khanna RK, Pasco J, Santallier M, Pichard T, Arsene S. Surgical outcomes after unilateral horizontal rectus surgery in children with infantile esotropia for the correction of A or V pattern. *J Fr Ophtalmol* 2019;42:451–6.





CRANIOSYNOSTOSIS

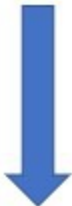

Bone deformations

Developmental malformation

HTIC  
Optic nerve : atrophy edema  
refractive disorders  
exorbitism  
Muscle traction

Muscle abnormalities:  
agenesis  
hypotrophy  
hypertrophy



OPHTHALMOLOGICAL CONSEQUENCES

Functionnal and organic AMBLYOPIA  
Loss of binocularity  
strabismus

NEURO-SENSORY  
SYSTEM MATURING

