



HAL
open science

Study of the growth and shape of the brain and cranial base during the first two years of life

C. Delteil, E. Lesieur, L. Tuchtan, A. Carballeira Alvarez, K. Chaumoitre, B. Saliba, P. Adalian, M.-D. Piercecchi-Marti

► **To cite this version:**

C. Delteil, E. Lesieur, L. Tuchtan, A. Carballeira Alvarez, K. Chaumoitre, et al.. Study of the growth and shape of the brain and cranial base during the first two years of life. *Morphologie*, 2021, 105 (348), pp.45-53. 10.1016/j.morpho.2020.09.007 . hal-03570651

HAL Id: hal-03570651

<https://hal.science/hal-03570651>

Submitted on 14 Feb 2023

HAL is a multi-disciplinary open access archive for the deposit and dissemination of scientific research documents, whether they are published or not. The documents may come from teaching and research institutions in France or abroad, or from public or private research centers.

L'archive ouverte pluridisciplinaire **HAL**, est destinée au dépôt et à la diffusion de documents scientifiques de niveau recherche, publiés ou non, émanant des établissements d'enseignement et de recherche français ou étrangers, des laboratoires publics ou privés.



Distributed under a Creative Commons Attribution - NonCommercial 4.0 International License

Study of the growth and shape of the brain and cranial base during the first two years of life

Etude de la croissance et de la conformation de l'encéphale et de la base du crâne durant les deux premières années de vie.

C. Delteil ^{a,b}, E. Lesieur ^c, L. Tuchtan ^a, A. Carballeira Alvarez ^d, K. Chaumoitre ^e, B. Saliba ^b, P. Adalian ^b, M-D Piercecchi-Marti ^a

^a Forensic Department, Assistance Publique-Hôpitaux de Marseille, La Timone, 264 rue St Pierre, 13385 Marseille Cedex 05, France

^b Aix Marseille Univ, CNRS, EFS, ADES, Marseille, France

^c Department of Gynaecology and Obstetrics, Gynépole, Assistance Publique-Hôpitaux de Marseille, AMU, Aix-Marseille Université, Marseille, France

^d Department of Radiology, Conception Hospital, Assistance Publique-Hôpitaux de Marseille, 147 Boulevard Baille, 13005 Marseille Cedex 05, France

^e Department of Radiology, CHU Nord, Assistance Publique-Hôpitaux de Marseille, France, Chemin des Bourrely, 13015 Marseille

Corresponding author:

Clémence Delteil

<https://orcid.org/0000-0001-5171-8520>

Forensic Department, APHM, La Timone, 264 rue St Pierre, 13385 Marseille Cedex 05, France

Tel. (33) 4 91 38 63 85

Fax (33) 4.91.92.33.31

E-mail address: clemence.delteil@ap-hm.fr

KEYWORDS: GROWTH, MATURATION, BRAIN, SKULL BASE, INFANT

MOTS-CLES : CROISSANCE, MATURATION, CERVEAU, BASE DU CRANE, NOURRISSON

Abstract

Ontogeny of the cranial base and the brain integrates data on growth, maturation and ontogenetic allometry of these two systems in the course of development.

The aim of our work was to study the ontogeny of the cranial base and the brain in order to understand their growth dynamic and shape changes using a traditional morphometric approach in individuals with normal (non-pathological) development.

Material and Method: Forty-seven infants having been included in the unexpected infant death french protocol were analyzed. Medical imaging (CT and MRI) exams, followed by an autopsy and pathology examination allowed us to include only infants free from brain disease or pathology affecting growth.

Results: Testing of measurement reliability validated 12 distances and 3 angles as well as the positioning of the landmarks that had been used to obtain the distances and the angles.

No correlation between sex and the various variables studied was found. However, a correlation was observed between these variables and age, making it possible to propose a growth curve. A medium to strong correlation was found between brain variables and the bone variables of the cranial base, underlining the parallel development of the two systems.

Conclusion: Our study, carried out in a rigorously selected population of infants, presents a fundamental approach to the study of ontogenesis.

Résumé :

L'ontogénie de la base du crâne et de l'encéphale intègre les données de croissance, de maturation et d'allométrie ontogénétique de ces deux systèmes au cours du développement.

But de l'étude : Etudier l'ontogénie de la base du crâne et de l'encéphale afin de comprendre leur dynamique de croissance ainsi que les modifications de conformation à partir d'une approche en morphométrie traditionnelle.

Matériel et méthodes : Quarante-sept nourrissons ayant été inclus dans le protocole français de mort subite du nourrisson ont été analysés. Les examens d'imagerie médicale (tomodensitométrie et IRM), suivis d'une autopsie et d'un examen anatomopathologique nous ont permis de n'inclure que les nourrissons exempts de maladie cérébrale ou de pathologie affectant la croissance.

Résultats : Le test de fiabilité des mesures a permis de valider 12 distances et de 3 angles ainsi que la pose des points de repères ayant servi à obtenir les distances et les angles. Aucune corrélation entre le sexe et les différents paramètres étudiés n'a été mise en évidence. En contrepartie, une corrélation entre les différents paramètres étudiés et l'âge a été attestée, permettant de proposer une courbe de croissance. Une corrélation dont la valeur fluctue de moyenne à forte entre les paramètres encéphaliques et les paramètres osseux de la base du crâne a été mise en évidence, soulignant une évolution parallèle des deux systèmes.

Conclusion : Notre étude, conduite sur une population de nourrissons rigoureusement sélectionnés, présente une approche fondamentale dans l'étude de l'ontogénèse.

1. Introduction

Brain volume doubles in the first 6 months of life, reaching 50% of adult brain volume. Brain development is heterogeneous. The rate of maturation is different depending on the brain region. Thus, the sensory and motor regions organize themselves first, while the regions involved in more associative functions are extremely slow and will not mature until after puberty and even continue to change throughout life. The integration of active growth systems of the brain and cranial base suggest that these systems mutually influence each other, although this influence has never been proven to be an exclusive one [1]. This reciprocal influence may occur during the fetal period and the first three years of life, at the time when brain growth is greatest [2].

However, evaluation of growth of the brain and the cranial base relies on incomplete data [3–5]. Radiological charts exist for the fetus [6], but there are none for infants with no pathological condition. Only radiological comparisons between pathological [7] or premature infants [8,9] and infants considered as “normal” have been reported, with no mention of “normal” measurements.

In view of this lack of data in the infant, we aimed to study the development of the cranial base and the brain during the first two years of life through an ontogenic study of these two systems using conventional morphometrics.

Conventional morphometrics consists of the application of multivariate statistical analyses to a series of quantitative variables: linear distances (between two points: length, width, height), angles, ratios, surface and volume [10]. It is used in comparative biology to study growth, shape and allometry [10].

The aim of our work was to study the ontogeny of the cranial base and the brain in order to understand their normal (non-pathological) growth dynamic and age-related shape changes.

2. Material and Methods

Sample

The samples studied consisted of a retrospective series of infants who had died between the ages of 0 and 24 months and who had been included in the sudden infant death (SID) protocol in the sudden infant death unit of the Hôpital de la Conception in the geographical reference region of west Provence-Côte d’Azur, France.

We studied 58 infants who had died between January 1, 2010, and 31 December, 2016, and had been managed in the public hospitals of Marseille (Assistance Publique des Hôpitaux de Marseille). The majority of

deaths were due to sleeping accidents (positional mechanical asphyxia), infectious disorders (viral and bacterial) and surgical abdominal disorders (acute intestinal intussusception, peritonitis, volvulus).

Only infants with no disorder affecting growth and no brain disorder identified on imaging followed by autopsy and histopathological examination were included in the study.

The non-inclusion criteria were incomplete or insufficient quality imaging exams (CT-scan or magnetic resonance imaging).

Autopsy completed by histopathological examination was considered the gold standard to exclude any disorder. Autopsy was performed after the written consent of the parents had been obtained. Any external or internal abnormalities were described. Information on pregnancy, term at birth, and medical and surgical history was also recorded.

For each infant, anonymized anthropological data were available: chronological age (or corrected age if the infant was born before 38 weeks amenorrhea), weight, crown-heel length, head circumference and sex.

Imaging protocols

As part of the recommendations of the High Authority for Health (Haute Autorité de la Santé, HAS) [11] regarding sudden infant death, each infant underwent:

- CT scan: whole-body scans were obtained and recorded in Digital Imaging and Communications in Medicine (DICOM) format. The native scans (overlapping 0.50–5 mm sections) were the raw data used in our study.
- Magnetic resonance imaging (MRI): whole-body scans recorded in DICOM format. The native scans (overlapping 0.9-5 mm sections) were the raw data used in our study.

Conventional morphometric measurement protocols

Seventeen linear measurements and 5 angles were obtained using OsiriX version 5.6 software developed by Pixmeo. Three-dimensional multiplanar reconstruction (MPR) enabled optimal selection of the landmarks and thus of the measurements obtained. The measurements were selected according to literature relating to normal cranio-cerebral development in the foetus: brainstem (1), cerebral (1, 6), cerebellum (1, 7), cranial base (1, 12). All measurements and the methods used to obtain them are described in Table 1 (figures in Annex).

Table 1

Imaging	Measurements	Abbreviation	Definition
---------	--------------	--------------	------------

type			
CT	AP length of the PP	PP AP	Axial section perpendicular to middle cranial fossa: most anterior and most posterior point of the right PP (12)
CT	PP height	PP H	Axial section perpendicular to right middle cranial fossa: most medial point, passing through the external auditory canal (12)
CT	Surface of the PP	PP Suf	Axial section perpendicular to right middle cranial fossa, delimiting the region of interest (ROI)
CT	Maximum length of the PB	PB ML	Axial section through the axis: maximum length of the PB of the occipital bone (12)
CT	Sagittal length of the PB	PB SL	Axial section through the axis: sagittal length of PB the occipital bone (12)
CT	Maximum width of the PB	PB MW	Axial section through the axis: maximum width of PB the occipital bone (12)
MRI (T1)	Length of anterior level	Ant L	Median sagittal section: distance from the foramen caecum to the area between the two anterior clinoid processes
CT	Length of the middle level	Mid L	Horizontal section: distance between the most lateral part of the anterior border of the right PP to the most lateral part of the small wing of the right sphenoid
MRI (T1)	Length of the posterior level	Post L	Median sagittal section: distance from the region between the two posterior clinoid processes to the internal occipital protuberance
MRI (T1)	Total length of the cranial base	Total L	Median sagittal section: distance from the foramen caecum to the internal occipital protuberance
MRI (T1)	Sphenoid angle	Sph A	Median sagittal section: nasion-sphenoid-occipital basion angle (1)
MRI (T1)	Interpetrous angle	IPA	Axial section: angle of the intersection of lines drawn through the posterior border of the Crista partis petrosae (7)
MRI (T2)	Occipitofrontal diameter	OFD	Median sagittal section: distance between the extremities of the occipital and frontal lobes (6)

MRI (T2)	Bone biparietal diameter	Bone BPD	Coronal section through the temporal horns of the lateral ventricles: greatest diameter of the brain: maximum distance between the two internal tables of the cranium (6)
MRI (T2)	Brain biparietal diameter	Brain BPD	Coronal section through the temporal horns of the lateral ventricles: greatest diameter of the brain (6)
MRI (T2)	Length of corpus callosum	LCC	Median sagittal section: distance between the genu and the posterior extremity of the splenium (6)
MRI (T2)	AP vermis diameter	APVD	Median sagittal section: diameter taken perpendicular to the median part of the roof of the 4 th ventricle (6)
MRI (T2)	Height of the vermis	HV	Median sagittal section: maximum height of the vermis, parallel to the brainstem (6)
MRI (T2)	Transverse cerebellar diameter	TCD	Coronal section through the atrium: maximum cerebellar diameter (6)
MRI (T2)	Brainstem-tentorium angle	BSTA	Median sagittal section: intersection between the line tangent to the posterior aspect of the pons and the line tangent to the cerebellar tentorium
MRI (T2)	Basion-tentorium angle	BTA	Median sagittal section: intersection between the line joining the most internal part of the roof of the cerebellum and the line tangent to the cerebellar tentorium (7,13)
MRI (T2)	Pontomedullary angle	PMA	Median sagittal section: angle between the upper 2/3 of the anterior aspect of the pons, the posterior aspect of the bulbomedullary junction and the posterior aspect of the lower cervical spinal cord

PP: petrous pyramid; AP: anteroposterior; PB: pars basilaris; BS: brainstem; T1: T1-weighted sequence; T2: T2-weighted sequence.

Statistical analysis

Statistical analysis was carried out using the RStudio statistical environment [14] and R software version 3.2. Repeatability (intra-observer) and reproducibility (inter-observer) were analyzed from the coefficient of

precision (mean of the differences observed between the two observations), Lin's concordance coefficient (Lin's CC) and the Bland and Altman method using an Excel add-in [15] in 20 infants. Repeatability was checked blind after an interval of two months for age, sex and the results previously obtained. Reproducibility was checked blind by two observers for age, sex and the results previously obtained. The values obtained for Lin's CC were interpreted according to Partik et al. [16]. Only results with a Lin's CC greater than 71 for repeatability and reproducibility were retained as we considered that their measurement error was acceptable (Table 2).

Table 2

Interpretation of the value of the correlation coefficient

< 0.50	Unacceptable
0.51-0.60	Poor
0.61-0.70	Mediocre
0.71-0.80	Moderately satisfactory
0.81-0.90	Fairly good
0.91-0.95	Very good
> 0.95	Excellent

The normality of distribution of each of the biometric variables and the equality of variance were studied using the Shapiro-Wilk test. The null hypothesis of this test is that the population is normally distributed. If the p-value is lower than the alpha level selected, the null hypothesis is rejected [17].

For normally distributed variables, the correlation between the different variables was studied using the Pearson correlation (multivariate statistical test applied to a series of quantitative variables). Growth curves were established for the variables correlated with age.

A correlation between sex and the different variables analyzed was sought using an ANOVA test.

For all tests, the alpha risk was set at 0.05.

3. Results

Study population

The retrospective cohort included 47 infants (22 girls, 25 boys).

Measurement reliability

Repeatability and reliability were studied in 20 infants selected at random (11 boys, 9 girls).

The precision coefficient was low.

Lin's correlation coefficient was used to select the variables presented in Table 3.

Table 3

Measurements	Repeatability: agreement	Reproducibility: agreement
PP height	moderately satisfactory (0.74)	fairly good (0.90)
Maximum length and width of the pars basilaris	moderately satisfactory (0.90 and 0.81)	fairly good (0.83 and 0.88)
Length of posterior level	very good (0.92)	fairly good (0.81)
Total length of cranial base	very good (0.95)	fairly good (0.85)
Sphenoid angle	fairly good (0.84)	moderately satisfactory (0.78)
Interpetrous angle	moderately satisfactory (0.76)	moderately satisfactory (0.76)
Occipitofrontal diameter	very good (0.95)	very good (0.95)
Bone and brain biparietal diameter	very good (0.93 and 0.91)	Very good and fairly good (0.91 et 0.85)
Length of corpus callosum	moderately satisfactory (0.78)	moderately satisfactory (0.78)
Anteroposterior diameter and height of the vermis	Fairly good (0.83)	moderately satisfactory (0.78)
Transverse cerebellar diameter	excellent (0.99)	excellent (0.98)
Pontomedullary angle	very good (0.91)	very good (0.92)

The difference between the two measurements (intra and interobserver) were normally distributed and 95% of the values of measurement differences were within the limits of agreement. Bias (mean of the differences) was low. Among the variables retained, regarding inter-observer variability, none was not within the confidence

interval of bias for measurement of petrous pyramid height and vermis height: there was a systematic difference and bias was therefore significant.

Conventional morphometrics

All variables were normally distributed.

Correlation between sex and the variables studied

None of the variables studied showed a significant difference according to sex.

Correlation between age and the variables studied

Pearson's test showed a correlation between age and all the variables studied. The principal findings were a strong correlation between age and crown-heel length ($p < 0.01$, $R = 0.855$), head circumference ($p < 0.01$, $R = 0.799$), maximum length ($p < 0.01$, $R = 0.747$) and width ($p < 0.001$, $R = 0.738$) of the pars basilaris, petrous pyramid height ($p < 0.01$, $R = 0.714$), bone biparietal diameter ($p < 0.01$, $R = 0.788$), brain biparietal diameter ($p < 0.01$, $R = 0.807$) and cerebellar variables: transverse cerebellar diameter ($p < 0.01$, $R = 0.817$), anteroposterior diameter and height of the vermis ($p < 0.01$, $R = 0.664$ and $R = 0.677$).

Notably, there was a negative correlation between age and the sphenoid angle ($p < 0.01$, $R = -0.353$).

Growth curves were drawn for each of these variables (Fig. 1). There was positive linear growth during the first two years of life, with the exception of the interpetrous angle, which did not develop after 12 months. The value of the sphenoid angle decreased during the period studied.

Correlation between the cranial base and the brain

Overall, the correlations between the dimensions of the cranial base and the brain were very strong.

Head circumference was strongly correlated with crown-heel length ($p < 0.01$, $R = 0.909$), maximum length ($p < 0.01$, $R = 0.841$) and maximum width ($p < 0.01$, $R = 0.843$) of the pars basilaris, height of the petrous pyramid ($p < 0.01$, $R = 0.718$), occipitofrontal diameter ($p < 0.01$, $R = 0.865$), bone biparietal diameter ($p < 0.01$, $R = 0.932$) and brain biparietal diameter ($p < 0.01$, $R = 0.926$), transverse cerebellar diameter ($p < 0.01$, $R = 0.870$) and interpetrous angle ($p < 0.01$, $R = 0.615$).

Occipitofrontal diameter was very strongly correlated with the total length of the cranial base ($p < 0.01$, $R = 0.911$). Brain biparietal diameter was very strongly correlated with bone biparietal diameter ($p < 0.01$,

R=0.988) and transverse cerebellar diameter ($p<0.01$, $R=0.937$). The relation between transverse cerebellar diameter and biparietal diameter showed a linear increase, reflecting relatively greater increase in cerebellar width than in biparietal diameter in the infant (Fig. 2).

The sphenoid angle was correlated with transverse cerebellar diameter ($p=0.01$, $R=0.386$), brain and bone biparietal diameter ($p<0.05$, $R= -0.367$ and -0.376 , respectively) and also with maximum length ($p<0.01$, $R=-0.381$), and maximum width ($p<0.01$, $R=-0.420$) of the pars basilaris. The sphenoid angle was correlated with crown-heel length ($p<0.02$, $R=-0.405$).

The cephalic index (CI) corresponding to the ratio of brain biparietal diameter to occipitofrontal diameter showed relative widening of the brain (Fig. 3). According to the classification of Cohen and Maclean [18], for our cases, up to the age of 8 months the CI is between 81.0–85.4 and indicates a brachycephalic cranium. After 8 month the CI is superior at 85.5, indicated a hyperbrachycephalic cranium.

There was a strong correlation between transverse cerebellar diameter and maximum length ($p<0.01$, $R=0.861$) and maximum width ($p<0.01$, $R=0.895$) of the pars basilaris, as well as with the height ($p<0.01$, $R=0.801$) and volume ($p<0.01$, $R=0.75$) of the petrous pyramid.

There was also a strong correlation between the height of the vermis and maximum height ($p<0.01$, $R=0.764$) and maximum width ($p<0.01$, $R=0.809$) of the pars basilaris.

The interpetrous angle, corresponding to the opening of the posterior fossa, was correlated with occipitofrontal diameter ($p<0.01$, $R=0.459$), brain biparietal diameter ($p<0.01$, $R=0.604$), transverse cerebellar diameter, anteroposterior diameter and height of the vermis ($p<0.01$, $R=0.355$ and 0.494 , respectively). It became stable after the first year of life.

Transverse cerebellar diameter was also strongly correlated with occipitofrontal diameter ($p<0.01$, $R=0.851$) and bone biparietal diameter ($p<0.01$, $R=0.937$). The length of the corpus callosum was correlated with occipitofrontal diameter ($p<0.01$, $R=0.779$).

4. Discussion

As far as we are aware, this study is the first to propose a joint approach to analysis of the cranial base and the brain during the first years of life while taking into account the possibility of sexual dimorphism.

It revealed that the growth dynamic of these two systems was strongly correlated and synchronous. Studies in variations of the angles enabled analysis of shape changes of the cranial base.

Lastly, our study is original in that it uses two types of data to allow an overall approach to ontogeny in a well-defined population of infants. We were thus able to study a population that was unique both by the size of the series and by our use of multiple data obtained by imaging (CT and MRI) and by autopsy.

Study population and imaging techniques

Although our series was large compared with other studies, the population included in the SID protocol was heterogeneous in distribution but coherent with the epidemiological data for SID [11]. In France, cases of SID are managed in a reference center (specialized pediatric hospital department) following a protocol based on the recommendations of the High Authority for Health (Haute Autorité de la Santé, HAS). This protocol enables rapid medical investigations in order to identify a cause of death and includes, in particular, medical imaging and full autopsy. There was a marked predominance of infants aged under 10 months and an unbalanced sex ratio with a majority of boys. This led to non-representativity of certain age groups, limiting the scope of our conclusions for certain variables.

The infants we included were rigorously selected (only 80% of the initial population was retained) in order to exclude any disorder that might affect the biometric variables examined.

Our study interested a wide range of measurements obtained through the combined use of CT and MRI. This combination is, to the best of our knowledge, not used previous literature on its use for study of ontogeny, in the infant in particular. The combination of these two investigations enabled study of 15 validated quantitative variables (12 linear measurements and 3 angles) of both the brain and the cranial base.

This study is as yet the most voluminous collection of biometric data on the head segment.

Measurement reliability

More than half (15 of 23) of the biometric variables included in our study were found to be reliable and valid after study of their reproducibility and repeatability. Error could be explained by the thickness of the MRI sections studied and by lack of precision in placing landmarks in this context where distances are often less than a millimeter.

McBride [19] proposed a descriptive scale for values of Lin's correlation coefficient in biology. It is considered as poor when below 0.90. However, in the medical domain this evaluation is arbitrary and unjustified. Partik et al. [16] proposed threshold values that are more pertinent for medical research, and notably for medical imaging.

Metric approach

All biometric variables studied showed variance that increased during the first two years of life, with the exception of the interpetrous angle which remained stable after the 12th month of life. Brain biparietal diameter, transverse cerebellar diameter, crown-heel length and head circumference were the variables that were most strongly correlated with age. Our approach to study of brain growth and of elements of the cranial base yielded growth curves that may be used to assess normal development in the infant. However, the relatively small size of our sample did not enable us to establish true norms for growth or speed of growth.

We demonstrated that overall, the correlations between the brain and the cranial base were strong in the infant. We confirmed certain findings of the literature [20,21], notably with regard to the relation between age and closure of the sphenoid angle after birth. Like Lieberman, we showed a negative correlation between closure of the sphenoid angle and crown-heel length [21, 22]. We also showed that closure of sphenoid angle and opening of the interpetrous angle was significantly correlated with widening of the cerebellum and with increase of biparietal diameter. The angle variation could be explained because of the rapid growth of the posterior fossa growth from birth to 3.58 years [23]. The rapid growth phase is explained by the absence of ossification of occipitomastoidal synchondrosis, petro-occipital synchondrosis and sphenoid-occipital synchondrosis [23].

In the adult, it has been shown that variations in the width, length and flexion of the cranial base are independent and that only the maximum width of the cranial base has a significant effect on overall cranial proportions [22]. However, in our study we underlined, in addition to these data, a close relationship between occipitofrontal diameter on the one hand and total length of the cranial base, sphenoid angle, biparietal diameter and transverse cerebellar diameter on the other.

Our study confirmed that measurements of the vermis and cerebellum were strongly correlated with age in the infant. Some neonatology teams use these measurements to assess gestational age [24]. We also observed that transverse cerebellar diameter (representing cerebellar growth in width), which is part of fetal development after 28 weeks amenorrhea [1,25], increased faster than biparietal diameter (growth in width of the cerebral hemispheres).

Several authors have shown with traditional morphometry that basioccipital dimensions evolve during foetal development [26-28] and its characteristics intensify with age [27]. The basioccipital are used not only in anatomy but also in biological anthropology: it can give an idea about the foetal age [29] and as our study showed about the post-natal age.

As Paetz et al, we find that the temporal bone grows study is also relevant during the first 2 years of life [30] in particular the petrous pyramid height, strongly correlated, with age and head circumference.

The cephalic index, based on MRI imaging of brain structures, showed in the infant a brain of brachycephalic type (width greater than length). These data are coherent with those of the literature [31,32] obtained from CT imaging.

The influence of sex on growth of the immature child aged less than 2 years was studied for each biometric variable. We found no sex-related difference in growth in any of the variables.

Few studies have looked for dimorphism of brain structures in this age group. Choe et al. [33] showed sexual dimorphism only in the caudate nucleus and the vermis. Their findings are not in agreement with ours. Matthews et al also showed craniofacial dimorphism in 1 year-olds [34]. Moreover Rees and al. [35] described in the sudden infant death syndrome morphological facial characteristics, it could be extrapolate to the skull base. The sample size is very minimal once distributed into the particular age categories. The lack of a correlation between sex and the variables examined could merely reflect the small sample size.

With regard to the cranial base, some studies have shown sexual dimorphism of the anterior part of the cranial base (width) [36,37]. However, sexual dimorphism was not observed at the posterior level or the sphenoid angle [36].

Interactions between growth of the cranial base and the brain

Our methodological approach did not enable us to determine whether growth of the brain was dependent on that of the cranial base, or the contrary. We did however demonstrate that there was a parallel dynamic of the one in relation to the other. In order to study a true cause-effect relationship, it would be necessary to examine a brain or bone disorder and observe its impact on adjacent structures. However, there is no sufficiently prevalent disorder that would enable pertinent study.

The effect of abnormalities of cranial suture closure on the brain is known [18], but congenital abnormalities of the cranial base are rare (encephalocele, dermoid cyst) [38], which limits the possibilities of extrapolating a possible interrelation of the systems in development.

5. Conclusion

Our study demonstrated that growth of the cranial base and the brain develop in parallel during the first two years of life. It was carried out in a large series of rigorously selected infants and proposes an innovatory

approach to the study of ontogenesis through the combined use of medical imaging, autopsy and histopathological data. Lastly, it contributes to better knowledge of overall growth and normal development, improving our understanding of pathological mechanisms that affect the brain and cranial segment.

Conflict of interest: The authors declare that they have no conflict of interest.

For this type of study formal consent is not required.

Declaration:

Funding: none

Conflicts of interest/Competing interests: none

Ethics approval (include appropriate approvals or waivers) : by the ethics committee of our establishment CIL/AP-HM 2017-41

Consent to participate: Not applicable (death infant)

Consent for publication Not applicable (death infant)

Authors' contributions

C. Delteil: •Protocol/project development; Data curation; Writing

E. Lesieur: Data curation

L. Tuchtan : Reviewing

A. Carballeira Alvarez : Resources; Software

C. Chaumoitre: Resources; Software

B. Saliba: Statistical analysis

P. Adalian: Project administration; Reviewing

M.D. Piercecchi-Marti: Supervision; Validation; Reviewing

References

[1] G. Captier, L.J. Boë, P. Badin, A.M. Guihard-Costa, F. Canovas, J.C. Larroche, Geometrical growth models of the fetal forebrain, cerebellum, brainstem and change of the cranial base angles during fetal period, *Morphologie* 97 (2013) 38–47. doi: 10.1016/j.morpho.2012.12.002

[2] A.M. Guihard-Costa, F. Ramirez-Rozzi, Growth of the human brain and skull slows down at about 2.5 years old, *Comptes Rendus Palevol.* 3 (2004) 397–402. doi.org/10.1016/j.crpv.2004.03.004

- [3] J.N. Giedd, F.X. Castellanos, J.C. Rajapakse, D. Kaysen, A.C. Vaituzis, Y.C. Vauss, et al., Cerebral MRI of human brain development: Ages 4–18, *Biol. Psychiatry* 37 (1995) 657. doi.org/10.1016/0006-3223(95)94641-9.
- [4] R.K. Lenroot, N. Gogtay, D.K. Greenstein, E.M. Wells, G.L. Wallace, L.S. Clasen, et al., Sexual dimorphism of brain developmental trajectories during childhood and adolescence, *Neuroimage* 36 (2007) 1065–1073. doi: 10.1016/j.neuroimage.2007.03.053
- [5] R.K. Lenroot, J.N. Giedd, Brain development in children and adolescents: insights from anatomical magnetic resonance imaging, *Neurosci. Biobehav. Rev.* 30 (2006) 718–729. doi: 10.1016/j.neubiorev.2006.06.001.
- [6] C. Garel, *MRI of the Fetal Brain: Normal Development and Cerebral Pathologies*, Springer-Verlag, Berlin, Heidelberg, 2004.
- [7] R. Calandrelli, G. D’Apolito, M. Panfili, G. Zampino, T. Tartaglione, C. Colosimo, Costello syndrome: Analysis of the posterior cranial fossa in children with posterior fossa crowding, *Neuroradiol. J.* 28 (2015) 254–258. doi:10.1177/1971400915592549.
- [8] J.M. Walsh, L.W. Doyle, P.J. Anderson, K.J. Lee, Cheong JL, Moderate and late preterm birth: effect on brain size and maturation at term-equivalent age, *Radiology* 273 (2014) 232–240. doi: 10.1148/radiol.14132410.
- [9] S.N. Tich, P.J. Anderson, R.W. Hunt, K.J. Lee, L.W. Doyle, T.E. Inder, Neurodevelopmental and perinatal correlates of simple brain metrics in very preterm infants, *Arch. Pediatr. Adolesc. Med.* 5 (2011) 216–222. doi: 10.1001/archpediatrics.2011.9.
- [10] F. James Rohlf, L.F. Marcus, A revolution morphometrics, *Trends Ecol. Evol.* 8 (1993) 129–132. doi: 10.1016/0169-5347(93)90024-J.
- [11] Haute Autorité de Santé (HAS), *Prise en charge en cas de mort inattendue du nourrisson (moins de 2 ans)*, Haute Autorité de Santé; 2007 p. 46.
- [12] I. G. Fazekas, F. Kósa, *Forensic Fetal Osteology*, Akadémiai Kiadó, Budapest, 1978. fourth ed., Longman, New York, 2000.
- [13] D. Vatansever, V. Kyriakopoulou, J.M. Allsop, M. Fox, A. Chew, J.V. Hajnal, et al., Multidimensional analysis of fetal posterior fossa in health and disease, *Cerebellum* 12 (2013) 632–644. doi: 10.1007/s12311-013-0470-2.

- [14] R Development Core Team, R: A language and environment for statistical computing. [Internet], R Foundation for Statistical Computing, Vienna, Austria, 2005. Available from: <http://www.R-project.org>.
- [15] L. Desquilbet, Répétabilité, reproductibilité, et concordance de méthodes de mesure, version 9. 2019. Available at https://loicdesquilbet.wixsite.com/biostat_epidemiologie/documents
- [16] B.L. Partik, A. Stadler, S. Schamp, A. Koller, M. Voracek, G. Heinz, et al., 3D versus 2D ultrasound: accuracy of volume measurement in human cadaver kidneys, *Invest. Radiol.* 37 (2002) 489–495. doi: 10.1097/01.RLI.0000023573.59066.43.
- [17] S.S. Shapiro, M.B. Wilk, An analysis of variance test for normality (complete samples), *Biometrika* 52 (1965) 591–611. doi:org/10.1093/biomet/52.3-4.591.
- [18] M.M. Cohen, R.E. MacLean, *Craniosynostosis : Diagnosis, Evaluation, and Management*, second ed., Oxford University Press, New York, Oxford, 2000. Available from: <http://trove.nla.gov.au/version/39761935>
- [19] McBride GB. A proposal for strength-of-agreement criteria for Lin's Concordance Correlation Coefficient. 2005 NIWA Client Report: HAM2005-062. <<http://www.niwa.co.nz>>
- [20] I.S. Watanabe, M.C. Madeira, I.S. Watanabe, M.C. Madeira, [The clivus-sphenoidale angle in children (postnatal flexion of the cranial base)], *Rev. Bras. Pesqui. Med. Biol.* 10 (1977) 325–329.
- [21] D.E. Lieberman, R.C. McCarthy, The ontogeny of cranial base angulation in humans and chimpanzees and its implications for reconstructing pharyngeal dimensions, *J. Hum. Evol.* 36 (1999) 487–517.
- [22] D.E. Lieberman, O.M. Pearson, K.M. Mowbray, Basicranial influence on overall cranial shape, *J. Hum. Evol.* 38 (2000) 291–315.
- [23] G. Coll, J.-J. Lemaire, F. Di Rocco, I. Barthélémy, J.-M. Garcier, E. De Schlichting, et al. Human foramen magnum area and posterior cranial fossa volume growth in relation to cranial base synchondrosis closure in the course of child development *Neurosurgery*, 79 (2016), pp. 722-735, 10.1227/NEU.0000000000001309.
- [24] E. Co, T.N. Raju, O. Aldana, Cerebellar dimensions in assessment of gestational age in neonates, *Radiology* 181 (1991) 581–585.
- [25] N. Jeffery, F. Spoor, Brain size and the human cranial base: a prenatal perspective, *Am. J. Phys. Anthropol.* 118 (2002) 324–340.

- [26] Scheuer L, MacLaughlin-Black S. Age estimation from the pars basilaris of the fetal and juvenile occipital bone. *International Journal of Osteoarchaeology*. 1994;4(4):377-380. <https://doi.org/10.1002/oa.1390040412>
- [27] Scheuer L, Black S, Cunningham C (2000) *Developmental Juvenile Osteology*. San Diego: Elsevier Academic Press.
- [28] Nagaoka T, Kawakubo Y, Hirata K. Estimation of fetal age at death from the basilar part of the occipital bone. *Int J Legal Med*. 2012;126(5):703-711. doi:10.1007/s00414-012-0718-2
- [29] Niel M, Chaumoître K, Corny J, Lalys L, Adalian P. Maturation of the human foetal basioccipital: quantifying shape changes in second and third trimesters using elliptic Fourier analysis. *J Anat*. 2019;235(1):34-44. doi:10.1111/joa.12997
- [30] Paetz P, Goetz GF, Lanfermann H, Giesemann AM. The developing temporal bone: computed tomography measurements and assessment of suture closure from birth to 18 years of age. *Surg Radiol Anat*. 2017;39(6):663-671. doi:10.1007/s00276-016-1786-7
- [31] P. Hummel, D. Fortado, Impacting infant head shapes, *Adv. Neonatal Care* 5(2005) 329–340. doi: 10.1016/j.adnc.2005.08.009
- [32] W. Likus, G. Bajor, K. Gruszczyńska, J. Baron, J. Markowski, M. Machnikowska-Sokołowska, et al., Cephalic index in the first three years of life: study of children with normal brain development based on computed tomography, *ScientificWorldJournal* 2014;2014:502836. doi: 10.1155/2014/502836.
- [33] M. S. Choe, S. Ortiz-Mantilla, N. Makris, M. Gregas, J. Bacic, D. Haehn, et al., Regional Infant brain development: an MRI-based morphometric analysis in 3 to 13 month olds, *Cereb. Cortex* 23 (2013) 2100–2117. doi: 10.1093/cercor/bhs197.
- [34] Matthews H, Penington T, Saey I, Halliday J, Muggli E, Claes P. Spatially dense morphometrics of craniofacial sexual dimorphism in 1-year-olds. *J Anat*. 2016;229(4):549-559. doi:10.1111/joa.12507
- [35] Rees, K., Wright, A., Keeling, J. W., & Douglas, N. J. (1998). Facial structure in the sudden infant death syndrome: case-control study. *BMJ (Clinical research ed.)*, 317(7152), 179–180. <https://doi.org/10.1136/bmj.317.7152.179>
- [36] W.J. Ursi, C.A. Trotman, J.A. McNamara, R.G. Behrents, Sexual dimorphism in normal craniofacial growth, *Angle Orthod*. 63 (1993) 47–56.

[37] E. Bulygina, P. Mitteroecker, L. Aiello, Ontogeny of facial dimorphism and patterns of individual development within one human population, *Am. J. Phys. Anthropol.* 131 (2006) 432–443. doi: 10.1002/ajpa.20317

[38] A. Di Ieva, E. Bruner, T. Haider, L.F. Rodella, J.M. Lee, M.D. Cusimano, et al., Skull base embryology: a multidisciplinary review, *Childs Nerv. Syst.* 30 (2014) 991–1000. doi: 10.1007/s00381-014-2411-x.

Légends

Table 1 : Conventional morphometric measurement protocols

Table 2 : Interpretation of the value of the correlation coefficient

Table 3 : Lin's correlation coefficient

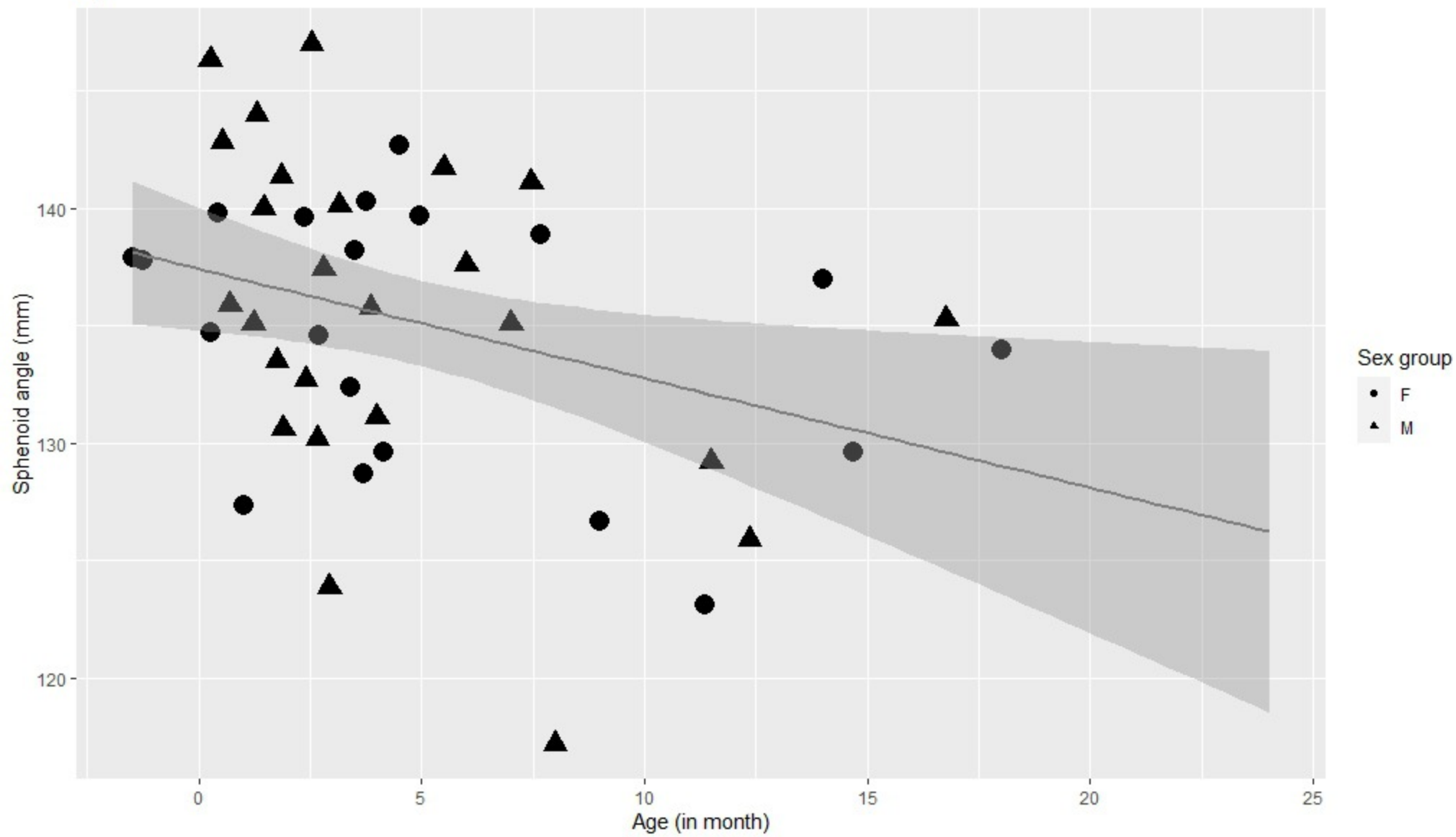
Figures

Fig. 1. Growth curves according to age (in months) for the (a) sphenoid angle, (b) interpetrous angle, (c) anteroposterior diameters: OFD (black) and total cranial base (gray), (d) biparietal diameters (black and mid gray) and transverse cerebellar diameter (clear gray), (e) anteroposterior height (black) and height (gray) of the vermis, (f) height of the petrous pyramid, (g) maximum length (black) and width (clear gray) of the pars basilaris, (h) body height (i) weight, (j) head circumference. The circle corresponds to the girls and the triangles to the boys.

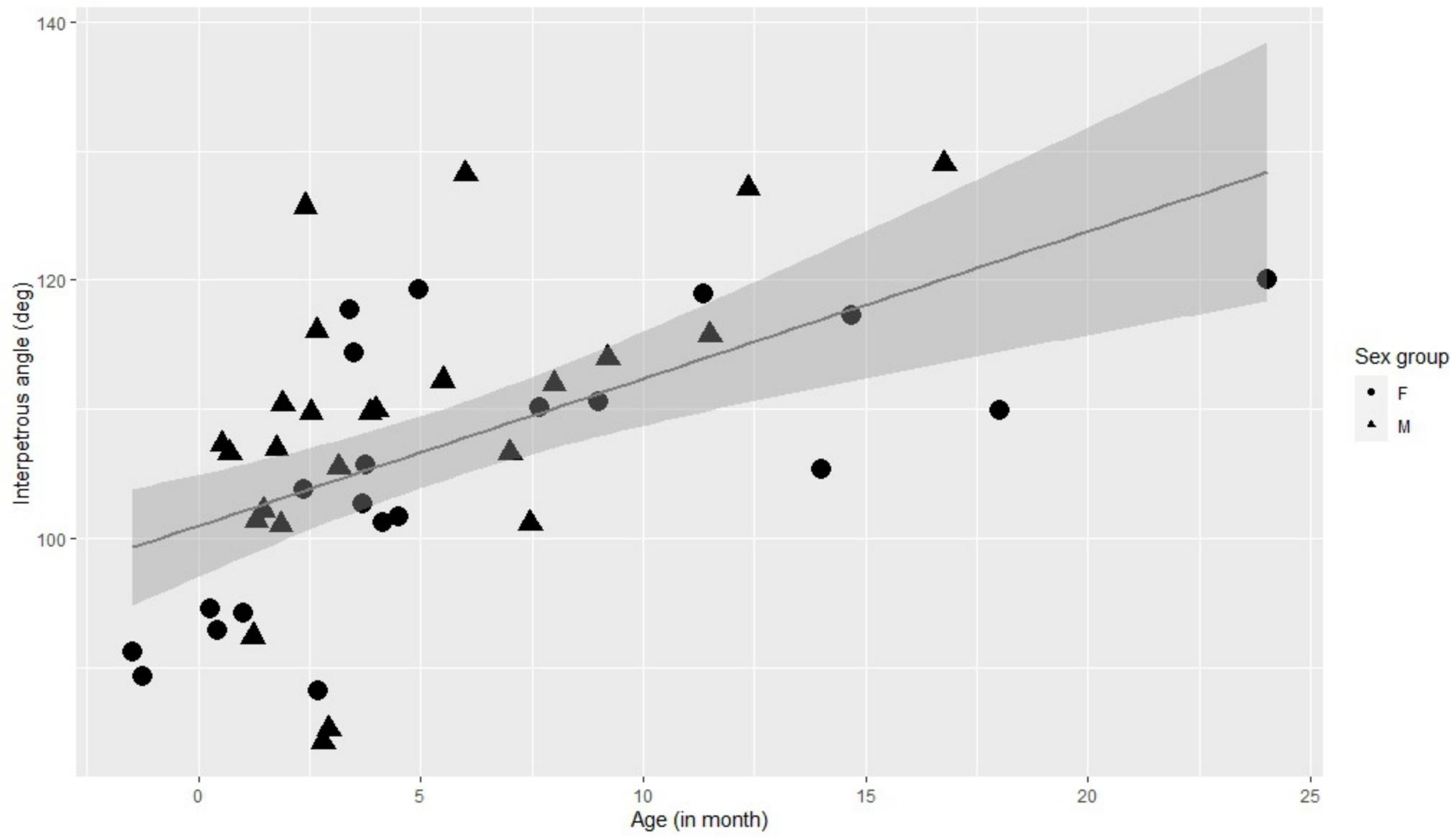
Fig. 2. Relation between transverse cerebellar diameter and biparietal diameter according to age group : TDC/brain BPD x 100 versus age in months. The circle corresponds to the girls and the triangles to the boys.

Fig. 3. Cephalic index according to age group (in months). The circle corresponds to the girls and the triangles to the boys

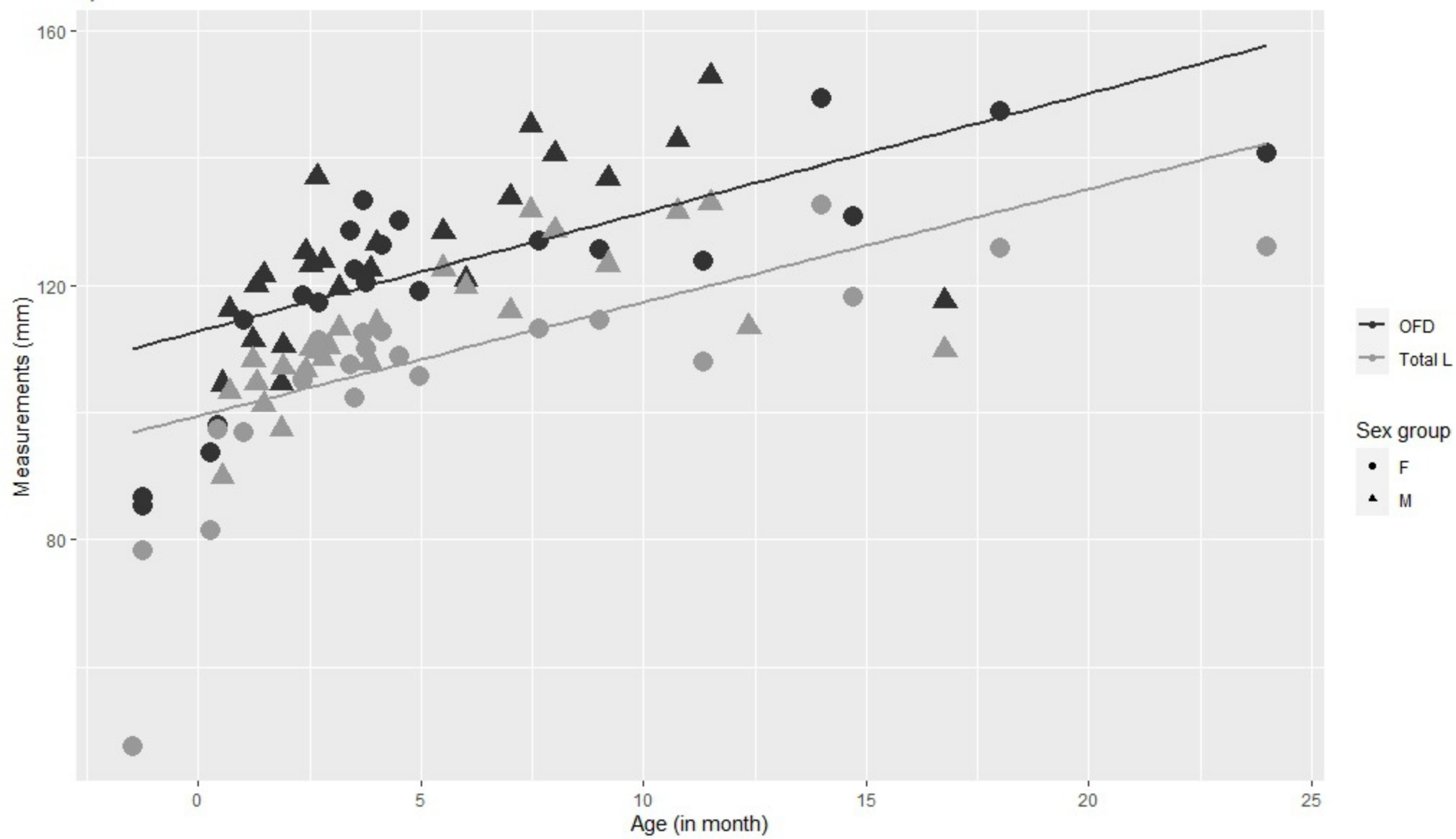
a)



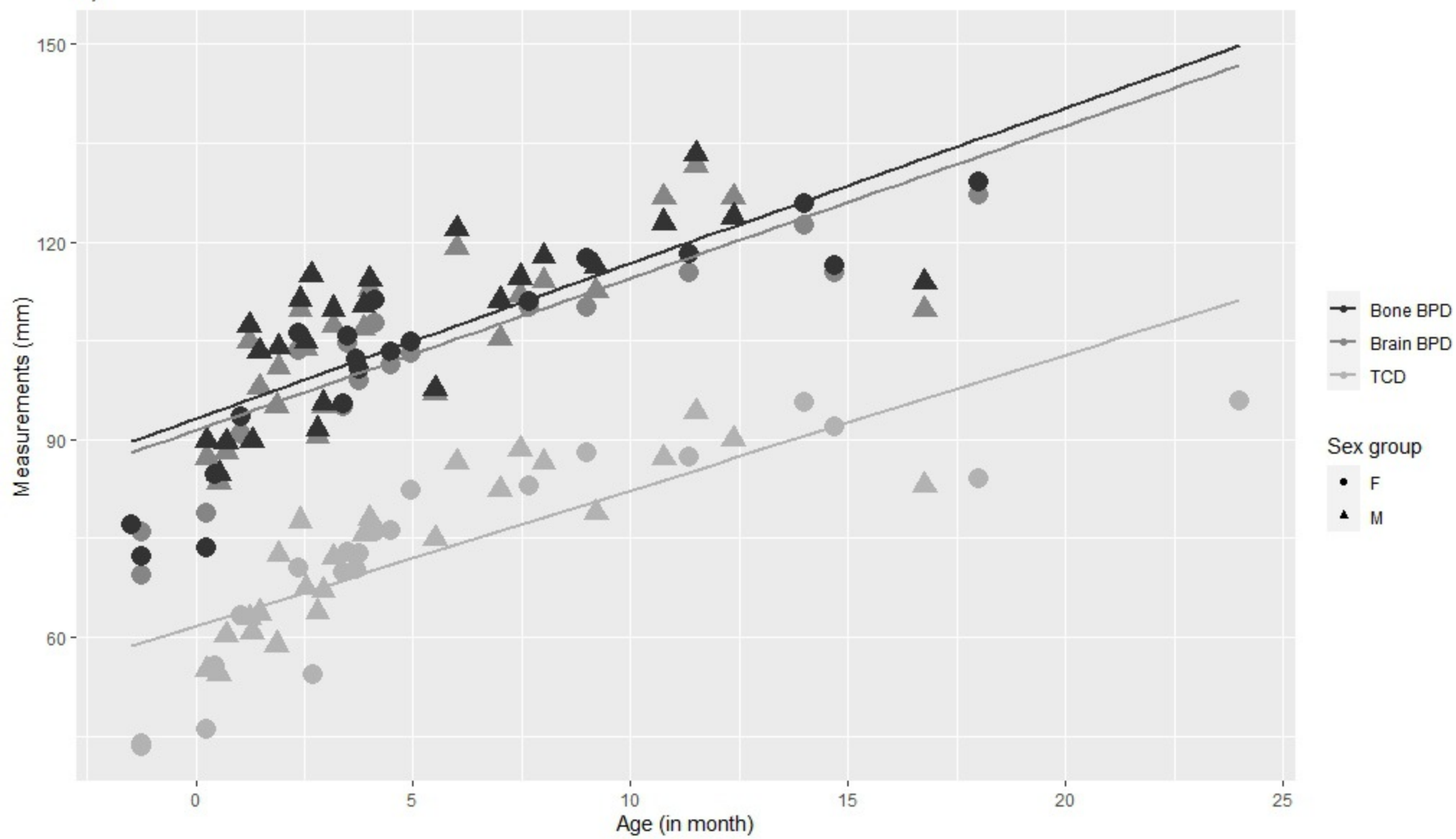
b)



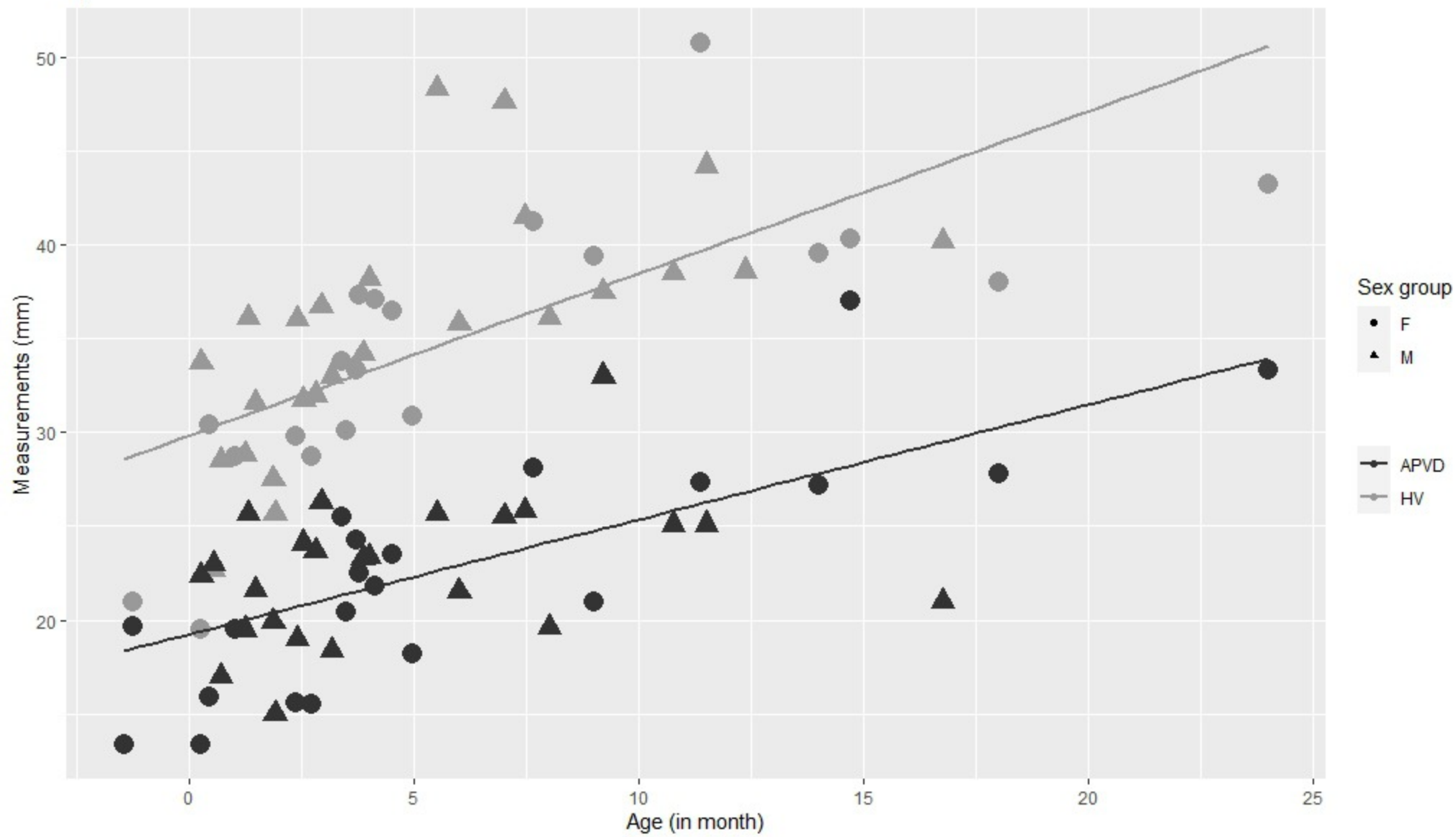
c)



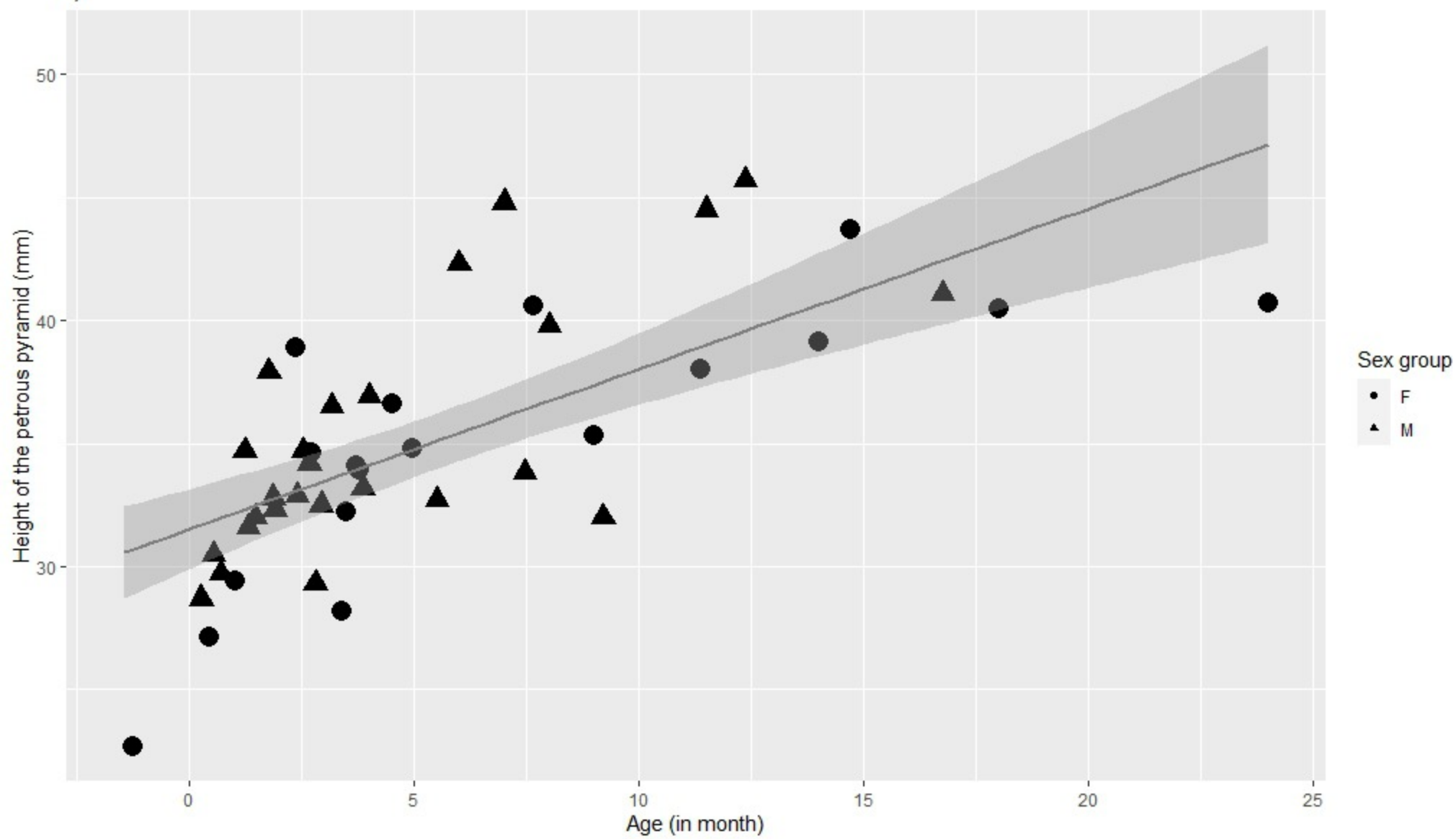
d)



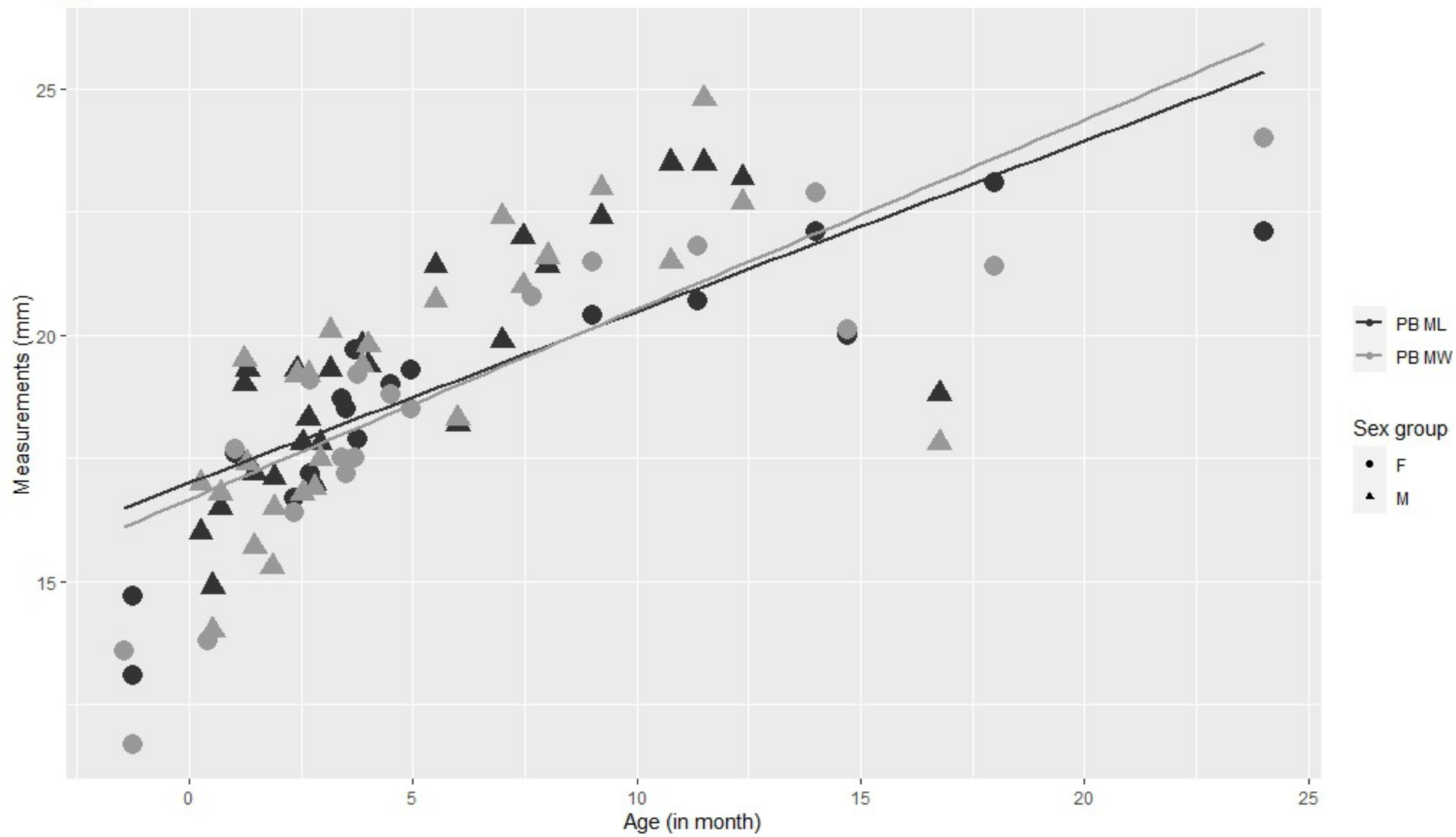
e)



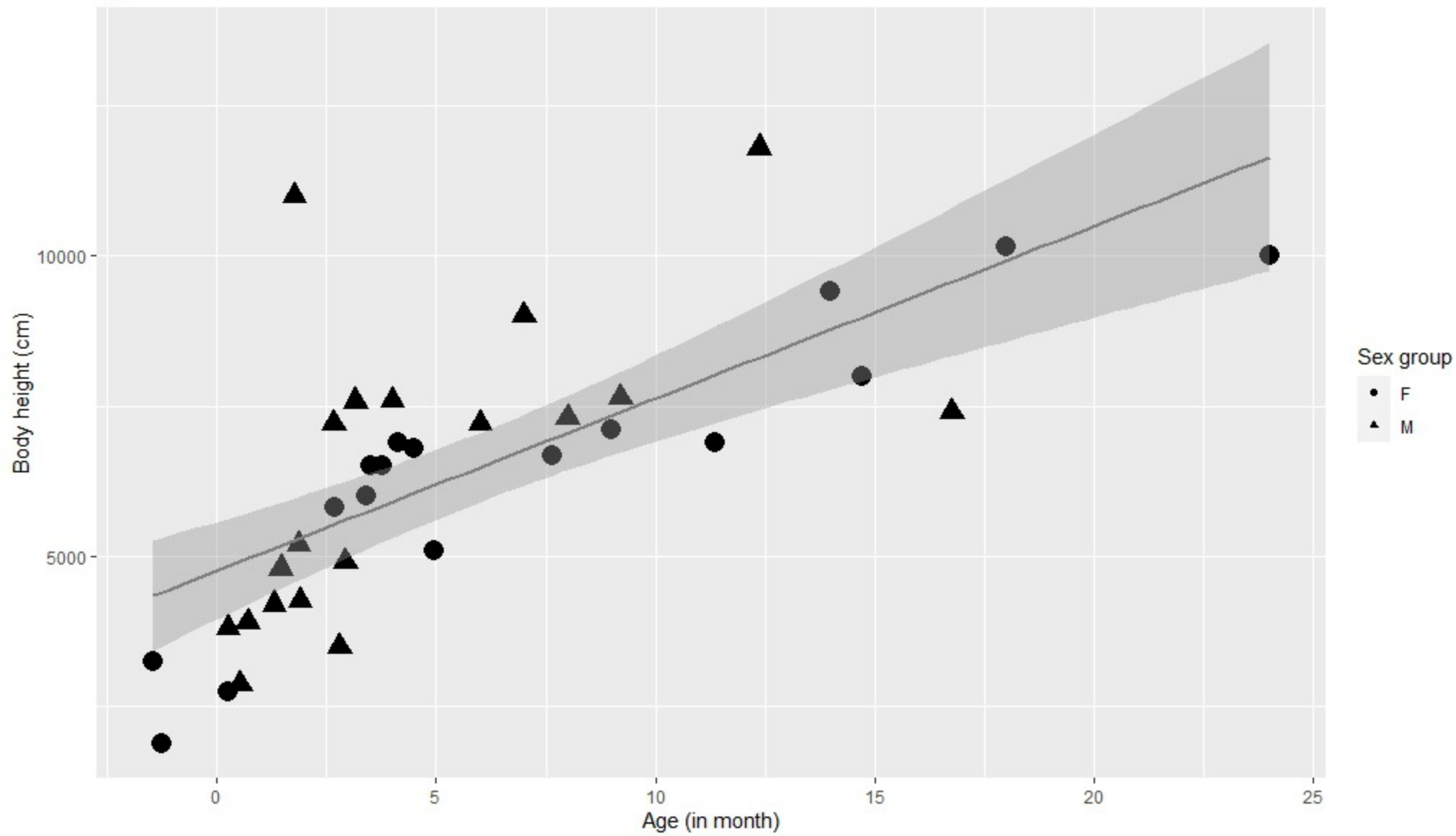
f)



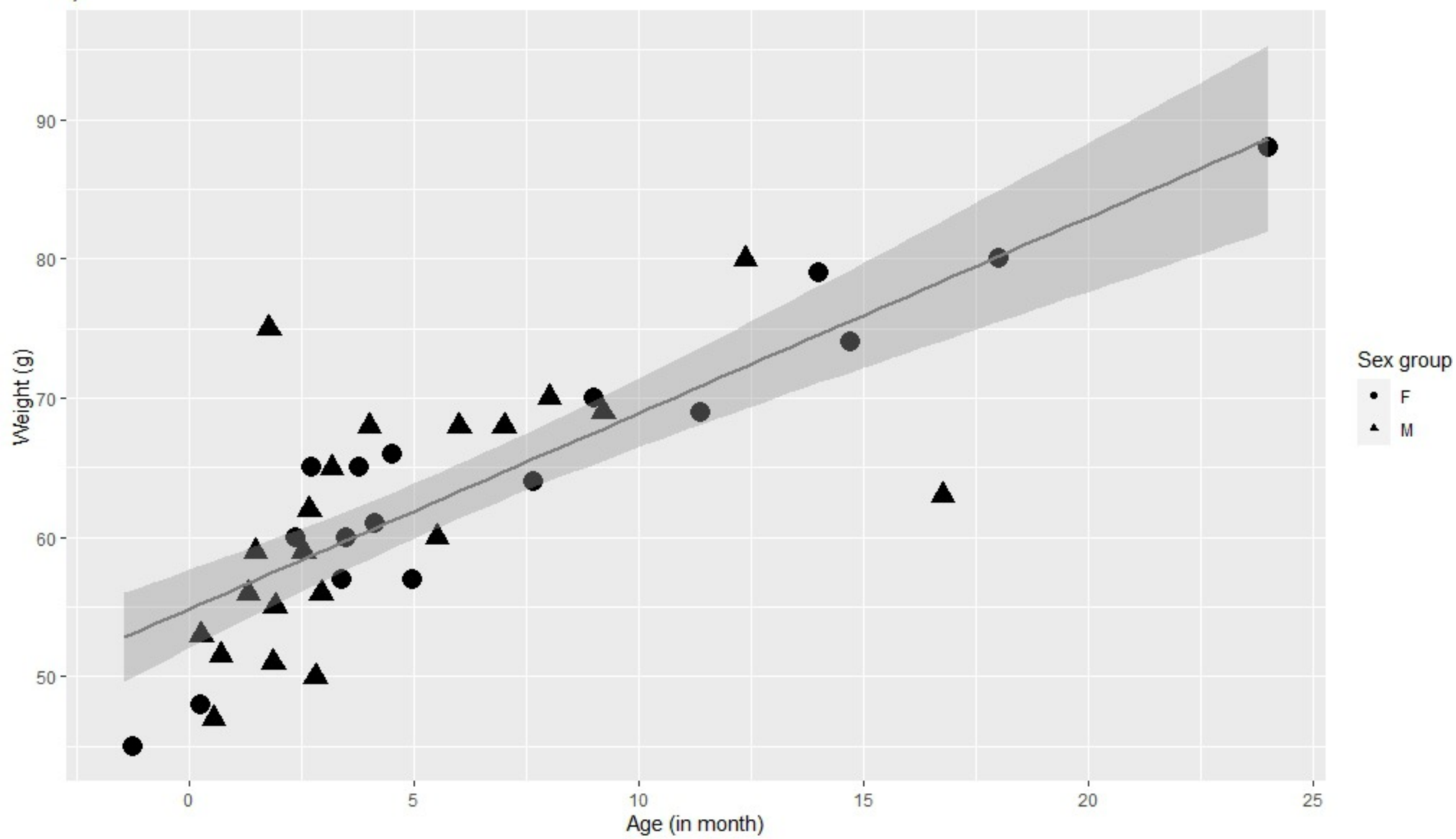
g)



h)



i)



j)

