



HAL
open science

Hepatic artery complications following liver transplantation. Does preoperative chemoembolization impact the postoperative course?

Fabrizio Panaro, Jeanne Ramos, Benoit Gallix, Grégoire Mercier, Astrid Herrero, Halidou Niampa, Georges-Philippe Pageaux, Francis Navarro

► To cite this version:

Fabrizio Panaro, Jeanne Ramos, Benoit Gallix, Grégoire Mercier, Astrid Herrero, et al.. Hepatic artery complications following liver transplantation. Does preoperative chemoembolization impact the postoperative course?. *Clinical Transplantation*, 2014, 28 (5), pp.598-605. 10.1111/ctr.12358 . hal-03562828

HAL Id: hal-03562828

<https://hal.science/hal-03562828v1>

Submitted on 9 Feb 2022

HAL is a multi-disciplinary open access archive for the deposit and dissemination of scientific research documents, whether they are published or not. The documents may come from teaching and research institutions in France or abroad, or from public or private research centers.

L'archive ouverte pluridisciplinaire **HAL**, est destinée au dépôt et à la diffusion de documents scientifiques de niveau recherche, publiés ou non, émanant des établissements d'enseignement et de recherche français ou étrangers, des laboratoires publics ou privés.



Distributed under a Creative Commons Attribution - NonCommercial 4.0 International License

Hepatic artery complications following liver transplantation. Does preoperative chemoembolization impact the postoperative course?

Panaro F, Ramos J, Gallix B, Mercier G, Herrero A, Niampa H, Pageaux G-P, Navarro F. Hepatic artery complications following liver transplantation. Does preoperative chemoembolization impact the postoperative course?

Abstract: Background: Transarterial chemoembolization (TACE) in patients with hepatocellular carcinoma (HCC) may cause damage to the hepatic artery (HA) and impact the postoperative course of the liver transplantation (LT). We aim to describe the relationship between preoperative TACE and the occurrence of histological and radiological hepatic artery complications (HAC).

Methods: All cirrhotic patients with HCC undergoing LT between January 2009 and October 2012 were included and divided in two groups: TACE (group 1) and No TACE (group 2). HA histological complications were reviewed and compared.

Results: Sixty-seven patients were reviewed, 32 in group 1 and 35 in group 2. Both groups were similar in gender, age, cirrhosis origin, and American Society of Anesthesiology (ASA) score. After a mean follow-up of 17 months, 10 radiological HAC occurred: seven in group 1 and three in group 2 ($p = 0.02$). There was one thrombosis in each group: six non-thrombotic complications in group 1 and two in group 2.

Histological screening showed 12 HA injuries in group 1 (three HA wall edemas, five fibrosis, one edema + fibrosis, one hemorrhagic necrosis + thrombosis, two thrombosis) and three in group 2 (two HA wall edemas, one fibrosis) ($p = 0.01$). All these injuries were found at the proper HA and at the right/left HA bifurcation level.

Conclusions: Despite the limits of our study, we found a higher incidence of radiological and histological injury in patients underwent TACE.

Fabrizio Panaro^a, Jeanne Ramos^b, Benoit Gallix^c, Grégoire Mercier^d, Astrid Herrero^a, Halidou Niampa^a, Georges-Philippe Pageaux^e and Francis Navarro^a

^aDepartment of General and Liver Transplant Surgery, University of Montpellier, Hôpital Saint Eloi, ^bDepartment of Pathology and Laboratory Medicine, University of Montpellier, Hôpital Gui de Chauliac, ^cDepartment of Abdominal Imaging, University of Montpellier, Hôpital Saint Eloi, ^dStatistical Analysis Unit, University of Montpellier and ^eDepartment of Hepatology, University of Montpellier, Hôpital Saint Eloi, Montpellier-Cedex 5, France

Key words: artery – complications – hepatocellular carcinoma – liver transplantation – transarterial chemoembolization

Corresponding author: Fabrizio Panaro, MD, PhD, Liver Transplant Unit, Department of Surgery, Montpellier University Hospital, College of Medicine, 80, avenue Augustin Fliche, 34295-Montpellier Cedex 5, France. Tel.: (+33) 04 67 33 67 33; fax: (+33) 04 67 33 76 23; e-mail: f-panaro@chu-montpellier.fr

The abstract was presented at European Society Organ Transplantation (ESOT), September 8–11, Vienna, Austria.

Conflict of interests: None.

Accepted for publication 10 March 2014

Hepatocellular carcinoma (HCC) represents almost 15% of liver transplantation (LT) indications (1). For carcinologic reasons, some patients may need another treatment while waiting for a graft (2, 3). Transarterial chemoembolization (TACE) is one of these treatment options. TACE has been widely used since 1980 for unresectable HCC with good results in several studies (4, 5),

and its positive impact on patient survival was recently confirmed by a meta-analysis (6, 7). Since Starzl's first publications on LT in humans, hepatic artery complications (HAC) have been recognized as a factor of graft loss and death (8–10). HACs may be due to a surgical technique, small diameter, atherosclerosis, or bile leak, etc. (8–10). TACE is also used as a down-staging treatment (2, 3, 7).

TACE, applied directly in HA, may theoretically damage it and be the cause of arterial complication (11–14). However, no report has shown that TACE is a risk factor for HAC.

The aim of this retrospective study was to evaluate the relationship between preoperative TACE, and the apparition of histological and radiological HAC in patients transplanted for HCC.

Materials and methods

Study population

After IRB approval, all medical record files of 227 consecutive transplanted patients with whole grafts between January 2009 and October 2012 were reviewed.

We performed a retrospective study including all consecutive patients with HCC who underwent LT with or without TACE in our center. Seventy-six patients with HCC were inserted on the waiting list, but only 67 patients (60 males and seven females) were finally transplanted.

The patients transplanted were divided in two groups depending on whether they had TACE before transplantation or not:

1. Group 1: with TACE (39 on waiting list and 32 were finally transplanted).
2. Group 2: without TACE (37 on waiting list and 35 were finally transplanted).

The mean age was 58.7 yr old (61.2 yr old in group 1 vs. 59.7 in group 2). In group 2, 13 (37%) patients had a radiofrequency thermoablation as a bridge treatment. The patients did not undergo transplantation because of the progression of the HCC.

Both groups were similar regarding gender, age, medical/surgical history, and cirrhosis etiology. Of 86.4% had a past medical history in group 1 vs. 87.5% in group 2, and 43% had previous abdominal surgery in group 1 vs. 36.3% in group 2 (Table 1). Among them, eight (25%, three right and five left hepatectomies) patients in group 1 and six (17%, three right and three left hepatectomies) in group 2 underwent liver surgery for HCC before LT.

In both groups, alcoholic liver disease and hepatic C virus infections were the main causes of cirrhosis.

No statistical difference was reported between groups concerning American Society of Anesthesiology (ASA) and WHO performance scale (0 and 1). More patients had WHO scale 2 in group 2 than in group 1 (p = 0.005).

Table 1. Recipient characteristics and cardiovascular risks

Parameters	TACE (n = 32)	No TACE (n = 35)	Total (n = 67)	p Value
Number	32	35	67	
Age (yr)	59.87	57.71	58.74	0.23
Patient medical history	24	28	52	0.91
Patient surgical history	25	27	52	1.00
ASA 2	21	18	39	0.72
ASA 3	11	13	24	0.94
WHO scale 0	16	13	29	0.14
WHO scale 1	14	9	23	0.61
WHO scale 2	2	13	15	0.005
Alcohol	16	23	39	0.25
Virus	14	9	23	0.15
CHILD A	24	6	30	0.0002
CHILD B	5	12	17	0.25
CHILD C	3	17	20	0.007
Mean MELD	9.53	17.34	13.61	0.0001
AFP	62 (2–440)	52 (3–501)	–	0.06
Gender (M/F)	28/4	32/3	60/7	0.57
TIPSS	3	5	8	0.46
Recipient cardiovascular risks				
Arteriopathy	3	5	8	0.53
Hypertension	10	10	20	0.94
Diabetes	10	11	21	0.92
Dyslipidemia	3	5	8	0.08
Smoking	25	21	46	0.34
Smoking discontinuation	15	11	26	0.34

ASA, American Society of Anesthesiology; WHO, World Health Organization; MELD, model end-stage liver disease; AFP, alpha-fetoprotein (normal range under 5 ng/mL); M, male; F, female; TIPSS, transjugular intrahepatic portosystemic stent-shunt; TACE, transarterial chemoembolization. Bold values indicate statistical significance (p<0.05).

For cirrhosis severity, we had more CHILD A in group 1 (p < 0.001) and more CHILD C in group 2 (p = 0.01). Mean model end-stage liver disease (MELD) score was 9.72 in group 1 and 17 in group 2 (p < 0.001).

The hepatic artery (HA) anastomosis was performed at the level of the recipient gastroduodenal artery in 65 (97%) cases, and in two (3%), remnant cases were performed with the recipient right HA origin from the superior mesenteric artery.

Selection criteria

All patients affected by HCC were discussed at the weekly multidisciplinary meeting.

TACE was performed in patients according to Barcelona algorithm (15). The TACE procedures were performed only in patients who do not match the Milan criteria but within the University of California San Francisco (UCSF) criteria during the waiting time period. LT was performed only in patients within UCSF criteria (15).

TACE procedure

Three different experienced interventional radiologists (≥ 50 procedures) performed all TACE procedures. Conventional TACE and TACE with drug-eluting beads were performed. Briefly, conventional TACE was performed with an intra-arterial injection of an emulsion of 40–60 mg of doxorubicin (Pfizer, Vienna, Austria) in lipiodol (Guerbet, Milan, Italy) followed by particle embolization with an embolic agent (Bead Block; Biocompatibles, Farnham, UK). TACE with drug-eluting beads was performed with doxorubicin-loaded beads (150 mg doxo per procedure, two flacons 150–300 μm ; DC Bead, Biocompatibles) (5, 16–19).

In the TACE groups, selective or troncular embolization of the HA branches feeding the tumor was performed with a micro catheter inserted in the femoral artery (micro catheter; Progreat, Terumo, Leuven, Belgium). Embolization was performed until stasis was achieved in the second- or third-order branches of the right or left HA (conventional TACE) or until hypostasis was achieved (TACE with drug-eluting beads).

Contrast-enhanced CT or MRI of the liver was performed four to six wks after TACE to assess the effect of embolization on the tumor. In patients with a residual arterially enhancing tumor, another TACE was repeated to treat the residual tumors and any remaining tumor-feeding arteries. In patients with complete tumor necrosis, contrast-enhanced CT or MRI was repeated every three months. In case of recurrence, and if the patients still fulfilled the UCSF criteria, another TACE was performed.

TACE was selective in 27 patients and troncular in five patients. All patients received doxorubicin. Most of them ($n = 20$, 62.5%) had TACE with drug-eluting beads. The mean number of TACE was 1.56 (range: 1–3). The mean interval between last TACE and LT was 4.1 months (range: 1–16).

Surgical technique

All patients had an arterial anastomosis between the proper HA (at the level of the stump of the gastroduodenal or the splenic artery) of the graft and the recipient common HA (at the level of the gastroduodenal artery) (13). The recipient gastroduodenal artery was not ligated and the anastomosis was performed with a running suture using polypropylene (Prolene suture; Ethicon Inc., Johnson & Johnson, Sommerville, NJ, USA) 6/0-7/0-8/0

with the aid of $2.5 \times$ magnification surgical loupes. When the right HA originated from the superior mesenteric artery, vascular reconstruction (aortic patch, splenic, or gastroduodenal artery) was performed using a prolene 6–7/0 running suture to obtain a single anastomotic patch. When HA bifurcation (left and right branches) was low and when an accessory left HA originated from the left gastric artery, vessels were cut as short as possible, but with conservation of a single patch to easily perform the anastomosis. In addition, when the caliber of the proper HA was inferior to 3 mm, we preferred to cut the artery longer but at the level of the gastroduodenal or splenic artery bifurcation to achieve a good-size anastomotic patch. All the anastomoses were performed by experienced transplant surgeons (≥ 50 liver transplant procedures).

Postoperative management and radiological assessment

After LT, all patients were hospitalized in intensive care unit. They underwent Doppler ultrasound (D-US) examination once a day for the first week and twice a week the following month. Measurements included the angle-corrected peak systolic and end-diastolic velocities, the resistive index (RI), and the systolic rise time. A qualitative assessment of the hepatic arterial upstroke was made. Thereafter, the patients were followed by monthly repeated echo D-US and three monthly CT scan. After the first year, the patients were followed by an echo D-US four times per year and a CT scan two times per year. Patients with abnormal D-US and clinical findings underwent an angio-CT scan. We defined radiologic HAC as the presence of abnormal anatomy of the arterial vascular imaging (presence of stenosis, aneurysms, dissection, and thrombosis). The angio-CT evaluated the arteriograms, the presence of the arterial-portal venous shunting, and the portal and supra-hepatic venous system patencies.

Periodical blood test examinations (liver function tests, ALP, GGT, PT, INR) were performed during the entire follow-up. When signs of biliary complications (hepatic pedicle fluid collection or bile ducts intrahepatic dilatation) were detected at D-US or CT scan, MRI cholangiography and liver biopsies were performed.

Patients with back-table arterial reconstruction were not routinely placed on antiplatelet therapy, unless the additional anastomosis involved vessels with a diameter < 3 mm. Patients undergoing arterial thrombectomy (HA thrombosis during the first 15 postoperative days) were routinely placed on

aspirin (100 mg p.o. daily) in the post-transplantation period once the graft showed signs of good function and there was no evidence of bleeding. Immunosuppression included a regimen of tacrolimus (Prograf; Astellas Pharma, Chertsey, UK) as part of a dual or triple drug regimen with prednisone and mycophenolate mofetil (CellCept; Hoffman-LaRoche, Basel, Switzerland) (20).

Histological analysis

The policy of our center is to routinely perform histological analysis of the native liver parenchyma and the hepatic pedicle, searching for metastasis and other abnormalities the day after LT. To conduct this retrospective study, all the native liver sections were reviewed and checked for arterial and biliary tree histological injuries. The native liver arterial samples removed were fixed in 10% formalin, embedded in paraffin, and sectioned (5 μ m) for hematoxylin and eosin staining. All analyses were performed by a single experienced blinded pathologist. The histological HA wall injuries were classified as follows: normal, edema, fibrosis, necrosis/thrombosis, and dissection. Histology of the arterial wall was compared with the liver parenchyma structure in all cases.

Statistical analysis

The summary data are presented as median (range) or mean. Differences between groups were calculated by Fisher's exact test for categorical variables and the Mann-Whitney *U*-test for continuous variables. Patient and graft survival was analyzed by the Kaplan-Meier method. The outcome events were death and the presence of arterial histological complications. Survival curves were compared with the log-rank test. Statistical significance was indicated by *p* values of <0.05. Calculations were made with the SPSS statistical software package (version 11.5; SPSS, Chicago, IL, USA). All analyses were carried out by an experienced statistician.

Results

Donor/recipient vascular risks

Donor/recipients vascular risks were similar in both groups (Table 1). Indeed, there was no difference regarding arteriopathy, diabetes, hyperlipidemia, and tobacco addiction. Among recipients, half of the smokers continued to smoke after LT.

HCC characteristics

Mean age of HCC diagnosis was similar in both groups: 59.36 vs. 57.33 yr in group 1 and group 2, (*p* = 0.32; Table 2). However, there were more patients within Milan criteria in group 2 (*p* = 0.03). The mean number of nodules at the histological analysis of the native liver was 2.9 in group 1 vs. 1.87 in group 2 (*p* < 0.001). The mean alpha-fetoprotein (AFP) level in the group 1 was of 62 (2–440), the mean AFP level in the group 2 was of 52 (3–501), and there was no a significant difference (*p* = 0.06) in AFP levels between the two groups.

The down staging was performed in 18.75% of patients in group 1 within the UCSF criteria at the pre-LT imaging. However, the histological analysis of the native liver showed that the UCSF criteria were fulfilled in only three patients.

Graft/donor characteristics

Grafts were similar in both groups regarding age, cold ischemia time (CIT), and warm ischemia time

Table 2. HCC and hepatic artery characteristics based on native liver histology

Parameters	TACE (n = 32)	No TACE (n = 35)	Total (n = 67)	<i>p</i> Value
Mean age at diagnosis	58	56.14	58.3	0.32
Nodule number	3.03	2.05	2.33	0.0007
Within Milan criteria	17	27	44	0.03
Within UCSF criteria	6	5	11	0.33
Beyond UCSF ^a	9	3	11	0.03
Tumoral necrosis (%)	86.25	NA	–	NA
Truncular HA histology				
Normal	20	32	67	0.0124
Edema	3	2	5	
Fibrosis	6 ^b	1	7	
Necrosis	1	0	1	
Thrombosis	2	0	2	
Segmental HA histology				
Normal	0	28	28	0.001
Edema	32	6	38	
Fibrosis	3	1	4	
Necrosis	0	0	0	
Thrombosis	5	0	5	
Peritumoral histology				
Normal	0	27	27	0.001
Edema	32	8	40	
Fibrosis	0	0	0	
Necrosis	19	0	19	
Thrombosis	18	0	18	
Ductal ischemia	32	0	32	

NA, not applicable; HA, hepatic artery; UCSF, University of California San Francisco; HCC, hepatocellular carcinoma; TACE, transarterial chemoembolization. Bold values indicate statistical significance (*p*<0.05).

^aThese patients were found beyond the UCSF criteria only at the native liver histology.

^bIn one case, edema + fibrosis.

(WIT). Mean age of donors was 49.8 yr in group 1 vs. 46.5 in group 2 ($p = 0.53$). Mean CIT was 429.2 min and 450.7 min in group 1 and 2, respectively. WIT was 56.68 and 64.41 min in group 1 and 2, respectively.

Radiological postoperative arterial complications

Ten (14.93%) radiological HACs were observed (US, CT scan) in total: seven (21.87%) in group 1 and three (8.57%) in group 2 ($p = 0.02$; Table 3). There was one thrombosis in each group, six non-thrombotic complications in group 1, and two in group 2. The mean delay between the LT and the radiological HAC appearance was 27.5 d (range: 1–210 d). All the radiological HACs were reported at the anastomotic site.

The univariate analysis showed no relationship between TACE and HA radiological complications ($p = 0.51$). Table 3 summarizes the radiological arterial complications, their management, and the results.

Histology

Histological screening reported 12 hilar HA injuries in group 1 and three in group 2 ($p = 0.01$; Table 2, Fig. 1). Particularly, the pathologists reported the following: three wall edema, five fibrosis, one edema + fibrosis, one hemorrhagic necrosis + thrombosis, two thrombosis in group 1; two artery wall edema and one fibrosis in group 2 (Fig. 1). All these injuries were found isolated to the arterial wall segment at the anastomotic site (proper HA and/or at the right/left HA bifurcation level [truncular lesions]). Inside the liver parenchyma, the arterial wall histology detected a severe edema in all cases of group 1 and in six cases of

group 2 ($p = 0.001$). In five cases, a segmental thrombosis was also found in group 1. The peritumoral histological analysis found a severe arterial wall edema associated with thrombosis in all patients undergoing TACE. Moreover, we found a peritumoral bile ductal ischemic injuries in all patients of group 1, but no common bile duct lesions were noticed (Table 3).

Follow-up

The overall follow-up was 17 months (Table 4). Medical complications occurred in 17 (53.2%) patients in group 1 vs. 21 (60%) in group 2 ($p = 0.32$). Particularly, sepsis occurred in 9.4% and 14.3% of patients, respectively ($p = 0.12$). Acute rejection was observed in 13.6% and 12.5% ($p = 0.87$), and biliary complications (leakage/stenosis) in 13.6% and 20.8%, in group 1 and 2, respectively ($p = 0.45$).

The overall surgical complications (minor and major) were observed in 28% of patients in both groups ($p = 0.87$). Two patients died in each group, the mortality rates being 6.25% in group 1 and 5.71% in group 2 ($p = 0.73$). The cause of death was the sepsis associated with multi-organ failure in all cases. In our series, three of the four deceased patients had artery complications, including two in group 1 and one in group 2. Two of them were histological complications, and one was radiological.

Discussion

The aim of this study was to investigate the relationship between TACE before LT, and the development of histological and radiological HACs in patients with HCC.

Table 3. Groups 1 (TACE) and 2 (no TACE) radiological arterial complications after LT

Arterial complications	Delays (d)	Management	Results
Group 1 (TACE)			
Recipient arterial dissection	13	Reconstruction with autologous vein graft	Good
Right hepatic artery stenosis	1	Monitoring	Good
Rupture of the pseudoaneurysms	64	Reconstruction with autologous vein graft	Death
Stenosis of the anastomosis	120	Monitoring	Good
Arterial dissection	1	Monitoring	Good
Thrombosis	21	End to end re-anastomosis	Re-thrombosis
Post-anastomotic stenosis	49	Monitoring	Good
Group 2 (no TACE)			
Low RI at echo Doppler (stenosis)	2	Monitoring	Good
Hepatic artery stenosis and pseudoaneurysms	64	Reconstruction with autologous vein graft	Liver abscesses LFT: normal
Thrombosis	51	Reconstruction with autologous vein graft	Good

RI, resistance index; LFT, liver function tests; LT, liver transplantation; TACE, transarterial chemoembolization.

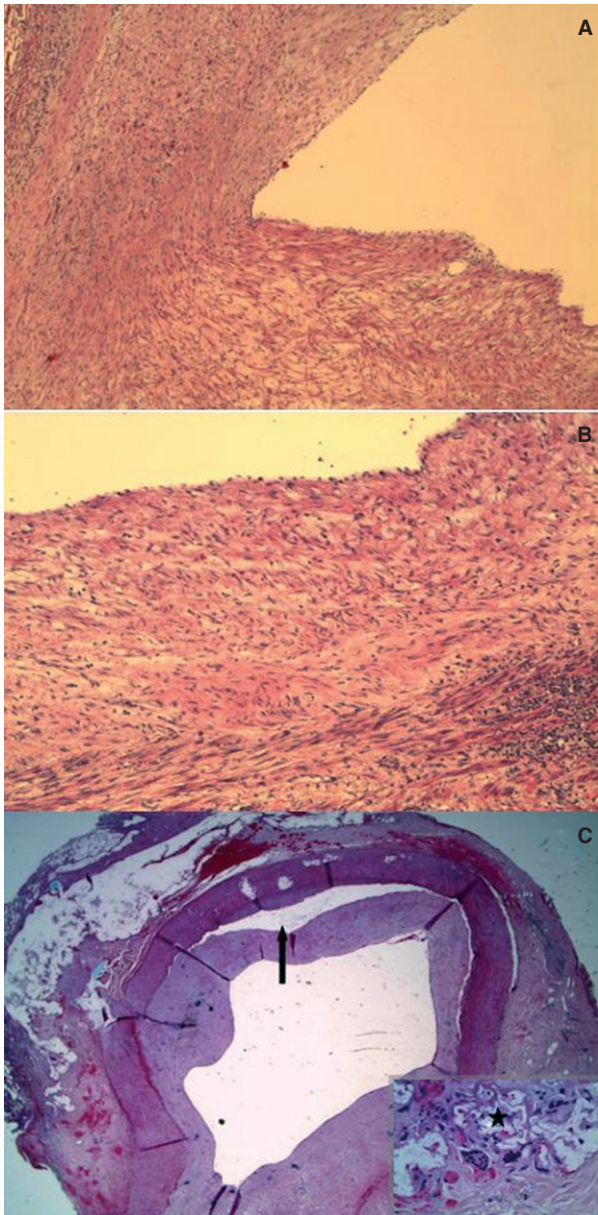


Fig. 1. Different hepatic artery (HA) injuries in patients undergoing transarterial chemoembolization. Light microscopic appearance of the arteries: edema (A); fibrosis (B); thrombosis (C). (A) Original magnification $\times 10$: vascular injury with edema in the intima. (B) Original magnification $\times 20$: arterial wall thickened by accumulation of collagen in the intima. (C) HA pseudoaneurysms (arrow) associated with thrombosis. In the zoom area (bottom right), giant cells with residual chemoembolization agent (*).

We found a statistical association between TACE, and the radiological and histological arterial wall injury.

In the past 25 yr, TACE has been widely used in the treatment of HCC (3, 4, 7). However, this radiological procedure may potentially cause vascular lesions of the arterial wall (9, 11, 14). The injury of the artery may be related to the presence

of the catheter inside the common HA for almost one hour as well as in case of selective procedures (14, 21). Furthermore, the drugs used may also damage and weaken the vessel wall (20, 22, 23). All these factors may contribute to increased risks of arterial complications in patients undergoing TACE after LT (24–26).

In our study, the pathologists reported different grades of arterial wall injury such as edema, fibrosis, necrosis, and thrombosis. We included patients with liver dysfunction, which is often associated with parenchymal fibrosis that usually does not involve the arterial wall structure (27). Therefore, this fibrosis which observed in the arterial wall (media layer) may be related to the exposure to TACE. Furthermore, none of these arterial wall injuries were identified at the time of TACE.

Richard et al. compared the prevalence of hepatic arterial complications in 47 patients who underwent TACE for HCC before LT. They concluded that patients who underwent hepatic arterial chemotherapy were not at increased risk of developing HACs (28).

In the literature since now, only Lin et al. showed that TACE is associated with a higher incidence of dissection of the arterial intima. These dissections of the intima may lead to severe complications such as HA thrombosis and graft loss. They concluded that these dissections after chemoembolization could be a source of intraoperative complications which can be avoided. Intraoperative recognition of these lesions and rigorous dissection of the artery to a safe area would be the key to a good anastomosis (14).

The radiological follow-up for the detection of HAC was very aggressive in our series which allowed picking up all vascular abnormality events in the absence of liver dysfunction.

Recently, in the meta-analysis reported by Bekker et al. (9), arterial thrombosis was a major cause of graft loss (53.1%) and mortality (33.3%) in the early postoperative period. In addition, the frequent need for retransplantation is a burden that adds to the problem of the number of grafts which are already limited. Otherwise, the sequelae of these complications are associated with an exponential increase in health costs (9).

Our study is limited by the number of patients, by its retrospective nature, and by the fact that it is not randomized (selection bias). Moreover, the ASA, CHILD, and MELD scores were different between groups, representing other bias.

Our data show a good outcome of patients undergoing TACE even in cases of very advanced HCC.

Table 4. Morbi-mortality

Parameters	Group 1 TACE (n = 32)	Group 2 No TACE (n = 35)	Total (n = 67)	p Value
Follow-up (months)	10.7	8.41	9.5	0.26
Survival	90.9%	91.8%	91.3%	0.93
Sepsis	n = 3 (9.4%)	n = 5 (8.6%)	n = 8 (8.9%)	0.12
Reject	n = 3 (9.4%)	n = 3 (14.3%)	n = 6 (11.9%)	0.60
Biliary complications	n = 3 (13.6%)	n = 5 (20.8%)	n = 8 (17.4%)	0.53
Other complications	n = 13 (40.6%)	n = 18 (51.4%)	n = 31 (46.3%)	0.26

TACE, transarterial chemoembolization.

In conclusion, arterial complications of liver transplants continue to be a source of mortality and graft loss; therefore, it is necessary to minimize any risk factors.

TACE is related to arterial histological and radiological changes and therefore with a higher risk of vascular complication. The risk of HCC progression with patient dropout of the list should balance the theoretical increased risk of vascular complications.

Authors' contributions

Designed study: FP, JR, BG. Collected data: FP, JR, AH, HN. Analyzed data: FP, JR, BG, GM, GPP. Wrote the paper: FP, BG, GPP, FN.

References

1. EUROPEAN REGISTER OF LIVER TRANSPLANTATION, 2010. Available at: <http://www.elts.org>. Accessed April 2013.
2. JANG JW, YOU CR, KIM CW et al. Benefit of downsizing hepatocellular carcinoma in a liver transplant population. *Aliment Pharmacol Ther* 2010; 1: 415.
3. YAO FY, HIROSE R, LABERGE JM et al. A prospective study on downstaging of hepatocellular carcinoma prior to liver transplantation. *Liver Transpl* 2005; 11: 1505.
4. YAMADA R, SATO M, KAWABATA M, NAKATSUKA H, NAKAMURA K, TAKASHIMA S. Hepatic artery embolization in 120 patients with unresectable hepatoma. *Radiology* 1983; 148: 397.
5. BURREL M, REIG M, FORNER A et al. Survival of patients with hepatocellular carcinoma treated by transarterial chemoembolisation (TACE) using drug eluting beads. Implications for clinical practice and trial design. *J Hepatol* 2012; 56: 1330.
6. SALHAB M, CANELO R. An overview of evidence-based management of hepatocellular carcinoma: a meta-analysis. *J Cancer Res Ther* 2011; 7: 463.
7. LLOVET JM, BRUIX J. Systematic review of randomized trials for unresectable hepatocellular carcinoma: chemoembolization improves survival. *Hepatology* 2003; 37: 429.
8. STARZL TE, MARCHIORO TL, VON KAULLA KN, HERMANN G, BRITTAIN RS, WADDELL WR. Homotransplantation of the liver in humans. *Surg Gynecol Obstet* 1963; 117: 659.
9. BEKKER J, PLOEM S, JONG KP. Early hepatic artery thrombosis after liver transplantation: a systematic review of the incidence, outcome and risk factors. *Am J Transplant* 2009; 9: 746.
10. WARNER P, FUSAI G, GLANTZOUNIS GK et al. Risk factors associated with early hepatic artery thrombosis after orthotopic liver transplantation – univariable and multivariable analysis. *Transpl Int* 2011; 24: 401.
11. IKEDA K, KUMADA H, SAITOH S, ARASE Y, CHAYAMA K. Effect of repeated transcatheter arterial embolization on survival time in patients with hepatocellular carcinoma: an analysis by the Cox proportional hazard model. *Cancer* 1991; 15: 2150.
12. MAJNO PE, ADAM R, BISMUTH H et al. Influence of preoperative transarterial lipiodol chemoembolization on resection and transplantation for hepatocellular carcinoma in patients with cirrhosis. *Ann Surg* 1997; 226: 688.
13. PANARO F, BOUYABRINE H, CARABALONA JP, MARCHAND JP, JABER S, NAVARRO F. Hepatic artery kinking during liver transplantation: survey and prospective intraoperative flow measurement. *J Gastrointest Surg* 2012; 16: 1524.
14. LIN TS, CHIANG YC, CHEN CL et al. Intimal dissection of the hepatic artery following transarterial embolization for hepatocellular carcinoma: an intraoperative problem in adult living donor liver transplantation. *Liver Transpl* 2009; 15: 1553.
15. HSU CY, LEE YH, HSIA CY et al. Performance status in patients with hepatocellular carcinoma: determinants, prognostic impact, and ability to improve the Barcelona Clinic Liver Cancer system. *Hepatology* 2013; 57: 112.
16. SONG MJ, CHUN HJ, SONG DO S et al. Comparative study between doxorubicin-eluting beads and conventional transarterial chemoembolization for treatment of hepatocellular carcinoma. *J Hepatol* 2012; 57: 1244.
17. GIUNCHEDI P, MAESTRI M, GAVINI E, DIONIGI P, RASSU G. Transarterial chemoembolization of hepatocellular carcinoma. Agents and drugs: an overview. *Expert Opin Drug Deliv* 2013; 10: 679.
18. TERZI E, GOLFIERI R, PISCAGLIA F et al. Response rate and clinical outcome of HCC after first and repeated cTACE performed “on demand.” *J Hepatol* 2012; 57: 1258.
19. PATEL SS, ARRINGTON AK, MCKENZIE S et al. Milan criteria and UCSF criteria: a preliminary comparative study of liver transplantation outcomes in the United States. *Int J Hepatol* 2012; 2012: 253517.
20. PANARO F, GALLIX B, BOUYABRINE H et al. Liver transplantation and spontaneous neovascularization after arterial thrombosis: “the neovascularized liver.” *Transpl Int* 2011; 24: 949.

21. ANTOCH G, ROELLE G, LADD SC et al. Selective and sequential transarterial chemoembolization: survival in patients with hepatocellular carcinoma. *Eur J Radiol* 2012; 81: 2290.
22. SHIMOHIRA M, OGINO H, KAWAI T, SAKURAI K, NAKAGAWA M, SHIBAMOTO Y. Use of the triaxial microcatheter method in super-selective transcatheter arterial chemoembolisation for hepatocellular carcinoma. *Br J Radiol* 2011; 84: 184.
23. CHAN AO, YUEN MF, HUI CK, TSO WK, LAI CL. A prospective study regarding the complications of transcatheter intraarterial lipiodol chemoembolization in patients with hepatocellular carcinoma. *Cancer* 2002; 94: 1747.
24. HAMBY BA, RAMIREZ DE, LOSS GE et al. Endovascular treatment of hepatic artery stenosis after liver transplantation. *J Vasc Surg* 2013; 57: 1067.
25. KIM HY, PARK JW, JOO J et al. Severity and timing of progression predict refractoriness to transarterial chemoembolization in hepatocellular carcinoma. *J Gastroenterol Hepatol* 2012; 27: 1051.
26. PRATSCHKE S, MEIMARAKIS G, MAYR S et al. Arterial blood flow predicts graft survival in liver transplant patients. *Liver Transpl* 2011; 17: 436.
27. MA C, BRUNT EM. Histopathologic evaluation of liver biopsy for cirrhosis. *Adv Anat Pathol* 2012; 19: 220.
28. RICHARD HM 3rd, SILBERZWEIG JE, MITTY HA, LOU WY, AHN J, COOPER JM. Hepatic arterial complications in liver transplant recipients treated with pretransplantation chemoembolization for hepatocellular carcinoma. *Radiology* 2000; 214: 775.