



**HAL**  
open science

# Rheumatoid Forefoot Reconstruction in Nonrheumatic Patients: Lesser Metatarsal Head Resection versus Osteotomy

Jean-Charles Giunta, Tanguy Mouton, Michel-Henri Fessy, Jean-Luc Besse

► **To cite this version:**

Jean-Charles Giunta, Tanguy Mouton, Michel-Henri Fessy, Jean-Luc Besse. Rheumatoid Forefoot Reconstruction in Nonrheumatic Patients: Lesser Metatarsal Head Resection versus Osteotomy. *Journal of Foot and Ankle Surgery*, 2021, 60 (2), pp 252-257. 10.1053/j.jfas.2020.03.004 . hal-03562579

**HAL Id: hal-03562579**

**<https://hal.science/hal-03562579>**

Submitted on 10 Mar 2023

**HAL** is a multi-disciplinary open access archive for the deposit and dissemination of scientific research documents, whether they are published or not. The documents may come from teaching and research institutions in France or abroad, or from public or private research centers.

L'archive ouverte pluridisciplinaire **HAL**, est destinée au dépôt et à la diffusion de documents scientifiques de niveau recherche, publiés ou non, émanant des établissements d'enseignement et de recherche français ou étrangers, des laboratoires publics ou privés.



Distributed under a Creative Commons Attribution - NonCommercial 4.0 International License

# Rheumatoid forefoot reconstruction in non-rheumatic patients: lesser metatarsal head resection versus osteotomy

Jean-Charles GIUNTA<sup>2</sup>, Tanguy MOUTON M.D.<sup>2</sup>, Michel-Henri FESSY M.D, Ph.D<sup>1,2</sup>, Jean-Luc BESSE M.D, Ph.D<sup>1,2</sup>

1. Université Lyon 1, IFSTTAR, LBMC UMR-T 9406 - Laboratoire de Biomécanique et Mécanique des Chocs, 69675 Bron Cedex, France.

2. Hospices Civils de Lyon, Centre Hospitalier Lyon-Sud, Service de Chirurgie Orthopédique et Traumatologique, 69495 Pierre-Bénite Cedex, France.

3. Hospices Civils de Lyon, Service de Biostatistique et Bioinformatique, F-69003 Lyon, France; Université de Lyon, F-69000 Lyon, France; Université Lyon 1, F-69100 Villeurbanne, France; CNRS, UMR 5558, Laboratoire de Biométrie et Biologie Evolutive, Equipe Biostatistique-Santé, F-69100 Villeurbanne, France.

## Corresponding author: Jean-Charles Giunta

Email: [jcgiunta@chu-grenoble.fr](mailto:jcgiunta@chu-grenoble.fr)

Tel : (+33) 4 767 666 06

Fax : (+33)4 767 675 75

## Digit orcid of the author

0000-0003-3433-4781

## ABSTRACT 247 words

### Purpose:

In the literature, first metatarsophalangeal joint arthrodesis with lesser metatarsal head resection seems to be a reliable procedure in rheumatoid foot deformity. Maybe this procedure could be proposed in non-rheumatoid severe forefoot deformity (hallux valgus angle  $> 40^\circ$  and lesser metatarsophalangeal dislocation). The aim of this study was to compare radiological and clinical outcomes between lesser metatarsal head resection and lesser metatarsal head osteotomy in non-rheumatoid patients.

### Methods:

Thirty-nine patients (Fifty-six feet) suffering from well-defined non-rheumatoid severe forefoot deformity were retrospectively enrolled in our institution between 2009 and 2015. Metatarsal head resection and metatarsal head osteotomy represented 13 patients (20 feet) and 26 patients (36 feet) respectively. In this observational study, a rheumatoid population (twenty-one patients) was included as the control.

The clinical outcome measures consisted of AOFAS score, FFAM and SF-36. The radiological outcomes were: intermetatarsal angle, hallux valgus angle and MTP alignment.

**Results:**

Mean follow-up was 24 months. Satisfaction rate was respectively 92% for resection, 91 % for osteotomy procedure and 80% for surgery in rheumatoid patients. SF 36 Global score was respectively 80.7 (52.5 – 96.4), 76 (57.7 – 93) and 68.3 (22.6 – 86). No functional outcome difference was found between resection and osteotomy procedures, except that the metatarsal head resection group had poorer results in sports activities than the osteotomy group. Complications were similar between osteotomy and resection ( $p>0.05$ ). The radiological outcomes were improved significantly from preoperative to postoperative.

**Conclusion:**

First metatarsophalangeal joint arthrodesis with lesser metatarsal head resection in non-rheumatoid severe forefoot deformity might be a good therapeutic option.

**Keywords:** rheumatoid forefoot reconstruction, non-rheumatic patient, metatarsal head resection, lesser metatarsal head osteotomy, severe hallux valgus

**Acknowledgments:** We thank Prof. Michel-Henry Fessy (PhD, Md) and Dr. Jean-Luc Besse (PhD, Md) for providing study data and assisting with the manuscript. Furthermore, we would like to thank Dr. Tanguy Mouton (Md) for this assistance during the clinical study.

**Funding:** There is no funding source.

**Compliance with ethical standards**

**Conflict of interest:** The authors declare that they have no conflict of interest.

**Ethical approval:** This study was approved by our local ethic committee.

**Informed consent:** Informed consent was obtained from all individual participants included in the study.

**INTRODUCTION**

Forefoot pain and deformity are frequent complaints in foot and ankle consultations [1-3]. Residual forefoot pain and recurrent deformity might be main causes of patient dissatisfaction [1-3]. Forefoot disorders present a real challenge for surgeons. They have to obtain a sustainable long-term correction by realigning the first ray and to relieve the lateral hyperpressure zones [1-6]. First metatarsophalangeal (MTP) joint arthrodesis with lesser metatarsal head resection is a well-established operation for forefoot deformity in patients with a diagnosis of rheumatoid arthritis (RA) [7-9]. It relieves hallux valgus pain, intractable metatarsalgia and lesser MTP synovitis, while minimizing recurrence. Mann's studies showed good outcomes in RA patients treated with rheumatoid forefoot reconstruction [9]. Nixon et al. reported first MTP arthrodesis coupled with lesser metatarsal head resection as an option for nonrheumatoid patients who failed prior attempts at forefoot reconstruction or with severe forefoot deformity (hallux valgus angle  $> 40^\circ$  and lesser metatarsophalangeal dislocation) [8]. However, to our knowledge, no studies evaluated MTP arthrodesis associated to lesser metatarsal head resection versus MTP arthrodesis and lesser metatarsal head osteotomy.

The purpose of this study was to compare radiological and clinical outcome between lesser metatarsal head resection and lesser metatarsal head osteotomy in non-rheumatoid patients. We hypothesized that resection would yield satisfactory clinical outcomes and sustained radiographic alignment at follow-up.

## METHODS

### Patients

Between 2009 and 2015, 39 patients (56 feet) operated on by single senior surgeon (JLB) for non-rheumatoid severe forefoot deformities in our institution were included. We defined non-rheumatoid severe forefoot deformities as hallux valgus angle  $> 40^\circ$  associated with two or more lesser metatarsophalangeal dislocations [8]. During this period, 21 patients (33 feet) with rheumatoid forefoot deformities were treated operatively. Patients with RA present forefoot pain including metatarsalgia, hallux valgus, and often lesser toe deformity [7-10]. RA patients (RA-group) were included as the reference population [7]. The indication for surgical MTP arthrodesis with lesser metatarsal head resection or osteotomy was symptomatic foot (forefoot pain including metatarsalgia, hallux valgus  $>40^\circ$ ) with metatarsophalangeal dislocation [8]. For the total of 154 MTP arthrodesis and metatarsal head surgery procedures (96 patients) performed during the study period, our exclusion criteria eliminated feet with incomplete clinical or radiological documentation (33 feet in 17 patients), feet with hallux valgus angle  $< 40^\circ$  (12 feet in 8 patients), and feet with fewer than two metatarsophalangeal dislocations (20 feet in 11 patients).

Patients were retrospectively reviewed with a minimal 1-year follow-up performed at our institution. The rheumatoid patients were treated by MTP arthrodesis associated to lesser metatarsal head resection (21 patients 100 %). The non-rheumatoid patients were treated by MTP arthrodesis and lesser metatarsal head resection (HV-R group, 13 patients (20 feet)) or MTP arthrodesis +lesser metatarsal head osteotomy (HV-O group, 26 patients (36 feet)). The mean age was  $64.1 \text{ years} \pm 21.8$  (51–83.2), with 8 men (21%) and 30 women (79 %). Mean body mass index (BMI) was  $24.7 \pm 5.1$  (18.7–35.1). The main demographic data of the series are summarized in Table 1.

### Operative procedure

All patients were operated on by a single senior surgeon (JLB) under general or loco-regional anesthesia, with an ankle tourniquet. The first ray arthrodesis was performed through a medial approach; joint surfaces were prepared with ball and cup reamers. The fixation was then performed with a non-locking screw plate made of titanium alloy (Fyxis<sup>®</sup>, EOS, St Maurice sur Eygues, France) (Fig 1-3). An oblique screw allowed compression of the arthrodesis. The metatarsal head resection was performed by a dorsal transversal approach, the length of the metatarsal being determined prior to surgery to obtain an ideal Lelievre curve (Fig 1-2).

Detailed descriptions of surgical first ray arthrodesis and metatarsal head resection have been previously published [6]. In case of a joint sparing treatment on the lateral rays, the osteotomy was performed according to standard guidelines [10,11]. Lesser metatarsal procedures (Fig 3) comprised Weil osteotomy (n=16), or percutaneous distal metaphyseal metatarsal osteotomy (DMMO) (n=20). Additional procedures were made in 6 patients of the HV-R group (proximal interphalangeal (PIP) fusion, n =7), in 8 patients of the HV-O group (PIP fusion n= 10), and in five patients of the RA group (PIP fusion). The mean surgical time was 66 minutes (40-85), 61 minutes (40-85) and 64 minutes (59-69) respectively in the metatarsal head resection group (HV-R group), metatarsal head osteotomy group (HV-O group) and rheumatoid group (RA group), with no statistical difference. Full weight-bearing was allowed using a rocker-bottom post-operative shoe for 45 days whatever the surgical procedure. Preventive postoperative anticoagulants for 10 days were only prescribed for patients with personal history of deep venous thrombosis.

### Methods of assessment

For the clinical and radiographic evaluation of the patients, the same assessment scheme as in the previous report [8] was used. All eligible patients were contacted for voluntary participation in an initial phone survey. The phone questionnaire was used to obtain postoperative data including overall satisfaction rate with the

surgery (rated by the patient from 0 to 100%, with 100% being the most satisfied), any subsequent reoperations and complications on the forefoot, willingness to undergo the procedure again and need for special durable medical equipment (including orthotics, special shoe wear, or pain medications directly related to the forefoot). If the patient agreed to participate in the phone questionnaire, a follow-up survey was mailed to the patient that included the AOFAS score [12], the Foot and Ankle Ability Measurement (FAAM) [13] questionnaires and the quality of life SF-36 scale [14]. For patients who had operations bilaterally, if the procedures were at different dates, one questionnaire was administered per surgery. At follow-up, clinical evaluation was performed by the surgeon.

Radiographic evaluation consisted of a standard AP foot radiograph and lateral view of the foot [15] pre- and post-operatively. Radiographic parameters included intermetatarsal angle (IMA) [16], hallux valgus angle (HVA) [15], and lesser MTP alignment [8]. IMA is the angle between the longitudinal axis of the first and second metatarsal shafts. HVA was measured between the axes of the first proximal phalanx and metatarsal. Moreover, post-operative radiographs evaluated radiographic union of the first MTP joint arthrodesis and first MTP dorsiflexion angle. First MTP dorsiflexion angle measured on the lateral weightbearing radiograph was the angle between the first metatarsal shaft and proximal phalanx at the arthrodesis site [16]. Radiographic union was defined as bridging bone on at least 2 orthogonal radiographs without any evidence of hardware failure. The absolute values for each parameter were used to better characterize the total correction of the joint in neutral position. MTP alignment was determined by the techniques previously described by Coughlin and Nixon [8, 15]. Sagittal malalignment was based on the overlap of the proximal phalanx on the metatarsal head/distal metatarsal shaft based on the anterior-posterior (AP) radiograph. Axial alignment of the lesser MTP joints was also based on the AP radiograph. These radiographic parameters were evaluated by one of us not involved in the surgical care of the patients.

### **Statistical analysis**

Normal distribution was tested using the Kolmogorov-Smirnov test. The Student's t test was used to compare demographic, preoperative and postoperative clinical and radiographic parameters. Fisher's exact test was used for binominal data. ANOVA test was used for comparisons between surgical procedures and functional scores. Stata 14.0 (Stata Corporation, College Station, TX, USA) software was used for statistical analysis. All statistical procedures were performed with a significance level of  $\alpha = 0.05$ .

### **Ethical approval**

This study was approved by the Helsinki Declarations. All individual participants included in the study were informed and consented.

## **RESULTS**

The median follow-up was  $24 \pm 13$  (12–84) months. Mean follow up was respectively  $20 \pm 16$  (12–84),  $17 \pm 14$  (14–7) and  $35 \pm 20$  (12–84) months in group HV-R, HV-O and RA.

### **Clinical results**

Satisfaction rate was respectively 92% for resection (HV-R group), 91% for osteotomy (HV-O group) and 80% for surgery in rheumatoid patients (RA group). The differences were not statistically significant ( $p > 0.05$ ).

The mean global SF36 for the HV-R group was  $80.7 \pm 20.5$  (52.5 – 96.4),  $76.0 \pm 22.2$  (57.7 – 93) for the HV-O group and  $68.3 \pm 24.9$  (22.6 – 86) for the RA group. Mean AOFAS score was respectively  $82.0 \pm 16.8$  (60 – 90),  $77.0 \pm 18.6$  (72 – 90) and  $80.0 \pm 19$  (42 – 90) for the HV-R, HV-O and RA groups (Table 2).

The differences were not statistically significant ( $p > 0.05$ ). The HV-O group had better FAAM sport scores than the HV-R or RA groups ( $p < 0.05$ );  $82.8 \pm 24.7$  (31 – 100),  $59.4 \pm 23.5$  (17.8 – 100), and  $68.7 \pm 27.2$  (25 – 96.8) respectively. However, FAAM activities of daily living showed no significant difference between the three groups (Table 2).

### **Complications**

Seventeen post-operative complications (52%) were recorded in the RA group, versus six (30%) and two complications (6%) in the HV-R and HV-O groups. The differences were not statistically significant ( $p > 0.05$ ). The complications are summarized in Figure 4. Complications did not significantly differ between the HV-R group and HV-O group ( $p > 0.05$ ). One patient of the R-HV group (5%) and 2 of the O-HV group (6%) had residual metatarsalgia. All patients of the RA group were free from metatarsalgia. Three patients in the RA group (9%) had subsequent reoperations (removal arthrodesis) at the time of final follow-up.

### **Radiographic measurements (Table 3)**

Pre-operatively, hallux valgus angle was more severe in the HV-R group ( $54.0^\circ \pm 16.9$  (41-67)) than in the HV-O group ( $45.5^\circ \pm 12.1$  (41-58)) or RA group ( $45.0^\circ \pm 12$  (41-64)). However, the differences were not statistically significant ( $p > 0.05$ ). 32 MTP first ray arthrodeses in the RA group (97%) achieved a total bony union in forty-five days. At forty-five days, 100% of MTP first ray arthrodeses had total fusion in the HV-O group and HV-R group. We did not detect any significant relationships between group and rate of radiological fusion or the time to union. MTP joint alignment improved significantly from preoperative to postoperative ( $p < 0.001$ ). Radiographic parameters (IMA and HVA) improved significantly with surgery ( $p < 0.05$ ).

ANOVA test did not show significant difference between the different groups for any radiographic parameter ( $p = 0.18$ ) (Table 3).

## **DISCUSSION**

Metatarsal head resection is an original procedure in severe forefoot deformity [1, 3, 8]. The good choices in terms of surgical management (resection or osteotomy treatment) remain not to be established [1, 3, 8]. Metatarsal head resection seems to be comparable to metatarsal head osteotomy. The present results, we suggest that first metatarsophalangeal joint arthrodesis with lesser metatarsal head resection in non-rheumatoid severe forefoot deformity (Figs 1, 2) might be a good therapeutic option. This procedure showed good results at clinical and radiographic follow-up in the most severe degenerative cases. To our knowledge, we found only two studies used rheumatoid forefoot reconstruction in the non-rheumatoid population [4, 8]. None compared osteotomy procedures to metatarsal head resection for metatarsalgia.

First MTP fusion is an effective surgery for patients with idiopathic hallux valgus [6, 8, 19-21]. Coughlin demonstrated, at a mean follow-up of over 8 years, that 100% of patients had good to excellent outcomes [19]. Arthrodesis has also been shown to be a reliable treatment after failed previous hallux valgus. Lipscomb argued for primary arthrodesis in severe hallux valgus deformity [20]. De Sandis proved that first MTP joint arthrodesis was successful for functional outcome, particularly for daily activities. Most patients had little to no functional limitation and were satisfied with their outcome. The greatest functional improvements were

seen in patients' ability to walk distances and perform low-impact sport activity [21]. Moreover, arthrodesis consolidation for these patients was complete [8, 19, 21]. In our study, the fusion rate was 99%.

First MTP arthrodesis combined with lesser metatarsal head resection has also been described for rheumatoid forefoot reconstruction [5, 7]. Coughlin found more than 90% excellent and good results, with 80% of patients very satisfied. Coughlin demonstrated, with over 6 years follow-up, that rheumatoid forefoot reconstruction (MTP arthrodesis associated to lesser metatarsal head resection) had 49% excellent outcomes and 47% good results [5]. Recently, Nixon reported that 80% patients had excellent satisfaction with decreased postoperative pain [8]. Mann reported, in 1984, that first MTP arthrodesis and lesser metatarsal head excision can relieve forefoot pain in patients with RA [18]. In our study, this surgical procedure was successful, with good functional outcomes for three scores (AOFAS, SF-36 and FFAM) and a low surgical revision rate (3%).

Metatarsal head resection in rheumatoid forefoot was reported to have good results on pain (no postoperative metatarsalgia) and allowed the correction rheumatoid deformities of the forefoot [5, 7, 9, 17]. Recurrent metatarsalgia after hallux valgus correction can occur in up to 50% cases [3]. Hofstaetter et al. reported a 12% incidence of recurrent lesser MTP dislocations after Weil osteotomy [22]. Besse et al. [3] pointed out that DMMO and Weil osteotomy were similar for AOFAS score, residual metatarsalgia, and MTP joint motion range after 1 year. Nevertheless, the time to postoperative recovery was longer after DMMO, due to higher incidence of residual metatarsalgia (24% vs. 7%) after 3 months. In the present study, the rate of residual metatarsalgia was 6% at 24 months follow-up. The rate of residual metatarsalgia in metatarsal head osteotomy remains controversial despite consensus statements and guidelines [3].

It could be interesting to propose metatarsal head resection for severe forefoot deformity [3]. No studies compared osteotomy versus metatarsal head resection. The rate of residual metatarsalgia in the HV-R group was 5%. Resection seems to be as effective as osteotomy.

Nixon [8] showed that first MTP arthrodesis combined with lesser metatarsal head resection, in non-rheumatoid population, provided excellent satisfaction. Moreover, pain scores significantly decreased, from 6.2 preoperatively to 1.9 postoperatively. Mann reported 83% good to excellent results and no increase in painkiller consumption at a mean follow-up of 5 years [4]. We found the same results, with functional outcomes similar to the RA population. Patients reported decreased pain and increased walking capacity after surgery. Functional score were better for the HV-R group than the HV-O group: probably these patients had greater functional demand than the HV-R and RA groups. The complications rate in the HV-O and HV-R groups was low, with no reoperations, confirming the literature [4, 8]. For radiographic parameters, Nixon [8] and the present study demonstrated that MTP joint alignment improved significantly from preoperative to postoperative, with joint dislocation rates decreasing from 60% to 22%, respectively. Coughlin found less toe dislocation in the sagittal plane: 70% preoperatively versus 7% postoperatively [5]. HVA and IMA were better postoperatively than preoperatively. Like Mann and Nixon, we do not routinely offer this surgery as a first-line intervention in patients without a diagnosis of inflammatory or rheumatoid arthritis or in patients with lower functional demand whose previous surgeries left them with multiple sites of deformity and pain in both the great and lesser toes. The data showed that the resection procedure provided a low complications rate, high patient-reported satisfaction, and decreased pain scores at follow-up.

Some limitations can be pointed out. Firstly, our follow-up period was relatively short (two years). Secondly, this study did not find any significant association between surgical procedures and functional outcomes. We suppose that the number of patients in each surgical group was not enough to show significant differences. The last limitation was the retrospective design with non-matched comparison. Nevertheless this was a

comparative study. The three groups were homogeneous (no difference between demographic parameters) and we had a larger population (89 feet) than Nixon (15 feet), or Mann (18 feet) [8, 18].

First metatarsophalangeal joint arthrodesis with lesser metatarsal head resection in non-rheumatoid severe forefoot deformity might be a good therapeutic option. In an experienced center, it provides satisfactory clinical and radiological results. Complications were equivalent to those of metatarsal head osteotomy. Daily life activities were not impacted whatever the surgical procedure. We could use metatarsal head resection in non-rheumatoid severe forefoot deformity.

**Acknowledgments:** XXXXX

**Funding :** There is no funding source.

**Compliance with ethical standards**

**Conflict of interest :** The authors declare that they have no conflict of interest.

**Ethical approval :** This study was approved by our local ethic committee.

**Informed consent :** Informed consent was obtained from all individual participants included in the study.

## **REFERENCES**

- [1] Raymakers R, Waugh W (1971) The treatment of metatarsalgia with hallux valgus. *J Bone Joint Surg Br* 53:684–687.
- [2] Mann JJ. et al (2013) Low profile titanium plate construct for early weightbearing with first metatarsophalangeal joint arthrodesis. *The Journal of Foot & Ankle Surgery* 52:460–464
- [3] Besse JL (2017) Metatarsalgia. *Orthop Traumatol Surg Res.* Feb;103(1S):S29-S39. doi: 10.1016/j.otsr.2016.06.020. Epub 2017 Jan 18. Review.
- [4] Mann RA, Chou LB (1995) Surgical Management for Intractable Metatarsalgia. *Foot Ankle Int* 16:322–327. doi: 10.1177/107110079501600602
- [5] Coughlin MJ (2000) Rheumatoid forefoot reconstruction. A long-term follow-up study. *J Bone Joint Surg Am* 82:322–341.
- [6] Hyer C. et al. (2012) A retrospective Comparison of four plate constructs for first metatarsophalangeal joint fusion: static plate, static plate with lag screw, locked plate, and locked plate with lag screw. *The Journal of Foot & Ankle Surgery* 51:285 – 287
- [7] Matsumoto T. (2014) Midterm results of resection arthroplasty for forefoot deformities in patient with rheumatoid arthritis and the risk factors associated with patient dissatisfaction. *The Journal of Foot and Ankle Surgery* 53:41 – 46
- [8] Nixon DC, McKean RM, Klein SE, et al (2017) Rheumatoid Forefoot Reconstruction in the Nonrheumatoid Patient. *Foot Ankle Int* 38:605–611. doi: 10.1177/1071100717696253
- [9] Mann RA, Schakel ME (1995) Surgical Correction of Rheumatoid Forefoot Deformities.



Foot Ankle Int 16:1–6. doi: 10.1177/107110079501600101

[10] Trieb K., Hofstaetter S.G., Panotopoulos J. et al (2013) The Weil osteotomy for correction of the severe rheumatoid forefoot. *International Orthopaedics (SICOT)*37: 1795. <https://doi.org/10.1007/s00264-013-2011-5>

[11] Henry J, Besse JL, Fessy MH (2011) Distal osteotomy of the lateral metatarsals: A series of 72 cases comparing the Weil osteotomy and the DMMO percutaneous osteotomy. *Orthop Traumatol Surg Res* 97:S57–S65. doi: 10.1016/j.otsr.2011.07.003

[12] Schneider W. & Jurenitsch S (2016) Normative data for the American Orthopedic Foot and Ankle Society ankle-hindfoot, midfoot, hallux and lesser toes clinical rating system. *International Orthopaedics (SICOT)* 40: 301. <https://doi.org/10.1007/s00264-015-3066-2>

[13] Martin RL, Irrgang JJ, Burdett RG, et al (2005) Evidence of validity for the Foot and Ankle Ability Measure (FAAM). *Foot Ankle Int* 26:968–983. doi: 10.1177/107110070502601113

[14] SooHoo NF, Shuler M, Fleming LL (2003) American Orthopaedic Foot and Ankle Society Evaluation of the validity of the AOFAS Clinical Rating Systems by correlation to the SF-36. *Foot Ankle Int* 24:50–55. doi: 10.1177/107110070302400108

[15] Coughlin MJ, Jones CP (2007) Hallux valgus: demographics, etiology, and radiographic assessment. *Foot Ankle Int* 28(7):759-777

[16] Dalat F, Cottalorda F, Fessy M-H, Besse J-L (2015) Does arthrodesis of the first metatarsophalangeal joint correct the intermetatarsal M1M2angle? Analysis of a continuous series of 208 arthrodeses fixed with plates. *Orthop Traumatol Surg Res* 101:709–714. doi: 10.1016/j.otsr.2015.06.021

[17] Graham CE (1994) Rheumatoid Forefoot Metatarsal Head Resection Without First Metatarsophalangeal Arthrodesis. *Foot Ankle Int*15:689–690. doi: 10.1177/107110079401501213

[18] Mann RA, Thompson FM (1984) Arthrodesis of the first metatarsophalangeal joint for hallux valgus in rheumatoid arthritis. *J Bone Joint Surg Am.* 66(5):687-692.

[19] Coughlin MJ, Grebing BR, Jones CP (2005) Arthrodesis of the first metatarsophalangeal joint for idiopathic hallux valgus: intermediate results. *Foot Ankle Int* 26(10):783-792

[20] Lipscomb PR (1979) Arthrodesis of the first metatarsophalangeal joint for severe bunions and hallux rigidus. *Clin Orthop Relat Res.* 142:48-54.

[21] DeSandis, Pino A, Levine DS, Roberts M, Deland J, O'Malley M, Elliott A (2016) Functional Outcomes Following First Metatarsophalangeal Arthrodesis. *Foot Ankle Int.* 2016 Jul;37(7):715-21. doi: 10.1177/1071100716642286. Epub 2016 Apr 8.

[22] Hofstaetter SG, Hofstaetter JG, Petroutsas JA, et al (2005) The Weil osteotomy: a seven-year follow-up. *J Bone Joint Surg Br* 87:1507–1511. doi: 10.1302/0301-620X.87B11.16590

## TABLES

Parameters	HV-R	HV-O	RA	p value
Number of patients (feet)	13 (20)	26 (36)	21(33)	NS
Follow-up (months)	20 ± 16 (12–84)	17 ± 13(12–84)	35 ± 20 (12–84)	NS
Age (years)	68.3± 24.9 (51.6 – 83.2)	67.4± 20.2(51-76.6)	56.5± 20.4(40 – 71.3)	NS
Sex (%)				
male	2 (29%)	2(14%)	4 (23%)	NS
female	5 (71%)	12 (86%)	13 (77%)	NS
Side (%)				
right	7 (64%)	9 (60%)	11 (41%)	NS
left	5 (36%)	5 (40%)	16 (59%)	NS
Height (cm)	166 ± 11 (152–190)	164 ± 9 (147–185)	169±7.7 (146-179)	NS
Weight (kg)	67 ± 15 (42–97)	63 ± 13 (45–103)	66 ± 12 (49–103)	NS
Body mass index (kg/m <sup>2</sup> )	24.5± 5.5(18.7 – 33.6)	24.6 ± 4 (18.7–29.3)	25.1±5.9 (18.7 – 35.1)	NS

*Values of continuous parameters are expressed as mean ± SD with range in parentheses*

**Table 1 : Demographic parameters of the three study groups**

Scores	HV-R	HV-O	RA	p (ANOVA) value
SF 36 Physical	72.1±23.6 (44 – 100)	78.1± 22.2 (49.3 – 95)	64±24.9 (15.2 – 87)	NS
SF 36 Mental	75.7± 20.3 (45 – 92.8)	71.3± 19.8 (49.6 – 90)	63.0± 24.1 (30 – 81)	NS
SF36 Global	80.7±20.5 (52.5 – 96.4)	76.0±24.5 (57.7 – 93)	68.3± 20.6 (22.6 – 86)	NS
AOFAS	82.0± 16.8(60 – 90)	77.0±15.6 (72 – 90)	80.0 ± 19 (42 – 90)	NS
FAAM ADL	96.4±21.3 (45.2 – 100)	92.9±12.3 (73.7 – 100)	89.2±18.7 (56.7 – 97.6)	NS
FAAM SPORT	59.4±23.5 (17.8 – 100)	82.8±24.7 (31 – 100)	68.7±27.2 (25 – 96.8)	<b>p&lt;0.05</b>

**Table 2. Relationship between surgical procedure and functional outcomes**

Radiographic parameters	HV-R	HV-O	RA	p (ANOVA) value
<b>HVA angle pre-operative</b>	54.0°± 16.9 (41-67)	45.5° ± 12.1(41-58)	45.0°± 12 (41-64)	ns
<b>HVA angle post-operative</b>	18.0°± 6.3 (8-28)	14.5°± 4.2 (7-31)	11.0°± 6.7 (3-22)	ns
<b>p-value</b>	0.003	<0.001	<0.001	
<b>First MTP DF angle post-operative</b>	25.0°± 13(15-40)	23.0°± 8.5(13-30)	22.0°± 8.3(16-35)	ns
<b>IMA angle pre-operative</b>	16.0°±7.9 (12-25)	16.5°± 5.3(10-26)	13.0± 6.9(10-32)	ns
<b>IMA angle post-operative</b>	7.0°±3.6(3-13)	7.5°±2.8 (5-10)	6.0°± 3.3 (4-12)	ns
<b>p-value</b>	0.003	<0.001	<0.001	
				<b>p (Chi<sup>2</sup>) value</b>
<b>Lesser toe alignment pré-operative</b>				
alignated	0/64 (0%)	44/80 (40%)	8/108 (7%)	ns
dislocated	64/64 (100%)	56/80 (60 %)	100/108 (93%)	ns
<b>p-value</b>	<0.001	<0.001	<0.001	
<b>Lesser toe alignment post-operative</b>				
alignated	49/64 (89%)	74/80 (90%)	102/108 (94%)	ns
dislocated	15/64 (11%)	26/80 (10%)	6/108 (6%)	ns
<b>p-value</b>	<0.001	<0.001	<0.001	

**Table 3. Relationship between surgical procedure and radiographic parameters**

## LEGENDS FIGURE

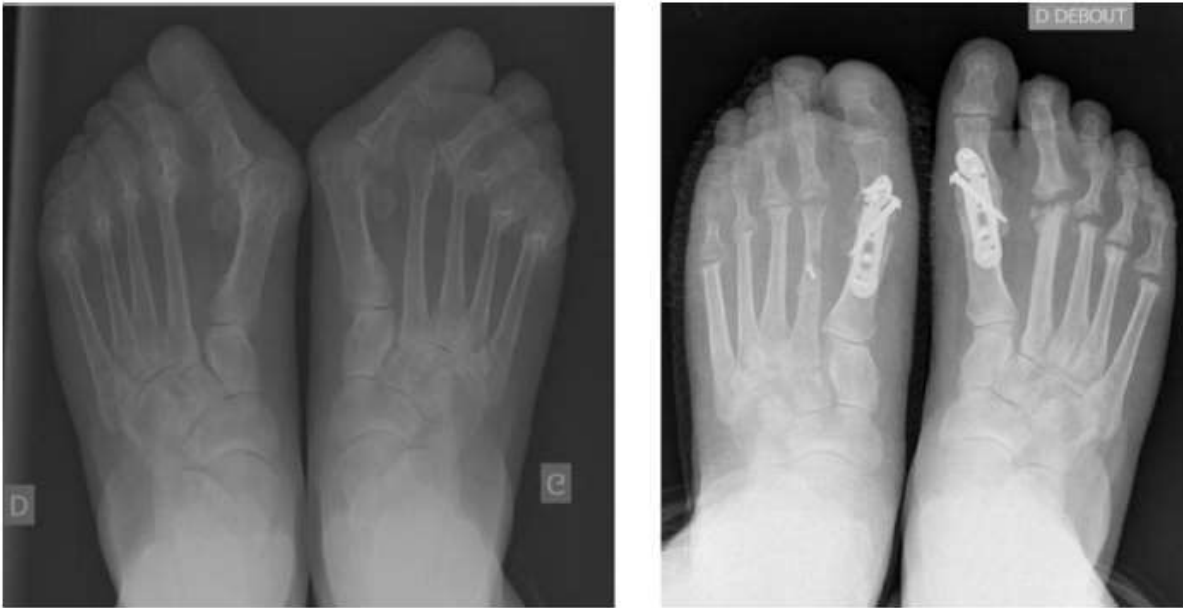

Figure 1.

**Figure 1.** Forefoot rheumatoid preoperative. First arthrodesis with lesser head metatarsal resection at 1-year follow-up

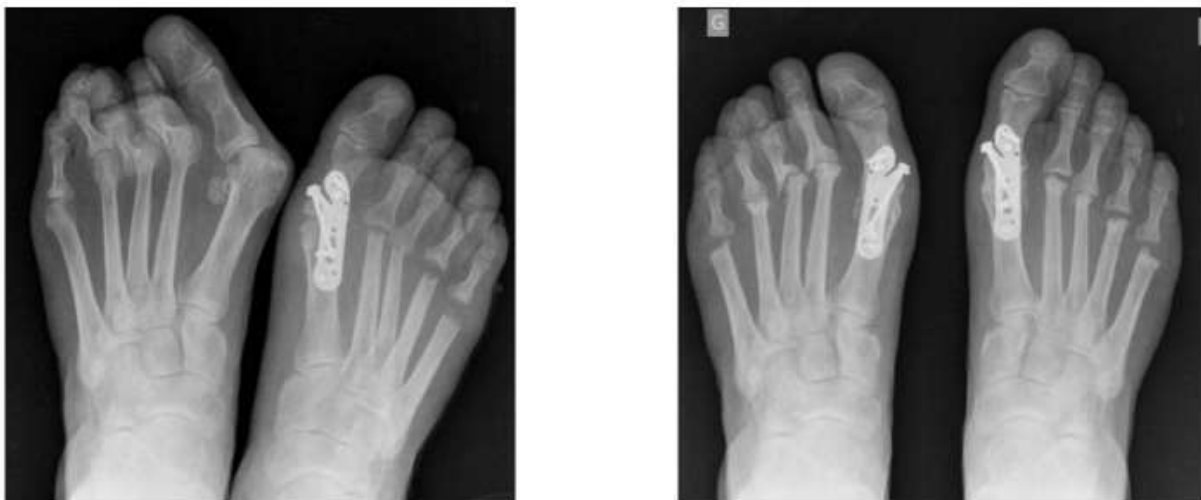

Figure 2.

**Figure 2.** Severe hallux valgus with dislocation M2, M3, M4. First arthrodesis with lesser head metatarsal resection at 1-year follow-up

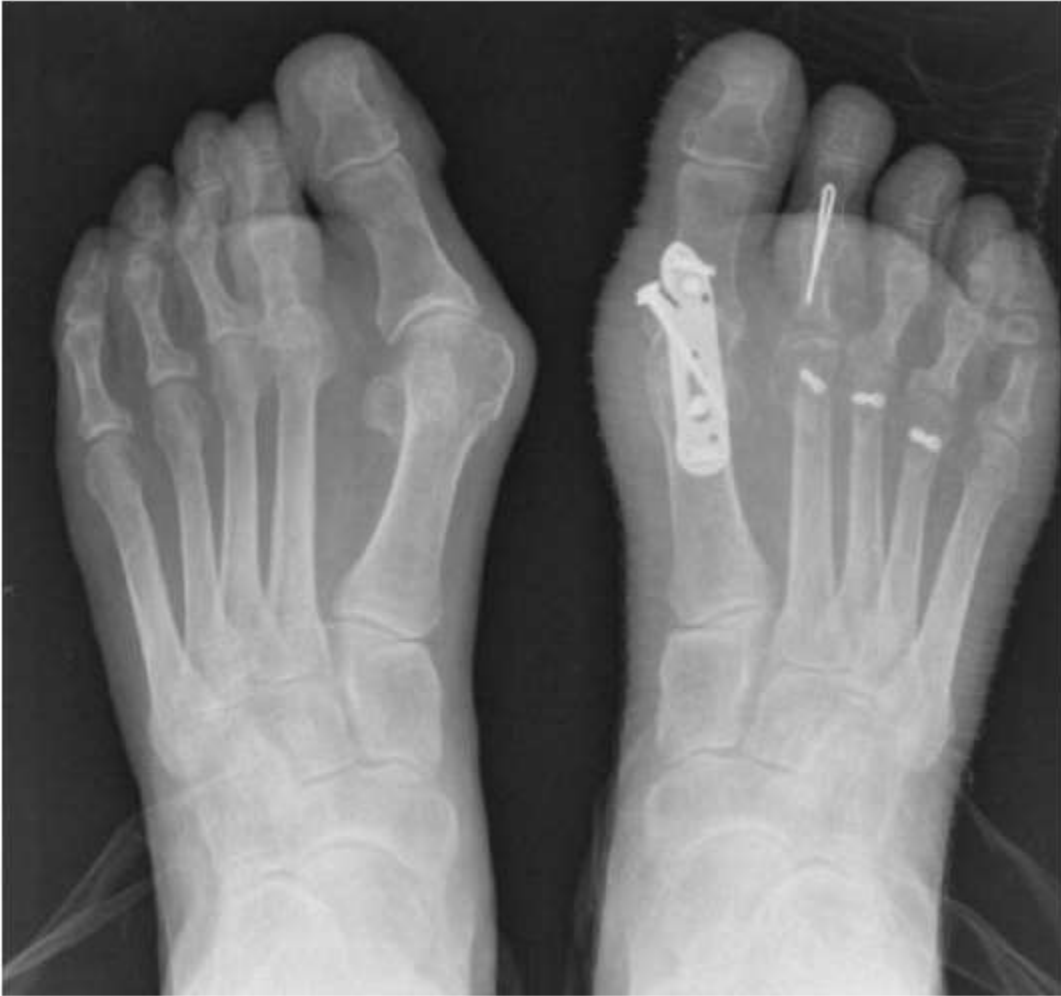

Figure 3.

**Figure 3.** Severe hallux valgus with dislocation M2, M3, M4. First arthrodesis with lesser head metatarsal osteotomy at 1-year follow-up

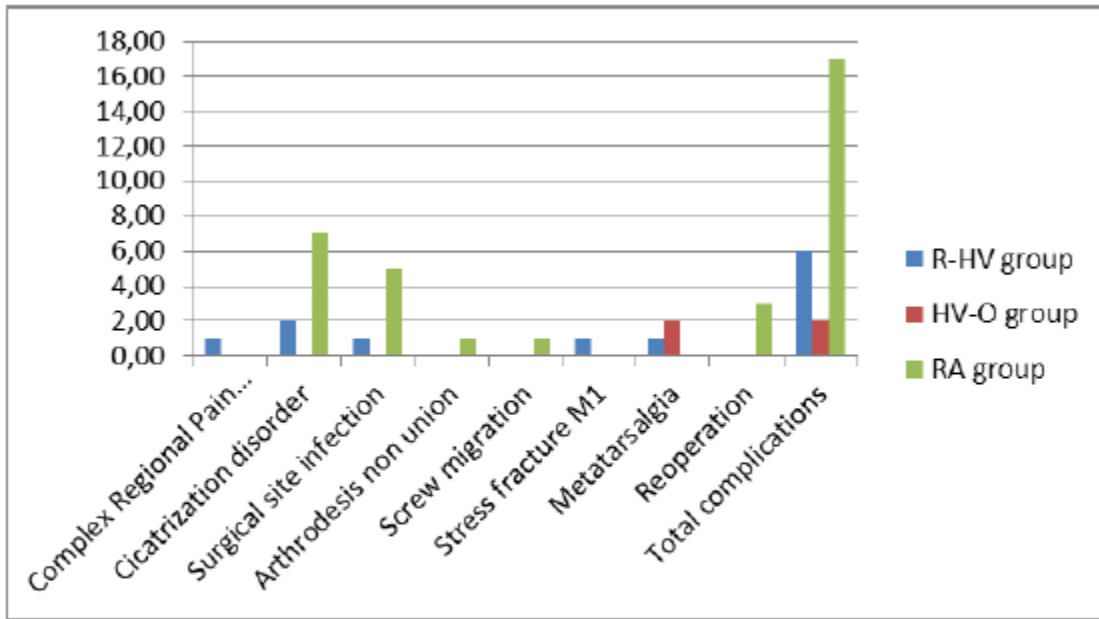


Figure 4.

**Figure 4.** Post-operative complications. *No significant difference between the three groups ( $p > 0.05$ )*