



HAL
open science

Netherton syndrome subtypes share IL-17/IL-36 signature with distinct IFN- α and allergic responses

Claire Barbieux, Mathilde Bonnet Des Claustres, Matthias Fahrner, Evgeniya Petrova, Lam C Tsoi, Olivier Guoin, Florent Leturcq, Pascale Nicaise-Roland, Christine Bole, Vivien Béziat, et al.

► To cite this version:

Claire Barbieux, Mathilde Bonnet Des Claustres, Matthias Fahrner, Evgeniya Petrova, Lam C Tsoi, et al.. Netherton syndrome subtypes share IL-17/IL-36 signature with distinct IFN- α and allergic responses. *Journal of Allergy and Clinical Immunology*, 2021, 10.1016/j.jaci.2021.08.024 . hal-03559943

HAL Id: hal-03559943

<https://hal.science/hal-03559943>

Submitted on 22 Feb 2022

HAL is a multi-disciplinary open access archive for the deposit and dissemination of scientific research documents, whether they are published or not. The documents may come from teaching and research institutions in France or abroad, or from public or private research centers.

L'archive ouverte pluridisciplinaire **HAL**, est destinée au dépôt et à la diffusion de documents scientifiques de niveau recherche, publiés ou non, émanant des établissements d'enseignement et de recherche français ou étrangers, des laboratoires publics ou privés.

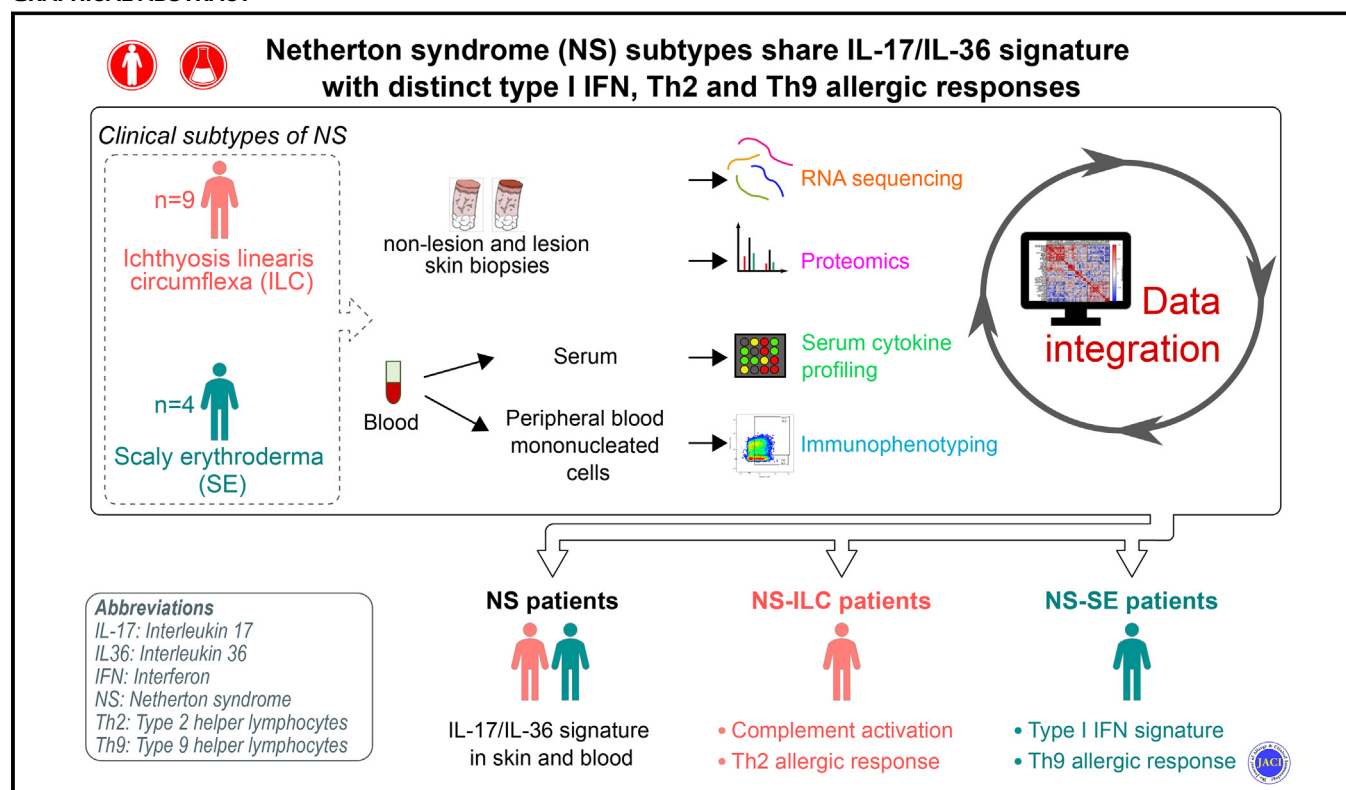


Distributed under a Creative Commons Attribution - NonCommercial - NoDerivatives 4.0 International License

Netherton syndrome subtypes share IL-17/IL-36 signature with distinct IFN- α and allergic responses

Claire Barbieux, PhD,^a Mathilde Bonnet des Claustres, MSc,^a Matthias Fahrner, MSc,^{i,j,k} Evgeniya Petrova, PhD,^a Lam C. Tsoi, PhD,^a Olivier Gouin, PhD,^a Florent Leturcq, BSc,^a Pascale Nicaise-Roland, MD, PhD,^{b,c} Christine Bole, PhD,^d Vivien Béziat, PhD,^e Emmanuelle Bourrat, MD,^f Oliver Schilling, PhD,ⁱ Johann E. Gudjonsson, MD, PhD,^l and Alain Hovnanian, MD, PhD^{g,h,i}
Paris, France; Freiburg, Germany; and Ann Arbor, Mich

GRAPHICAL ABSTRACT



Background: Netherton syndrome (NS) is a rare recessive skin disorder caused by loss-of-function mutations in *SPINK5* encoding the protease inhibitor LEKTI (lymphoepithelial

Kazal-type-related inhibitor). NS patients experience severe skin barrier defects, display inflammatory skin lesions, and have superficial scaling with atopic manifestations. They present with

From ^aINSERM UMR 1163, Laboratory of Genetic Skin Diseases, Imagine Institute, ^bthe Department of Immunology, Bichat Hospital, AP-HP-Nord, ^cINSERM UMR 1152, ^dINSERM UMR 1163, Imagine Institute, ^eINSERM UMR 1163, Laboratory of Human Genetics of Infectious Diseases, Imagine Institute, ^fthe Department of Dermatology, Saint-Louis Hospital, ^gthe University of Paris, ^hthe Department of Genetics, Necker Hospital for Sick Children (AP-HP), Paris; ⁱthe Institute for Surgical Pathology, Medical Center, Faculty of Medicine, University of Freiburg, ^jthe Spemann Graduate School of Biology and Medicine (SGBM), Albert-Ludwigs-University Freiburg, and ^kthe Faculty of Biology, Albert-Ludwigs-University Freiburg, Freiburg; and ^lthe Department of Dermatology, University of Michigan, Ann Arbor.

The first 3 authors contributed equally as co-first authors. Authors 4 and 5 contributed equally as co-second authors.

This project was funded by the French National Research Agency ANR-17-CE14-0025 Th Atopy (A.H.), ANR-19-CE17-0017 Target-NS (A.H.), the Imagine Institute with Cross-Lab program, and Association Ichtyose France (A.H.). A.H. and O.S. were supported by the European Union's Horizon 2020 research and innovation program under the ERA-NET Cofund action 643578 (KLKIN project); J.E.G. and L.C.T. are supported by NIH P30-AR075043 and A1130025.

All data associated with this study are present in this report or in this article's Online Repository at www.jacionline.org. We deposited RNA-Seq data on the Gene Expression Omnibus (GEO; accession no. GSE164285) and proteomic data on MassIVE (accession no. PXD023658).

Disclosure of potential conflict of interest: The authors declare that they have no relevant conflicts of interest.

Received for publication March 3, 2021; revised August 12, 2021; accepted for publication August 27, 2021.

Corresponding author: Alain Hovnanian, MD, PhD, Imagine Institute, INSERM UMR 1163, Genetic Skin Diseases: From Disease Mechanisms to Therapies, 24, boulevard du Montparnasse, 75015 Paris, France. E-mail: alain.hovnanian@inserm.fr. 0091-6749

© 2021 The Authors. Published by Elsevier Inc. on behalf of the American Academy of Allergy, Asthma & Immunology. This is an open access article under the CC BY-NC-ND license (<http://creativecommons.org/licenses/by-nc-nd/4.0/>).

<https://doi.org/10.1016/j.jaci.2021.08.024>

typical ichthyosis linearis circumflexa (NS-ILC) or scaly erythroderma (NS-SE).

Objective: We used a combination of several molecular profiling methods to comprehensively characterize the skin, immune cells, and allergic phenotypes of NS-ILC and NS-SE patients.

Methods: We studied a cohort of 13 patients comprising 9 NS-ILC and 4 NS-SE.

Results: Integrated multiomics revealed abnormal epidermal proliferation and differentiation and IL-17/IL-36 signatures in lesion skin and in blood in both NS endotypes. Although the molecular profiles of NS-ILC and NS-SE lesion skin were very similar, nonlesion skin of each disease subtype displayed distinctive molecular features. Nonlesion and lesion NS-SE epidermis showed activation of the type I IFN signaling pathway, while lesion NS-ILC skin differed from nonlesion NS-ILC skin by increased complement activation and neutrophil infiltration.

Serum cytokine profiling and immunophenotyping of circulating lymphocytes showed a T_H2-driven allergic response in NS-ILC, whereas NS-SE patients displayed mainly a T_H9 axis with increased CCL22/MDC and CCL17/TARC serum levels.

Conclusions: This study confirms IL-17/IL-36 as the predominant signaling axes in both NS endotypes and unveils molecular features distinguishing NS-ILC and NS-SE. These results identify new therapeutic targets and could pave the way for precision medicine of NS. (J Allergy Clin Immunol 2021;■■■:■■■-■■■.)

Key words: Netherton syndrome, IL-36, ichthyosis linearis circumflexa, scaly erythroderma, type I IFN, T_H2, T_H9

Netherton syndrome (NS) (OMIM 256500) is a rare and severe recessive genetic skin disease characterized by the diagnostic triad of ichthyosiform erythroderma, a specific hair shaft abnormality known as trichorrhexis invaginata, and high serum IgE levels with atopic manifestations. NS is an orphan disease that currently has no satisfactory treatment. NS is caused by recessive loss-of-function mutations in *SPINK5*,¹ encoding the serine protease inhibitor lymphoepithelial Kazal-type-related inhibitor (LEKTI) expressed at the granular layer–stratum corneum interface,^{2,3} leading to unopposed activity of cutaneous proteases, including kallikrein-related proteinases (KLK) 5, KLK7, and KLK14 as well as epidermal elastase 2.⁴⁻⁸ Unrestrained epidermal protease activity causes excessive desquamation resulting in a profound skin barrier defect and triggers the activation of inflammatory pathways.⁹⁻¹² NS patients display increased transepidermal water loss, superficial scaling, and redness of the skin. At birth or shortly thereafter, NS patients present with diffuse erythroderma and scaling. During childhood and adulthood, cutaneous lesions evolve in some patients toward ichthyosis linearis circumflexa (ILC), which refers to fluctuating polycyclic and serpiginous erythematous lesions bordered by a double collar of scales, while other patients retain a scaly erythrodermic (SE) phenotype. Both NS-ILC and NS-SE patients usually develop increased allergen-specific serum IgE with associated multiple airborne and/or food allergies. The presence of immune system abnormalities remains debated.^{13,14}

Histologic analyses of NS skin shows stratum corneum detachment, parakeratosis, reduced granular layer¹⁵ with epidermal hyperplasia, and hyperpapillomatosis with increased expression of proliferation markers such as keratin (KRT) 16.¹⁶

Abbreviations used

AD:	Atopic dermatitis
DC:	Dendritic cell
DEG:	Differentially expressed gene
DEP:	Differentially expressed protein
HC:	Healthy control
ILC:	Ichthyosis linearis circumflexa
KLK:	Kallikrein-related peptidase
KRT:	Keratin
LEKTI:	Lymphoepithelial Kazal-type-related inhibitor
NS:	Netherton syndrome
pDC:	Plasmacytoid DC
SE:	Scaly erythroderma

Differentiation markers such as involucrin, loricrin, and filaggrin are diffuse in NS upper epidermal layers with a reduction of desmosomal components,⁵ which contribute to the skin barrier defect. Several studies pointed to an altered lipid composition of NS stratum corneum,^{17,18} which is likely to aggravate the skin barrier defect and inflammation. Epidermal hyperplasia, abnormal differentiation, and altered lipid composition are features in common with other inflammatory skin diseases, including atopic dermatitis (AD), psoriasis, and ichthyoses. A transcriptomic study comparing different forms of ichthyoses including NS, with psoriasis and AD, revealed that the NS transcriptomic signature was closer to psoriasis, although psoriatic patients lack allergic manifestations.¹⁶

In addition to skin barrier disruption, epidermal proteases such as KLK5 and KLK14 play a role in skin inflammation by activating protease-activated receptor 2, which in turn triggers the expression of proinflammatory cytokines such as TSLP, CXCL8, and TNF- α .^{9,19-21} Bacterial- and allergen-derived proteases can also induce protease-activated receptor 2 signaling and activate downstream proinflammation pathways. In particular, NS patients are susceptible to infections by *Staphylococcus aureus*, which also induces an immune response driven by the T_H17 and IL-36 axis, thus enhancing skin inflammation.^{22,23} Previous transcriptomic analyses of NS lesion skin showed an IL-17 signature with increased expression of target genes encoding antimicrobial peptides or IL-17-related cytokines.^{16,24} NS patients also displayed an enrichment in circulating lymphocytes expressing IL-17 and IL-22,²⁵ suggesting that NS could be a T_H17-driven disorder resulting from skin barrier impairment.¹⁴ The involvement of the T_H17 axis in NS pathogenesis is supported by the successful treatment of NS patients with anti-IL-17A antibodies.²⁶⁻²⁸ Although anti-IL-17A therapy results in a significant clinical benefit, we recently reported that improvement could not be durably sustained, suggesting that other biological pathways are likely to contribute to NS pathogenesis.²⁷

NS is a disorder with a profound impact on skin homeostasis leading to skin inflammation and systemic allergic manifestations involving the immune system. The biological mechanisms underlying NS pathophysiology are not fully understood. In this study, we performed a comprehensive molecular characterization of a NS patient cohort to gain further insight into the consequences of loss of LEKTI expression in the skin and at the systemic level. We sought to define NS and endotype-specific molecular signatures that could pave the way for novel and precise therapeutic strategies.

METHODS

Patient cohort

A cohort of 13 NS patients from 10 kindreds with a median age of 32 years and 19 age- and sex-matched healthy controls (HCs) (median age, 30 years) was recruited. NS was confirmed by the identification of deleterious mutations in *SPINK5* and negative LEKTI immunostaining for the 13 NS patients including 9 NS-ILC and 4 NS-SE patients. Demographic information of patients is provided in Table I. Treatments included emollients on a daily basis and topical corticosteroids during acute flare-ups. Skin and blood were collected by biopsy before any biotherapy and at least 48 hours from the application of a corticosteroid. The protocol was approved by the international review board of Necker Hospital (NCT02081313), and the study was conducted in accordance with the principles of the Declaration of Helsinki. All patients and HCs provided written informed consent.

RNA sequencing library of NS skin

Total RNA was isolated from a 5 mm skin biopsy sample. After a DNase treatment with HL-dsDNase (ArcticZymes Technologies, Tromsø, Norway), complementary DNA was prepared using the NuGEN Ovation RNA-Seq System (NuGEN, San Juan, Puerto Rico) from 100 ng of total RNA. RNA-Seq libraries were sequenced on an Illumina HiSeq device (Illumina, San Diego, Calif). Further details are provided in the Online Repository at www.jacionline.org. The transcriptomic data were deposited at the Gene Expression Omnibus (GEO) data repository under accession number GSE164285.

Proteomic analysis of NS skin

Proteins were extracted from frozen skin samples using RapiGest containing buffer followed by reduction and alkylation. Proteins were digested by first incubating with LysC, then incubating with trypsin. Data were acquired with a Q-Exactive Plus (Thermo Fisher Scientific, Waltham, Mass) mass spectrometer. Further details are provided in the Online Repository. Mass spectrometry data as well as data analysis results have been deposited to ProteomeXchange via MassIVE (ID: PXD023658).

Statistical analyses

Statistical analyses were performed by GraphPad Prism v8.4.3 (GraphPad Software, La Jolla, Calif) and R v3.5.0 (R Foundation for Statistical Computing, Vienna, Austria; <https://www.r-project.org/>). Further details are provided in the Online Repository. Differences were considered significant at $P < .05$.

Experimental procedures of immunostaining, immunophenotyping of PBMCs, Western blot analysis, and serum cytokine profiling by Luminex (Austin, Tex) are described in the Online Repository.

RESULTS

Patient characterization

To study the molecular mechanisms involved in NS, we analyzed a cohort of 13 patients comprising 9 NS-ILC and 4 NS-SE (Table I). NS diagnosis was confirmed by the identification of deleterious mutations in *SPINK5* and negative LEKTI immunostaining for each patient. NS-ILC patients presented with flares of erythematous, seriginous lesions with a double scaly edge on their trunk and/or limbs. In contrast, NS-SE patients had extensive scaly and red skin and often displayed a lichenified appearance of flexion creases (Fig 1, A).

In both endotypes, histologic analyses revealed stratum corneum detachment, psoriasiform epidermal hyperplasia with elongated rete ridges, and parakeratosis in nonlesion and lesion skin (Fig 1, B). The stratum granulosum was thicker in nonlesion NS-SE skin and was almost completely absent in lesion skin from

both NS endotypes. Subcorneal microabscesses were seen in lesions from NS-ILC skin only. Histologic observations were supported by immunostaining of skin sections (see Fig E1 in the Online Repository available at www.jacionline.org). Marked inflammatory infiltrates were observed in NS lesion skin in both subtypes. Immunostaining with myeloperoxidase and tryptase antibodies showed massive neutrophil and mast cell infiltrates in lesion NS-ILC and lesion NS-SE skin, respectively (Fig 1, C). No eosinophils or infiltrating lymphocytes were observed (data not shown).

Total serum IgE levels were similarly increased by 3- to 40-fold in both NS-ILC and NS-SE patients (Table I) and were associated with several atopic manifestations. Serum component allergen-specific IgE showed high levels of specific IgE against pollens, dust mites, pets, and nuts (Fig 1, D, and see Fig E2, A, in the Online Repository available at www.jacionline.org). Likewise, all patients analyzed had elevated specific IgE against cross-species allergens such as profilin, tropomyosin, or PR10 proteins (Fig 1, D, and Fig E2, B). These results showed that the 2 clinical subtypes of NS shared common histologic and allergic sensitization features with distinct immune cell skin infiltrates.

NS patients display IL-17- and IL-36-driven immune response in skin and peripheral blood

To investigate the transcriptomic signature of NS, RNA-Seq was performed of lesion and nonlesion skin biopsy samples obtained from NS patients or healthy donors. Principal component analysis revealed a clear separation between NS lesion, nonlesion, and healthy control samples (Fig 2, A), with nonlesion skin of NS-ILC patients being close to HCs and nonlesion NS-SE skin resembling lesion samples. A global analysis was performed to compare HCs, NS nonlesion skin, and NS lesion skin (see Table E1 in the Online Repository available at www.jacionline.org), and the differentially expressed genes (DEGs) identified in each comparison were submitted to the DAVID online tool (<https://david.ncifcrf.gov/>). Epidermal differentiation, immune response, inflammation, and proliferation were the most enriched biological processes in DEGs. Lesion and nonlesion skin showed similar features with DEGs mainly involved in epidermal differentiation and immune response compared to healthy controls. Inflammation and proliferation were specifically enriched in lesion skin (see Fig E3, A, in the Online Repository available at www.jacionline.org).

In parallel, proteomic profiling of nonlesion and lesion skin biopsy samples from the same patients showed a clear separation between NS and healthy controls, as revealed at the RNA level (Fig E3, B). RNA-Seq and proteomic results were positively correlated (Fig 2, B) and showed enrichment for the same biological processes. Upregulated proteins in NS nonlesion and lesion skin (Table E1) were mainly involved in epidermal differentiation, cell adhesion, antimicrobial response, and immune response, whereas multiple proteins crucial in extracellular matrix organization were downregulated compared to healthy skin biopsy samples (Fig E3, C). Proteins involved in the immune response, especially in the IL-17/IL-36 pathways, were specifically upregulated in lesion skin.

Genes involved in IL-17/IL-36 pathways (*S100A7/8/9*, *P13*, *IL36G*) were among the ones with the highest transcript and protein fold changes (Fig 2, B). Immunostaining of skin sections revealed a significant increase in IL-36 γ in lesion and nonlesion NS

TABLE I. Demographic, clinical, and molecular characteristics of 13 NS patients

Patient no.	Sex	Age (years)	<i>SPINK5</i> mutation	Consequences	NS subtype	Trichorhexis invaginata	IgE (IU/mL) [†]	Atopy	Associated manifestations	Severity score
1	F	27	c.880_882del; c.1820 + 2T > A	Altered splicing; [‡] altered splicing	NS-ILC	–	6217	Allergic rhinitis, food allergies	Blepharitis, flat warts	5
2	F	17	HMZ: c.1048C > T	p.R350 [‡]	NS-SE	+	282	Allergic rhinitis, angioedema, multiple food allergies	Perinatal dehydration, failure to thrive	8
3.1	M	16	c.238dup; c.891C > T	p.A217Gfs*19; p.C297C (altered splicing)	NS-ILC	+	783	Allergic rhinitis, asthma, allergic conjunctivitis		6
3.2	M	12	c.238dup; c.891C > T	p.A217Gfs*19; p.C297C (altered splicing)	NS-ILC	+	670	Multiple food allergies, angioedema		8
4	F	21	c.666 + 1G > A; c.2620_2621insT	Altered splicing; p.Y874Lfs*6	NS-ILC	–	519	Allergic rhinitis, food allergy (eggs)	Diarrhea in perinatal period	2
5	F	57	c.2468dup; c.1351del	p.K824Efs*4; p.C451Afs*53	NS-ILC	+	7827	Allergic conjunctivitis, asthma, angioedema, multiple food allergies	Failure to thrive in infancy	6
6	F	14	HMZ: c.2539-1501G > C	Retention of 79 bp intronic fragment	NS-ILC	+	11657	Allergic rhinitis, allergic conjunctivitis, asthma, multiple food allergies	Perinatal dehydration, blepharitis, visual impairment, [§] obesity, [§] developmental delay [§]	8
7	F	18	c.55 + 1G > A; c.2015 + 5G > A	Altered splicing; altered splicing	NS-ILC	–	14471	Allergic rhinitis, angioedema, multiple food allergies	Short stature (<2.5 percentile)	6
8	F	34	HMZ: 55kb deletion including exon 1 to 16	Partial <i>SPINK5</i> deletion	NS-SE	+	1259	—	Perinatal dehydration, blepharitis, failure to thrive in infancy, short stature (<2.5 percentile)	5
9	M	28	c.238dup; 52kb deletion including exon 5 to 34	p.A217Gfs*19; partial <i>SPINK5</i> deletion	NS-SE	+	4676	Allergic rhinitis, allergic conjunctivitis, angioedema, multiple food allergies	Perinatal dehydration, flat warts, short stature (<2.5 percentile)	8
10.1	F	45	c.283-2A > T; c.2468dup	Altered splicing; p.K824Efs*4	NS-ILC	+	40918	Allergic rhinitis, allergic conjunctivitis, multiple food allergies		8
10.2	F	43	c.283-2A > T; c.2468dup	Altered splicing; p.K824Efs*4	NS-ILC	+	15538	Allergic rhinitis, allergic conjunctivitis, multiple food allergies	Failure to thrive in infancy, short stature (<2.5 percentile), flat warts	8
10.3	M	41	c.283-2A > T; c.2468dup	Altered splicing; p.K824Efs*4	NS-SE	+	8538	Allergic rhinitis, allergic conjunctivitis, angioedema, multiple food allergies	Perinatal dehydration, failure to thrive in infancy, short stature (<2.5 percentile), papillomatous lesions, flat warts	8

[†]The normal values of IgE serum level of the laboratory are below 114 IU/mL.

[‡]This mutation changes the last nucleotide of exon 10 and disrupts the donor splice site of intron 10.

[§]These features are caused by the association of Bardet-Biedl syndrome, confirmed by molecular diagnosis in this patient.

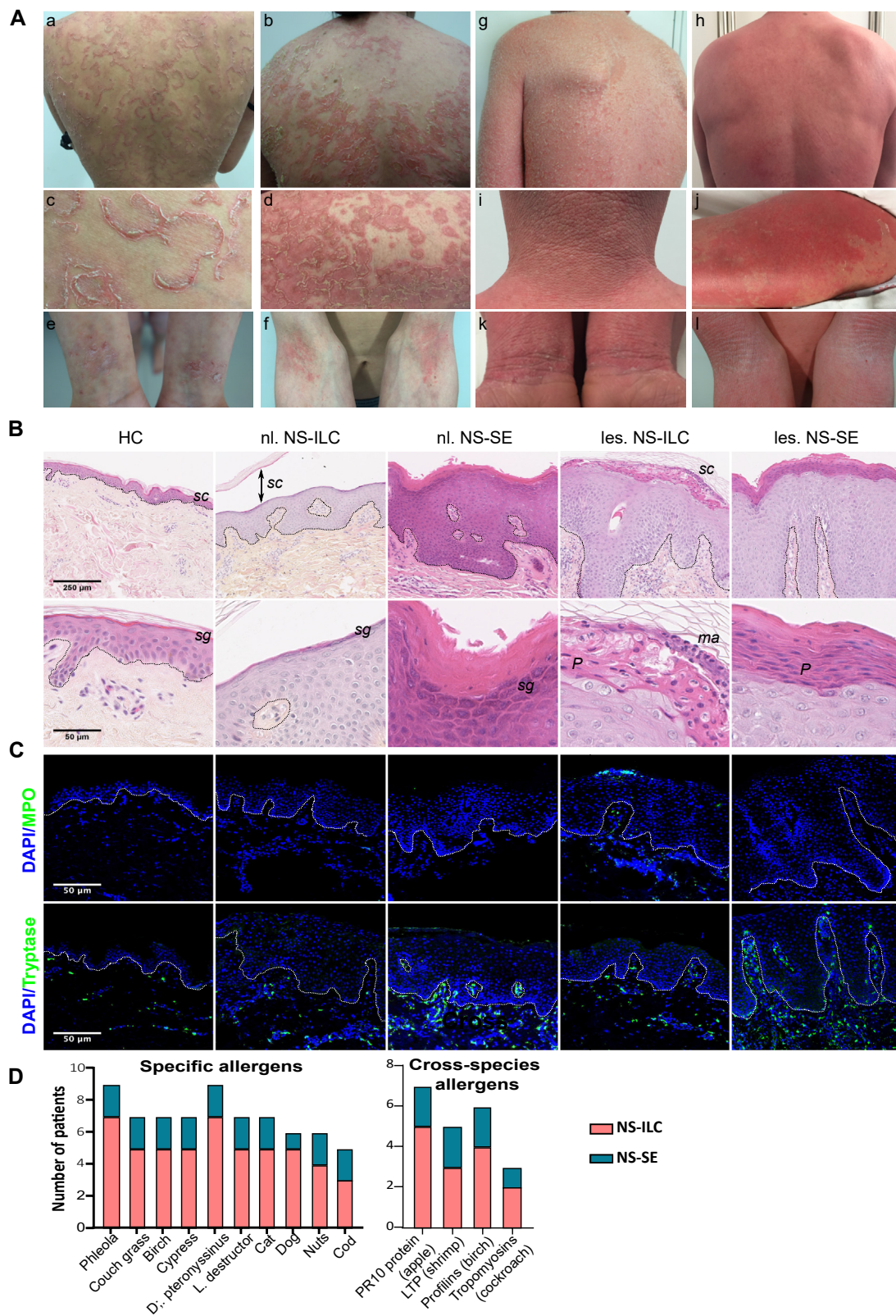


FIG 1. Clinical and histologic features, but not IgE profiles, distinguish 2 NS subtypes. **(A)** Representative clinical pictures of NS-ILC and NS-SE patients. **(B)** Hematoxylin and eosin staining of skin sections of HCs and of lesion and nonlesion skin samples from NS-ILC and NS-SE patients (original magnification $\times 10$); bar = 25 μm . The enlargements (original magnification $\times 40$) correspond to upper epidermal layers; bar = 50 μm . The dotted black line delineates the dermal-epidermal junction. *sc*, Stratum corneum; *sg*, stratum granulosum; *ma*, microabscess; *P*, parakeratosis. **(C)** Neutrophil and mast cell infiltrates were detected with anti-myeloperoxidase and tryptase antibodies, respectively. Nuclei were counterstained with 4',6-diamidino-2-phenylindole (blue). The dotted white line delineates the dermal-epidermal junction. Bar = 50 μm (original magnification $\times 40$). **(D)** Specific IgE values were measured by ImmunoCap ISAC (NS-ILC, $n = 7$; NS-SE, $n = 2$); the number of patients showing reactivity toward specific allergens or panallergens such as PR10 proteins, lipid transfer proteins (LTP), profilins, and tropomyosins is represented.

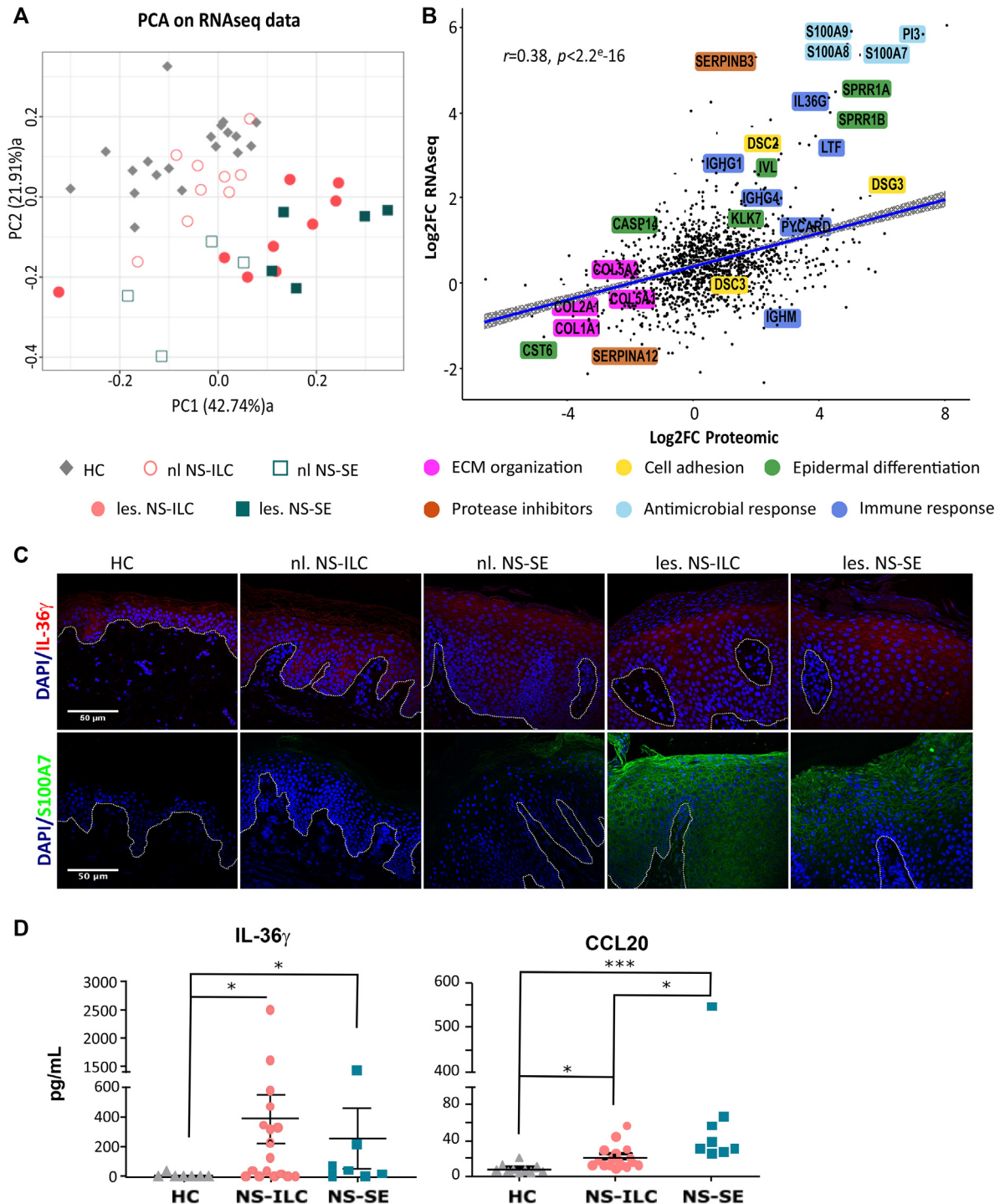


FIG 2. Transcriptomic and proteomic profiling of NS reveal an IL-36 signature. **(A)** Principal component analysis of RNA-Seq data from healthy donor skin biopsy samples ($n = 19$), nonlesion skin ($n = 13$), and lesion skin ($n = 14$) of 9 NS-ILC and 4 NS-SE patients. **(B)** Pearson correlation analysis using RNA and protein expression values of cumulatively identified genes. Linear regression line is shown in blue with 95% confidence interval (gray). **(C)** IL-36 γ (red) and antimicrobial peptides S100A7 (green) immunostaining of skin sections from HCs as well as nonlesion and lesion skin samples from NS-ILC and NS-SE patients. Nuclei were counterstained with 4',6-diamidino-2-phenylindole (blue). The dotted white line delineates the dermal-epidermal junction. Bar = 50 μ m (original magnification $\times 40$). **(D)** Serum levels of proinflammatory IL-36 γ and CCL20 in NS patients ($n = 13$) and healthy controls ($n = 11$). Lines correspond to means \pm SEMs. * $P < .05$, ** $P < .01$, *** $P < .001$.

skin and S100 proteins in lesion NS skin compared to healthy controls (Fig 2, C). Evidence for IL-17 and IL-36 signature was also sought in NS patient sera. IL-36 γ and the IL-17–induced chemokine CCL20 serum levels were significantly increased in NS patients compared to HCs (Fig 2, D). Overall, the IL-17/IL-36 transcriptomic and proteomic signature was identified in lesion skin of both NS endotypes and in nonlesion NS-SE skin.

Transcriptomic and proteomic profiling distinguishes NS-ILC from NS-SE

Despite common features, omic analyses revealed that differences could be observed between the 2 NS endotypes. Therefore, transcriptomic data were further analyzed by calculating the Euclidian distance, which clearly distinguished nonlesion NS-ILC samples from nonlesion NS-SE skin with 2208 DEGs (Fig 3, A, and see Table E2 in the Online Repository available at www.jacionline.org). In contrast, lesion skin from NS-ILC and NS-SE showed more similarities, with only 168 DEGs identified (see Fig E6, A, and Table E2 in the Online Repository). Extracellular matrix organization, cell adhesion, and innate immune response were significantly enriched in NS-ILC, whereas the NS-SE signature involved the type I interferon signaling pathway and response to viruses (Fig 3, B). NS-ILC and NS-SE skin transcriptomic profiles were compared to AD and psoriasis lesion skin,^{29,30} with results showing that lesion NS-ILC and NS-SE and nonlesion NS-SE skin significantly correlated with psoriasis (Fig E6, B).

In parallel, proteomic data were also further analyzed and revealed 66 significant differentially expressed proteins (DEPs) between NS-ILC nonlesion and NS-SE nonlesion skin and 54 DEPs between NS-ILC lesion and NS-SE lesion skin (Table E2). Multiple proteins involved in the extracellular matrix organization as well as in neutrophil degranulation were present in higher abundance in NS-ILC compared to NS-SE biopsy samples (Fig 3, C). Four SERPINS, some of which are known as protease inhibitors, were enhanced in NS-ILC skin compared to NS-SE. Of note, heavy chains of IgG₁ and IgM (IGHG₁ and IGHM, respectively) and C1S, which are involved in the classical pathway of complement activation, were also enriched in NS-ILC lesion skin (Fig 3, C, and Fig E6, B). In the NS-SE endotype, proteins involved in epidermal development, keratinocyte differentiation, cell proliferation, and inflammatory response were upregulated. Proteomic profiling of NS-SE skin revealed that the IFN pathway downstream effector STAT1 was more abundant in NS-SE nonlesion skin than in NS-ILC nonlesion skin (Fig E6, B).

Complement activation is more pronounced in NS-ILC skin

Proteomic data showed increased expression of complement C1S as well as IgG and IgM heavy chains. Enhanced expression of classical complement components was confirmed at the transcript level by RNA-Seq data. In particular, C1QB and C1QC presented significantly increased transcript levels in nonlesion and lesion skin compared to healthy controls (Fig 4, A). C1R was also significantly increased in lesion NS-ILC skin compared to healthy controls. Because these components initiate the classical cascade, cleavage of complement C3 was assessed by Western blot analysis of NS skin (Fig 4, B). Complement C3 could be detected in NS skin lysates but not in healthy controls. Complement C3 α full length (115 kDa) and fragments iC3b (68

kDa) and C3dg (40 kDa) were observed. The 3 bands were quantified and added to obtain total complement C3, which was significantly increased by 2-fold in lesion NS-ILC skin lysates compared to nonlesion NS-ILC and NS-SE (Fig 4, B). In addition, the percentage of complement C3 cleavage was enhanced by 1.5-fold in nonlesion and lesion NS-ILC skin compared to NS-SE (Fig 4, C). The increased cleavage of C3 in NS-ILC skin suggested that complement activation was involved in NS-ILC inflammatory response.

NS-SE patients show an IFN signature that predominates in the skin

Transcriptomic profiling revealed a marked type I IFN signature in nonlesion and lesion skin from NS-SE patients that was absent in nonlesion NS-ILC and minimal in lesion NS-ILC (Fig 4, D, and see Fig E7, A, in the Online Repository available at www.jacionline.org). Strikingly, the intensity of increased expression of IFN-induced gene was comparable between nonlesion and lesion NS-SE skin. The IFN signaling pathway was further assessed in skin biopsy samples by immunostaining of STAT1 and its phosphorylated form. Increased expression and phosphorylation of STAT1 with nuclear localization were observed in lesion epidermis of both NS subtypes compared to healthy control (Fig 4, E). STAT1 expression and phosphorylation were also enhanced in nonlesion NS-SE skin, consistent with type I IFN pathway activation, in contrast to nonlesion NS-ILC. Plasmacytoid dendritic cells (pDCs), which are the main source of type I IFN, were not detected by immunostaining (data not shown). Evidence for a type I IFN signature was also shown at the systemic level with increased serum level of IFN- α in NS-SE patients compared to HCs and NS-ILC patients (Fig 4, F). However, patients' PBMCs showed no evidence for IFN polarization (Fig E7, B), except for patients 10.2 and 9. Immunophenotyping of peripheral dendritic cells (DCs) revealed no differences in pDC frequency and increased type 1 myeloid DC in NS-SE compared to HCs (Fig E7, C).

Distinct allergic responses are triggered in NS-ILC and NS-SE

Discrimination between the 2 endotypes was further assessed at the systemic level by analyzing their serum cytokine profiles. A supervised partial least-squares discriminant analysis revealed that these cytokine profiles differed between HCs, NS-ILC, and NS-SE (Fig 5, A). Among the 49 cytokines, 15 were significantly discriminant and could explain the projection of the 3 groups along the 2 axes. The first axis was mainly driven by CCL22/MDC and CCL17/TARC, while the second axis was mostly explained by CCL27/CTACK, IL-4, IL-16, and CXCL2. CCL22/MDC and CCL17/TARC serum levels were significantly increased in NS-SE, but not in NS-ILC, patients compared to HCs. CCL27/CTACK and IL-4 showed no statistical difference between NS-ILC and HCs but were significantly decreased in NS-SE sera compared to NS-ILC and HCs (Fig 5, B).

The 4 most discriminant cytokines (CCL17/TARC, CCL22/MDC, CCL27/CTACK, IL-4) are known to be involved in allergic response. Although IL-4 and CCL27 are T_H2 cytokines, the major source of CCL17/TARC and CCL22/MDC is T_H9 cells. Detailed immunophenotyping of PBMCs revealed a significant increased T_H2 subset in NS-ILC compared to healthy controls, while

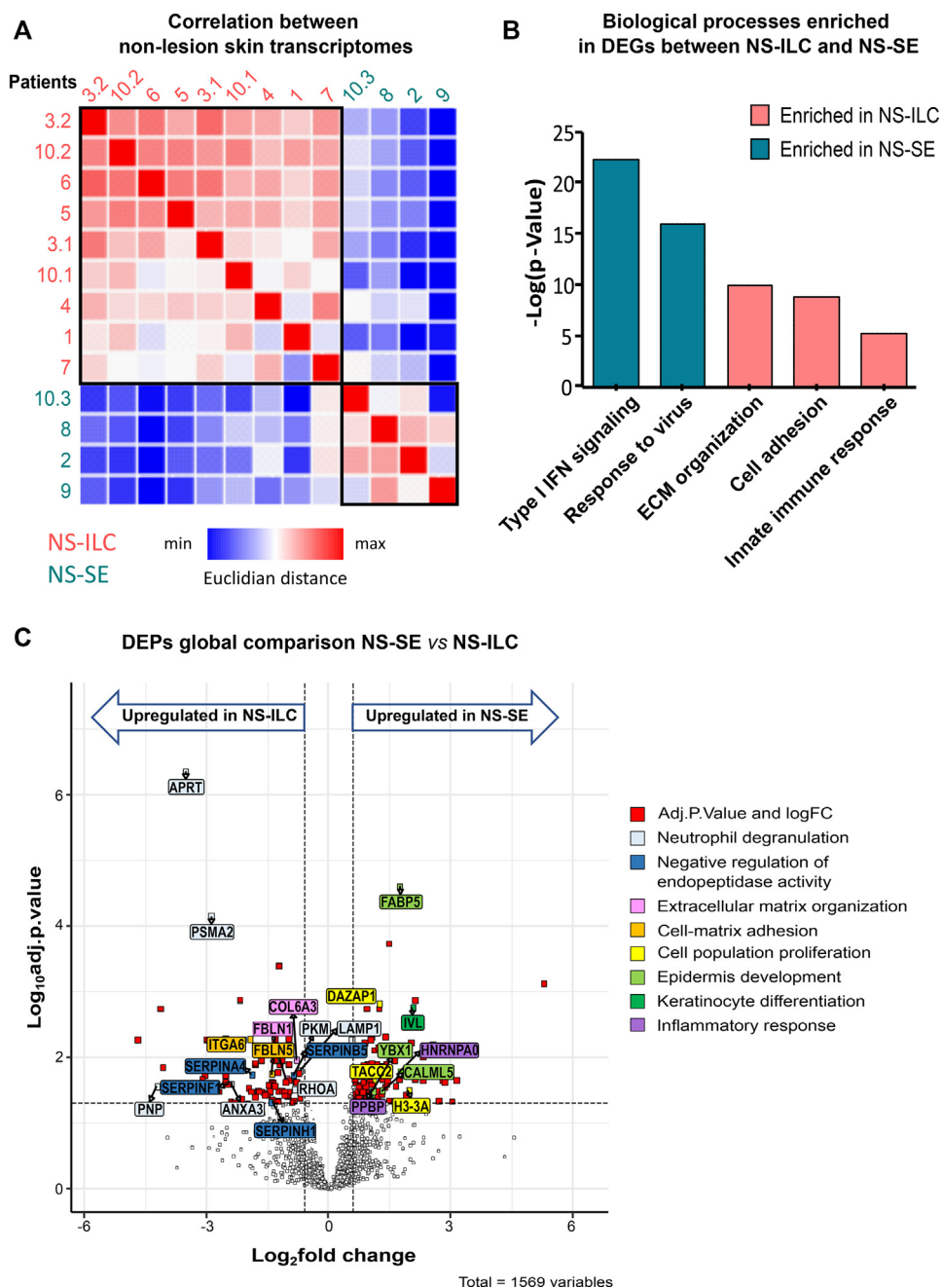


FIG 3. Transcriptomic and proteomic profiling of NS-ILC and NS-SE patients revealed molecular differences between each endotype. (A) Correlation between nonlesion samples determined by calculating Euclidian distance, which is represented on the heat map. (B) Biological processes enriched in DEGs between NS-ILC and NS-SE skin. (C) Volcano plot comparing proteome data from healthy donor skin as well as nonlesion and lesion skin samples from NS patients ($n = 11$). Proteins of interest and their respective Gene Ontology (GO; <http://geneontology.org/>) “biological process” term are highlighted in *different colors*.

NS-SE showed a significantly enhanced T_H9 subset compared to both healthy controls and NS-ILC patients (Fig 5, C). These results were supported by increased IL-4- and IL-13-positive memory CD4 T cells in NS-ILC patients compared to NS-SE. Of note, IL-9-producing memory CD4 T cells were not enhanced in either NS-ILC or NS-SE patients. T_H2 and T_H9 cells contribute to the maturation of B cells, which are involved in the allergic response by producing IgE.

Skin and blood multiomics show correlated signature

Each NS subtype could be distinguished on the basis of its cutaneous molecular signature and its immune profile in peripheral blood. Spearman correlation and hierarchical clustering were built on omic, Luminex, and phenotyping data sets to identify related cutaneous and systemic signatures and their correlation with NS clinical features (IgE serum levels and severity score).

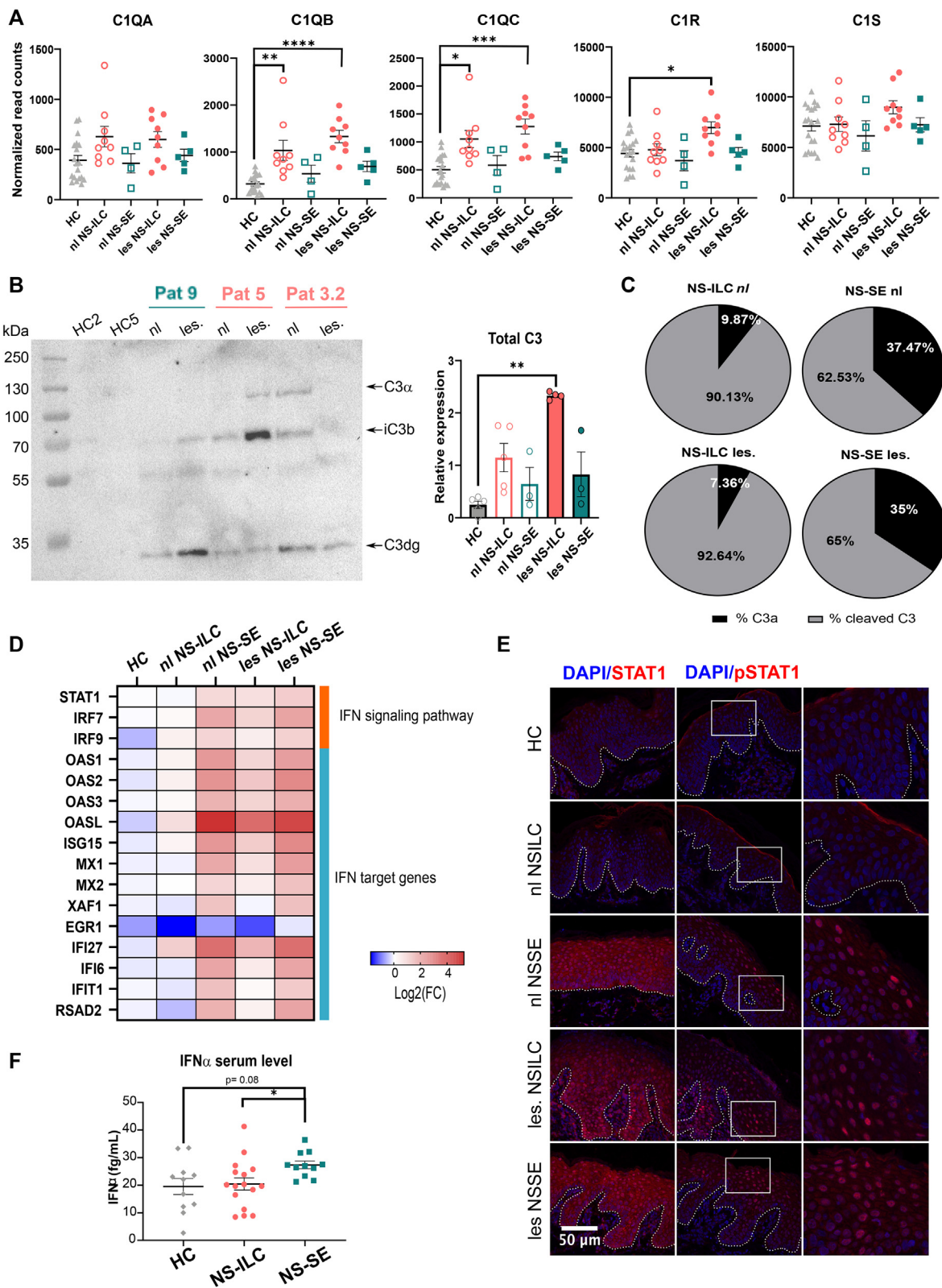


FIG 4. NS-ILC and NS-SE skin display distinct inflammatory response involving complement and IFN pathway, respectively. (A) Level of C1QA, C1QB, C1QC, C1R, and C1S transcripts. (B) Complement C3 expression level skin lysates assessed by Western blot analysis and its (C) cleavage percentage in protein extracts from HCs as well as nonlesion and lesion NS skin samples. (D) The \log_2 of the fold change for the genes involved in the IFN pathway is represented on the heat map for each group. (E) STAT1 and pSTAT1 immunostaining in skin sections from HCs as well as nonlesion and lesion skin samples from NS-ILC and NS-SE patients. Nuclei were counterstained with 4',6-diamidino-2-phenylindole (blue). The dotted white line delineates the dermal-epidermal junction. Bar = 50 μm (original magnification $\times 40$). (F) Serum levels of IFN- α in NS patients ($n = 13$) and healthy controls ($n = 11$). Horizontal bars indicate means \pm SEMs. * $P < .05$, ** $P < .01$, *** $P < .001$.

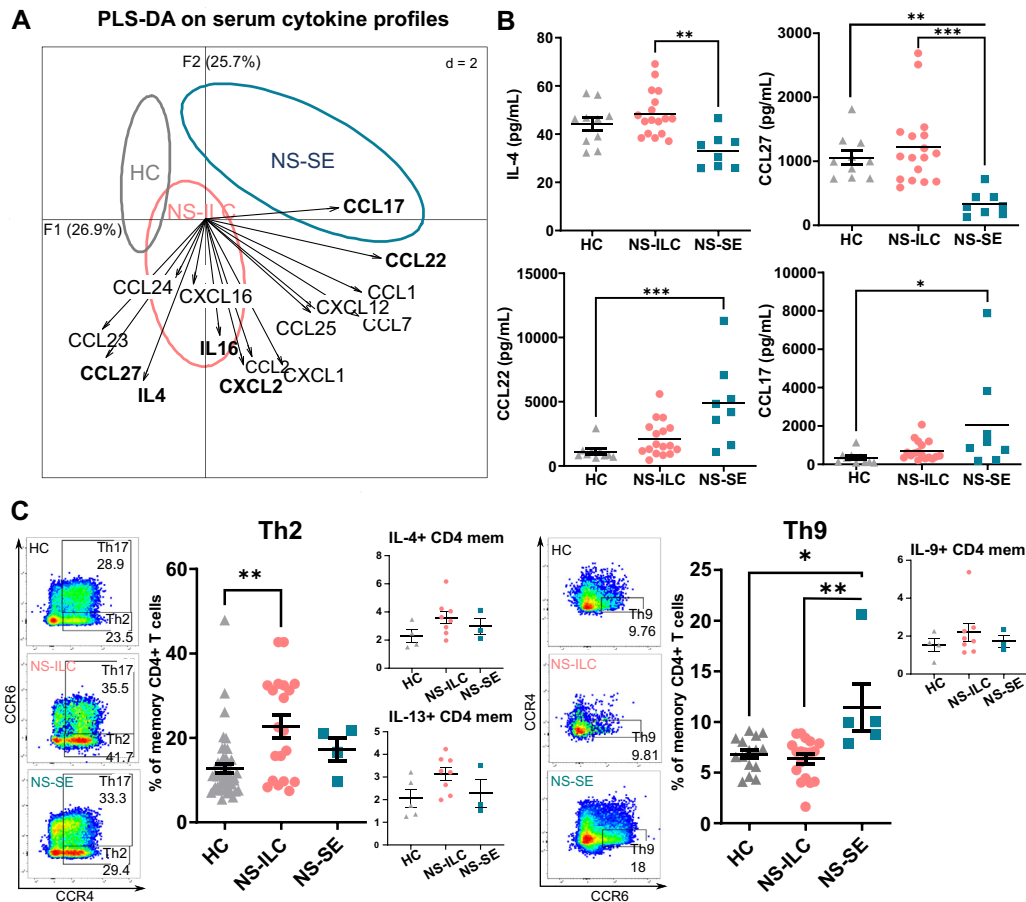


FIG 5. NS-ILC and NS-SE show allergic features involving either T_H2 or T_H9 axes. (A) Partial least squares discriminant analysis (PLS-DA) model followed by the determination of variable importance projection (VIP, *bold*) based on serum cytokine profiles. (B) Serum concentrations of IL-4, CCL27/CTACK, CCL22/MDC, and CCL17/TARC. Horizontal bars indicate means \pm SEMs. (C) Percentages of T_H2 and T_H9 in PBMCs from HCs, NS-ILC, and NS-SE and production of their cytokines after stimulation with phorbol 12-myristate 13-acetate/ionomycin. Horizontal bars indicate means \pm SEMs. * $P < .05$, ** $P < .01$, *** $P < .001$.

Four clusters, including 2 with positive correlations and 2 with negative correlations, were observed (Fig 6). The first cluster consisted of a strongly positive correlation between the expression level of genes involved in type I IFN, IL-36 pathways, T_H9 subset frequency, and CCL22, CCL20, and IFN- α serum levels. This cluster also revealed a strong correlation with markers of epidermal proliferation (MKI67), wound healing (KRT16), and differentiation (involucrin). The enhancement of these markers was more pronounced in NS-SE than in NS-ILC patients. The second correlation cluster gathered C1Q and myeloperoxidase transcript levels, CXCL2, CCL27, IL-4, and IgE serum levels, and the frequency of IL-17-, IL-13-, and IL-4-positive CD4 T cells, which were all increased in NS-ILC patients. Conversely, the last 2 clusters resulted from negative correlations between the markers of the first and the second cluster and *vice versa*. IgE serum levels were included in the NS-ILC-specific cluster, but no significant correlation was observed except for IL-4-positive memory T cells. The severity score showed a significant positive correlation with CCL17 serum levels and was negatively correlated with IL-9-positive memory CD4 T cells. The Spearman correlation matrix was consistent with the inflammatory signatures identified in each endotype.

DISCUSSION

Here we describe the global changes in NS-ILC and NS-SE patients compared to HCs at the clinical, histologic, and molecular levels. In both clinical subtypes, transcriptomic and proteomic signatures of nonlesion skin revealed abnormalities in epidermal proliferation and differentiation. Epidermal hyperproliferation and impaired differentiation are major characteristics of NS lesion skin that have been previously reported.^{15,16,31} Complete loss of differentiation markers seen in NS-SE lesions may result from increased serine protease activity in lesion NS-SE compared to NS-ILC,¹⁸ which is supported in our study by downregulation of protease inhibitors in NS-SE patients. Multiomic profiling showed a prominent IL-17/IL-36 signature in lesion skin of both NS endotypes, which could contribute to epidermal hyperproliferation and impaired differentiation. IL-17 and IL-36 cytokines trigger epidermal proliferation^{32,33} and inhibit epidermal differentiation in psoriasis.^{34,35} We previously reported, and confirmed in this study, that lesion NS-ILC skin displayed marked neutrophil infiltrates, whereas lesion NS-SE skin was mainly infiltrated with mast cells.²⁷ Neutrophil gelatinase-associated lipocalin and histamine released by mast cells could participate in the dysregulation of epidermal differentiation in

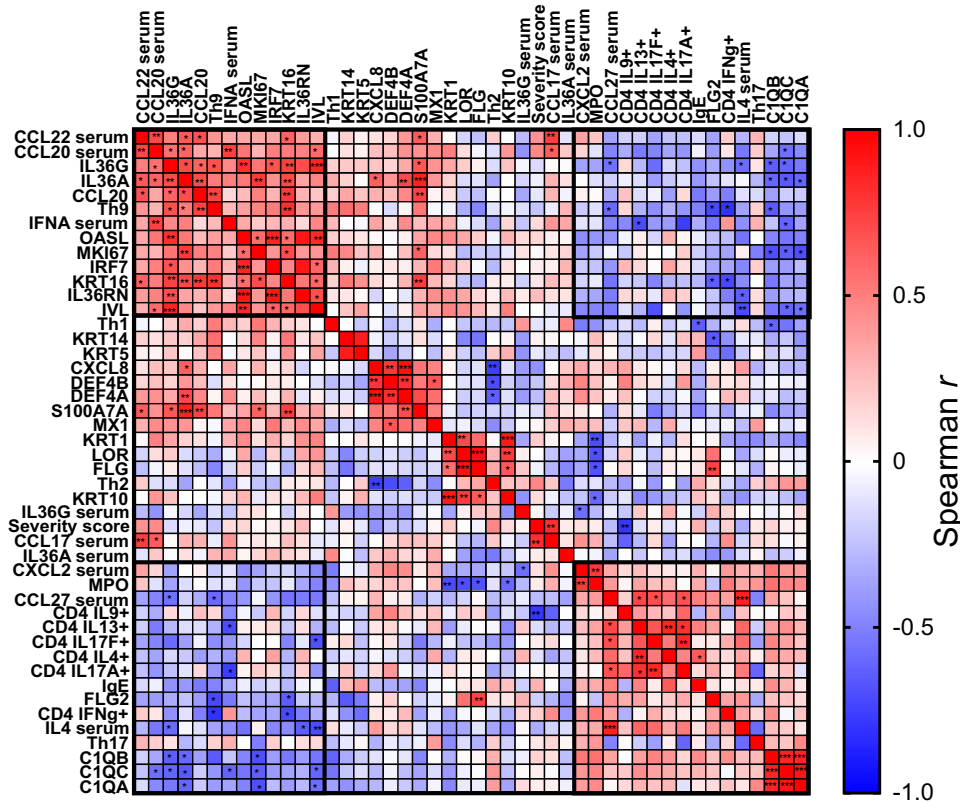


FIG 6. Cutaneous molecular features and peripheral blood phenotype are strongly correlated in each NS subtype. Spearman correlation heat map of clinical (severity score, serum IgE level) markers, transcript levels, serum cytokine levels, and PBMC immunophenotyping. The *black boxes* underline clustered markers. Statistical significance is indicated in the heat map. * $P < .05$, ** $P < .01$, *** $P < .001$.

NS-ILC and NS-SE patients, respectively.^{36,37} The expression of wound healing markers (KRT6 and KRT16) was enhanced in NS-SE nonlesion skin compared to NS-ILC nonlesion skin, suggesting that skin homeostasis is more disrupted in NS-SE patients. Nonlesion NS-SE skin also displayed increased expression of epidermal differentiation markers compared to NS-ILC, which could result from the enhanced IFN signature in nonlesion NS-SE skin. Indeed, IFN- β is required to induce differentiation of cultured keratinocytes.³⁸

Multimic analyses of NS skin revealed increased immune and inflammatory responses, which mainly relied on IL-17 and IL-36 cytokines. IL-17A and IL-17F are secreted by T_H17 cells, and IL-17C is expressed by keratinocytes, while IL-36 α , β , and γ cytokines are mainly found in the epidermis.³⁹ *Staphylococcus aureus* is the most represented strain in NS skin microbiome²² and contributes to the IL-17/IL-36 signature by disrupting the skin barrier. In addition, a recent study showed that epicutaneous *Staphylococcus aureus* enhanced IgE production in an IL-36-dependent manner.⁴⁰ Therefore, the skin barrier defect is likely to trigger an immune response in NS patients with no evidence for an immunodeficiency, as previously suggested.¹⁴ Of note, the inflammatory properties of IL-17 and IL-36 pathways are enhanced by their capacity to mutually regulate each other.⁴¹⁻⁴³ Studies have shown that IL-36 cytokines are the most upstream mediator of skin inflammation in murine models of psoriasis.⁴⁴⁻⁴⁶ In keratinocytes, IL-17 and IL-36 cytokines induce CCL20 and CXCL8 expression and secretion, which contribute

to the inflammatory environment by recruiting neutrophils.^{47,48} In psoriatic patients, IL-17A/F and IL-36 α and γ cytokines have been shown to be crucial in the course of the disease and to correlate with disease severity.^{49,50} A transcriptomic study showed increased expression of IL-36 α and γ cytokines in NS skin, which also correlated with disease severity.²⁴ The present study is to our knowledge the first to describe nonlesion and lesion NS skin as well as systemic abnormalities found in both clinical manifestations of the disease. In addition to their increased expression in skin, IL-36 α and γ serum levels were also enhanced in the sera from both NS endotypes. Although the IL-17/IL-36 signature was found in lesion skin from both endotypes, only nonlesion NS-SE skin displayed increased expression of IL-17/IL-36-related genes, suggesting that each endotype could present a unique molecular signature.

Multimic analyses showed distinct signatures in NS-ILC and NS-SE, suggesting that the molecular mechanisms involved in skin inflammation are partially different between the 2 endotypes. Transcriptomic and proteomic analyses revealed an immune response involving the innate compartment in NS-ILC lesion skin. In particular, complement C1Q, heavy chains of immunoglobulins G₁ and M, and complement C3 cleavage were increased, suggesting classical complement activation, and are likely to participate in neutrophil recruitment in NS-ILC lesion skin. Indeed, subcorneal neutrophil collection requires C5a, one of the most potent neutrophil chemoattractant factors.⁵¹ When psoriatic lesions were induced by imiquimod in a C3-deficient

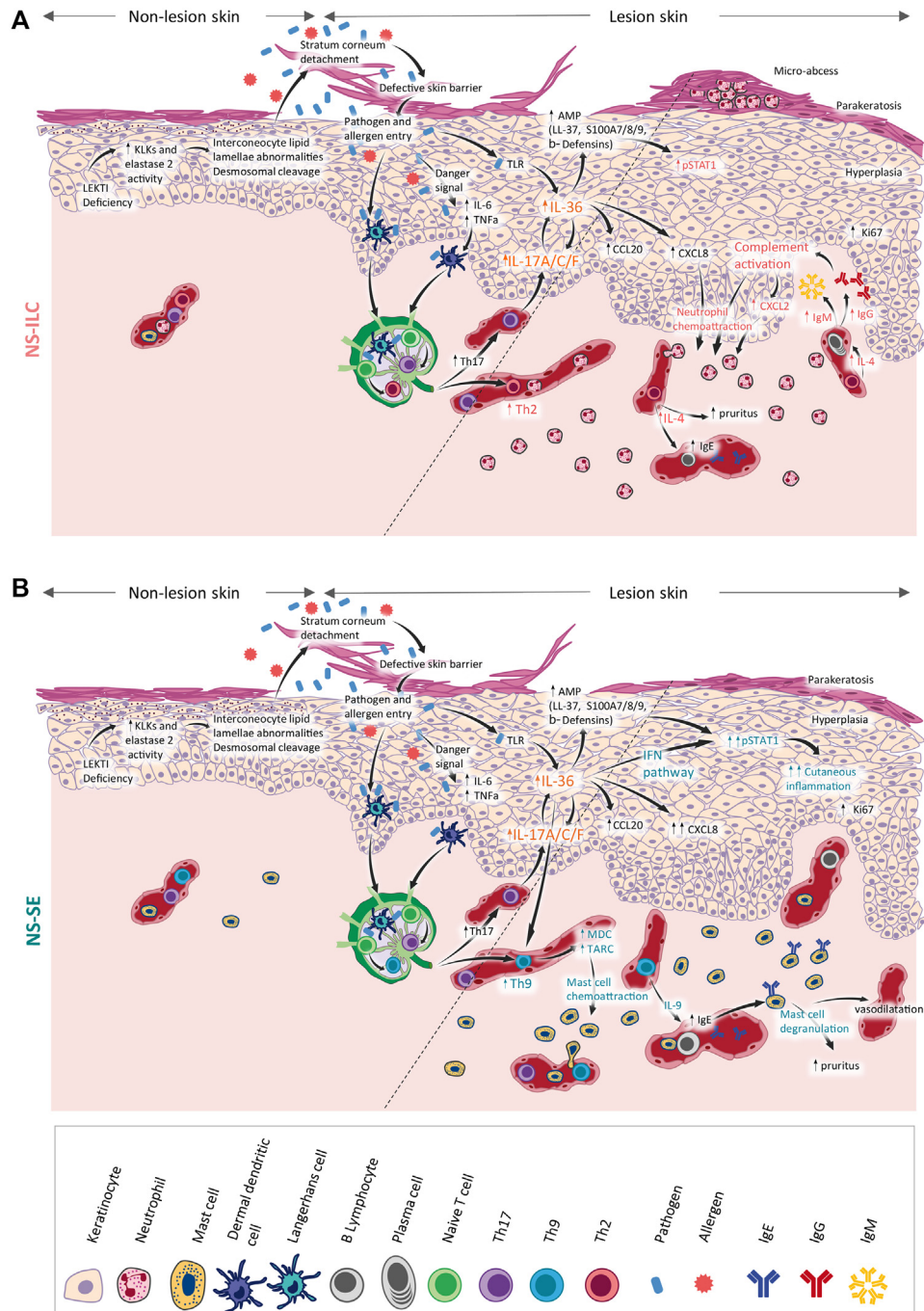


FIG 7. Proposed model of NS physiopathology in its 2 clinical forms. Loss of LEKTI function due to *SPINK5* mutations leads to unopposed activity of cutaneous proteases and causes stratum corneum detachment, epidermal hyperplasia, and parakeratosis. The profound skin barrier defect allows pathogen and allergen entry, triggering the production of proinflammatory mediators, the priming of naive T lymphocytes. **(A)** In NS-ILC, naive T cells differentiate into T_H2 cells, which release IL-4, triggering pruritus and allergic responses. Complement molecules and CXCL8 chemokine contribute to the formation of marked neutrophil infiltrates in the dermis and in the stratum corneum. **(B)** In NS-SE, T_H9 cells produce large amounts of CCL22/MDC and CCL17/TARC chemokines, which are mast cell chemoattractants. T_H9 cells contribute to the allergic response by enhancing the secretion of IgEs, which induce mast cell degranulation. Increased IFN signature could contribute to cutaneous inflammation.

murine model, inflammation and neutrophil infiltrates were reduced,⁵² supporting the role of complement activation in neutrophil recruitment and skin inflammation.

In NS-SE lesion and nonlesion skin, transcriptomic analyses revealed a type I IFN-related signature, which was supported by increased nuclear pSTAT1 immunostaining in keratinocytes.

Type I IFN cytokines are produced by pDCs, which massively infiltrate psoriatic skin⁵³ upon activation of the IL-36 pathway.^{54,55} However, we could not observe pDC infiltrates in lesion or nonlesion NS-SE skin. In chronic plaque psoriasis lesions, almost no pDCs are detected, but AMP self-RNA complexes and type I IFN trigger myeloid DC activation,^{56,57} which is consistent with the increase in type 1 myeloid DC subset observed in PBMCs from NS-SE patients. The expression level of IL-36 cytokines was higher in nonlesion NS-SE skin and could contribute to the enhanced IFN signature. Indeed, IL-36 cytokines induce a strong and early expression of *STAT1*, *MX2*, and *OAS* genes in human keratinocytes.⁴⁷ A recent transcriptomic analysis of blood from pustular and plaque psoriasis patients showed that IL-36 induces a type I IFN response in severe forms of psoriasis.⁵⁴ Overall, although no marked induction of the IFN pathway was observed in NS blood, it is likely that the IFN pathway contributes to chronic inflammation in NS-SE patient skin.

In addition to skin barrier defect and inflammation, all NS patients studied, except patient 8, had elevated serum IgE levels associated with atopic manifestations. Specific IgE profiling revealed that all NS patients were sensitized to at least 1 panallergen and presented sensitivity to food and airway allergens, as previously shown in a pediatric NS cohort.⁵⁸ Immunophenotyping of PBMCs revealed increased T_H2 subset in NS-ILC, suggesting that the T_H2 axis contributes to allergic manifestations in NS-ILC patients. This hypothesis is supported by increased IL-4 and CCL27/CTACK serum levels, which distinguished NS-ILC from NS-SE patients. T_H2 cells secrete cytokines, including but not limited to IL-4 and CCL27, which activate immunoglobulin secretion by B cells.⁵⁹ In contrast, the allergy-mediated immune response in NS-SE patients involved massive mast cell infiltrates, increased serum levels of CCL22/MDC and CCL17/TARC, and an enhanced T_H9 subset in circulating lymphocytes. The T_H9 subset has previously been involved in allergen sensitization and in the development of allergic asthma by producing CCL22/MDC and CCL17/TARC chemokines, leading to mast cell chemotaxis in mice and in humans.^{60,61} IL-36 γ and type I IFN increase the differentiation of naive T cells into T_H9,^{62,63} and could contribute to the allergic response in NS-SE.

The description of biological pathways led to considerable progress in the treatment of NS because classical NS treatments, including emollients, calcineurin inhibitors, or topical corticosteroids, show a limited benefit.¹⁰ The new current treatments of NS mainly rely on providing intravenous immunoglobulins in children with recurrent infections¹³ and biotherapy targeting TNF- α , IL-4/IL-13, IL-12/IL-23, or IL-17A, which reduce skin inflammation.^{26,64-66} The inhibition of the IL-17 axis²⁷ has revealed a duality in the therapeutic response according to the NS endotype, suggesting that other pathways may contribute to NS pathogenesis. Here we confirm the relevance of blocking IL-17A in both endotypes and the T_H2 axis in NS-ILC patients. Our multiomic approach also revealed a significantly increased IL-36 signature, which has become an attractive therapeutic target with promising results in pustular psoriasis.^{67,68} We also reveal an IFN signature in NS-SE patients. Few therapies specifically inhibit the IFN signaling pathway, but Janus kinase inhibitors are commonly used in AD and psoriasis to block the IFN pathway,^{69,70} and could be a new option in NS treatment. Although biotherapies are not curative for NS, they substantially improve NS patients' quality of life.

Taken together, our study results reveal a complex skin and systemic inflammatory phenotype in NS, which confirms the IL-17/IL-36 signature as a common characteristic of NS-ILC and NS-SE and distinguishes the 2 endotypes by the type of their immune response: a T_H2/complement-driven (NS-ILC) versus a type I IFN/T_H9-driven (NS-SE) inflammatory axis (Fig 7). The dual immune responses triggered in NS-ILC and NS-SE could pave the way for precision medicine, with the potential to improve NS patient care and quality of life.

We are grateful to Marie-Louis Frémond (Imagine Institute, Paris) and Hervé Bachelez (Saint-Louis Hospital, Paris) for insightful discussions. We acknowledge Ranjitha Uppala (University of Michigan, Ann Arbor, Mich), Fanny Louis (University of Lorraine, Metz), Snaigune Miskinyte (Imagine Institute, Paris), and Nicolas Cagnard (Imagine Institute, Paris) for technical support.

Key messages

- Multiomic analysis revealed IL-36 signature to be a hallmark of NS.
- Cutaneous molecular signatures of NS-ILC involved neutrophil infiltration and complement activation, while NS-SE involved type I IFN.
- Allergic responses were predominantly associated with T_H2 phenotype in NS-ILC patients but with a T_H9 phenotype in NS-SE.

REFERENCES

1. Chavanas S, Bodemer C, Rochat A, Hamel-Teillac D, Ali M, Irvine AD, et al. Mutations in *SPINK5*, encoding a serine protease inhibitor, cause Netherton syndrome. *Nat Genet* 2000;25:141-2.
2. Bitoun E, Micheloni A, Lamant L, Bonnart C, Tartaglia-Polcini A, Cobbold C, et al. LEKTI proteolytic processing in human primary keratinocytes, tissue distribution and defective expression in Netherton syndrome. *Hum Mol Genet* 2003;12:2417-30.
3. Ishida-Yamamoto A, Deraison C, Bonnart C, Bitoun E, Robinson R, O'Brien TJ, et al. LEKTI is localized in lamellar granules, separated from KLK5 and KLK7, and is secreted in the extracellular spaces of the superficial stratum granulosum. *J Invest Dermatol* 2005;124:360-6.
4. Bonnart C, Deraison C, Lacroix M, Uchida Y, Besson C, Robin A, et al. Elastase 2 is expressed in human and mouse epidermis and impairs skin barrier function in Netherton syndrome through filaggrin and lipid misprocessing. *J Clin Invest* 2010;120:871-82.
5. Descargues P, Deraison C, Prost C, Fraïtag S, Mazereeuw-Hautier J, D'Alessio M, et al. Corneodesmosomal cadherins are preferential targets of stratum corneum trypsin- and chymotrypsin-like hyperactivity in Netherton syndrome. *J Invest Dermatol* 2006;126:1622-32.
6. Deraison C, Bonnart C, Lopez F, Besson C, Robinson R, Jayakumar A, et al. LEKTI fragments specifically inhibit KLK5, KLK7, and KLK14 and control desquamation through a pH-dependent interaction. *Mol Biol Cell* 2007;18:3607-19.
7. Schechter NM, Choi EJ, Wang ZM, Hanakawa Y, Stanley JR, Kang Y, et al. Inhibition of human kallikreins 5 and 7 by the serine protease inhibitor lymphoepithelial Kazal-type inhibitor (LEKTI). *Biol Chem* 2005;386:1173-84.
8. Fortugno P, Bresciani A, Paolini C, Pazzagli C, El Hachem M, D'Alessio M, et al. Proteolytic activation cascade of the Netherton syndrome-defective protein, LEKTI, in the epidermis: implications for skin homeostasis. *J Invest Dermatol* 2011;131:2223-32.
9. Briot A, Deraison C, Lacroix M, Bonnart C, Robin A, Besson C, et al. Kallikrein 5 induces atopic dermatitis-like lesions through PAR2-mediated thymic stromal lymphopoietin expression in Netherton syndrome. *J Exp Med* 2009;206:1135-47.
10. Hovnanian A. Netherton syndrome: new advances in the clinic, disease mechanism and treatment. *Exp Rev Dermatol* 2012;7:81-92.

11. Hovnanian A. Netherton syndrome: skin inflammation and allergy by loss of protease inhibition. *Cell Tissue Res* 2013;351:289-300.
12. Furio L, Hovnanian A. Netherton syndrome: defective kallikrein inhibition in the skin leads to skin inflammation and allergy. *Biol Chem* 2014;395:945-58.
13. Renner ED, Hartl D, Rylaarsdam S, Young ML, Monaco-Shawver L, Kleiner G, et al. Comèl-Netherton syndrome—defined as primary immunodeficiency. *J Allergy Clin Immunol* 2009;124:536-43.
14. Stuvèl K, Heeringa JJ, Dalm VASH, Meijers RWJ, van Hoffen E, Gerritsen SAM, et al. Comèl-Netherton syndrome: a local skin barrier defect in absence of an underlying systemic immunodeficiency. *Allergy* 2020;75:1710-20.
15. Leclerc-Mercier S, Bodemer C, Furio L, Hadj-Rabia S, de Peuffelhoux L, Weibel L, et al. Skin biopsy in Netherton syndrome: a histological review of a large series and new findings. *Am J Dermatopathol* 2016;38:83-91.
16. Paller AS, Renert-Yuval Y, Suprun M, Esaki H, Oliva M, Huynh TN, et al. An IL-17-dominant immune profile is shared across the major orphan forms of ichthyosis. *J Allergy Clin Immunol* 2017;139:152-65.
17. van Smeden J, Janssens M, Boiten WA, van Drongelen V, Furio L, Vreeken RJ, et al. Intercellular skin barrier lipid composition and organization in Netherton syndrome patients. *J Invest Dermatol* 2014;134:1238-45.
18. Smeden J van, Al-Khakany H, Wang Y, Visscher D, Stephens N, Absalah S, et al. Skin barrier lipid enzyme activity in Netherton patients is associated with protease activity and ceramide abnormalities. *J Lipid Res* 2020;61:859-69.
19. Briot A, Lacroix M, Robin A, Steinhoff M, Deraison C, Hovnanian A. Par2 inactivation inhibits early production of TSLP, but not cutaneous inflammation, in Netherton syndrome adult mouse model. *J Invest Dermatol* 2010;130:2736-42.
20. Oikonomopoulou K, Hansen KK, Saifeddine M, Tea I, Blaber M, Blaber SI, et al. Proteinase-activated receptors, targets for kallikrein signaling. *J Biol Chem* 2006;281:32095-112.
21. Stefansson K, Brattsand M, Roosterman D, Kempkes C, Bocheva G, Steinhoff M, et al. Activation of proteinase-activated receptor-2 by human kallikrein-related peptidases. *J Invest Dermatol* 2008;128:18-25.
22. Williams MR, Cau L, Wang Y, Kaul D, Sanford JA, Zaramela LS, et al. Interplay of staphylococcal and host proteases promotes skin barrier disruption in Netherton syndrome. *Cell Rep* 2020;30:2923-33.e7.
23. Liu H, Archer NK, Dillen CA, Wang Y, Ashbaugh AG, Ortines RV, et al. *Staphylococcus aureus* epicutaneous exposure drives skin inflammation via IL-36-mediated T cell responses. *Cell Host Microbe* 2017;22:653-66.e5.
24. Malik K, He H, Huynh TN, Tran G, Mueller K, Doytcheva K, et al. Ichthyosis molecular fingerprinting shows profound TH17 skewing and a unique barrier genomic signature. *J Allergy Clin Immunol* 2019;143:604-18.
25. Czarnowicki T, He H, Leonard A, Malik K, Magidi S, Rangel S, et al. The major orphan forms of ichthyosis are characterized by systemic T-cell activation and Th-17/Tc-17/Th-22/Tc-22 polarization in blood. *J Invest Dermatol* 2018;138:2157-67.
26. Luchsinger I, Knöpfel N, Theiler M, Bonnet des Claustres M, Barbieux C, Schwieger-Briel A, et al. Secukinumab therapy for Netherton syndrome. *JAMA Dermatol* 2020;156:907-11.
27. Barbieux C, Bonnet des Claustres M, de la Brassinne M, Bricteux G, Bagot M, Bourrat E, et al. Duality of Netherton syndrome manifestations and response to ixekizumab. *J Am Acad Dermatol* 2021;84:1476-80.
28. Blanchard SK, Prose NS. Successful use of secukinumab in Netherton syndrome. *JAAD Case Rep* 2020;6:577-8.
29. Tsoi LC, Rodriguez E, Degenhardt F, Baurecht H, Wehkamp U, Volks N, et al. Atopic dermatitis is an IL-13-dominant disease with greater molecular heterogeneity compared to psoriasis. *J Invest Dermatol* 2019;139:1480-9.
30. Tsoi LC, Rodriguez E, Stölzl D, Wehkamp U, Sun J, Gerdes S, et al. Progression of acute-to-chronic atopic dermatitis is associated with quantitative rather than qualitative changes in cytokine responses. *J Allergy Clin Immunol* 2020;145:1406-15.
31. Descargues P, Deraison C, Bonnart C, Kreft M, Kishibe M, Ishida-Yamamoto A, et al. Spink5-deficient mice mimic Netherton syndrome through degradation of desmoglein 1 by epidermal protease hyperactivity. *Nat Genet* 2005;37:56-65.
32. Wu L, Chen X, Zhao J, Martin B, Zepp JA, Ko JS, et al. A novel IL-17 signaling pathway controlling keratinocyte proliferation and tumorigenesis via the TRAF4-ERK5 axis. *J Exp Med* 2015;212:1571-87.
33. Jiang Z, Liu Y, Li C, Chang L, Wang W, Wang Z, et al. IL-36 γ induced by the TLR3-SLUG-VDR axis promotes wound healing via REG3A. *J Invest Dermatol* 2017;137:2620-9.
34. Wang W, Yu X, Wu C, Jin H. IL-36 γ inhibits differentiation and induces inflammation of keratinocyte via Wnt signaling pathway in psoriasis. *Int J Med Sci* 2017;14:1002-7.
35. Pfaff CM, Marquardt Y, Fietkau K, Baron JM, Lüscher B. The psoriasis-associated IL-17A induces and cooperates with IL-36 cytokines to control keratinocyte differentiation and function. *Scientific Reports* 2017;7:1-13.
36. Mallbris L, O'Brien KP, Hulthén A, Sandstedt B, Cowland JB, Borregaard N, et al. Neutrophil gelatinase-associated lipocalin is a marker for dysregulated keratinocyte differentiation in human skin: NGAL is a marker for parakeratosis. *Exp Dermatol* 2002;11:584-91.
37. Gschwandtner M, Mildner M, Mlitz V, Gruber F, Eckhart L, Werfel T, et al. Histamine suppresses epidermal keratinocyte differentiation and impairs skin barrier function in a human skin model. *Allergy* 2013;68:37-47.
38. Bielenberg DR, McCarty MF, Bucana CD, Yuspa SH, Morgan D, Arbeit JM, et al. Expression of interferon- β is associated with growth arrest of murine and human epidermal cells. *J Invest Dermatol* 1999;112:802-9.
39. Blumberg H, Dinh H, Trueblood ES, Pretorius J, Kugler D, Weng N, et al. Opposing activities of two novel members of the IL-1 ligand family regulate skin inflammation. *J Exp Med* 2007;204:2603-14.
40. Patrick GJ, Liu H, Alphonse MP, Dikeman DA, Youn C, Otterson JC, et al. Epicutaneous *Staphylococcus aureus* induces IL-36 to enhance IgE production and ensuing allergic disease. *J Clin Invest* 2021;131:e143334.
41. Carrier Y, Ma HL, Ramon HE, Napierata L, Small C, O'Toole M, et al. Inter-regulation of Th17 cytokines and the IL-36 cytokines in vitro and in vivo: implications in psoriasis pathogenesis. *J Invest Dermatol* 2011;131:2428-37.
42. Chi HH, Hua KF, Lin YC, Chu CL, Hsieh CY, Hsu YJ, et al. IL-36 signaling facilitates activation of the NLRP3 inflammasome and IL-23/IL-17 axis in renal inflammation and fibrosis. *J Am Soc Nephrol* 2017;28:2022-37.
43. Bridgewood C, Fearnley GW, Berekermeri A, Laws P, Macleod T, Ponnambalam S, et al. IL-36 γ is a strong inducer of IL-23 in psoriatic cells and activates angiogenesis. *Front Immunol* 2018;9:200.
44. Mahil SK, Catapano M, Di Meglio P, Dand N, Ahlfors H, Carr IM, et al. An analysis of IL-36 signature genes and individuals with IL1RL2 knockout mutations validates IL-36 as a psoriasis therapeutic target. *Sci Transl Med* 2017;9.
45. Germán B, Wei R, Hener P, Martins C, Ye T, Gottwick C, et al. Disrupting the IL-36 and IL-23/IL-17 loop underlies the efficacy of calcipotriol and corticosteroid therapy for psoriasis. *JCI Insight* 2019;4(2):e123390; <https://doi.org/10.1172/jci.insight.123390>.
46. Hernández-Santana YE, Leon G, St Leger D, Fallon PG, Walsh PT. Keratinocyte interleukin-36 receptor expression orchestrates psoriasiform inflammation in mice. *Life Sci Alliance* 2020;3:e201900586.
47. Swindell WR, Beamer MA, Sarkar MK, Loftus S, Fullmer J, Xing X, et al. RNA-Seq analysis of IL-1B and IL-36 responses in epidermal keratinocytes identifies a shared MyD88-dependent gene signature. *Front Immunol* 2018;9:80.
48. Müller A, Hennig A, Lorscheid S, Grondona P, Schulze-Osthoff K, Hailfinger S, et al. I κ B ζ is a key transcriptional regulator of IL-36-driven psoriasis-related gene expression in keratinocytes. *Proc Natl Acad Sci U S A* 2018;115:10088-93.
49. D'Erme AM, Wilmann-Theis D, Wagenpfeil J, Hölzel M, Ferring-Schmitt S, Sternberg S, et al. IL-36 γ (IL-1F9) is a biomarker for psoriasis skin lesions. *J Invest Dermatol* 2015;135:1025-32.
50. Kolbinger F, Loesche C, Valentin M-A, Jiang X, Cheng Y, Jarvis P, et al. β -Defensin 2 is a responsive biomarker of IL-17A-driven skin pathology in patients with psoriasis. *J Allergy Clin Immunol* 2017;139:923-32.e8.
51. Giang J, Seelen MAJ, van Doorn MBA, Rissmann R, Prens EP, Damman J. Complement activation in inflammatory skin diseases. *Front Immunol* 2018;9:639.
52. Giacomassi C, Buang N, Ling GS, Crawford G, Cook HT, Scott D, et al. Complement C3 exacerbates imiquimod-induced skin inflammation and psoriasiform dermatitis. *J Invest Dermatol* 2017;137:760-3.
53. Nestle FO, Conrad C, Tun-Kyi A, Homey B, Gombert M, Boyman O, et al. Plasmacytoid dendritic cells initiate psoriasis through interferon- α production. *J Exp Med* 2005;202:135-43.
54. Catapano M, Vergnano M, Romano M, Mahil SK, Choon SE, Burden AD, et al. IL-36 promotes systemic IFN-I responses in severe forms of psoriasis. *J Invest Dermatol* 2020;140:816-26.e3.
55. Lande R, Gregorio J, Facchinetti V, Chatterjee B, Wang YH, Homey B, et al. Plasmacytoid dendritic cells sense self-DNA coupled with antimicrobial peptide. *Nature* 2007;449:564-9.
56. Conrad C, Gilliet M. Type I IFNs at the interface between cutaneous immunity and epidermal remodeling. *J Invest Dermatol* 2012;132:1759-62.
57. Zhang L. Type 1 interferons potential initiating factors linking skin wounds with psoriasis pathogenesis. *Front Immunol* 2019;10:1440.
58. Hannula-Jouppi K, Laasanen S-L, Heikkilä H, Tuomiranta M, Tuomi ML, Hilvo S, et al. IgE allergen component-based profiling and atopic manifestations in patients with Netherton syndrome. *J Allergy Clin Immunol* 2014;134:985-8.
59. Chen L, Lin S, Agha-Majzoub R, Overbergh L, Mathieu C, Chan LS. CCL27 is a critical factor for the development of atopic dermatitis in the keratin-14 IL-4 transgenic mouse model. *Int Immunol* 2006;18:1233-42.

60. Sehra S, Yao W, Nguyen ET, Glosson-Byers NL, Akhtar N, Zhou B, et al. TH9 cells are required for tissue mast cell accumulation during allergic inflammation. *J Allergy Clin Immunol* 2015;136:433-40.e1.
61. Pajulas A, Kaplan MH. The role of IL-9 secreting CD4+ T helper cells in promoting mast cell expansion in pulmonary models of inflammation. *J Immunol* 2020;204:65.22-65.22.
62. Harusato A, Abo H, Le Ngo V, Yi SW, Mitsutake K, Osuka S, et al. IL-36 γ signaling controls the induced regulatory T cell—TH9 cell balance via NF κ B activation and STAT transcription factors. *Mucosal Immunol* 2017;10:1455-67.
63. Wong MT, Ye JJ, Alonso MN, Landrigan A, Cheung RK, Engleman E, et al. Regulation of human Th9 differentiation by type I interferons and IL-21. *Immunol Cell Biol* 2010;88:624-31.
64. Fontao L, Laffitte E, Briot A, Kaya G, Roux-Lombard P, Fraitag S, et al. Infliximab infusions for Netherton syndrome: sustained clinical improvement correlates with a reduction of thymic stromal lymphopoietin levels in the skin. *J Invest Dermatol* 2011;131:1947-50.
65. Steuer AB, Cohen DE. Treatment of Netherton syndrome with dupilumab. *JAMA Dermatol* 2020;156:350-1.
66. Volc S, Maier L, Gritsch A, Aichelburg MC, Volc-Platzer B. Successful treatment of Netherton syndrome with ustekinumab in a 15-year-old girl. *Br J Dermatol* 2020;183:165-7.
67. Todorović V, Su Z, Putman CB, Kakavas SJ, Salte KM, McDonald HA, et al. Small molecule IL-36 γ antagonist as a novel therapeutic approach for plaque psoriasis. *Sci Rep* 2019;9:1-15.
68. Bachelez H, Choon SE, Marrakchi S, Burden AD, Tsai TF, Morita A, et al. Inhibition of the interleukin-36 pathway for the treatment of generalized pustular psoriasis. *N Engl J Med* 2019;380:981-3.
69. Howell MD, Kuo FI, Smith PA. Targeting the Janus kinase family in autoimmune skin diseases. *Front Immunol* 2019;10:2342.
70. Solimani F, Meier K, Ghoreschi K. Emerging topical and systemic JAK inhibitors in dermatology. *Front Immunol* 2019;10:2847.