



Ovarian torsion in a twin pregnancy at 32 weeks and 6 days: A case-report

Oriane Bernigaud, Eloise Fraison, Gabriel Thiberville, Gery Lamblin

► To cite this version:

Oriane Bernigaud, Eloise Fraison, Gabriel Thiberville, Gery Lamblin. Ovarian torsion in a twin pregnancy at 32 weeks and 6 days: A case-report. *Journal of Gynecology Obstetrics and Human Reproduction*, 2021, 50 (6), 5p. 10.1016/j.jogoh.2021.102117 . hal-03554707

HAL Id: hal-03554707

<https://hal.science/hal-03554707>

Submitted on 22 Mar 2023

HAL is a multi-disciplinary open access archive for the deposit and dissemination of scientific research documents, whether they are published or not. The documents may come from teaching and research institutions in France or abroad, or from public or private research centers.

L'archive ouverte pluridisciplinaire **HAL**, est destinée au dépôt et à la diffusion de documents scientifiques de niveau recherche, publiés ou non, émanant des établissements d'enseignement et de recherche français ou étrangers, des laboratoires publics ou privés.



Distributed under a Creative Commons Attribution - NonCommercial 4.0 International License

Ovarian torsion in a twin pregnancy at 32 weeks and 6 days: a case-report

Oriane BERNIGAUD¹; Eloise FRAISON¹⁻²; Gabriel THIBERVILLE¹; Gery LAMBLIN¹

1 - Department of Obstetrics and Gynecology, CHU Lyon, Hôpital Femme Mère Enfant, 59 Bd Pinel, 69500 BRON

2 - Department of Reproductive Medicine, CHU Lyon, Hôpital Femme Mère Enfant, 59 Bd Pinel, 69500 BRON

Funding: None

Conflicts of interest: None

A written and signed consent form was obtained from the patient

Corresponding Author:

Dr Eloïse FRAISON, Department of Obstetrics and Gynecology and Reproductive Medicine, CHU Lyon, Hôpital Femme Mère Enfant, 59 Bd Pinel, 69500 BRON

Phone number: + 33 6 03 49 03 96, email address: fraison.eloise@yahoo.fr

Running title: Ovarian torsion in a third trimester twin pregnancy

Key words: Ovarian torsion, twin pregnancy, third trimester, mini laparotomy, ultrasound guidance, case report

Abstract

Background: Ovarian torsion during pregnancy is a rare event and occurs mostly during the first trimester. This is the first case describing the diagnosis and management of an ovarian torsion at 33 weeks in a twin pregnancy with a normal term delivery.

Case summary: The patient presented with irregular uterine contraction due to an acute abdominal pain in the right iliac fossa. A cyst was discovered during the ultrasound scan on the right ovary and a torsion was highly suspected. A small laparotomy facing the ovarian mass after an ultrasound guidance was chosen. The patient finally delivered at 37 weeks.

Conclusion: The clinic holds a preponderant place in the diagnosis of ovarian torsion. Our surgical approach by laparotomy under ultrasound guidance was less risky than by laparoscopy.

Introduction

Ovarian torsion is the first gynecological emergency, affecting 2.7 % of women¹. It is often due to an increase of the ovarian volume by a cyst. It leads to an ischemia of the tissue with an arrest of the blood supply by strangulation. It may cause further infertility by altering the ovarian reserve.

Acute abdominal pain during pregnancy is difficult to manage due to its unspecific presentation and various etiologies. During pregnancy, ovarian torsion is a rare event with a prevalence of 6/10 000 and is mostly discovered during the first trimester². Presumed benign ovarian tumor during pregnancy occurred in 0.3 to 5.4 % of the cases³. Except for obstetrical causes, the prevalence of all abdominal emergency surgeries during pregnancy is between 0.2 and 2%⁴. In the literature, several cases of ovarian torsion are described during the third trimester of singleton pregnancy⁵ and only a few studies report an ovarian torsion in twin pregnancy⁶⁻¹⁸ (table 1). Only one case reports an ovarian torsion in a triplet pregnancy during the third trimester resulting in a preterm delivery by C-section¹⁹.

This is the first case describing the diagnosis and management of an ovarian torsion at 33 weeks in a twin pregnancy with a normal term delivery.

Case report

A 34-year-old woman, gravida 2 para 1, with a dizygotic twin pregnancy was admitted to the emergency maternity department of the Hôpital-Femme-Mère-Enfant in Lyon at 32 weeks and 6 days for uterine contractions.

The patient did not have any past medical history or family history. She had a scheduled left ovarian cystectomy by laparoscopy a few years ago for a dermoid cyst. Due to secondary infertility, she underwent treatment by in vitro fertilization and was successfully transferred with two day-5 embryos.

She described an abrupt pain starting three hours earlier, in the right iliac fossa followed by one episode of vomiting. She was afebrile, her blood pressure was 120/57 mmHg and quoted her pain at 10/10 on a pain scale (Numeric rating scale). She was given paracetamol and phloroglucinol at her arrival without any relief. Therefore, a grade II analgesic was given (intravenous nefopam). There was neither vaginal bleeding, fluid loss or uterine contractility. The patient did not complain about any bowel or urinary symptoms.

Physical examination showed a point of maximal tenderness in the right iliac fossa radiating to the flank and deep palpation lead to abdominal guarding. The uterus was smooth. The cardiotocograph revealed a normal fetal heart rate and some irregular contractions. Pathology results showed no inflammatory syndrome (white blood cells: 10 G/L, C reactive protein: 7.6 mg/L) and the urine dipstick was normal.

Concerning the ultrasound scan, both fetuses presented with good vitality, were eutrophic (1980 grams, 14th percentiles and 2110 grams, 30th percentiles) and the floating membrane was clearly seen among a normal amniotic fluid. There was no cervix modification since the last consultation with a 39 mm length. However, an anechoic and heterogeneous image of 32 mm in the right iliac fossa surrounded by an effusion was discovered. After a discussion with the radiologist, an abdominal-pelvic ultrasound was performed completed by an Injected-

Computed Tomography Scan. The ultrasound was not contributive. The scan highlighted the presence of a cystic formation in the right flank, measuring 65 x 37 x 78 mm, heterogeneous, with calcifications and a fatty portion. It was developed at the expense of the right ovary. No turn of coil nor thrombosis were detected (figure 1 and 2). Acute appendicitis and renal colic were excluded. Despite the grade II analgesic, the patient was still in pain. Surgery was decided upon 8 hours after the onset of pain. The patient was well informed of the risk of a per operative ovariectomy.

Operative technique

A multidisciplinary discussion between the obstetrics and the anesthetic team was conducted to determine the best surgical approach. A laparotomy facing the ovarian mass after an ultrasound guidance was chosen. A small incision of five centimeters was performed. This opening allowed the surgeon to directly find the right adnexal torsion (three turns of coil) with a necrotic ovary and an edematous fallopian tube. An ovariectomy was decided upon, because of its macroscopic aspect (figure 3 and 4). The surgery was performed under tocolytic medication (Atosiban) and after an initial dose of corticosteroids (Betamethasone) in case of premature delivery. Fetal well-being was monitored before and after surgery. There was no postoperative complication, the second dose of corticosteroids was administered, and the patient went home four days after surgery. Histological analysis confirmed the nature of the cyst as being a mature teratoma, with signs of major hemorrhagic reorganization.

Finally, the patient delivered four weeks later, at 37 weeks, after a spontaneous labor, and gave birth to two healthy children: a 2660g boy and a 2770 g girl.

Discussion

This case reports the diagnosis and management of an ovarian torsion in a twin pregnancy during the third trimester. To our knowledge, there is no other report of ovarian torsion during the third trimester of a twin pregnancy with a normal term delivery at the end. The first difficulty was to identify the torsion.

To begin with, we wanted to eliminate an obstetrical complication as the patient belonged to a risky pregnancy group with her twin pregnancy. Indeed, twin pregnancies are at higher risk of a preterm delivery and the first reason of her consultation was uterine contractions. Clinical examination, cardiotocograph and cervix length were reassuring. There was no sign of pre-eclampsia. The specific complications of multiple pregnancy were dismissed because of the dizygotic status. Moreover, for each fetus the amount of amniotic liquid was normal, the bladder was seen and umbilical Doppler was normal (Resistivity index was respectively for fetus A and B: 0.55 and 0.58). Subsequently, we wanted to explore an abdominal or urinary cause and more specifically appendicitis or renal colic. Pathology results ruled out an infection and dipstick urinalysis did not highlight leukocytes, blood, protein, or nitrite. Moreover, the patient did not complain about bowel or urinary problems.

An ovarian cause was therefore highly suspected. Exploration of the ovaries was limited by the volume of the womb. A mass on the right ovary was discovered yet the Doppler was not helpful. The patient was at high risk of an ovarian torsion due to her assisted reproductive treatment (ART) and her past medical history of dermoid cyst. Regarding the diagnosis of ovarian torsion, ultrasound scan has a high sensitivity (range: from 76% to 100%) and specificity (range: from 94% to 100%) when the Doppler signal is abnormal²⁰. However, in 54 % of cases the Doppler is normal in patients with a suspicion of adnexal torsion²¹. An Injected-Computed Tomography (ICT) scan was performed. A study reports a good diagnostic performance of the ICT²². Magnetic Resonance Imaging (MRI) is a good way to examine an

ovarian mass but its availability in emergency is limited. The scan confirmed the presence of a cyst and ruled out other previously mentioned etiologies and an ovarian thrombosis. Ovarian torsion was therefore the only diagnosis.

Concerning the surgery, for other abdominal emergencies during pregnancy, it is described that laparoscopy must be preferred²³. Its advantage lies in the fewest operative complications and a shorter hospital stay. However, laparotomy is the most frequent approach during pregnancy for ovarian torsion (odd ratio 1.28; confidence interval 95%, 1.08-1.51; $p<0.01$)²⁴. According to Daykan *et al.*'s study, ovarian torsion during pregnancy, regardless the treatment chosen, does not seem to increase the risk of premature delivery, obstetric or neonatal complications, but these conclusions are based mostly for ovarian torsion occurring during the first trimester²⁵.

In our case, the patient was at 33 SA with a twin pregnancy and a laparoscopy was rejected by the anesthetic team. After discussion with the team and the painful patient, we decided to do a successful ultrasound guided mini laparotomy. Although the first management option was to keep the right ovary after untwisting, an adnexectomy was decided upon the macroscopic appearance of it. Indeed, it remained entirely necrotic without any signs of reperfusion even after 10 minutes. Mage *et al.* recommend a radical treatment after untwisting when the ovary remains black, necrotic and friable²⁶, which was the case in our study. Moreover, the aspect of the left ovary was completely normal at the CT-scan.

In the literature, only one case reports the same technique for a 31 SA with a singleton pregnancy and an ovarian torsion without any cyst²⁷. Lastly, the patient delivered vaginally at a normal term, thus the surgery did not have any consequences either to her pregnancy or her abdominal wall.

References

1. Hibbard LT. Adnexal torsion. *Am J Obstet Gynecol.* 1985; 152(4): 456-61.
2. Kumari I, Kaur S, Mohan H, Huria. Adnexal masses in pregnancy: a 5-year review. *Aust N Z J Obstet Gynaecol.* 2006;46(1): 52-4.
3. Tariel O, Huissoud C, Rudigoz RC, Dubernard G. Tumeurs ovariennes présumées bénignes lors de la grossesse. *Journal de Gynécologie Obstétrique et Biologie de la Reproduction.* 2013 ;42(8) : 842-55.
4. Bouyou J, Gaujoux S, Marcellin L, Leconte M, Goffinet F, Chapron C, et al. Abdominal emergencies during pregnancy. *J Visc Surg.* 2015 ;152(6 Suppl.) : S105-115.
5. Li C, Wang S, Tao X, Hu Y, Li X, Xiao X. Torsion of normal-sized ovary during late pregnancy: A case report and review of the literature. *J Obstet Gynaecol Res.* 2018 ;44(11) :2110-4.
6. Gil Navarro N, Garcia Grau E, Pina Pérez S, Ribot Luna L. Ovarian torsion and spontaneous ovarian hyperstimulation syndrome in a twin pregnancy: A case report. *Int J Surg Case Rep.* 2017; 34:66-8.
7. Habek D, Bauman R, Rukavina Kralj L, Hafner T, Turudic T, Vujisic S. Acute Abdomen in the 17th Week of Twin Pregnancy due to Ovarian Torsion – A Late Complication of IVF. *Geburtshilfe Frauenheilkd.* 2016;76(12):1345-9.
8. Arena S, Canonico S, Luzi G, Epicoco G, Brusco GF, Affronti G. Ovarian torsion in in vitro fertilization–induced twin pregnancy: Combination of Doppler ultrasound and laparoscopy in diagnosis and treatment can quickly solve the case. *Fertility and Sterility.* 1 oct 2009;92(4): 1496.e9-1496.e13.
9. Yu M, Liu Y, Jia D, Tian T, Xi Q. Adnexal torsion in pregnancy after in vitro fertilization. *Medicine* Adnexal torsion in pregnancy after in vitro fertilization.

- Medicine (Baltimore). 2021;100(3).
10. Aydin T, Yucel B. Laparoscopic management of adnexal torsion in a twin, in vitro fertilization pregnancy at 23 weeks. *Wideochir Inne Tech Maloinwazyjne*. 2014;9(4):655-7.
 11. Bassil S, Steinhart U, Donnez J. Successful laparoscopic management of adnexal torsion during week 25 of a twin pregnancy. *Hum Reprod*.1999 ;14(3) :855-7.
 12. Omari WA, Ghazal-Aswad S, Sidky IH, Bassam MKA. Ovarian salvage in bilaterally complicated severe ovarian hyperstimulation syndrome. *Fertility and Sterility*. 2011 ;96(2): e77-9.
 13. Dursun P, Gülümser Ç, Çağlar M, Araz Ç, Zeyneloğlu H, Haberal A. Laparoendoscopic single-site surgery for acute adnexal pathology during pregnancy: preliminary experience. *The Journal of Maternal-Fetal & Neonatal Medicine*. 2013;26(13):1282-6.
 14. Child TJ, Watson NR, Ledger WL. Sequential bilateral adnexal torsion after a single cycle of gonadotropin ovulation induction with intrauterine insemination. *Fertility and Sterility*.1997 ;67(3):573-5.
 15. Ferrari F, Tisi G, Forte S, Sartori E, Odicino F. Adnexal torsion with normal ovary in the third trimester of a twin pregnancy: Case report and literature review. *Journal of Obstetrics and Gynaecology Research*. 2019;45(1):226-9.
 16. Kahramanoglu I, Eroglu V, Turan H, Kaval G, Sal V, Tokgozoglu N. Isolated adnexal torsion in a 20-week spontaneous twin pregnancy. *Int J Surg Case Rep*. 2016; 23:138-40.
 17. Djakovic A, Hönig A, Gross M, Dietl J. Adnexal torsion in a patient with bichorial twin pregnancy in the 21st week of gestation treated by open laparoscopy: a case report. *Arch Gynecol Obstet*. 2006;274(4):248-9.

18. Schmidt T, Nawroth F, Foth D, Rein DT, Römer T, Mallmann P. Gasless Laparoscopy as an Option for Conservative Therapy of Adnexal Pedicled Torsion with Twin Pregnancy. *The Journal of the American Association of Gynecologic Laparoscopists*. 2001;8(4):621-2.
19. Goshen R, Lavy Y, Hochner-Celnikier H, Milwidsky A. Third Trimester Torsion of Persistent Ovarian Cyst following Ovarian Hyperstimulation – An Unusual Cause of Preterm Labor. *GOI*. 1992;33(4):244-5.
20. Polena V, Huchon C, Varas Ramos C, Rouzier R, Dumont A, Fauconnier A. Non-Invasive Tools for the Diagnosis of Potentially Life-Threatening Gynaecological Emergencies: A Systematic Review. *PLoS One*. 2015;10(2): e0114189
21. Shadinger LL, Andreotti RF, Kurian RL. Preoperative sonographic and clinical characteristics as predictors of ovarian torsion. *J Ultrasound Med*. 2008;27(1):7-13.
22. Swenson DW, Lourenco AP, Beaudoin FL, Grand DJ, Killelea AG, McGregor AJ. Ovarian torsion: Case-control study comparing the sensitivity and specificity of ultrasonography and computed tomography for diagnosis in the emergency department. *European journal of radiology*. 2014;83(4):733-8.
23. Collège National des Gynécologues et Obstétriciens Français. Recommandations pour la pratique clinique : Risques de la voie d'abord en cœlioscopie. 2010.
24. Bassi A, Czuzoj-Shulman N, Abenhaim HA. Effect of Pregnancy on the Management and Outcomes of Ovarian Torsion: A Population-Based Matched Cohort Study. *Journal of Minimally Invasive Gynecology*. 2018 ; 25(7) :1260-5.
25. Daykan Y, Bogin R, Sharvit M, Klein Z, Josephy D, Pomeranz M, et al. Adnexal Torsion during Pregnancy: Outcomes after Surgical Intervention—A Retrospective Case-Control Study. *Journal of Minimally Invasive Gynecology*. 2019 ;26(1):117-21.

- 201 26. Mage, G, Canis M, Manhes H, Pouly JL, Bruhat MA. Laparoscopic management of
202 adnexal torsion. A review of 35 cases. J Reprod Med 1989 ; 34 :520-4.
- 203 27. Vincens C, Rathat G, Boulot P, Giacalone P-L. Recurrent adnexal torsion with
204 normal ovarian, in the second and third trimesters of pregnancy. Gynecol Obstet
205 Fertil. 2010;38(7-8):486-9.

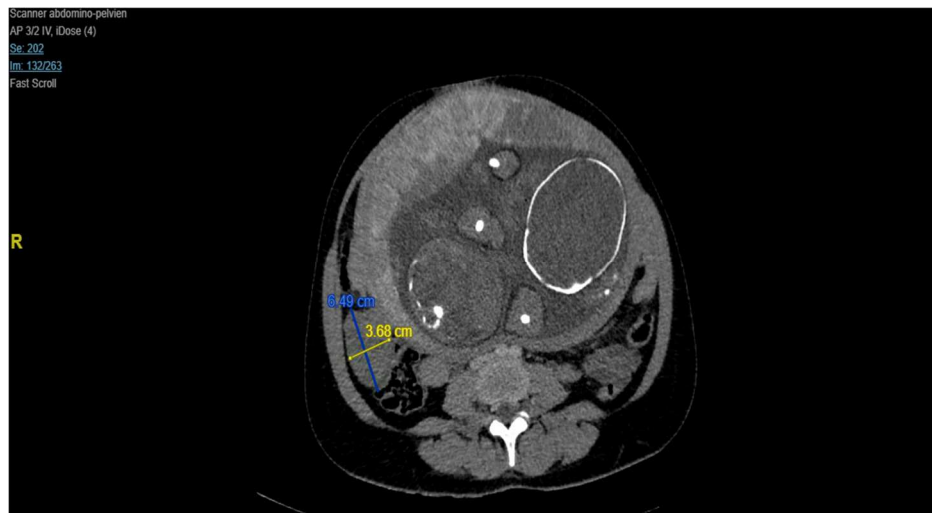


Figure 1. Ovarian mass on CT scan axial image

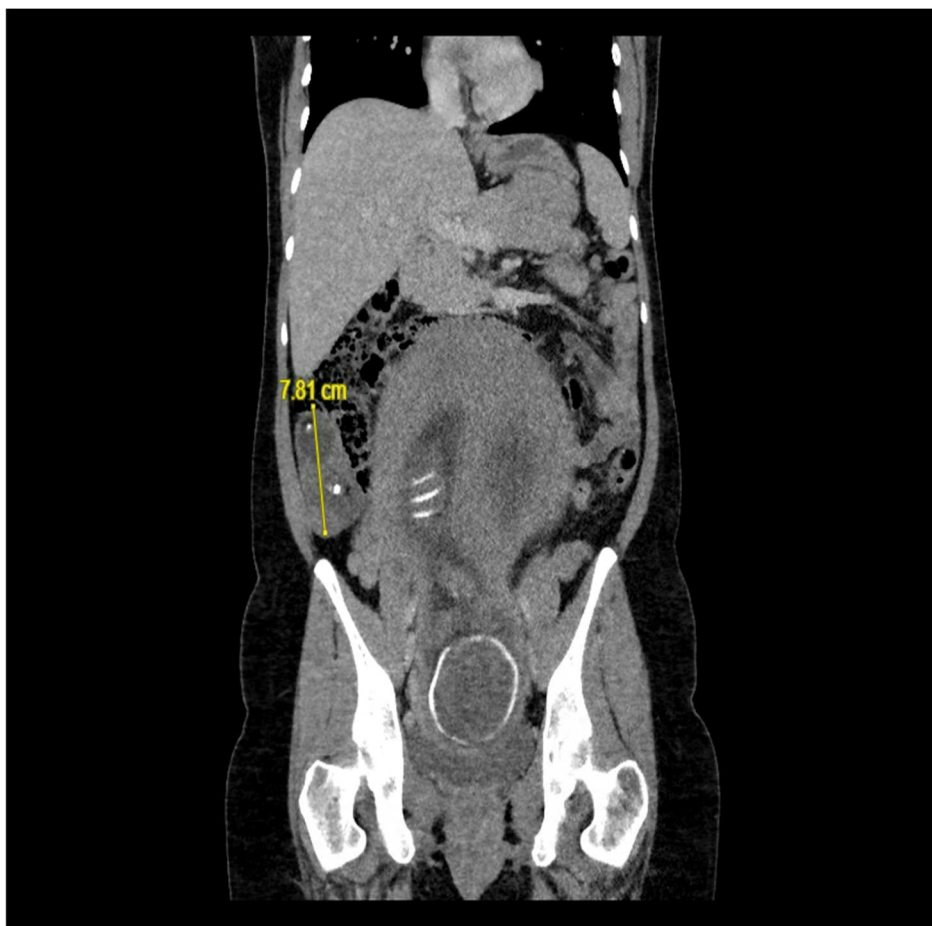

Figure 2. Ovarian Mass on CT scan coronal image

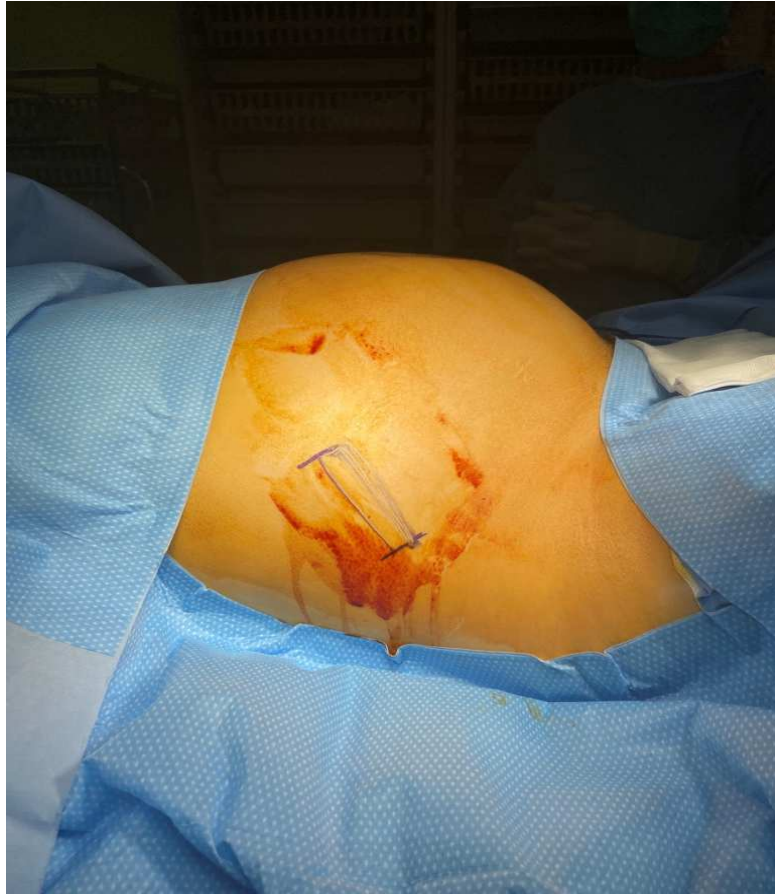

Figure 3: Ultrasound tracking before surgery

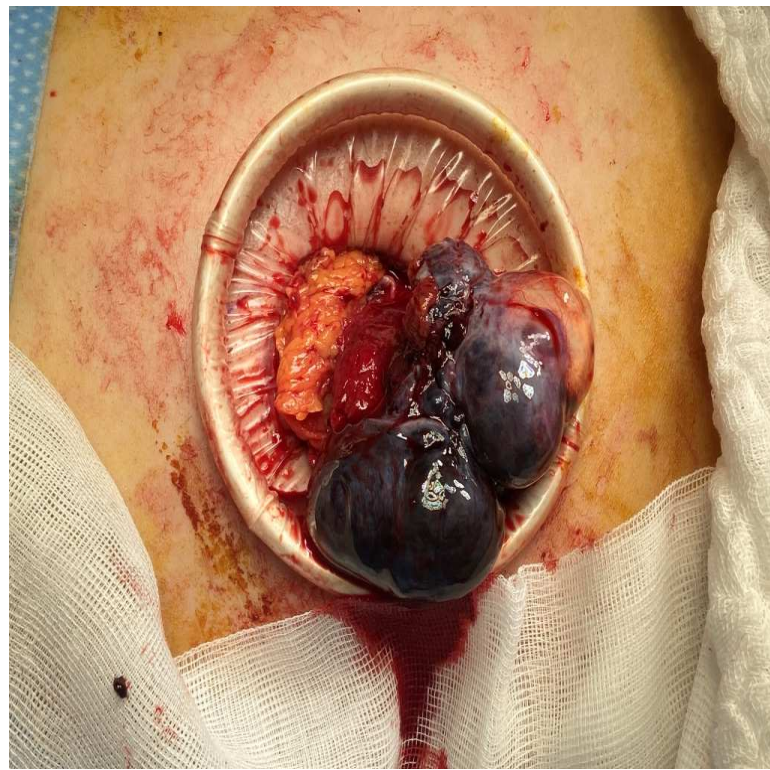


Figure 4: Ovarian torsion with necrotic ovary

Article	Age (years old)	WG	History of ovarian cyst	ART ¹	Onset Symptoms	Detorsion only	Adnexectomy	Side	Timing diagnosis/surgery	Cysts anatomopathology	Risks factors	Obstetrical outcomes
Navarro <i>et al.</i> 2016 ⁶	30	11	No	No	Acute abdominal pain	No	Laparoscopy	Left	Unspecified	Unspecified	Ovarian hyperstimulation syndrome	Spontaneous labor with vaginal delivery at 31 WG ³ ; healthy children
Habek <i>et al.</i> 2016 ⁷	32	5	No	IVF ²	Moderate lower abdominal pain	No	Laparotomy	Right	48 hours	Unspecified	Ovarian hyperstimulation syndrome	Caesarean section at 37 WG ³ for twin breech presentation
Arena <i>et al.</i> 2009 ⁸	38	10	No	IVF ²	Abdominal pain	No	Laparoscopy	Right	Unspecified	Unspecified	Unspecified	Cesarean section due to placenta praevia, term unspecified
Yu <i>et al.</i> 2021 ⁹	32	6	No	IVF ²	Acute lower left abdominal pain Vomiting	Yes, by laparoscopy Normal appearance of the ovary within 20 minutes	No	Left with 3 rotations	1 hours 30	No ovarian cyst	No	Delivery at 30 WG ³ ; one child died
Aydin <i>et al.</i> 2014 ¹⁰	28	23	No	IVF ²	Lower abdominal pain Vomiting	Yes, by laparoscopy Decrease of the adnexal edema and re-coloration of the ovary after a few minutes	No	Right with 3 rotations	Unspecified	Right ovary was normal during cesarean section	No	Cesarean section at 35 WG ³ . Healthy children
Bassil <i>et al.</i> 1999 ¹¹	33	25	No	IVF ²	Left flank and abdominal lower pain Vomiting	Yes, by laparoscopy	No	Left	Unspecified	No ovarian cyst	Ovarian hyperstimulation syndrome	Vaginal delivery at 33 WG ³ . Healthy children
Omari <i>et al.</i> 2011 ¹²	30	10	No	IVF ²	Left lower abdominal pain Vomiting	No	Yes, only the left side	Left and right three day after	Unspecified	Right ovary was normal during cesarean section	Ovarian hyperstimulation syndrome	Preterm labor at 35 WG ³ . Cesarean section (first twin was in breech presentation)
Dursun <i>et al.</i> 2013 ¹³	-	25	No	IVF ²	Colic pain Vomiting	No	Laparoscopy single port	Left	Unspecified	Unspecified	Ovarian hyperstimulation syndrome	Cesarean section at 33 WG ³
Child <i>et al.</i> 1997 ¹⁴	35	6	No	IUI ¹	Acute right iliac fossa pain	Yes, by laparotomy for left ovary	Laparotomy after laparoscopy for the right ovary	Right with 2 rotations and the left 3 days after the first surgery	4 hours after the onset of pain for the first surgery	Normal looking of the left ovary during cesarean section	No	Cesarean at 37 WG ³ for spontaneous labor and previous cesarean
Ferrari <i>et al.</i> 2019 ¹⁵	34	32	No	No	Acute right lower abdominal pain	Yes, by laparotomy under umbilicus	No	Right with 2 rotations	Unspecified	No ovarian cyst	No	Caesarean section at 38 WG ³ for transverse foetal position
Kahramanoglu <i>et al.</i> 2016 ¹⁶	32	20	No	No	Right lower abdominal pain	Yes, by laparoscopy	No	Right 2 rotations	3 hours	No ovarian cyst	No	Caesarean section at 36 WG ³ for severe preeclampsia
Djakovic <i>et al.</i> 2006 ¹⁷	26	21	No	OI ⁵	Left lower abdominal pain	Yes, by laparoscopy	No	Left twisted	At least 5 hours	Normal size and color during cesarean section	No	Caesarean section at 37 WG ³
Schmidt <i>et al.</i> 2001 ¹⁸	36	5	No	No	Acute abdomen	Yes, by laparoscopy	No	Right	Unspecified	Right ovary appears normal during Caesarean section	No	Caesarean section at 34 WG ³ for intra uterine growth retardation

Table 1: Ovarian torsion in twin pregnancies: a literature review

¹ ART: assisted reproductive techniques

² IVF: In vitro fertilization,

³ WG: week of gestation

⁴ IUI: intra uterine insemination

⁵ OI: ovulation induction