



HAL
open science

Orientation and end zone of the osteotomy cut for high tibial osteotomy: Influence on the risk of lateral hinge fracture. A finite element analysis.

Wiyao Azoti, Mohammadjavad Aghazade, Matthieu Ollivier, Nadia Bahlouli, Henri Favreau, Matthieu Ehlinger

► To cite this version:

Wiyao Azoti, Mohammadjavad Aghazade, Matthieu Ollivier, Nadia Bahlouli, Henri Favreau, et al.. Orientation and end zone of the osteotomy cut for high tibial osteotomy: Influence on the risk of lateral hinge fracture. A finite element analysis.. Orthopaedics & Traumatology: Surgery & Research, 2021, 107 (7), pp.103031. 10.1016/j.otsr.2021.103031 . hal-03553776

HAL Id: hal-03553776

<https://hal.science/hal-03553776>

Submitted on 29 Apr 2022

HAL is a multi-disciplinary open access archive for the deposit and dissemination of scientific research documents, whether they are published or not. The documents may come from teaching and research institutions in France or abroad, or from public or private research centers.

L'archive ouverte pluridisciplinaire **HAL**, est destinée au dépôt et à la diffusion de documents scientifiques de niveau recherche, publiés ou non, émanant des établissements d'enseignement et de recherche français ou étrangers, des laboratoires publics ou privés.

Original article

Orientation and end zone of the osteotomy cut for high tibial osteotomy: Influence on the risk of lateral hinge fracture. A finite element analysis

Wiyao Azoti^a, Mohammadjavad Aghazade^a, Matthieu Ollivier^b, Nadia Bahlouli^a, Henri Favreau^c, Matthieu Ehlinger^{a,c,*}

^a Laboratoire ICube, équipe MMB, 67400 Illkirch, France

^b Département de chirurgie orthopédique, hôpital Sainte-Marguerite, hôpital Universitaire de Marseille, 270, boulevard Sainte-Marguerite, 13009 Marseille, France

^c Service de chirurgie orthopédique et de traumatologie, hôpital de Hautepierre, 1, avenue Molière, 67098 Strasbourg cedex, France

ARTICLE INFO

Keywords:

Hinge
Tibial osteotomy
Finite element
Simulation

ABSTRACT

Introduction: the hinge plays a fundamental role in the support and consolidation of a high tibial osteotomy. The objective of this work was to analyse the influence of the end zone of the osteotomy cut and its orientation in relation to the articular joint line (JL) on the risk of hinge fracture.

Hypothesis: a specific orientation and end zone of the osteotomy cut can be utilised to decrease the risk of hinge fracture.

Material and Method: a finite element (FE) model was used to reproduce the proximal portion of the tibia and the proximal tibiofibular joint with transverse isotropic elastic bone properties. A 1.27 mm thick, complete, anteroposterior saw cut was made with a U-shaped saw blade. Five proximal and lateral tibial zones were used according to Nakamura et al corresponding to the end zones of the osteotomy cut. Three angulations of the cut relative to the JL were defined: 10°, 15°, 20°. The tests consisted of simulating 15 possible situations (3 angulations for each of the 5 end zones) on this model. These simulations made it possible to identify the existence of a local stress concentration (von Mises, in MPa) at the level of the hinge, corresponding to the main judgment criterion.

Results: If we consider only the end zones of the osteotomy cut, regardless of its angulation with respect to the JL, the zone which presents, on average, the lowest local stress concentration is the AM zone (40.3 MPa). If we consider only the angulation of the osteotomy cut, with respect to the JL, regardless of the end zone of the cut, the angulation that locally concentrates, on average, the least stress is an angulation at 10° (147.7 MPa). Finally, it is important to define the best end zone of the osteotomy cut for each angulation value in relation to the JL: for an angulation of 10°, the end zone must be in AM (38 MPa), but also for an angulation of 15° (45 MPa), and for an angulation of 20° (38 MPa).

Discussion–conclusion: With the inherent caveats of the experimental conditions, the hypothesis is confirmed. An end zone of the osteotomy cut exists (AM) and an orientation (10°) that induces the lowest local stress concentration and therefore the least likely to induce lateral hinge fracture. However, the orientation of the osteotomy cut is also a matter of surgical habit, especially regarding complementary osteotomy of the tibial tuberosity that some may want to avoid. Thus, it is equally important to know the best end zone associated with a given angulation of the cut in relation to the JL, which according to these results is the AM zone for each angulation. This information helps guide the operator in their surgical practices according to their habits.

Level of evidence: V, expert opinion.

1. Introduction

High tibial osteotomy (HTO) is an effective solution in the treatment of isolated medial osteoarthritis in young patients [1] and there is no difference between opening-wedge or closing-wedge HTO [2].

On the other hand, respecting and protecting the lateral hinge is essential to the success of a medial opening HTO. In fact, this hinge makes it possible to preserve the angular correction, to ensure primary stability and to achieve bone union within a reasonable timeframe [3–7].

Recently it has been shown that the placement of a hinge pin through a custom-made cutting guide [5] protects it [6] by increasing the maximum breaking load by 880% [7].

In addition, we considered the influence of the end zone of the osteotomy cut but also the orientation of this cut in relation to the joint line (JL) with respect to the risk of a lateral hinge fracture. Literature from both clinical and experimental studies, pertaining to the end zone of the osteotomy cut, remains controversial [8–11]. However, to our knowledge, no study has analysed the orientation of the osteotomy cut in relation to the JL let alone the association of the two parameters.

The objective of this work was to analyse the influence of the end zone of the osteotomy cut and its orientation in relation to the JL on the risk of hinge fracture using a finite element (FE) model [12]. This was achieved by incorporation of the proximal tibiofibular joint, allowing these results to be compared with those of Nakamura et al. [8] along with all the caveats inherent to a FE analysis. The hypothesis was that there is an orientation and an end zone of the osteotomy cut reducing the risk of lateral hinge fracture.

2. Materials and methods

2.1. The model

The FE model of the proximal tibia used in this work has been validated [12] and is cortical with transverse isotropic elastic behaviour, since its properties are independent of the direction in the transverse plane. Instead, the proximal tibiofibular joint was incorporated, with the aim of getting as close as possible to reality, subject to experimental conditions, and to compare with the results of Nakamura et al. [8] (Fig. 1).

The saw cut modelled was complete and anteroposterior (with a saw blade thickness of 1.27 mm). The shape of the saw blade used was U-shaped, corresponding to the shape that caused the lowest risk of hinge fracture from preliminary work [12] (Fig. 2). The osteotomy opening occurred by a load applied distally with the proximal portion fixed, at a rate of 1 mm/sec until the desired opening of 10°, was obtained.

Five proximal and lateral tibial zones were defined, corresponding to the five zones of Nakamura and al [8] (Fig. 3): AL, AM, WL, WM, B.

Three angulations of the osteotomy cut with respect to the JL were chosen: 10°, 15°, 20°, following conventionally observed practices (ME, MO) (Fig. 4). Indeed, some authors want to avoid performing a complementary tibial tuberosity osteotomy (TTO) and thus prefer an osteotomy cut with a lower obliquity, conversely, others aim for TTO and make the cut more vertical.

2.2. Simulation procedure

The tests consisted of 15 possible situations, simulated by the FE model; 3 angulations of the osteotomy cut in relation to the JL for each of the 5 end zones of the cut. The ABAQUS software (Inc Dassault Systèmes, France) was used.

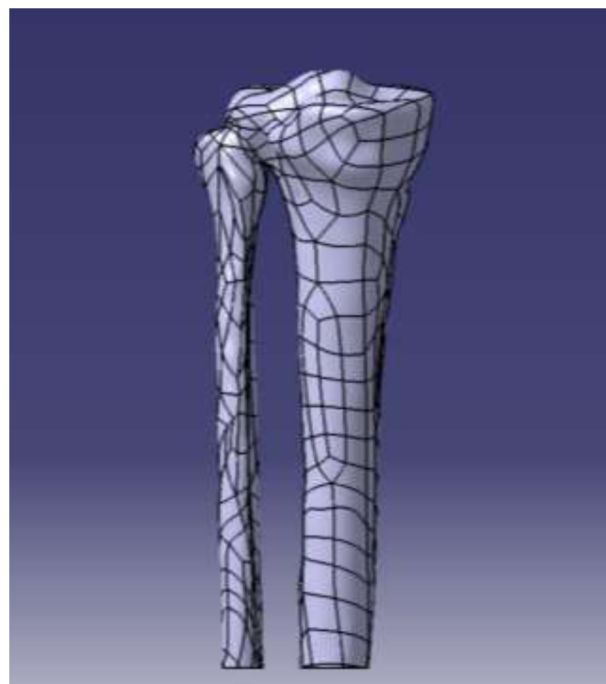


Fig. 1. FE model of the proximal tibia and proximal tibiofibular joint.

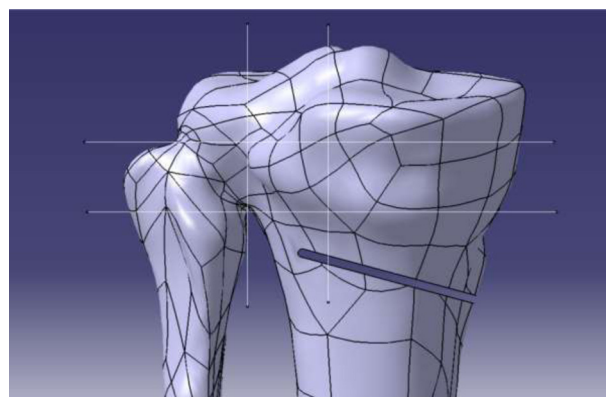


Fig. 2. FE modelling of the saw line using a U-shaped saw blade [12].

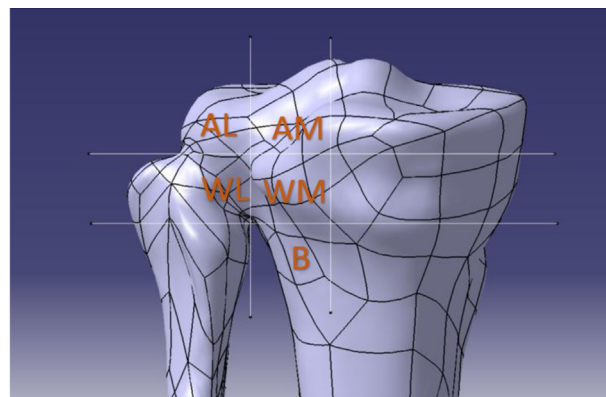


Fig. 3. Reproduction of the 5 zones defined by Nakamura et al. [8]. L: lateral; M: medial. A (AL and AM): defined zone above the top of the fibula. B: defined below the distal boundary of the proximal tibiofibular joint. W: intermediate zone between A and B.

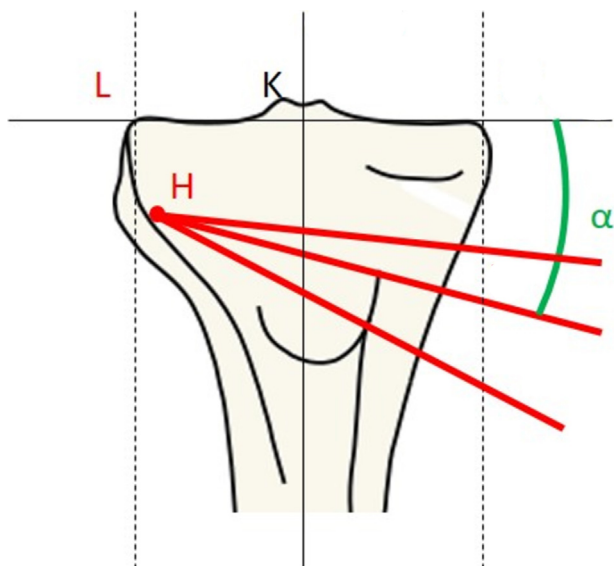


Fig. 4. Schematic representation of the 3 angulations of the osteotomy cut. Right tibia. L: lateral; M: medial; K: centre of the knee; H: end of the osteotomy cut; alpha: an oblique angle relative to the horizontal.

2.3. Study criteria

These simulations made it possible to measure the local stress concentration (von Mises, in MPa) at the level of the hinge. These stress concentrations are defined by a colour level integrated into the software. The von Mises yield criterion is based on the theory of plasticity and indicates the equivalent stress state in the material. This criterion specifies the time at which the material will deform without being able to return to its original state.

The measurement of these local stress concentrations makes it possible to define situations with the least risk of secondary hinge fracture: the lower the stress concentration the lower the risk of fracture.

3. Results

If only the end zones of the osteotomy cut are considered, regardless of their angulation with respect to the JL, the zone with the lowest local stress concentration on average is the AM zone (40.3 MPa) (Table 1).

If we consider only the angulation of the osteotomy cut with respect to the JL, regardless of the end zone of the cut, the angulation that concentrates locally on average the least stress is an angulation of 10° (147.7 MPa), but with little marked differences in terms of the absolute value of the results.

It is important to define the best end zone of the osteotomy cut by the oblique cut in relation to the JL:

Table 1
Results of local stress concentrations (MPa) according to the von Mises yield criterion.

	10° Angulation	15° Angulation	20° Angulation	Average concentration for each end zone
AM	38	45	38	40.3
AL	239	207	225	223.7
WL	187	182	184	184.3
WM	103	104	103	103.3
B	170	227	206	201
Average concentration for each angulation	147.7	153	151.2	150.5

L: lateral; M: medial. A (AL and AM): defined area above the top of the fibula. B: defined below the distal boundary of the proximal tibiofibular joint. W: intermediate zone between A and B.

- for an angulation of 10° the most favourable end zone is AM (38 MPa);
- for an angulation of 15° the most favourable end zone is AM (45 MPa);
- for an angulation of 20° the most favourable end zone is AM (38 MPa).

4. Discussion

The objective of this work was to study the influence of the end zone of the osteotomy cut and its angulation compared to the JL on a FE model of the proximal tibia by associating the proximal tibiofibular joint. The hypothesis has been verified. Finishing in the AM zone is the least likely to break the hinge and, unsurprisingly, the lowest of the 3 angulations tested (10°) is the least likely to break the hinge. This work also made it possible to identify for each angulation a favourable end zone of the osteotomy cut, making it possible to respond to individual surgical practices, which correspond to the AM zone.

Respecting the lateral hinge during a HTO appears to be fundamental to the success of the intervention [3–7], allowing an easier, faster consolidation, stable correction and better functional results [13]. Hinge fractures decrease axial stiffness (by 58%) and torsional stiffness (by 68%) [14]. However, some authors have observed that the existence of a hinge fracture was not an unfavourable local factor to the development of a HTO [15,16], particularly concerning consolidation. Lateral hinge fractures remain frequent at approximately 25% [17–19]. Some authors also encourage the use of a CT scan [18] if there is the slightest doubt, because 25% of fractures are observed by CT scan while only 16% are detected with x-ray [19].

Risk factors for lateral hinge fracture have been identified in the literature. Some studies highlight obesity as unfavourable to the hinge integrity and to achieving quality consolidation. [16,20]. While others underline the importance of the angular correction of the HTO that must be recognized as a fracture factor [8,19,21], but this point remains debated [22]. Finally, the surgical experience appears fundamental [23], which can also be related to the importance of the angular correction to be made.

Conversely, elements that can protect the hinge are also reported in the literature. Notably, the surgical experience and low angular correction are favourable [8,19,21,23], which this study confirms with the least risk of hinge fracture for the lowest angulation (10°) of the 3 tested. To our knowledge, no publication reports the influence of the angulation of the osteotomy cut in relation to JL, so the discussion will be limited. On the other hand, concerning the end zone of the osteotomy cut the literature is more prolific (Table 2) and the end zone of the cut is considered by some authors as an essential factor in hinge protection. However, there appears to be a lack of consensus on the zone, since 4 zones are popular: AL, AM, WL and WM. The FE analysis reported here also showed that regardless of the angulation of the osteotomy cut, this cutting line should finish in the AM zone. This makes it possible to

Table 2
Summary table of the end zones of the osteotomy cut found by the literature.

Authors	Year	Location according to Fig 3
Kessler et al. [24]	2002	WM; since the zone is 2 cm below the lateral medial condyle and 1 cm from the lateral cortical
Staubli et al. [25]	2003	AL
Lobenhoffer et Agneskirchner [26]	2003	WM
Staubli et Jacob [27]	2010	WL and WM
Jacobi et al. [28]	2010	AL
Takeuchi et al. [17]	2012	WL
Vanadurongwan et al. [29]	2013	AL
Han et al. [30]	2013	WL and AL
Nakamura et al. [8]	2017	WL
Ogawa et al. [10]	2017	AL

L: lateral; M: medial. A (AL and AM): defined area above the top of the fibula. B: defined below the distal boundary of the proximal tibiofibular joint. W: intermediate zone between A and B.

provide some answers to individual surgical practices and habits, because indeed some surgeons want to avoid a TTO while others seek it. The WL zone, in relation to the proximal tibiofibular joint, certainly has anatomical advantages which may well explain why it is preferred by some authors; greater bone mineral density in that region [31] and there are ligamentous and tendinous elements that intrinsically contribute to its stability and therefore reduce the risk of rupture [30,32]. Finally, certain technical solutions have been proposed to protect the lateral hinge: 1) placement of a pin to protect the hinge, positioned through a custom-made cutting guide [5–7,33], 2) a pin positioned via an anteroposterior path to the lateral end of the osteotomy cut [34] to reduce local stresses on the lateral cortex, 3) use of a locked plate to maintain angular correction and protect the hinge [35], 4) use of a cutting protection system to allow control of the cutting depth thus leaving a sufficient hinge thickness [36,37], while acknowledging that navigation also allows this depth control [38], 5) use of a temporary external lateral compression fixator compressing the lateral side [28].

This work has limitations but also strengths.

These are in vitro data with a FE model that does not strictly correspond to the structural reality of the proximal tibia. The force exerted and the displacement are relatively low, thus not necessarily reproducing the surgical conditions in vivo. The model is digital, continuous, elastic and isotropic, which induces a linear distribution of the mechanical properties of volume, possibly influencing its interpretation in clinical practice. Finally, the modelling of the proximal tibiofibular joint does not exhibit any flexibility or micro-mobility as observed in the clinical setting. The results found here, i.e. the AM zone, must be placed in this experimental context by FE, because in practice it is obvious that the proper positioning of the plate and the fixation screws of the osteotomy can be difficult at the level of such a proximal zone.

On the other hand, it presents strengths, since to our knowledge it is the only study to: 1) analyse the influence of the obliquity of the osteotomy cut in relation to the JL and 2) to model the proximal tibiofibular joint making it possible to approach the macroscopic anatomy and to allow the literature concerning the preferred different end areas of the osteotomy cut to be addressed, from a theoretical point of view. In addition, adding the end zone of the osteotomy cut as an analysis parameter makes it possible to define a favourable zone according to the obliquity of the cut and thus to respond to the different choices and habits of surgeons.

5. Conclusion

With the inherent caveats of the experimental conditions, the hypothesis was confirmed. From a theoretical point of view, there

is an end zone of the osteotomy cut (AM) and an angulation (10°) which induce the lowest local stress concentrations and therefore a situation less conducive to a hinge fracture. However, this AM zone must be considered with caution due to the risk of technical difficulties in placing screws in the proximal fragment with a risk of a lateral tibial condyle fracture. This is in consideration of the 15 tests performed, but also the level of angulation of the cut compared to the JL where the AM end zone is the least risky. This information could help guide the surgeon's practices according to their habits, however large-scale clinical studies are needed.

Disclosure of interest

The authors declare that they have no competing interest.
ME: Depuy-Synthes®, Lepine®, NewClip®, Amplitude®, Sofcot Teaching Conference Writer.
MA, WA, HF, NB: none.
MO: Education Consultant Arthrex®, Newclip®, Stryker®.

Sources of funding

None.

Contribution of the authors

ME, HF: writing.
HF, MO: bibliography.
WA, MO, NB: proofreading.
ME, MA, WA: data collection.

References

- [1] Gstottner M, Pedross F, Liedensteiner M, Bach C. Long term outcome after high tibial osteotomy. *Arch Orthop Trauma Surg* 2008;128:111–5.
- [2] Sun H, Zhou L, Li F, Duan J. Comparison between closing-wedge and opening-wedge high tibial osteotomy in patients with medial knee osteoarthritis: a systematic review and meta-analysis. *J Knee Surg* 2017;30:158–65.
- [3] Nawas HT, Vansadia DV, Heltsley JR, Suri M, Montgomery S, Jones DG. Factors affecting the union of opening wedge high tibial osteotomy using a titanium wedge plate. *Ochsner J* 2016;16:464–70.
- [4] Yokoyama M, Nakamura Y, Onishi T, Hirano K, Doi M. Healing period after open high tibial osteotomy and related factors: can we really say that it is long? *Springer* 2016;5:123.
- [5] Munier M, Donnez M, Ollivier M, Flecher X, Chabrand P, Argenson JN, et al. Can three-dimensional patient-specific cutting guides be used to achieve optimal correction for high tibial osteotomy? Pilot study. *Orthop Traumatol Surg Res* 2017;103:245–50.
- [6] Gualagaci F, Jacquet C, Ehlinger M, Sharma A, Kley K, Wilson A, et al. A protective hinge wire, intersecting the osteotomy plane, can reduce the occurrence of perioperative hinge fractures in medial opening wedge osteotomy. *Knee Surg Sports Traumatol Arthrosc* 2020;28:3173–82.
- [7] Dessyn E, Sharma A, Donnez M, Chabrand P, Ehlinger M, Argenson JN, et al. Adding a protective K-wire during opening high tibial osteotomy increases lateral hinge resistance to fracture. *Knee Surg Sports Traumatol Arthrosc* 2020;28:751–8.
- [8] Nakamura R, Komatsu N, Fujita K, Kurida K, Takahashi M, Omi R, et al. Appropriate hinge position for prevention of unstable lateral hinge fracture in open wedge high tibial osteotomy. *Bone Joint J* 2017;99B:1313–8.
- [9] Ducat A, Sariali E, Lebel B, Mertl P, Hernigou P, Flecher X, et al. Posterior tibial slope changes after opening- and closing-wedge high tibial osteotomy: a comparative prospective multicenter study. *Orthop Traumatol Surg Res* 2012;98:68–74.
- [10] Ogawa H, Matsumoto K, Akiyama H. The prevention of a lateral hinge fracture as a complication of a medial opening wedge high tibial osteotomy: a case control study. *Bone Joint J* 2017;99B:887–93.
- [11] Villatte G, Erivan R, Fournier PL, Pereira B, Galvin M, Descamps S, et al. Opening-wedge high tibial osteotomy with a secure bone allograft (Osteopure) and mocked plate fixation: retrospective clinical and radiological evaluation of 69 knees after 7.5 years follow-up. *Orthop Traumatol Surg Res* 2015;101:953–7.
- [12] Ehlinger M, Ollivier M, Course S, Guerin A, Lantz E, Zahraa D, et al. Effect of saw blade geometry on crack initiation and propagation on the lateral cortical hinge for HTO: finite elements analysis. *Orthop Traumatol Surg Res* 2019;105:1079–83.
- [13] Bouguennec N, Mergenthaler G, Gicquel T, Briand C, Nadau E, Pailhé R, et al. Medium-term survival and clinical and radiological results in high tibial

- osteotomy: factors for failure and comparison with unicompartmental arthroplasty. *Orthop Traumatol Surg Res* 2020;106:S223–30.
- [14] Miller BS, Dorsey WO, Bryant CR, Austin JC. The effect of lateral cortex disruption and repair on the stability of the medial opening wedge high tibial osteotomy. *Am J Sports Med* 2005;33:1552–7.
- [15] Kobayashi H, Akamatsu Y, Kumagai K, Kusayama Y, Saito T. radiographic and computed tomographic evaluation of bone union after medial opening wedge high tibial osteotomy with filling gap. *Knee* 2017;24:1108–17.
- [16] van Houten AH, Heesterbeek PJ, van heerwaarden RJ, van Tienen TG, Wymenga AB. Medial open wedge high tibial osteotomy: can delayed or nonunion be predicted? *Clin Orthop Relat Res* 2014;472:1217–23.
- [17] Takeuchi R, Ishikawa H, Kumagai K, Yamaguchi Y, Chiba N, Akamatsu Y, et al. Fractures around the lateral cortical hinge after a medial opening-wedge high tibial osteotomy: a new classification of lateral hinge fracture. *Arthroscopy* 2012;28:85–94.
- [18] Lee OS, Lee YS. Diagnostic value of computed tomography and risk factors for lateral hinge fracture in the open wedge high tibial osteotomy. *Arthroscopy* 2018;34:1032–43.
- [19] Lee SS, Celik H, Lee DH. Predictive factors for and detection of lateral hinge fractures following open wedge high tibial osteotomy: plain radiography versus computed tomography. *Arthroscopy* 2018;34:3073–9.
- [20] Meidinger G, Imhoff AB, Paul J, Kirchoff C, Sauersching M, Hinterwimmer S. May smokers and overweight patients be treated with a medial opening wedge HTO? Risk factors for non-union. *Knee surg sports Traumatol Arthrosc* 2011;19:333–9.
- [21] Miller BS, Downie B, McDonough EB, Wojtys EM. Complications after medial opening wedge high tibial osteotomy. *Arthroscopy* 2009;25:639–46.
- [22] Nelissen EM, van Langelaan EJ, Nelissen RG. Stability of medial opening wedge high tibial osteotomy: a failure analysis. *Int Orthop* 2010;34:217–23.
- [23] Lee DK, Kim KK, Ham CU, Yun ST, Kim BK, Ok KJ. The learning curve for biplanar medial open wedge high tibial osteotomy in 100 consecutive cases assessed using the cumulative summation method. *Knee Surg Relat Res* 2018;30:303–10.
- [24] Kessler OC, Jacob HA, Romero J. Avoidance of medial cortical fracture in high tibial osteotomy: improved technique. *Clin Orthop Relat Res* 2002;395:180–5.
- [25] Staubli AE, De Simni C, Babst R, Lobenhoffer P. Tomofix: a new LCP-concept for open wedge osteotomy of medial tibia – early results in 92 cases. *Injury* 2003;34:B55–62.
- [26] Lobenhoffer P, Agneskirchner JD. Improvements in surgical technique of valgus high tibial osteotomy. *Knee Surg Sports Traumatol Arthrosc* 2003;11:132–8.
- [27] Staubli AE, Jacob HA. Evolution of open-wedge high-tibial osteotomy experience with a special angular stable device for internal fixation without interposition material. *Int Orthop* 2010;34:167–72.
- [28] Jacobi M, Wahl P, Jacob RP. Avoiding intraoperative complications in opening-wedge high tibial valgus osteotomy: technical advancement. *Knee Surg Sports Traumatol Arthrosc* 2010;18:200–3.
- [29] Vanadurongwan B, Siripisitsak T, Sudjai N, Harnroongroj T. The anatomical safe for medial opening oblique wedge high tibial osteotomy. *Singapore Med J* 2013;54:102–4.
- [30] Han SB, Lee DH, Shetty GM, Chae DJ, Song JG, Nha KW. A “safe” in medial opening wedge high tibia osteotomy to prevent lateral cortex fracture. *Knee Surg Sports Traumatol Arthrosc* 2013;21:90–5.
- [31] Lee YS, Won JS, Oh WS, Park HG, Lee BK. Lateral tibial bone mineral density around the level of the proximal tibiofibular joint. *Knee Surg Sports Traumatol Arthrosc* 2014;22:1678–83.
- [32] Barsoum WK, Lee HH, Murray TG, Colbrunn R, Klika AK, Butler S, et al. Robotic testing of proximal tibio-fibular joint kinetics for measuring instability following arthroplasty. *J Orthop Res* 2011;29:47–52.
- [33] Tardy N, Steltzlen C, Bouguennec N, Cartier JL, Mertil P, Batailler C, et al. Is patient-specific instrumentation more precise than conventional techniques and navigation in achieving planned correction in high tibial osteotomy? *Orthop Ytaumatol Surg res* 2020;106:S231–6.
- [34] Difo Kaze A, Maas S, Hoffmann A, Pape D. Mechanical strength assessment of a drilled hole in the contralateral cortex at the end of th open wedge for high tibial osteotomy. *J Exp Orthop* 2017;4:23.
- [35] Han JH, Kim HJ, Song JG, Yang JH, Nakamura R, Shah D, et al. Locking plate versus non-locking plate in open-wedge high tibial osteotomy: a meta-analysis. *Knee Surg Sports Traumatol Arthrosc* 2017;25:808–16.
- [36] Lee YS, Moon GH. Comparative analysis of osteotomy accuracy between the conventional and devised technique using a protective cutting system in medial open-wedge high tibial osteotomy. *J Orthop Sci* 2015;20:129–36.
- [37] Lee YS, Lee MC, Kang SG, Elazab A, Oh WS. Open-wedge high tibial osteotomy using a protective cutting system: technical advancement complications. *Arthrosc Tech* 2016;5(e7):10.
- [38] Saragaglia D, Chedal-Bornu B, Rouchy RC, Rubens-Duval B, Mader R, Pailhé R. Role of computer-assisted surgery in osteotomies around the knee. *Knee Surg Sports Traumatol Arthrosc* 2016;24:3387–95.