



**HAL**  
open science

## Arthroscopic Repair of the Hip Abductor Musculotendinous Unit: The Effect of Microfracture on Clinical Outcomes.

Baris Kocaoglu, Ahmet Emre Paksoy, Simone Cerciello, Matthieu Ollivier,  
Romain Seil, Marc Safran

► **To cite this version:**

Baris Kocaoglu, Ahmet Emre Paksoy, Simone Cerciello, Matthieu Ollivier, Romain Seil, et al..  
Arthroscopic Repair of the Hip Abductor Musculotendinous Unit: The Effect of Microfracture  
on Clinical Outcomes.. The American Journal of Sports Medicine, 2021, 49 (6), pp.1570–1577.  
10.1177/0363546521999678 . hal-03553767

**HAL Id: hal-03553767**

**<https://hal.science/hal-03553767v1>**

Submitted on 15 Apr 2022

**HAL** is a multi-disciplinary open access archive for the deposit and dissemination of scientific research documents, whether they are published or not. The documents may come from teaching and research institutions in France or abroad, or from public or private research centers.

L'archive ouverte pluridisciplinaire **HAL**, est destinée au dépôt et à la diffusion de documents scientifiques de niveau recherche, publiés ou non, émanant des établissements d'enseignement et de recherche français ou étrangers, des laboratoires publics ou privés.

# Arthroscopic Repair of the Hip Abductor Musculotendinous Unit

## The Effect of Microfracture on Clinical Outcomes

Baris Kocaoglu,<sup>\*†</sup> MD, Ahmet Emre Paksoy,<sup>†</sup> MD, Simone Cerciello,<sup>‡§</sup> MD, Matthieu Ollivier,<sup>||</sup> MD, Romain Seil,<sup>¶#</sup> MD, and Marc Safran,<sup>\*\*</sup> MD  
*Investigation performed at Acibadem Altunizade Hospital, Istanbul, Turkey*

**Background:** Endoscopic surgical repair has become a common procedure for treating patients with hip abductor tendon tears. Considering that retear rates are high after the repair of gluteus medius and minimus tendons, exploring alternative strategies to enhance structural healing is important.

**Purpose/Hypothesis:** The purpose of this study was to evaluate the effect of adding microfracture to single-row repair (SR) on outcomes after the surgical repair of gluteus medius and minimus tendons and compare with SR and double-row repair (DR) without microfracture. We hypothesized that microfracture of the trochanteric footprint with SR would lead to superior clinical outcomes and lower clinically evident retear rates compared with SR and DR without the addition of microfracture.

**Study Design:** Cohort study; Level of evidence, 3.

**Methods:** A total of 50 patients who underwent primary arthroscopic repair of hip gluteus medius and minimus tendon tears were investigated. Patients were divided into 3 groups: DR, 16 patients; SR, 14 patients; and SR with microfracture (SRM), 20 patients. Patients were evaluated with a visual analog scale (VAS) for pain as well as the Hip Outcome Score–Activities of Daily Living (HOS-ADL), Hip Outcome Score–Sport Specific (HOS-SS), and modified Harris Hip Score (mHHS) both preoperatively and at a minimum 2-year follow-up (mean, 30 months).

**Results:** Among the SR, SRM, and DR groups, the greatest decrease in VAS scores and increase in mHHS, HOS-ADL, and HOS-SS scores were seen in the SRM group, and all the differences were significant ( $P < .001$  to  $P = .006$ ). The abductor tendon retear rates were 31.3%, 35.7%, and 15.0% in the DR, SR, and SRM groups, respectively. Retear rates were lower in the SRM group compared with the SR and DR groups ( $P = .042$ ); however, there was no significant difference between the SR and DR groups ( $P = .32$ ) in terms of retear rates.

**Conclusion:** Endoscopic SR with microfracture was a safe, practical, and effective technique and had the potential advantage of enhancing biological healing at the footprint. The addition of microfracturing the trochanteric footprint significantly lowered the retear rate and provided better functional outcomes than SR and DR without microfracture.

**Keywords:** endoscopic gluteus medius repair; microfracture; single-row repair; double-row repair

Gluteus medius and minimus tendon tears have been recognized as a major cause of recalcitrant greater trochanteric pain syndrome.<sup>6,7</sup> Some authors noted the similarity of gluteus medius and minimus tendon insertions on the greater trochanter with those of the rotator cuff, leading to term hip abductor tendon tears as “rotator cuff tears of the hip.”<sup>3,15</sup>

Surgery is indicated when there are 4 associated conditions similar to rotator cuff tears: (1) duration of symptoms >6 months; (2) magnetic resonance imaging (MRI) showing a tendon tear; (3) failure of nonoperative management

including physical therapy, activity modification, and injections; and (4) absence of significant retraction or fatty degeneration of the gluteus medius and minimus muscles.<sup>19</sup>

As with rotator cuff abnormalities, higher retear rates after repair have been associated with older age, a larger tear size, significant fatty infiltration, the presence of comorbidities, and possibly the use of a single-row technique.<sup>2,3</sup> Retear rates differ after gluteus medius and minimus tendon repair. In some studies, retear rates are low; thus, good and excellent results are demonstrated.<sup>6,12,13,15</sup> On the other hand, some other studies show high retear rates, which led to exploring alternative strategies to enhance structural healing, including biological growth factors such as platelet-rich plasma, grafts, and suture-augmentation techniques.<sup>4,8,9,11,16,19</sup>

Single-row repair with microfracture (SRM) of the greater trochanter could be an option as it is a confirmed procedure in rotator cuff surgery that has gained popularity because of the simplicity of the technique. The biology of gluteus medius and minimus tendon repair could be enhanced with bone marrow vents created by microfracture of the greater trochanter, forming a “crimson duvet” or bone marrow superclot, which will envelop the repair site, similar to that seen with rotator cuff repair.<sup>17</sup> However, to date, the effectiveness and results of microfracture performed in conjunction with gluteus medius and minimus tendon repair have not been studied.

The purpose of this study was to evaluate the effect of microfracture of the greater trochanter, as a marrow-stimulating procedure, on outcomes after the surgical repair of gluteus medius and minimus tendons. We hypothesized that microfracture of the trochanteric footprint would create better abductor tendon healing and lead to superior clinical outcomes and lower clinically evident retear rates.

## METHODS

This study is a retrospective review of data that were prospectively collected between January 2015 and August 2018 on all patients who underwent arthroscopic repair of gluteus medius and/or minimus tendon tears by the senior author (B.K.). Institutional ethical committee approval was obtained, and all patients gave their informed consent in accordance with the Declaration of Helsinki before their inclusion in the study (ACB/2014-4/8).

The inclusion criteria for this study were all patients who underwent arthroscopic gluteus medius or minimus tendon repair by the senior author with a minimum follow-up of 2 years. Additional criteria were that all patients in the study have symptoms of lateral hip pain, tenderness on palpation of the greater trochanter, weakness with resisted hip abduction, and findings on MRI of gluteus medius and/or minimus tendon tears. Patients were excluded from the study if they had undergone a previous surgical intervention on their ipsilateral or contralateral hip, had undergone previous spinal surgery, or had any systemic or metabolic disease. The indications for arthroscopic repair were failed nonoperative management, which included a combination of activity modification, oral anti-inflammatory medications, and corticosteroid injections, as well as MRI findings of gluteus medius and/or minimus tendon tears. All patients

underwent a standard preoperative assessment. During that assessment, the following demographic variables were recorded: patient sex, date of surgery, and age at the time of surgery. In addition, patients were questioned regarding the nature of the injury; the onset of symptoms was defined as acute if there was a specific incident, or classified as unknown if the symptoms were of gradual onset.

There were 62 patients reviewed who underwent arthroscopic hip abductor tendon repair. Of the 62 hips, 8 were excluded because they underwent revision surgery, and 4 patients were lost to follow-up. The remaining 50 patients were divided into 3 groups based on the method of repair performed, and these groups were clinically and radiologically evaluated and compared:

double-row repair (DR), 16 patients;  
single-row repair (SR), 14 patients; and  
single-row repair with microfracture (SRM), 20 patients.

The surgical technique selected by the senior surgeon was based on a 3-month interval schedule. During the first 3 months of the year, DR was performed; during the second 3 months, SR was performed; and during the next 3 months, SRM was performed. For the length of the study, the techniques were performed in the same order.

Patients were also questioned on the nature of the injury, which was defined as acute or unknown. Preoperative MRI scans of the patients were evaluated for the presence of abductor atrophy and/or fatty infiltration, tear size, and Goutallier-Fuchs classification grade.<sup>3</sup> Tear size was categorized according to Thaunat et al<sup>21</sup> as a small or low-grade partial tear measuring <2 cm (grade 1), a large or high-grade partial tear measuring >2 cm (grade 2), or a large or high-grade full-thickness tear measuring >2 cm (grade 3) via diagnostic arthroscopic surgery. The Goutallier-Fuchs classification grade has been evaluated by Bogunovic et al,<sup>3</sup> assessing the utility, reliability, and reproducibility of this classification system that was adapted to examine abductor tendon tears of the hip in addition to its correlation with patient-rated outcomes after repair.

## Operative Technique

All procedures were performed by the senior author, and no other combined procedures were performed during peritrochanteric tenoscopy. Patients were placed in the supine position, and the feet were attached to a hip traction

device. The operative leg was placed in about 20° of abduction for this procedure to loosen the iliotibial band. Proximal and distal lateral portals were created with a stab incision. The peritrochanteric space was accessed through the distal lateral accessory portal. Trochanteric bursectomy was carried out in every case with a shaver from the superior lateral portal. The attachments of the vastus lateralis, gluteus maximus, and gluteus minimus and medius tendons were examined in every case. The gluteus minimus and medius tendons were probed at their insertions into the trochanter for palpable deficiencies.

When a tear was observed at the gluteus medius and/or minimus tendon, degenerative tissue was debrided with a shaver. If there was a partial tear, a slit was made in the tendon(s) to perform decortication and microfracture. Once adequate debridement and decortication had taken place in all patients, 2 No. 2 double-loaded 5.5-mm Corkscrew anchors (Arthrex) were used in all patients, and 2 additional 5.5-mm SwiveLock anchors (Arthrex) were placed laterally with the standard transosseous-equivalent technique in the DR group (Figure 1).

The abductor tendon complex was repaired with 2 No. 2 double-loaded 5.5-mm Corkscrew anchors in the SR group (Figure 2).

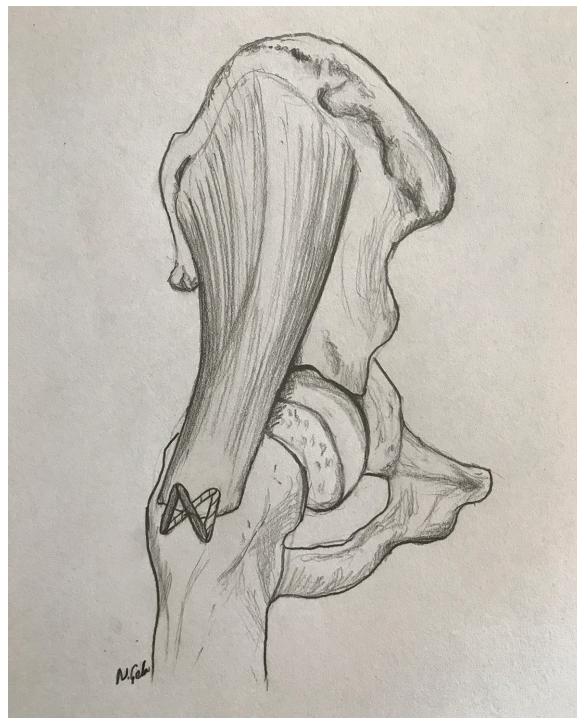
In the SRM group, SR was performed in a standard fashion, and a custom-made awl (Arthrex) with a straight trihedral cutting tip was used to perform microfracture to penetrate subchondral bone. The holes were standardized with a 1.3-mm diameter, 4- to 5-mm distance, and 5-mm depth to the lateral side of the repair zone in the greater trochanteric facet (Figure 3).

## Follow-up Protocol

The patients were followed up by clinical visits at 6 weeks, 3 months, 6 months, 1 year, and 2 years. The mean follow-up time was 30 months (range, 24-42 months). Postoperative rehabilitation was standardized and followed a 3-phase protocol. Phase 1 (0-6 weeks postoperatively) included only gentle passive range of motion as well as nonweightbearing in the operated extremity with a walker or crutches. No full-time bracing was used to limit abduction. In phase 2 (6-12 weeks postoperatively), the patient progressed to full weightbearing and initiated hip-strengthening exercises as the brace was discontinued. Phase 3 (>12 weeks postoperatively) allowed for ambulation without assistance and return to general activity as tolerated.

## Postoperative Outcome Measures

Patients were evaluated by an independent observer (A.E.P.) who was not involved in the treatment process of the patients. A visual analog scale (VAS) for pain as well as the Hip Outcome Score—Activities of Daily Living (HOS-ADL), Hip Outcome Score—Sport Specific (HOS-SS), and modified Harris Hip Score (mHHS) were used for evaluations both preoperatively and at a minimum 2-year follow-up (mean, 30 months [range, 24-42 months]).<sup>1,17</sup> MRI was used to diagnose and confirm retears in case of prolonged pain and persistent or recently developed



**Figure 1.** Double-row repair of hip abductor tendon tears.

weakness of abductor strength against resistance, and/or the Trendelenburg sign on physical examination at follow-up.

## Statistical Analysis

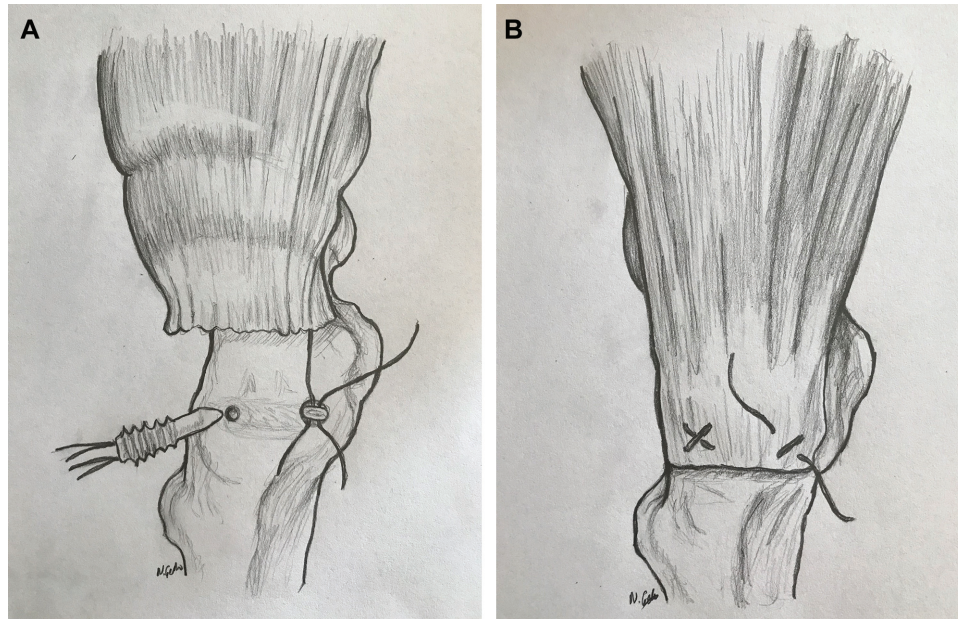
A power analysis was performed to calculate the sample size. A mean difference of  $5 \pm 4$  points on both the mHHS and the HOS was defined as the minimal clinically important difference; with a power of 80%, a 95% confidence level, and an alpha of .05, the results of the power analysis determined a sample size of 12 in each group. The data were analyzed using SPSS Version 25.0 software (IBM). The results were presented as frequencies, percentages, means, and standard deviations. A skewness value between  $-0.5$  and  $+0.5$  was considered approximately symmetric. A 1-way analysis of variance with the post hoc Tukey test and paired-samples *t* test were used to compare the numerical variables between multiple groups, and the chi-square test (or Fisher exact test) was used for categorical variables. A *P* value of  $<.05$  was considered statistically significant.

## RESULTS

### Participants

The mean patient age was  $53 \pm 8.9$  years,  $52 \pm 6.5$  years, and  $54 \pm 8.3$  years for the DR, SR, and SRM groups, respectively. Most of the patients (78%;  $n = 39$ ) were





**Figure 2.** (A) Preparation of single-row repair. (B) Single-row repair of hip abductor tendon tears.

female. The mean age for the entire cohort was  $53.16 \pm 7.96$  years (range, 38-68 years).

### Demographic Findings

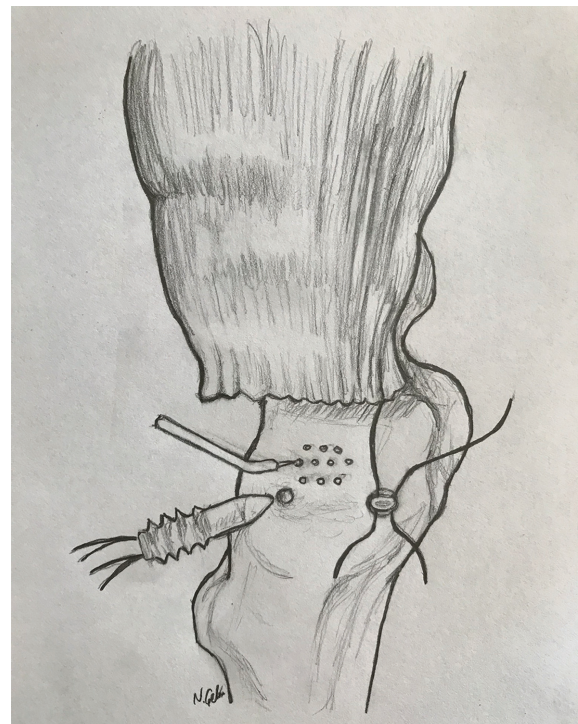
Age, sex, duration of symptoms, and other preoperative characteristics were similar between the groups (Table 1). The mechanism of injury was acute for 4 (25.0%), 3 (21.4%), and 3 (15.0%) patients in the DR, SR, and SRM groups, respectively. There was no significant difference between the 3 groups concerning the mechanism of injury (chi-square test:  $P = .580$ ; Fisher exact test:  $P = .749$ ).

The most common tear size was grade 1 in all groups with a rate of 50.0%, and the least common tear size was grade 3 with rates of 18.8%, 7.1%, and 15.0% in the DR, SR, and SRM groups, respectively. The most common fatty degeneration level according to the Goutallier-Fuchs classification was grade 1 with rates of 50.0%, 64.3%, and 50.0% in the DR, SR, and SRM groups, respectively, and the least common fatty degeneration level was grade 2 with rates of 18.8%, 28.6%, and 15%, respectively.

### Outcome Scores

All functional outcomes significantly improved in all groups at last follow-up (Table 2). When all groups were compared, there was a significant difference in terms of the VAS score as well as the HOS-ADL, HOS-SS, and mHHS scores.

The mean postoperative VAS scores were 2.3, 3.1, and 1.6 in the DR, SR, and SRM groups, respectively (Table 2), and there was an improvement/decrease in VAS scores, which averaged 5.6, 4.9, and 6.6 for the DR, SR, and SRM groups, respectively. A comparison of the differences between the groups in the mean improvement/decrease



**Figure 3.** Single-row repair of hip abductor tendon tears with microfracture at the tendon footprint with an awl.

in the VAS scores is shown in Table 3. Among the SR, SRM, and DR groups, the lowest score was seen in the SRM group with a significant difference ( $P < .001$ ).

The mean postoperative mHHS scores were 81.6, 70.5, and 86.9 in the DR, SR, and SRM groups, respectively,

TABLE 1  
Preoperative Patient Characteristics<sup>a</sup>

	DR (n = 16)	SR (n = 14)	SRM (n = 20)	F/ $\chi^2$ Value	P Value
Age, y	53 $\pm$ 8.9	52 $\pm$ 6.5	54 $\pm$ 8.3	0.516	.600
Duration of symptoms, mo	16 $\pm$ 6.77	14 $\pm$ 5.37	17 $\pm$ 6.28	0.857	.431
Sex				0.326	.901
Female	13 (81.3)	12 (85.7)	16 (80)		
Male	3 (18.8)	2 (14.3)	4 (20)		
Tear size, n (%)				1.934	.775
Small	9 (56.3)	10 (71.4)	12 (60.0)		
Large	6 (37.5)	3 (21.4)	5 (25.0)		
Full	1 (6.3)	1 (7.1)	3 (15.0)		
Tear size <sup>b</sup>				1.031	.933
Grade 1	8 (50.0)	7 (50.0)	10 (50.0)		
Grade 2	5 (31.3)	6 (42.9)	7 (35.0)		
Grade 3	3 (18.8)	1 (7.1)	3 (15.0)		
Goutallier-Fuchs classification				3.865	.399
Grade 1	8 (50.0)	9 (64.3)	10 (50.0)		
Grade 2	3 (18.8)	4 (28.6)	3 (15.0)		
Grade 3	5 (31.3)	1 (7.1)	7 (35.0)		
VAS score				3.865	.399
Grade 1	6 (37.5)	4 (28.6)	4 (20.0)		
Grade 2	5 (31.3)	5 (35.7)	9 (45.0)		
Grade 3	5 (31.3)	5 (35.7)	7 (35.0)		
mHHS score	48.94 $\pm$ 8.32	48.21 $\pm$ 7.89	47.80 $\pm$ 6.64	0.101	.904
HOS-ADL score	52.75 $\pm$ 7.63	46.71 $\pm$ 6.35	47.60 $\pm$ 8.56	2.841	.068
HOS-SS score	43.81 $\pm$ 7.95	42.00 $\pm$ 6.36	44.70 $\pm$ 7.13	0.583	.562

<sup>a</sup>Data are reported as mean  $\pm$  SD or n (%). DR, double-row repair; HOS-ADL, Hip Outcome Score–Activities of Daily Living; HOS-SS, Hip Outcome Score–Sport Specific; mHHS, modified Harris Hip Score; SR, single-row repair; SRM, single-row repair + microfracture; VAS, visual analog scale.

<sup>b</sup>Tear size was categorized according to Thauinat et al<sup>21</sup> as a small or low-grade partial tear measuring <2 cm (Grade 1), a large or high-grade partial tear measuring >2 cm (Grade 2), or a large or high-grade full-thickness tear measuring >2 cm (Grade 3) via diagnostic arthroscopic surgery.

TABLE 2  
Outcome Scores<sup>a</sup>

	DR			SR			SRM		
	Mean $\pm$ SD	F/ $\chi^2$ Value	P Value	Mean $\pm$ SD	F/ $\chi^2$ Value	P Value	Mean $\pm$ SD	F/ $\chi^2$ Value	P Value
VAS		20.68	<.001		18.49	<.001		48.43	<.001
Preoperative	7.94 $\pm$ 0.85			8.07 $\pm$ 0.82			8.15 $\pm$ 0.74		
Postoperative	2.31 $\pm$ 0.87			3.14 $\pm$ 0.66			1.60 $\pm$ 0.50		
mHHS		23.27	<.001		13.10	<.001		30.42	<.001
Preoperative	48.94 $\pm$ 8.32			48.21 $\pm$ 7.88			47.80 $\pm$ 6.63		
Postoperative	81.63 $\pm$ 7.31			70.50 $\pm$ 3.39			86.90 $\pm$ 3.27		
HOS-ADL		30.25	<.001		14.73	<.001		22.94	<.001
Preoperative	52.75 $\pm$ 7.62			46.71 $\pm$ 6.35			47.60 $\pm$ 8.56		
Postoperative	81.31 $\pm$ 6.09			71.00 $\pm$ 4.82			86.40 $\pm$ 3.95		
HOS-SS		31.82	<.001		19.59	<.001		26.45	<.001
Preoperative	43.81 $\pm$ 7.95			42.00 $\pm$ 6.36			44.70 $\pm$ 7.13		
Postoperative	76.13 $\pm$ 7.59			68.43 $\pm$ 4.50			83.85 $\pm$ 5.41		

<sup>a</sup>DR, double-row repair; HOS-ADL, Hip Outcome Score–Activities of Daily Living; HOS-SS, Hip Outcome Score–Sport Specific; mHHS, modified Harris Hip Score; SR, single-row repair; SRM, single-row repair + microfracture; VAS, visual analog scale.

and these scores are shown in Table 2. There was an improvement in mHHS scores, which averaged 32.7, 22.3, and 39.1 points for the DR, SR, and SRM groups, respectively. A comparison of the differences in the mean

improvement in the mHHS scores between the groups is shown in Table 3. Among the SR, SRM, and DR groups, the highest score was seen in the SRM group with a significant difference ( $P = .006$ ).

TABLE 3  
Difference in Outcome Scores<sup>a</sup>

	Mean Difference	P Value	95% CI
mHHS			
DR vs SR	10.402	<.001	5.19 to 15.61
SR vs SRM	-16.814	<.001	-21.78 to -11.85
DR vs SRM	-6.413	.006	-11.19 to -1.63
HOS-ADL			
DR vs SR	4.277	.153	-1.20 to 9.75
SR vs SRM	-14.514	<.001	-19.73 to -9.30
DR vs SRM	-10.237	<.001	-15.26 to -5.22
HOS-SS			
DR vs SR	5.884	.014	1.03 to 10.74
SR vs SRM	-12.721	<.001	-17.34 to -8.10
DR vs SRM	-6.837	.002	-11.29 to -2.39
VAS			
DR vs SR	0.696	.095	-1.49 to 0.10
SR vs SRM	-1.621	<.001	-2.38 to -0.87
DR vs SRM	-0.925	.009	-1.65 to -0.20

<sup>a</sup>DR, double-row repair; HOS-ADL, Hip Outcome Score–Activities of Daily Living; HOS-SS, Hip Outcome Score–Sport Specific; mHHS, modified Harris Hip Score; SR, single-row repair; SRM, single-row repair + microfracture; VAS, visual analog scale.

TABLE 4  
Goutallier-Fuchs Classification Grades and Retears<sup>a</sup>

	DR (n = 16)	SR (n = 14)	SRM (n = 20)	P Value
Goutallier-Fuchs classification				
Grade 1	8 (50.0)	9 (64.3)	10 (50.0)	.46
Grade 2	3 (18.8)	4 (28.6)	3 (15.0)	.23
Grade 3	5 (31.3)	1 (7.1)	7 (35.0)	.02
Retears	5 (31.3)	5 (35.7)	3 (15.0)	.042 <sup>b</sup>

<sup>a</sup>Data are reported as n (%). DR, double-row repair; SR, single-row repair; SRM, single-row repair + microfracture.

<sup>b</sup>There were significantly fewer retears in the SRM group versus the DR and SR groups.

The mean postoperative HOS-ADL scores were 81.3, 71.0, and 86.4 in the DR, SR, and SRM groups, respectively. There was an improvement in HOS-ADL scores, which averaged 28.5, 24.3, and 38.8 points for the DR, SR, and SRM groups, respectively. Among the SR, SRM, and DR groups, the highest score was seen in the SRM group with a significant difference ( $P = .002$ ) (Table 3).

The mean postoperative HOS-SS scores were 76.1, 68.4, and 83.8 in the DR, SR, and SRM groups, respectively. There was an improvement in HOS-SS scores, which averaged 32.3, 26.4, and 39.1 points for the DR, SR, and SRM groups, respectively. Among the SR, SRM, and DR groups, the highest score was seen in the SRM group with a significant difference ( $P = .002$ ) (Table 3).

The abductor tendon retear rates were 31.3%, 35.7%, and 15.0% in the DR, SR, and SRM groups, respectively (Figure 4 and Table 4). A comparison of the retear rates for each repair technique revealed that there was

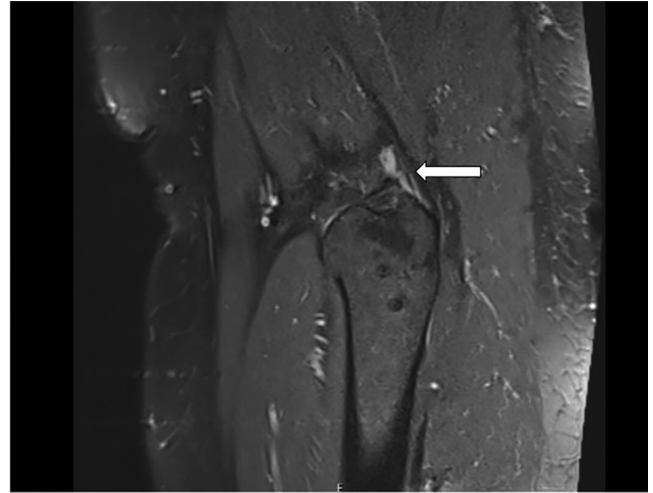


Figure 4. Magnetic resonance imaging of a patient with a retear (arrow) in the double-row repair group.

a significant difference in the SRM group versus the SR and DR groups ( $P = .042$ ); however, there was no significant difference between the SR and DR groups ( $P = .32$ ).

## DISCUSSION

In the current study, there were improvements in patient-reported outcome scores from preoperatively to follow-up, including the VAS for pain, HOS-ADL, HOS-SS, and mHHS, at a mean of 30 months postoperatively, with significantly improved results in the SRM group compared with the DR and SR groups. Further, in terms of the retear rate, the SRM group was found to be superior to both the DR and the SR groups, which may indicate that healing biology is more important than tendon fixation stability.

As with rotator cuff surgery, higher retear rates after gluteus tendon repair have been associated with older age, a larger tear size, significant fatty infiltration, the presence of comorbidities, and possibly the use of a single-row technique.<sup>2,17,20</sup> What we know about rotator cuff repair, which resembles hip abductor repair, is that both fatty degeneration and tendon healing biology are more important than tendon fixation stability.<sup>5</sup>

Considering that retear rates are still problematic after gluteus medius and minimus tendon repair, exploring alternative strategies to enhance structural healing is important.<sup>1,14</sup> The rate of tendon retears after open and endoscopic gluteus medius and minimus repair was between 9% and 11% in studies with a large sample size and a longer follow-up.<sup>1,14</sup> The lower rate reported in endoscopic studies is probably linked to the small sample size and short-term follow-up.<sup>5,6,12,15</sup> To overcome this problem, biological growth factors such as platelet-rich plasma, as well as tissue and suture-augmentation techniques, have been introduced with some promising biomechanical advantages, but some of them are technically demanding and have not yet been transferred routinely into regular clinical practice.<sup>11,16,18,19</sup>



Augmented surgical repair for hip abductor tendon tears has also been described with improved results. The goal of biological or synthetic tissue augmentation is to decrease retear rates and increase patient satisfaction. Ebert et al<sup>7</sup> reported on a consecutive series of 146 patients who underwent open gluteal tendon repair using synthetic augmentation with the Ligament Augmentation and Reconstruction System. They reported significantly improved clinical and functional outcomes, high levels of patient satisfaction, and a relatively low failure rate up to 24 months after surgery. Rao et al<sup>18</sup> described a prospective evaluation of patients treated with open transosseous repair of gluteus medius and minimus insertions augmented by a GraftJacket allograft and acellular human dermal matrix. They reported that in the 12 patients evaluated, significant improvements were seen in VAS pain scores, limping, and gait, along with abductor strength. A negative Trendelenburg test finding was reported in 11 of 12 patients, and the HHS score improved significantly at 22 months postoperatively.

These noted studies evaluated the outcomes of open procedures for gluteus medius and minimus tendon tears with the comorbidities of open surgery. On the other hand, many surgeons have evolved to arthroscopic gluteus repair. The treatment of gluteus medius tendon tears with endoscopic repair has demonstrated clinically beneficial results with lower complications.<sup>5,10,12,13</sup> Endoscopic augmentation of abductor repair with an acellular human dermal matrix and human dermal allograft has been performed and presented by different authors with successful results.<sup>16,18</sup> The major flaws of these open and endoscopic augmentation techniques are that they are expensive because of the use of many anchors and augmentation materials, and they are not easily reproducible.

As we accept that hip abductor tendon tears have been coined rotator cuff tears of the hip,<sup>3</sup> there is 1 augmentation procedure that is very safe, cheap, and reproducible and has been tested many times at rotator cuff surgery. This is marrow stimulation using the microfracture augmentation technique. With this technique, the biology of the repair is enhanced with bone marrow vents created by microfracture of the greater trochanter, forming a crimson duvet or bone marrow superclot, which will envelop the repair site and regenerate the footprint of abductor tendons.<sup>2,17</sup>

Pulatkan et al<sup>17</sup> examined 123 patients with full-thickness rotator cuff tears. Of this group, 44 were treated with SRM, and their retear rate was superior to that of patients undergoing SR and DR. Bilsel et al,<sup>2</sup> in a prospective randomized study, demonstrated that the rotator cuff tendon healing rate was 52.6% in patients in the SR group and 65.7% in the SRM group, which is a significant difference between groups.

To investigate the effect of microfracture on outcomes after the surgical repair of gluteus medius and minimus tendons, we hypothesized that microfracture would accelerate abductor tendon healing and lead to superior clinical outcomes and lower clinically evident retear rates. The results of our study are in agreement with the hypothesis in that the SRM group had the lowest retear rate compared with the DR and SR groups. When the groups were

compared, there was a significant difference in favor of the SRM group in terms of the VAS score as well as HOS-ADL, HOS-SS, and mHHS scores. We were not able to observe any statistical difference between the DR and SR groups in terms of the VAS score as well as HOS-ADL, HOS-SS, and mHHS scores, which supports the results of previous abductor repair studies and also rotator cuff repair studies. These results may show that hip abductor tendon healing biology is more important than the stability of tendon repair, which resembles rotator cuff healing.<sup>2</sup> The results of the current study show that healing after SR augmented with marrow stimulation was superior to that after DR in terms of retear rates and clinical outcomes.

There are several limitations of the study. This was a retrospectively analyzed prospective study with a short follow-up of 30 months. The randomization method was weak, and the senior surgeon changed his repair technique every 3 months, and thus, there was an unequal number of patients in the groups. The interrater reliability of grading abductor tendon tears showed only fair agreement, which may affect the comparison of grades between patient groups and may also challenge the higher interobserver reliability found for the Goutallier-Fuchs classification of hip abductor tendons. Groups were compared with only clinical grading, and we did not check or compare healing with follow-up MRI. Follow-up MRI was used for the validation of retears in cases of prolonged pain. Another limitation of the study is that 50.0% of patients undergoing repair had low-grade tears. In addition to this, tears at the hip abductor area are always problematic in terms of the healing process, which has similarity with rotator cuff tears.

## CONCLUSION

Microfracture at the trochanteric footprint of hip abductor tendons seemed to improve tendon healing and led to superior clinical outcomes and lower clinically evident retear rates. Thus, endoscopic SRM was a safe, easy, and effective technique and had the potential advantage of biological healing at the footprint. The SRM group had a significantly lower retear rate and better functional outcomes than the SR and DR groups. On the basis of our results, a future large, prospective randomized controlled trial or systematic meta-analysis is recommended.

## REFERENCES

1. Alpaugh K, Chillelli BJ, Xu S, et al. Outcomes after primary open or endoscopic abductor tendon repair in the hip: a systematic review of the literature. *Arthroscopy*. 2015;31:530-540.
2. Bilsel K, Yildiz F, Kapicioglu M, et al. Efficacy of bone marrow-stimulating technique in rotator cuff repair. *J Shoulder Elbow Surg*. 2017;26(8):1360-1366.
3. Bogunovic L, Lee SX, Haro MS, et al. Application of the Goutallier/Fuchs rotator cuff classification to the evaluation of hip abductor tendon tears and the clinical correlation with outcome after repair. *Arthroscopy*. 2015;31:2145-2151.
4. Bucher TA, Darcy P, Ebert JR, Smith A, Janes G. Gluteal tendon repair augmented with a synthetic ligament: surgical technique and a case series. *Hip Int*. 2014;24:187-193.



5. Chandrasekaran S, Lodhia P, Gui C, Vemula SP, Martin TJ, Domb BG. Outcomes of open versus endoscopic repair of abductor muscle tears of the hip: a systematic review. *Arthroscopy*. 2015;31(10):2057-2067.
  6. Domb BG, Botser I, Giordano BD. Outcomes of endoscopic gluteus medius repair with minimum 2-year follow-up. *Am J Sports Med*. 2013;41:988-997.
  7. Ebert JR, Brogan K, Janes GC. A prospective 2-year clinical evaluation of augmented hip abductor tendon repair. *Orthop J Sports Med*. 2020;8(1):2325967119897881.
  8. Gullledge CM, Makhni EC. Open gluteus medius and minimus repair with double-row technique and bioinductive implant augmentation. *Arthrosc Tech*. 2019;8(6):e585-e589.
  9. Kaplan DJ, Dold AP, Fralinger DJ, Meislin RJ. Endoscopic gluteus medius repair augmented with bioinductive implant. *Arthrosc Tech*. 2016;5(4):e821-e825.
  10. LaPorte C, Vasaris M, Gossett L, Boykin R, Menge T. Gluteus medius tears of the hip: a comprehensive approach. *Phys Sportsmed*. 2019;47(1):15-20.
  11. Laskovski J, Urchek R. Endoscopic gluteus medius and minimus repair with allograft augmentation using acellular human dermis. *Arthrosc Tech*. 2018;7(3):e225-e230.
  12. Lerebours FR, Cohn R, Youm T. Endoscopic treatment of gluteus medius tears: a review. *Bull Hosp Jt Dis (2013)*. 2016;74(1):58-62.
  13. Levy DM, Bogunovic L, Grzybowski JS, Kuhns BD, Bush-Joseph CA, Nho SJ. All-endoscopic single-row repair of full-thickness gluteus medius tears. *Arthrosc Tech*. 2016;5(1):e1-e6.
  14. Makridis KG, Lequesne M, Bard H, et al. Clinical and MRI results in 67 patients operated for gluteus medius and minimus tendon tears with a median follow-up of 4.6 years. *Orthop Traumatol Surg Res*. 2014;100:849-853.
  15. Okorooha KR, Beck EC, Nwachukwu BU, Kunze KN, Nho SJ. Defining minimal clinically important difference and patient acceptable symptom state after isolated endoscopic gluteus medius repair. *Am J Sports Med*. 2019;47(13):3141-3147.
  16. Pascual-Garrido C, Schwabe MT, Chahla J, Haneda M. Surgical treatment of gluteus medius tears augmented with allograft human dermis. *Arthrosc Tech*. 2019;8(11):e1379-e1387.
  17. Pulatkan A, Anwar W, Tokdemir S, Akpınar S, Bilsel K. The clinical and radiologic outcome of microfracture on arthroscopic repair for full-thickness rotator cuff tear. *J Shoulder Elbow Surg*. 2020;29(2):252-257.
  18. Rao BM, Kamal TT, Vafaye J, Taylor L. Surgical repair of hip abductors: a new technique using Graft Jacket allograft acellular human dermal matrix. *Int Orthop*. 2012;36:2049-2053.
  19. Saltzman BM, Ukwuani G, Makhni EC, Stephens JP, Nho SJ. The effect of platelet-rich fibrin matrix at the time of gluteus medius repair: a retrospective comparative study. *Arthroscopy*. 2018;34(3):832-841.
  20. Schröder JH, Geßlein M, Schütz M, Perka C, Krüger D. Open repair of gluteus medius and minimus tendons tears with double-row technique: clinical and radiological results. *Orthopade*. 2018;47(3):238-245.
  21. Thauinat M, Clowez G, Desseaux A, et al. Influence of muscle fatty degeneration on functional outcomes after endoscopic gluteus medius repair. *Arthroscopy*. 2018;34(6):1816-1824.
-