



HAL
open science

Minimally invasive harvesting of the quadriceps tendon: Technical note.

Matthieu Ollivier, Jérémy Cognault, Régis Pailhé, Xavier Bayle-Iniguez,
Etienne Cavaignac, Jérôme Murgier

► To cite this version:

Matthieu Ollivier, Jérémy Cognault, Régis Pailhé, Xavier Bayle-Iniguez, Etienne Cavaignac, et al.. Minimally invasive harvesting of the quadriceps tendon: Technical note.. Orthopaedics & Traumatology: Surgery & Research, 2021, 107 (2), pp.102819. 10.1016/j.otsr.2021.102819 . hal-03553765

HAL Id: hal-03553765

<https://hal.science/hal-03553765>

Submitted on 15 Apr 2022

HAL is a multi-disciplinary open access archive for the deposit and dissemination of scientific research documents, whether they are published or not. The documents may come from teaching and research institutions in France or abroad, or from public or private research centers.

L'archive ouverte pluridisciplinaire **HAL**, est destinée au dépôt et à la diffusion de documents scientifiques de niveau recherche, publiés ou non, émanant des établissements d'enseignement et de recherche français ou étrangers, des laboratoires publics ou privés.

Technical note

Minimally invasive harvesting of the quadriceps tendon: Technical note

Matthieu Ollivier^a, Jérémy Cognault^b, Régis Pailhé^{c,d,e}, Xavier Bayle-Iniguez^{f,g}, Etienne Cavaignac^{h,i,j}, Jérôme Murgier^{g,k,*}

^a Institute for Locomotion, Department of Orthopaedics and Traumatology, Aix Marseille University, APHM, CNRS, ISM, Sainte-Marguerite Hospital, Marseille, France

^b Clinique du Parc Lyon, Groupe C2S, 155, Boulevard de Stalingrad, 69006 Lyon, France

^c University Grenoble-Alpes, CNRS, Grenoble INP, TIMC-IMAG, 38000 Grenoble, France

^d CHU Grenoble-Alpes, South Teaching Hospital, Department of Orthopaedic Surgery and Sports Traumatology, 38130 Echirolles, France

^e INSERM, CIC 1406, 38000 Grenoble, France

^f Clinique Médipôle Saint-Roch, Elsan, Service de chirurgie orthopédique, 66330 Cabestany, France

^g South French Knee Association (Association du Genou du Sud de la France), 66330 Cabestany, France

^h Clinique Universitaire du Sport, CHU Toulouse, Toulouse, France

ⁱ I2R, Toulouse, France

^j SPS Recherche, Toulouse, France

^k Clinique Aguiléra, Ramsey Santé, Service de chirurgie orthopédique, 21, rue de l'Estagnas, 64200 Biarritz, France

ARTICLE INFO

Keywords:

Anterior cruciate ligament
Quadriceps tendon
Minimally invasive surgery

ABSTRACT

The quadriceps tendon is gaining preference as an autograft over conventional grafts for the primary reconstruction of the anterior and posterior cruciate ligaments and of the medial patello-femoral ligament. In the past, the use of the quadriceps tendon was associated with considerable morbidity and less favourable outcomes compared to other grafts, specifically due to post-operative weakness of the quadriceps and other complications such as patellar fracture and rupture of the extensor apparatus. These problems are partially ascribable to the graft harvesting method used (large incision, bone block > 2 cm, and full-thickness tendon harvesting). Recent technical advancements have made reproducible harvesting of quadriceps grafts possible, thereby largely preventing the complications. In this study we describe an original quadriceps tendon harvesting technique in which a minimally invasive approach allows the collection of a sufficiently long graft, while sparing the deep layer of the quadriceps tendon. This technique decreases intra-operative morbidity and improves the post-operative outcomes.

1. Introduction

The selection of the type of graft used to reconstruct the anterior cruciate ligament (ACL) [1,2] remains a matter of debate. Use of the quadriceps tendon (QT) has recently generated increased interest [3]. In the past, use of the QT was associated with considerable morbidity and with less favourable outcomes compared to other grafts, in particular due to post-operative weakness of the quadriceps and other complications such as patellar fracture and rupture of the extensor apparatus [4]. However, improvements in harvesting methods [5] have decreased the morbidity of the

surgical procedure [6]. There is increasing use of autologous QTs [7]. Nevertheless, a variety of surgical techniques exist not only regarding the harvesting modalities and incision types but also the nature of the harvested material (e.g., harvesting of the full-thickness tendon or preservation of the deep layer, tendon graft with or without a bone block).

In this study we describe an original minimally invasive method for harvesting a QT graft and a patellar bone block, while sparing the deep layer of the QT.

2. Technique

The QT has a mean length of 6.1 ± 1 cm and a mean thickness of 7 mm (range, 6.4–7.8 mm), i.e., 1.8 times more than that of the patellar ligament [8,9]. The thickness of the QT increases from proximal to distal (video). Its mean width is 27 mm (range, 21–37 mm).

* Corresponding author at: Clinique Aguiléra, Ramsey Santé, Service de chirurgie orthopédique, 21, rue de l'Estagnas, 64200 Biarritz, France.
E-mail address: docteur.murgier@gmail.com (J. Murgier).

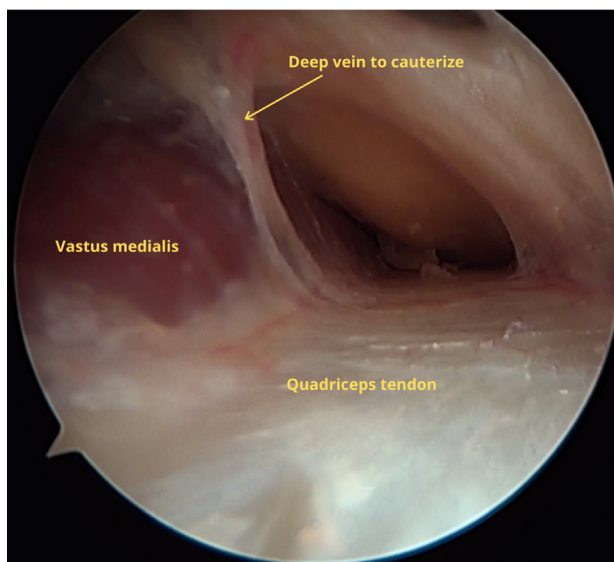


Fig. 1. Endoscopic view of the veins to be coagulated before harvesting the quadriceps tendon.

The QT fibres are arranged in three layers: the deep layer is the tendon of the vastus intermedius, the middle layer is formed by the convergence of fibres from the vastus medialis and vastus lateralis, and the superficial layer is the tendon of the rectus femoris.

A pneumatic tourniquet is placed on the thigh (video) and the knee is flexed at 90°. A vertical incision of 2 to 3 cm in length is made, starting 1 cm proximal to the middle of the proximal pole of the patella and then continuing distally in a direction parallel to the bulge formed by the vastus medialis. The incision then deepens into the subcutaneous plane (Fig. 1) and the tissues are released using a finger. Veins are usually present and can be identified endoscopically (Fig. 1). These veins must be coagulated. The QT, vastus medialis, and patella are identified to determine the exact site of graft harvesting. The future bone block is marked using an electric cautery at the proximal pole of the patella (20 mm in length and 10 mm in width). The knee can then be flexed and extended to allow soft tissue movement and to visualise the entire harvesting site. Orifices of 1.5 mm in diameter are drilled at the ends of the future bone block to decrease the risk of fracture related to the harvesting. One or two central orifices are also created at this stage to serve later for the passage of traction sutures. A double knife is then used to make a double incision starting at the centre of the proximal patellar pole then travelling downwards, parallel to, and 1–2 mm away from, the vastus medialis, to increase the length of the transplant. Ideally, the graft length should be at least 6 cm. The incisions are extended distally to the patella. A bone block having the same width as the double incision and measuring 20 mm in length is then harvested. Several rules are applied to minimise the risk of fracture: the longitudinal saw cuts (using small blades) are made first, from proximal to distal, following the marks made with the electric cautery and angulating the blade by about 45° relative to the plane of the patella. The ideal depth is about 10 mm and markings on the instrument allow enhanced control over this. The distal cut is then made, taking care not to go beyond the width of the future bone block. Finally, a slender osteotome is used to release the bone block (Figs. 2 and 3, video 1). Once the bone block has been elevated using a clamp, the dissection of the tendon tissue can commence. Care should be taken not to enter the joint cavity and to spare the deep layer (the goal being to harvest the superficial and intermediate layers). At first, dissection scissors or a scalpel blade can be used to separate the intermediate and deep layers. After a few centimetres, finger dissection can be used. The length of the

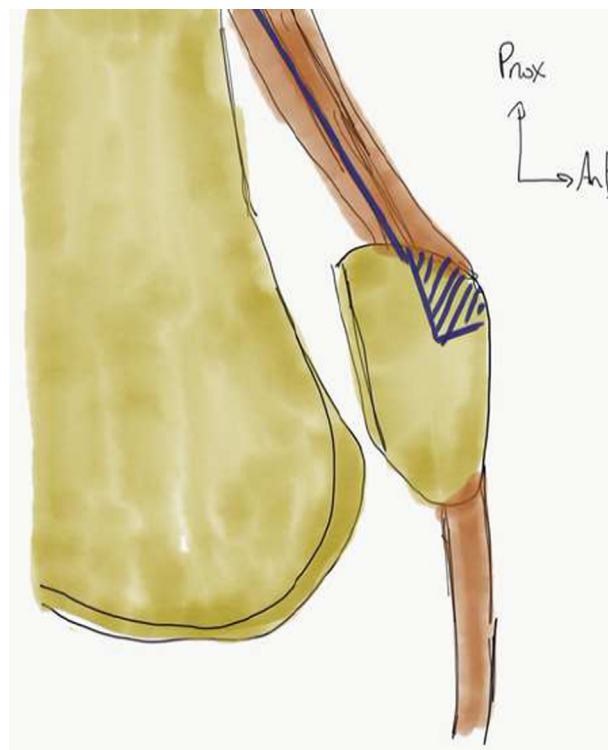


Fig. 2. Lateral view of the saw blade direction.

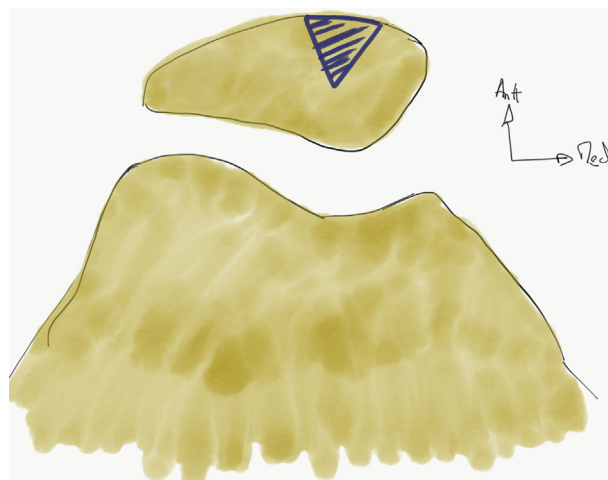


Fig. 3. Axial view of the saw blade direction.

transplant is measured, the goal being at least 8 cm (including the bone block). Once the desired length has been obtained, the tendon is detached from its proximal end (Fig. 4). Importantly, the proximal myotendinous junction must remain intact to avoid weakening the quadriceps. To improve visualisation, the knee can be extended and the retractors positioned at the proximal part of the incision while strong traction is exerted on the transplant distally. The section can be performed using a specific tool (a closed stripper) such as Mayo scissors or a scalpel. By moving the knee from a flexed to an extended position and taking advantage of the elasticity of the skin, each part of the harvested graft can be seen by direct vision.

The harvesting site is then inspected to look for a breach in the joint capsule, which must be sutured to avoid fluid leakage during the arthroscopic phase. The bone defect is filled at the end of the

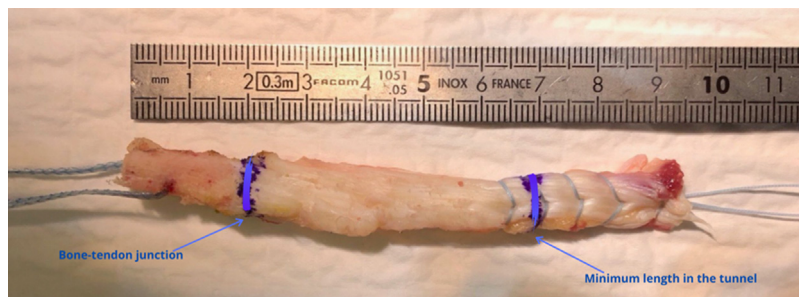


Fig. 4. Quadriceps tendon graft with the bone block.

Table 1
Advantages and drawbacks of using the quadriceps tendon.

Advantages	Drawbacks
Graft length of 70 to 90 mm is ideal for reconstruction of the ACP or PCL Tubular graft which naturally has a constant diameter of 9 to 10 mm	Relies on a learning curve and is technically demanding Possible increase in the incidence of cyclops syndrome (1.4% in our cohort)
Possible harvesting of a bone block measuring 2 cm by 1 cm	Risk of complications affecting the extensor apparatus (0.5% in our cohort)
Incidence of known re-tears is satisfactory (1.4% after 2 years)	Greater quadriceps weakness after 6 months than with hamstring grafts
Preservation of the hamstring tendons	Risk of protracted tendinopathy, particularly if closure is with a non-absorbable suture (0.9% in our cohort)
Does not cause dysesthesia, kneeling position remains possible	Visible scar on the anterior knee (2–3 cm)

ACL: anterior cruciate ligament; PCL: posterior cruciate ligament.

procedure by the bone chips recovered during drilling of the tibial tunnel.

To close the harvesting site, an absorbable braided suture size 2 is used by approximating the tendon edges on either side of the site. An X-shaped stitch at the beginning can serve as a traction suture to close all the wound edges proximally, while extending the knee increases visibility. The transplant is then prepared according to the planned technique (Table 1) lists the advantages and drawbacks of this harvesting method.

3. Results

The first 340 patients operated on using this technique were studied. There were 278 males and 62 females with a mean age of 26 ± 8 years. Mean follow-up was 2 ± 0.7 years. Mean tendon transplant length was 7.5 ± 1.4 cm. The bone block had a mean length of 1.7 ± 0.7 mm, a mean proximal diameter of 9 ± 2 mm, and a mean distal diameter of 9 ± 1 mm. Harvesting was possible in all patients without the occurrence of major difficulties, particularly regarding the bone block.

All patients were operated on by the same senior surgeon. The complication rate was 17/350 (4.8%). The complications are listed below:

- rupture of the extensor apparatus occurred in 2 patients; 1 of these patients experienced a rupture of the quadriceps tendon 3 weeks after surgery during a motorcycle accident and the other experienced a fracture of the patella during surgery, which was treated immediately by internal fixation;
- early documented re-tears of the graft occurred in 5 patients at an average of 9 months after surgery; 4 of these patients were treated surgically;

- cyclops syndrome occurred in 5 patients, requiring excision of the nodule;
- 2 patients developed infections at the harvest site and these were managed by wound lavage and debridement;
- QT tendinopathy persisted for more than 6 months in 3 patients.

4. Discussion

The QT autograft is of value in the surgical reconstruction of the ACL due to its anatomical and biomechanical properties and due to the multiple possibilities it offers the surgeon. Studies of clinical outcomes support the importance of the QT autograft.

Some studies published over the last few years have evaluated the biomechanical properties of the QT. Shani et al. [9] found that both rigidity and resistance were greater with the QT than with the patellar tendon. Load to rupture was 2185.9 ± 758.8 N compared to 1580.6 ± 479.4 N for the patellar ligament. The mean cross-section surface area of the QT was nearly twice that of the patellar tendon. In addition, the QT is asymmetrical, with thicker middle and distal regions [10]. Two other biomechanical studies confirmed that the biomechanical properties of the QT were not inferior to those of the hamstrings used as short grafts (semi-tendinosus quadruple-bundle graft or 6-stranded gracilis-semi-tendinosus graft) [11–13]. Moreover, another study found no difference between grafts made from partial thickness versus full-thickness QT [14].

The clinical outcomes obtained in cohort studies of QT reconstructions are promising [15]. A meta-analysis by Mouarbes et al. [6] showed that the QT was associated with less severe harvesting-site pain compared to the patellar ligament and provided better functional scores compared to hamstring grafts. This data was supported by a study conducted by Nyland et al. [16], demonstrating less pivot-shift laxity and a lower re-tear rate with the QT than with hamstring grafts. Finally, the QT was associated with the lowest rate of post-operative morbidity [17] and with less sensations of numbness after surgery [18]. It should be noted that this technique has a learning curve [19–21].

The QT is a versatile graft making it useful for different types of harvesting. Harvesting can be performed depending on the surgical indication and on the patient's anatomy (with or without a bone block, harvesting of two or three layers if a large diameter is desirable, creation of a double-bundle construct by separating the tendon layers and suitable for use in paediatrics). In addition, the QT can be used for reconstructive surgery not only of the ACL but also of the posterior cruciate ligament and medial patello-femoral ligament, as well as in shoulder surgery.

Complications have been reported with QT harvesting. They include patella fractures, extensor apparatus ruptures, and post-operative haematomas. The risk of such complications can be decreased with meticulous technique throughout the procedure. An evaluation of the post-operative complications needs to be performed to confirm the lower morbidity rate with this technique compared with conventional harvesting methods.

Disclosure of interest

E. Cavaignac is a consultant for Arthrex Education and has received financial support from Smith & Nephew, Omnis Medica, Stryker, FH Orthopedics, and Zimmer Biomet; there are no conflicts of interest related to this work.

M. Ollivier is a consultant for Arthrex, Newclip, and Stryker and has received financial support from Arcos, Adler, Orthofix, and Smith & Nephew; there are no conflicts of interest related to this work.

R. Pailhé is a consultant for BBraun and has received financial support from Stryker; there are no conflicts of interest related to this work.

J. Murgier is an associate editor for *Orthopaedics & Traumatology: Surgery & Research* and has received financial support from Stryker and Smith & Nephew; there are no conflicts of interest related to this work.

J. Cognault has received financial support from Sanofi; there are no conflicts of interest related to this work.

X. Bayle-Iniguez declares that he has no competing interest.

Funding

None.

Contributions of each author

J. Murgier wrote the article.

M. Ollivier recorded the surgical video and revised the article for important intellectual content.

X. Bayle-Iniguez, R. Pailhé, J. Cognault, and E. Cavaignac contributed to the development of the project and revised the article for important intellectual content.

Appendix A. Supplementary data

Supplementary data associated with this article can be found, in the online version

References

- [1] Ode Q, Gonzalez JF, Pailhe R, Dejour D, Ollivier M, Panisset JC, et al. Influence of operative technique on anterior cruciate ligament reconstruction in patients older than 50 years. *Orthop Traumatol Surg Res* 2019;105:S253–8.
- [2] Thauinat M, Fayard JM, Sonnery-Cottet B. Hamstring tendons or bone-patellar tendon-bone graft for anterior cruciate ligament reconstruction? *Orthop Traumatol Surg Res* 2019;105:S89–94.
- [3] Lind M, Nielsen TG, Soerensen OG, Mygind-Klavsen B, Fauno P. Quadriceps tendon grafts does not cause patients to have inferior subjective outcome after anterior cruciate ligament (ACL) reconstruction than do hamstring grafts: A 2-year prospective randomised controlled trial. *Br J Sports Med* 2020;54:183–7.
- [4] Marshall JL, Warren RF, Wickiewicz TL, Reider B. The anterior cruciate ligament: A technique of repair and reconstruction. *Clin Orthop Relat Res* 1979;143:97–106.
- [5] Gaudot F, Leymarie JB, Drain O, Boisrenoult P, Charrois O, Beauflis P. Double-incision mini-invasive technique for BTB harvesting: Its superiority in reducing anterior knee pain following acl reconstruction. *Orthop Traumatol Surg Res* 2009;95:28–35.
- [6] Mouarbes D, Menetrey J, Marot V, Courtot L, Berard E, Cavaignac E. Anterior cruciate ligament reconstruction: A systematic review and meta-analysis of outcomes for quadriceps tendon autograft versus bone-patellar tendon-bone and hamstring-tendon autografts. *Am J Sports Med* 2019;47:3531–40.
- [7] Ugwuoke A, Syed F, El-Kawy S. Predicting adequacy of free quadriceps tendon autograft, for primary and revision acl reconstruction, from patients' physical parameters. *Knee Surg Sports Traumatol Arthrosc* 2020;28:448–53.
- [8] Harris NL, Smith DA, Lamoreaux L, Purnell M. Central quadriceps tendon for anterior cruciate ligament reconstruction. Part i: Morphometric and biomechanical evaluation. *Am J Sports Med* 1997;25:23–8.
- [9] Shani RH, Umpiarez E, Nasert M, Hiza EA, Xerogeane J. Biomechanical comparison of quadriceps and patellar tendon grafts in anterior cruciate ligament reconstruction. *Arthroscopy* 2016;32:71–5.
- [10] Chivot M, Pioeger C, Cognault J, Sharma A, Pailhe R, Cavaignac E, et al. Every layer of quadriceps tendon's central and medial portion offers similar tensile properties than hamstrings or ilio-tibial band grafts. *J Exp Orthop* 2020;7:50.
- [11] Sasaki N, Farraro KF, Kim KE, Woo SL. Biomechanical evaluation of the quadriceps tendon autograft for anterior cruciate ligament reconstruction: A cadaveric study. *Am J Sports Med* 2014;42:723–30.
- [12] Urchek R, Karas S. Biomechanical comparison of quadriceps and 6-strand hamstring tendon grafts in anterior cruciate ligament reconstruction. *Orthop J Sports Med* 2019;7 [2325967119879113].
- [13] Murgier J, Powell A, Young S, Clatworthy M. Effectiveness of thicker hamstring or patella tendon grafts to reduce graft failure rate in anterior cruciate ligament reconstruction in young patients. *Knee Surg Sports Traumatol Arthrosc* 2021;29, <http://dx.doi.org/10.1007/s00167-020-05973-y>.
- [14] Kanakamedala AC, de Sa D, Obioha OA, Arakgi ME, Schmidt PB, Lesniak BP, et al. No difference between full thickness and partial thickness quadriceps tendon autografts in anterior cruciate ligament reconstruction: A systematic review. *Knee Surg Sports Traumatol Arthrosc* 2019;27:105–16.
- [15] Akoto R, Albers M, Balke M, Bouillon B, Hoher J. ACL reconstruction with quadriceps tendon graft and press-fit fixation versus quadruple hamstring graft and interference screw fixation - a matched pair analysis after one year follow up. *BMC Musculoskelet Disord* 2019;20:109.
- [16] Nyland J, Collis P, Huffstutler A, Sachdeva S, Spears JR, Greene J, et al. Quadriceps tendon autograft ACL reconstruction has less pivot shift laxity and lower failure rates than hamstring tendon autografts. *Knee Surg Sports Traumatol Arthrosc* 2020;28:509–18.
- [17] Mouarbes D, Dagneaux L, Olivier M, Lavoue V, Peque E, Berard E, et al. Lower donor-site morbidity using QT autografts for ACL reconstruction. *Knee Surg Sports Traumatol Arthrosc* 2020;28:2558–66.
- [18] Horteur C, Cavalie G, Gaulin B, Cohen Bacry M, Morin V, Cavaignac E, et al. Saphenous nerve injury after anterior cruciate ligament reconstruction: Reduced numbness area after ligamentoplasty using quadriceps tendon compared with hamstring tendon. *Knee* 2020;27:1151–7.
- [19] Lind M, Strauss M, Nielsen T, Engebretsen L. Response letter to "higher re-rupture rate in quadriceps tendon acl reconstruction surgeries performed in Denmark: Let's return to the mean" by Matthieu Ollivier (*Knee Surg Sports Traumatol Arthrosc* 2020;28:3657–8).
- [20] Ollivier M, Jacquet C, Pailhe R, Cognault J, Cavaignac E, Seil R. Higher re-rupture rate in quadriceps tendon acl reconstruction surgeries performed in Denmark: Let's return to the mean. *Knee Surg Sports Traumatol Arthrosc* 2020;28:3655–6.
- [21] Lind M, Strauss MJ, Nielsen T, Engebretsen L. Low surgical routine increases revision rates after quadriceps tendon autograft for anterior cruciate ligament reconstruction: Results from the Danish knee ligament reconstruction registry. *Knee Surg Sports Traumatol Arthrosc* 2021;29, <http://dx.doi.org/10.1007/s00167-020-06220-0>.