



**HAL**  
open science

## **Osteoid Osteoma: Percutaneous CT-guided Cryoablation Is a Safe, Effective, and Durable Treatment Option in Adults.**

Thomas Le Corroller, Thomas Vives, Jean-Camille Mattei, Vanessa Pauly, Daphne Guenoun, Alexandre Rochwerger, Pierre Champsaur

### ► To cite this version:

Thomas Le Corroller, Thomas Vives, Jean-Camille Mattei, Vanessa Pauly, Daphne Guenoun, et al.. Osteoid Osteoma: Percutaneous CT-guided Cryoablation Is a Safe, Effective, and Durable Treatment Option in Adults.. Radiology, 2022, 302 (2), pp.392–399. <10.1148/radiol.2021211100>. <hal-03553762>

**HAL Id: hal-03553762**

**<https://hal.science/hal-03553762v1>**

Submitted on 13 Mar 2023

HAL is a multi-disciplinary open access archive for the deposit and dissemination of scientific research documents, whether they are published or not. The documents may come from teaching and research institutions in France or abroad, or from public or private research centers.

L'archive ouverte pluridisciplinaire HAL, est destinée au dépôt et à la diffusion de documents scientifiques de niveau recherche, publiés ou non, émanant des établissements d'enseignement et de recherche français ou étrangers, des laboratoires publics ou privés.



HAL Authorization

# Osteoid Osteoma: Percutaneous CT-guided Cryoablation Is a Safe, Effective, and Durable Treatment Option in Adults

Thomas Le Corroller, MD, PhD • Thomas Vives, MD • Jean-Camille Mattei, MD • Vanessa Pauly, PhD • Daphné Guenoun, MD, PhD • Alexandre Rochwerg, MD, PhD • Pierre Champsaur, MD, PhD

From the Department of Radiology, Hôpitaux Sud, Assistance Publique – Hôpitaux de Marseille, Marseille, France (T.L.C., T.V., D.G., P.C.); Aix Marseille Université, CNRS, ISM UMR 7287, Marseille, France (T.L.C., D.G., P.C.); Department of Orthopedic Surgery, Hôpital Nord, Assistance Publique – Hôpitaux de Marseille, Marseille, France (J.C.M., A.R.); and Aix Marseille Université, Unité de Recherche EA 3279, Santé Publique et Maladies Chroniques, Marseille, France (V.P.). Received May 5, 2021; revision requested July 6; revision received August 13; accepted September 14. **Address correspondence to** T.L.C., Department of Radiology, Hôpital Sainte-Marguerite, 270 Bd de Sainte-Marguerite, 13009 Marseille, France (e-mail: [Thomas.LeCorroller@ap-bm.fr](mailto:Thomas.LeCorroller@ap-bm.fr)).

Conflicts of interest are listed at the end of this article.

**Background:** Cryoablation is playing an increasing role in the percutaneous treatment of bone tumors. However, despite its potential advantages over heat-based ablation techniques, the clinical safety and efficacy of cryoablation have not been established for osteoid osteoma treatment.

**Purpose:** To evaluate percutaneous CT-guided cryoablation for the treatment of osteoid osteoma in young patients and adults.

**Materials and Methods:** This retrospective study reviewed data from 50 consecutive patients who underwent percutaneous CT-guided cryoablation for the treatment of osteoid osteoma between January 2013 and June 2019 in a single institution. In 30 of 50 patients (60%), the procedure was carried out with the patient under local anesthesia and conscious sedation, with the cryoprobe covering the lesion from an extraosseous position, avoiding direct penetration of the nidus. Clinical and radiologic features, procedure-related data, visual analog scale (VAS) pain scores, complications, and overall success rate were evaluated. Statistical analyses were performed by using the nonparametric Friedman test and Wilcoxon signed rank test for repeated measures.

**Results:** Fifty patients (median age, 24 years; interquartile range [IQR], 19–38 years; 31 men) underwent CT-guided cryoablation for the treatment of osteoid osteoma, with a 96% (48 of 50 patients) overall clinical success rate. Of the two patients without clinical success, one patient had incomplete pain relief and the other experienced a recurrence of osteoid osteoma at 11 months, which was successfully treated with a second cryoablation procedure. The median VAS pain score was 8 (IQR, 7–8) before the procedure and 0 (IQR, 0–1;  $P < .001$ ) after the procedure at both primary (6 weeks) and secondary (18–90 months) follow-up. Three of the 50 patients had minor complications (6%); no major complications were reported.

**Conclusion:** Osteoid osteoma was safely, effectively, and durably treated with CT-guided percutaneous cryoablation. In the majority of patients, treatment could be performed without general anesthesia, with the cryosphere covering the nidus from an extraosseous position.

Osteoid osteoma is a relatively common benign primary bone tumor that is typically encountered in young patients, with a male-to-female ratio of 2:1 (1,2). Patients present with pain, which is characteristically more pronounced at night and relieved by nonsteroidal anti-inflammatory drugs, especially acetylsalicylic acid (3). At imaging, this bone-forming tumor consists of a small, round, or oval well-demarcated nidus, with or without central mineralization, associated with a surrounding zone of reactive bone formation (1). The lesion is typically associated with adjacent bone marrow and soft-tissue edema. In contrast with osteoblastoma, osteoid osteoma has limited growth potential and usually measures less than 15–20 mm in diameter (4). Most osteoid osteomas are found in the appendicular skeleton, with more than half of tumors occurring in the femur and tibia, while spinal osteoid osteoma accounts for 7%–20% of all lesions (5,6).

Although percutaneous ablation of such tumors may be performed using any thermal ablation technology, radiofrequency (RF) ablation is the most commonly used technique (7–9). Because RF ablation is successful in more than 90% of patients after a single treatment and has a very

low complication rate, it has replaced surgery as the first-line treatment option since the late 1990s (10–12).

On the other hand, cryoablation is currently playing an increasing role in percutaneous treatment of bone tumors, affording several distinct advantages over heat-based ablation techniques (13). First, the evolution of the cryosphere generated with cryoablation can be monitored intraprocedurally using intermittent nonenhanced CT scans. The second advantage of the cryoablation systems is that, as opposed to the inductive nature of RF heat generation, the conductive nature of ice formation allows the ice ball to be transmitted across sclerotic bone, which is particularly useful when treating bone-forming tumors such as osteoid osteoma and osteoblastoma (14,15). Furthermore, in the setting of osteoid osteoma, cryoablation may even allow the treatment of the lesion from an extraosseous position, avoiding direct placement of the probe tip within the nidus to destroy the tumor (16,17). A third major advantage of this technology is that cryoablation is well tolerated by patients under conscious sedation and is associated with less postprocedural pain than RF ablation (18).

## Abbreviations

IQR = interquartile range, RF = radiofrequency, VAS = visual analog scale

## Summary

CT-guided cryoablation should be considered in patients scheduled for percutaneous treatment of osteoid osteoma because it has decreased pain and faster workflow compared with radiofrequency ablation.

## Key Results

- In a retrospective study of 50 consecutive patients, osteoid osteoma was treated with percutaneous CT-guided cryoablation, with a 96% overall clinical success rate.
- In 70% of patients (35 of 50), treatment was performed with the cryoprobe placed at the cortex parallel to the lesion, covering the nidus from an extraosseous position, which avoided bone drilling.
- In 60% of patients (30 of 50), cryoablation was performed with the patient under local anesthesia combined with conscious sedation, providing a faster workflow.

However, despite its potential advantages over heat-based ablation techniques, cryoablation has been less thoroughly studied for the treatment of osteoid osteoma than RF ablation and larger studies on clinical results remain lacking (16,17,19–21). Therefore, the aim of our study was to evaluate percutaneous CT-guided cryoablation for the treatment of osteoid osteoma in young patients and adults.

## Materials and Methods

### Study Design

Institutional review board approval was obtained for this retrospective study, with a waiver for the requirement of written informed consent because the study was a review of clinical and imaging data. All consecutive patients who underwent primary treatment of osteoid osteoma with CT-guided percutaneous cryoablation at a single academic hospital offering tertiary services to adult patients (age  $\geq 15$  years) (Institute for Locomotion, Aix-Marseille Université, Marseille, France) from January 2013

to June 2019 were identified by research performed in our institutional radiologic information system (Xplore, EDL). A total of 53 patients were identified. Three patients were excluded because no follow-up data were available after their discharge from the hospital. Consequently, 50 patients were included in the study (Fig 1).

Of note, the initial results for 21 of the 50 patients in this series were reported in a previously published article that evaluated the technical feasibility and preliminary efficacy of percutaneous cryoablation for the treatment of osteoid osteoma (17). In the present study, we evaluate patient outcomes after performing cryoablation treatment of osteoid osteoma in a larger sample of patients.

### Preprocedural Evaluation

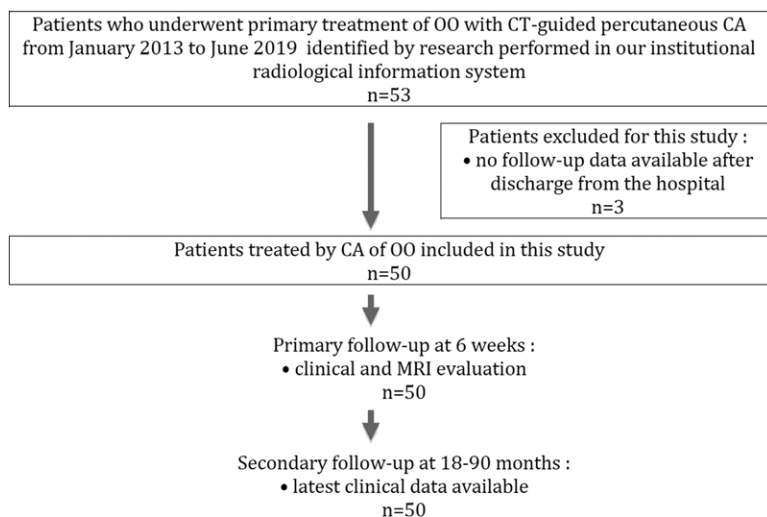
All patients were referred for treatment by a multidisciplinary tumor board including orthopedic surgeons and musculoskeletal radiologists. Cryoablation treatment was proposed for young patients and adults (age  $\geq 15$  years) with typical clinical presentation, a pain score of 5 or above on a visual analog scale (VAS), and characteristic imaging findings.

Imaging evaluation involved the review of nonenhanced CT scans, MRI scans, and, in some patients, technetium-99m methylene diphosphonate isotope bone scans that were available before the cryoablation procedure. CT scan findings suggestive of osteoid osteoma included the presence of a round or ovoid tumor with a maximum diameter of 20 mm exhibiting a radiolucent nidus, well-defined margins, and surrounding osteosclerosis (1). Upon examining the MRI scans, there was evidence of bone marrow edema around the tumor; after intravenous contrast material injection, the nidus showed typical enhancement. When bone scintigraphy was performed, the tumor constantly manifested a focal higher uptake of the radionuclide tracer because of a large vascular supply and high osteoblastic activity.

### Cryoablation Technique

All patients were treated by a single operator specialized in musculoskeletal intervention and experienced in performing cryoablation procedures (T.L.C., with 10 years of experience). Between 2 and 8 weeks before the procedure, patients were informed of the cryoablation technique and the benefits and potential complications during a preprocedural consultation with the interventional radiologist.

All procedures were performed on an inpatient basis because this is the standard of care for cryoablation in our institution. When possible (30 of 50 patients, 60%), procedures were carried out with the patient under local anesthesia with 1% lidocaine and 0.2% ropivacaine at the skin entry site and periosteum, combined with conscious sedation using nitrous oxide administered by inhalation (50% N<sub>2</sub>O, 50% oxygen; duration, 10–30 minutes). In addition, tramadol (100–200 mg) and paracetamol (1–2 g) were intravenously administered before the procedure for pain management.



**Figure 1:** Flowchart illustrates number of patients treated with cryoablation (CA), excluded patients, study population, and follow-up. OO = osteoid osteoma.

The remaining 20 patients received general anesthesia to allow direct penetration of the nidus (15 of 50 patients, 30%) or because of patient anxiety (five of 50 patients, 10%).

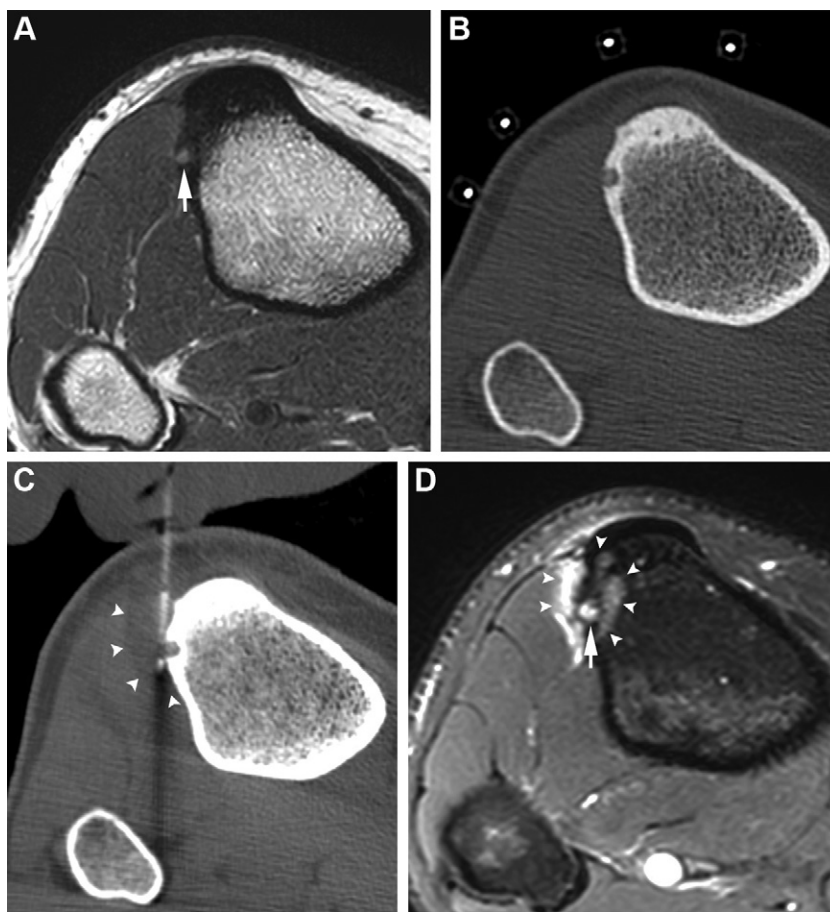
Multidetector CT (LightSpeed VCT 64, GE Healthcare) without contrast material injection was used to localize the lesion and plan the approach. Then, cryoablation was conducted under strict aseptic conditions using a cryoablation system (VISUAL-ICE System, Galil Medical) and a single 17-gauge cryoablation needle with ablation zone diameters measuring either 20 × 27 mm at −20°C (IceSeed 1.5, Galil Medical) or 26 × 32 mm at −20°C (IceSphere 1.5, Galil Medical).

Every time the ablation zone could cover the lesion from an extraosseous position (35 of 50 patients, 70%), the cryoprobe was placed at the cortex, parallel to the lesion, avoiding bone drilling and direct penetration of the nidus (Figs 2, 3) (16,17). In the remaining patients (15 of 50 patients, 30%), an 11-gauge bone biopsy needle (Laurane Bone Biopsy Kit, Laurane Medical) was inserted into the bone up to the nidus margin and bone biopsy was performed using a 12.5-gauge trephine needle. Then, the cryoprobe was placed coaxially through the access needle within the nidus (Fig 4). The access needle was finally withdrawn slightly so that the distal 2 cm of the cryoprobe was exposed. To prevent skin injury, a surgical glove filled with warm saline solution was placed on the skin at the puncture area. A freeze-thaw-freeze cycle was performed with a time frame consisting of two 10-minute freezing phases around an intermediate 8-minute thawing phase, itself divided into a 7-minute passive thawing phase and a 1-minute active thawing phase using either helium gas or helium-free active thawing. However, according to the size of the target lesion and the need for the protection of nearby nontarget structures, freezing cycles were terminated prematurely or reduced in power (60%–100%) when the cryosphere extended within 10 mm of adjacent critical structures such as nerves or cartilage. When necessary, carbodissection allowed the displacement and insulation of vulnerable organs by injecting CO<sub>2</sub> (Fig 3) (22). Intermittent noncontrast CT images were obtained intraprocedurally to visualize the ice ball extension during freezing phases and to monitor for changes in the surrounding tissue. The ablation zone could be observed on CT scans as a hypoattenuating area in the soft tissue but was often less conspicuous within the bone or adjacent to the dense metallic probe in the soft tissue (20). In addition, to evaluate a particular vulnerable motor pathway, the interventional radiologist conducted a focused neurologic physical examination

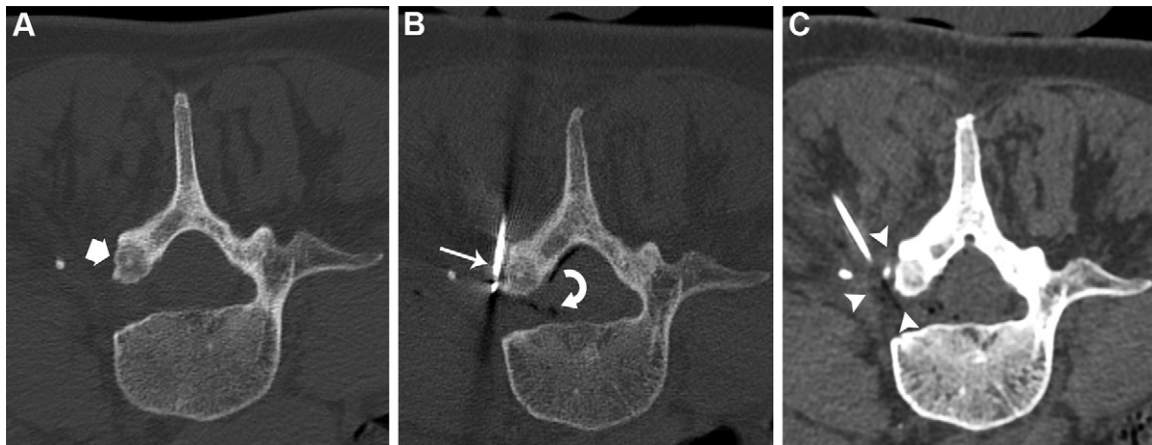
on patients under conscious sedation during the ablation procedure.

Technical success was defined as the ability to visualize the ice ball adequately covering the osteoid osteoma nidus. Signs of complications were monitored if the ablation zone extended into the neurovascular bundle, skin, or articular cartilage (20).

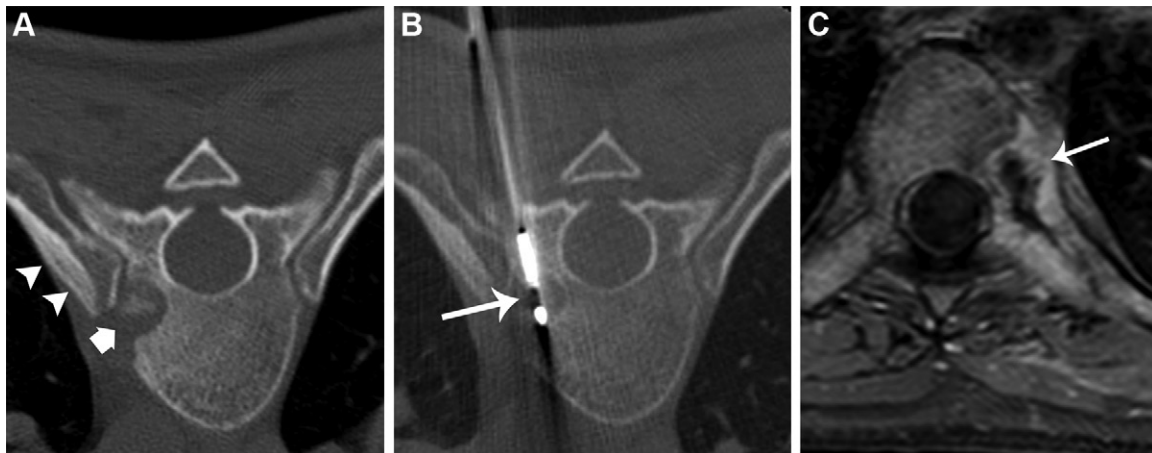
After ablation, the cryoprobe was removed and a final CT examination was performed to check for immediate complications. Patients were observed for 30 minutes in the interventional radiology department and then returned to the ward if there was no discomfort. In case of immediate posttreatment residual symptoms, ketoprofen (100 mg) was intravenously administered in addition to the premedication regimen described earlier for a complete prostaglandin blockade. Patients were discharged home the day following the procedure and were asked to limit high-impact athletic activities and cyclic-loading activities during the 4 weeks after treatment.



**Figure 2:** Images in an 18-year-old man with a right tibia osteoid osteoma. **(A)** Axial noncontrast T1-weighted spin-echo MRI scan demonstrates the 5-mm nidus (arrow) and adjacent cortical sclerosis of the anterolateral shaft of the right tibia. **(B)** Axial noncontrast CT image shows the intracortical nidus with subtle central mineralization. **(C)** Axial noncontrast CT image obtained intraprocedurally to visualize the ice ball extension (arrowheads) during the freezing phase. The parallel placement of the cryoprobe is crucial for juxtacortical treatment because the cryosphere does not develop in axis distally from the tip of the probe. **(D)** Axial fat-suppressed T1-weighted spin-echo MRI scan obtained at 6-week follow-up after intravenous injection of gadolinium-based contrast material shows the ablation zone (arrowheads) with a target-like appearance encompassing the nidus (arrow).



**Figure 3:** Images in a 48-year-old woman with a spinal osteoid osteoma of L4. **(A)** Axial noncontrast CT image obtained with the patient in the prone position demonstrates the 9-mm nidus (arrow) and adjacent cortical sclerosis of the left pars interarticularis. **(B)** Axial noncontrast CT image shows the cryoprobe (straight arrow) placed at the cortex parallel to the nidus. Carbolysis allowed the insulation of the dural sac and, most important, the spinal nerve by injecting CO<sub>2</sub> (curved arrow) using a spinal needle placed within the intervertebral foramen. **(C)** Axial noncontrast CT image obtained intraoperatively to visualize the ice ball extension (arrowheads) during the freezing phase. Of note, the spinal needle used for carbolysis is only partially seen.



**Figure 4:** Images in a 24-year-old woman with a spinal osteoid osteoma of T8. **(A)** Axial noncontrast CT image obtained with patient in the prone position demonstrates the 10-mm nidus (arrow) and hyperostosis of the adjacent left rib (arrowheads). **(B)** Axial noncontrast CT image shows the cryoprobe (arrow) placed within the nidus coaxially through the access needle. **(C)** Axial fat-suppressed T1-weighted spin-echo MRI scan obtained at 6-week follow-up after intravenous injection of gadolinium-based contrast material shows the ablation zone (arrow) with a target-like appearance of central necrosis and bright edematous periphery.

### Patient Follow-up

All patients were primarily reassessed at 6 weeks after cryoablation to evaluate clinical success and potential postprocedural complications. The postprocedure VAS score was collected at this time. In addition, a follow-up MRI examination was performed on the same day to evaluate the ablation zone and identify potential complications (including stress fractures, osteonecrosis, synovitis, and adjacent tissue damage) (16). Then, to collect the latest available clinical data, all patients were contacted for secondary follow-up and outcome evaluation between 18 and 90 months after the procedure regarding the recurrence of pain or delayed complications. The VAS score was again collected at that time.

Clinical success was defined as complete relief of pain at the primary and secondary follow-up without the use of any pain medication and with full return to normal activities. Minor

complications were defined as complications that resulted in no sequelae, whereas major complications were defined as complications that resulted in prolonged hospitalization or permanent adverse sequelae (20).

### Statistical Analysis

Statistical tests were performed by a statistical analyst (V.P., with 10 years of experience) using SPSS software (SPSS). Categorical variables were described using numbers and percentages, and quantitative variables were described using medians and interquartile range (IQR). To test whether there were changes in VAS scores before and after the procedure (6 weeks and 18–90 months after), we performed the nonparametric Friedman test for repeated measures.

Then, two-way comparisons were performed using the nonparametric Wilcoxon signed rank test for repeated measures

data. All significance tests were two sided, and  $P < .05$  was considered indicative of a statistically significant difference.

## Results

### Patient Characteristics

Among the 50 patients who were enrolled in the study, there were 31 male and 19 female patients, with a median age of 24 years (IQR, 19–38 years; age range, 15–75 years) (Table 1). Lesions were located in the femur ( $n = 20$ ), spine ( $n = 9$ ), tibia ( $n = 5$ ), humerus ( $n = 5$ ), talus ( $n = 4$ ), cuboid ( $n = 2$ ), coxal bone ( $n = 1$ ), patella ( $n = 1$ ), fibula ( $n = 1$ ), calcaneus ( $n = 1$ ), and intermediate cuneiform ( $n = 1$ ). The median ni-

dus diameter was 6 mm (IQR, 4–9 mm; range, 3–16 mm). Eight osteoid osteomas (16%) were intra-articular, located in the hip ( $n = 3$ ), knee ( $n = 2$ ), midfoot ( $n = 2$ ), and ankle joints ( $n = 1$ ).

### Cryoablation Treatment

Table 2 summarizes the procedural factors related to cryoablation treatment. The median entire procedure duration was 80 minutes (IQR, 60–100 minutes; range, 40–120 minutes), with an effective cryoablation median time of 28 minutes. The cryoablation procedure was technically successful in 98% of patients (49 of 50), with the ice ball adequately covering the lesion and no sign of immediate complication. In one patient, retrospective imaging review revealed a sub-optimal placement of the cryoprobe with an inadvertent eccentric position of the probe tip next to the nidus center and incomplete coverage of the lesion by the ice ball on CT images during ablation (17).

**Table 1: Baseline Patient Characteristics**

Characteristic	Value
No. of patients	50
Patient age (y)*	24 (19–38)
Sex	
M	31 (62)
F	19 (38)
Tumor size (mm)*	6 (4–9)
Tumor anatomic location	
Femur	20 (40)
Vertebra	9 (18)
Tarsus	8 (16)
Tibia	5 (10)
Humerus	5 (10)
Other	3 (6)
Tumors in challenging locations	
Articular lesion	8 (16)
Spinal lesion	9 (18)

Note.—Unless otherwise noted, data are numbers of patients, with percentages in parentheses.

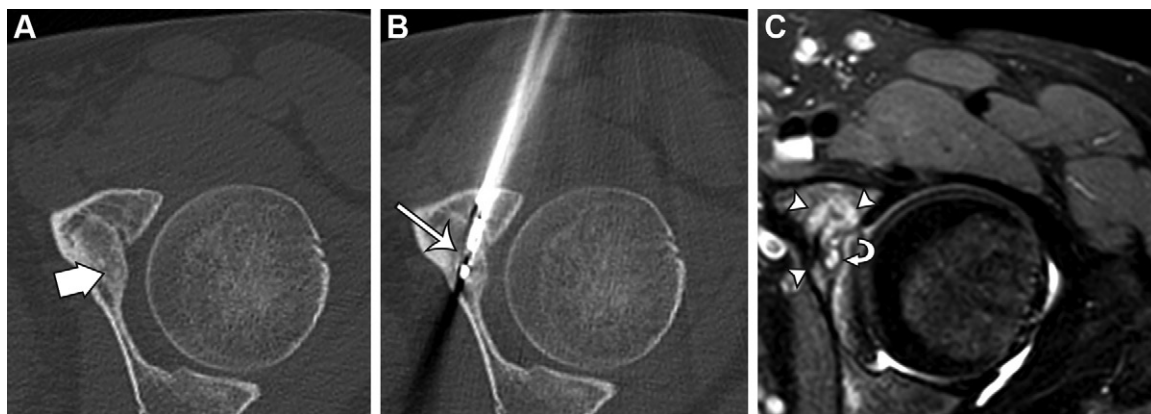
\* Median value, with interquartile range in parentheses.

**Table 2: Procedural Factors Related to Cryoablation Treatment**

Factor	Value
Complete treatment duration (min)*	80 (60–100)
Effective treatment duration (min)	28
Anesthesia type	
Local	30 (60)
General	20 (40)
Cryoprobe position	
Extraosseous	35 (70)
Intraosseous	15 (30)
Bone biopsy required	15 (30)
Technical success	49 (98)

Note.—Unless otherwise noted, data are numbers of patients, with percentages in parentheses.

\* Median value, with interquartile range in parentheses.



**Figure 5:** Images in a 26-year-old woman with an osteoid osteoma of the left acetabulum. **(A)** Axial noncontrast CT image obtained with the patient in the supine position demonstrates a 4-mm intra-articular nidus (arrow) of the anterior acetabulum. **(B)** Axial noncontrast CT image obtained intraprocedurally shows that to prevent damage to the articular cartilage, treatment was performed in this patient with an eccentric position of the cryoprobe tip (arrow) with regard to the lesion center, still allowing the nidus to be fully included in the  $-20^{\circ}\text{C}$  isotherm. **(C)** Axial fat-suppressed T1-weighted spin-echo MRI scan obtained at 6-week follow-up after intravenous injection of gadolinium-based contrast material shows the ablation zone (arrowheads) encompassing the nidus (arrow). No complications were observed.

**Table 3: Clinical Outcome after Percutaneous Cryoablation**

Parameter	Value	Observation
Baseline vs primary follow-up VAS score*	8 (7–8) vs 0 (0–1)	Significant difference ( $P < .001$ )
Baseline vs secondary follow-up VAS score*	8 (7–8) vs 0 (0–1)	Significant difference ( $P < .001$ )
Clinical success rate (%)	96 (48)	Recurrence ( $n = 1$ ), persistent pain related to hip FAI ( $n = 1$ )
Recurrence rate (%)	2 (1)	Successful treatment obtained with a second cryoablation procedure
Complication rate (%)	6 (3)	Soft-tissue swelling ( $n = 2$ ), mild skin burn ( $n = 1$ )

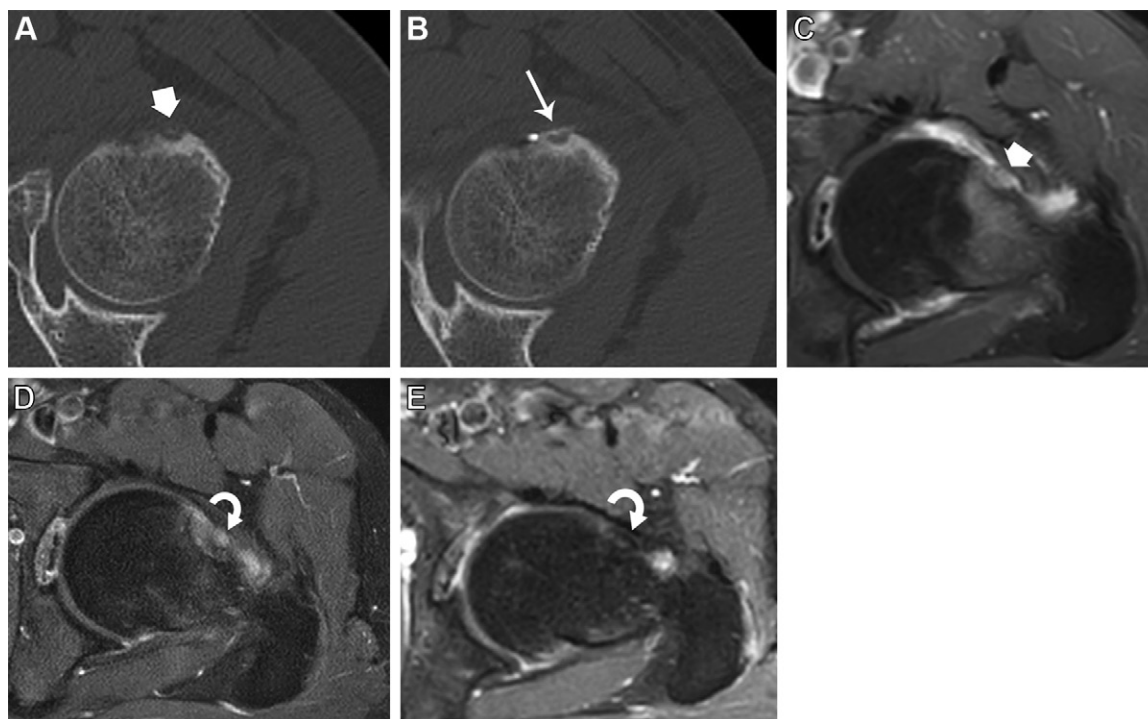
Note.— Unless otherwise noted, data in parentheses are numbers of patients. FAI = femoro-acetabular impingement, VAS = visual analog scale.

\* Median value, with interquartile range in parentheses.

### Patient Outcomes

At 6 weeks, the ablation zone was clearly visible on postprocedure MRI scans in only 27 of the 50 patients (54%), with a “target-like” appearance encompassing the nidus (Figs 2, 5) (17). Median VAS scores were 8 (IQR, 7–8; range, 5–10) before the procedure and 0 (IQR, 0–1; range, 0–5) ( $P < .001$ ) after the procedure at the 6-week follow-up. At the secondary follow-up (18–90 months), the median VAS score was 0 (IQR, 0–1; range, 0–7) ( $P < .001$ ) (Table 3). The comparison between the post-procedure pain scores at the primary and secondary follow-up did not show any statistically significant difference ( $P = .23$ ).

The overall clinical success rate was 96% (48 of 50 patients), with one patient experiencing incomplete pain relief and another experiencing a recurrence of osteoid osteoma at 11 months, which was successfully treated with a second cryoablation procedure. We noted that this single case of recurrence was related to the suboptimal placement of the cryoprobe, described above as a technical failure (17). Interestingly, the patient with incomplete pain relief after cryoablation treatment of a femoral neck osteoid osteoma demonstrated complete resolution of his proximal femur bone marrow edema at follow-up MRI examinations; however, he presented with cam-type femoro-acetabular impingement



**Figure 6:** Images in a 32-year-old man with an intra-articular osteoid osteoma of the left hip. **(A)** Axial noncontrast CT image obtained with patient in the supine position demonstrates a 3-mm intra-articular nidus (arrow) of the proximal femur. **(B)** Axial noncontrast CT image shows the cryoprobe (arrow) placed at the cortex parallel to the nidus. **(C)** Axial fat-suppressed T1-weighted spin-echo MRI scan obtained after intravenous injection of gadolinium-based contrast material shows a small intra-articular nidus (arrow) of the proximal femur with adjacent bone marrow edema and joint effusion. **(D)** Axial fat-suppressed T1-weighted spin-echo MRI scan obtained at 6-week follow-up after intravenous injection of gadolinium-based contrast material shows the ablation zone (arrow) with a target-like appearance encompassing the nidus. **(E)** Axial fat-suppressed T1-weighted spin-echo MRI scan obtained at 4-year follow-up after intravenous injection of gadolinium-based contrast material demonstrates complete resolution of the previous nidus and adjacent bone marrow abnormalities (arrow). However, this patient had femoro-acetabular impingement related to residual hypertrophy of the femoral head-neck junction.

related to residual hypertrophy of the femoral head-neck junction at the site of tumor ablation (Fig 6).

Three of the 50 patients (6%) experienced minor complications: two patients had transient pain and soft-tissue swelling during the week that followed the treatment of midfoot osteoid osteomas, and one patient had mild skin burn at the ankle. No major complications were reported.

Finally, when a bone biopsy was performed before ablation, the diagnosis of osteoid osteoma was histologically proven in only 40% of patients (six of 15), while inconclusive findings were observed in 60% of patients (nine of 15).

## Discussion

Cryoablation can provide additional benefits over radiofrequency ablation in patients scheduled for CT-guided treatment of osteoid osteoma. Most importantly, cryoablation treatment can be performed with an eccentric position of the cryoprobe tip with regard to the tumor center as long as the nidus is fully included in the  $-20^{\circ}\text{C}$  isotherm. In the majority of osteoid osteomas, ablation can even be performed from an extraosseous position with the cryoprobe placed at the cortex, parallel to the lesion, which avoids bone drilling and direct penetration of the nidus (16,17). However, despite its advantages over heat-based ablation techniques, the clinical safety and efficacy of cryoablation have not been established for osteoid osteoma treatment. Our objective was to retrospectively evaluate patient outcomes after cryoablation treatment of osteoid osteoma. In our study of 50 consecutive patients, osteoid osteoma was effectively treated with percutaneous CT-guided cryoablation, with a significant pain score decrease ( $P < .001$ ) after the procedure both at the primary and secondary follow-up. In 70% of patients (35 of 50), cryoablation was performed with the cryoprobe placed at the cortex parallel to the lesion, covering the nidus from an extraosseous position, which avoided bone drilling; in 60% of patients (30 of 50), cryoablation was even performed without general anesthesia, providing a faster workflow.

Percutaneous RF ablation for the treatment of osteoid osteoma was first introduced in 1992 by Rosenthal et al (7). Since then, RF ablation has been the most thoroughly studied and commonly performed ablation method for the treatment of osteoid osteoma, with published success rates ranging from 88% to 95% (9,11,23). On the other hand, cryoablation has only recently been applied in the treatment of osteoid osteoma (16–21,24–26). Our data suggest at least equal efficacy between RF ablation and cryoablation for the treatment of osteoid osteoma, which is of particular importance given the additional benefits of cryoablation. We report a 98% technical success rate with a single case of technical failure, which may be more related to the learning curve phenomenon than to an intrinsic limitation of this ablation technology (17). Our overall clinical success rate was 96%, with one patient experiencing a recurrence of osteoid osteoma related to the suboptimal placement of the cryoprobe described earlier and another experiencing incomplete pain relief secondary to cam-type femoro-acetabular impingement after technically successful treatment of a femoral neck osteoid osteoma. The complication rate was 6%, with no major complications observed. Our results are comparable

to the findings of previous case series and preliminary studies describing cryoablation treatment of osteoid osteoma, with reported success rates between 89% and 100%, recurrence rates between 0% and 8%, and complication rates between 0% and 14% (16,27).

Special attention was given in our study to the ablation of osteoid osteomas in the more challenging locations that are represented by intra-articular and spinal lesions. First, the treatment of intra-articular osteoid osteoma is associated with a risk of joint damage and cartilage injury (27). In our study, although the number of intra-articular osteoid osteomas was relatively small (eight of 50), we did not observe any joint-specific complications over at least an 18-month clinical follow-up interval. However, we acknowledge that longer term follow-up will be needed to exactly determine the risk of chondrolysis and subsequent osteoarthritis in intra-articular osteoid osteomas. As described earlier, we observed one case of femoro-acetabular impingement after cryoablation treatment of a femoral neck osteoid osteoma related to a residual bump at the femoral head-neck junction. Similar bone changes, such as osteophytes mimicking early osteoarthritis or a widening of the femoral neck, are known to be associated with hip osteoid osteoma (28).

Spinal lesions ( $n = 9$ ) were treated in the same way and given particular attention because of the proximity to critical structures such as the spinal nerves and cord (6,27). Nevertheless, no transient or permanent neurologic complications were noted in our patients. Protective measures were taken in lesions with less than 10 mm distance between the nidus and the neural structure at risk, with epidural and/or foraminal carbon dioxide insufflation administered during the procedure (6,22,29). In addition, in patients treated with local anesthesia, real-time functional assessment of nerve function during the procedure provided greater safety in the vicinity of critical neural structures (17,29).

Potential disadvantages of cryoablation for the percutaneous treatment of osteoid osteoma should also be discussed. First, cryoablation is theoretically more time consuming than RF ablation because of the typical time frame consisting of two 10-minute freezing phases around an intermediate 8-minute thawing phase. However, in our study, the median duration of the entire procedure was only 80 minutes and varied from 40 minutes for the simplest lesions treated under conscious sedation to 120 minutes for the most complex lesions that needed bone drilling under general anesthesia. Wu et al (20) reported in their pediatric case series a mean duration of 90 minutes for the entire cryoablation procedure, which is comparable to the 90–120-minute average duration reported by Rosenthal et al (11) when using RF ablation. In fact, cryoablation should instead be considered time saving when the patient is treated under conscious sedation, with less time spent in both the CT unit and the postinterventional care unit, providing a faster workflow as compared with RF ablation. Second, because cryoablation does not necessitate a direct approach to the nidus, histologic confirmation of osteoid osteoma was not systematically performed. However, performing periprocedural biopsies before RF ablation of osteoid osteoma may lead to disappointing results because of highly variable histopathologic confirmation rates, regardless

of the needle caliber or quality of the sample (30). Finally, the equipment required for cryoablation is more expensive than that for RF ablation, with an average cryoprobe cost approximately three times higher than that of an RF needle. However, cryoablation is associated with less postprocedure pain, less analgesic use, and shorter hospital stays when compared with RF ablation (18). Cryoablation treatment for osteoid osteoma can even be performed on an outpatient basis in experienced centers as a way to reduce costs (16).

Limitations of our study are mainly the retrospective analysis of data and the lack of systematic histologic tumor verification. First, we acknowledge that the present work is a retrospective, single-arm, noncontrolled, and single-institution study. Because the perception of pain is influenced by a placebo effect, the lack of placebo condition is a major weakness of our study. Thus, cryoablation treatment of osteoid osteoma, while demonstrating promising results, still requires more published data for comparative efficacy. Second, because a major advantage of cryoablation is to allow juxtacortical treatment of osteoid osteoma, we did not perform a biopsy in most patients. Rather, the diagnosis was made preoperatively by a multidisciplinary tumor board and relied only on characteristic clinical and radiologic presentation. Finally, because our institution offers tertiary services to patients aged 15 years and older, we acknowledge that our data may not be generalized to younger patients and believe further research is required to evaluate cryoablation as a new technique for treating children with osteoid osteoma.

In conclusion, our study suggests at least that osteoid osteoma can be safely, effectively, and durably treated with percutaneous cryoablation in the adult population. In most patients, treatment was performed without general anesthesia and cortical drilling, with the cryosphere covering the nidus from an extraosseous position. Overall, our data indicate that cryoablation should be considered in patients scheduled for percutaneous treatment of osteoid osteoma given its additional benefits, such as decreased pain and faster workflow, over radiofrequency ablation.

**Author contributions:** Guarantors of integrity of entire study, T.L.C., T.V., J.C.M., D.G., P.C.; study concepts/study design or data acquisition or data analysis/interpretation, all authors; manuscript drafting or manuscript revision for important intellectual content, all authors; approval of final version of submitted manuscript, all authors; agrees to ensure any questions related to the work are appropriately resolved, all authors; literature research, T.L.C., T.V., J.C.M., D.G.; clinical studies, T.L.C., T.V., J.C.M., D.G.; experimental studies, T.L.C., T.V., J.C.M.; statistical analysis, T.L.C., T.V., V.P.; and manuscript editing, T.L.C., T.V., J.C.M., A.R.

**Disclosures of Conflicts of Interest:** T.L.C. No relevant relationships. T.V. No relevant relationships. J.C.M. No relevant relationships. V.P. No relevant relationships. D.G. No relevant relationships. A.R. No relevant relationships. P.C. No relevant relationships.

## References

- Kransdorf MJ, Stull MA, Gilkey FW, Moser RP Jr. Osteoid osteoma. *RadioGraphics* 1991;11(4):671–696.
- Unni KK. *Dahlin's bone tumours: general aspects and data on 11,087 cases*. 5th ed. Philadelphia, Pa: Lippincott-Raven, 2016; 121–142.
- Huang AJ. Radiofrequency ablation of osteoid osteoma: difficult-to-reach places. *Semin Musculoskelet Radiol* 2016;20(5):486–495.
- Yalcinkaya U, Doganavsargil B, Sezak M, et al. Clinical and morphological characteristics of osteoid osteoma and osteoblastoma: a retrospective single-center analysis of 204 patients. *Ann Diagn Pathol* 2014;18(6):319–325.
- Rosenthal D, Callstrom MR. Critical review and state of the art in interventional oncology: benign and metastatic disease involving bone. *Radiology* 2012;262(3):765–780.
- Tsoumakidou G, Thénint MA, Garnon J, Buy X, Steib JP, Gangi A. Percutaneous image-guided laser photocoagulation of spinal osteoid osteoma: A single-institution series. *Radiology* 2016;278(3):936–943.
- Rosenthal DI, Alexander A, Rosenberg AE, Springfield D. Ablation of osteoid osteomas with a percutaneously placed electrode: a new procedure. *Radiology* 1992;183(1):29–33.
- Gangi A, Alizadeh H, Wong L, Buy X, Dietemann JL, Roy C. Osteoid osteoma: percutaneous laser ablation and follow-up in 114 patients. *Radiology* 2007;242(1):293–301.
- Rimondi E, Mavrogenis AF, Rossi G, et al. Radiofrequency ablation for non-spinal osteoid osteomas in 557 patients. *Eur Radiol* 2012;22(1):181–188.
- Rosenthal DI, Hornicek FJ, Wolfe MW, Jennings LC, Gebhardt MC, Mankin HJ. Percutaneous radiofrequency coagulation of osteoid osteoma compared with operative treatment. *J Bone Joint Surg Am* 1998;80(6):815–821.
- Rosenthal DI, Hornicek FJ, Torriani M, Gebhardt MC, Mankin HJ. Osteoid osteoma: percutaneous treatment with radiofrequency energy. *Radiology* 2003;229(1):171–175.
- Lanza E, Thouvenin Y, Viala P, et al. Osteoid osteoma treated by percutaneous thermal ablation: when do we fail? A systematic review and guidelines for future reporting. *Cardiovasc Intervent Radiol* 2014;37(6):1530–1539.
- Callstrom MR, Kurup AN. Percutaneous ablation for bone and soft tissue metastases: why cryoablation? *Skeletal Radiol* 2009;38(9):835–839.
- Cazzato RL, Auloge P, Dalili D, et al. Percutaneous Image-Guided Cryoablation of Osteoblastoma. *AJR Am J Roentgenol* 2019;213(5):1157–1162.
- Poullain F, Mattei JC, Rochwerger A, et al. Percutaneous cryoablation of osteoblastoma in the proximal femur. *Skeletal Radiol* 2020;49(9):1467–1471.
- Coupal TM, Mallinson PI, Munk PL, Liu D, Clarkson P, Ouellette H. CT-guided percutaneous cryoablation for osteoid osteoma: initial experience in adults. *AJR Am J Roentgenol* 2014;202(5):1136–1139.
- Santiago E, Pauly V, Brun G, Guenoun D, Champsaur P, Le Corroller T. Percutaneous cryoablation for the treatment of osteoid osteoma in the adult population. *Eur Radiol* 2018;28(6):2336–2344.
- Thacker PG, Callstrom MR, Curry TB, et al. Palliation of painful metastatic disease involving bone with imaging-guided treatment: comparison of patients' immediate response to radiofrequency ablation and cryoablation. *AJR Am J Roentgenol* 2011;197(2):510–515.
- Liu DM, Kee ST, Loh CT, et al. Cryoablation of osteoid osteoma: two case reports. *J Vasc Interv Radiol* 2010;21(4):586–589.
- Wu B, Xiao YY, Zhang X, Zhao L, Carrino JA. CT-guided percutaneous cryoablation of osteoid osteoma in children: an initial study. *Skeletal Radiol* 2011;40(10):1303–1310.
- Whitmore MJ, Hawkins CM, Prologo JD, et al. Cryoablation of Osteoid Osteoma in the Pediatric and Adolescent Population. *J Vasc Interv Radiol* 2016;27(2):232–237; quiz 238.
- Garnon J, Cazzato RL, Caudrelier J, et al. Adjunctive Thermoprotection During Percutaneous Thermal Ablation Procedures: Review of Current Techniques. *Cardiovasc Intervent Radiol* 2019;42(3):344–357.
- Hage AN, Chick JFB, Gemmete JJ, Grove JJ, Srinivasa RN. Percutaneous radiofrequency ablation for the treatment of osteoid osteoma in children and adults: a comparative analysis in 92 patients. *Cardiovasc Intervent Radiol* 2018;41(9):1384–1390.
- Callstrom MR, Dupuy DE, Solomon SB, et al. Percutaneous image-guided cryoablation of painful metastases involving bone: multicenter trial. *Cancer* 2013;119(5):1033–1041.
- Auloge P, Cazzato RL, Rousseau C, et al. Complications of Percutaneous Bone Tumor Cryoablation: A 10-year Experience. *Radiology* 2019;291(2):521–528.
- Jennings JW. Is Percutaneous Bone Cryoablation Safe? *Radiology* 2019;291(2):529–530.
- Lindquister WS, Crowley J, Hawkins CM. Percutaneous thermal ablation for treatment of osteoid osteoma: a systematic review and analysis. *Skeletal Radiol* 2020;49(9):1403–1411.
- Malghem J, Lecouvet F, Kirchgessner T, Acid S, Vande Berg B. Osteoid osteoma of the hip: imaging features. *Skeletal Radiol* 2020;49(11):1709–1718.
- Kurup AN, Schmit GD, Morris JM, et al. Avoiding complications in bone and soft tissue ablation. *Cardiovasc Intervent Radiol* 2017;40(2):166–176.
- Laredo JD, Hamze B, Jeribi R. Percutaneous biopsy of osteoid osteomas prior to percutaneous treatment using two different biopsy needles. *Cardiovasc Intervent Radiol* 2009;32(5):998–1003.