



HAL
open science

Ultrasound-Guided Perimeniscal Injections: Anatomical Description and Feasibility Study

Clemence Coll, Jean-Marie Coudreuse, Daphne Guenoun, Laurent Bensoussan, Jean-Michel Viton, Pierre Champsaur, Thomas Le Corroller

► **To cite this version:**

Clemence Coll, Jean-Marie Coudreuse, Daphne Guenoun, Laurent Bensoussan, Jean-Michel Viton, et al.. Ultrasound-Guided Perimeniscal Injections: Anatomical Description and Feasibility Study. Journal of Ultrasound in Medicine, 2022, 41 (1), pp.217-224. 10.1002/jum.15700 . hal-03553760

HAL Id: hal-03553760

<https://hal.science/hal-03553760>


Submitted on 9 Mar 2023

HAL is a multi-disciplinary open access archive for the deposit and dissemination of scientific research documents, whether they are published or not. The documents may come from teaching and research institutions in France or abroad, or from public or private research centers.

L'archive ouverte pluridisciplinaire **HAL**, est destinée au dépôt et à la diffusion de documents scientifiques de niveau recherche, publiés ou non, émanant des établissements d'enseignement et de recherche français ou étrangers, des laboratoires publics ou privés.

Ultrasound-guided Perimeniscal Injections

Anatomical Description and Feasibility Study

Clemence Coll, MD, Jean-Marie Coudreuse, MD, Daphne Guenoun, MD, PhD, Laurent Bensoussan, MD, PhD, Jean-Michel Viton, MD, PhD, Pierre Champsaur, MD, Thomas Le Corroller, MD, PhD 

Objectives—To anatomically describe the ultrasound (US)-guided perimeniscal injection technique, and evaluate its feasibility in the treatment of meniscal pain.

Methods—This work was initially undertaken in four cadaveric specimens with US-guided medial and lateral perimeniscal injection of China ink, followed by cadaveric dissection to assess injectate distribution, and potential injury to intra-articular and peri-articular structures. Then, 35 consecutive patients who underwent US-guided perimeniscal corticosteroid injection under local anesthesia for the treatment of symptomatic medial (30/35) or lateral (5/35) degenerative meniscal tear were retrospectively evaluated. Clinical outcome was assessed using a 0–10 numerical verbal rating scale (VRS) to evaluate severity of pain before, during, and after procedure at 6 weeks follow-up.

Results—Seven of eight (87.5%) ex vivo injections were accurate. A single inaccurate medial perimeniscal injection infiltrated the tibial collateral ligament instead of the perimeniscal area. No anatomical specimen exhibited intrameniscal injection or injury to regional structures. All procedures (35/35) performed clinically were technically successful. Median VRS scores were: 7 (range, 3–9) before procedure, 5 (range, 0–10) during procedure, and 1.5 (range, 0–9) after procedure at 6 weeks follow-up ($P < .0001$). No complication was observed.

Conclusions—US-guided perimeniscal injections can accurately and safely deliver injectates in the perimeniscal area. In addition, our data suggest that perimeniscal corticosteroid injection provides significant symptom relief at 6 weeks in patients with meniscal pain. Further studies with long-term follow-up will be required to evaluate the role of perimeniscal injections in the nonoperative management of meniscal pathology.

Key Words—anatomy; knee; meniscus; ultrasound

The knee menisci are two crescent-shaped discs of fibrocartilage that enable effective articulation between the femoral condyles and the relatively flat tibial plateau.^{1,2} Their main functions are load transmission to a large area of articular cartilage, joint stabilization and shock absorption during locomotion. Because of the enhanced understanding of the anatomic structure and biomechanical functions of the menisci, the management of meniscal tears has evolved; and the concept of meniscal preservation has progressed over years.³⁻⁶

Conservative treatment is now the first-line choice in most patients presenting symptomatic degenerative meniscal tears, with image-guided injections being routinely used for the treatment of

meniscal pain.⁷ In recent years, there has been increased interest in the use of ultrasound (US) guidance for therapeutic injections in the musculoskeletal system, with the advantages of real-time imaging, absence of radiation exposure, and convenience of performing the procedure portably.⁸ In particular, at the knee, US offers high spatial resolution and exquisite soft tissue delineation, making it an ideal guidance modality for both intra- and extra-articular injections.^{9,10} However, experience with meniscus-targeted injections for the treatment of knee pain due to degenerative meniscal tears is still limited.^{11,12} In particular, there is a lack of description of the precise anatomical target that is referred to as either “parameniscal area,” “perimeniscal area,” or “meniscus wall” in the previously published case series.^{11,12} Other authors even combine during the same procedure perimeniscal injection with meniscal needling and intrameniscal injection.¹³ Thus, the objectives of the present study were first to describe the anatomical target and precise technique of US-guided perimeniscal injections with confirmation of accuracy using cadaveric specimens, and then to evaluate the safety and preliminary clinical outcome of this injection technique in the treatment of meniscal pain.

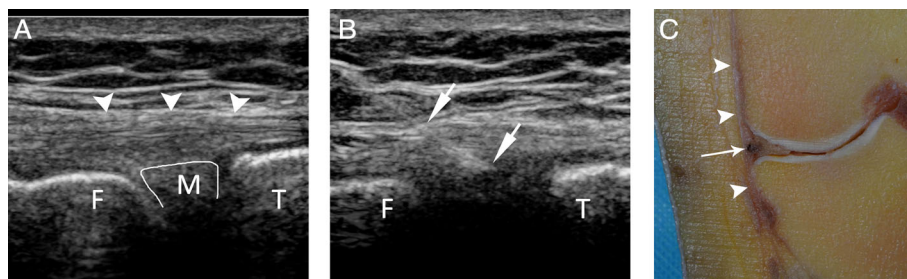
Materials and Methods

Anatomical Study in Cadavers

In compliance with institutional safety and ethics regulations, this study was initially undertaken on four formalin-embalmed cadaveric lower limbs amputated

at the mid-thigh level (1 man and 1 woman, age at death 76 and 82 years, respectively) to preliminarily assess whether US guidance permits precise delivery of medication in the perimeniscal tissue. None of the cadavers showed prior evidence of knee injury or surgical procedures. The specimens were placed in supine position with the knee positioned at approximately 30° of flexion and were examined using an iU22 (*Philips*) and a linear 17–5 MHz probe. A staff radiologist with 15 years of experience performed all the examinations. Initial US examination of the medial and lateral menisci was performed both longitudinally and transversely to obtain visualization of the tibio-femoral joint space and body of the meniscus. Then, the US-guided perimeniscal injection was performed. The transducer was aligned with the long axis of the lower limb across the tibio-femoral joint space. The anterior aspect of the medial collateral ligament (MCL) and the popliteal sulcus were used as anatomical landmarks for transducer placement during medial and lateral perimeniscal injections, respectively. Using an in-plane approach, a 21-gauge needle was advanced under sonographic guidance from cranial to caudal into the medial or lateral meniscus wall (Figure 1). Once the needle touched the meniscus wall, it was slightly retracted by 1 mm, and an injection of 1 mL of China ink in the perimeniscal tissue was performed. The injectate administration was confirmed by real-time visualization of bright echoes filling the perimeniscal area interposed between the meniscus wall and joint capsule.

Figure 1. Left knee of an 82 year-old female cadaver. **A**, Coronal sonographic view of the medial tibiofemoral joint space showing the superficial tibial collateral ligament (arrowheads), femur (F), tibia (T), and medial meniscus (M). **B**, Coronal sonographic view of the medial tibiofemoral joint space showing a 21 gauge needle (short arrows) advanced in the medial meniscus wall. **C**, Coronal anatomical slice at the level of the tibial collateral ligament (arrowheads) demonstrating China ink (long arrow) distribution in the perimeniscal tissue between the medial meniscus wall and joint capsule.



After each injection, specimens were placed at -20°C for 48 hours. Thick coronal slices were obtained to evaluate the injectate distribution (Figure 1). Then, the anatomical specimens were further dissected to assess for iatrogenic injury to the regional at-risk structures, including the medial and lateral inferior geniculate arteries, saphenous nerve, common fibular nerve, and hyaline cartilage. Accuracy was considered as either “accurate” (a clear track of ink within the perimeniscal tissue) or “inaccurate” (no clear track seen within the targeted perimeniscal area).

Patient Selection and Clinical Study

The clinical part of this study was approved by the institutional ethics committee with waiver of written informed consent for the review of clinical and imaging data.

All consecutive patients who underwent US-guided perimeniscal injection from January 2017 to October 2018 were initially identified in the institutional radiologic information system (*Xplore, EDL*) through a search using two keywords (“meniscus” and “injection”) entered simultaneously. Then, because the diagnosis of symptomatic meniscal tear relies on a careful combination of clinical history, physical examination, and imaging findings, our inclusion criteria were: localized knee pain with joint line tenderness, pain duration of less than one year, absence or minimal joint space narrowing (> 4 mm joint space) on Rosenberg radiographs, presence of a medial or lateral degenerative meniscal tear on magnetic resonance (MR) imaging without proposed arthroscopic treatment, and MR examination of the knee performed within 3 months before procedure as part of the pretherapeutic work-up. Exclusion criteria were a history of previous knee arthroscopy or open surgery, a previous knee steroid injection within 6 months before procedure, and a lack of clinical follow-up. A total of thirty-five patients could finally be included (25 men, 10 women; mean age, 55 years old; age range, 30–77 years old).

The US-guided perimeniscal injections were performed using an iU22 (*Philips*) and either a linear 15–7 MHz hockey stick probe or a linear 17–5 MHz probe. Five staff radiologists with 2 to 15 years of experience performed all the examinations. Power Doppler was systematically used before injection to identify either the medial or lateral inferior geniculate

artery. Local anesthesia was the first step with 2 mL of lidocaine injected in the subcutaneous tissue and in proximity to the meniscus wall by using a 25-gauge needle. Then, the injection technique was exactly the same as described in cadavers, with either a 25- or 21-gauge needle advanced into the meniscus wall and slightly retracted by 1 mm to allow injection in the perimeniscal tissue of 1 mL of either betamethasone (7 mg) in 20/35 patients or triamcinolone (20 mg) in 15/35 patients. A retrospective review of the images from the 35 injections was made in consensus by two radiologists different from the operator to determine technical accuracy. Technical success was defined as visualization of bright echoes filling the perimeniscal area and visualization of capsule distension. In every patient, the severity of pain during procedure was documented using a 0–10 numerical verbal rating scale (VRS).

Then, patients were clinically followed up by the referring clinician to evaluate pain evolution and primary clinical outcome. Clinical success was defined as patients who reported full return to daily activities, and no need for NSAIDs or other analgesics at six weeks after procedure.

Statistical analyses were performed with XLSTAT software for Microsoft Excel (*version 2018.7, XLSTAT*). Categorical variables were described using numbers and percentages, and quantitative ones using means \pm standard deviation, or medians and interquartile range. Two-ways comparisons were performed using the non-parametric Wilcoxon signed rank test for correlated data. All significance tests were two-sided, and *P* values less than .05 were considered statistically significant.

Results

Anatomical Study in Cadavers

Injection accuracy is presented in Table 1. Seven of eight (87.5%) *ex vivo* injections were accurate. A single inaccurate medial perimeniscal injection infiltrated the MCL instead of the perimeniscal area.

No anatomical specimens exhibited intrameniscal injection or demonstrated evidence of iatrogenic injury to regional structures.

Clinical Study

Thirty medial (30/35; 85.7%) and five lateral (5/30; 14.3%) US-guided perimeniscal injections were performed. Technical success was achieved in all cases.

Median VRS scores were: 7 (range, 3–9) before procedure, 5 (range, 0–10) during procedure, and 1.5 (range, 0–9) after procedure at 6 weeks follow-up ($P < .0001$) (Table 2).

Five patients (5/35; 14.3%) reported transient post-procedural pain during the 24 hours that followed the perimeniscal injection which may logically be related to capsule distension. No immediate or delayed complication was observed.

Perimeniscal corticosteroid injection provided significant symptom relief with a 66.85% mean VRS decrease at 6 weeks follow-up (Table 2).

No difference was observed between the betamethasone (20/35) and triamcinolone (15/35) groups.

Primary clinical success was 71% (25/35) with twenty-five patients reporting full return to daily activities, and no need for analgesics at six weeks.

Among the remaining ten patients who did not report clinical success at 6 weeks, four patients (4/35; 11.4%) underwent arthroscopic surgery or knee

replacement surgery during the year that followed procedure. The six others patients were treated conservatively with prolonged physiotherapy and in case of femorotibial chondropathy intrasynovial injection of hyaluronic acid.

Discussion

The primary function of the knee menisci is to transmit load across the tibiofemoral joint by increasing congruency, and thereby decreasing the resultant stress placed on the articular cartilage.^{1,2} The menisci also play a crucial role in shock absorption, stability, lubrication, nutrition, and proprioception to the knee joint.¹⁴ Over the past three decades, with the advent of knee arthroscopy, there has been a continuous improvement in surgical techniques to assess and treat meniscal pathology.^{15,16} The enhanced understanding of the anatomic structure and biomechanical functions of the menisci has progressively led to a shift toward meniscal preservation.⁶ In particular, recent randomized studies demonstrated that arthroscopic partial meniscectomy has no superiority over non-operative treatment.^{4,5} The current surgical consensus is that intact meniscal tissue should be preserved as much as possible to avoid the degenerative results that may follow its removal.¹⁷ Because conservative treatment is now the first-line choice in symptomatic meniscal tears, meniscal pain is routinely treated with activity modification, quadriceps strengthening, anti-inflammatory or analgesic medications, and intra-articular or meniscus-targeted injections.^{7,11-13} Thus, the objectives of the present study were to determine the accuracy of US-guided perimeniscal injections by using cadaveric specimens, and then to evaluate the safety and preliminary clinical outcome of this technique in the treatment of meniscal pain.

First, our work demonstrated in anatomical specimens that US permits precise delivery of medication in the perimeniscal tissue. Anatomically, the outer rim of the menisci is thick, convex, and attached to the knee joint capsule.² Yet, our data showed that, although the peripheral border of the meniscus body apparently merges with the knee joint capsule, US-guided injections targeting the meniscocapsular junction were able to accurately place 1 mL injectates

Table 1. Injection Accuracy in Cadavers

Anatomical region	Accurate (n)	Inaccurate (n)	Observation
Medial meniscus	3	1	China ink distribution superficial to target
Lateral meniscus	4	0	
Total	7 (87.5%)	1 (12.5%)	

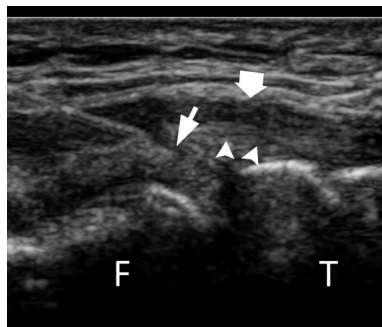
Table 2. Clinical Results at 6 weeks in 35 Patients

VRS	Before Injection	After Injection	Observation
Minimum	3	0	
Maximum	9	9	
Median	7	1.5	$P < .0001$
Mean (SD)	6.89 (1.6)	2.24 (2.45)	66.85% decrease

VRS, verbal rating scale; SD, standard deviation.

in the perimeniscal area. In our cadaveric study, a single inaccurate medial perimeniscal injection was noted that infiltrated the MCL instead of the perimeniscal tissue. An anatomic explanation here is that the medial meniscus shares fibers with the deep MCL near its capsular attachment.¹⁸ Because it can sometimes be difficult to distinguish between the deep MCL and the most peripheral border of the meniscus, the single inaccurate cadaveric injection was too superficial and infiltrated the MCL bursa, between the deep and superficial fibers of the MCL. Of note, a retrospective review of our images disclosed that

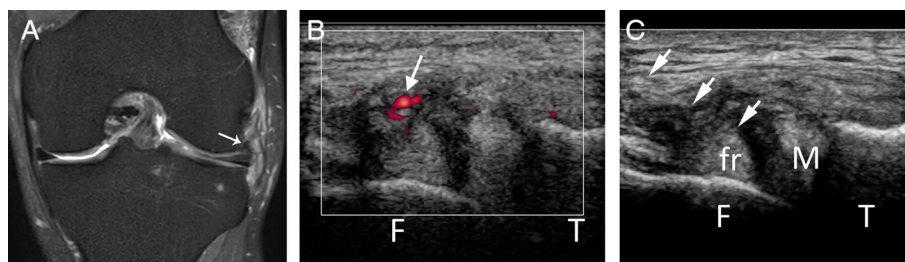
Figure 2. 63 year-old male with symptomatic medial meniscus tear. Coronal sonographic view of the medial tibiofemoral joint space showing the femur (F), tibia (T), and a 25-gauge needle (short arrow) advanced from cranial to caudal into the medial meniscus wall, using an in-plane approach technique. The superficial (thick arrow) and deep (arrowheads) fibers of the MCL are identified both superficial to the needle tip. The correct position of the needle tip (short arrow) between the meniscus wall and deep MCL fibers will allow successful corticosteroid injection in the perimeniscal tissue.



inaccurate injection could also occur in vivo when the needle was retracted and inadvertently positioned superficial to the deep MCL fibers, leading to MCL bursa injection instead of perimeniscal injection (Figure 2). Besides, we did not observe any intrameniscal injection or iatrogenic injury to the menisci. In contrast, we found a low resistance flow pattern during injection in which the injectate distribution only involved the perimeniscal tissue interposed between the meniscus wall and joint capsule. A previous anatomical study recently suggested that, given the tightly woven collagen fibers of the meniscus, intrameniscal distribution can only occur with high resistance injection or in the presence of pre-existing substantial degenerative changes such as meniscal clefts.¹⁹

Then, our study showed in 35 patients with symptomatic degenerative meniscal tears that medial and lateral perimeniscal injection procedures could safely be performed under US guidance (Figures 2 and 3). Technical success for the US-guided injection was achieved in all cases. Furthermore, in our population, perimeniscal corticosteroid injection provided symptom relief and functional recovery in most patients with a 66.85% mean VRS decrease at 6 weeks follow-up, and no immediate or delayed complications. Because the menisci innervation follows the blood supply, nerve fibers are found primarily in the peripheral vascular zone covering the outer third of the meniscus, whereas the inner two-thirds of the menisci contain no nerves.^{2, 20} Owing to the peripheral location of the free nerve endings acting as

Figure 3. 65 year-old male with symptomatic complex tear of the lateral meniscus. **A.** Coronal fat suppressed proton-density MR image obtained before perimeniscal injection showing complex tear of the lateral meniscus body with displaced fragment in the parafemoral recess (long arrow) and edematous signal of the perimeniscal tissue. **B.** Coronal sonographic view of the lateral tibiofemoral joint space with power Doppler demonstrating the femur (F), tibia (T), and inferior lateral geniculate artery (arrow) before perimeniscal injection. **C.** Coronal sonographic view of the lateral tibiofemoral joint space disclosing the lateral meniscus (M) with a superiorly displaced meniscal fragment (fr). Using an in-plane approach technique, a 25-gauge needle (short arrows) is advanced in the perimeniscal area.

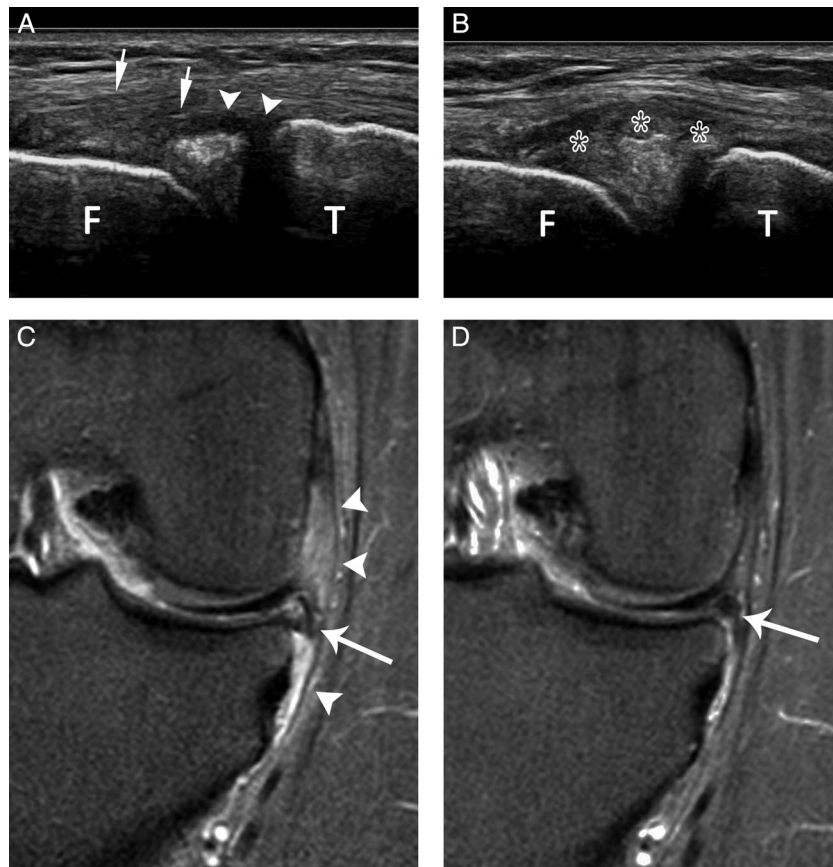


nociceptors in meniscal pain, a meniscus-targeted injection with corticosteroid may support the diagnosis of symptomatic meniscal tear and help to rule out other intra-articular pain generators, such as cartilage defects and synovitis. Furthermore, perimeniscal injection may provide mid- to long-term symptomatic relief by interrupting the inflammatory cascade and reducing vascular permeability at the peripheral border of the menisci.^{11,21}

Some limitations may be considered inherent to the materials and methods used in this study. First, all injections in cadavers were performed by a single experienced operator. Thus, interoperator reliability was not formally investigated in this study. Yet, in the

clinical part of this study, a total of five different radiologists with 2–15 years of experience successfully performed all the perimeniscal injections. Second, we acknowledge that the viscosity of China ink used *ex vivo* may be higher than that of corticosteroids, which may influence the propensity for injectate spread from the target site, and may minimize the therapeutic agent migration from the target site. In the same way, a specific anatomical study using cadavers with meniscal tears would also be helpful to highlight the areas of seepage of the injectate and to demonstrate whether the injectate penetrates through the meniscal tears into the joint. Third, we acknowledge that our population is too small to allow further

Figure 4. 45 year-old male with symptomatic complex tear of the medial meniscus body and posterior horn. **A**, Coronal sonographic view of the medial tibiofemoral joint space showing the femur (F), tibia (T), subtle hypoechoic thickening of the perimeniscal tissue (arrowheads), and a 25-gauge needle (short arrows) advanced in the medial meniscus wall. **B**, The injectate administration was confirmed by real-time visualization of bright echoes (asterisks) filling the perimeniscal area. **C**, Coronal fat suppressed proton-density MR images obtained before perimeniscal injection showing focal edema (arrowheads) of the perimeniscal tissue and complex tear with extrusion of the medial meniscus body (long arrow). **D**, Coronal fat suppressed proton-density MR images at 6 months after perimeniscal injection demonstrating resolution of the perimeniscal edema and persistent medial meniscus tear with slight improvement of meniscal extrusion (long arrow).



statistical analysis on subgroups of patients that would have taken into consideration the type or location of meniscal tear. Fourth, another important limitation of the present work is the lack of long-term clinical follow-up in our population. Because a recently published case series showed an average 5.68 weeks duration of symptom reduction after perimeniscal injection, we decided to evaluate responses to our procedure at a 6 week follow-up.¹¹ Thus, our data cannot provide further insight into the long-term efficacy of this treatment option.

Another limitation of our study is the lack of comparison to intra-articular joint injection which is theoretically quicker and less technically challenging. We acknowledge that our results highlight the need for future prospective research comparing perimeniscal injections with intra-articular steroid injections to clarify the role of perimeniscal injections in the non-operative management of meniscal pathology. Finally, because degenerative meniscal tears are frequent incidental findings, the use of meniscal pain as main inclusion criteria in our clinical study should itself be discussed. Other structures or processes related to knee osteoarthritis may be contributing to the pain, such as synovitis or bone marrow lesions, the latter possibly initiated by altered loading patterns and chronic overloading due to the loss of meniscal function. Therefore, careful clinical evaluation was required in our study at patients' inclusion to determine if the damaged meniscus was likely to directly impact the patient's symptoms.²¹ To make a confident diagnosis of symptomatic meniscal tear, we relied on a combination of clinical history (localized pain, duration < one year), physical examination (joint space tenderness at palpation, lack of varus alignment), and imaging findings (absence or minimal joint space narrowing on radiographs, meniscal tear on MRI) as suggested by Katz et al²² At MR imaging, edematous signal of the perimeniscal tissue was also helpful to support the diagnosis of symptomatic meniscal tear (Figures 3 and 4).

In conclusion, our study demonstrates that US guidance by offering optimal visualization of local anatomical structures permits safe and precise delivery of medication in the perimeniscal tissue. In addition, our results suggest that perimeniscal corticosteroid injection can provide mid-term symptom relief and functional recovery in patients with meniscal pain. Further studies

with longer follow-up will now be required to evaluate the role of perimeniscal injections in the management of patients with meniscal disorders.

Conflict of Interest

The authors have nothing to disclose.

References

1. Messner K, Gao J. The menisci of the knee joint. Anatomical and functional characteristics, and a rationale for clinical treatment. *J Anat* 1998; 193:161–178.
2. Fox AJ, Wanivenhaus F, Burge AJ, Warren RF, Rodeo SA. The human meniscus: a review of anatomy, function, injury, and advances in treatment. *Clin Anat* 2015; 28:269–287.
3. Yim JH, Seon JK, Song EK, et al. A comparative study of meniscectomy and nonoperative treatment for degenerative horizontal tears of the medial meniscus. *Am J Sports Med* 2013; 41:1565–1570.
4. Sihvonen R, Paavola M, Malmivaara A, et al. Arthroscopic partial meniscectomy versus sham surgery for a degenerative meniscal tear. *N Engl J Med* 2013; 369:2515–2524.
5. Gauffin H, Sonesson S, Meunier A, Magnusson H, Kvist J. Knee arthroscopic surgery in middle-aged patients with meniscal symptoms: A 3-year follow-up of a prospective, randomized study. *Am J Sports Med* 2017; 45:2077–2084.
6. Beaufils P, Pujol N. Management of traumatic meniscal tear and degenerative meniscal lesions. Save the meniscus. *Orthop Traumatol Surg Res* 2017; 103:S237–S244.
7. Byrne C, Alkhatat A, Bowden D, Murray A, Kavanagh EC, Eustace SJ. Degenerative tears of the posterior horn of the medial meniscus: correlation between MRI findings and outcome following intra-articular steroid/bupivacaine injection of the knee. *Clin Radiol* 2019; 74:488.e1–488.e8.
8. Rastogi AK, Davis KW, Ross A, Rosas HG. Fundamentals of joint injection. *AJR Am J Roentgenol* 2016; 207:484–494.
9. Lalam RK, Winn N, Cassar-Pullicino VN. Interventional articular and para-articular knee procedures. *Br J Radiol* 2016; 89: 20150413.
10. Lee JH, Lee JU, Yoo SW. Accuracy and efficacy of ultrasound-guided pes anserinus bursa injection. *J Clin Ultrasound* 2019; 47: 77–82.
11. Wilderman I, Berkovich R, Meaney C, Kleiner O, Perelman V. Meniscus-targeted injections for chronic knee pain due to meniscal tears or degenerative fraying: a retrospective study. *J Ultrasound Med* 2019; 38:2853–2859.

12. Di Sante L, Venditto T, Ioppolo F, Paoloni M, Mangone M, Alviti F. Ultrasound guided injection of a painful knee osteoarthritis with medial meniscus extrusion: a case series study. *Muscles Ligaments Tendons J* 2017; 18:331–337.
13. Ricci V, Özçakar L, Galletti L, Domenico C, Galletti S. Ultrasound-guided treatment of extrusive medial meniscopathy: A 3-step protocol. *J Ultrasound Med* 2020; 39:805–810.
14. Chevrier A, Nelea M, Hurtig MB, Hoemann CD, Buschmann MD. Meniscus structure in human, sheep, and rabbit for animal models of meniscus repair. *J Orthop Res* 2009; 27: 1197–1203.
15. Abrams GD, Frank RM, Gupta AK, Harris JD, McCormick FM, Cole BJ. Trends in meniscus repair and meniscectomy in the United States, 2005-2011. *Am J Sports Med* 2013; 41:2333–2339.
16. Salata MJ, Gibbs AE, Sekiya JK. A systematic review of clinical outcomes in patients undergoing meniscectomy. *Am J Sports Med* 2010; 38:1907–1916.
17. Herrlin SV, Wange PO, Lapidus G, et al. Is arthroscopic surgery beneficial in treating non-traumatic, degenerative medial meniscal tears? A five year follow-up. *Knee Surg Sports Traumatol Arthrosc* 2013; 21:358–364.
18. Stein G, Koebeke J, Faymonville C, Dargel J, Müller LP, Schiffer G. The relationship between the medial collateral ligament and the medial meniscus: a topographical and biomechanical study. *Surg Radiol Anat* 2011; 33:763–766.
19. Baria MR, Sellon JL, Lueders D, Smith J. Sonographically guided knee meniscus injections: feasibility, techniques, and validation. *PMR* 2017; 9:998–1005.
20. Mine T, Kimura M, Sakka A, Kawai S. Innervation of nociceptors in the menisci of the knee joint: an immunohistochemical study. *Arch Orthop Trauma Surg* 2000; 120:201–204.
21. Englund M, Roemer FW, Hayashi D, Crema MD, Guermazi A. Meniscus pathology, osteoarthritis and the treatment controversy. *Nat Rev Rheumatol* 2012; 22:412–419.
22. Katz JN, Smith SR, Yang HY, et al. Value of history, physical examination, and radiographic findings in the diagnosis of symptomatic meniscal tear among middle-aged subjects with knee pain. *Arthritis Care Res (Hoboken)* 2017; 69:484–490.