



HAL
open science

Intradiscal oxygen-ozone therapy for the treatment of symptomatic lumbar disc herniation: A preliminary study.

Clémentine Simon, Thomas Le Corroller, Vanessa Pauly, Maud Creze, Pierre Champsaur, Daphne Guenoun

► **To cite this version:**

Clémentine Simon, Thomas Le Corroller, Vanessa Pauly, Maud Creze, Pierre Champsaur, et al.. Intradiscal oxygen-ozone therapy for the treatment of symptomatic lumbar disc herniation: A preliminary study.. *Journal de Neuroradiologie / Journal of Neuroradiology*, 2022, 49 (2), pp.180-186. 10.1016/j.neurad.2021.09.004 . hal-03553759

HAL Id: hal-03553759

<https://hal.science/hal-03553759>

Submitted on 10 May 2022

HAL is a multi-disciplinary open access archive for the deposit and dissemination of scientific research documents, whether they are published or not. The documents may come from teaching and research institutions in France or abroad, or from public or private research centers.

L'archive ouverte pluridisciplinaire **HAL**, est destinée au dépôt et à la diffusion de documents scientifiques de niveau recherche, publiés ou non, émanant des établissements d'enseignement et de recherche français ou étrangers, des laboratoires publics ou privés.

Intradiscal oxygen-ozone therapy for the treatment of symptomatic lumbar disc herniation: A preliminary study

Clémentine Simon^{a,b}, Thomas Le Corroller^{a,b}, Vanessa Pauly^{c,d},
Maud Creze, Writing - review & editing^e, Pierre Champsaur, Formal analysis^{a,b},
Daphne Guenoun^{a,b,*}

^a APHM, Sainte-Marguerite Hospital, Institute for Locomotion, Department of Radiology, 13009, Marseille, France

^b Aix Marseille Univ, CNRS, ISM, Inst Movement Sci, Marseille, France

^c Aix Marseille Univ, Unité de recherche EA3279, Santé Publique et Maladies Chroniques: Qualité de vie Concepts, Usages et Limites, Déterminants, 13005, Marseille, France

^d APHM, Service de Santé Publique et d'Information Médicale, Hôpital de la Conception, Marseille, France

^e Radiology Department, Bicêtre Hospital, APHP, Le Kremlin-Bicêtre, France

A B S T R A C T

Purpose: To assess safety and effectiveness of computed tomography (CT)-guided intradiscal oxygen-ozone therapy (O₂-O₃ therapy) for the treatment of symptomatic lumbar disc herniation and radiological changes.

Materials and Methods: This study was conducted in twenty patients presenting lumbar disc herniation with resistant lumbar or lumbar radicular pain. They underwent intradiscal oxygen-ozone therapy under CT guidance. They were treated at one- or two-disc levels, representing a total of 24 discs treated. MR imaging examinations were obtained before treatment and 2 months post-procedure to analyse treatment-related disc modifications including modification of the surfaces of the disc and of the herniated disc, and the variations in disc height according to the disc height index. Clinical outcomes were assessed using the visual analogue scale (VAS) to evaluate the severity of pain before the procedure, at primary (2 months) and at secondary (12 months) follow-ups.

Results: All the procedures were technically successful. The median VAS scores were 7.95 before the procedure, 3.9 at 2 months and 2.95 at 12 months. MRI analysis showed a significant decrease in herniation size at 2 months (-20%, $p = 0.008$). No immediate or late complications were observed. Only three patients (13.6%) underwent lumbar spine microdiscectomy in the year following ozone therapy. The treatment appeared to be more effective in cases of nerve root symptomatology.

Conclusion: This study suggests that intradiscal O₂-O₃ therapy is safe and effective for the treatment of lumbar disc herniation associated with resistant lumbar or lumbar radicular pain.

1. Introduction

Nonspecific nerve root pain and low back pain are two of the most common cause of disability in the world. More than three out of four people will experience several episodes of lumbar and/or radicular pain during their lifetime.¹

Most of the time, the pain disappears spontaneously or after conservative treatment. Otherwise, it becomes a real public health

* Corresponding author at: Daphne GUENOUN, MD PhD, APHM, Sainte-Marguerite Hospital, Institute for Locomotion, Department of Radiology, 270 boulevard sainte Marguerite 13009 Marseille, France.

E-mail addresses: clementine.simon@ap-hm.fr (C. Simon), Thomas.lecorroller@ap-hm.fr (T.L. Corroller), Vanessa.pauly@ap-hm.fr (V. Pauly), Maud.creze@aphp.fr (M. Creze), Pierre.champsaur@ap-hm.fr (P. Champsaur), Daphne.guenoun@ap-hm.fr (D. Guenoun).

problem with social and economic impacts. Therapeutic planning traditionally begins with noninvasive treatment based on pharmacological and rehabilitation treatments. If conservative treatment, including rest, medications, and physical therapy, failed to relieve the pain, facet joint or epidural corticosteroid injection is considered (periradicular corticosteroid injection is not recommended in France because of its potential side effects).

When this treatment is not sufficiently effective, minimally invasive percutaneous techniques including intradiscal steroid, chemonucleolysis, intradiscal decompression, laser, discectomy, and annuloplasty, are an interesting alternative to avoid or delay surgical treatment.^{2,3}

Intra-discal O₂-O₃ therapy is a minimally invasive and inexpensive procedure feasible under CT-scan or fluoroscopic guidance. The treatment principle is based on reducing the volume of the disc and

Glossary

O ₂ -O ₃	oxygen ozone
VAS	Visual Analogic Scale
DH	Disc Herniation
IDET	Electrothermal Intradiscal Therapy
MEOPA	(Nitrogen Monoxide-Oxygen Mixture)
HIZ	High-Intensity Zone
DHI	Disc Height Index
MDH	Mean Disc Height

the pressure on the adjacent nerve root, without affecting spinal canal.⁴

The use of ozone (O₂-O₃ therapy), the tri-atomic form of oxygen, has many advantages, including its low cost, ease of manufacture and safety for adjacent structures, with few complications.^{4,5}

Ozone injection induces an oxidation reaction. By oxidizing the proteoglycans contained in the disc nucleus, ozone is responsible for dehydration, with a reduction of the disc volume and pressure and a resorption of hernia. Its chemical properties are anti-inflammatory and anti-nociceptive. Despite its low cost, the ease of the technique and the good results reported in the literature, intra-discal oxygen-ozone treatment is not widely used in France. Because intra-discal O₂-O₃ therapy is not well known to clinicians and radiologists, only 3 cities all over France offer this treatment.

Previous studies have shown the clinical efficacy of intradiscal ozone therapy in low back pain and nerve root pain caused by lumbar disc herniation (LDH) but there is no consensus on the selection of patients, nor on the injection method: fluoroscopic or CT-guidance, general or local analgesia, total gas volume, ozone concentration, frequency of injection, use of perforaminial steroid and local anesthetics. Your experience could be considered to constitute a contribution to an effort to validate this technique.

The main objective of our study was to assess the effectiveness and safety of intradiscal O₂-O₃ therapy. The second objective was to analyse radiological changes and criteria for good therapeutic response.

2. Materials and methods

2.1. Study design

We started intradiscal O₂-O₃ therapy in our centre in 2018, under CT-guidance, and we followed the first twenty-two patients treated with ozone during the first-year post-treatment.

Institutional review board approval was obtained for this study with waiver of written informed consent for the review of clinical and imaging data.

2.2. Inclusion and exclusion criteria

We included patients (from 20 to 85 years old) treated by oxygen-ozone therapy at one or more disc levels, at Sainte Marguerite Hospital, APHM, Marseille, France between 2018 and 2019.

Inclusion criteria were as follows: patients suffering from low back pain and/or radicular leg pain; persistent pain for at least 6 months that was nonresponsive to conservative treatments; at least one epidural or facet joint corticosteroid injection in the last past year without pain relief or with an improvement in pain of less than 2 months. Lumbar protrusion level discopathy on MRI corresponding to the level of pain. No interventional pain treatment was applied within the last 3 months and patients needed a pain score equal or greater than 4 on the visual analogic scale (VAS).

Exclusion criteria were as follows: patients with motor deficits, systemic infection, coagulation disorders, pregnancy, VAS pain score lower than 4, no pre-procedure MRI, and those who did not benefit from follow-up consultations.

2.3. Procedural technique

Intravenous analgesia was administered during the procedure (paracetamol 1 g ± tramadol), and MEOPA (nitrogen monoxide-oxygen mixture) was given if necessary.

The procedure was completed under strictly sterile conditions (without prophylactic antibiotics⁶) under computed tomographic guidance (CT GE light speed 2009 classe 3).

The patient was positioned in ventral decubitus in the CT-scan room. After local anaesthesia (Lidocaine 2% 5 ml), a posterior-lateral approach was employed. The side of approach corresponded to the side of maximal pain as described by the patient.

The ozone-oxygen mixture was produced in real time by a medical ozone generator (Ozo2futura; Alnitec). High-pressure pure medical oxygen cylinders were used to transform O₂ in O₃, and a Millipore bacteriological filter was placed between the syringe and the generator.

When the tip of the needle (Orgapix, size 22 gauges, 20 cm) reached the centre of the nucleus pulposus, 4–7 ml of gas mixture (30 micrograms/ml concentration) was injected (Fig. 1).

A CT scan confirmed the diffusion of gas into the disc and the herniation.

No corticosteroids or local anaesthetic were injected into the disc or epidural space during the procedure.

The mean time to complete the procedure was approximately 25 min.

The patient was kept for overnight observation and discharged the next morning. Return to work was permitted. The ozone-oxygen mixture was produced in real time by a medical ozone generator (Ozo2futura; Alnitec). High-pressure pure medical oxygen cylinders were used to transform O₂ in O₃, and a Millipore bacteriological filter was placed between the syringe and the generator.

When the tip of the needle (Orgapix, size 22 gauges, 20 cm) reached the centre of the nucleus pulposus, 4–7 ml of gas mixture (30 micrograms/ml concentration) was injected (Fig. 1).

A CT scan confirmed the diffusion of gas into the disc and the herniation.

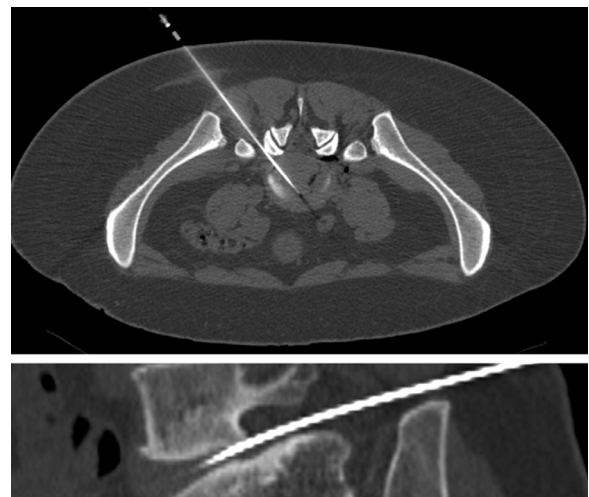

Fig. 1. CT-Guided procedure. Axial (upper) and sagittal (lower) cross-sectional scannographic acquisitions showing the position of the needle in the centre of the disc and the gas diffusion after oxygen-ozone mixture injection.

The mean time to complete the procedure was approximately 25 min.

The patient was kept for overnight observation and discharged the next morning. Return to work was permitted 7 days after the procedure.

2.4. Outcome measures

2.4.1. Clinical data

First consultation was performed one month prior to the procedure, the second consultation (including MRI) between 5 and 12 weeks after the procedure (on average 8 weeks) and the third consultation was conducted between 11 and 15 months after the procedure (on average 13 months).

At each consultation, patients were evaluated for pain using the visual analogue scale (VAS). The patient's age, gender, initial symptomatology (lumbar, root or mixed pain) and a history of epidural and/or posterior joint corticosteroid infiltration, other minimally invasive methods or lumbar surgery were noted at the initial consultation.

During the first consultation we identified radiological disc anomalies, such as a herniated disc, that may explain low back pain with or without root pain, to select patients eligible for the procedure. Then we informed them of the principles of the treatment and explain the benefits sought and the risks (e.g., haematoma, infection, compression). The treatment was considered effective if there was a decrease in the VAS score greater than or equal to 3 points at the 2-month consultation.

At the one-year consultation, the patients completed the modified MacNab questionnaire (Appendix 1) to assess the effectiveness of the treatment.⁷

2.4.2. Radiological data

Two MRI examinations were performed, first, prior to the procedure (less than one month before procedure), and second from 2 months after procedure. No additional MRI was performed at the 12 months follow-up.

The MRIs were performed on 1.5 or 1 T devices (PHILIPS Achieva 1.5T 2004, PHILIPS Ingenia 1.5 T omega 2015, PHILIPS Panorama HFO 1T 2013) with usual spine sequences (sagittal T1-, T2-, STIR-weighted images, and axial T2 weighted).

Two radiologists, a junior with 4 years of experience (CS) and a senior with 10 years of experience (DG) reviewed the initial and 2-month follow-up MRI images in consensus. They were blinded to the initial pre-procedure MRI.

We analysed the following criteria:

- The modification of the surfaces of the disc and of the herniated disc: in the axial plane, we contoured the disc with the ROI (region of interest) tool to obtain its surface. We did the same for the hernia.
- The variations in disc height according to the disc height index (DHI)⁸
- The following initial radiological characteristics:
 - The type of disc herniation: bulging, protrusion, extrusion
 - The location of disc herniation: postero-median, postero-lateral, foraminal, extra-foraminal
 - The contact or compression on the nerve root
 - The endplate changes according to the Modic classification⁹
 - The severity of disc degeneration according to the Pfirrmann's classification¹⁰
 - The presence or absence of calcifications in the disc herniation
 - The presence of a high-intensity zone (HIZ) defined as high-intensity signal located in the substance of the posterior annulus fibrosus.¹¹

2.5. Statistical analysis

First, we described the population included using means and standard deviations (or medians and interquartile ranges) for quantitative data and using numbers and percentages for qualitative data.

Then, we compared subjects whose decrease was greater than or equal to 3 points at 2 months with other subjects by performing univariate statistical analyses: chi-square or Fisher's exact test for percentage comparisons and means (or nonparametric) Mann-Whitney U tests for quantitative variables. Statistical significance was maintained at the alpha threshold of 5%. Statistical analyses were performed with SPSS V20 software.

3. Results

3.1. Description of the population

Between 2018 and 2019, 22 patients received intradiscal oxygen-ozone therapy, with a total of 27 injections.

We excluded a man and a woman (the first had two discs levels treated at the same time) because they did not participate in the second and the third consultations.

In total, 20 patients, 12 men and 8 women aged 26 to 80 years (mean age = 47 years), were included, representing 24 injections: two patients were treated at 2 levels at the same time, 2 patients at 2 levels at 1-year intervals.

All patients received epidural steroid injection (Hydrocortancyl 2.5%) in the last past year. 10 patients had no pain improvement. The 10 other patients had an improvement between 2 days and 2 months (mean= 3 weeks).

Table 1 shows the initial clinical characteristics of the patients. Most of them had been in pain for less than a year (but more than six months). The most frequently treated levels were L4-L5 (N = 9) and L5-S1 (N = 11), followed equally by L2-L3 (N = 2) and L3-L4 (N = 2).

3.2. Clinical results

The mean VAS score before the procedure was 7.95. The mean VAS score was 3.9 at two months and 2.95 at one year.

On average, VAS scores decreased by 4 points at two months and by 4.9 points at one year ($p < 0.0001$) (Fig. 2).

A decrease of 3 points or more was observed in 81.8% of patients at 2 months and 86.3% of patients at 12 months.

No complications related to intradiscal injection of oxygen-ozone injection were identified, sooner or later (up to one year). Sometimes, during the injection, we could see a leak of O2-O3 in the epidural veins, without clinical impact.

In the twenty patients included in the study, the success rate, according to the modified MacNab criteria was 65%, with 20% (N = 4)

Table 1
Initial characteristics of patients: initial symptomatology, duration of symptoms and previous treatments.

		Number	%
Sex	Female	10	42
	Male	14	58
Initial symptomatology	Lumbar pain	5	21
	Lumboradicular pain	13	54
	Radicular pain	6	25
Duration of symptoms	Less than one year but more than 6 months	16	67
	More than one year	8	33
Previous treatments	Epidural steroid injection	24	100
	Facet joint steroid injection	2	8
	Intradiscal injection of discogel®	1	4
	Spinal surgery	1	4

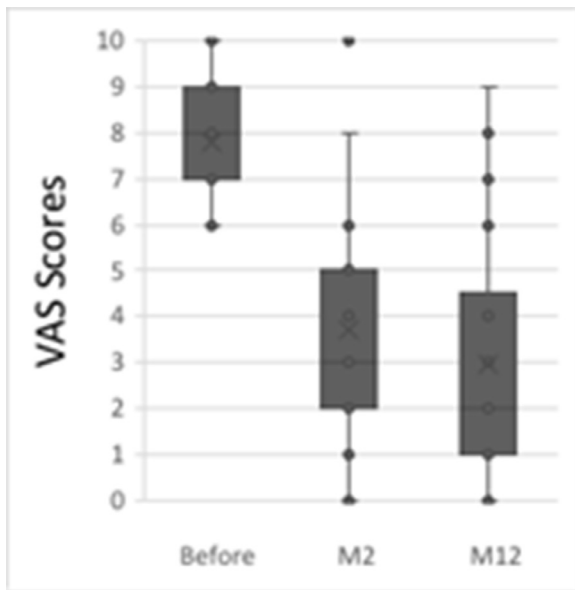


Fig. 2. Box plot of visual analogue scale (VAS) score data recorded before the procedure, at 2 months (M2) and at 12 months (M12) after the intervention. The scale is expressed in points and varies from 0 to 10. The lower limit corresponds to the absence of pain, and the upper limit corresponds to the maximum degree of pain.

excellent responses, 25% ($N = 5$) good responses and 20% ($N = 4$) satisfactory responses. The failure rate of 35% was mainly due to 30% poor responses ($N = 6$), and to 5% incorrect response rate ($N = 1$). amongst the failure of the treatment, the surgery rate was 15% at one year, representing 3 patients at 4, 6 and 11 months respectively after the procedure. These patients had lumbar radicular pain ($N = 2$) and radicular pain ($N = 1$), respectively.

No perioperative difficulties were reported by the surgeons. No adhesions between soft tissue and bone structures were unexpectedly discovered, contrary to what was reported in the study by Vanni et al. after intraforaminal ozone injections.¹²

3.3. Radiological results

At two months, herniation disc surfaces decreased significantly in 75% of cases: the mean reduction was approximately 20% (Table 2, Fig. 3).

Disc surfaces and disc height, according to the DHI, tended to decrease, but without statistical significance (Table 2).

3.4. Correlations with treatment effectiveness

We found significant correlations between clinical efficacy and sex, initial type of symptomatology and initial duration of symptoms (Table 3).

Indeed, all men (100%) had a significant improvement in pain compared to only half of women (50%).

Treatment was more effective in patients with radicular pain: 100% for isolated radicular pain, 92.3% for mixed lumbar and radicular pain, and 0% for isolated low back pain ($p = 0,003$).

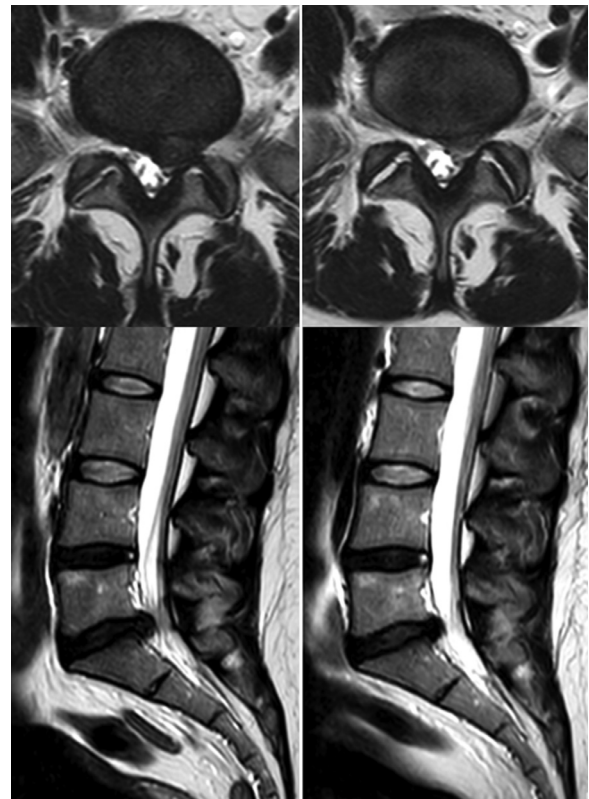

Fig. 3. MRI images before and after oxygen ozone treatment. The figures on the left show TW2 images in axial and sagittal sections in a patient with a left median L5-S1 disc protrusion compressing the left nerve root S1. The figures on the right show the control images at 2 months in this same patient after the intradiscal injection of the oxygen-ozone mixture, with a marked decrease in the size of the herniation.

Finally, treatment was more effective if the pain lasted less than one year (100%) than if it lasted more than one year (50%) ($p = 0,046$).

We found no significant differences by age or initial radiological parameters (Table 3).

According to the modified MacNab criteria, intra-discal O_2-O_3 therapy was successful for all the patients with extra-foraminal ($N = 2$) and median hernia ($N = 1$), for 2 of the 3 patients who had a foraminal hernia, and for 8 of the 14 patients who had a postero-lateral hernia.

However, we noted that all patients with calcified disc herniation responded well to the treatment (100% versus 77,8% if there were no calcifications in the herniated disc, $p = 0,99$). We did not find any significant correlation between pain improvement and the reduction in disc surfaces or disc height.

4. Discussion

4.1. Clinical efficiency

The natural history of disc herniation symptoms is to disappear over time. However, for some patients, the pain is too intense and/or

Table 2
Surface variations of discs and herniations, and disc height index variations at 2 months.

	Mean difference		Median	S.D.	Min	Max	Decreasing		Increasing		Significance (p value)
	mm ²	%					%	N	%	N	
Herniation	-16,7	-19,97	-14	26,3	-81	36	75	15	25	5	0,008
Disc	-15,67	-1,17	-9,5	69,3	-211	81	54,2	13	45,8	11	0,203
Disc index	Mean difference						Decreasing		Increasing		Significance (p value)
DHI	-0,0129						54,2	13	45,8	11	0,548

Table 3

Correlations between baseline clinical data and 2-month efficacy based on the decrease in VAS scores greater than or equal to 3 points.

		Number	Responding		No responding		p
			%	N	%	N	
Sex	Female	8	50	4	50	4	0,01*
	Male	14	100	14	0	0	
Initial symptomatology	Lumbar pain	3	0	0	100	3	0,003*
	Lomboradiculalgia	13	92,3	12	7,7	1	
	Radiculalgia	6	100	6	0	0	
Duration of symptoms	Less than one year	16	93,8	15	6,2	1	0,046*
	More than one year	6	50	3	50	3	

too prolonged, and more radical treatments can quickly improve the situation.

As we have shown in our study, oxygen-ozone therapy can accelerate the healing process in these patients, with a significant and prolonged decrease in the VAS scores at 2 months and even more at 12 months.

The efficiency of oxygen-ozone therapy has already been demonstrated by other studies, with a reduction of the VAS score in 62 to 93% of cases (mean 3.9 points).^{13,14}

65% of patients treated with oxygen-ozone had a successful outcome at one year follow-up, according to their McNab clinical outcome scores. This result compares favourably to studies assessing intra-discal ozone: Steppan et al.¹³ found in a metaanalysis a success rate of 79% (for all follow up dates) and Crockett et al.¹⁵ found a success rate at 68% at 6 months. Despite these encouraging results, in the literature and to date the intradiscal procedures are not recommended until rigorous controlled trials prove their efficacy.

Unlike most studies, we did not conduct concomitant epidural or foraminal injections of corticosteroids because all patients received treatment by corticosteroid infiltration with treatment failure. In the metaanalysis of Steppan et al.,¹³ in 9 out of 12 studies, intra-discal oxygen-ozone treatment was associated with a periradicular corticosteroid injection. Ezeldin and al.¹⁶ added a periradicular injection of the same O₂-O₃ mixture, steroid, and local anaesthetic. Therefore, in those studies, it is difficult to know if the clinical efficacy comes from ozone treatment or corticosteroid treatment. The study of Ercalik et al.¹⁶ is the only study that compares intra-discal O₂-O₃ therapy alone versus intra-discal O₂-O₃ therapy with perforaminal steroid injection. This randomized study demonstrated that intradiscal ozone injection alone was sufficient to treat low back pain and leg pain caused by LDH, and that perforaminal steroid injection does not provide additional benefit.

MacNab qualitative scale was designed to assess functional improvement. The subjectivity of the criteria constituting the modified MacNab scale as well as the lack of precision of the questions and answers may have been a limitation of our work. However, MacNab scale has been widely used in other studies in evaluation of patients' pain response and disability.⁵

Three patients underwent surgery. For one of them, the oxygen-ozone treatment had been temporarily efficient. For another, symptoms improvement was insufficient and for the last one, no pain relief was noticed. For this third patient, surgery remained ineffective. This rate was also found in other oxygen-ozone therapy studies (18%)¹³ and is similar to intradiscal laser (4.4–25%),¹⁷ nucleoplasty (18.7%),¹⁸ and chymopapain (5–30%)¹⁹ treatments. Therefore, oxygen-ozone therapy does not appear to be inferior to other minimally invasive methods.

This low rate seems acceptable, given the number of surgeries potentially avoided. Furthermore, intradiscal oxygen-ozone treatment procedure last 25 min and the price is very low compared to surgery. Finally, ozone does not preclude recourse to traditional surgery if it should fail. Indeed, the surgeons who took charge of the 3 patients did not report any difficulty during the surgery: they did not

find any adhesions between the soft tissues and bony structures, contrary to the article of Vanni et al.¹² No side effects were recorded at either short- or long-term follow-up (until one year). In the literature, the complication rate reaches 0,6%.¹³

Most complications are minor and transient. They consist of vagal discomfort during the procedure. We did not face this problem, probably because we slowly injected small volumes of gas and used subcutaneous analgesia.

The predominant serious complications described were infectious and more frequent at cervical stage.^{20–22} Ozone is a powerful oxidant and an excellent disinfectant. Antibiotic prophylaxis does not seem essential at the lumbar level⁶ and strict asepsis is sufficient.

Furthermore, the CT-guided injection allows to monitor the gas diffusion, and thus to avoid certain complications.

4.2. Radiological modifications

Disc-size reduction was not statistically significant in our study. In the literature, however, this result is quite unanimous,^{23–26} probably related to the dehydration properties of ozone on the disc. Nevertheless, the reduction does not seem to be significant until the 6th month.²⁷

Our early control (at two months) and our small number of patients may explain the lack of significant results.

However, most studies, such as ours, have found a significant size reduction of discs herniation (DH),^{17,28} except the study by Apuzzo et al.,²⁹ who found herniation size reduction in only 36% of cases.

Ozone, therefore, seems to have an effect first on disc herniation, probably by decreasing disc pressure with a reabsorption effect, and then on the entire disc in relation to disc dehydration. But even if disc herniation has persisted in patients for several months or years before oxygen-ozone therapy, it cannot be excluded that the decreased size of disc herniation wasn't due to the natural progression of disc herniation.

4.3. Correlations with efficiency

To compare the effectiveness of the treatment, according to the clinical and radiological parameters, we created 2 groups: the responding group if the VAS scores decreased by 3 points or more at 2 months and the nonresponding group if the scores decreased by fewer than 3 points. This three-point threshold seems to correspond to adequate pain control.³⁰

We found better efficiency on root symptoms, with or without low back pain, and resistance in the case of isolated low back pain.

Although it is recognized that radicular pain is a better clinical indication for O₂-O₃ therapy than low back pain,^{31,32} to our knowledge, no study has proven it to date.

Given these results, we wonder whether this treatment is useful in cases of isolated low back pain. The systematic review of Costa et al.⁵ confirm that little evidence is available on the effect of ozone injections in patient with low back pain due to lumbar disc herniation. Indeed, most low back pain is non-specific, and in case of

isolated low back pain, several lumbar structures are plausible sources of pain (eg, the intervertebral disc, the facet joints, the vertebral endplates), but clinical tests do not reliably attribute the pain to those structures.

Bryce et al. also found lower efficacy in women.³³ They used another minimally invasive therapy, electrothermal intradiscal therapy (IDET). We believe that independent parameters, such as psychological factors, and that more comprehensive management of pain should be implemented in women.³⁴⁻³⁶

The finding of better efficacy in our study if pain lasted from less than one year was discordant with the findings of Bonetti et al.²⁴: they showed that oxygen-ozone treatment remains effective when the pain was evolving for more than 2 years.

We did not find a significant correlation between the initial radiological parameters, including the changes in disc and herniation sizes.

Treatment was no more effective in mild and moderate disc degeneration than in severe disc degeneration, contrary to the findings of Perri et al.³⁷

No other studies have examined the issue of effectiveness in relation to Modic changes. For the other results, the previous studies were variable.

Muto et al.³⁸ did not find a correlation between disc-size reduction after oxygen-ozone nucleolysis and pain reduction, but Elawamy et al.²⁵ found a significant correlation between the percentage reduction in DH and the decrease in the VAS score.

Perri et al.³⁷ showed that extrusion and protrusion disc herniations had a better response than bulging disc herniations, but this result was contradictory to what Ghatge et al.'s study.³⁹ Amoretti et al.⁴⁰ was the only study that found that treatment was more effective if the disc herniation was posterolateral or foraminal than if it was posteromedian.

Moreover, several studies have shown that the presence of calcifications in the herniated discs was predictive of failure.^{38,41}

In our study, treatment was successful for the 4 patients with calcified disc herniation. These studies did not specify whether the herniated discs were very or slightly calcified and, in our series, they were very poorly calcified.

The association of ductal stenosis was identified as a potential bias by Lu et al.⁴¹

In any case, the presence of small calcifications in the herniated disc should not be considered as a treatment resistance factor.

4.4. Strengths and limitations

4.4.1. Strengths

In our study, patients were representative of the population that was eligible for this procedure. The inclusion criteria were broad, including patients ranging from 26 to 80 years in age with all types of disc herniations.

The patients benefited from the same protocol undertaken in the same centre by 2 trained operators. The ozone dose was consistent with the recommended optimal concentration.^{25,38}

In our opinion, scanner guidance is more secure, allowing for meticulous positioning of the needle and, thus, avoiding potential complications.⁴⁰ In addition, CT permits to avoid intradiscal contrast injection, which, even at low doses, reduces the discal absorption of ozone.⁴²

In contrast to many studies, we did not perform complementary epidural injections of corticosteroids, which could have resulted in the overestimation of efficiency in the literature.^{16,35,42-45}

4.4.2. Limitations

The small number of patients and treated discs were responsible for a lack of statistical power that could explain nonsignificant results.

Two patients received oxygen-ozone injections at 2 different levels during the same procedure. The effectiveness of the treatment was not differentiable from one level to another, and we had to take this into account in our statistical analysis.

5. Conclusion

In conclusion, our preliminary findings show that oxygen-ozone therapy in disc herniation realized under CT-scan guidance is safe and effective when conservative treatment and epidural or facet joint steroid injection failed to relieve pain.

O₂-O₃ therapy improves pain in most patients.

Based on your first results, we wonder whether this treatment should be reserved for patients with nerve root symptoms, rather than for those with only low back pain. We assume that the effectiveness of the treatment is both mechanical, related to a decrease in the pressure of the disc on the nerve root, whatever the location of the hernia, and chemical, linked to the anti-inflammatory properties of ozone.

Furthermore, we suggest that the presence of low calcifications in the disc herniation should not be a contraindication.

This treatment had no impact on any future spine surgery.

Intra-discal oxygen-ozone therapy is an easy and low cost procedure but it's not widely used in France.

These promising preliminary results have convinced us of the usefulness and the safety of this treatment, and we hope that it will be more widely used in our country.

Funding sources

This research did not receive any specific grant from funding agencies in the public, commercial, or not-for-profit sectors.

Declaration of Competing Interest

The authors declare that they have no competing interest.

CRediT authorship contribution statement

Clémentine Simon: Investigation, Data curation, Writing – original draft. **Thomas Le Corroller:** Methodology, Data curation. **Vanessa Pauly:** Conceptualization, Supervision. **Daphne Guenoun:** Conceptualization, Methodology, Validation, Writing – review & editing, Supervision.

Acknowledgement

The authors thank the Assistance Publique des Hôpitaux de Marseille (APHM).

Supplementary materials

Supplementary material associated with this article can be found in the online version at doi:10.1016/j.neurad.2021.09.004.

References

- Balagué F, Mannion AF, Pellisé F, Cedraschi C. Non-specific low back pain. *Lancet*. 2012;379(9814):482–491. [https://doi.org/10.1016/S0140-6736\(11\)60610-7](https://doi.org/10.1016/S0140-6736(11)60610-7).
- Hashemi M, Poorfarokh M, Mohajerani SA, et al. Injection of intradiscal O₂-O₃ to reduce pain and disability of patients with low back pain due to prolapsed lumbar disk. *Anesth Pain Med*. 2014;4(5):e19206. <https://doi.org/10.5812/aapm.19206>.
- Crock HV. Observations on the management of failed spinal operations. *Bone Jt Surg*. 1976;58-B:193–199.
- De Sèze M, Cugy E, Bassiri A. Traitements percutanés intra-discaux dans les lombosciatiques et les lombalgies. *Rev du Rhum Monogr*. 2013;80(4):247–251.
- Costa T, Linhares D, Ribeiro da Silva M, Neves N. Ozone therapy for low back pain. A systematic review. *Acta Reumatol Port*. 2018;43(3):172–181.

6. Wei CJ, Li YH, Chen Y, et al. Percutaneous intradiscal oxygen-ozone injection for lumbar disc herniation: no need of perioperative antibiotic prophylaxis. *South Med Univ*. 2007;27(3):384–386.
7. Muto M, Avella F. Percutaneous treatment of herniated lumbar disc by intradiscal oxygen-ozone injection. *Interv Neuroradiol*. 1998;4(4):279–286. <https://doi.org/10.1177/159101999800400403>.
8. Fyllos AH, Arvanitis DL, Karantanias AH, Varitimidis SE, Hantes M, Zibis AH. Magnetic resonance morphometry of the adult normal lumbar intervertebral space. *Surg Radiol Anat*. 2018;40(9):1055–1061. <https://doi.org/10.1007/s00276-018-2048-7>.
9. Modic MT, Steinberg PM, Ross JS, Masaryk TJ, Carter JR. Degenerative disk disease: assessment of changes in vertebral body marrow with MR imaging. *Radiology*. 1988;1:193–199. <https://doi.org/10.1148/radiology.166.1.3336678>.
10. Pfirrmann CW, Metzdorf A, Zanetti M, Hodler J, Boos N. Magnetic resonance classification of lumbar intervertebral disc degeneration. *Spine*. 2001;26(17):1873–1878. <https://doi.org/10.1097/00007632-200109010-00011>.
11. Lam KS, Carlin D, Mulholland RC. Lumbar disc high-intensity zone: the value and significance of provocative discography in the determination of the discogenic pain source. *Eur Spine J*. 2000;9(1):36–41. <https://doi.org/10.1007/s005860050006>.
12. Vanni D, Galzio R, Kazakova A, et al. Intraforaminal ozone therapy and particular side effects: preliminary results and early warning. *Acta Neurochir*. 2016;158(3):491–496. <https://doi.org/10.1007/s00701-015-2545-y>.
13. Steppan J, Meaders T, Muto M, Murphy KJ. A metaanalysis of the effectiveness and safety of ozone treatments for herniated lumbar discs. *J Vasc Interv Radiol*. 2010;21(4):534–548. <https://doi.org/10.1016/j.jvir.2009.12.393>.
14. Ercalik T, Kilic M. Efficacy of intradiscal ozone therapy with or without perforaminal steroid injection on lumbar disc herniation: a double-blinded controlled study. *Pain Physician*. 2020;23(5):477–484.
15. Crockett MT, Moynagh M, Long N, et al. Ozone-augmented percutaneous discectomy: a novel treatment option for refractory discogenic sciatica. *Clin Radiol*. 2014;69(12):1280–1286. <https://doi.org/10.1016/j.crad.2014.08.008>.
16. Ezeldin M, Leonardi M, Princiotta C, et al. Percutaneous ozone nucleolysis for lumbar disc herniation. *Neuroradiology*. 2018;60(11):1231–1241. <https://doi.org/10.1007/s00234-018-2083-4>.
17. Schenk B, Brouwer PA, Peul WC, van Buchem MA. Percutaneous laser disk decompression: a review of the literature. *Am J Neuroradiol*. 2006;27(1):232–235.
18. Klessinger S. The frequency of resurgery after lumbar disc Nucleoplasty in a ten-year period. *Clin Neurol Neurosurg*. 2018;170:79–83. <https://doi.org/10.1016/j.clin-neuro.2018.05.004>.
19. Runge M. La chimionucléolyse. *Ann Kinésithér Masson Paris*. 1987:431–437.
20. Andrés-Cano P, Vela T, Cano C, García G, Vera JC, Andrés-García JA. Cervical spondylodiscitis after oxygen-ozone therapy for treatment of a cervical disc herniation: a case report and review of the literature. *HSS J*. 2016;12(3):278–283. <https://doi.org/10.1007/s11420-016-9500-1>.
21. Bo W, Longyi C, Jian T, et al. A pyogenic discitis at c3-c4 with associated ventral epidural abscess involving c1-c4 after intradiscal oxygen-ozone chemonucleolysis: a case report. *Spine*. 2009;34(8):298–304. <https://doi.org/10.1097/BRS.0b013e318195a87e.22>.
22. Yang CS, Zhang LJ, Sun ZH, Yang L, Shi FD. Acute prevertebral abscess secondary to intradiscal oxygen-ozone chemonucleolysis for treatment of a cervical disc herniation. *J Int Med Res*. 2018;46(6):2461–2465. <https://doi.org/10.1177/0300060518764186>.
23. Lehnert T, Naguib NN, Wutzler S, et al. Analysis of disk volume before and after CT-guided intradiscal and periganglionic ozone-oxygen injection for the treatment of lumbar disc herniation. *J Vasc Interv Radiol*. 2012;23(11):1430–1436. <https://doi.org/10.1016/j.jvir.2012.07.029>.
24. Bonetti M, Zambello A, Leonardi M, Princiotta. Herniated disks unchanged over time: size reduced after oxygen-ozone therapy. *Interv Neuroradiol*. 2016;22(4):466–472. <https://doi.org/10.1177/1591019916637356>.
25. Elawamy A, Kamel EZ, Hassanien M, Wahba OM, Amin SE. Implication of two different doses of intradiscal ozone-oxygen injection upon the pain alleviation in patients with low back pain: a randomized, single-blind study. *Pain Physician*. 2018;21(1):25–31.
26. Bruno F, Smaldone F, Varrassi M, et al. MRI findings in lumbar spine following O₂-O₃ chemiodiscolysis: a long-term follow-up. *Interv Neuroradiol*. 2017;23(4):444–450. <https://doi.org/10.1177/1591019917703784>.
27. Splendiani A, Perri M, Conchiglia A, et al. MR assessment of lumbar disk herniation treated with oxygen-ozone diskolysis: the role of DWI and related ADC versus intervertebral disk volumetric analysis for detecting treatment response. *Neuroradiol J*. 2013;26(3):347–356. <https://doi.org/10.1177/197140091302600316>.
28. Buric J, Rigobello L, Hooper D. Five and ten year follow-up on intradiscal ozone injection for disc herniation. *Int J Spine Surg*. 2014;8:17. <https://doi.org/10.14444/1017>.
29. Apuzzo D, Giotti C, Pasqualetti P, Ferrazza P, Soldati P, Zucco GM. An observational retrospective/horizontal study to compare oxygen-ozone therapy and/or global postural re-education in complicated chronic low back pain. *Funct Neurol*. 2014;29(1):31–39.
30. Lee JS, Hobden E, Stiell IG, Wells GA. Clinically important change in the visual analog scale after adequate pain control. *Acad Emerg Med*. 2003;10(10):1128–1130. <https://doi.org/10.1111/j.1553-2712.2003.tb00586.x>.
31. Muto M, Giurazza F, Silva RP, Guarnieri G. Rational approach, technique and selection criteria treating lumbar disk herniations by oxygen-ozone therapy. *Interv Neuroradiol*. 2016;22(6):736–740. <https://doi.org/10.1111/j.1553-2712.2003.tb00586.x>.
32. Lutze M, Stendel R, Vesper J, Brock M. Periradicular therapy in lumbar radicular syndromes: methodology and results. *Acta Neurochir*. 1997;139(8):719–724. <https://doi.org/10.1007/BF01420044>.
33. Bryce DA, Nelson J, Glurich I, Berg RL. Intradiscal electrothermal annuloplasty therapy: a case series study leading to new considerations. *Wmj*. 2005;104(6):39–46.
34. Oder B, Loewe M, Reisegger M, Lang W, Ilias W, Thurnher SA. CT-guided ozone/steroid therapy for the treatment of degenerative spinal disease - Effect of age, gender, disc pathology and multi-segmental changes. *Neuroradiology*. 2008;50(9):777–785. <https://doi.org/10.1007/s00234-008-0398-2>.
35. Enthoven P, Skargren E, Carstensen J, Oberg B. Predictive factors for 1-year and 5-year outcome for disability in a working population of patients with low back pain treated in primary care. *Pain*. 2006;122(1–2):137–144. <https://doi.org/10.1016/j.pain.2006.01.022>.
36. Alcouffe J, Manillier P, Brehier M, Fabin C, Faupin F. Analysis by sex of low back pain among workers from small companies in the Paris area: severity and occupational consequences. *Occup Environ Med*. 1999;56(10):696–701. <https://doi.org/10.1136/oem.56.10.696>.
37. Perri M, Marsecano C, Varrassi M, Giordano AV, Splendiani A, di Cesare E. Indications and efficacy of O₂-O₃ intradiscal versus steroid intraforaminal injection in different types of disc vertebral pathologies: a prospective randomized double blind trial with 517 patients. *Radiol Medica*. 2016;121(6):463–471. <https://doi.org/10.1007/s11547-015-0598-x>.
38. Muto M, Andreula C, Leonardi M. Treatment of herniated lumbar disc by intradiscal and intraforaminal oxygen-ozone (O₂-O₃) injection. *J Neuroradiol*. 2004;31:183–189. [https://doi.org/10.1016/s0150-9861\(04\)96989-1](https://doi.org/10.1016/s0150-9861(04)96989-1).
39. Ghatge S, Modi PD, Modi DB. Clinical and radiological improvement following ozone disc nucleolysis: a case report. *Cureus*. 2017;9(4):e1162. <https://doi.org/10.7759/cureus.1162>.
40. Amoretti N, Hauger O, Marcy PY, Amoretti ME, Lesbats V, Yvonne M. Percutaneous discectomy on lumbar radiculopathy related to disk herniation: why under CT guidance? An open study of 100 consecutive patients. *Eur J Radiol*. 2012;81(6):1259–1264. <https://doi.org/10.1016/j.ejrad.2011.02.071.41>.
41. Lu W, Li Y-H, He X-F. Treatment of large lumbar disc herniation with percutaneous ozone injection via the posterior-lateral route and inner margin of the facet joint. *World J Radiol*. 2010;2(3):109–112. <https://doi.org/10.4329/wjr.v2.i3.109>.
42. Andreula C. Ozone therapy. *Neuroradiology*. 2011;53(S1):207–209. <https://doi.org/10.1007/s00234-011-0930-7.43>.
43. Perri M, Grattacaso G, Di Tunno V, Marsecano C, Di Cesare E, Splendiani A. MRI DWI/ADC signal predicts shrinkage of lumbar disc herniation after O₂-O₃ discolysis. *Neuroradiol J*. 2015;28(2):198–204. <https://doi.org/10.1177/1971400915576658>.
44. Gallucci M, Limbucci N, Zugaro L, et al. Sciatica: treatment with intradiscal and intraforaminal injections of steroid and oxygen-ozone versus steroid only. *Radiology*. 2007;242(3):907–913. <https://doi.org/10.1148/radiol.2423051934>.
45. Zhang Y, Ma Y, Jiang J, Ding T, Wang J. Treatment of the lumbar disc herniation with intradiscal and intraforaminal injection of oxygen-ozone. *J Back Musculoskelet Rehabil*. 2013;26(3):317–322. <https://doi.org/10.3233/BMR-130386>.