



**HAL**  
open science

## The torsion of the proximal femur in cementless total hip arthroplasty: a 3-dimensional evaluation

Michael Wettstein, Elyazid Mouhsine, Jean-Manuel Aubaniac, Laurent Audigé, Matthieu Ollivier, Pierre-François Leyvraz, Jean-Noël Argenson

### ► To cite this version:

Michael Wettstein, Elyazid Mouhsine, Jean-Manuel Aubaniac, Laurent Audigé, Matthieu Ollivier, et al.. The torsion of the proximal femur in cementless total hip arthroplasty: a 3-dimensional evaluation. Hip International, 2023, 33 (2), 10.1177/11207000211037196 . hal-03553753

**HAL Id: hal-03553753**

**<https://hal.science/hal-03553753>**

Submitted on 14 Apr 2023

**HAL** is a multi-disciplinary open access archive for the deposit and dissemination of scientific research documents, whether they are published or not. The documents may come from teaching and research institutions in France or abroad, or from public or private research centers.

L'archive ouverte pluridisciplinaire **HAL**, est destinée au dépôt et à la diffusion de documents scientifiques de niveau recherche, publiés ou non, émanant des établissements d'enseignement et de recherche français ou étrangers, des laboratoires publics ou privés.



Distributed under a Creative Commons Attribution - NonCommercial 4.0 International License

# The torsion of the proximal femur in cementless total hip arthroplasty: a 3-dimensional evaluation

Michael Wettstein<sup>1,2,3</sup>, Elyazid Mouhsine<sup>1,2,3</sup>,  
Jean-Manuel Aubaniac<sup>4</sup>, Laurent Audigé<sup>5</sup>, Matthieu Ollivier<sup>4</sup>,  
Pierre-François Leyvraz<sup>3</sup> and Jean-Noël Argenson<sup>4</sup>

## Abstract

**Introduction:** The anatomy of the proximal femur at the time of total hip arthroplasty has been widely studied but the horizontal plane was never considered, or only limited to the torsion of the femoral neck.

**Methods:** Using CT-scan images from a group of 178 patients scheduled for cementless total hip arthroplasty (THA), we analysed the evolution of the torsion of the proximal femoral metaphysis, in reference to the posterior bicondylar plane of the femur. The evolution of the torsion, between 20 mm below the centre of the lesser trochanter and 20 mm above, was evaluated.

**Results:** In cases of primary osteoarthritis, osteonecrosis, rheumatoid arthritis and epiphysiolysis capitis femoris, the mean torsion decreased from 46° to 20° without significant differences in average values between the different diagnoses, but important individual variations were found. In the groups of dysplasia and congenital hip dislocation, the torsion values were significantly higher, decreasing in mean from 59° to 25° and 63° to 34° respectively, and with important individual variations.

**Conclusions:** These data are important when using cementless femoral stems, since an ideal fit-and-fill in the proximal femur zone has been shown to positively influence bone ingrowth of the stem. However, a strict adaptation of the stem to the medullary canal, without considering its torsion, can lead to an increased or decreased torsion of the prosthesis neck and thus to an instability of the arthroplasty. For these reasons, if a perfect adaptation of the stem to the intramedullary anatomy and an optimal reconstruction of the extramedullary anatomy are to be achieved, 3-dimensional planning should ideally be obtained for every patient. This will allow the best stem choice adapted to every single patient and every kind of anatomy.

## Keywords

Anatomy, arthroplasty, cementless, femur, helitortion, hip, torsion

## Introduction

The anatomy of the proximal femur has been widely studied, aiming to standardise the conception of cementless femoral stems. Noble et al.,<sup>1</sup> Rubin et al.<sup>2</sup> and Laine et al.<sup>3</sup> showed that the anatomy of the proximal femur can be divided into intramedullary and extramedullary parts.

The extramedullary anatomy of the femur sets the position of the hip centre, depending on neck length, frontal offset, CCD angle (Centre – Colum - Diaphyseal) and neck anteversion. Despite the clinical importance of this extramedullary part,<sup>4-8</sup> the present study will focus mainly on the intramedullary anatomy, with consequences on neck anteversion.

---

<sup>1</sup>Institute of Traumatology and Orthopaedics of Lake Geneva Switzerland (ITOLS), SMN Clinique de Genolier, Genolier, Switzerland

<sup>2</sup>Hospital Riviera-Chablais (HRC) Vaud Valais, Hospital of Rennaz, Rennaz, Switzerland

<sup>3</sup>Orthopaedic and Traumatology Service, Locomotor Department of Musculoskeletal System, Lausanne University Hospital, Lausanne, Switzerland

<sup>4</sup>Institute for Locomotion, Department of Orthopaedics and Traumatology, Sainte-Marguerite Hospital, Aix-Marseille University, Marseille, France

<sup>5</sup>Research Group Upper Extremity, Schulthess Klinik, Zürich, Switzerland

### Corresponding author:

Michael Wettstein, ITOLS, Clinique de Genolier, Route du Muids 3, Genolier, Vaud CH-1272, Switzerland.

Email: m.wettstein@itols.ch

**Table 1.** Distribution of gender, side and age according to diagnosis.

Diagnosis	Gender	Side	Mean age (years)
Primary osteoarthritis	55 men, 45 women	52 right, 48 left	60.5 ± 12.5 (30–84)
Dysplasia	6 men, 14 women	12 right, 8 left	53.9 ± 17.2 (23–78)
Congenital dislocation of the hip	6 men, 14 women	11 right, 9 left	57.8 ± 13.9 (27–78)
Aseptic osteonecrosis of femoral head	15 men, 5 women	9 right, 11 left	55.4 ± 16.1 (32–80)
Rheumatoid polyarthritis	5 men, 4 women	6 right, 3 left	63.5 ± 11.3 (47–77)
Epiphysiolysis capitis femoris	6 men, 3 women	5 right, 4 left	55.3 ± 12.7 (35–70)

In an anatomic study of 200 cadaveric femurs, Noble et al.<sup>1</sup> defined canal flare index as the width of the canal 20 mm above the lesser trochanter divided by the width at the level of the isthmus, finding 83% normal, 9% called stove-pipe (large canal) and 8% champagne-fluted (narrow canal).

Rubin et al.<sup>2</sup> showed the same anatomic variations of the proximal femur in the frontal plane, highlighting that a standard radiological analysis was insufficient and recommending an additional CT-scan.

Husmann et al.,<sup>9</sup> in a more recent CT-scan study, showed that the variations in shape described by Noble et al.<sup>1</sup> do not only occur in the frontal plane but also in the sagittal plane. When considering canal flare index in both planes they only found 30% of the femurs could be considered as normal.

In contrast with its frontal and sagittal shape, the geometry of the proximal femur in the horizontal plane is not well described, except for neck anteversion.<sup>10–14</sup> This anterior torsion of the femoral neck is defined as the angle between the posterior bicondylar plane and the axis of the femoral neck. According to Husmann et al.,<sup>9</sup> its mean value is  $24.7^\circ \pm 8.7^\circ$ .

Wilkinson,<sup>15</sup> and more recently Yu et al.,<sup>16</sup> have shown that anterior torsion does not only depend on the position of implantation of the femoral neck on the intertrochanteric region, but also on the torsion of the proximal femoral metaphysis.

Proximal femoral torsion is defined as the angle between the posterior femoral bicondylar plane and the axis of the femoral metaphysis at the level of osteotomy of the femoral neck for total hip arthroplasty (THA). According to Husmann et al.,<sup>9</sup> proximal femoral torsion, or helitortion, has no correlation with anterior torsion of the femoral neck and shows broad individual variations between  $8.3^\circ$  and  $44.9^\circ$ , with a mean value of  $24.0^\circ \pm 11.8^\circ$ .

However, the choice of the level of proximal femoral torsion corresponding to the level of osteotomy of the femoral neck during hip arthroplasty does not take into account the progression of metaphyseal torsion along the proximal femur. Furthermore, this could explain why anatomic and prosthetic antetorsion may not match, as mentioned by Sendtner et al.<sup>17</sup>

Because of the recent interest in metaphyseal fixation of cementless stems, particularly in so-called “anatomic designs”, a more precise knowledge of the evolution of proximal femoral torsion seems important. This should help with the design of cementless stems in THA for various anatomies and also allow a precise adaptation of the stem to the intramedullary anatomy of each patient when needed, in order to achieve an optimal fit-and-fill.<sup>18–20</sup>

Our hypothesis was that the femoral torsion progressively changes along the proximal femoral diaphysis and metaphysis and that its progression is highly individual. The goal of this study was to determine the mean values of proximal femur torsion at different levels of the metaphysis as well as its individual differences in various types of pathologic hips found at the time of THA.

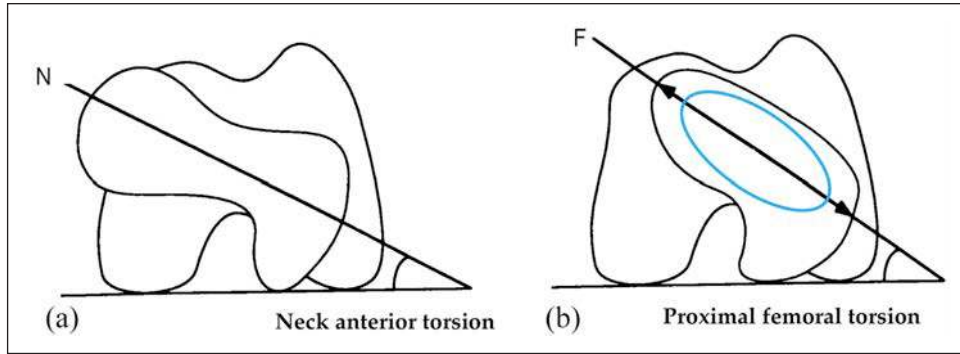
## Material and methods

A total of 178 patients scheduled for cementless THA and representing various etiologies were evaluated by X-rays and CT-scans using the same protocol. The X-rays consisted of A/P pelvis, both hips A/P and profile, as well as a telemetry view. CT-scans were carried out in 5 millimetre intervals from the top of the acetabulum to the femoral isthmus, 1 slice at the knee and 1 at the foot. Because the femur was not scanned along its complete length, it was not possible to relate the level of the slices to the relative length of the femur.

Table 1 shows the number of cases analysed for each diagnosis as well as sex and age distribution.

Primary hip osteoarthritis (OA), used as reference values, is defined as osteoarthritis with coxometry values within a normal range.<sup>21</sup> Dysplasia is defined as Wiberg<sup>22</sup> VCE (vertical centre-edge) angle  $<25^\circ$ , Tschauer AC (acetabular index) angle  $>10^\circ$  and Lequesne<sup>23</sup> ACE (anterior centre-edge) angle  $<25^\circ$ . We used the expression hip dysplasia for Crowe stage I, II and III and the expression congenital dislocation of the hip for Crowe et al.<sup>24</sup> stage IV.

A computer-assisted design program (Contouring, Symbios, Yverdon, Switzerland), was performed on CT-scan images for computer-assisted analysis.<sup>9,25</sup> The first step was to determine the axis of the posterior bicondylar plane, which was automatically reported on all



**Figure 1.** Measurement of anterior torsion: (a) at the level of the femoral neck (N) and proximal femoral torsion and (b) at the level of the proximal femoral metaphysis (F). The oval shape helps measuring the axis of the metaphysis.

images of the single series. This allowed for the measurement of the angle formed with the metaphyseal axis, represented by the long axis of an oval shape matching the inner contour of the bone at each selected level of the femur and representing the proximal femoral torsion angle (Figure 1).

After determining the midpoint of the lesser trochanter (LT) as a reference point, the levels of CT-scan images to be analysed were selected at 5 mm between 20 mm below LT and 20 mm above LT, and 1 slice at 30 mm above LT. 1 slice at the basis of the femoral neck and 1 slice at the level of the centre of the femoral head were used to measure neck torsion according to the technique described by Murphy et al.<sup>26</sup>

The lowest level of measure at 20 mm below LT was chosen because most cases showed an almost round shape of the femoral canal beneath, thus not allowing a precise measure of proximal femoral torsion.

25 randomly selected cases were blinded and analysed by 2 experienced observers, twice, and 2 days apart, to verify the accuracy of the measures.

All results were recorded as angular values (degrees) with mean and extreme values as well as  $\pm 1$  SD (standard deviation) indicated.

Statistical analysis was done with Stata (StataCorp LLC, College Station, TX, USA), using the 2-sample *t*-test with equal variances. Significance was defined as *p*-value  $< 0.05$ .

This study protocol was accepted by the ethical committee of the Faculty of Biology and Medicine of Lausanne University (Switzerland).

## Results

A group of 178 files representing 100 men and 78 women (93 right and 85 left hips) with a mean age of  $59 \pm 14$  years (23–84 years) were analysed. We found no significant differences between the groups in means of gender, side or age.

The 25 files which were analysed twice showed a SD of torsion angle of  $\pm 2^\circ$ , not considered as significant

( $p > 0.05$ ), and in accordance with similar analyses.<sup>27</sup> Intra- and inter-observer correlation ranging from 0.95 to 0.91 was considered excellent.

The mean foot progression angle showed no statistically significant difference across all groups, meaning that no torsional leg deformity was present below the knee.

Figure 2 shows the results of mean proximal femoral torsion with maxima and minima in the different groups of pathologies, including the neck angle. Mean femoral torsion in primary OA decreased from  $46.1 \pm 12^\circ$  at  $-20$  mm to  $19 \pm 7.8^\circ$  at  $+20$  mm from LT, with important individual variations at each level. Mean anterior femoral neck torsion was  $10.8 \pm 8.5^\circ$ , varying between  $3.1^\circ$  and  $19.5^\circ$ .

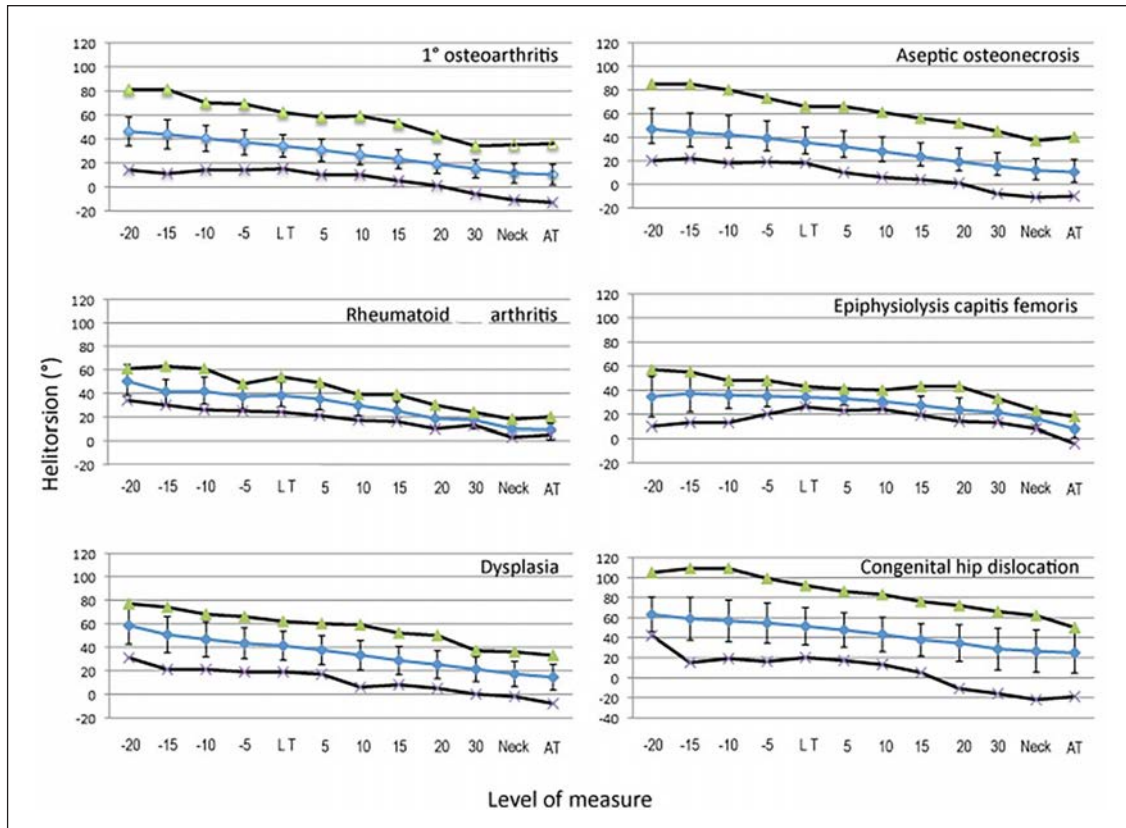
This group was divided into 2 subgroups, 1 with 56 patients  $< 65$  years and the other with 44 patients  $> 65$  years. There was no significant difference in proximal femoral torsion between the 2 groups at each measured level ( $p > 0.05$ ), meaning that torsion does not vary with the age of the patient.

In the femoral head osteonecrosis group, proximal femoral torsion decreased from  $46.8 \pm 17.5^\circ$  at  $-20$  mm to  $19.1 \pm 11.7^\circ$  at  $+20$  mm and in the rheumatoid arthritis group from  $50.3 \pm 14.4^\circ$  at  $-20$  mm to  $18.6 \pm 7.2^\circ$  at  $+20$  mm.

The epiphysiolysis capitis femoris group had a proximal femoral torsion decreasing from  $36.6 \pm 16.8^\circ$  at  $-20$  mm to  $23.6 \pm 9.9^\circ$  at  $+20$  mm. In contrast with all other groups, we found an important difference of anterior torsion between the level of the femoral neck basis (mean  $16.3^\circ$ ) and the femoral head level (mean  $7.9^\circ$ ) explained by the epiphyseal origin of this disease.

No statistically significant difference was found between the proximal femoral torsion values of the reference group of primary OA and the groups of osteonecrosis, rheumatoid arthritis and epiphysiolysis capitis femoris ( $p > 0.05$ ).

When comparing the proximal femoral torsion at the level of neck osteotomy to the ideal anterior torsion of a prosthetic femoral neck of  $15^\circ$ , we found that 50% of the cases were within a range of  $\pm 5^\circ$  and 50% were outside this range for all pathologies.



**Figure 2.** Mean, minimal and maximal femoral torsion at several levels in all diagnostic groups.

Proximal femoral torsion of the dysplasia group decreased from  $58.4 \pm 15.8^\circ$  at  $-20$  mm to  $25.2 \pm 12^\circ$  at  $+20$  mm. The mean anterior torsion of the femoral neck in this group was the same as in the reference group, with a mean value of  $14.4 \pm 11^\circ$ .

Finally, the group of congenital dislocation of the hip had a proximal femoral torsion decreasing from  $63.1 \pm 17.2^\circ$  at  $-20$  mm to  $34.4 \pm 18.3^\circ$  at  $+20$  mm. In this group, anterior neck torsion was significantly higher than in the reference group, with a mean value of  $24.8 \pm 20.1^\circ$  ( $p < 0.05$ ).

The proximal femoral torsion in the groups of dysplasia and congenital dislocation was significantly different at each level compared to the reference group especially for congenital dislocation ( $p = 0.02$  compared to  $p = 0.002$ ).

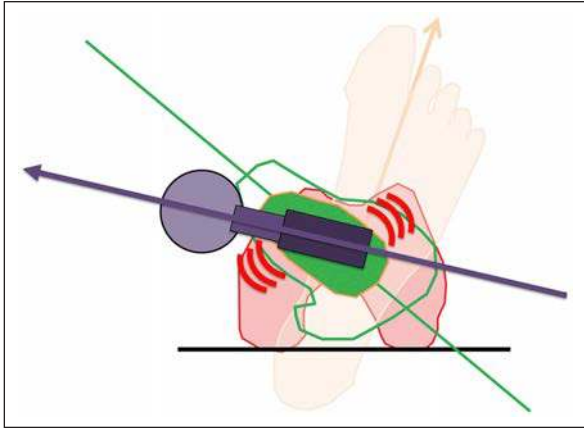
When we compared proximal femoral torsion at the level of osteotomy of the femoral neck to an ideal anterior torsion of  $15^\circ$  of a prosthetic femoral neck, we only found 20% of the dysplasia and 5% of the congenital dislocation cases within a range of  $\pm 5^\circ$ .

## Discussion

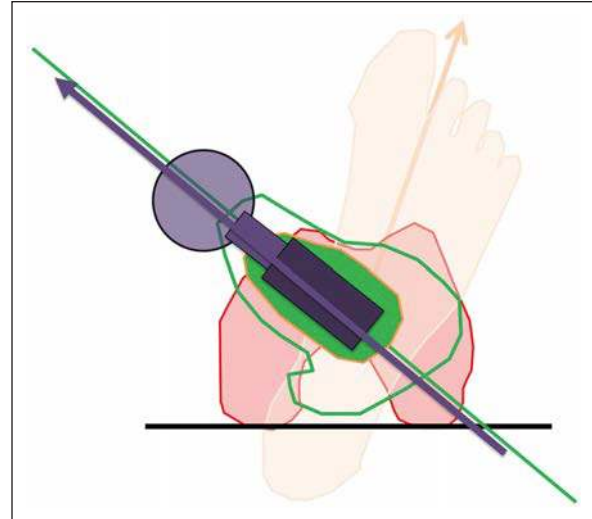
The anatomy of the proximal femur is more sophisticated than often reported and outlined by only a few previous articles.<sup>1,2,9</sup> The anatomic variations of the femur have

been described in terms of length and anteversion of the femoral neck, as well as inclination (CCD angle). Intramedullary anatomy has shown large individual variations of shape, in the frontal and the sagittal planes.<sup>1,2,9</sup> Proximal femoral torsion, defined as the torsion of the upper femur useful for THA, was first reported by Husmann et al.<sup>9</sup> They only reported a value of torsion at the level of osteotomy of the femoral neck, but they did not take into account the progression of the torsion along the metaphysis. The present study has shown that torsion was located in the whole proximal femur, beginning at approximately 20 mm under the midpoint of the lesser trochanter. Our preliminary hypothesis that proximal femoral torsion changes progressively along with the proximal femoral metaphysis was verified in all studied groups of different hip diseases leading to THA.

No difference in terms of proximal femoral torsion was found in our study between younger and older patients in the group of primary OA. Noble et al.<sup>28</sup> also found no difference in male femora, but found significant differences in female femora, which may be explained by osteoporosis decreasing bone-density, possibly influencing the frontal and sagittal shape of the femur, but not affecting the horizontal plane, namely the proximal femoral torsion. In their study, Husmann et al.<sup>9</sup> found no significant difference between the mean value of proximal femoral torsion ( $24.0^\circ \pm 11.8^\circ$ ) and



**Figure 3.** If a rectangular stem is not adapted to proximal femoral torsion (middle green line without arrow) but implanted so as to achieve the desired anterior torsion of the femoral neck (lower purple arrowed line), the edges of the implant will induce peak loads at the femoral cortex. Furthermore, the size of the implant must be decreased to adapt to the transverse shape of the medullary canal.



**Figure 4.** A stem which is implanted according to an increased proximal femoral torsion (middle green line without arrow) will induce an increased femoral neck anterior torsion (lower purple arrowed line).

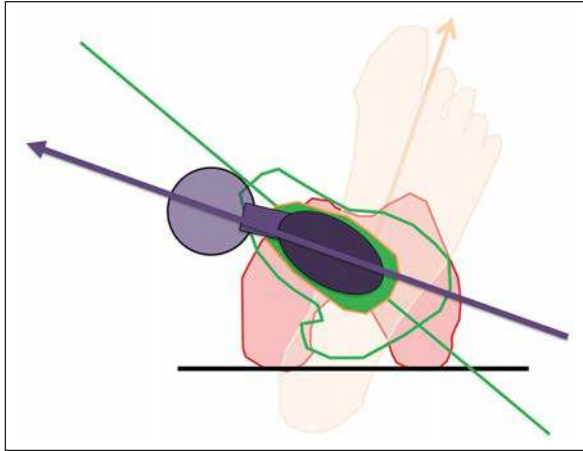
the mean value of anterior torsion of the neck ( $24.7^\circ \pm 8.7^\circ$ ) in patients with primary OA of the hip, despite broad variation of proximal femoral torsion between  $8.3^\circ$  and  $44.9^\circ$ . In our study, the mean value of anterior torsion of the neck in primary OA was  $10.3^\circ \pm 8.5^\circ$  and significantly different ( $p < 0.05$ ) compared to the proximal femoral torsion at 15 millimetres above the midpoint of the lesser trochanter (approximate level of osteotomy during THA). The same finding was true for all groups of diagnoses.

No significant difference of proximal femoral torsion could be found at any level between the reference group of primary OA and the groups of aseptic osteonecrosis of the femoral head, rheumatoid arthritis and epiphysiolysis capitis femoris. This finding is explained by the epiphyseal or articular origin of the disease, which does not affect femoral metaphysis. However, there were important individual differences of torsion at each level within all these groups. This finding is important because it shows that a femur not only differs from 1 patient to the other in the frontal and the sagittal planes as described by Noble et al.<sup>1</sup> and Husmann et al.<sup>9</sup> but also in the horizontal plane. This adds 1 component to the 3-dimensional anatomy of the femur which should be taken into account when planning or designing femoral stems for THA.

Significant differences of proximal femoral torsion were found at each level between the groups of dysplasia or congenital dislocation of the hip and the reference group of primary osteoarthritis. This difference is explained by the congenital origin of the disease as shown by Tönnis and Heinecke<sup>29</sup> and Wilkinson,<sup>30</sup> attributed to the different rotational postures of the foetus, thus affecting the rotation of the whole proximal femur during its development.

The knowledge of the decrease of proximal femoral torsion, from metaphysis to the neck, is very important

for the design of a cementless femoral stem. Indeed, the literature shows that the long-term results of cementless hip stems are related to an optimal proximal fit-and-fill to achieve primary and secondary stability with good bone ingrowth.<sup>18,19,31-33</sup> With a straight femoral stem design it is difficult to optimally fit-and-fill the metaphysis because of the variation of proximal femoral torsion depending on the metaphyseal level (Figure 3). Furthermore, this design may induce some peak stresses at the edges of the prosthesis where all loads are transmitted to the bone.<sup>34</sup> So-called “anatomic” designs have been developed to allow better adaptation of the prosthesis to the intramedullary anatomy. These designs are optimally adapted to cases respecting mean anatomy at each level in the frontal and sagittal planes. As shown in our study, proximal femoral torsion varies between patients within a similar diagnostic group and varies even more in groups of hip dysplasia and congenital dislocation of the hip. Therefore, a straight stem design may achieve optimal fit-and-fill in only 50% of patients, taking into account the optimal anterior torsion of the femoral neck of  $15^\circ \pm 5^\circ$  to achieve a stable prosthesis.<sup>35,36</sup> Without correction of the orientation of the prosthetic neck, a so-called anatomic stem will achieve an anterior torsion between  $10^\circ$  and  $20^\circ$  in only 50% of the cases in the groups of primary osteoarthritis, aseptic osteonecrosis, rheumatoid arthritis and epiphysiolysis capitis femoris. In the other 50%, if the femoral stem rotates during the implantation to adapt itself to the proximal femoral torsion, this can induce a malrotation of the leg leading to gait problems if the foot is turned inside or outside, or more importantly, an instability of the hip which can lead to dislocation (Figure 4). In cases



**Figure 5.** In patients with an increased proximal femoral torsion (middle green line without arrow), if the goal is to achieve optimal adaptation of the stem to the intramedullary shape of the bone without compromising femoral neck anterior torsion (lower purple arrowed line), a modular or custom stem should be considered.

of dysplasia and congenital dislocation of the hip, the number of patients achieving an optimal fitting with an anterior torsion of the neck between  $10^\circ$  and  $20^\circ$  would be decreased to 20% and 5% respectively, which correlates with the findings of Sugano et al.<sup>37</sup>

Several previous articles have described techniques for correcting torsion of the femur in regards to femoral neck anterior torsion,<sup>38–41</sup> such as cementing of the femoral stem, the cement acting as “fit-and-fill” between prosthesis and bone. Other techniques including prosthesis undersizing or subtrochanteric femoral osteotomy were also described with poor mid- to long-term results and high morbidity.<sup>42,43</sup> Another alternative is a conical prosthesis, influenced by neither proximal femoral torsion nor anterior torsion of the neck. However, this does not allow an optimal fit-and-fill of the metaphysis, even if medium term results in dysplastic patients are satisfactory.<sup>44</sup> Therefore, if a cementless hip prosthesis is to be used, we believe that the better way to simultaneously obtain an optimal proximal fit-and-fill adapted to each proximal femoral torsion and to achieve an ideal anterior torsion of  $15^\circ \pm 5^\circ$  of the femoral neck is to plan every single patient THA in 3 dimensions based on CT scans. A precise analysis of the torsional anatomy of each individual femur allows the determination of the single best femoral stem for each case, both intramedullary and extramedullary.<sup>45,46</sup> It will also indicate those cases where the torsion of the proximal femoral metaphysis does not allow us to simultaneously achieve both a perfect fit-and-fill and anterior torsion (Figure 5). This is the case in dysplasia (80%) and congenital dislocation of the hip (95%), but also in approximately 50% of the patients with other diagnoses. A modular stem could be an alternative, adapting the orientation of

the stem to the metaphyseal torsion, and correcting the anterior torsion to its optimal angulation. However, this adaptation is often limited to a few degrees and the modularity may also introduce potential metal ion problems. In cases where no optimal adaptation between proximal femoral torsion and anterior torsion can be found, a custom femoral stem may be an attractive alternative in order to offer the patient a femoral stem with the most optimal correction and bony adaptation.<sup>47–50</sup>

The limitations of this study include the small number of patients analysed and the absence of measurements on the whole femur. However, the main portion affected by the torsion of the femur at the time of THA is located on the proximal metaphysis, which is covered in our study. We believe this series represents a significant contribution to anatomic knowledge of the proximal femoral metaphyseal torsion in various aetiologies leading to THA.

The knowledge of proximal femoral torsion, its values and variations, are of tremendous importance to the surgeon who believes in the principles of fit-and-fill.<sup>31–33</sup> As proximal femoral torsion can only be assessed by CT scan, we suggest that, ideally, each patient with a high life expectancy or suspected dysplasia and who is scheduled for a cementless THA, may benefit from 3-dimensional computer assisted planning with the goal of a perfect intramedullary adaptation and anatomic extramedullary reconstruction. We also believe the results of the present study could help in the design of cementless stems in THA for various anatomies. This can be considered as one further step in optimising the success rate of cementless total hip arthroplasty.

#### Declaration of conflicting interests

The author(s) declared no potential conflicts of interest with respect to the research, authorship, and/or publication of this article.

#### Funding

The author(s) received no financial support for the research, authorship, and/or publication of this article.

#### References

1. Noble PC, Alexander JW, Lindahl LJ, et al. The anatomic basis of femoral component design. *Clin Orthop Relat Res* 1988; 235: 148–165.
2. Rubin PJ, Leyvraz PF, Aubaniac JM, et al. The morphology of the proximal femur. A three-dimensional radiographic analysis. *J Bone Joint Surg Br* 1992; 74: 28–32.
3. Laine HJ, Lehto MU and Moilanen T. Diversity of proximal femoral medullary canal. *J Arthroplasty* 2000; 15: 86–92.
4. Ramaniraka NA, Rakotomanana LR, Rubin PJ, et al. Noncemented total hip arthroplasty: influence of extramedullary parameters on initial implant stability and on bone-implant interface stresses. *Rev Chir Orthop Reparatrice Appar Mot* 2000; 86: 590–597.

5. Sugano N, Noble PC and Kamaric E. Predicting the position of the femoral head center. *J Arthroplasty* 1999; 14: 102–107.
6. Lecerf G, Fessy MH, Philippot R, et al. Femoral offset: anatomical concept, definition, assessment, implications for preoperative templating and hip arthroplasty. *Orthop Traumatol Surg Res* 2009; 95: 210–219.
7. Matsushita A, Nakashima Y, Fujii M, et al. Modular necks improve the range of hip motion in cases with excessively anteverted or retroverted femurs in THA. *Clin Orthop Relat Res* 2010; 468: 3342–3347.
8. McMahon SJ, Christmas MUSI, Pierrepont J, et al. The accuracy of acetabular cup positioning using patient-specific 3D orientation guidance in total hip arthroplasty. *Surg Technol Int* 2020; 36: 426–431.
9. Husmann O, Rubin PJ, Leyvraz PF, et al. Three-dimensional morphology of the proximal femur. *J Arthroplasty* 1997; 12: 444–450.
10. Hackenbruch W. Die idiopathische coxa antetorta (antetorsionssyndrom). *European J Pediatr Surg* 1983; 38: 404–409.
11. Haspl M and Bilic R. Assessment of femoral neck-shaft and antetorsion angles. *Int Orthop* 1996; 20: 363–366.
12. Starker M, Hanusek S, Rittmeister M, et al. Validation of computerized tomography antetorsion angle measurement of the femur. *Z Orthop Ihre Grenzgeb* 1998; 136: 420–427.
13. Wissing H and Spira G. Determination of rotational defects of the femur by computer tomographic determination of the antetorsion angle of the femoral neck. *Unfallchirurgie* 1986; 12: 1–11.
14. Tönnis D and Heinecke A. Decreased acetabular anteversion and femur neck antetorsion cause pain and arthrosis. 1: statistics and clinical sequelae. *Z Orthop Ihre Grenzgeb* 1999; 137: 153–159.
15. Wilkinson JA. Femoral anteversion in the rabbit. *J Bone Joint Surg Br* 1962; 44-B: 386–397.
16. Yu D, Zeng Y, Li H, et al. Prediction of postoperative stem anteversion in Crowe type II/III developmental dysplasia of the hip on preoperative two-dimensional computed tomography. *J Arthroplasty* 2020; 35: 457–464.
17. Sendtner E, Tibor S, Winkler R, et al. Stem torsion in total hip replacement: CT measurements in 60 patients. *Acta Orthop* 2010; 81: 579–582.
18. Callaghan JJ. The clinical results and basic science of total hip arthroplasty with porous-coated prostheses. *J Bone Joint Surg Am* 1993; 75: 299–310.
19. Rubin PJ, Rakotomanana RL, Leyvraz PF, et al. Frictional interface micromotions and anisotropic stress distribution in a femoral total hip component. *J Biomech* 1993; 26: 725–739.
20. de Boer FA and Sariali E. Comparison of anatomic vs. straight femoral stem design in total hip replacement – femoral canal fill in vivo. *Hip Int* 2017; 27: 241–244.
21. Gordenne W and Malchair F. Results of our experience with coxometry (apropos of 104 examinations). Verification of normal angular values in the adult. *J Belge Radiol* 1984; 67: 401–404.
22. Wiberg G. Studies on dysplastic acetabula and congenital subluxation of the hip joint with special reference to the complication of osteoarthritis. *JAMA* 1940; 115: 81.
23. Lequesne M. False profile of the pelvis. A new radiographic incidence for the study of the hip. Its use in dysplasias and different coxopathies. *Rev Rhum Mal Osteoartic* 1961; 28: 643–652.
24. Crowe JF, Mani VJ and Ranawat CS. Total hip replacement in congenital dislocation and dysplasia of the hip. *J Bone Joint Surg Am* 1979; 61: 15–23.
25. Sariali E and Knaffo Y. Three-dimensional analysis of the proximal anterior femoral flare and torsion. Anatomic bases for metaphyseally fixed short stems design. *Int Orthop* 2017; 41: 2017–2023.
26. Murphy SB, Simon SR, Kijewski PK, et al. Femoral anteversion. *J Bone Joint Surg Am* 1987; 69: 1169–1176.
27. Sariali E, Mouttet A, Pasquier G, et al. Three-dimensional hip anatomy in osteoarthritis. Analysis of the femoral offset. *J Arthroplasty* 2009; 24: 990–997.
28. Noble PC, Box GG, Kamaric E, et al. The effect of aging on the shape of the proximal femur. *Clin Orthop Relat Res* 1995; 316: 31–44.
29. Tönnis D and Heinecke A. Decreased acetabular anteversion and femur neck antetorsion cause pain and arthrosis. 2: Etiology, diagnosis and therapy. *Z Orthop Ihre Grenzgeb* 1999; 137: 160–167.
30. Wilkinson JA. Experimental bone growth. *J Bone Joint Surg Br* 1967; 49-B: 583.
31. Hua J and Walker PS. Relative motion of hip stems under load. An in vitro study of symmetrical, asymmetrical, and custom asymmetrical designs. *J Bone Joint Surg Am* 1994; 76: 95–103.
32. Robertson DD, Walker PS, Hirano SK, et al. Improving the fit of press-fit hip stems. *Clin Orthop Relat Res* 1988; 228: 134–140.
33. Walker PS and Robertson DD. Design and fabrication of cementless hip stems. *Clin Orthop Relat Res* 1988; 235: 25–34.
34. Laine HJ, Puolakka TJS, Moilanen T, et al. The effects of cementless femoral stem shape and proximal surface texture on ‘fit-and-fill’ characteristics and on bone remodeling. *Int Orthop* 2000; 24: 184–190.
35. Herrlin K, Pettersson H, Selvik G, et al. Femoral anteversion and restricted range of motion in total hip prostheses. *Acta Radiol* 1988; 29: 551–553.
36. Herrlin K, Selvik G, Pettersson H, et al. Position, orientation and component interaction in dislocation of the total hip prosthesis. *Acta Radiol* 1988; 29: 441–444.
37. Sugano N, Noble PC, Kamaric E, et al. The morphology of the femur in developmental dysplasia of the hip. *J Bone Joint Surg Br* 1998; 80: 711–719.
38. Becker DA and Gustilo RB. Double-chevron subtrochanteric shortening derotational femoral osteotomy combined with total hip arthroplasty for the treatment of complete congenital dislocation of the hip in the adult. Preliminary report and description of a new surgical technique. *J Arthroplasty* 1995; 10: 313–318.
39. Yasgur DJ, Stuchin SA, Adler EM, et al. Subtrochanteric femoral shortening osteotomy in total hip arthroplasty for high-riding developmental dislocation of the hip. *J Arthroplasty* 1997; 12: 880–888.
40. Zadeh HG, Hua J, Walker PS, et al. Uncemented total hip arthroplasty with subtrochanteric derotational osteotomy for severe femoral anteversion. *J Arthroplasty* 1999; 14: 682–688.



41. Huo MH, Zatorski LE and Keggi KJ. Oblique femoral osteotomy in cementless total hip arthroplasty. Prospective consecutive series with a 3-year minimum follow-up period. *J Arthroplasty* 1995; 10: 319–327.
42. Hartofilakidis G, Stamos K and Karachalios T. Treatment of high dislocation of the hip in adults with total hip arthroplasty. Operative technique and long-term clinical results. *J Bone Joint Surg Am* 1998; 80: 510–517.
43. Huo MH, Zurauskas A, Zatorska LE, et al. Cementless total hip replacement in patients with developmental dysplasia of the hip. *J South Orthop Assoc* 1998; 7: 171–179.
44. Cherubino P, Zatti G, D’Angelo F, et al. “Conus” uncemented stem in developmental hip dysplasia. *Hip Int* 2007; 17(Suppl. 5): S134–S137.
45. Sariali E, Mouttet A, Pasquier G, et al. Accuracy of reconstruction of the hip using computerised three-dimensional pre-operative planning and a cementless modular neck. *J Bone Joint Surg Br* 2009; 91-B: 333–340.
46. Wegrzyn J, Roux JP, Loriau C, et al. The tridimensional geometry of the proximal femur should determine the design of cementless femoral stem in total hip arthroplasty. *Int Orthop* 2018; 42: 2329–2334.
47. Argenson JN, Flecher X, Parratte S, et al. Anatomy of the dysplastic hip and consequences for total hip arthroplasty. *Clin Orthop Relat Res* 2007; 465: 40–45.
48. Argenson JN, Ryembault E, Flecher X, et al. Three-dimensional anatomy of the hip in osteoarthritis after developmental dysplasia. *J Bone Joint Surg Br* 2005; 87: 1192–1196.
49. Wettstein M, Mouhsine E, Argenson JN, et al. Three-dimensional computed cementless custom femoral stems in young patients: midterm followup. *Clin Orthop Relat Res* 2005; 2005: 169–175.
50. Tsiampas DT, Pakos EE, Georgiadis GC, et al. Custom-made femoral implants in total hip arthroplasty due to congenital disease of the hip: a review. *Hip Int* 2016; 26: 209–214.