



HAL
open science

Stenosing tenosynovitis of the extensor digitorum tendons of the hand: clinical and sonographic features.

Antoine Moraux, Thomas Le Corroller, Aurelien Aumar, Stefano Bianchi

► To cite this version:

Antoine Moraux, Thomas Le Corroller, Aurelien Aumar, Stefano Bianchi. Stenosing tenosynovitis of the extensor digitorum tendons of the hand: clinical and sonographic features.. *Skeletal radiology*, 2021, 50 (10), pp.2059–2066. 10.1007/s00256-021-03784-x . hal-03553749

HAL Id: hal-03553749

<https://hal.science/hal-03553749>

Submitted on 15 Apr 2022

HAL is a multi-disciplinary open access archive for the deposit and dissemination of scientific research documents, whether they are published or not. The documents may come from teaching and research institutions in France or abroad, or from public or private research centers.

L'archive ouverte pluridisciplinaire **HAL**, est destinée au dépôt et à la diffusion de documents scientifiques de niveau recherche, publiés ou non, émanant des établissements d'enseignement et de recherche français ou étrangers, des laboratoires publics ou privés.

Stenosing tenosynovitis of the extensor digitorum tendons of the hand: clinical and sonographic features

Antoine Moraux^{1,2} · Thomas Le Corroller³ · Aurelien Aumar⁴ · Stefano Bianchi⁵

Abstract

Objective To describe the ultrasound (US) features of 18 patients with extensor digitorum communis stenosing tenosynovitis (EDCST).

Materials and methods A retrospective search in the radiologic information systems of two separate Institutions was performed to identify all patients presenting EDCST between January 2010 and September 2019. A total of 18 patients (ten males and eight females; mean age, 57.4 years) were identified and included. Sonographic examinations were retrospectively reviewed by two senior radiologists to assess morphologic changes and power Doppler activity of the extensor retinaculum (ER) and of the extensor digitorum communis (EDC) tendons and sheath. The presence of dynamic impingement between the EDC and the ER was evaluated using video clip records.

Results At the ultrasound, all patients (18/18; 100%) presented thickening of both the ER and EDC tendons associated with EDC tendon sheath effusion. Power Doppler hyperemia of the ER was inconstant and observed in 11 cases (11/18; 61.1%) as tendon sheath effusion observed in 16 cases (16/18; 88.9%). A cyst located inside the EDC of the index finger was observed in three of these patients (3/18; 17%). Dynamic examination showed impingement of the EDC against the ER during active tendon extension in all patients (18/18; 100%). Four of these patients (4/18; 22%) underwent surgery allowing diagnosis confirmation and release of EDCST, while the remaining fourteen patients (14/18; 78%) were either treated conservatively or using US-guided steroid injection.

Conclusion US findings of EDCST include thickening of the ER and EDC tendons, EDC tendon sheath effusion, and in some cases presence of an EDC intratendinous cyst. Impingement of the EDC tendons against the ER is well demonstrated using dynamic US.

Keywords Tendon entrapment · Ultrasound · Wrist · Hand

Introduction

Stenosing tenosynovitis (ST) is a frequently encountered clinical condition that may involve the first extensor compartment

of the wrist in the De Quervain tenosynovitis or the flexor digitorum tendons in the trigger finger. ST affecting the extensor digitorum communis (EDC) tendons is rather unusual with only a few reports in the literature [1–5]. Yet, we herein describe the ultrasound (US) features of extensor digitorum communis stenosing tenosynovitis (EDCST) in eighteen patients. To the best of our knowledge, this is the first study providing a thorough description of the static and dynamic US features of EDCST.

✉ Antoine Moraux
amoraus@yahoo.com

¹ Imagerie Médicale Jacquemars Giélee, 73 rue Jacquemars Giélee, 59000 Lille, France

² Hôpital Privé La Louvière, Ramsay Santé, 59000 Lille, France

³ Hôpital Sainte Marguerite, 13009 Marseille, France

⁴ Archimed, Clinique Lille Sud, Ramsay Santé, 59000 Lille, France

⁵ CIM SA Cabinet Imagerie Médicale, CH 1208 Geneva, Switzerland

Materials and methods

This study was approved by the institutional review boards with permission to review medical records; and waivers were issued for written informed consent.

A retrospective search in the radiologic information systems of two separate Institutions was performed to identify all patients presenting EDCST on a total of 986 wrist ultrasound examinations between January 2010 and September 2019 using the following keywords: stenosing tenosynovitis, extensor digitorum tendons, tendon entrapment, tendon impingement, and wrist. Medical records were reviewed to assess patients' past history, EDCST treatment, complications, and clinical outcomes. Patients with a past history of either previous surgery of the affected wrist and proven or suspected rheumatologic disease were excluded. A total of 18 patients (ten males and eight females; mean age, 57.4 years) could be identified and finally included in this study. The follow-up period was variable with ten patients (10/18; 55%) presenting at least 1-year clinical follow-up in our Institutions. The following patient data were collected: age, gender, contributing factors, symptom duration, triggering factors, and treatments. US examinations were performed by two senior radiologists (AM and SB) with 12 and 32 years of experience, respectively, in musculoskeletal US.

US examinations were carried out over a 10-year period using either an Affiniti (Philips Healthcare, Bothell, WA) with 15–7 MHz (width = 23 mm) or 18–5 MHz (width = 39 mm) linear transducers or a RS85 (Samsung Medical, Seoul, Korea) with a 4–18 MHz linear transducer (width = 37.3 mm), both for B-mode and power Doppler energy mode. All patients underwent the same US examination protocol including patient position (hand in pronation lying on the examination table) and bilateral examination with both static and dynamic assessment. No standoff pad was used. US images of the dorsal wrists were obtained in the transverse and sagittal planes.

All images and videos of our population were reviewed and assessed retrospectively in consensus by two senior radiologists (AM and SB). In all patients, the ER of the EDC was identified, as described previously [6]. Data obtained from US examinations were thickness and echogenicity of the ER and EDC, presence of an effusion and a thickening of the EDC synovial tendon sheath on transverse images, and presence of EDC intratendinous cysts. The largest value for ER and EDC thickness was measured on both the symptomatic and contralateral sides. ER and EDC echogenicity was rated as either hypo- or isoechoic in relation to the contralateral side. Intratendinous cyst size was measured in the longitudinal and transverse planes. Tendon sheath was rated as either normal (no thickening), mildly thickened (synovial sheath thinner than EDC tendons), or markedly thickened (synovial sheath thicker than EDC tendons). Power Doppler images were also reviewed for positive or negative flow within the ER, EDC, and EDC tendon sheath. The presence of local anatomic variants including accessory muscles was noted. Bilateral and comparative dynamic assessment was available on video clip records obtained during active and passive flexion/extension

of the wrist and fingers. Tendon impingement was diagnosed on US dynamic examination with correlation with patients' pain. It was rated as positive in case of bulging of tendons on the distal edge of the ER with restriction of tendon sliding in comparison with the normal side and reproduction of the patient pain during the dynamic impingement. Ultrasound examination searched also tenosynovitis of both palmar and other dorsal tendons of the wrists and synovitis of radio-ulnar, radiocarpal, and mediocarpal joints (i.e., effusion, synovial thickening, and power Doppler hyperemia) to exclude potential rheumatologic disease.

Statistics

Quantitative data are reported as mean, median, first and third quartiles, as well as minimum and maximum. Qualitative data were reported by number and percentage. Univariate comparisons use Fisher's exact test for qualitative data and Wilcoxon's rank test for quantitative values.

All statistical tests used give significant values for $p < 0.05$. A statistical report was performed using open-source R version 3.4.4 (2018-03-15) and LATEX, on a i386-w64-mingw32 platform. Tables and graphics were created using Sweave 1.

Results

The study population characteristics are presented in Table 1. There were 10 males and 8 females with a mean age of 57.4 years; and the age range was 11–94 years. EDCST most often affected the left wrist ($n = 11$). Dominant hand was recorded in only 6 cases in the database. In six patients (6/18; 33%), repetitive movements were recorded prior to the apparition of the lump: the youngest patient was a gymnast, one patient was a typist, one was a safe installer, one was a pianist, and the two remaining patients were referred after intensive gardening. In 12 patients, no repetitive movement or

Table 1 Characteristics of the study population ($N = 18$)

Characteristic	
Age (years)	
Mean	57.4
Median (range: min–max)	61.4 (11–94)
Gender	
Male	10
Female	8
Hand affected	
Right	7
Left	11

microtraumatic injury could be identified. No patient had a history of previous local trauma or surgery. No patient was diabetic. A total of 15 patients (15/18; 83%) consulted for a chronic painful swelling of the dorsal aspect of the wrist extending distally to the hand associated with local discomfort (Fig. 1a). Of note, the lumps were partially compressible (Fig. 1b). One patient had an acute onset with a rapid development of the swelling a few days before the US examination. Except for the patient with acute onset, the duration of symptoms was >3 months with a progressive onset. No patient was clinically suspected of EDCST. At the time of US examination, the overlying skin was normal. Mild local tenderness and pain were exacerbated by wrist extension. In contrast, the three remaining patients (3/18; 17%) consulted for a dorsal painful mass that was in continuity with the index extensor tendon and showed proximal and distal migration during extension and flexion of the finger.

US showed changes in both the ER and EDC in all patients. The ER was hypoechoic and thickened in all cases (Fig. 2). The mean thickness of the ER was 2.1 mm versus 1.1 mm for the unaffected contralateral wrist ranging from 1.2 to 2.7 mm versus 0.76 to 1.6 mm ($p < 0.0007$) (Table 2) (Graph.1).

The EDC was thickened and hypoechoic in all cases with a mean thickness of 5.2 mm versus 3.8 mm for the unaffected side ranging from 3.0 to 7.3 mm versus 2.6 to 5.1 ($p < 0.013$) (Table 2) (Graph 2). Patients were divided into 2 groups: ER thickness values up to $2 \times$ contralateral ER thickness, and ER values superior to $2 \times$ contralateral ER thickness. The patients with less thick ER were older (mean age 69 vs 58 years old), mainly men (78% vs 50%), and presented relatively thicker EDC (mean diameter 6.2 Vs 4,2 mm). Power Doppler hyperemia of the ER was inconstant and observed in 11 cases (11/18; 61.1%) (Fig. 3). A cyst located inside the EDC of the index finger was observed in three cases (3/18; 16,7%). When present, the intratendinous cyst exhibited a fusiform appearance with the largest diameter in the sagittal plane (mean 18.4 mm, range: 13.4–27.0 mm). Tendon sheath

Table 2 Ultrasound findings

	Pathological side	Unaffected side
ER thickness (mm)		
Mean	1.99	1.18
Range (min–max)	(1.16–2.7)	(0.76–1.5)
EDCT thickness (mm)		
Mean	5.22	3.8
Range (min–max)	(3.1–8.3)	(3.0–5.1)
ER power Doppler activity	11 (61.1%)	0
EDCT sheath thickening	18 (100%)	0
EDCT sheath effusion	16 (88.9%)	0
EDCT Doppler	14 (77.8%)	0

effusion was observed in 16 cases (16/18; 88.9%). Tendon sheath synovial thickening was constant (18/18; 100%) and was constantly rated as mild (Fig. 4a). Tendon sheath Doppler hyperemia was observed in 14 cases (14/18; 77.8%) (Fig. 4b).

A dynamic study showed impingement between the EDC and ER in all cases during wrist and finger extension when the enlarged EDC tendon mass impacted on the distal boundary of the thickened ER which limited its excursion (Fig. 5). The impingement reproduced the pain experienced by the patients. In the three patients with an intratendinous cyst, extension of the index finger was associated with the confinement of the cyst under the ER, which was displaced dorsally (Fig. 6). We did not observe any anatomical variant of the fourth dorsal compartment of the wrist. Finally, no other tenosynovitis/synovitis was depicted.

In four of these patients (4/18; 22%), surgery was able to confirm the US diagnosis. Exploration via a mini-open technique showed thickening of both the ER and EDC. Surgical release of the ER and tenosynovectomy was followed in all patients by complete pain relief at 3 months. Synovial tissue histological analysis revealed fibrosis changes with no/little synovial hyperplasia and inflammatory reaction. In one of

Fig. 1 a, b Clinical appearance of EDCST in a 65-year-old female patient show a soft swelling (arrows) on the dorsal aspect of the right wrist

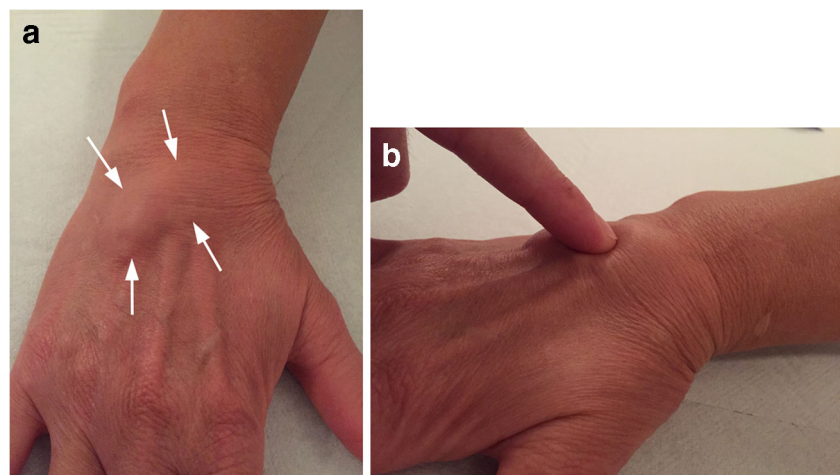
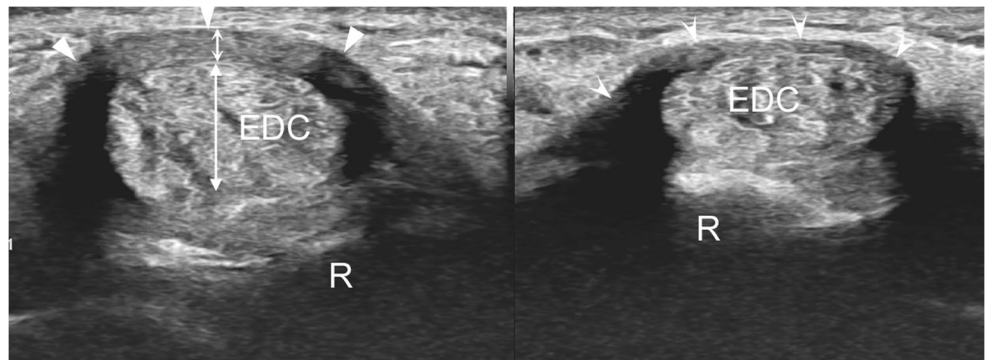


Fig. 2 Ultrasound appearance of EDCST in the same patient as Fig. 1: Left (right wrist): transverse image showing a hypoechoic thickening (small double curved arrow) of the ER (arrowheads) and thickening and round shape of EDC (double arrow). Right: image obtained at the same level for the contralateral normal wrist. (R, radius)



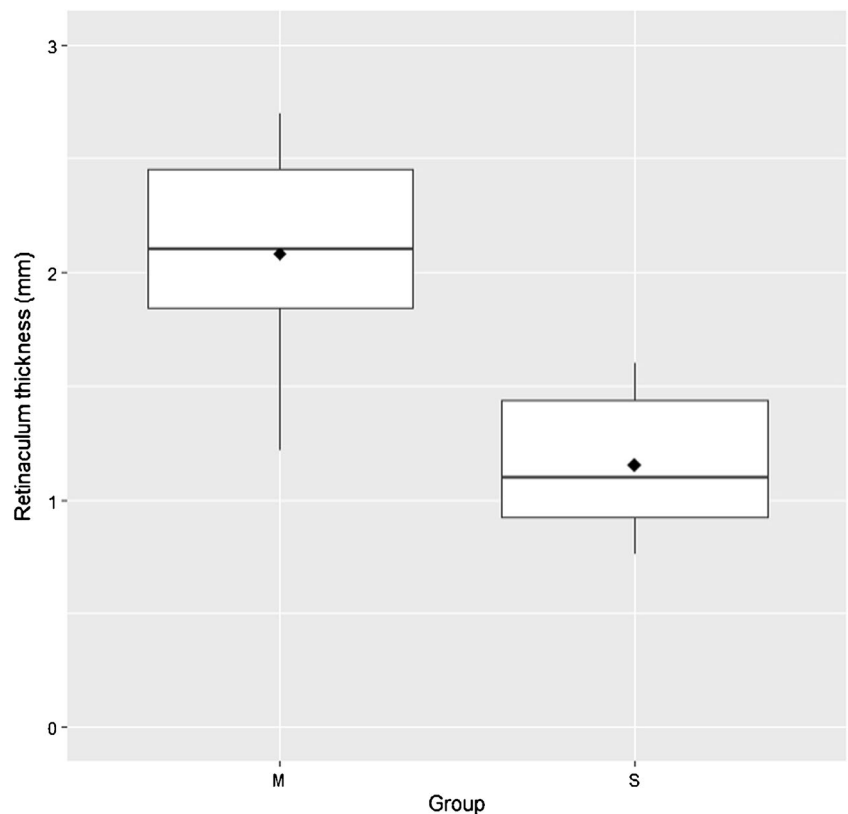
these four patients, the extensor tendon had in addition to be repaired (Fig. 7). Among the fourteen patients that did not undergo surgery, two patients were treated with US-guided corticosteroid injection providing complete symptom relief at 3 months. Five patients were treated conservatively and presented mild residual swelling and partial relief of pain at the last follow-up. Unfortunately, seven patients including the three patients with intratendinous cysts were initially treated conservatively and then lost to clinical follow-up.

Discussion

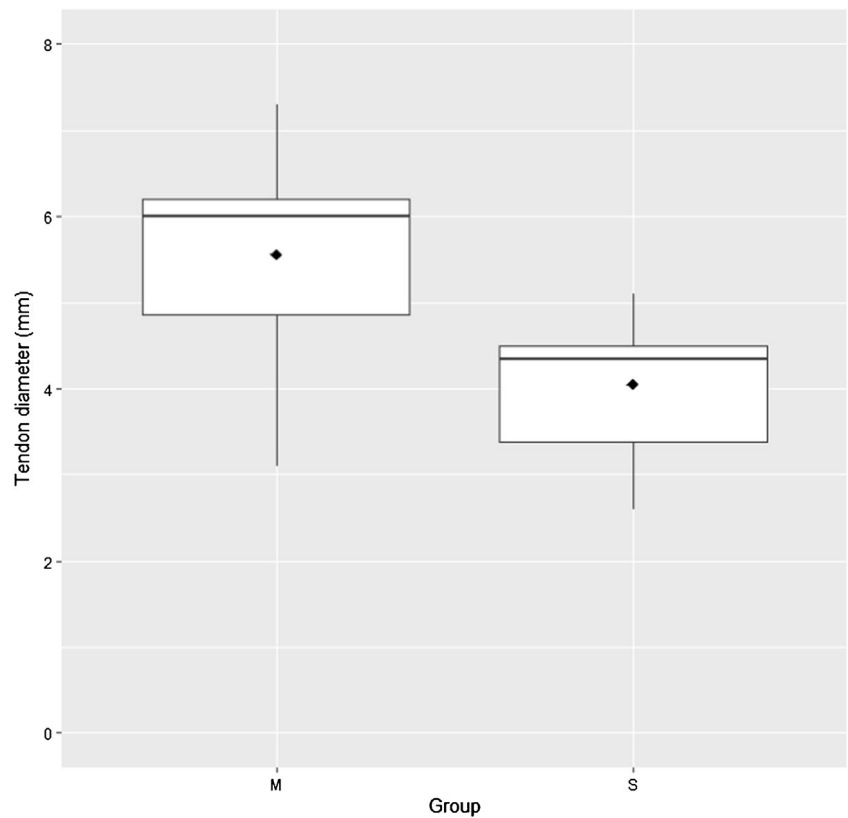
At the dorsal aspect of the wrist, the extensor tendons course in osteofibrous tunnels delimited by bony depressions and the

ER, a fibrous band that inserts into the dorsal aspects of the distal radial styloid process and in the palmar side into the flexor carpi ulnaris, triquetrum pisiform, fascia of the abductor digiti quinti muscle, and, deep to it, into the base of the small finger metacarpal [7] (Fig. 8). Proximally, the ER arises from the antebrachial fascia of the forearm and extends distally into the superficial fascia of the dorsum of the hand [8, 9]. At the level of the distal epiphysis of the radius, the insertions of the ER give origin to six compartments that house the extensor tendons surrounded by synovial sheaths. The function of the ER is to prevent bowstringing by keeping the extensor tendons close to the bone surface but separate from each other. The US appearance of the fourth dorsal compartment ER has been described previously [6]. It is thicker than the ER of the other dorsal compartments, which may be misinterpreted as

Graph 1 Box plot representation of the comparison between ER thickness in affected side (M) and unaffected side (S) (thick lines, median; square dots, mean)



Graph 2 Box plot representation of the comparison between tendon thickness in affected side (M) and unaffected side (S) (thick lines, median; square dots, mean)



complex fluid in the tendon sheath, and simulates tenosynovitis [6]. A US study by Robertson et al. [6] showed a maximum thickness of 0.6–1.7 mm in men and 0.5–1.6 mm in women along the short axis of the ER. In our patients, the mean thickness was greater than that described by Robertson et al., measured at 1.99 mm, with an overlap between pathological and normal values. In our patients, the ER of the affected wrist was always thicker than the healthy side, by about 0.81 mm (e.g., 78% thicker). Given the overlap in ER thickness values between pathological and asymptomatic individuals, US assessment of the contralateral wrist is of crucial

importance to diagnose ER thickening in EDCST. The possibility of a bilateral and comparative examination is a great

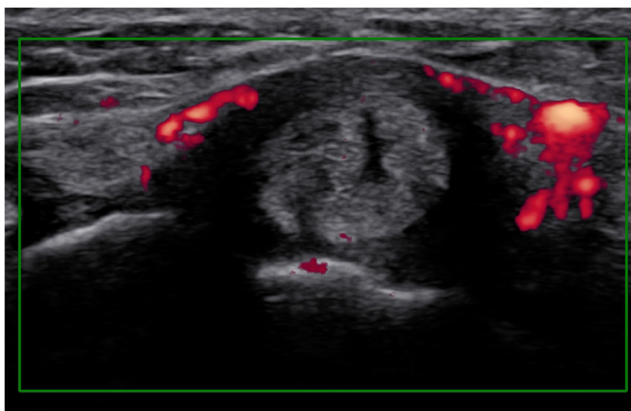


Fig. 3 Ultrasound appearance of EDCST in the same patient as Fig. 1. Transverse power Doppler sonogram obtained over the ER shows its hypoechoic appearance associated with thickening and local hyperemia

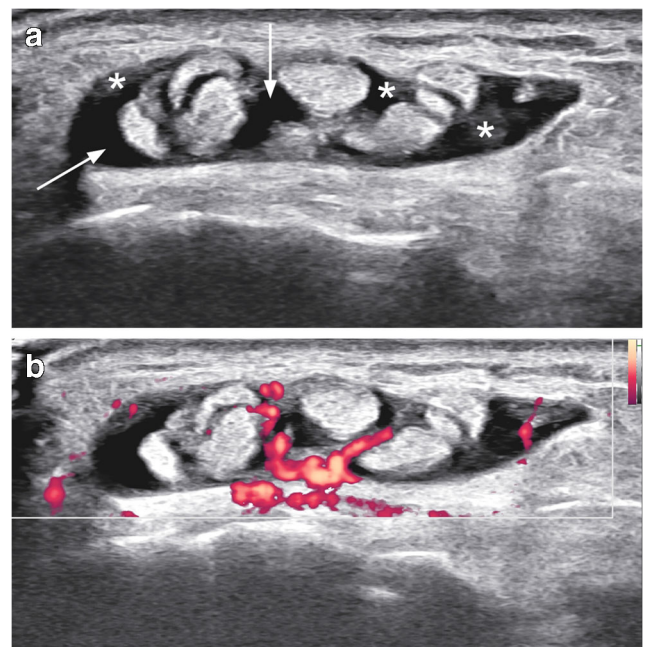


Fig. 4 Power Doppler ultrasound appearance of EDCST in a 59-year-old male patient. **a** Transverse grayscale and **b** power Doppler ultrasounds obtained distal to the thickened ER. In **a**, note the normal hyperechoic tendons surrounded by an effusion (arrows) and hypoechoic thickening of the synovial sheath (asterisks). **b** Power Doppler shows hyperemia of the sheath

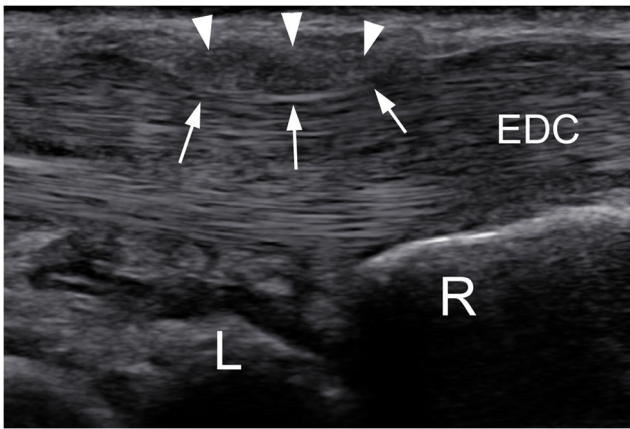


Fig. 5 Ultrasound dynamic examination of EDCST in the same patient as Fig. 4. Sagittal ultrasound image obtained with active finger extension. Focal compression (arrows) of the hypoechoic thickened ER (arrowheads) on the underlying EDC. (L, lunatum; R, radius)

advantage of US over MRI. Power Doppler ER hyperemia may be helpful in the diagnosis but is not constant. In all cases, the EDC tendons were thickened with a more rounded cross section at the level of ER. In the transverse view, the association of retinaculum hypoechoic thickening and a more rounded tendon is the typical pattern of De Quervain tenosynovitis [10–14] and trigger finger [15]. In the same way, this pattern

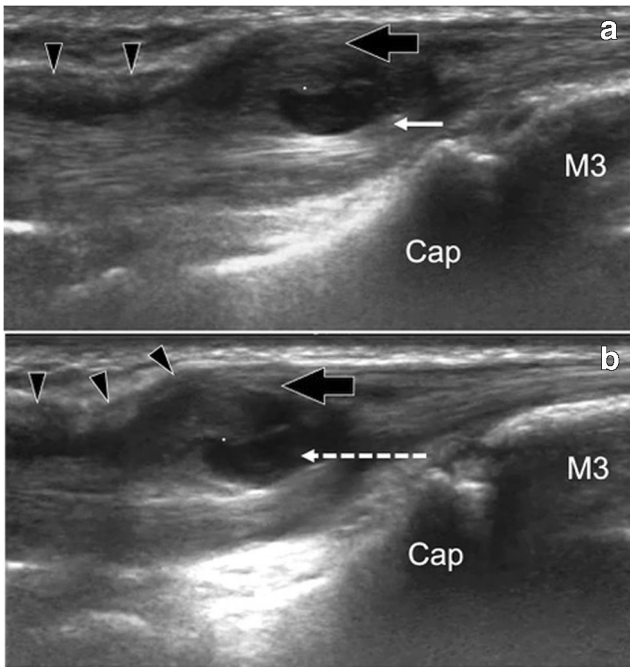


Fig. 6 Ultrasound Dynamic examination of EDCST with intratendinous cyst in an 11-year-old gymnast. Sagittal ultrasound image obtained at rest (a) and with active finger extension (b). a Intratendinous ganglion cyst within the index EDC (white arrow) surrounded by hypoechoic thickening of the tendon (black arrow) and focal compression of the ER (black arrowheads). b Proximal displacement of the tendon and ganglion cyst (white dotted arrow) with the confinement of the ganglion cyst under the ER and bulging of the EDC. (M3, third metacarpal bone; Cap, capitatum)

was constant in all our EDCST cases. Our operational definition of impingement was based on three coincident features. Morphologic US criteria (thickening of the ER compared by the asymptomatic side, morphologic changes of the EDC), dynamic US criteria (impingement of the EDC against the ER during simultaneous finger and wrist extension), and reproduction of the patient pain during the dynamic impingement. The synovial hypoechoic thickening observed in all our patients and synovial sheath fluid observed in 88.9% of our patients could be confusing with proliferative extensor tenosynovitis which is a common and well-described condition in patients with rheumatoid arthritis [16] that commonly affects the fourth compartment [17, 18]. In rheumatic tenosynovitis, the ER remains normal and may even be used for surgical procedure [19]. Therefore, in case of unicompartamental tenosynovitis of the EDC, ER thickness should be assessed, and local impingement of the EDC tendons should be evaluated

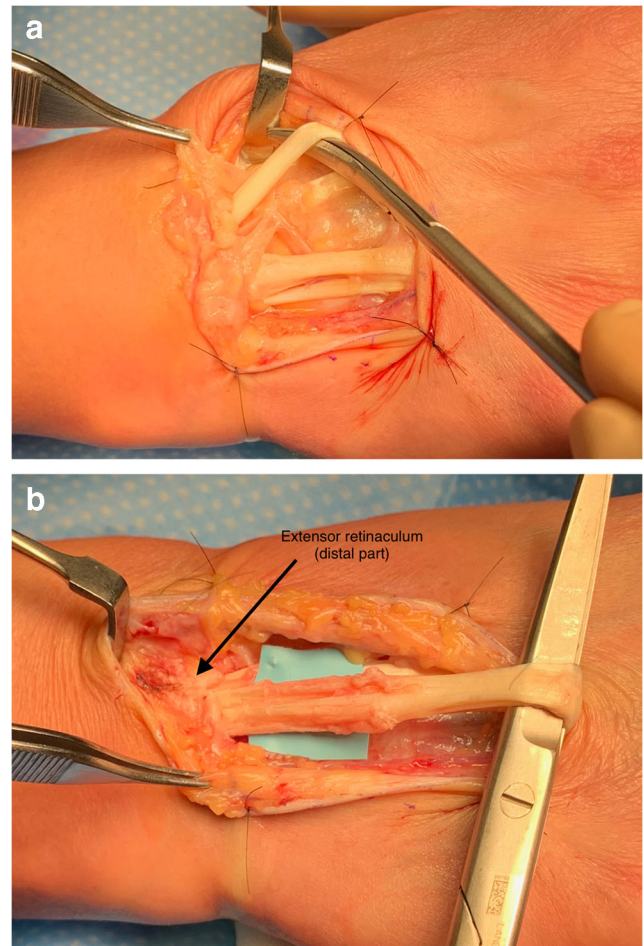


Fig. 7 EDCST perioperative findings in the same patient as Fig. 1 and Fig. 2. a Exposure of the common extensor apparatus of the finger with excision of the superficial layer of the EDC tendon sheath. b Release of the distal part of the extensor retinaculum (arrow) and tenosynovectomy of the tendon sheath. The extensor tendon of the medius was split longitudinally, and inflammatory tissue was removed and the tendon repaired

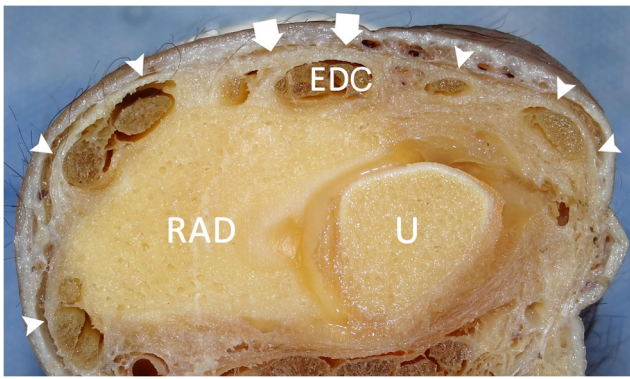


Fig. 8 Transverse cadaveric section of a right wrist showing a normal ER (curved arrowheads) with fibrous thickening of the fourth dorsal compartment (arrows) around EDC. (Rad, radius; U, ulna)

during dynamic maneuvers to differentiate ST and rheumatic tenosynovitis. The clinical presentation and population data of our study are similar to the findings reported by Cooper et al. [20] and by Mahajan [5]. They described proliferative extensor tenosynovitis of the wrist in, respectively, 11 and 10 patients. These authors reported the presence of a proliferative synovial mass adherent to the EDC that blocked proximal tendon extrusion, but they did not assess the ER and could not exclude EDCST. In our population, we hypothesize that the synovial thickening is only a part of the spectrum of EDCST and should therefore be considered a consequence of the impingement between the tendon sheath and the ER. According to our data, dynamic sagittal US scanning during flexion/extension of the fingers is a key examination in diagnosing ST because it demonstrates decreased tendon motion and is the only imaging modality to confirm the impingement between the thickened EDC and the ER. Interestingly, we did not find a past history of repetitive movements as a contributing factor for EDCST in 11 out of our 18 patients. Nevertheless, we believe that overuse and chronic microtrauma may lead to localized thickening of the ER as has been described in the De Quervain tenosynovitis or trigger finger. Age may also be a contributing factor as most of our patients were in their fifties. In three cases, patients had an intratendinous cyst. Para-articular ganglion cysts are very common at the wrist [21], but intratendinous cysts are very unusual. One of the three patients with an intratendinous cyst was a gymnast, as reported in one case by Wilson et al. [2], supporting the hypothesis of a microtraumatic origin. Microtrauma of the EDC on the ER may also lead to tendon attrition lesions as observed on the fourth finger extensor tendon of one of our patients during surgery. Like Seidman et al. [22] and Khazzam et al. [4], we suggest that tenosynovitis may invade a damaged tendon, as encountered in the EDC index tendon in our three patients. It is difficult to determine which phenomenon occurred first, ER thickening and stenosis or occurrence of the intratendinous cyst, given that cases of

intratendinous cysts have been reported without impingement [22]. Nevertheless in our three cases, cysts developed in hypoechoic and thickened EDC tendons with dynamic conflict, which can logically be related to repetitive microtrauma and synovial intratendinous invasion.

Our work presents several limitations. First, because this entity is quite rare, the study was retrospective in nature. We have not included patients with tenosynovitis of other etiology and so cannot affirm that the described three coincident features are pathognomonic of EDCST. Nevertheless, in our practice, we never noted such simultaneous features in other types of tenosynovitis, and we are not aware of studies on this subject. Second, we did not investigate intra- or inter-observer variability in EDR and EDC measurements, and did not compare our measurements with a control group. Third, a surgical correlation was only available in four cases. Nevertheless, surgical findings confirmed the US data in all patients. Finally, clinical follow-up was variable in our population with ten patients only presenting at least 1-year follow-up in our Institutions.

Conclusion

Stenosing tenosynovitis is a rare finding at the 4th dorsal compartment. US typical features associate in our patients a mild proliferative thickening of EDC tendon sheath with fluid, hypoechoic thickening of the EDC tendons with a round pattern in transverse view, a hypoechoic thickening of the ER, and most importantly a dynamic impingement between the tendon and the ER. Further studies on EDC tenosynovitis without impingement seem required to judge if the described features are specific to EDCST.

Declarations

Conflict of interest The authors declare no competing interests.

Informed consent Written informed consent was obtained from all subjects (patients) in this study.

Ethical approval Institutional Review Board approval was obtained.

No study subjects or cohorts have been previously reported.

Methodology: retrospective.

References

1. Gooding GA. Tenosynovitis of the wrist. A sonographic demonstration. *J Ultrasound Med.* 1988;7(4):225–6.
2. Wilson SM, Dubert T, Rozenblat M. Extensor tendon impingement in a gymnast. *J Hand Surg.* 2006;31(1):66–7.
3. VanHeest AE, Luger NM, House JH, Vener M. Extensor retinaculum impingement in the athlete: a new diagnosis. *Am J Sports Med.* 2007;35(12):2126–30.

4. Khazzam M, Patillo D, Gainor BJ. Extensor tendon triggering by impingement on the extensor retinaculum: a report of 5 cases. *J Hand Surg.* 2008;33(8):1397–400.
5. Mahajan NP, Palange ND, Pawar E, Supe A. Surgical treatment of tenosynovitis of extensor tendons of fourth compartment of wrist in nonrheumatoid patients—a case series of 10 patients in India. *J Hand Microsurg.* 2019;11(1):45–9.
6. Robertson BL, Jamadar DA, Jacobson JA, Kalume-Brigido M, Caoili EM, Margaliot Z, et al. Extensor retinaculum of the wrist: sonographic characterization and pseudotenosynovitis appearance. *AJR Am J Roentgenol.* 2007;188(1):198–202.
7. Taleisnik J, Gelberman RH, Miller BW, Szabo RM. The extensor retinaculum of the wrist. *J Hand Surg Am.* 1984;1984(9A):495–501.
8. Taleisnik J, Gelberman RH, Miller BW, Szabo RM. The extensor retinaculum of the wrist. *J Hand Surg.* 1984;9(4):495–501.
9. Palmer AK, Skahen JR, Werner FW, Glisson RR. The extensor retinaculum of the wrist: an anatomical and biomechanical study. *J Hand Surg.* 1985;10(1):11–6.
10. Marini M, Boni S, Pingi A, De Dominicis C, Cartolari R. De Quervain's disease: diagnostic imaging. *La Chirurgia degli organi di movimento.* 1994;79(2):219–23.
11. Nagaoka M, Matsuzaki H, Suzuki T. Ultrasonographic examination of de Quervain's disease. *J Orthop Sci.* 2000;5(2):96–9.
12. Trentanni C, Galli A, Melucci G, Stasi G. Ultrasonic diagnosis of De Quervain's stenosing tenosynovitis. *La Radiologia Med.* 1997;93(3):194–8.
13. Giovagnorio F, Andreoli C, De Cicco ML. Ultrasonographic evaluation of de Quervain disease. *J Ultrasound Med.* 1997;16(10):685–9.
14. Gitto S, Draghi AG, Draghi F. Sonography of non-neoplastic disorders of the hand and wrist tendons. *J Ultrasound Med.* 2018;37(1):51–68.
15. Bianchi S, Gitto S, Draghi F. Ultrasound features of trigger finger: review of the literature. *J Ultrasound Med.* 2019;38(12):3141–54.
16. Rubin AD. MRI and ultrasound of the hands and wrists in rheumatoid arthritis. I Imaging findings. *Skeletal Radiol.* 2019;48(5):677–95.
17. Wilson RL, DeVito MC. Extensor tendon problems in rheumatoid arthritis. *Hand Clin.* 1996;12(3):551–9.
18. Papp SR, Athwal GS, Pichora DR. The rheumatoid wrist. *J Am Acad Orthop Surg.* 2006;14(2):65–77.
19. Rabarin A, Saint Cast Y, Raimbeau G, Cesari B, Fouque PA, Jeudy J, et al. "Butterfly flap": the retinaculum to the rescue of the extensors. *Orthop Traumatol, Surg Res.* 2015;2015(101):207–9.
20. Cooper HJ, Shevchuk MM, Li X, Yang SS. Proliferative extensor tenosynovitis of the wrist in the absence of rheumatoid arthritis. *J Hand Surg Am.* 2018;2009(34 (10)):1827–31.
21. Zhang A, Falkowski AL, Jacobson JA, Kim SM, Koh SH, Gaetke-Udager K. Sonography of wrist ganglion cysts: which location is most common? *J Ultrasound Med.* 2019;38(8):2155–60.
22. Seidman GD, Margles SW. Intratendinous ganglia of the hand. *J Hand Surg.* 1993;18(4):707–10.