



HAL
open science

Concepts and techniques of a new robotically assisted technique for total knee arthroplasty: the ROSA knee system.

Cécile Batailler, Didier Hannouche, Francesco Benazzo, Sébastien Parratte

► **To cite this version:**

Cécile Batailler, Didier Hannouche, Francesco Benazzo, Sébastien Parratte. Concepts and techniques of a new robotically assisted technique for total knee arthroplasty: the ROSA knee system.. Archives of Orthopaedic and Trauma Surgery, 2021, 141 (12), pp.2049–2058. <10.1007/s00402-021-04048-y>. <hal-03553740>

HAL Id: hal-03553740

<https://hal.science/hal-03553740v1>

Submitted on 15 Apr 2022

HAL is a multi-disciplinary open access archive for the deposit and dissemination of scientific research documents, whether they are published or not. The documents may come from teaching and research institutions in France or abroad, or from public or private research centers.

L'archive ouverte pluridisciplinaire HAL, est destinée au dépôt et à la diffusion de documents scientifiques de niveau recherche, publiés ou non, émanant des établissements d'enseignement et de recherche français ou étrangers, des laboratoires publics ou privés.



HAL Authorization

Concepts and techniques of a new robotically assisted technique for total knee arthroplasty: the ROSA knee system

Cécile Batailler¹  · Didier Hannouche² · Francesco Benazzo^{3,4} · Sébastien Parratte^{5,6}

Abstract

Introduction The ROSA (Robotic Surgical Assistant) Knee system (Zimmer Biomet, Warsaw, IN) for total knee arthroplasty (TKA) can be considered as collaborative robotics, where the surgeon remains in charge of the procedure and collaborates with a smart robotic tool, to perform the surgery with a high accuracy and reproducibility. The aim was to describe: (1) its concept and surgical technique; (2) its advantages and potential limits; (3) the early experience with this system. **Materials and methods** The goal during its development phase was to keep the surgeon active and at the center of the operation: the surgeon handles the saw and performs the cuts while the robotic arm places and holds the guide at the right place. The ROSA knee platform assists the surgeon for the distal femoral cut, the femoral component sizing and positioning, the tibial cut and the ligament balance. This robotic system has two options: image-based with 3D virtual model; or image-less, based on intraoperative landmarks acquisition. All the classic surgical techniques can be used: measured resection, gap balancing, functional alignment, kinematic alignment. Some techniques recently developed are more ROSA-specific: Robotic personalized TKA, ROSA-FuZion technique.

Results Its advantages as compared to other available systems include: radiographs in standing position, collaborative robotic system where the robot completes the surgeon skills, “off-the-shelf” implants, predictive robotic with concept of machine learning incorporated into the system. Two cadaveric studies have reported the high accuracy and reproducibility of this device. This robotic system is recent and currently no clinical series has enough follow-up to report clinical outcomes.

Conclusion The ROSA knee system is a robotically assisted semi-autonomous surgical system with some specific characteristics. The aim of this collaborative robotic system is to improve the accuracy and reliability of the bone resections and the ligament balancing, without replacing the steps well performed by the surgeon.

Keywords ROSA knee system · Robotically assisted system · Total knee arthroplasty · Collaborative robotics · Personalized robotic TKA

✉ Cécile Batailler
cecile-batailler@hotmail.fr

¹ Orthopaedics Surgery and Sports Medicine Department, Croix-Rousse Hospital, Lyon University Hospital, Lyon, France

² Department of Orthopaedic Surgery, Geneva University Hospitals, Geneva, Switzerland

³ Sezione di Chirurgia Protesica ad Indirizzo Robotico—Unità di Traumatologia dello Sport, U.O. Ortopedia e Traumatologia Fondazione Poliambulanza, Brescia, Italy

⁴ Università degli Studi di Pavia, Pavia, Italy

⁵ International Knee and Joint Centre, Abu Dhabi, United Arab Emirates

⁶ Institute for Locomotion, Aix-Marseille University, Marseille, France

Introduction

Improving implants positioning and gap balancing are important goals in total knee arthroplasty (TKA). The use of conventional instrumentation in TKA showed limited accuracy with up to 40% of outliers [1]. In the past few years, new targets in TKA have been defined with more patient-specific targets both for alignment and gap balancing. Restoring the physiological knee kinematics with these techniques can provide excellent functional results when well executed [2], but may also have detrimental effects when alignment is outside the classically accepted $0^\circ \pm 3^\circ$ range [3]. Different types of new technologies, such as computer-assisted surgery, patient-specific instrumentation, and more recently robotic-assisted TKA, have been developed to improve surgical accuracy and reproducibility,

allowing surgeons to reach personalized targets, which may improve patient outcomes and satisfaction after TKA [4]. The development of robotic-assisted surgery has been possible thanks to the technological advancements made during the last 20 years starting with the rise of conventional computer-assisted surgery in the early 2000s. Different types of robotic-assisted systems have been developed with different features and characteristics, depending on robot autonomy, the requirement or not of 3-D pre-operative images, the use of a cutting guide or not, the use of haptic or assistive technologies, and the use of a burr or a saw.

A new robotically assisted system for TKA (ROSA knee System; Zimmer Biomet; Warsaw, IN) has been recently introduced. The previous systems available in the market were either active: the surgeon sets the robotic arm close to the patient and then the robot autonomously performs the surgery [5–8], or haptic: the surgeon pushes the “Go Button” but the robot keeps the instrument within pre-determined boundaries [9–14]. During the last decade, these systems have shown their accuracy and safety, but they also have some limits in terms of usability, as the movements of the surgeon are constrained on a predefined surface. Thus, the surgeon may have the feeling to lose the control of the operation or being framed into a certain pattern. The new system presented here had the intention to keep the surgeon active, performing the cut while the robot is positioning and holding the cutting jig based on the pre-operative plan made by the surgeon. This can be considered as collaborative robotics, where the surgeon remains in charge of the procedure and collaborates with a smart robotic tool. After a preclinical evaluation in Australia in 2018, this device has been officially launched in March 2019 in the Middle East (Abu Dhabi), and thereafter in the US and in Europe. The ROSA knee system has been developed based on the accuracy of the ROSA brain [15, 16]. ROSA stands for Robotic Surgical Assistant and is able to ideally position the instruments allowing the surgeon to perform the surgery with a high accuracy and reproducibility. The ROSA system offers both image-less and image-based options using 2D X-rays which are then transformed into a 3D model of the patient’s knee. The integration of real-time intraoperative ligament balancing allows the surgeon to perform personalized Robotic Knee arthroplasties.

The aim of this paper was: (1) to describe the concept and the surgical technique of the ROSA knee system for TKA; (2) to describe its advantages and potential limits; and (3) to report the early experience with this system.

Concept of ROSA knee

Most of the surgeons involved in the development of the ROSA knee platform had previous experience with the pre-existing platforms. They have outlined the constraints

and limits of active and haptic systems, and have listed the necessary and desirable features and characteristics of the device. The goal during the development phase of ROSA was to keep the surgeon active and at the center of the operation: here, the surgeon handles the saw and performs the cuts while the robotic arm, which is equipped with a cutting jig, places and holds the guide at the right place, with a high accuracy and reproducibility. After the planning step, the robot places the jig according to the surgical plan for the tibial and the distal femoral cuts, and determines the position of the 4-in-1 resection guide. The robotic arm has 3 modes of action: automatic, collaborative and static. In the automatic mode, when the tip of the robotic arm is far from the knee, the robot moves in the space on its own. When approaching the knee and the surgical field, the robot switches to a so-called collaborative mode. In this mode, the surgeon can collaborate with the robotic arm by applying a gentle force on the guide to move it to the bone within the cutting plane. At this step, the movement of the robotic arm is restricted to the planned cutting surface, but follows the knee and constantly adapts to any joint movement. The position of the jig is verified by looking at live cut values on the screen, then fixed, before switching to a static mode which allows the surgeon to perform the different cuts. Perfectly flat cuts are obtained very naturally using a conventional saw and very reliably due to the rigid construct achieved by the robotic arm. After performing the cut, the jig is freed from the bone and the robot switches back to a collaborative mode to perform the next cut. The aim is to keep a smooth surgical flow and increase the efficiency, the accuracy, and the reliability of the conventional surgical steps. The ROSA knee platform has been developed to assist the surgeon for the distal femoral cut, the sizing and positioning of the femoral component (including the determination of the rotation), the tibial cut and the ligament balance.

Surgical technique

Principles of image-based or image-less robotic system

This robotic system has two options for case creation and planning: image-based with 3D virtual model derived from 2D full-length preoperative plain radiographs; or image-less, exclusively based on intraoperative landmarks acquisition.

For the image-based procedure, standard 2D X-rays are converted into a patient-specific 3D model of the knee thanks to a dedicated algorithm. Using a conventional radiographic system, standing long-leg AP and lateral radiographs are taken with two calibrated trackers disks positioned on the thigh and the calf with a Velcro strap. The 2D radiographic data are then uploaded into a secure image

segmentation platform. Using validated algorithms, engineers are able to create a patient-specific 3D virtual model of the patient's knee. Similarly, to what was done for PSI TKA, a 3-D planning of the surgery is then created on these virtual 3-D models and uploaded on the surgeon's platform for edition (Fig. 1). With this technique, implant sizes and positioning can be anticipated at this step. The advantages of an image-based robotic system on the clinical outcomes are not yet demonstrated in knee arthroplasty [17, 18].

For the image-less option, the standard preoperative radiographs are performed according to the surgeon's practice. The planning during the surgery is based on the bony landmarks and on the ligament balancing collected at the beginning of the surgery. The image-less option appears to be also very accurate [19, 20].

Set-up

The ROSA knee platform comprises two main components which are positioned on opposite sides of the operating table. A robotic unit which consists of a robotic arm and a touch screen, and an optical unit including an infra-red camera mounted on a dedicated arm and a touchscreen. The ROSA knee TKA universal cutting guide is mounted at the tip of the robotic arm. This jig can be used with any of the Zimmer Biomet TKA implants (Persona[®], NexGen[®], and Vanguard[®]). The robotic and optical units, the instruments, and patient's bones are linked by infra-red optical reference frames.

The surgeon and the robot are positioned on the same side of the patient, and the optical system is positioned on the other side of the table (Fig. 2). The robot can be draped and aligned to the patient's knee at the beginning of the procedure in a so-called set-up position. An automatic calibration is performed to link the robotic arm and the camera.

Registration and planning

The robotic procedure requires the installation of two rigid bodies, one in the femur and one in the tibia, as for all the current systems of robotic surgery. The trackers can be installed inside or outside the surgical incision depending on the surgeon's preference. They should be far enough of the knee to avoid any conflict with the instruments during surgery and placed distal enough on the tibial side to not interfere with the keel preparation of the tibial component.

Once the trackers are set in the bone, femoral and tibial bony landmarks are acquired. First the localization of the femoral head center is established by capturing 14 distinct

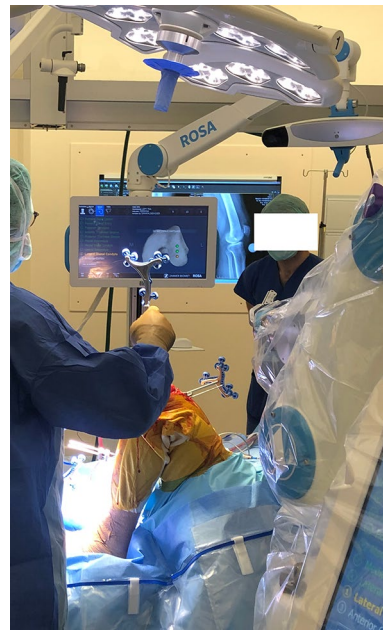
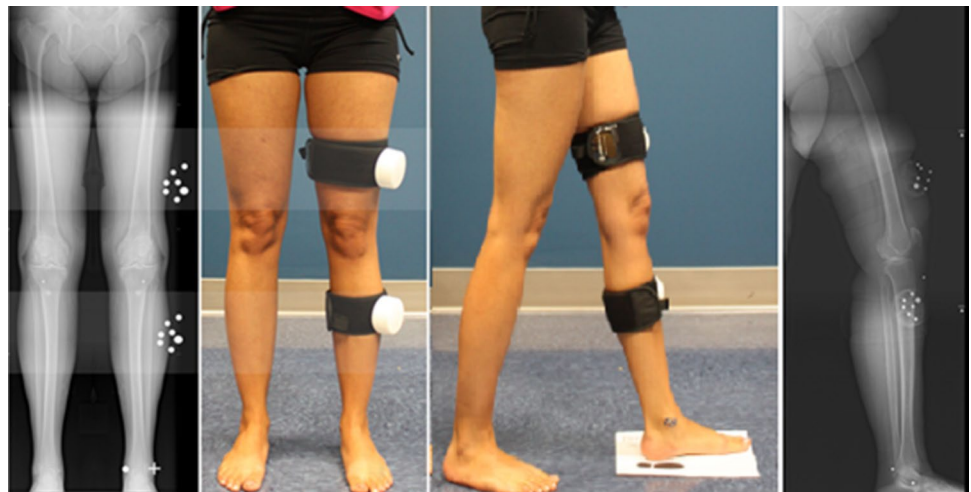

Fig. 2 Robotic system positioning in OR

Fig. 1 Radiographs in standing position (AP view and lateral view) with the calibrated markers to obtain a 3D virtual model, used for the per-operative planning



positions of the hip during circumduction. The mechanical axis of the femur is determined with the femoral head center and the distal femoral canal entry point. Further landmark registration points of the distal femur include the medial and lateral distal condyles, the medial and lateral epicondyles. The posterior condyles are used to determine the posterior condylar axis, and the anterior and posterior trochlear groove is used to determine the Whiteside's line. The anterior cortex is used for femoral sizing and A/P translational positioning and to determine if notching will occur. The mechanical axis of the tibia is determined by the medial and lateral malleoli distally and the tibial canal entry point. The tibia rotation is determined by the medial third of the tibial tubercle and the PCL insertion. The medial and lateral plateau resection references are also collected. Importantly, when landmarking articular surfaces, care should be taken not to pierce the cartilage with the ROSA knee registration Pointer.

The next step assesses the knee frontal laxity using varus and valgus stresses at different angles of the knee flexion, the most important being the extension and 90° of knee flexion. But the laxity can also be tested and recorded at 30°, 45°, 60° and 120° of knee flexion. The values obtained can then be used to guide implant frontal, sagittal and rotational positioning, implant sizing and consecutively soft tissue balancing. This evaluation of the laxity can be performed before the planning but after the approach and osteophytes removal; during the bone preparation if needed with a spacer; at the end of the procedure with the trials or the definitive implants. This evaluation can be done at any time to adapt the surgical planning if needed. The surgeon can also decide not to use the ligamentous evaluation and perform a pure measured resection technique without considering the ligament at all, as when using a PSI technique.

After the landmarks collection and the assessment of the frontal laxity, the surgeon can perform the final planning according to her/his surgical preferences. During this planning, several parameters are determined: the femoral and tibial component sizes, the orientations of the bone cuts (femoral distal, posterior and anterior, tibial) and their thickness based on the bony and ligaments references. Predictive values of the final gaps and alignment are provided. (Fig. 3).

Bony preparation

The sequence of bone cuts, either tibia or femur first, can be individualized based on the surgeon's preference. After finalizing the planning, the surgeon can switch to the "Resection panel" on the touch screen. Pressing the button femoral or tibial resection will send ROSA to the knee in automatic mode. Once the tip of the ROSA arm reaches the surgical field, a switch to collaborative mode occurs and the surgeon is allowed to bring the jig exactly where it should be, while ROSA remains coplanar and maintains the accuracy of the

cut in terms of frontal and sagittal alignment, and thickness of resection (Fig. 4). Live cut values are shown on the screen, with the agreement between the planned values and the actual ones (compensating for any knee motion). Once the jig is aligned with the planned femoral or tibial cut, two pins are installed to fix the jig and the cut can be performed using a conventional saw. After the bone cut, the validation tool is placed on the bony resection to confirm the adequation between the planned and the actual cut. Each cut can be readjusted anytime if needed.

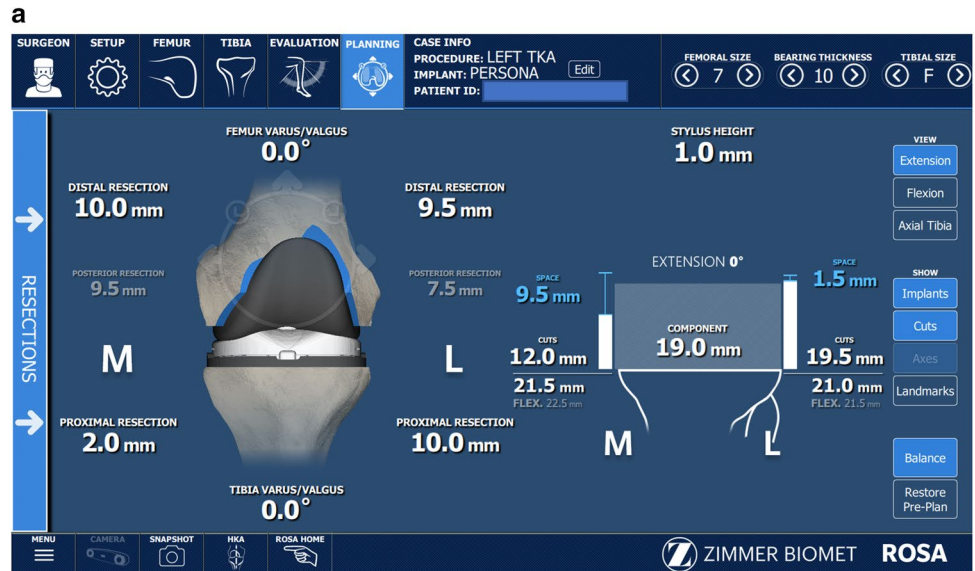Different surgical strategies can be performed with the ROSA knee, according to the surgeon's preferences. All the classic techniques can be used with ROSA: measured resection, gap balancing, functional alignment, kinematic alignment. Some techniques recently developed are more ROSA-specific: Robotic personalized TKA and ROSA-FuZion technique. The software has been created to navigate between the different surgical steps according to the surgeon's preference for the alignment, the implants positioning, but also the ligament balancing in flexion and extension.

Classic surgical techniques

The conventional technique aims at achieving a neutral limb alignment (with a $0^\circ \pm 3^\circ$ range), by implanting the femoral and tibial components perpendicular to the mechanical axis [21]. The cuts are either independent of the other (starting usually by the distal femur) or dependent, meaning that the distal and posterior femoral cuts are performed parallel to the tibial cut. Ligament balancing is obtained by a standardized sequence of soft tissue release to equalize the medial and lateral compartments, as well as flexion and extension gaps. Knee joint stability relies on the conformity of the prosthetic components and tensioning of the ligaments in flexion and extension.

The case of a ROSA TKA implanted for a varus deformity will be taken as an example. Once the trackers have been installed, the knee is exposed; the menisci are completely excised together with the cruciate ligaments depending on the type of prosthesis; the medial osteophytes are removed which opens the gap medially and is usually sufficient to balance the knee. Femoral and tibial landmarking are performed at this step. The knee is then assessed in terms of motion and laxity, and the femoral cuts are set by the surgeon on the planning panel overview. Typically, with the mechanical alignment technique, the amount of bone to be resected will be greater on the lateral side on the tibia, on the medial side on the distal femur, and on the medial side on the posterior condyle. After the distal femoral cut and the tibial cut are performed, the extension is checked with a spacer block. The amount of residual varus and flexor contracture is visualized on the screen. Further release of the medial compartment is performed by elevating the medial collateral ligament, and in

Fig. 3 The orientation of bone resections, the implant positioning and their sizing allow to adjust the gap balancing in extension (a) and in flexion (b), and the limb alignment (c). The manipulation of the implants will give “live” feedback on implants alignment and gaps in flexion and extension

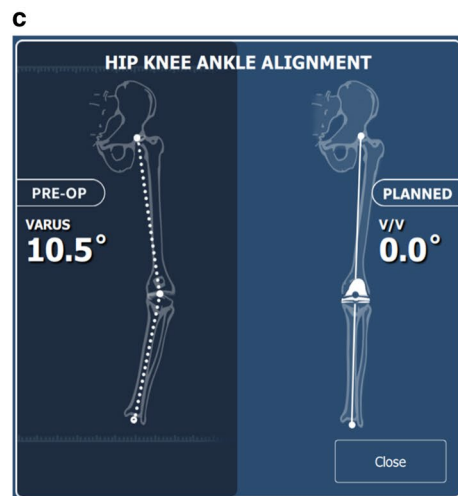
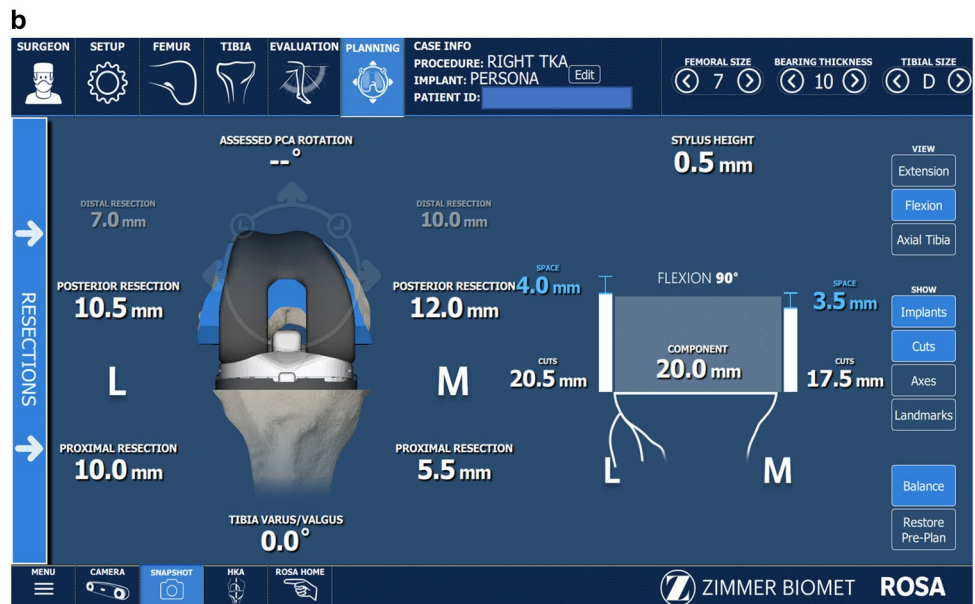
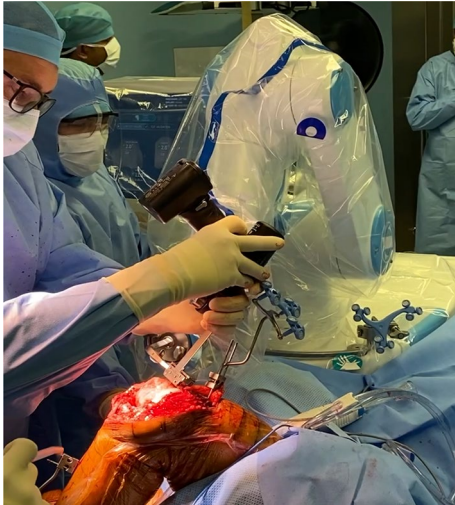



Fig. 4 When the jig is fixed to the bone and the robot is locked in place, an extremely solid construct is provided, allowing the bone cut by the surgeon

severe constitutional varus knees, by the detachment of the semi-membranous tendon. The knee is flexed, and the ROSA cut guide is moved to the bone to drill the 4-in-1 holes. Rotational alignment is adjusted to the surgical epicondylar axis, which is 3° externally rotated relative to the posterior condylar line. The cut guide is then disengaged, and the 4-in-1 cuts are performed according to the planning. The trial implants are inserted, and final knee evaluation is performed to check for full range of motion, mechanical axis, and joint stability both in extension and flexion.

ROSA-specific techniques

Personalized robotic TKA The concept of personalized robotic TKA is to recreate the patient anatomy, avoid ligament release, restore the joint line orientation and the limb alignment. The first step is to verify the absence of major extra-articular deformity on the pre-operative X-rays as this technique is not intended to correct a more than 10° extra-articular deformity inside the joint. The second step is to look at the patellar tracking and make sure that there is not patellar tilt of more than 30°. Intra-operatively, the ROSA set-up and landmarks registration are performed as previously described. The ligament laxity is recorded at 0° and 90°. The femoral planning is then done to restore the anatomy of the femur in a kinematic manner (compensating for the wear), the implant being intended to recreate the anatomy as it was before the OA. Persona TKA is ideal for that (anatomic design with small increment of sizes). The femur is then positioned on average between 0° and 3° of valgus and aligned to the posterior condylar axis in the absence of preoperative patellar mal-tracking. The tibial cut is planned

based on the residual laxity to obtain at the end a perfectly symmetrical gap in extension (aiming for 1 mm of laxity both for the medial and lateral side of the knee). The second parameter is the space in flexion intended to be trapezoidal with a perfectly stable medial compartment all along the arc of knee flexion and some opening (from 2 to 6 mm depending of the initial laxity of the knee at the beginning of the procedure) in the lateral compartment. ROSA is used to perform all the cuts based on this planning, femur first and then the tibia to optimize exposure and the surgical flow.

Fuzion technique An optional feature of ROSA knee is the Femoral Rotation Tool, which guides the anterior and posterior rotational cuts of the femur based on a balanced flexion gap. This method is extrapolated from the FuZion method of the conventional technique. The femoral distal cut and the tibial cut are performed first. Then, the ROSA knee system will provide quantitative information about ligament laxity and tension in extension after the surgeon performs a distraction test. During this step, the Fuzion instrument has a 9 mm shim in place. ROSA Knee will accurately measure and record the values of the extension gap and indicate the frontal alignment. The knee is then positioned at 90° of flexion and the Fuzion instrument is positioned again without the 9 mm shim. FuZion® instrument is tensioned to equally tension the medial and lateral compartments in flexion. ROSA knee will record the flexion gap values and assess the femoral component rotation to match the extension gap. ROSA will then ideally position the 4-in-1 femoral resection bloc to obtain the ideal femoral rotation.

Trials and definitive implants

The trial implants are positioned, and the postoperative knee state evaluation is performed to assess the knee balance and range of motion (Fig. 5). If the results are approved, the final components can be implanted.

Advantages and limits

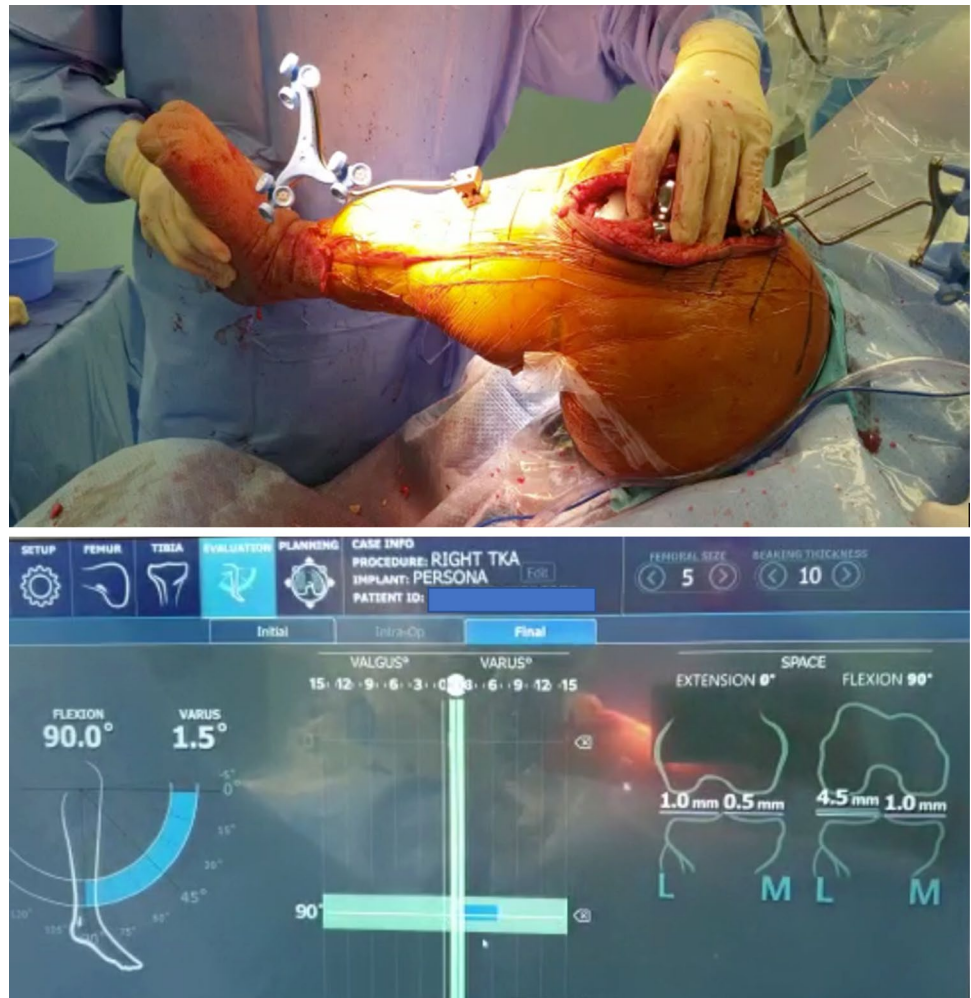
The characteristics of this system are simplicity, preservation of the surgical flow, minimization of extra-time related to robotic surgery, while achieving high levels of accuracy for the orientation of the bone cuts and resection thickness.

The advantages and limits of the ROSA system as compared to other available systems can be summarized as follows:

Radiographs in standing position

Compared to CT scans, the use of plain radiographs is less costly, requires less radiation exposure, and is less

Fig. 5 Evaluation with the trials or definitive implants to assess the range of motion, the gap balancing in flexion and extension



inconvenient to the patient [18]. The image-based system consists of a 3D virtual model derived from plain full-length radiographs, whose the accuracy and the reliability have been recently demonstrated [22]. The radiographs are performed in a standing position. Contrary to a CT scan performed in supine position, the radiographs of the ROSA knee show a knee in a functional position, that means a full weight-bearing knee. These radiographs allow a more functional analysis of the osteoarthritic knee. If needed, ROSA Knee can be also used without imaging, and still remains very accurate which could be also considerate as an advantage in terms of organization.

Collaborative robotic system

The ROSA knee system is considered as a collaborative robotic system, where the robot is holding and placing the cutting jig, while the surgeon keeps the tactile “feel” and remains in full control of sawing through the jig. The concept of the system is to complete the surgeon skills and not to serve as a substitute for the tasks that are easily and well

performed by the surgeon. The sequence of bone cuts, the implant positioning, the limb alignment, and the targets of ligament balancing, can be individualized based on the surgeon’s preferences.

This system must remain easy to manipulate and should not require much time for the set-up as compared to a conventional technique. That is why the landmark’s acquisition is fast without bone morphing or preoperative planning. The planning during the surgery is also simplified to visualize all data on a few screens. To perform the bone resections, only one cutting jig is necessary, easily manipulated with the three modes of action. The system has been conceived not to add steps during the surgery, but just to help the surgeon to improve his accuracy for the bone resections and the ligament balancing.

Implants

This system is associated with femoral and tibial implants with satisfactory outcomes and with good positioning in international registries and the literature [23–26]. The tibial

component is anatomical, allowing an optimal bone coverage [24, 25]. This “off-the-shelf” knee arthroplasty is appropriate for the majority of the patients, with a large increment of femoral sizes. The aim of these “personalized” implants associated to the accuracy of the robotic system is to restore more easily a native knee, without needing a customized implant.

Predictive robotics

With the rise of robotic surgery and new technologies, the surgical procedure becomes easier, more accurate, more reliable, which may represent an important step towards the improvement of patient outcomes and satisfaction after TKA. One of the missing features currently is mainly the target: “where should we go?” Understanding how other groups of variables (other than the surgical quality), such as patient-specific characteristics, knee deformities, per-operative settings influence clinical outcomes, becomes increasingly important [27, 28]. Conceivably, using relevant data points incorporated into an algorithm (preoperative clinical data, surgical data), the surgeon could improve his practice with this predictive model and incorporate this machine learning in the robotic system. That is why the OrthoIntel Orthopedic Intelligence Platform connects the pre-, intra- and post-operative data gathered through the mymobility application and allows analyzing surgical decisions with quantifiable data provided by the robotic system. The concept is to “close the loop”: learn from every surgery to make the next one better. The analysis of surgical data combined with clinical outcomes could improve progressively the TKA procedure.

Limits

Several limits exist also with this robotic system. First, all robotic-assisted TKAs have a significant cost and cannot be available for every surgeon. Second, the significant improvement of the functional outcomes of patients with the use of robotic system is not yet demonstrated. Third, there is also a learning curve with this robotic system, mainly for the surgical planning. Fourth, like every robotic or navigation system, the surgical planning on the screens can be difficult and needs some experience to be relevant and efficient. The data reported on the planning screens are numerous and can sometimes be confusing for the surgeon. And if the surgical planning is not appropriate, there is no feedback of the robotic system to improve the planning currently. Finally, the specific complications of the robotic system, such as breakage of pins or fracture on the pins holes, remain uncommon and can be avoided with better pin placement techniques [29].

Pre-clinical validation

This robotic system is recent and currently no clinical series has enough follow-up to report clinical outcomes. Nevertheless, two cadaveric studies have reported the accuracy of this device. Parratte et al. [19] have demonstrated the accuracy and the reproducibility of this robotic system with an imageless mode in a series of 30 cadaveric knees. The authors have compared three different measurements: the per-operative planning of the bone cuts performed with the ROSA knee system, the real bone cuts measured with a validated computer-assisted navigation system (ORTHOsoft; Zimmer Biomet) [30, 31], and the resection thickness for each cut measured with a caliper. To standardize the procedure, the HKA target was 180°, with 90° for both the tibia and femoral coronal angles. They reported that the cuts performed using ROSA knee were very accurate. Regarding the resection angles, there were no significant differences between the planned and the measured values, except for femoral flexion that had a mean difference of -0.95° . For the resection thickness values, no differences were observed except for the distal medial femoral cut and for the medial proximal tibial cut. The HKA mean difference was computed at $-0.03^\circ \pm 0.87^\circ$. In another cadaveric study, Seidenstein et al. [20] have compared the accuracy of the ROSA knee system with a conventional TKA technique. There were two TKA groups: a conventional group of 20 knees operated by conventional technique and a robotic group of 14 knees operated with the ROSA knee system. Each bone resection was controlled by the handheld validation tool of the robotic system and measured with a caliper. The accuracy of bone resection angles was significantly improved for all values in the robotic group compared to the conventional group ($p < 0.05$). For the robotically assisted knees, the accuracy of all bone resection angles was below 0.6° , except for the sagittal femoral cut. The accuracy of all bone resection levels was below 0.7 mm. All values of the robotic group had 100% of cases within 2 mm of target, except for the distal femoral resection (93%). This robotic system provided accurate bone resections with fewer outliers compared than conventional technique. The distal femoral cut is a little less accurate than the others (sagittal plan and thickness) but remains more accurate than with the conventional ancillary. These results are similar to other TKA robotic systems [9, 14, 32–34]. The clinical studies are in process to assess the outcomes for the patients.

Conclusion

The ROSA knee system is a robotically assisted semiautonomous surgical system with some specific characteristics compared to the previous robotic system. The aim of this collaborative robotic system is to improve the accuracy

and the reliability of the bone resections and the ligament balancing, without replace the steps well performed by the surgeon. The preliminary results of this system reported a good reproducibility and accuracy in the TKA procedures.

Funding There is no funding source.

Declarations

Conflict of interest CB: Grant from SoFCOT. DH: Consultant for Zimmer Biomet; Grants from Fondation pour la Recherche Ostéo-Articulaire. FB: Consultant for Zimmer Biomet and Limacorporate; Grants from Limacorporate; Royalties from Zimmer Biomet and Limacorporate. SP: Royalties from Zimmer Biomet and Newclip; Consultant for Zimmer Biomet; Treasurer for European Knee Society.

Ethical approval This article does not contain any studies with human participants or animals performed by any of the authors.

Informed consent Not applicable.

References

1. Hetaimish BM, Khan MM, Simunovic N, Al-Harbi HH, Bhandari M, Zalzal PK (2012) Meta-analysis of navigation vs conventional total knee arthroplasty. *J Arthroplasty* 27(6):1177–1182. <https://doi.org/10.1016/j.arth.2011.12.028>
2. Courtney PM, Lee GC (2017) Early outcomes of kinematic alignment in primary total knee arthroplasty: a meta-analysis of the literature. *J Arthroplasty* 32(6):2028–2032. <https://doi.org/10.1016/j.arth.2017.02.041>
3. Lee BS, Cho HI, Bin SI, Kim JM, Jo BK (2018) Femoral component varus malposition is associated with tibial aseptic loosening after TKA. *Clin Orthop Relat Res* 476(2):400–407. <https://doi.org/10.1007/s11999-0000000000000012>
4. Batailler C, Swan J, Sappey Marinier E, Servien E, Lustig S (2020) New technologies in knee arthroplasty: current concepts. *J Clin Med*. <https://doi.org/10.3390/jcm10010047>
5. Liow MH, Chin PL, Tay KJ, Chia SL, Lo NN, Yeo SJ (2014) Early experiences with robot-assisted total knee arthroplasty using the DigiMatch ROBODOC(R) surgical system. *Singap Med J* 55(10):529–534. <https://doi.org/10.11622/smedj.2014136>
6. Bellemans J, Vandenuecker H, Vanlauwe J (2007) Robot-assisted total knee arthroplasty. *Clin Orthop Relat Res* 464:111–116. <https://doi.org/10.1097/BLO.0b013e318126c0c0>
7. Song EK, Seon JK, Park SJ, Jung WB, Park HW, Lee GW (2011) Simultaneous bilateral total knee arthroplasty with robotic and conventional techniques: a prospective, randomized study. *Knee Surg Sports Traumatol Arthrosc* 19(7):1069–1076. <https://doi.org/10.1007/s00167-011-1400-9>
8. Song EK, Seon JK, Yim JH, Netravali NA, Bargar WL (2013) Robotic-assisted TKA reduces postoperative alignment outliers and improves gap balance compared to conventional TKA. *Clin Orthop Relat Res* 471(1):118–126. <https://doi.org/10.1007/s11999-012-2407-3>
9. Hampp EL, Chughtai M, Scholl LY, Sodhi N, Bhowmik-Stoker M, Jacofsky DJ et al (2019) Robotic-arm assisted total knee arthroplasty demonstrated greater accuracy and precision to plan compared with manual techniques. *J Knee Surg* 32(3):239–250. <https://doi.org/10.1055/s-0038-1641729>
10. Marchand RC, Sodhi N, Khlopas A, Sultan AA, Harwin SF, Malkani AL et al (2017) Patient satisfaction outcomes after robotic arm-assisted total knee arthroplasty: a short-term evaluation. *J Knee Surg* 30(9):849–853. <https://doi.org/10.1055/s-0037-1607450>
11. Smith AF, Eccles CJ, Bhimani SJ, Denehy KM, Bhimani RB, Smith LS et al (2019) Improved patient satisfaction following robotic-assisted total knee arthroplasty. *J Knee Surg*. <https://doi.org/10.1055/s-0039-1700837>
12. Batailler C, Fernandez A, Swan J, Servien E, Haddad FS, Catani F et al (2020) MAKO CT-based robotic arm-assisted system is a reliable procedure for total knee arthroplasty: a systematic review. *Knee Surg Sports Traumatol Arthrosc*. <https://doi.org/10.1007/s00167-020-06283-z>
13. Collins K, Agius PA, Fraval A, Petterwood J (2021) Initial experience with the NAVIO robotic-assisted total knee replacement: coronal alignment accuracy and the learning curve. *J Knee Surg*. <https://doi.org/10.1055/s-0040-1722693>
14. Bollars P, Boeckxstaens A, Mievis J, Kalaai S, Schotanus MGM, Janssen D (2020) Preliminary experience with an image-free handheld robot for total knee arthroplasty: 77 cases compared with a matched control group. *Eur J Orthop Surg Traumatol* 30(4):723–729. <https://doi.org/10.1007/s00590-020-02624-3>
15. Miller BA, Salehi A, Limbrick DD Jr, Smyth MD (2017) Applications of a robotic stereotactic arm for pediatric epilepsy and neurooncology surgery. *J Neurosurg Pediatr* 20(4):364–370. <https://doi.org/10.3171/2017.5.PEDS1782>
16. De Benedictis A, Trezza A, Carai A, Genovese E, Procaccini E, Messina R et al (2017) Robot-assisted procedures in pediatric neurosurgery. *Neurosurg Focus* 42(5):7. <https://doi.org/10.3171/2017.2.FOCUS16579>
17. Jacofsky DJ, Allen M (2016) Robotics in arthroplasty: a comprehensive review. *J Arthroplasty* 31(10):2353–2363. <https://doi.org/10.1016/j.arth.2016.05.026>
18. Ponzio DY, Lonner JH (2015) Preoperative mapping in unicompartmental knee arthroplasty using computed tomography scans is associated with radiation exposure and carries high cost. *J Arthroplasty* 30(6):964–967. <https://doi.org/10.1016/j.arth.2014.10.039>
19. Parratte S, Price AJ, Jeys LM, Jackson WF, Clarke HD (2019) Accuracy of a new robotically assisted technique for total knee arthroplasty: a cadaveric study. *J Arthroplasty* 34(11):2799–2803. <https://doi.org/10.1016/j.arth.2019.06.040>
20. Seidenstein A, Birmingham M, Foran J, Ogden S (2020) Better accuracy and reproducibility of a new robotically-assisted system for total knee arthroplasty compared to conventional instrumentation: a cadaveric study. *Knee Surg Sports Traumatol Arthrosc*. <https://doi.org/10.1007/s00167-020-06038-w>
21. Insall J, Scott WN, Ranawat CS (1979) The total condylar knee prosthesis. A report of two hundred and twenty cases. *J Bone Joint Surg Am* 61(2):173–180
22. Masse V, Ghate RS (2021) Using standard X-ray images to create 3D digital bone models and patient-matched guides for aiding implant positioning and sizing in total knee arthroplasty. *Comput Assist Surg (Abingdon)* 26(1):31–40. <https://doi.org/10.1080/24699322.2021.1894239>
23. Bizzozero P, Bulaid Y, Flecher X, Ollivier M, Parratte S, Argenson JN (2018) Morphometric tibial implant decreases posterior overhang rate and improves clinical outcomes: results of a prospective, matched controlled study. *J Arthroplasty* 33(9):2804–2809. <https://doi.org/10.1016/j.arth.2018.04.020>
24. Stulberg SD, Goyal N (2015) Which tibial tray design achieves maximum coverage and ideal rotation: anatomic, symmetric, or asymmetric? An MRI-based study. *J Arthroplasty* 30(10):1839–1841. <https://doi.org/10.1016/j.arth.2015.04.033>
25. Dai Y, Scuderi GR, Bischoff JE, Bertin K, Tarabichi S, Rajgopal A (2014) Anatomic tibial component design can increase tibial

- coverage and rotational alignment accuracy: a comparison of six contemporary designs. *Knee Surg Sports Traumatol Arthrosc* 22(12):2911–2923. <https://doi.org/10.1007/s00167-014-3282-0>
26. Kim YH, Park JW, Lim HM, Park ES (2014) Cementless and cemented total knee arthroplasty in patients younger than fifty five years. Which is better? *Int Orthop* 38(2):297–303. <https://doi.org/10.1007/s00264-013-2243-4>
 27. Bini SA, Shah RF, Bendich I, Patterson JT, Hwang KM, Zaid MB (2019) Machine learning algorithms can use wearable sensor data to accurately predict six-week patient-reported outcome scores following joint replacement in a prospective trial. *J Arthroplasty* 34(10):2242–2247. <https://doi.org/10.1016/j.arth.2019.07.024>
 28. Kunze KN, Polce EM, Sadauskas AJ, Levine BR (2020) Development of machine learning algorithms to predict patient dissatisfaction after primary total knee arthroplasty. *J Arthroplasty* 35(11):3117–3122. <https://doi.org/10.1016/j.arth.2020.05.061>
 29. Beldame J, Boisrenoult P, Beaufils P (2010) Pin track induced fractures around computer-assisted TKA. *Orthop Traumatol Surg Res* 96(3):249–255. <https://doi.org/10.1016/j.otsr.2009.12.005>
 30. Scholes C, Sahni V, Lustig S, Parker DA, Coolican MR (2014) Patient-specific instrumentation for total knee arthroplasty does not match the pre-operative plan as assessed by intra-operative computer-assisted navigation. *Knee Surg Sports Traumatol Arthrosc* 22(3):660–665. <https://doi.org/10.1007/s00167-013-2670-1>
 31. Lustig S, Scholes CJ, Oussedik S, Coolican MR, Parker DA (2014) Unsatisfactory accuracy with VISIONAIRE patient-specific cutting jigs for total knee arthroplasty. *J Arthroplasty* 29(1):249–250. <https://doi.org/10.1016/j.arth.2013.05.020>
 32. Casper M, Mitra R, Khare R, Jaramaz B, Hamlin B, McGinley B et al (2018) Accuracy assessment of a novel image-free handheld robot for total knee arthroplasty in a cadaveric study. *Comput Assist Surg (Abingdon)* 23(1):14–20. <https://doi.org/10.1080/24699322.2018.1519038>
 33. Jeon SW, Kim KI, Song SJ (2019) Robot-assisted total knee arthroplasty does not improve long-term clinical and radiologic outcomes. *J Arthroplasty* 34(8):1656–1661. <https://doi.org/10.1016/j.arth.2019.04.007>
 34. Koulalis D, O'Loughlin PF, Plaskos C, Kendoff D, Cross MB, Pearle AD (2011) Sequential versus automated cutting guides in computer-assisted total knee arthroplasty. *Knee* 18(6):436–442. <https://doi.org/10.1016/j.knee.2010.08.007>