



**HAL**  
open science

## Trabecular Metal Cones Combined With Short Cemented Stem Allow Favorable Outcomes in Aseptic Revision Total Knee Arthroplasty.

Christophe Jacquet, Fabien Ros, Sylvain Guy, Sebastien Parratte, Matthieu Ollivier, Jean-Noel Argenson

► **To cite this version:**

Christophe Jacquet, Fabien Ros, Sylvain Guy, Sebastien Parratte, Matthieu Ollivier, et al.. Trabecular Metal Cones Combined With Short Cemented Stem Allow Favorable Outcomes in Aseptic Revision Total Knee Arthroplasty.. The Journal of Arthroplasty, 2021, 36 (2), pp.657–663. 10.1016/j.arth.2020.08.058 . hal-03553385

**HAL Id: hal-03553385**

**<https://hal.science/hal-03553385>**

Submitted on 15 Apr 2022

**HAL** is a multi-disciplinary open access archive for the deposit and dissemination of scientific research documents, whether they are published or not. The documents may come from teaching and research institutions in France or abroad, or from public or private research centers.

L'archive ouverte pluridisciplinaire **HAL**, est destinée au dépôt et à la diffusion de documents scientifiques de niveau recherche, publiés ou non, émanant des établissements d'enseignement et de recherche français ou étrangers, des laboratoires publics ou privés.

# Trabecular Metal Cones Combined With Short Cemented Stem Allow Favorable Outcomes in Aseptic Revision Total Knee Arthroplasty

Christophe Jacquet, MD, Fabien Ros, MD, Sylvain Guy, MD, Sebastien Parratte, MD, PhD, Matthieu Ollivier, MD, PhD, Jean-Noel Argenson, MD, PhD \*

Department of Orthopedics and Traumatology, Institute for Locomotion, St. Marguerite Hospital, Marseille, France

## ARTICLE INFO

### Keywords:

revision TKA  
metaphyseal cone  
rotating hinge knee prosthesis  
short cemented stem  
long uncemented stem  
trabecular metal

## ABSTRACT

**Background:** The purpose of this study was to compare the functional outcomes and implant survivorship at a minimum of 5 years of follow-up of several reconstruction techniques with or without metaphyseal cone and stems of variable length.

**Methods:** A retrospective comparative matched analysis was performed from 2 prospectively collected databases. Only patients who underwent revision total knee arthroplasty procedures for aseptic causes using a single design of rotating hinge knee with a minimum of 5 years of follow-up were analyzed. Patients were separated into 3 groups: trabecular metal (TM) cones + short cemented stems (TM + short stem [SS]), TM cones + long uncemented stems (TM + long stem [LS]), and no cone (NC) + long uncemented stems (NC + LS). A matching process based on age ( $\pm 5$  years) was realized.

**Results:** About 99 patients were included; 33 in the TM + SS group, 33 in the TM + LS group, and 33 in the NC + LS group. The mean time of follow-up was 9.3 years. A significant difference of the improvement of subscale pain, symptom, activities of daily living, quality of life of the Knee Injury and Osteoarthritis Outcome score and knee, function of the Knee Society Score was observed in favor of TM + SS group compared with the 2 other groups. At 8 years of survivorship, the components free of revision for any cause were 90.9% for the TM + SS group, 84.9% for the TM + LS group, and 90.6% for the NC + LS group.

**Conclusion:** The use of a short cemented tibial stem combined with a TM cone in revision total knee arthroplasty offers identical survival rate with better functional outcome compared with the use of a long uncemented stem associated with TM cones or metallic augments at a minimum of 5 years of follow-up.

One or more of the authors of this paper have disclosed potential or pertinent conflicts of interest, which may include receipt of payment, either direct or indirect, institutional support, or association with an entity in the biomedical field which may be perceived to have potential conflict of interest with this work. For full disclosure statements refer to <https://doi.org/10.1016/j.arth.2020.08.058>.

Investigation was performed at Aix Marseille University, APHM, CNRS, ISM, Sainte-Marguerite Hospital, Department of Orthopedics and Traumatology, Institute for Locomotion, Marseille, France.

This research received no specific funding/grant from any funding agency in the public, commercial, or not-for-profit sectors. Local ethic committee approved our study protocol before investigation.

\* Reprint requests: Jean-Noel Argenson, MD, PhD, Department of Orthopedics and Traumatology, Institute for locomotion, St. Marguerite Hospital, 270 Boulevard Sainte Marguerite, BP 29 13274, Marseille, France.

The number of total knee arthroplasty (TKA) is rising and has been projected to grow by 673% from 2005 to 2030 in the United States [1]. Projections reveal that patients younger than 65 years will exceed 50% of population in need of TKA [2]. In consequence, the number of aseptic revision total knee arthroplasty (rTKA) is also inevitably increasing because of implant loosening [3]. Revision knee arthroplasties are often associated with significant bone loss, which can compromise the fixation. The management of bone loss to reconstruct femoral and tibial metaphyseal defects during rTKA is a controversial issue to achieve reliable long-term results. This challenge can be addressed using different techniques and implants; however, the optimal approach has not yet been identified because of insufficient long-term data [4]. Usually during rTKA procedure, the epiphyseal area (zone 1) is inadequate for a good

implant fixation. The fixation has to be at least metaphyseal (zone 2) or both metaphyseal and diaphyseal (zone 2 + 3) [5]. Trabecular metal (TM) tantalum cones (Zimmer, Warsaw, IN) have been proven to be a viable option to manage zone 2 fixation of the rTKA ensuring a reliable, biological, and long-lasting solution. TM cones represent an alternative to structural allografts used in the past and to metallic augments to ensure stable prosthesis fixation in zone 2. TM cones permit better osteointegration because of their physiological properties, close to cancellous bone, and have the potential to maintain long-term biological fixation [4–6]. Following the rules of fixation [7], the metaphyseal fixation alone is not sufficient, and a good zone 3 fixation (diaphyseal) is also mandatory. Two classic modes of fixation have been described for zone 3 fixation (diaphyseal): long uncemented press-fit stems or shorter fully cemented stems. Historically, long press-fit stems have been widely used [8] to optimize the implant alignment and offload the metaphysis. Long press-fit uncemented stems can offload the metaphysis and control the rotational stability and consecutively offer long-term fixation in zone 3 [7]; however, pain located at the stem tip has been described on both the tibial and femoral sides [9]. This pain is related to very high contact pressures and stresses between the tip of the stem and the host bone. This tibial or/and femoral high contact pressure decreases with shorter stems but modifies the stress distribution and theoretically reduces the survival of the implant [10]. To ensure a proper rotational stability while avoiding the stem-tip pain, the use of shorter fully cemented stems has been described as an alternative to long uncemented stems in rTKA [11,12]. It was our hypothesis that the use of TM cones associated with short stems (SSs) can provide a stable and durable fixation with better functional outcomes compared with the other techniques. Therefore, the purpose of the study was to compare the functional outcomes and survival of the implants at a minimum of 5 years of follow-up of several reconstruction techniques using the same rotating hinge knee design prosthesis with or without TM metaphyseal cone and stems of variable length.

## Methods

After review board approval, a retrospective comparative matched analysis was performed from 2 prospectively collected

databases in 2 high-volume knee joint reconstruction centers from the same institute.

A total of 204 patients who underwent rTKA procedures using a single design of rotating hinge knee prosthesis (NexGen RHK Knee, Zimmer-Biomet) from January 2005 to January 2014) were identified.

Exclusion criteria were as follows: a septic cause of revision defined by a preoperative sample or an intraoperative sample positive to a bacterial germ, or postoperative antibiotic therapy, a cavitory tibial bone defect Andersen Orthopaedi Research Institut (AORI) <II, the absence of minimum 5 years of complete clinical and radiographic follow-up, and a contralateral TKA during the follow-up.

Of the 204 patients in the 2 series, 49 septic causes were identified, 18 patients were excluded because of a tibial bone defect AORI <II, 15 patients were lost to follow-up before 5 years, and 5 patients died before 5 years from causes unrelated to their surgery. These patients were excluded from the final clinical outcome and survivorship analysis, although all had well-fixed implants at their latest visit and none had been revised.

Finally, 117 patients met inclusion and exclusion criteria and were identified. After the surgical technique used, it was possible to separate the patients into 3 different groups: 33 patients for the TM + SS group, 38 patients for the TM + long stem (LS) group, and 46 patients for the no cone (NC) + LS group. A matching process (1/1/1) based on age ( $\pm 5$  years) allowed to finally include 33 patients in each group for comparative analysis (Fig. 1). Preoperative data, including age, sex, body mass index, preoperative range of movement, and preoperative patient-reported outcome measure using the Knee Injury and Osteoarthritis Outcome Score (KOOS) and Knee Society Score (KSS), were collected from the routine preoperative questionnaire.

The mean time of follow-up was 9.3 years (range, 5–19). Patient preoperative characteristics are summarized in Table 1.

No significant difference between the 3 groups was observed for all the preoperative parameters.

The most common indication for revision surgery was tibial loosening (30 patients), pain (without stiffness or radiologic abnormalities) (21 patients) and polywear/osteolysis (13 patients) (Fig. 3). Intraoperative AORI grading bone defect is summarized in Table 2.

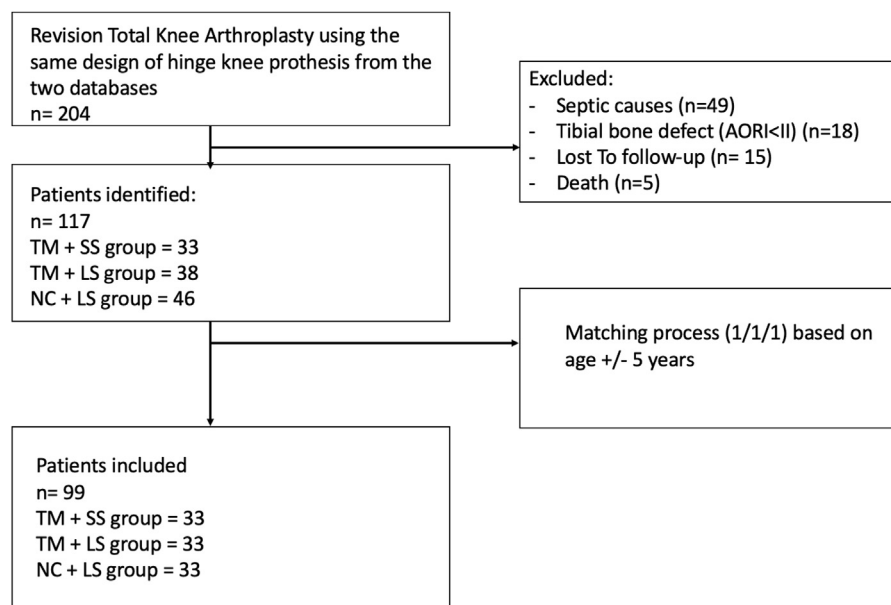
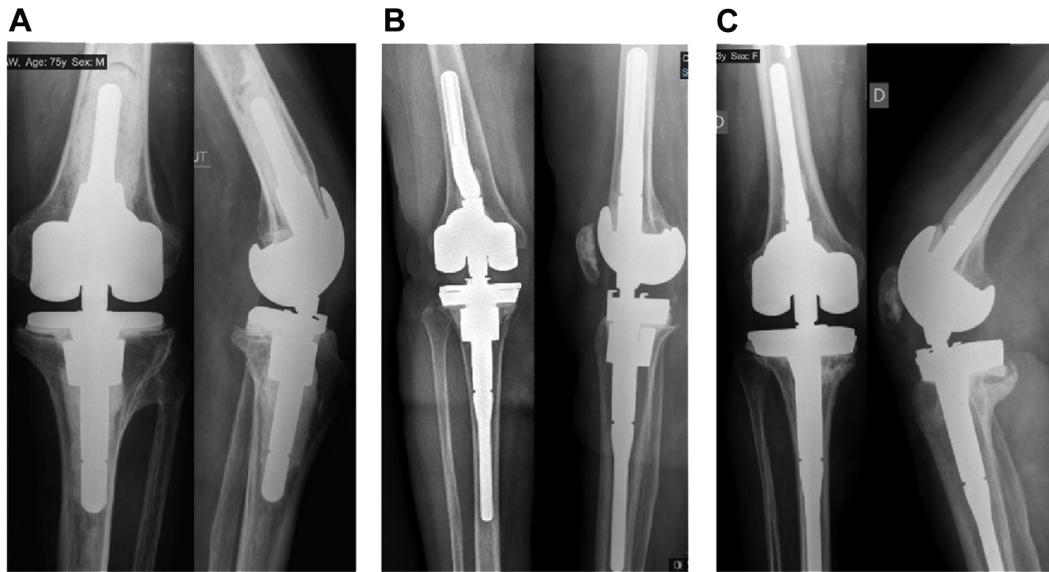


Fig. 1. Flowchart.



**Fig. 2.** X-rays of the 3 different revision total knee arthroplasty reconstructions. A = TM + SS/B = TM + LS/C = NC + LS. TM, trabecular metal; SS, short stem; LS, long stem; NC, no cone.

### Surgical Technique

For the first series (first center), all procedures were performed by 2 trained arthroplasty surgeons, and 66 patients were finally included from this series after the matching process (Fig. 2). In all cases, a tourniquet-less subvastus approach was realized, and bone defects were graded after component removal using the AORI classification system. The choice of surgical techniques (long uncemented stems or short cemented stems) was based on individual surgeons' preferences.

For the first group (TM + SS) (Fig. 2A), femoral implants were inserted systematically with a short cemented stem (diameter of 13 mm/length of 60 mm) after an adequate reaming. In cases of segmental femoral defect (AORI  $\geq$  II, 29 of 33 patients), a TM cone was used. The preparation of femoral cone consisted of initial hand reaming of the femoral metaphysis until achieving endosteal contact.

**Table 1**  
Patient Characteristics.

Characteristics	TM + SS (n = 33)	TM + LS (n = 33)	NC + LS (n = 33)	P
Ages (y)	72.9 ± 2.0	73.4 ± 1.9	71.8 ± 1.9	.90
Preoperative BMI (kg/m <sup>2</sup> )	28.1 ± 0.8	27.7 ± 1.3	28.3 ± 0.6	.95
Preoperative KOOS symptom	19.3 ± 0.9	20.5 ± 1.3	18.5 ± 1.1	.44
Preoperative KOOS pain	21.7 ± 1.2	19.4 ± 1.1	23.9 ± 1.1	.08
Preoperative KOOS ADL	24.3 ± 0.9	22.4 ± 0.9	22.7 ± 0.9	.31
Preoperative KOOS sport	15.1 ± 1.1	12.8 ± 1.1	13.7 ± 1.1	.38
Preoperative KOOS QOL	19.5 ± 0.9	20.8 ± 0.9	19.8 ± 0.9	.56
Preoperative KOOS global	29.9 ± 1.2	29.4 ± 1.2	28.3 ± 1.2	.66
Preoperative KSS knee	41.5 ± 1.9	42.1 ± 1.8	40.8 ± 1.8	.57
Preoperative KSS function	46.6 ± 2.7	47.2 ± 2.6	43.0 ± 2.6	.48
Preoperative KSS total	86.1 ± 4.1	87.2 ± 4.0	91.7 ± 4.0	.19
Preoperative flexion (°)	93.4 ± 2.9	94.2 ± 2.8	91.9 ± 2.8	.84
Preoperative deficit of extension (°)	5.6 ± 1.0	6.2 ± 1.0	6.2 ± 1.0	.90
Follow-up (y)	8.7 ± 1.7	8.9 ± 2.1	9.6 ± 2.4	.75

Data are shown as mean ± standard deviation or frequency (number).

TM, trabecular metal; SS, short stem; LS, long stem; NC, no cone; BMI, body mass index; KOOS, Knee Injury and Osteoarthritis Outcome Score; ADL, activities of daily living; QOL, quality of life; KSS, Knee Society Score.

For the tibial reconstruction, a similar cone preparation was used in all cases, and a TM cone was implanted in all 33 patients. Tibial implant was inserted with a short-cemented stem (diameter of 13 mm/length of 60 mm) after adequate reaming.

For the second group (TM + LS) (Fig. 2B), femoral and tibial implants were inserted systematically with an LS (diameter size dictated by the reaming according to the cork-screw technique [5]/length of 100 mm). Stems were partially cemented using a hybrid technique with cement being applied to the metaphyseal segment only.

A tibial TM cone (33 of 33 patients) and a femoral TM cone (27 of 33 patients) were implanted in case of segmental bone defects using a similar cone preparation.

A rotating hinge prosthesis (NexGen RHK Knee; Zimmer-Biomet) and antibiotic-loaded cement was used in all operations.

For the second series (second center) (NC + LS group) (Fig. 2C), all procedures were performed by 1 trained arthroplasty surgeon, and 33 patients were finally included from this series after the matching process. The same tourniquet-less subvastus approach and bone defect classification was used. No TM cone was available in this center. Femoral and tibial implants were inserted systematically with an LS (diameter size dictated by the reaming according to the cork-screw technique [5]/length of 100 mm) with cement

**Table 2**  
Intraoperative AORI Grading Bone Defect.

Bone Defect	TM + SS (n = 33)	TM + LS (n = 33)	NC + LS (n = 33)	P
Tibial bone defect, n (%)				.65
(AORI classification)				
Type IIa	11 (33)	8 (24)	9 (27)	
Type IIb	17 (52)	18 (55)	16 (49)	
Type III	5 (15)	7 (21)	8 (24)	
Femoral bone defect, n (%)				.3
(AORI classification)				
Type I	4 (12)	6 (18)	7 (21)	
Type IIa	10 (30)	9 (27)	6 (18)	
Type IIb	17 (52)	15 (46)	14 (41)	
Type III	2 (6)	3 (9)	4 (12)	

TM, trabecular metal; SS, short stem; LS, long stem; NC, no cone; AORI, Andersen Orthopaedic Research Institut.

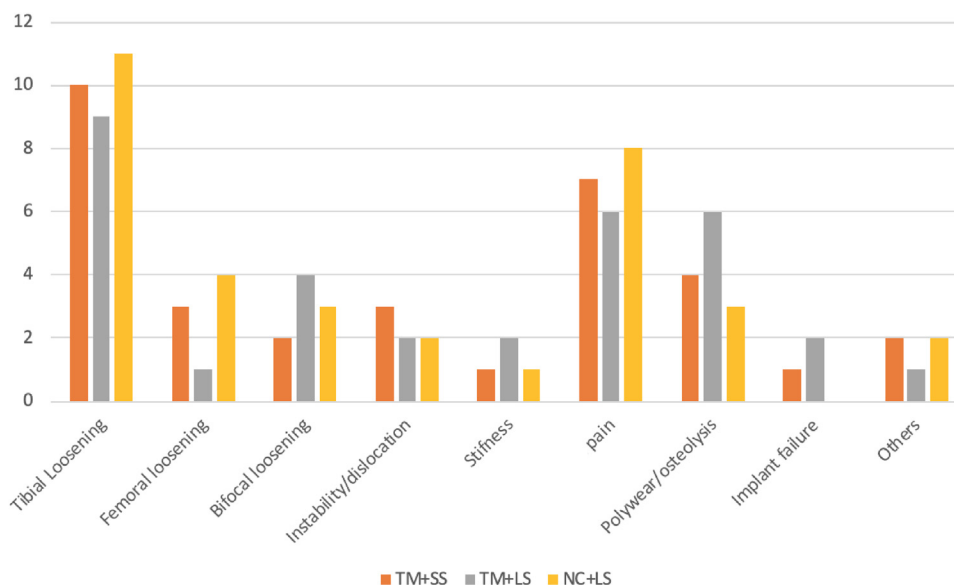


Fig. 3. Indications for revision surgery.

being applied to the metaphyseal segment only. In case of segmental defect, a reconstruction was realized using titanium modular tibial or femoral augments cemented onto component.

A rotating hinge knee prosthesis (NexGen RHK Knee; Zimmer-Biomet) and antibiotic-loaded cement were used in all operations.

For the 2 series, postoperative rehabilitation protocols included immediate weight bearing protected by crutches during the first 2 or 3 weeks according to patient tolerance, and exercises focused on passive and then active recuperation of range of motion. All patients received thromboprophylaxis with low molecular-weight heparin preoperatively and postoperatively for 35 days.

#### Clinical and Radiographic Evaluations

The clinical evaluations were performed by the surgeon preoperatively, at 3 months postoperatively, then at yearly intervals until the last follow-up, during which a radiographical and clinical evaluation was carried out by 1 surgeon not involved in the treatment. The radiographs were collected to assess any signs of loosening. In addition, information regarding complications, range of motion, and stem-end pain was prospectively collected. Patient-reported outcome questionnaires were completed by all patients including the KOOS and KSS.

#### Statistical Analysis

Means and standard deviations were determined for each of the measured and desired anatomic parameters. Normal (Gaussian) distributions were verified to determine adequate statistical testing method (either parametric or nonparametric) to estimate difference between groups in a univariate analysis. For each model, variables with a *P* value less than .1 were kept in the final model.

Finally, a Kaplan-Meier survivorship analysis was performed defining 1 end point: revision for any reason. Statistical analysis was performed using SPSS software (IBM, Armonk, NY) by a trained statistician.

## Results

### Functional Outcome

A significant difference of the  $\Delta$  (difference between preoperative and postoperative at the last follow-up data) subscale pain, symptom, activities of daily living, quality of life (QOL) of the KOOS and knee, and function of the KSS was observed in favor of TM + SS group compared with TM + LS group but also compared with NC + LS group (Table 3). No significant difference was observed for all the KOOS and KSS subscales between TM + LS group and NC + LS group.

No significant difference between the 3 groups was observed for the  $\Delta$  flexion and the  $\Delta$  deficit of extension.

### Survivorship

At last follow-up available, 14 knees required a reoperation (3 for TM + SS, 6 for TM + LS, and 5 for NC + LS groups), and 12 knees required an implant revision (3 for TM + SS, 5 for TM + LS, and 4 for NC + LS groups).

The 2 knees (1 from the TM + LS group and 1 from NC + LS group) reoperated but not revised were successfully treated with irrigation and debridement, polyethylene liner exchange with component retention, and appropriate antibiotic treatment because of an acute infection. The causes of the revision were chronic infections (10), dislocation (1), and postoperative periprosthetic femur fracture (1). There were no reoperations because of aseptic tibial or femur loosening or implant failure.

Regarding our first endpoint, at 8 years of survivorship of the components free of revision for any cause was  $90.9\% \pm 5.0\%$  for the TM + SS group,  $84.9\% \pm 6.2\%$  for the TM + LS group, and  $90.6\% \pm 5.2\%$  for the NC + LS group (Fig. 4).

## Discussion

The main finding of this study was that the use of a short cemented stem combined with a TM metaphyseal cone offers identical survival rate with a minimum of 5 years of follow-up

**Table 3**

Postoperative Functional Outcomes/ $\Delta$  = Difference Between Preoperative and Postoperative at the Last Follow-Up Data.

Characteristics	TM + SS (n = 33)	TM + LS (n = 33)	NC + LS (n = 33)
$\Delta$ KOOS global	29.7 $\pm$ 2.9	23.2 $\pm$ 2.6	23.7 $\pm$ 2.9
$\Delta$ KOOS symptom	35.1 $\pm$ 2.3 <sup>a</sup>	20.1 $\pm$ 2.6	23.9 $\pm$ 2.1
$\Delta$ KOOS ADL	37.8 $\pm$ 2.5 <sup>b</sup>	27.2 $\pm$ 2.1	20.6 $\pm$ 2.8
$\Delta$ KOOS sport	24.7 $\pm$ 1.5	20.9 $\pm$ 1.4	19.5 $\pm$ 1.4
$\Delta$ KOOS QOL	38.3 $\pm$ 2.0 <sup>c</sup>	24.6 $\pm$ 2.0	28.6 $\pm$ 2.2
$\Delta$ KOOS pain	43.3 $\pm$ 2.4 <sup>d</sup>	27.5 $\pm$ 2.6	21.9 $\pm$ 2.3
$\Delta$ KSS knee	35.1 $\pm$ 13.0 <sup>e</sup>	26.2 $\pm$ 2.7	20.9 $\pm$ 2.9
$\Delta$ KSS function	19.6 $\pm$ 3.5 <sup>f</sup>	10.9 $\pm$ 3.1	11.4 $\pm$ 23.7
$\Delta$ Flexion ( $^{\circ}$ )	95.4 $\pm$ 2.95	94.2 $\pm$ 2.86	91.9 $\pm$ 2.86
$\Delta$ Deficit of extension ( $^{\circ}$ )	4.8 $\pm$ 0.8	4.2 $\pm$ 1.1	4.5 $\pm$ 0.7

TM, trabecular metal; SS, short stem; LS, long stem; NC, no cone; KOOS, Knee Injury and Osteoarthritis Outcome Score; ADL, activities of daily living; QOL, quality of life; KSS, Knee Society Score.

<sup>a</sup> A pairwise comparison exhibited significant differences between TM + SS vs TM + LS ( $P < .001$ ) and TM + SS vs NC + LS ( $P = .008$ ).

<sup>b</sup> A pairwise comparison exhibited significant differences between TM + SS vs TM + LS ( $P = .003$ ) and TM + SS vs NC + LS ( $P < .001$ ).

<sup>c</sup> A pairwise comparison exhibited significant differences between TM + SS vs TM + LS ( $P < .001$ ) and TM + SS vs NC + LS ( $P = .001$ ).

<sup>d</sup> A pairwise comparison exhibited significant differences between TM + SS vs TM + LS ( $P < .001$ ) and TM + SS vs NC + LS ( $P < .001$ ).

<sup>e</sup> A pairwise comparison exhibited significant differences between TM + SS vs TM + LS ( $P = .005$ ) and TM + SS vs NC + LS ( $P < .001$ ).

<sup>f</sup> A pairwise comparison exhibited significant differences between TM + SS vs TM + LS ( $P = .003$ ) and TM + SS vs NC + LS ( $P = .005$ ).

compared with the use of a long uncemented tibial stem combined with TM cones or metallic augments during rTKA for aseptic loosening causes. Better functional outcome could be observed in the TM + SS group in particular on pain, symptoms, and QOL compared with the 2 other groups. The hypothesis of this study was therefore accepted.

Periprosthetic joint infection and aseptic loosening were identified as the most common indications for revision [13,14]. As the proportion of patients younger than 65 years who undergo primary TKA is expected to increase, reproducible, durable, and clinically satisfactory revision techniques had to be developed [2,15]. One of the main challenges of rTKA remains the management of bone loss [16–18]. Significant bone loss is a major risk factor for aseptic loosening after rTKA [19]. Metaphyseal (zone 2) and diaphyseal

(zone 3) anchorage are necessary to ensure proper and durable fixation in rTKA with significant bone loss [7].

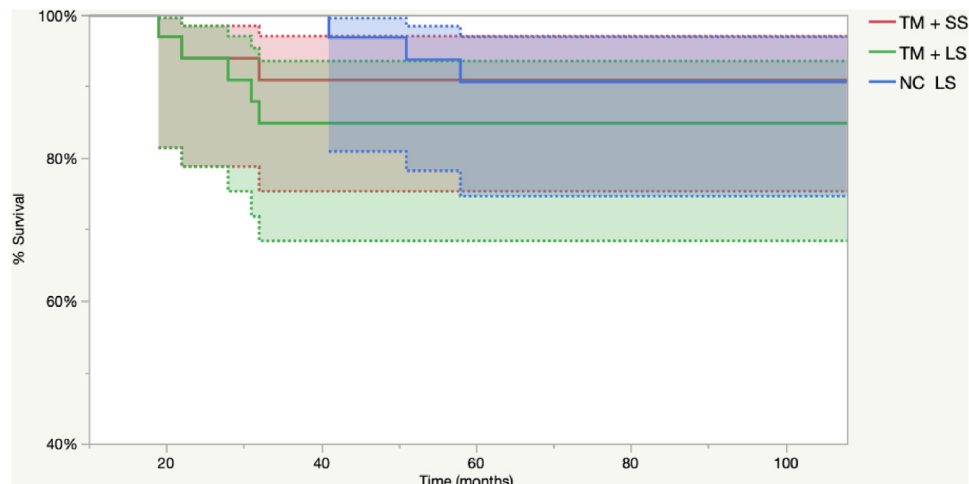
Among various options, the use of metaphyseal TM cones and porous-coated sleeves seem to be a validated choice for stage AORI II and III tibial or femoral bone loss [4,20,21]. They allow metaphyseal reconstruction with biological fixation and show interesting survival rates in the short term [22,23].

Using metaphyseal sleeves, Watters et al [24] and Chalmers et al [25] showed a survival rate of 98.5%–99.5% at 2 years of follow-up. However, with a longer follow-up, survival appears to drop with an any-cause revision rate of 22% at 7 years in the study conducted by Agarwal et al [26].

Using TM cones, a systematic review conducted by Zanirato et al [23] including exclusively TM cone reconstruction showed a short-term survival rate of 94.5%, with a low aseptic loosening rate of 0.84%. Denehy et al [27] found a 90.2% all-cause survival rate at 2 years of follow-up. At 5 years, it falls to 84%, according to Potter et al [28]. Better survival rate with the use of TM cones associated with short cemented stems was observed in the present study, at 8 years survivorship of the components free of revision for any cause was 90.6%  $\pm$  5.1% for the TM + SS group.

A systematic review conducted by Roach et al [29] concluded that the reoperation rate is twice as high when using TM cones compared with metaphyseal sleeves. However, it seems difficult to conclude in a formal way, as the studies cited never directly compare the 2 implants, and were realized with different implant designs. The review conducted by Zanirato et al [23] denies these results, showing an equivalent survival rate between these 2 implants.

Bony metaphyseal defects may be treated also by using metal augmentation devices (NC + LS group). Various types of augments (such as rectangular blocks and wedges) are available that allow selective augmentation for both femoral and tibial defects. On the tibial side, modular metal wedges are usually used to augment the tibial tray for tibial bone stock deficiency. Femoral defects most often occur on the posterior surfaces, and metal blocks can be used to increase femoral component rotation and maintain the balance between flexion and extension gaps. Metallic augments are cemented to fit the femoral and tibial components [30]. Some complications, including fretting, radiolucent lines, and poor fixation after using these devices, have been described in a few studies with short follow-up [31,32]. Patel et al [33] treated a total of 102 rTKA patients (AORI type 2 defects) with metal augments and observed 92% survival at 11 years, with no significant complications, including fretting and loosening. But this type of



**Fig. 4.** Kaplan-Meier component survivorship curve based on all-cause revision.

reconstruction requires systematically the use of LSs because of the lack of stable metaphyseal fixation [5].

After metaphyseal reconstruction (zone 2), the use of diaphyseal stems is therefore necessary to ensure good anchorage in zone 3. However, pain may occur at the end of LSs in almost 1 patient of 6 patients, reducing postoperative clinical satisfaction [9,11]. Moreover, the cadaveric study conducted by Gobba et al [12] shows that LSs can conflict with the tibial diaphysis, increasing the posteromedial offset, especially in the case of diaphyseal valgus.

The concept of modularity introduced by the TM cones allows an independent reconstruction of the epiphyseal area (coverage, joint line, and others) with good fixation without being forced by the metaphyseal reconstruction or the diaphyseal reconstruction, which is the case for the metaphyseal sleeves and metal augmentation devices [25]. The TM cone and cement construct used in this study provided rigid metaphyseal fixation. A rigid metaphyseal construct avoids the need for long diaphyseal stem fixation that can cause morbidity with stem pain [34–36].

In the present study, the functional results observed at a minimum of 2 years of follow-up confirm this hypothesis. Indeed, better functional results were observed when a short cemented stem (TM + SS) was used compared with LS (TM + LS and NC + LS) without reducing implant survival. Similar functional results were observed by Denehy et al [27] who used highly porous metaphyseal titanium cones with short cemented tibial stem in rTKA. The mean knee KSS improved from 51 points to 80 points at latest follow-up ( $\Delta$  knee KSS = 29 vs 35.1 for the TM + SS group in this study). Comparison of results with other studies is complex because of the multitude of different implants used and the different distribution of factors predictive of poor outcomes as defined by Verbeek et al [37]. In this study, not only the absence of significant differences between the different groups in terms of preoperative characteristics, causes of revision, and type of bone defect but also the use of the same type of prosthesis reinforces the strength in terms of better functional results of the TM + SS group.

Limitations of this study include those inherent to a retrospective analysis of data, including selection bias. Despite observing the efficacy of the 3 different types of reconstruction (TM + SS, TM + LS, and NC + LS), 14% of the cohort required reoperation, highlighting the overall poorer outcomes seen with complex revision surgery, especially in cases of multiple prior operations. On the other hand, the postoperative infection rate of the cohort was 12%, which is higher than the rate observed by Bonanzinga et al [38] who estimated the postoperative infection rate at 1% in rTKA for aseptic causes. This difference can be explained by the fact that occult infection causes could have been wrongly included in this study despite a preoperative or intraoperative sample negative to a bacterial germ [39]. Another limit of this study is the absence of comparison with metaphyseal sleeves, but it was not the aim of the study, and this type of reconstruction was not used in the 2 surgical centers. Finally, the matching process (1/1/1) based on age ( $\pm 5$  years) from the smallest group (TM + SS) reduced the size of the population but controlled one of the main independent risk factors for failure [40].

The present study is one of the few of the literature comparing different types of reconstruction using a single design of rotating hinge knee prosthesis in rTKA with a special interest on the length of the stems. It provides interesting arguments on the association of TM cone and short cemented stem because the survival is equivalent to long uncemented stems associated with TM cones or metallic augments. The functional results of this association are better in particular for pain, symptoms, and QOL. Finally, the use of TM cones in combination with a short cemented tibial stem is a reliable technique, and the generalized use of this type of association (TM + SS) could be recommended.

## Conclusion

The use of a short cemented tibial stem combined with a TM metaphyseal cone in revision TKA offers identical survival rate with better functional outcome in particular for pain, symptoms, and QOL compared with the use of a long uncemented stem associated with TM cones or metallic augments at a minimum of 5 years of follow-up.

## References

- [1] Kurtz S, Ong K, Lau E, Mowat F, Halpern M. Projections of primary and revision hip and knee arthroplasty in the United States from 2005 to 2030. *J Bone Joint Surg Am* 2007;89:780–5. <https://doi.org/10.2106/JBJS.F.00222>.
- [2] Kurtz SM, Lau E, Ong K, Zhao K, Kelly M, Bozic KJ. Future young patient demand for primary and revision joint replacement: national projections from 2010 to 2030. *Clin Orthop* 2009;467:2606–12. <https://doi.org/10.1007/s11999-009-0834-6>.
- [3] Leta TH, Lygre SHL, Skredderstuen A, Hallan G, Furnes O. Failure of aseptic revision total knee arthroplasties. *Acta Orthop* 2015;86:48–57. <https://doi.org/10.3109/17453674.2014.964097>.
- [4] Mancuso F, Beltrame A, Colombo E, Miani E, Bassini F. Management of metaphyseal bone loss in revision knee arthroplasty. *Acta Biomed* 2017;88:98–111. <https://doi.org/10.23750/abm.v88i2-5.6520>.
- [5] Radnay CS, Scuderi GR. Management of bone loss: augments, cones, offset stems. *Clin Orthop* 2006;446:83–92. <https://doi.org/10.1097/01.blo.0000214437.57151.41>.
- [6] Bobyn JD, Poggie RA, Krygier JJ, Lewallen DG, Hanssen AD, Lewis RJ, et al. Clinical validation of a structural porous tantalum biomaterial for adult reconstruction. *J Bone Joint Surg Am* 2004;86-A(Suppl. 2):123–9. <https://doi.org/10.2106/00004623-200412002-00017>.
- [7] Morgan-Jones R, Oussedik SIS, Graichen H, Haddad FS. Zonal fixation in revision total knee arthroplasty. *Bone Joint J* 2015;97-B:147–9. <https://doi.org/10.1302/0301-620X.97B2.34144>.
- [8] Vince KG. A step-wise approach to revision TKA. *Orthopedics* 2005;28:999–1001.
- [9] Mihalko WM, Whiteside LA. Stem pain after cementless revision total knee arthroplasty. *J Surg Orthop Adv* 2015;24:137–9.
- [10] Kim YH, Kwon OS, Kim K. Analysis of biomechanical effect of stem-end design in revision TKA using Digital Korean model. *Clin Biomech* 2008;23:853–8. <https://doi.org/10.1016/j.clinbiomech.2008.01.010>.
- [11] Kimpton CI, Crocombe AD, Bradley WN, Owen BGH. Analysis of stem tip pain in revision total knee arthroplasty. *J Arthroplasty* 2013;28:971–7. <https://doi.org/10.1016/j.arth.2012.10.007>.
- [12] Gobba MS, Chan N, Patel R, Noble PC, Incavo SJ. Tibial stems in revision total knee arthroplasty: is there an anatomic conflict? *J Arthroplasty* 2015;30:86–9. <https://doi.org/10.1016/j.arth.2014.12.039>.
- [13] Postler A, Lützner C, Beyer F, Tille E, Lützner J. Analysis of total knee arthroplasty revision causes. *BMC Musculoskelet Disord* 2018;19:55. <https://doi.org/10.1186/s12891-018-1977-y>.
- [14] Schroer WC, Berend KR, Lombardi AV, Barnes CL, Bolognesi MP, Berend ME, et al. Why are total knees failing today? Etiology of total knee revision in 2010 and 2011. *J Arthroplasty* 2013;28:116–9. <https://doi.org/10.1016/j.arth.2013.04.056>.
- [15] Erivan R, Tardieu A, Villatte G, Ollivier M, Jacquet C, Descamps S, et al. Knee surgery trends and projections in France from 2008 to 2070. *Orthop Traumatol Surg Res* <https://doi.org/10.1016/j.otsr.2020.02.018>.
- [16] Rosso F, Cottino U, Dettoni F, Bruzzone M, Bonasia DE, Rossi R. Revision total knee arthroplasty (TKA): mid-term outcomes and bone loss/quality evaluation and treatment. *J Orthop Surg* 2019;14:280. <https://doi.org/10.1186/s13018-019-1328-1>.
- [17] Sulco PK, Abdel MP, Hanssen AD, Lewallen DG. The management of bone loss in revision total knee arthroplasty: rebuild, reinforce, and augment. *Bone Joint J* 2016;98-B:120–4. <https://doi.org/10.1302/0301-620X.98B1.36345>.
- [18] Sheth NP, Bonadio MB, Demange MK. Bone loss in revision total knee arthroplasty: evaluation and management. *J Am Acad Orthop Surg* 2017;25:348–57. <https://doi.org/10.5435/JAAOS-D-15-00660>.
- [19] Lee S-H, Shih H-N, Chang C-H, Lu T-W, Chang Y-H, Lin Y-C. Influence of extension stem length and diameter on clinical and radiographic outcomes of revision total knee arthroplasty. *BMC Musculoskelet Disord* 2020;21:15. <https://doi.org/10.1186/s12891-019-3030-1>.
- [20] Beckmann NA, Mueller S, Gondan M, Jaeger S, Reiner T, Bitsch RG. Treatment of severe bone defects during revision total knee arthroplasty with structural allografts and porous metal cones—a systematic review. *J Arthroplasty* 2015;30:249–53. <https://doi.org/10.1016/j.arth.2014.09.016>.
- [21] Lei P-F, Hu R-Y, Hu Y-H. Bone defects in revision total knee arthroplasty and management. *Orthop Surg* 2019;11:15–24. <https://doi.org/10.1111/os.12425>.
- [22] Haidukewych GJ, Hanssen A, Jones RD. Metaphyseal fixation in revision total knee arthroplasty: indications and techniques. *J Am Acad Orthop Surg* 2011;19:311–8. <https://doi.org/10.5435/00124635-201106000-00001>.

- [23] Zanirato A, Cavagnaro L, Basso M, Divano S, Felli L, Formica M. Metaphyseal sleeves in total knee arthroplasty revision: complications, clinical and radiological results. A systematic review of the literature. *Arch Orthop Trauma Surg* 2018;138:993–1001. <https://doi.org/10.1007/s00402-018-2967-0>.
- [24] Watters TS, Martin JR, Levy DL, Yang CC, Kim RH, Dennis DA. Porous-coated metaphyseal sleeves for severe femoral and tibial bone loss in revision TKA. *J Arthroplasty* 2017;32:3468–73. <https://doi.org/10.1016/j.arth.2017.06.025>.
- [25] Chalmers BP, Desy NM, Pagnano MW, Trousdale RT, Taunton MJ. Survivorship of metaphyseal sleeves in revision total knee arthroplasty. *J Arthroplasty* 2017;32:1565–70. <https://doi.org/10.1016/j.arth.2016.12.004>.
- [26] Agarwal S, Neogi DS, Morgan-Jones R. Metaphyseal sleeves in revision total knee arthroplasty: minimum seven-year follow-up study. *Knee* 2018;25:1299–307. <https://doi.org/10.1016/j.knee.2018.09.010>.
- [27] Denehy KM, Abhari S, Krebs VE, Higuera-Rueda CA, Samuel LT, Sultan AA, et al. Metaphyseal fixation using highly porous cones in revision total knee arthroplasty: minimum two year follow up study. *J Arthroplasty* 2019;34:2439–43. <https://doi.org/10.1016/j.arth.2019.03.045>.
- [28] Potter GD, Abdel MP, Lewallen DG, Hanssen AD. Midterm results of porous tantalum femoral cones in revision total knee arthroplasty. *J Bone Joint Surg Am* 2016;98:1286–91. <https://doi.org/10.2106/JBJS.15.00874>.
- [29] Roach RP, Clair AJ, Behery OA, Thakkar SC, Iorio R, Deshmukh AJ. Aseptic loosening of porous metaphyseal sleeves and tantalum cones in revision total knee arthroplasty: a systematic review. *J Knee Surg* 2020. <https://doi.org/10.1055/s-0040-1701434>.
- [30] Hutten D. Femorotibial bone loss during revision total knee arthroplasty. *Orthop Traumatol Surg Res* 2013;99:S22–33. <https://doi.org/10.1016/j.otsr.2012.11.009>.
- [31] Fehring TK, Peindl RD, Humble RS, Harrow ME, Frick SL. Modular tibial augmentations in total knee arthroplasty. *Clin Orthop* 1996;327:207–17. <https://doi.org/10.1097/00003086-199606000-00026>.
- [32] Rand JA. Bone deficiency in total knee arthroplasty. Use of metal wedge augmentation. *Clin Orthop* 1991;271:63–71.
- [33] Patel JV, Masonis JL, Guerin J, Bourne RB, Rorabeck CH. The fate of augments to treat type-2 bone defects in revision knee arthroplasty. *J Bone Joint Surg Br* 2004;86:195–9. <https://doi.org/10.1302/0301-620x.86b2.13564>.
- [34] Completo A, Simões JA, Fonseca F, Oliveira M. The influence of different tibial stem designs in load sharing and stability at the cement-bone interface in revision TKA. *Knee* 2008;15:227–32. <https://doi.org/10.1016/j.knee.2008.01.008>.
- [35] Mabry TM, Hanssen AD. The role of stems and augments for bone loss in revision knee arthroplasty. *J Arthroplasty* 2007;22:56–60. <https://doi.org/10.1016/j.arth.2007.02.008>.
- [36] Xie S, Conlisk N, Hamilton D, Scott C, Burnett R, Pankaj P. Metaphyseal cones in revision total knee arthroplasty: the role of stems. *Bone Joint Res* 2020;9:162–72. <https://doi.org/10.1302/2046-3758.94.BJR-2019-0239.R1>.
- [37] Verbeek JFM, Hannink G, Defoort KC, Wymenga AB, Heesterbeek PJC. Age, gender, functional KSS, reason for revision and type of bone defect predict functional outcome 5 years after revision total knee arthroplasty: a multi-variable prediction model. *Knee Surg Sports Traumatol Arthrosc* 2019;27:2289–96. <https://doi.org/10.1007/s00167-019-05365-x>.
- [38] Bonanzinga T, Gehrke T, Zahar A, Zaffagnini S, Marcacci M, Haasper C. Are trabecular metal cones a valid option to treat metaphyseal bone defects in complex primary and revision knee arthroplasty? *Joints* 2018;6:58–64. <https://doi.org/10.1055/s-0037-1608950>.
- [39] Rasouli MR, Harandi AA, Adeli B, Purtill JJ, Parvizi J. Revision total knee arthroplasty: infection should be ruled out in all cases. *J Arthroplasty* 2012;27:1239–1243.e1–2. <https://doi.org/10.1016/j.arth.2011.01.019>.
- [40] Geary MB, Macknet DM, Ransone MP, Odum SD, Springer BD. Why do revision total knee arthroplasties fail? A single-center review of 1632 revision total knees comparing historic and modern cohorts. *J Arthroplasty* 2020. <https://doi.org/10.1016/j.arth.2020.05.050>.