



**HAL**  
open science

# Upper Femur Anatomy Depends on Age and Gender: A Three-Dimensional Computed Tomography Comparative Bone Morphometric Analysis of 628 Healthy Patients' Hips.

Max Carmona, Chris Tzioupis, Sally Liarno, Ahmad Faizan, Jean-Noël Argenson, Matthieu Ollivier

## ► To cite this version:

Max Carmona, Chris Tzioupis, Sally Liarno, Ahmad Faizan, Jean-Noël Argenson, et al.. Upper Femur Anatomy Depends on Age and Gender: A Three-Dimensional Computed Tomography Comparative Bone Morphometric Analysis of 628 Healthy Patients' Hips.. *The Journal of Arthroplasty*, 2019, 34 (10), pp.2487-2493. 10.1016/j.arth.2019.05.036 . hal-03553324

**HAL Id: hal-03553324**

**<https://hal.science/hal-03553324>**

Submitted on 14 Apr 2023

**HAL** is a multi-disciplinary open access archive for the deposit and dissemination of scientific research documents, whether they are published or not. The documents may come from teaching and research institutions in France or abroad, or from public or private research centers.

L'archive ouverte pluridisciplinaire **HAL**, est destinée au dépôt et à la diffusion de documents scientifiques de niveau recherche, publiés ou non, émanant des établissements d'enseignement et de recherche français ou étrangers, des laboratoires publics ou privés.



Distributed under a Creative Commons Attribution - NonCommercial 4.0 International License

# Upper Femur Anatomy Depends on Age and Gender: A Three-Dimensional Computed Tomography Comparative Bone Morphometric Analysis of 628 Healthy Patients' Hips

Max Carmona<sup>a,b,c</sup>, Chris Tzioupis<sup>b,c</sup>, Sally LiArno<sup>d</sup>, Ahmad Faizan<sup>d</sup>,  
Jean-Noël Argenson<sup>b,c</sup>, Matthieu Ollivier<sup>b,c,\*</sup>

<sup>a</sup> Department of Orthopedics and Traumatology, Pontificia Universidad Catolica de Chile, Santiago, Chile

<sup>b</sup> Aix-Marseille Université, CNRS, ISM UMR 7287, Marseille, France

<sup>c</sup> Department of Orthopedics and Traumatology, Institute of Movement and Locomotion, St. Marguerite Hospital, Marseille, France

<sup>d</sup> Stryker, Mahwah, NJ

**Background:** The knowledge of proximal femur geometry is essential in the understanding and treatment of hip pathologies. Our aim is to evaluate the range of “normal anatomical values of the proximal femur” and their relationship to age, gender, and ethnicity in a cohort of healthy population, using a 3-dimensional computed tomography automated software.

**Methods:** The pelvis and bilateral femora of 628 healthy individuals (394 males/234 females, mean age  $61.5 \pm 16.5$  years, mean body mass index [BMI]  $26.9 \pm 5.2$  kg/m<sup>2</sup>) including 2 ethnicities (226 Asians and 406 Caucasians) were assessed with a 3-dimensional computed tomography scan-based system using algorithm-calculated landmarks. The demographic parameters recorded were age, gender, BMI, and ethnicity. The femoral neck-shaft angle (NSA), femoral neck version, femoral offset (FO), and femoral canal flare index (fCFI) were calculated for each individual. Analyses were performed using SPSS version 22. *P*-values  $<.05$  were considered to indicate statistical significance.

**Results:** Overall, the mean NSA was  $124.7^\circ$  (standard deviation [SD] 6.2), mean femoral neck version was  $14.5^\circ$  (SD 8.1), mean FO was 42.9 mm (SD 6.8), and mean fCFI was 3.4 (SD 0.5). Gender was associated with all parameters, with the females presenting more valgus and anteverted hips. Multivariate analysis revealed a lower NSA and fCFI and a higher FO for older individuals. Ethnicity and BMI were not associated with any parameters.

**Conclusion:** Our results showed that there is a direct relationship of age and gender to the variations in the investigated proximal femur anatomical parameters in a large cohort of healthy individuals. Those important gender-based and age-based differences might advocate for more varus and lateralized component to reproduce preoperative anatomy of male and patients older than 50 years.

One or more of the authors of this paper have disclosed potential or pertinent conflicts of interest, which may include receipt of payment, either direct or indirect, institutional support, or association with an entity in the biomedical field which may be perceived to have potential conflict of interest with this work. For full disclosure statements refer to <https://doi.org/10.1016/j.arth.2019.05.036>.

Author Contributions: M.O. and J.N.A. designed the protocol; S.L. made all CT measurements; M.O. and C.T. performed statistical analysis; M.C. and C.T. wrote the initial draft; M.O. and J.N.A. edited the different version of the draft; M.C., C.T., S.L., J.N.A., and M.O. approved of the submitted and final versions.

Funding: No funding was needed for this study.

\* Reprint requests: Matthieu Ollivier, MD, PhD, Department of Orthopedics and Traumatology, Institute of Movement and Locomotion, St. Marguerite Hospital, 270, Boulevard Sainte Marguerite, BP 29, 13274 Marseille, France.

The knowledge of the anatomical parameters of the proximal femur is critical for a better understanding of the processes that drive different pathological entities. Recent research has determined the femoral-shaft angle under  $129^\circ$  as a risk factor for the development of idiopathic femoral head osteonecrosis [1]. Likewise, recent publications have linked this parameter with the development of clinical femoroacetabular impingement [2–4] and have given more relevance to the femoral neck version (FNV) in its physiopathology [5].

The understanding of the biomechanics of the human hip joint is essential for the precise analysis of diagnostic imaging modalities

and the consideration of treatment options. The differentiation between normal hip anatomy and pathological condition by comparing individual measurements to reference values is of the utmost importance [6].

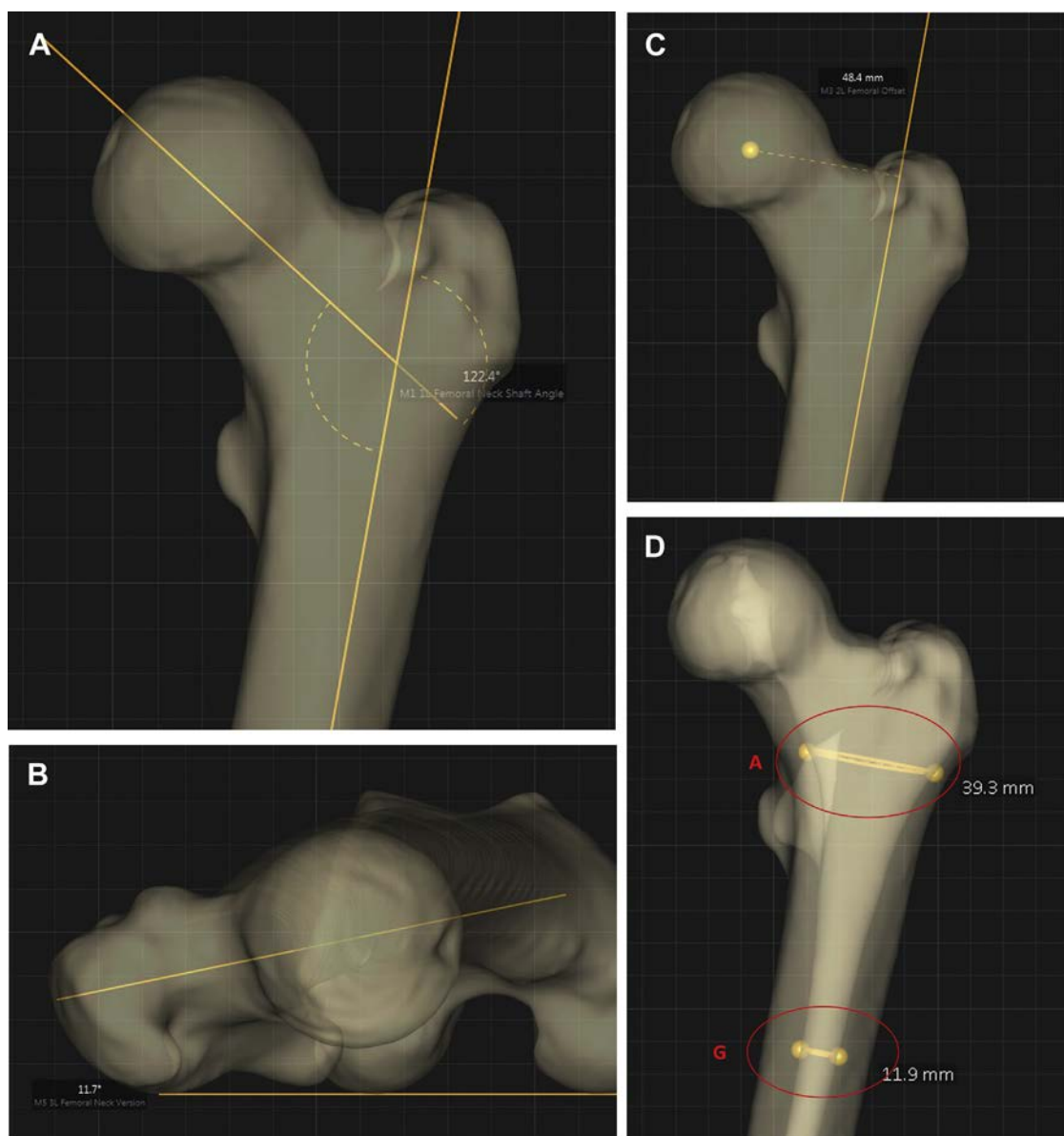
Proximal femoral geometry plays a pivotal role in the occurrence of a variety of hip pathologies in children as well as in adults [7]. The correct reconstruction of normal hip parameters is thought to be of extreme importance to secure the success of total hip arthroplasty (THA). An inadequate restoration of the femoral offset (FO) has been associated with limp, prosthetic instability, gait disorders, and less abductor muscle strength [8–12]. Most importantly, it has been demonstrated to be negatively associated with implant survival and quality of life [12–14]. Furthermore, recent publications have shown an incapacity of modern cementless stem designs to restore the proximal femur anatomy [15,16], specially the FO and native anteversion, with a mismatch of nearly 30% [16].

Radiographic descriptions such as angular measurements of hip morphology are often used as part of the decision-making process

for surgery, but the justification for use of certain thresholds or values is surprisingly sparse [17–19]. Indeed, numerous methods have been developed for the calculation of proximal femur's geometry [7,9]. Published values derive mostly from anatomic series studies and X-ray analysis of pathological hips, utilizing “two-dimension” analytical methods [20–27]. The drawback of these methods is that the interpretation of the results depends on the position of the pelvis, which can vary considerably between acquisitions [28] and the imprecise positioning of the femoral shaft and neck axis [6,18,29].

Computed tomography (CT) scan has gained a growing interest especially in the three-dimensional (3D) imaging of the pelvis and hip as an accurate diagnostic tool providing reliable data [20–26,30,31]. However, issues pertaining to high dose exposure and standing positioning parameters are always present [28].

Knowing the normal values of those parameters for different demographic groups and based on the most accurate morphometric analysis available is of vital importance (1) to understand



**Fig. 1.** Illustrations of proximal femur's anatomical parameters measurement: (A) femoral neck-shaft angle; (B) femoral neck version; (C) femoral offset; and (D) femoral canal flare index (ratio of A to G).

**Table 1**Analysis of Differences in Anatomical Parameters by Gender, *P*-Values Calculated With Student's *t*-Test.

Anatomical Parameters	Male (SD)	Female (SD)	Difference (95% CI)	<i>P</i> -Value
Neck-shaft angle (°)	123.8 (5.9)	126 (6.4)	-2.2 (-3.1 to -1.2)	<.0001
Femoral neck version (°)	12.9 (7.7)	16.9 (8.1)	-4.04 (-5.2 to -2.7)	<.0001
Femoral offset (mm)	44.3 (6.7)	40.6 (6.2)	3.6 (2.6-4.7)	<.0001
Canal flare index	3.4 (0.5)	3.2 (0.4)	0.2 (0.1-0.3)	<.0001

CI, confidence interval; SD, standard deviation.

the physiopathology of different conditions, (2) to define the standard of anatomical restoration, and (3) guide the development of new treatment strategies.

The aim of our study is to define the normal range of specific anatomical values of the proximal femur, with an emphasis on surgical parameters, by use of a 3D-CT automated software and to determine whether age, gender, body mass index (BMI), or ethnicity variables were associated with differences in those values.

## Materials and Methods

The CT scans of pelvis and bilateral femora of 628 normal individuals retrieved from the SOMA database (Stryker, Mahwah, NJ) were analyzed. SOMA is a database containing over 3500 CT scans which have been segmented to provide 3D models of more than 15,000 individual bones from patients with age between 3 and 109 years, weight from 29 to 181 kg, and height between 127 and 199 cm.

We used an automatic CT scan-based modeling and analytic system for this study. The pelvis and bilateral femora of 628 patients (394 males/234 females, mean age  $61.5 \pm 16.5$  years, mean BMI  $26.9 \pm 5.2$  kg/m<sup>2</sup>) including 2 ethnicities (226 Asians and 406 Caucasians) were examined. Subjects with bone or joint abnormalities were excluded before CT scan selection through radiographic inspection. The demographic parameters evaluated in our analysis include age, gender, height, weight, BMI, and ethnicity. Each of the measurements was made with algorithm-based constructions in an index bone. Then, these measurements were mapped to each bone of the database by the automated software, resulting in reproducible and consistent parameters for each subject [32–34]. The femoral neck shaft angle (NSA), FNV, FO, and femoral canal flare index (fCFI) were calculated for each patient. The precision of the automated extraction system was published to be associated to margin of error of less than 2 mm and less than 1° [32–34] (Fig. 1).

In order to define the femoral NSA, the femoral neck axis and the anatomical axis of the femur were first selected from the predefined landmarks available. These axes were then projected onto the frontal plane and the angle between both axes determined. The femoral head center was then chosen from the predefined landmark list and projected onto the frontal plane. The medial-lateral (ML) distance from the femoral head center to the anatomical axis in the frontal plane was measured to determine the FO. Next, the most posterior points on the medial and lateral condyle were chosen from the predefined landmark list and the points utilized to

define the posterior condylar axis. The posterior condylar axis and the femoral neck axis, chosen above, were projected onto the transverse plane and the angle between them measured as the FNV. Next, the center of the trabecular bone at the proximal 1/10 femoral distance and proximal 3/10 femoral distance were chosen from the predefined landmark list. Planes were created orthogonal to the anatomical axis and through these points. The femoral section at each of these planes was utilized to measure the ML width of the trabecular bone at the proximal 1/10 femoral distance (*A*) and the ML width of the trabecular bone at the proximal 3/10 femoral distance (*G*). The fCFI was defined as the ratio of *A* to *G*.

## Statistical Analysis

Means and standard deviations (SDs) were determined for each of the measurements made for the population as a whole and for subpopulations, based on gender, ethnicity, and age (decades). Normal (Gaussian) distributions were determined. Univariate analysis was performed using *t*-tests to estimate difference between groups and subgroups. Pearson's coefficients were calculated to examine correlations among specimen demographic data and femoral measurements. Multiple linear regression models were developed to establish the determinants for each of the variables. For each model, variables with a *P* value less than .1 were kept in the final model.

Sample size was defined based on expected NSA =  $124 \pm 6.2$  [35] for a required level of statistical significance of  $\alpha = 0.05$ , and a power of  $1 - \beta = 0.95$ . Eighty-five femurs would be required to detect a  $>2^\circ$  difference between groups and subgroups. A trained statistician (M.O.) performed statistical analysis using SPSS software (Version 22; SPSS Inc, Chicago, IL). All calculations will assume 2-tailed tests.

## Results

Overall, the mean NSA was  $124.7^\circ$  (SD 6.2), the mean FNV was  $14.5^\circ$  (SD 8.1), the mean FO was 42.9 mm (SD 6.8), and the mean fCFI was 3.4 (SD 0.5). Regarding the gender subgroup analysis, we found a mean NSA of  $123.8^\circ$  (SD 5.9) and  $126^\circ$  (SD 6.4) for males and females ( $P < .0001$ ), respectively. A mean FNV =  $12.9^\circ$  (SD 7.7) was found for males and  $16.9^\circ$  (SD 8.1) for females ( $P < .0001$ ), a mean FO = 44.3 mm (SD 6.7) for males and 40.6 mm (SD 6.2) for females ( $P < .0001$ ), and a mean fCFI = 3.4 (SD 0.5) for males and 3.2 (SD 0.4) for females ( $P < .0001$ ) (Table 1).

**Table 2**Analysis of Differences in Anatomical Parameters by Ethnicity, *P*-Values Calculated With Student's *t*-Test.

Anatomical Parameters	Asian (SD)	Caucasian (SD)	Difference (95% CI)	<i>P</i> -Value
Neck-shaft angle (°)	124.8 (6.2)	124.6 (6.2)	0.23 (-0.7 to 1.2)	.32
Femoral neck version (°)	14.9 (8.1)	14.2 (8.0)	0.63 (-0.6 to 1.9)	1.1
Femoral offset (mm)	42.4 (6.8)	43.1 (6.7)	-0.7 (-1.8 to 0.3)	.09
Canal flare index	3.4 (0.5)	3.3 (0.4)	0.1 (0.02-0.19)	.004

CI, confidence interval; SD, standard deviation.

**Table 3**  
Mean Anatomical Parameters by Decades, P-Values Calculated With ANOVA Testing.

Decades	Anatomical Parameters, Mean (SD)			
	NSA (°)	FNV (°)	FO (mm)	fCFI
2	129.1 (1.6)	20.3 (2.33)	39.8 (1.9)	3.6 (0.15)
3	131 (1.08)	16.3 (1.58)	38.7 (1.29)	3.4 (0.09)
4	129.5 (0.76)	15.7 (1.12)	39.6 (0.91)	3.6 (0.06)
5	126.4 (0.56)	15 (0.82)	41.4 (0.67)	3.4 (0.05)
6	125.2 (0.62)	14.1 (0.91)	43.3 (0.74)	3.3 (0.05)
7	123.7 (0.45)	14.5 (0.66)	43.8 (0.53)	3.3 (0.04)
8	120.4 (0.54)	13.5 (0.8)	44.6 (0.65)	3.2 (0.04)
9	120 (1.01)	11.3 (1.47)	46.7 (1.2)	3.2 (0.09)
P value	<b>&lt;.0001</b>	<b>.01</b>	<b>&lt;.0001</b>	.18

Bolded values represents statistically significant.

NSA, neck-shaft angle; FNV, femoral neck version; FO, femoral offset; fCFI, femoral canal flare index; SD, standard deviation; ANOVA, analysis of variance.

With respect to the ethnic subgroup, we found a mean NSA = 124.8° (SD 6.2) for Asians and 124.6° (SD 6.2) for Caucasians ( $P = .32$ ), a mean FNV = 14.9° (SD 8.1) for Asians and 14.2° (SD 8.0) for Caucasians ( $P = 1.1$ ), a mean FO = 42.4 mm (SD 6.8) for Asians and 43.1 mm (SD 6.7) for Caucasians ( $P = .09$ ), and a mean fCFI = 3.4 (SD 0.5) for Asians and 3.3 (SD 0.4) for Caucasians ( $P = .004$ ) (Table 2).

Age correlated with all parameters in the univariate analysis, but only with NSA, FO, and fCFI in the multivariate analysis. Older patients presented a lower NSA and fCFI and a higher FO. BMI was not associated with any parameter in the multivariate analysis (Tables 3 and 4, Fig. 2A-C).

## Discussion

The results of our study highlight the direct relationship of age and gender to the variations of the investigated proximal femur anatomical parameters in a large cohort of healthy individuals. This correlation should be thoroughly taken into consideration during surgical reconstruction of the hip [9,36]. Those gender and age-based differences might play an important role when planning optimal restoration of patient bony anatomy and soft tissue balancing [36].

In our contemporary daily practice, in order to accurately assess the investigated parameters, highly standardized anteroposterior X-rays are mandatory. However, projectional errors caused by hip rotation are not always easy to overcome [29,37] as almost all of the radiological parameters of the hip depend on the position of the pelvis [28,38,39]. Furthermore, the reliability of this method has been recently challenged because of a heterogeneity of the published results [7]. These concerns have led to a growing interest in 3D-CT imaging of the pelvis and proximal femur [40].

In order to overcome all the problems associated with the implementation of manual approaches in the calculation of the studied parameters, we have used an automated validated system [33]. This system autonomously identifies different kinds of

**Table 4**  
Results of Multivariate Analysis Regarding Factors Influencing Anatomical Parameters.

Associated Factors	NSA	FNV	FO	fCFI
Gender	$R^2 = -0.17, P = .0008$	<b><math>R^2 = -0.24, P = .0013</math></b>	<b><math>R^2 = 0.26, P = .0034</math></b>	<b><math>R^2 = 0.22, P &lt; .0001</math></b>
Age	<b><math>R^2 = -0.51, P &lt; .0001</math></b>	$R^2 = -0.15, P = .034$	<b><math>R^2 = 0.28, P &lt; .0001</math></b>	<b><math>R^2 = -0.22, P &lt; .0001</math></b>
Body mass index	$P = .12$	$P = .28$	$P = .36$	$P = .1$
Height	$R^2 = 0.14, P = .0019$	$P = .18$	$P = .55$	$P = .2$
Weight	$P = .13$	$P = .2$	$P = .27$	$P = .12$
Ethnicity	$P = .47$	$P = .94$	$P = .39$	$P = .29$

Bolded values represents statistically significant.

NSA, neck-shaft angle; FNV, femoral neck version; FO, femoral offset; fCFI, femoral canal flare index.

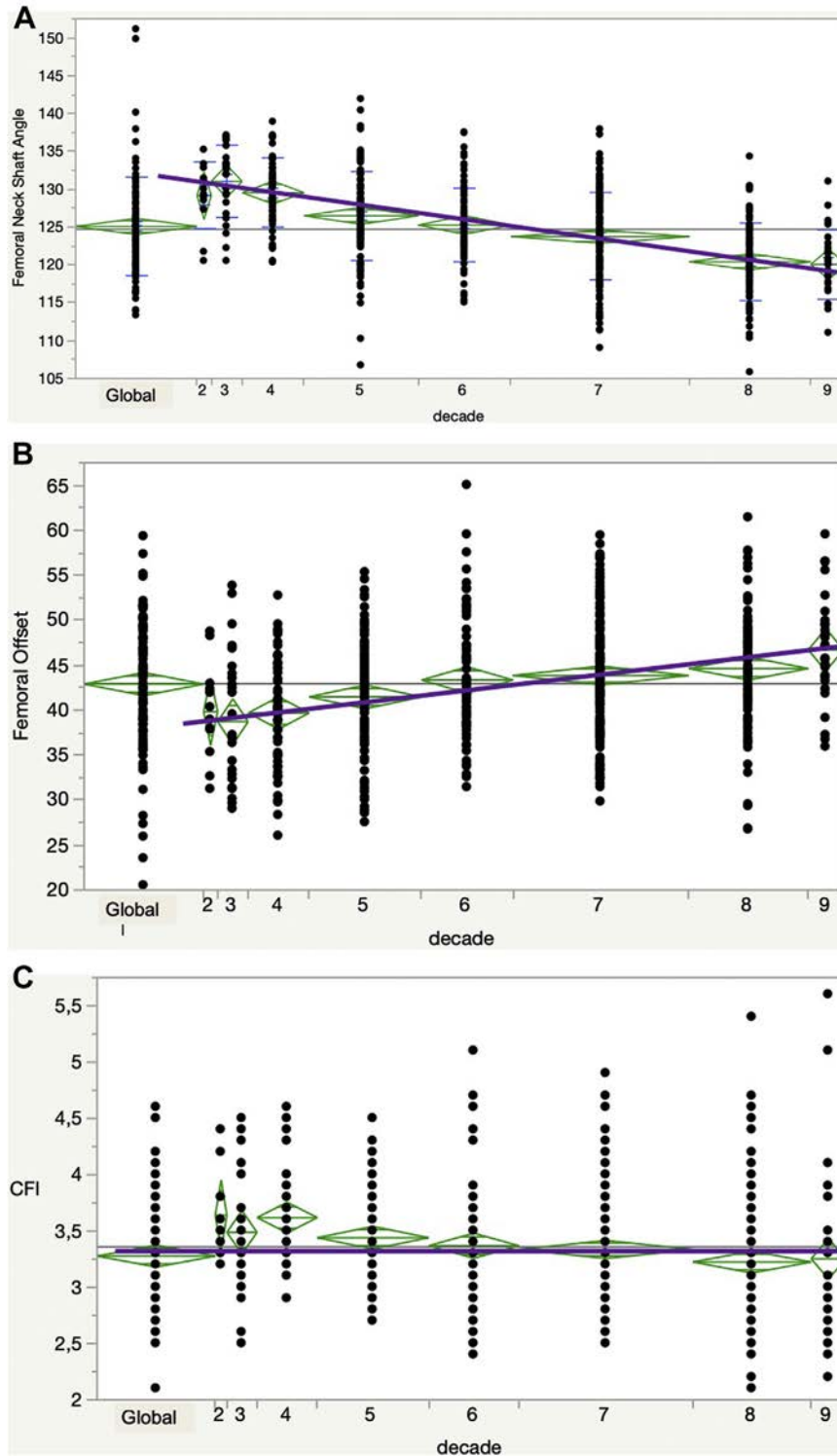
features (explicitly defined landmarks as well as user-supplied point features) on segmented bone samples stored in a database and performs measurements on these. It has been shown that correspondence mapping performs very well in practice and produces results that are comparable or even better than those achievable by manual point mapping. The mean error between the automatic mapping and the average of human-mapped points is less than 2 mm, and considerably less than the root mean square deviation of the latter.

The evidence provided by our study is in line with previous reports. However, there are 2 parameters that stand-out for the high variation of values reported and for their involvement with the physiopathology of different hip conditions, the NSA and FNV.

The mean NSA in our study was 124.7° (SD 6.2), as compared with the 123°-133° range published in the literature [6,9,20-23,25,26,31,41]. Our results are consistent with those reported by Noble et al [20], Rubin et al [21], and Maruyama et al [23]. However, there are publications with a reported NSA above 130° [6,26,31]. A recent systematic review of studies of the NSA on plain radiographs showed a mean NSA in healthy adults of 128.8° and 131.5° in osteoarthritic patients [7]. The authors concluded that there exists a great variability in the reported values across the different studies, identifying the inconsistency of the measurement methods as the central issue. The same group studied the NSA in 800 healthy adult hips through CT images, reporting a mean value of 130.8° in derotated coronal reconstructions [6]. The difference with our findings could be explained by the different methodologies used, the superior accuracy and reliability of the 3D-CT automated software over the 2D-CT analysis, and the inclusion of 2 different ethnic groups in our study, although we did not find differences among them.

Recent studies have associated the NSA with the development of different hip conditions. Ollivier et al [1] studied different anatomical parameters in patients undergoing THA for idiopathic femoral head osteonecrosis. They concluded that an NSA under 129°, among other findings, is an anatomic “abnormality” associated with this disease. Likewise, Ng et al [4] studied differences in anatomical parameters in patients with bilateral hip cam-type deformities but unilateral symptoms. They found that the symptomatic hips had significantly lower NSA (mean 125°) in comparison to the asymptomatic side (mean 127°), concluding that this parameter could be a predictor to determine which hip would be at risk of developing symptoms. Our results show that all these patients have a normal NSA, instead of presenting “abnormal” values. Probably this reaffirm that these hip pathologies represent the final expression of the combination of multiple factors, and that these anatomic parameters are just one part of the picture.

With respect to the FNV, the reported that the range of values in the literature is even wider, from 9.8° to 24.7°, reflecting the varying methodology used for its calculation [22,23,25,26,31,42-45]. We have found a mean value of 14.5° (SD 8.1), similar to the values reported by Bauman et al [45], Maruyama et al [23], Toogood et al



**Fig. 2.** Curves showing correlation between age and different parameters in multivariate analysis: (A) femoral neck-shaft angle; (B) femoral offset; and (C) femoral canal flare index.

[25], and Zhang et al [31]. However, the values reported by Husmann et al [22] and Sariali et al [44] are 24.7° and 21.9° respectively, a fact which might be explained by the inclusion of degenerative hip joints in their CT evaluation.

The mean values for the rest of the parameters we have studied (FO and fCFI) are in accordance with the values reported in the literature [20–22,26,31,44,46].

In our subgroup analysis, gender was correlated with all measured parameters, in the univariate and multivariate analysis, with the females presenting more valgus and anteverted hips. This is in concordance with the study by Boese et al [6], showing a higher mean NSA value for females. Traina et al [47], in their 2009 study, already advocated for gender-specific approaches and modular implants to enhance ability of THA to reproduce

preoperative anatomy. Our results exhibited more varus, retroverted, and lateralized male femoral neck as compared with female femoral neck. Those elements might influence implant selection and preoperative planning processes.

Regarding age, it was associated with NSA, FO, and fCFI in the multivariate analysis, with a decrease of NSA and fCFI with increasing age, also similar with previous publications [6,48]. These findings show that morphologic bone changes continue after skeletal maturity in youth, explained by mineral bone density decrease in the case of fCFI, changes that could also give account for the NSA variations. Up to our knowledge, this is the first paper to report an increase in FO with age, which could be explained by the simultaneous decrease in NSA. The mean values found for FO and NSA in patients older than 50 years put into question the ability of standard THA's femoral stem to reproduce upper femur anatomy in this population and thus advocate for more varus and lateralized stem design to avoid lower limb discrepancy and abnormal soft tissue balancing [36,49].

We did not find differences between Caucasian and Asian proximal femur parameters. Ethnicity was associated with fCFI in the univariate analysis, but not in the multivariate analysis. There exists a paucity of proximal femur anatomic studies in different ethnicities in the literature. Zhang et al [31] reported the parameters in Chinese healthy population, standing-out a mean NSA of 130.2°, FNV of 16.4°, FO of 37.1°, and fCFI of 3.7, and Mahaisavariya et al [43] reported the NSA (128°) and FNV (11.3°) for Thai population.

There is indeed ongoing debate as to whether any regional trends may reflect climatic adaptation or habitual activity patterns. Gilligan et al [41], analyzing a global NSA database of 8271 femora, highlighted climate, clothing, and lifestyle as potential sources of variation for NSA. Additionally, many studies have hypothesized the potential influence of climate on variation in NSA, illustrating that populations from high latitudes frequently display relatively wide bodies, high body masses for stature, short limbs relative to trunk length, and foreshortened distal extremities, as opposed to those living at low latitudes [50]. In our analysis, we did not find a strong correlation between height and weight and NSA. Although we have compared different ethnicities, the aforementioned potentially determining factors could not be addressed due to lack of pertaining data. However, based on our results, we are justified to suggest that their influence (especially climate and activities) is more profound than so far believed, thus necessitating a different research approach.

Finally, we did not find any associations between BMI and proximal femur anatomical parameters. Some studies have found an association between BMI and the shape of the proximal femur but based on dual-energy X-ray absorptiometry hip scans analysis and statistical shape modeling [51]. However, others have shown that, regardless of body proportions, the variation of NSA is presumed to be similar among individuals with similar gait and ambulatory behaviors and that BMI and NSA are receptive to different stimuli, therefore any potential relationship is likely complex and multifactorial [50].

To extrapolate our findings, based on the number of hips analyzed, Asian and Caucasian males and/or patients older than 50 years will present frequently with substantial coxa vara and higher FO value than females and/or patients younger than 50. No clear correlation was found with morphometric parameters such as BMI, height, and weight. The paucity of geographic data (dichotomy between Asian and Caucasian) do not allow us to draw strong conclusion on the impact of ethnicities on femur anatomy.

Our study has several limitations. Because of the retrospective nature of the database, we could not analyze information about patients' level of activity, which could influence the anatomy of the

proximal femur, and information about previous perceived symptoms. Although femurs with bony deformities, previous surgery, or surgical hardware were excluded, hips with slight anatomical alterations may have been included in the analysis. Also, we could not include ethnicities other than Caucasian and Asian because of database limitations, restraining a broader applicability of our data to other cohorts. Furthermore, we only included adult subjects; our results are not applicable to pediatric population. Finally, the decade's populations are small for some subgroups, especially for the younger population.

Despite the aforementioned limitations, the sound results derived from our study are further supported by the fact that it is based on a large cohort of more than 600 healthy individuals, including 2 different ethnicities. Additionally, our analysis is based on a 3D-CT based modeling and analytics system composed of a large database of bone models. This process is made by an automated software, avoiding the manual measurement of parameters, eliminating the potential bias of human input, and achieving a highly accurate degree of morphometric analysis [32–34].

In conclusion, this research project showed that there is a direct relationship of age and gender to the variations of the investigated proximal femur anatomical parameters in a large cohort of healthy individuals. Those important gender-based and age-based differences could imply more varus and lateralized component to reproduce preoperative anatomy of male and patients older than 50 years. We evaluated height, weight, and BMI but found no relationship between them and proximal femoral anatomy. We do not have enough information to comment on the role of ethnicity.

## References

- [1] Ollivier M, Lunebourg A, Abdel MP, Parratte S, Argenson J-N. Anatomical findings in patients undergoing total hip arthroplasty for idiopathic femoral head osteonecrosis. *J Bone Joint Surg Am* 2016;98:672–6. <https://doi.org/10.2106/JBJS.14.01099>.
- [2] Bardakos NV, Villar RN. Predictors of progression of osteoarthritis in femoroacetabular impingement: a radiological study with a minimum of ten years follow-up. *J Bone Joint Surg Br* 2009;91-B:162–9. <https://doi.org/10.1302/0301-620X.91B2.1137>.
- [3] Ng KCG, Lamontagne M, Adamczyk AP, Rahkra KS, Beaulé PE. Patient-specific anatomical and functional parameters provide new insights into the pathomechanism of cam FAI. *Clin Orthop Relat Res* 2015;473:1289–96. <https://doi.org/10.1007/s11999-014-3797-1>.
- [4] Ng KCG, Lamontagne M, Beaulé PE. Differences in anatomical parameters between the affected and unaffected hip in patients with bilateral cam-type deformities. *Clin Biomech* 2016;33:13–9. <https://doi.org/10.1016/j.clinbiomech.2016.01.007>.
- [5] Kraeutler MJ, Chadayammuri V, Garabekyan T, Mei-Dan O. Femoral version abnormalities significantly outweigh effect of cam impingement on hip internal rotation. *J Bone Joint Surg Am* 2018;100:205–10. <https://doi.org/10.2106/JBJS.17.00376>.
- [6] Boese CK, Jostmeier J, Oppermann J, Dargel J, Chang DH, Eysel P, et al. The neck shaft angle: CT reference values of 800 adult hips. *Skeletal Radiol* 2016;45:455–63. <https://doi.org/10.1007/s00256-015-2314-2>.
- [7] Boese CK, Dargel J, Oppermann J, Eysel P, Scheyerer MJ, Bredow J, et al. The femoral neck-shaft angle on plain radiographs: a systematic review. *Skeletal Radiol* 2016;45:19–28. <https://doi.org/10.1007/s00256-015-2236-z>.
- [8] McGrory B, Morrey B, Cahalan T, An K, Cabanela M. Effect of femoral offset on range of motion and abductor muscle strength after total hip arthroplasty. *J Bone Joint Surg Br* 1995;77-B:865–9. <https://doi.org/10.1302/0301-620X.77B6.7593096>.
- [9] Lecerf G, Fessy MH, Philippot R, Massin P, Giraud F, Flecher X, et al. Femoral offset: anatomical concept, definition, assessment, implications for preoperative templating and hip arthroplasty. *Orthop Traumatol Surg Res* 2009;95:210–9. <https://doi.org/10.1016/j.otsr.2009.03.010>.
- [10] Sariali E, Klouche S, Mouttet A, Pascal-Moussellard H. The effect of femoral offset modification on gait after total hip arthroplasty. *Acta Orthop* 2014;85:123–7. <https://doi.org/10.3109/17453674.2014.889980>.
- [11] Tezuka T, Inaba Y, Kobayashi N, Ike H, Kubota S, Kawamura M, et al. Effects of hip joint center location and femoral offset on abductor muscle strength after total hip arthroplasty. *Mod Rheumatol* 2015;25:630–6. <https://doi.org/10.3109/14397595.2014.988863>.
- [12] Mahmood SS, Mukka SS, Crnalic S, Wretenberg P, Sayed-Noor AS. Association between changes in global femoral offset after total hip arthroplasty and

- function, quality of life, and abductor muscle strength. *Acta Orthop* 2016;87:36–41. <https://doi.org/10.3109/17453674.2015.1091955>.
- [13] Sakalkale DP, Sharkey PF, Eng K, Hozack WJ, Rothman RH. Effect of femoral component offset on polyethylene wear in total hip arthroplasty. *Clin Orthop Relat Res* 2001;125–34. <https://doi.org/10.1016/j.otsr.2009.03.010>.
- [14] Little NJ, Busch CA, Gallagher JA, Rorabeck CH, Bourne RB. Acetabular polyethylene wear and acetabular inclination and femoral offset. *Clin Orthop Relat Res* 2009;467:2895–900. <https://doi.org/10.1007/s11999-009-0845-3>.
- [15] Tsai TY, Dimitriou D, Li G, Kwon YM. Does total hip arthroplasty restore native hip anatomy? Three-dimensional reconstruction analysis. *Int Orthop* 2014;38:1577–83. <https://doi.org/10.1007/s00264-014-2401-3>.
- [16] Boese CK, Dargel J, Jostmeier J, Eysel P, Frink M, Lechler P. Agreement between proximal femoral geometry and component design in total hip arthroplasty: implications for implant choice. *J Arthroplasty* 2016;31:1842–8. <https://doi.org/10.1016/j.arth.2016.02.015>.
- [17] Fowkes LA, Petridou E, Zagorski C, Karupiah A, Toms AP. Defining a reference range of acetabular inclination and center-edge angle of the hip in asymptomatic individuals. *Skeletal Radiol* 2011;40:1427–34. <https://doi.org/10.1007/s00256-011-1109-3>.
- [18] Mast NH, Impellizzeri F, Keller S, Leunig M. Reliability and agreement of measures used in radiographic evaluation of the adult hip. *Clin Orthop Relat Res* 2011;469:188–99. <https://doi.org/10.1007/s11999-010-1447-9>.
- [19] Fischer CS, Kühn JP, Itermann T, Schmidt CO, Gümbel D, Kasch R, et al. What are the reference values and associated factors for center-edge angle and alpha angle? A population-based study. *Clin Orthop Relat Res* 2018;476:2249–59. <https://doi.org/10.1097/CORR.0000000000000410>.
- [20] Noble P, Alexander J, Lindahl L, Yew D, Granberry W, Tullos H. The anatomic basis of femoral component design. *Clin Orthop Relat Res* 1988;148–65. <https://doi.org/10.1097/00003086-198810000-00015>.
- [21] Rubin P, Leyvraz P, Aubaniac J, Argenson J, Esteve P, de Roguin B. The morphology of the proximal femur. A three-dimensional radiographic analysis. *J Bone Joint Surg Br* 1992;74-B:28–32. <https://doi.org/10.1302/0301-620X.74B1.1732260>.
- [22] Husmann O, Rubin PJ, Leyvraz PF, De Roguin B, Argenson JN. Three-dimensional morphology of the proximal femur. *J Arthroplasty* 1997;12:444–50. [https://doi.org/10.1016/S0883-5403\(97\)90201-1](https://doi.org/10.1016/S0883-5403(97)90201-1).
- [23] Maruyama M, Feinberg JR, Capello WN, D'Antonio JA. Morphologic features of the acetabulum and femur. *Clin Orthop Relat Res* 2001;393:52–65. <https://doi.org/10.1097/00003086-200112000-00006>.
- [24] Argenson JN, Flecher X, Parratte S, Aubaniac JM. Anatomy of the dysplastic hip and consequences for total hip arthroplasty. *Clin Orthop Relat Res* 2007;465:40–5. <https://doi.org/10.1097/BLO.0b013e3181576052>.
- [25] Toogood PA, Skalak A, Cooperman DR. Proximal femoral anatomy in the normal human population. *Clin Orthop Relat Res* 2009;467:876–85. <https://doi.org/10.1007/s11999-008-0473-3>.
- [26] Unnanuntana A, Toogood P, Hart D, Cooperman D, Grant RE. Evaluation of proximal femoral geometry using digital photographs. *J Orthop Res* 2010;28:1399–404. <https://doi.org/10.1002/jor.21119>.
- [27] Argenson JN, Parratte S, Flecher X, Ryembault E, Aubaniac JM, Brassart N. Three-dimensional anatomy of the hip in osteoarthritis after developmental dysplasia. *J Bone Joint Surg Br* 2005;87-B:1192–6. <https://doi.org/10.1302/0301-620X.87B9.15928>.
- [28] Ghostine B, Sauret C, Assi A, Bakouny Z, Khalil N, Skalli W, et al. Influence of patient axial malpositioning on the trueness and precision of pelvic parameters obtained from 3D reconstructions based on biplanar radiographs. *Eur Radiol* 2017;27:1295–302. <https://doi.org/10.1007/s00330-016-4452-x>.
- [29] Lechler P, Frink M, Gulati A, Murray D, Renkawitz T, Bücking B, et al. The influence of hip rotation on femoral offset in plain radiographs. *Acta Orthop* 2014;85:389–95. <https://doi.org/10.3109/17453674.2014.931196>.
- [30] Wegrzyn J, Roux JP, Loriau C, Bonin N, Pibarot V. The tridimensional geometry of the proximal femur should determine the design of cementless femoral stem in total hip arthroplasty. *Int Orthop* 2018;42:1–6. <https://doi.org/10.1007/s00264-018-3843-9>.
- [31] Zhang Y, Wang J, Li ZH, Xiao J, Zhao L, Yan G, et al. The geometry of the bone structure associated with total hip arthroplasty. *PLoS One* 2014;9:e91058. <https://doi.org/10.1371/journal.pone.0091058>.
- [32] Gottschling H, Schröder M, Reimers N, Fischer F, Homeier A, Burgkart R. A system for performing automated measurements on large bone databases. *IFMBE Proc* 2009;25:910–3. <https://doi.org/10.1007/978-3-642-03882-2-243>.
- [33] Schröder M, Gottschling H, Reimers N, Hauschild M, Burgkart R. Automated morphometric analysis of the femur on large anatomical databases with highly accurate correspondence detection. *Open Med J* 2014;1:15–22. <https://doi.org/10.2174/1874220301401010015>.
- [34] Banerjee S, Faizan A, Nevelos J, Kreuzer S, Burgkart R, Harwin SF, et al. Innovations in hip arthroplasty three-dimensional modeling and analytical technology (SOMA). *Surg Technol Int* 2014;24:288–94.
- [35] Laumonerie P, Cavaignac E, Ollivier M, Argenson JN, LiArno S, Faizan A. Which factors influence proximal femoral asymmetry? *Bone Joint J* 2018;100B:839–44. <https://doi.org/10.1302/0301-620X.100B7.BJ-2017-1601.R1>.
- [36] Asayama I, Chamnongkitch S, Simpson KJ, Kinsey TL, Mahoney OM. Reconstructed hip joint position and abductor muscle strength after total hip arthroplasty. *J Arthroplasty* 2005;20:414–20. <https://doi.org/10.1016/j.arth.2004.01.016>.
- [37] Merle C, Waldstein W, Pegg E, Streit MR, Gotterbarm T, Aldinger PR, et al. Femoral offset is underestimated on anteroposterior radiographs of the pelvis but accurately assessed on anteroposterior radiographs of the hip. *Bone Joint J* 2012;94-B:477–82. <https://doi.org/10.1302/0301-620X.94B4.28067>.
- [38] Dandachli W, Islam SU, Richards R, Hall-Craggs M, Witt J. The influence of pelvic tilt on acetabular orientation and cover: a three-dimensional computerised tomography analysis. *Hip Int* 2013;23:87–92. <https://doi.org/10.5301/HIP.2013.10715>.
- [39] Clohisy JC, Carlisle JC, Trousdale R, Kim YJ, Beaulé PE, Morgan P, et al. Radiographic evaluation of the hip has limited reliability. *Clin Orthop Relat Res* 2009;467:666–75. <https://doi.org/10.1007/s11999-008-0626-4>.
- [40] Gomez-Torres A. CORR insights®: what are the reference values and associated factors for center-edge angle and alpha angle? A population-based study. *Clin Orthop Relat Res* 2018;476:37–9. <https://doi.org/10.1007/s11999-0000000000000080>.
- [41] Gilligan I, Chandraphak S, Mahakkanukrauh P. Femoral neck-shaft angle in humans: variation relating to climate, clothing, lifestyle, sex, age and side. *J Anat* 2013;223:133–51. <https://doi.org/10.1111/joa.12073>.
- [42] Sullivan JA, Vanhoute JJ, Remondino B. Femoral neck anteversion in perspective. *Clin Orthop Relat Res* 1982;185–91.
- [43] Mahaisavariya B, Sittisrisirapit K, Tongdee T, Bohez ELJ, Vander Sloten J, Oris P. Morphological study of the proximal femur: a new method of geometrical assessment using 3-dimensional reverse engineering. *Med Eng Phys* 2002;24:617–22.
- [44] Sariali E, Mouttet A, Pasquier G, Durante E. Three-dimensional hip anatomy in osteoarthritis. Analysis of the femoral offset. *J Arthroplasty* 2009;24:990–7. <https://doi.org/10.1016/j.arth.2008.04.031>.
- [45] Bauman PA, Singson R, Hamilton WG. Femoral neck anteversion in ballerinas. *Clin Orthop Relat Res* 1994;302:57–63.
- [46] Massin P, Geais L, Astoin E, Simondi M, Lavaste F. The anatomic basis for the concept of lateralized femoral stems. *J Arthroplasty* 2000;15:93–101. [https://doi.org/10.1016/S0883-5403\(00\)91337-8](https://doi.org/10.1016/S0883-5403(00)91337-8).
- [47] Traina F, De Clerico M, Biondi F, Pilla F, Tassinari E, Toni A. Sex differences in hip morphology: is stem modularity effective for total hip replacement? *J Bone Joint Surg Am* 2009;91:121–8. <https://doi.org/10.2106/JBJS.I.00533>.
- [48] Boymans TAEJ, Heyligers IC, Grimm B. The morphology of the proximal femoral canal continues to change in the very elderly: implications for total hip arthroplasty. *J Arthroplasty* 2015;30:2328–32. <https://doi.org/10.1016/j.arth.2015.06.020>.
- [49] Matsushita A, Nakashima Y, Jingushi S, Yamamoto T, Kuraoka A, Iwamoto Y. Effects of the femoral offset and the head size on the safe range of motion in total hip arthroplasty. *J Arthroplasty* 2009;24:646–51. <https://doi.org/10.1016/j.arth.2008.02.008>.
- [50] Child SL, Cowgill LW. Femoral neck-shaft angle and climate-induced body proportions. *Am J Phys Anthropol* 2017;164:720–35. <https://doi.org/10.1002/ajpa.23311>.
- [51] Muthuri SG, Saunders FR, Hardy RJ, Pavlova AV, Martin KR, Gregory JS, et al. Associations between body mass index across adult life and hip shapes at age 60 to 64: evidence from the 1946 British birth cohort. *Bone* 2017;105:115–21. <https://doi.org/10.1016/j.bone.2017.08.017>.