



**HAL**  
open science

# Double Fenestrated Physician-Modified Stent Graft for Endovascular Treatment of Traumatic Aortic Isthmus Rupture With an Aberrant Right Subclavian Artery

Leonore Freycon-Tardy, Baris Ata Ozdemir, Kheira Hireche, Pierre Alric,  
Ludovic Canaud

► **To cite this version:**

Leonore Freycon-Tardy, Baris Ata Ozdemir, Kheira Hireche, Pierre Alric, Ludovic Canaud. Double Fenestrated Physician-Modified Stent Graft for Endovascular Treatment of Traumatic Aortic Isthmus Rupture With an Aberrant Right Subclavian Artery. *Journal of endovascular therapy*, In press, pp.152660282110709. 10.1177/15266028211070964 . hal-03550811

**HAL Id: hal-03550811**

**<https://hal.science/hal-03550811>**

Submitted on 28 Jun 2023

**HAL** is a multi-disciplinary open access archive for the deposit and dissemination of scientific research documents, whether they are published or not. The documents may come from teaching and research institutions in France or abroad, or from public or private research centers.

L'archive ouverte pluridisciplinaire **HAL**, est destinée au dépôt et à la diffusion de documents scientifiques de niveau recherche, publiés ou non, émanant des établissements d'enseignement et de recherche français ou étrangers, des laboratoires publics ou privés.

# **Double Fenestrated Physician-Modified Stent Graft for Endovascular Treatment of Traumatic Aortic Isthmus Rupture With an Aberrant Right Subclavian Artery**

Leonore Freycon-Tardy, MD1 , Baris Ata Ozdemir, FRCS, PhD1,2, Kheira Hireche, MD1, Pierre Alric, MD, PhD1,3, and Ludovic Canaud, MD, PhD1,3

1 Department of Thoracic and Vascular Surgery, Arnaud de Villeneuve Hospital, Montpellier, France

2 University of Bristol, Bristol, UK

3PhyMedExp, CNRS, INSERM, CHU Montpellier, University of Montpellier, Montpellier, France

## **Corresponding Author:**

Ludovic Canaud, Department of Thoracic and Vascular Surgery, Arnaud de Villeneuve Hospital, 191 street Doyen Gaston Giraud, Montpellier 34090, France.

**Email:** [ludoviccanaud@hotmail.com](mailto:ludoviccanaud@hotmail.com)

## **Keywords**

thoracic aorta, aorta, homemade fenestrated stent graft, physician-modified stent graft, blunt traumatic aortic injury

---

# Abstract

## **Purpose:**

The purpose of the study was to demonstrate the feasibility of urgent endovascular treatment of a traumatic aortic isthmus rupture in a patient with an aberrant right subclavian artery.

## **Case report:**

A 23-year-old man was admitted to a regional trauma center after a motor vehicle collision and found to have cerebral trauma and a large pseudoaneurysm of the aortic arch. Trauma computed tomography (CT) identified a blunt traumatic thoracic aortic injury with an aortic false aneurysm in the context of an aberrant right subclavian artery. A hybrid repair was performed with bilateral subclavian carotid bypasses and a double fenestrated physician-modified stent graft. The patient had an uneventful postoperative course. Postoperative CT scan showed sealing of the aortic arch rupture and patency of all the supra-aortic trunks.

## **Conclusion:**

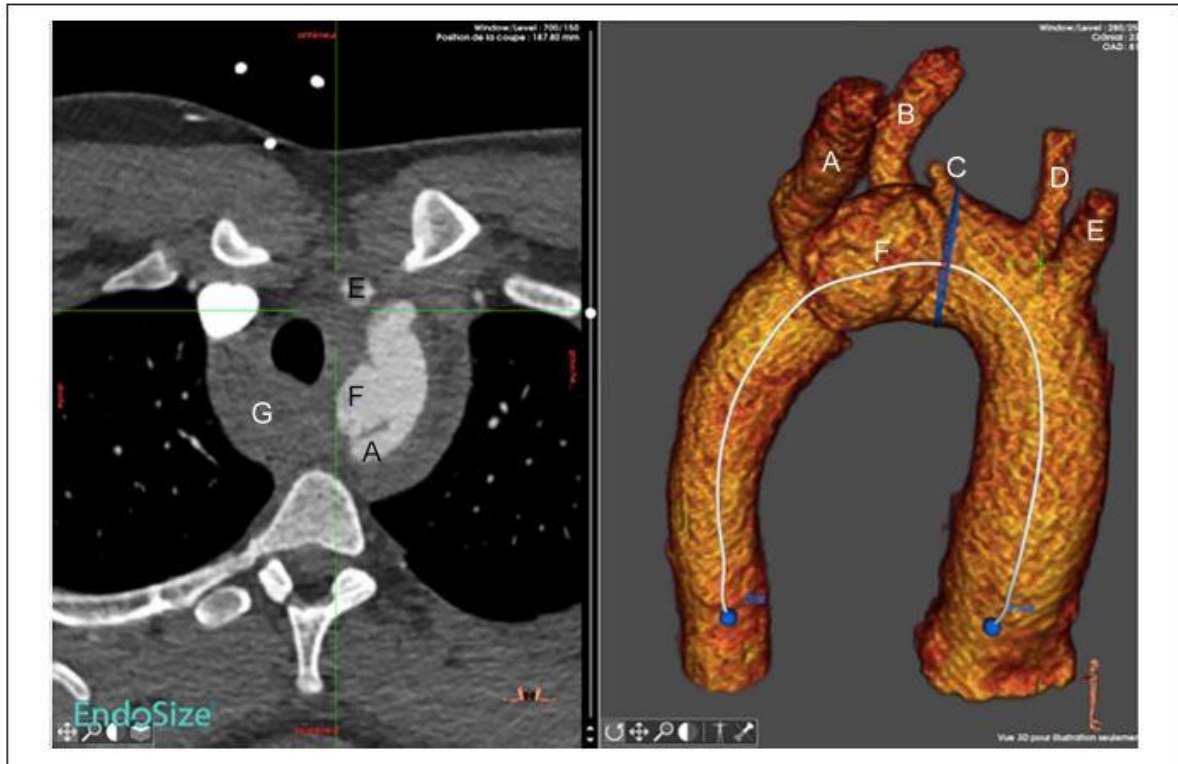
Endovascular repair of blunt traumatic thoracic aortic injury is considered first-line therapy. Aortic arch anomalies add complexity to treatment. This report demonstrates that a hybrid strategy with bilateral carotid-axillary bypasses and homemade double fenestrated endograft of the aortic arch is a valuable approach for this challenging emergency in the context of an aberrant right subclavian artery.

# Introduction

Blunt traumatic thoracic aortic injury (BTTI) is a rare life threatening injury, the management of which, in recent decades, has been revolutionized by the advent of TEVAR.

An aberrant right subclavian artery (also called *arteria lusoria*) is the most common congenital malformation of the aortic arch present in less than 2% of the general population.<sup>1,2</sup> Four vessels arise sequentially from the aortic arch: the right common carotid artery, the left common carotid artery (LCCA), the left subclavian artery (LSA), and the aberrant right subclavian artery, which crosses superior and from left to right in the posterior mediastinum.<sup>1</sup>

The rare coexistence of an aberrant right subclavian artery in BTTI has been reported in the literature and complicates surgical repair. The authors report an unusual case of blunt aortic injury in a young patient with an aberrant right subclavian artery treated with hybrid bilateral carotid-axillary bypasses and double fenestrated endograft of the aortic arch is reported.



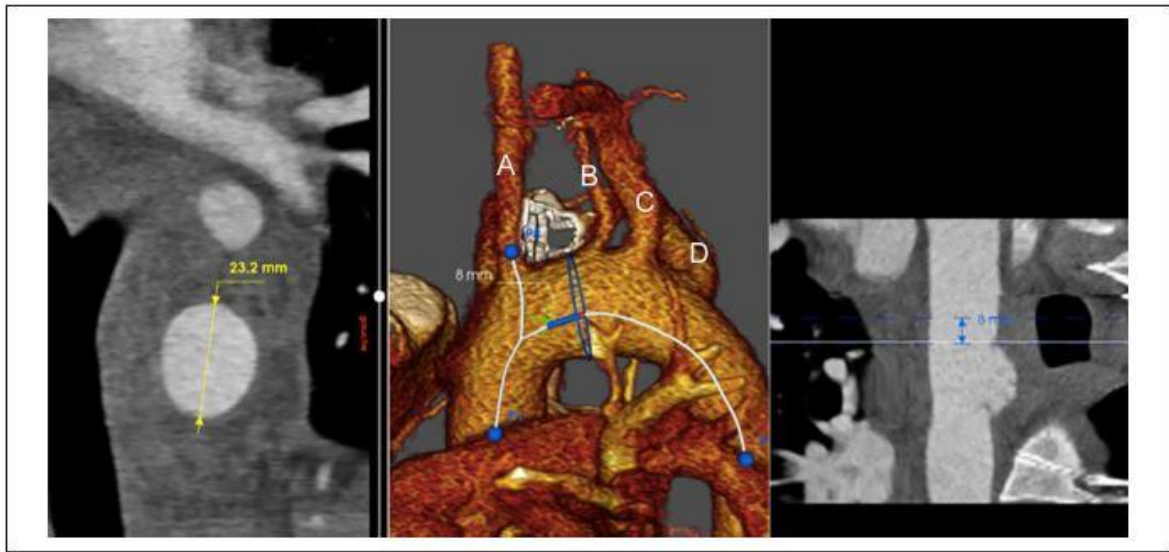
**Figure 1.** Preoperative scanner: (A) Right subclavian artery; (B) left subclavian artery; (C) left vertebral artery; (D) left carotid artery; (E) right carotid artery; (F) false aneurysm; (G) hemomediastinum.

## Case Report

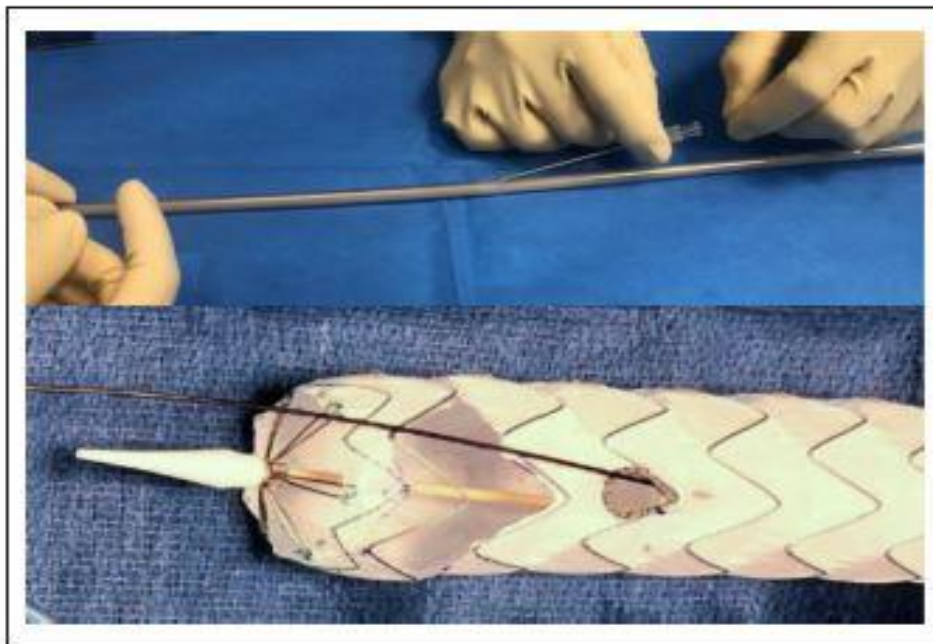
A 23-year-old otherwise fit and healthy man was admitted to a regional trauma center following a motor vehicle collision. The patient was hemodynamically stable. Total body trauma computed tomography (CT) identified cerebral trauma and a large aortic arch pseudoaneurysm. The BTTI was a grade III injury (false aneurysm with subadventitial rupture) complicated by a hemomediastinum and the abnormal origin of the right subclavian artery was identified (Figure 1 and Supplemental Movie 1). The pseudoaneurysm measured 20 mm, was located lateral to the aortic arch, and involved the origins of left and right subclavian arteries. Length between the LCCA and the false aneurysm was 8 mm (Figure 2). The left vertebral origin was directly from the aortic arch.

To avoid aggravating the edema associated with the cerebral injury, the trauma multidisciplinary team selected hybrid repair of the aortic injury with surgical debranching of both subclavian arteries and a physician-modified double fenestrated stent graft, thus avoiding cardiopulmonary bypass or cardiac arrest under deep hypothermia.

The procedure was performed in a hybrid room under general anesthesia. Bilateral Dacron prosthetic carotid-subclavian bypasses (MAQUET Holding B.V. & Co. KG, Rastatt, Germany) were fashioned, followed by Amplatzer Vascular Plug II (AVPII, St. Jude medical, St. Paul, MN, USA) occlusion of the right subclavian artery proximal to the origin of the right vertebral artery from the axillary access.



**Figure 2.** Distance between left carotid artery and false aneurysm: (A) Left carotid artery; (B) left vertebral artery; (C) left subclavian artery; (D) right subclavian artery.



**Figure 3.** Guidewire's path through the endograft sheath and fenestration.

In parallel, a double fenestrated stent graft (Valiant Captivia, 24-24/100 mm; Medtronic, Santa Rosa, CA, USA) was modified to accommodate the patient anatomy. The first fenestration was planned for the right carotid artery and the second for LCCA. The technical aspects of device modification and fenestration have previously been reported in detail.<sup>3</sup> Subsequently, a needle access into the introducer sheath (graft cover) just distal to the section bearing the endograft was used to pass a 260 cm 0.035 hydrophilic stiff angled guidewire

cephalad. The guidewire traversed both the inside of the sheath and the deployed endograft before being delivered through the left common carotid fenestration and continues cephalad external to the endograft (Figure 3). The endograft was re-sheathed using nylon tape and snuggers. The left common femoral artery was exposed. Systemic heparin 100 units/kg was administered and activated clotting time monitored. A 24 French 33 cm length introducer sheath was placed retrograde through the common femoral access. A 7 French 45 cm sheath introducer was placed through retrograde LCCA access to the ostium of this vessel. A double curved 300 cm extra stiff 0.035 wire was positioned against the aortic valve through the femoral access. The proximal side of the preloaded guide wire was advanced through the femoral access sheath, delivered to the LCCA using a 6 French 25 mm snare loop and exteriorized, establishing a through-and-through wire. The endograft was advanced over the Lunderquist wire, while simultaneously the preloaded hydrophilic guidewire was progressively pulled by the second operator from the LCCA access, orientating the fenestrations superiorly to face the supra-aortic trunks originating off the superior arch. The first angiographic run, perpendicular to the LCCA, was performed through the LCCA sheath. Mean blood pressure was lowered to approximately 80 mmHg and deployment commenced under visualization. Rapid pacing was not used. The 7 French carotid sheath was advanced with its dilatator through the LCCA fenestration over the preloaded guidewire into the stent graft lumen. A balloon-expandable covered stent (10 mm in diameter and 38 mm in length; LifeStream; Bard, Tempe, Arizona) was inflated, protruding 5 mm into the aortic stent graft lumen, with the remaining length in the LCCA. The covered stent was flared using a 12 mm balloon. Completion angiography was performed to verify the correct position of the Physician-modified endovascular grafts (PMEGs) and patency of all supraaortic vessel trunks.

The patient had an uneventful postoperative route. The postoperative CT scan demonstrated complete exclusion of the rupture and the patency of the supra-aortic trunks. The patient was discharged from hospital on postoperative day 5 on aspirin.

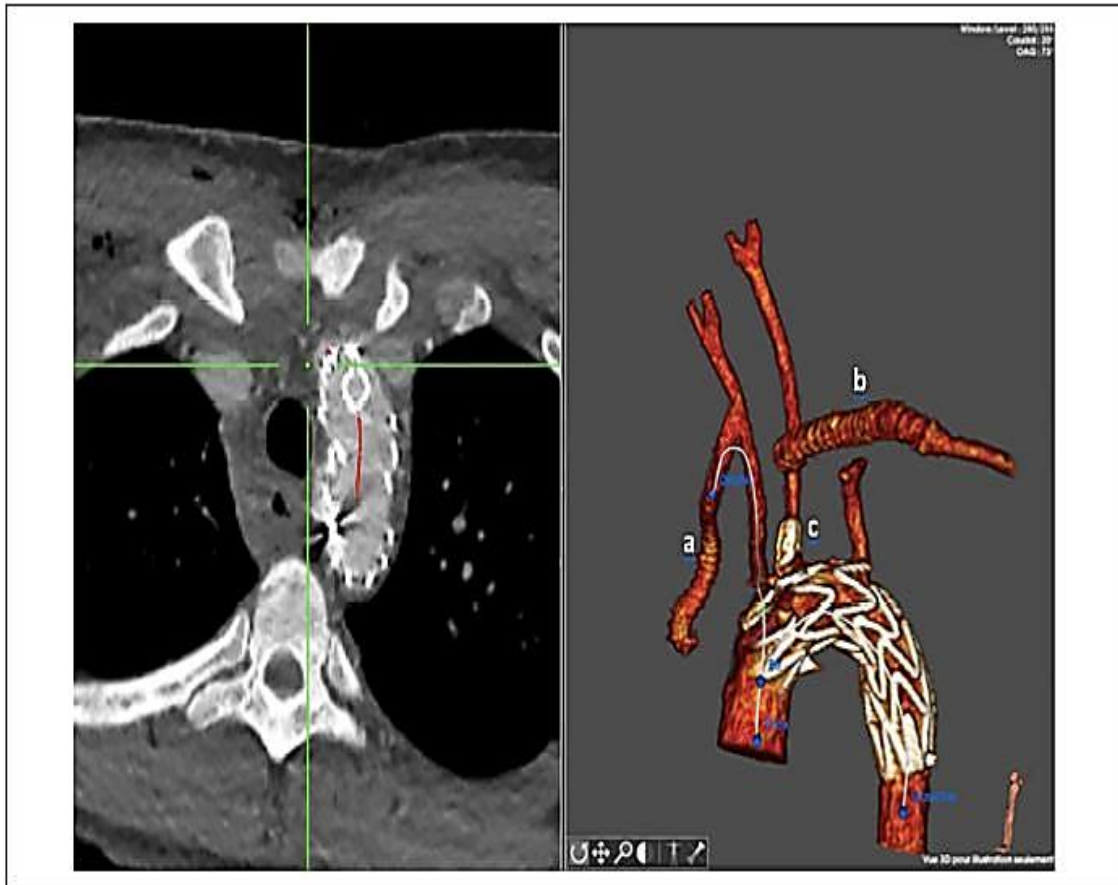Eight months follow-up was satisfactory, both clinically and radiologically (Figure 4). All supra-aortic trunks were patent and no endo leak was visualized.

## Discussion

Physician-modified fenestration offers an efficient technique for emergent repair of the aortic arch. This approach avoided zone 0 debranching requiring a sternotomy and clamping of the ascending aorta in a patient with cerebral trauma.

In recent decades, TEVAR has become established as the principal strategy management for aortic isthmus rupture, indicated for patients with injury grades II, III, and IV. Endovascular repair is strongly recommended for patients with a suitable anatomy.<sup>4,5</sup> Immediate repair is recommended for patients without other life-threatening injuries.

In the literature, only 2 cases of blunt traumatic thoracic injury with arteria lusoria have been described. The first patient was treated with open surgery under extracorporeal circulation,<sup>6</sup> whereas the second report described a hybrid approach with right subclavian transposition to the right carotid and standard TEVAR.<sup>7</sup>



**Figure 4.** Eight months postoperative scanner. a, right carotid-subclavian bypass; b, left carotid-subclavian bypass; c, left carotid stent.

In this patient, these therapeutic options were considered. Open surgery of a traumatic rupture of the aortic arch I is associated with a significant mortality (16%-31%) and paraplegia (5%-19%).<sup>3</sup> Furthermore, due to the cerebral trauma, the risk of cardiopulmonary bypass under deep hypothermia was considered high risk of exacerbating the cerebral injury. Chimney was an option; however, the rate of type 1 endoleak for this repair in the aortic arch remains sustainable.<sup>8</sup> In situ fenestration of the supra-aortic trunks was a feasible option that requires the use of an extracorporeal circulation.<sup>9</sup> The alternative hybrid option requiring total debranching of supra-aortic trunks and bypass from the ascending aorta combined with a standard endograft was obviously more invasive and associated with a significant risk of decontaining the rupture during the ascending aorta exposure. The LSA coverage is associated with complications; including stroke, spinal cord, and upper limb ischemia.<sup>10</sup> We believe that its revascularization is particularly warranted in this case of both subclavian endovascular coverage. Moreover, to avoid vertebrobasilar stroke, the realization of the right carotid-subclavian bypass was mandatory because of the endovascular coverage of the aortic origin of the left vertebral artery. The presence of aberrant right subclavian artery can be associated with other congenital anomalies which should be researched.<sup>2</sup>

The PMEGs with double fenestration have proved their feasibility and safety in treatment of aortic arch dissections and aneurysms.<sup>8,10,11</sup> The mid-term results are encouraging. This custom made technique is particularly adapted to emergency cases like this one.

Prefabricated, patient-customized devices require extensive planning with precise preoperative imaging and time for graft manufacturing. For this reason, these modalities are often not advisable or feasible for patients presenting with the acute thoracic aortic pathologies as described in this case.

We recognize that the current practice of endograft modification is controversial. Increasing experience with endovascular management of vascular pathology has led to efforts to broaden the indications for use of these techniques. Moreover, this procedure should be performed in high volume centers with vast endovascular and surgical expertise.

As with any endovascular procedure, strict surveillance of these endografts and modifications will be necessary to ensure durability of repair. The long-term interactions between the endograft and the covered stent will need to be monitored closely over time because of the potential for stent collapse or stent breakage and the development of a late type III endoleak between the 2 components. Until further technologic advances and clinical trials lead to the approval of branched arch devices, this technique offers a safe and feasible strategy. Longer follow-up remains necessary to elucidate the durability.

## Conclusion

Endovascular repair of BTTI is considered first-line therapy. Aortic arch anomalies can complicate the treatment. This report demonstrates that a hybrid strategy with bilateral carotid-axillary bypasses and homemade double fenestrated endograft of the aortic arch is a valuable approach for this challenging emergency.

### Declaration of Conflicting Interests

The author(s) declared no potential conflicts of interest with respect to the research, authorship, and/or publication of this article.

### Funding

The author(s) received no financial support for the research, authorship, and/or publication of this article.

## References

1. Myers PO, Fasel JHD, Kalangos A, et al. Arteria lusoria: developmental anatomy, clinical, radiological and surgical aspects. *Ann Cardiol Angeiol*. 2010;59:147–154.
2. Hanneman K, Newman B, Chan F. Congenital variants and anomalies of the aortic arch. *Radiographics*. 2017;37:32–51.
3. Canaud L, Ozdemir BA, Chassin-Trubert L, et al. Double homemade fenestrated stent graft for total endovascular aortic arch repair. *J Vasc Surg*. 2019;70:1031–1038.



4. Fox N, Schwartz D, Salazar JH, et al. Evaluation and management of blunt traumatic aortic injury: a practice management guideline from the Eastern Association for the Surgery of Trauma. *J Trauma Acute Care Surg*. 2015;78:136–146.
5. Riambau V, Böckler D, Brunkwall J, et al. Editor's choice— management of descending thoracic aorta diseases. *Eur J Vasc Endovasc Surg*. 2017;53:4–52.
6. Rosenbusch G, Vincent J, Wissink H. Traumatische Ruptur der thorakalen Aorta bei A. Subclavia dextra lusoria. *RöFo - Fortschritte Auf Dem Geb Röntgenstrahlen Bildgeb Verfahr*. 1976;125:54–56.
7. Ktenidis K, Lioupis A, Giannopoulos A, et al. Management of traumatic aortic isthmus rupture in case of aberrant right subclavian artery (arteria lusoria). *Ann Vasc Surg*. 2012;26:421.
8. Li Y, Hu Z, Wang J, et al. Endovascular chimney technique for aortic arch pathologies treatment: a systematic review and meta-analysis. *Ann Vasc Surg*. 2018;47:305–315.
9. Shang T, Tian L, Li D, et al. Favourable outcomes of endovascular total aortic arch repair via needle based in situ fenestration at a mean follow-up of 5.4 months. *Eur J Vasc Endovasc Surg*. 2018;55:369–376.
10. Rizvi A, Murad M, Fairman R, et al. The effect of left subclavian artery coverage on morbidity and mortality in patients undergoing endovascular thoracic aortic interventions: a systematic review and meta-analysis. *J Vasc Surg*. 2009;50:1159–1169.
11. Canaud L, Ozdemir BA, Chassin-Trubert L, et al. Homemade fenestrated stent-grafts for complete endovascular repair of aortic arch dissections. *J Endovasc Ther*. 2019;26:645–651.