



**HAL**  
open science

## **A dynamic study of the anterior cruciate ligament of the knee using an open MRI.**

Daphne Guenoun, Julien Vaccaro, Thomas Le Corroller, Pierre-Antoine Barral, Aude Lagier, Vanessa Pauly, Benjamin Coquart, Joel Coste, Pierre Champsaur

### **► To cite this version:**

Daphne Guenoun, Julien Vaccaro, Thomas Le Corroller, Pierre-Antoine Barral, Aude Lagier, et al.. A dynamic study of the anterior cruciate ligament of the knee using an open MRI.. Surgical and Radiologic Anatomy, 2017, 39 (3), pp.307–314. 10.1007/s00276-016-1730-x . hal-03550306

**HAL Id: hal-03550306**

**<https://hal.science/hal-03550306v1>**

Submitted on 10 May 2023

**HAL** is a multi-disciplinary open access archive for the deposit and dissemination of scientific research documents, whether they are published or not. The documents may come from teaching and research institutions in France or abroad, or from public or private research centers.

L'archive ouverte pluridisciplinaire **HAL**, est destinée au dépôt et à la diffusion de documents scientifiques de niveau recherche, publiés ou non, émanant des établissements d'enseignement et de recherche français ou étrangers, des laboratoires publics ou privés.

# A dynamic study of the anterior cruciate ligament of the knee using an open MRI

Daphne Guenoun<sup>1</sup> · Julien Vaccaro<sup>1</sup> · Thomas Le Corroller<sup>1</sup> · Pierre-Antoine Barral<sup>1</sup> · Aude Lagier<sup>2</sup> · Vanessa Pauly<sup>3</sup> · Benjamin Coquart<sup>1</sup> · Joel Coste<sup>4</sup> · Pierre Champsaur<sup>1</sup>

**Abstract** Recent anatomical and radiological studies of the anterior cruciate ligament (ACL) suggest the ACL length and orientation change during knee flexion, and an open MRI sequencing during knee flexion enables a dynamic ACL analysis. This study's goal is to describe a normal ACL using a 1T open MRI and, in particular, variations in length and insertion angles at different degrees of flexion. Twenty-one volunteers with clinically healthy knees received a dynamic MRI with their knees in hyperextension, neutral position, and flexed at 45° and 90° angles. For each position, two radiologists measured the ACL lengths and angles of the proximal insertion between the ACL's anterior edge and the roof of the inter-condylar notch. Additionally, we measured the ACL's and the tibial plateau's distal angle insertion between their anterior edges and then compared these with the nonparametric Wilcoxon test. The ACL had a significant extension between the 90° flexion and all other positions

(hyperextension:  $31.75 \pm 2.5$  mm, neutral position:  $32.5 \pm 2.6$  mm, 45°:  $35.6 \pm 1.6$  mm, 90°:  $35.6 \pm 1.6$  mm). There was also a significant increase of the angle insertion between the proximal 90° flexion and all other positions, as well as between hyperextension and bending to 45° (hyperextension:  $2.45^\circ \pm 3.7^\circ$ , neutral:  $13.4^\circ \pm 9.7^\circ$ , 45°:  $33.25 \pm 9.3$ , 90°:  $51.85^\circ \pm 9.3^\circ$ ). Additionally, there is a significant increase in the distal angle insertion for all positions (hyperextension:  $133.2^\circ \pm 5.4^\circ$ , neutral position:  $134.95^\circ \pm 4.4^\circ$ , 45°:  $138.35^\circ \pm 5.9^\circ$ , 90°:  $149.15^\circ \pm 8.6^\circ$ ). Our study is the first to exhibit that a dynamic MRI has a significant ACL extension in vivo during bending. This concept opens the way for further studies to improve the diagnosis of traumatic ACL injuries using a dynamic MRI.

**Keywords** Dynamic MRI · Anterior cruciate ligament · Knee · Open field · Anatomy

---

✉ Daphne Guenoun  
Daphne.guenoun@ap-hm.fr

Julien Vaccaro  
Julien.vaccaro@yahoo.fr

Thomas Le Corroller  
Thomas.lecorroller@ap-hm.fr

Pierre-Antoine Barral  
Pierre-antoine.barral@ap-hm.fr

Aude Lagier  
Aude.lagier@laposte.net

Vanessa Pauly  
Vanessa.pauly@ap-hm.fr

Benjamin Coquart  
Benjamin.coquart@ap-hm.fr

Joel Coste  
Joel-alain.coste@ap-hm.fr

Pierre Champsaur  
Pierre.champsaur@ap-hm.fr

<sup>1</sup> Department of Radiology, Sainte-Marguerite Hospital, Institute for Locomotion, APHM, 13009 Marseille, France

<sup>2</sup> Department of Anatomy, Aix Marseille Université, 13005 Marseille, France

<sup>3</sup> Unité de Recherche EA3279, Santé Publique et Maladies Chroniques: Qualité de vie Concepts, Usages et Limites, Déterminants, Aix Marseille Université, 13005 Marseille, France

<sup>4</sup> Department of Rheumatology, Sainte-Marguerite Hospital, Institute for Locomotion, APHM, 13009 Marseille, France

## Introduction

The anterior cruciate ligament (ACL) is one of the key knee stabilizers, and the most frequently injured ligament structure in knee trauma. In France, there are nearly 15,000 ACL tears per year from skiing as compared to 175,000 ligamentoplasty surgeries performed in the United States [7]. The biomechanical changes, loss of function and premature degenerative changes which can result from an ACL tear mandate an early diagnosis of a partial or complete ACL rupture.

While diagnosing an ACL tear is clinical, an MRI has long been the complementary examination of reference for confirmation. Because of its 92–97 % sensitivity and 92–99 % specificity [5, 11, 22], it is particularly informative for the impossible or doubtful clinical examinations as well as for related injury research. Therefore, the ACL has long been a preferred topic of study.

The evolution of medicine's knowledge of anatomy and biomechanics along with imaging's evolving, descriptive precision has improved patient care and functional prognosis.

Long considered isometric, new studies have recently demonstrated ACL's extension during flexion [15, 19, 25]. Additionally, some pre-existing dynamic knee studies better visualize the ACL during flexion despite using a closed rigid antenna which technically limits range of motion [17, 19]. The development of open MRIs and mobile surface antennas allow the realization of a dynamic MRI without any movement restrictions.

This study's goal is to describe a normal ACL using a 1T open MRI, and particularly variations in length and insertion angles at different degrees of flexion.

## Materials and methods

In compliance with institutional ethics regulations and after obtaining an informed consent, we performed MRI knee examinations on 21 volunteers between January and March 2016. None had any history of knee trauma or surgery and

all were asymptomatic. One patient was excluded from the study upon discovering an old ACL injury. The examinations were performed with a 1T open MRI (Panorama HFO 1 Tesla, Philips).

Each patient was placed in a lateral position and the knee was fixed using a graduated wedge angle system (graduated dynamic kit) to achieve different standardized and reproducible degrees of flexion (Fig. 1). Images were obtained using a standard, flexible knee surface antenna centered on the tip of the patella.

The protocol included coronal STIR sequences (TR = 2530 ms; TE = 20 ms; FOV = 160 × 148 mm<sup>2</sup>; Gap = 0) with a 3.5 mm slice thickness to identify ACL femoral insertions and achieve the sagittal sequences. This was followed by dynamic T2 fat sat (TR = 1812 ms; TE = 20 ms; FOV = 250 × 250 mm<sup>2</sup>; Gap = 0) sagittal obliques sequences, with a 3 mm slice thickness, ACL centered and successively realized while hyperextended, in a neutral position, and with 45° and 90° flexion positions.

For each knee, we measured:

- ACL at its greatest length in the sagittal plane between its intercondylar notch proximal insertion and its distal insertion on the tibial spines.
- The angle of proximal insertion, formed between the anterior ACL edge and the roof of the intercondylar notch (Blumensaat's line).
- The angle of distal insertion formed between the ACL and the anterior edge of the tibial plateau.

The morphological analysis and different measurements were successfully and independently achieved by both a senior and junior physician. When there was a disparity in their independent results, they jointly chose the measurements.

The data's statistical analysis was performed with the SAS<sup>®</sup> V9.4. A comparison of different measurements of the four positions (hyperextension, neutral position, and 45°, 90° angles) was performed using the nonparametric Wilcoxon test for paired data. In cases of globally significant statistical differences in the Wilcoxon test alpha level



**Fig. 1** a Patient position in the open-field MRI; b graduated dynamic kit

of 5 %, we conducted nonparametric, side by side post hoc test comparisons according to Dwass, Steel, Critchlow-Fligner (DSCF) available as SAS V9 0.4. The significance level is the threshold  $\alpha = 0.05$ .

## Results

We studied MRIs of 20 healthy knees in positions of hyperextension, neutral, 45° and 90° flexion.

Volunteers included 9 men and 11 women, from 24 to 47 years old (mean age = 32 years old).

### Lengthening of ACL

In our group, the average ACL lengths were  $31.75 \pm 2.5$  mm hyperextended,  $32.5 \pm 2.6$  mm in a neutral position, and  $33.5 \pm 1.8$  mm at 45° flexion and  $35.6 \pm 1.6$  mm 90° flexion (Table 1; Fig. 2) with an average elongation of 3.85 mm between the hyperextension and the 90° flexion.

The statistical analysis shows there is a significant difference in elongation between the different positions ( $p < 0.0001$ ; global Wilcoxon test). The side by side post

hoc test comparisons show these differences are between the 90° flexion and all other positions [hyperextension vs. 90° flexion ( $p < 0.0001$ )]; neutral position vs 90° flexion ( $p = 0.0016$ ); 45° flexion vs 90° flexion ( $p = 0.0052$ ) (Fig. 3). There was, however, no significant difference observed between hyperextension and the 45° angle.

### Insertion angles

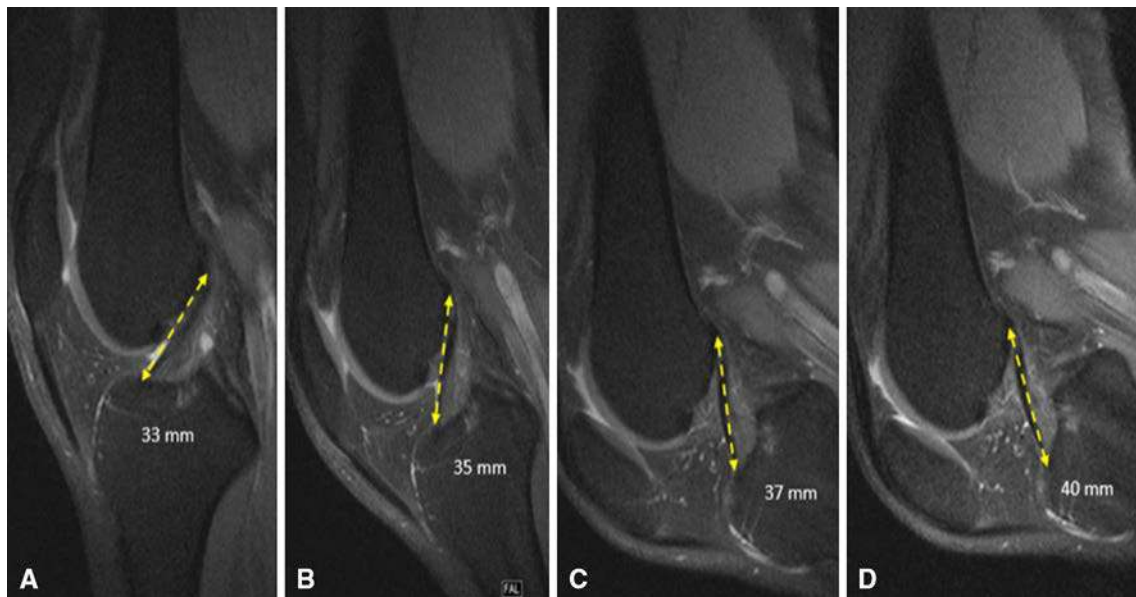
#### Proximal angle

Mean values were calculated at  $2.45^\circ \pm 3.7^\circ$  for hyperextension;  $13.4^\circ \pm 9.7^\circ$  in the neutral position;  $33.25 \pm 9.3$  with 45° of flexion; and  $51.85^\circ \pm 9.3^\circ$  with 90° flexion (Table 2; Fig. 4).

The statistical analysis showed a significant difference in the increase between the different positions ( $p < 0.0001$ ; global Wilcoxon test). Side by side post hoc test comparisons show that these differences are between 90° flexion and all other positions [hyperextension vs 90° flexion ( $p < 0.0001$ ); the neutral position vs a 90° flexion ( $p < 0.001$ ); 45° flexion vs 90° flexion ( $p = 0.0008$ ); and between the 45° flexion and hyperextension ( $p = 0.04$ )].

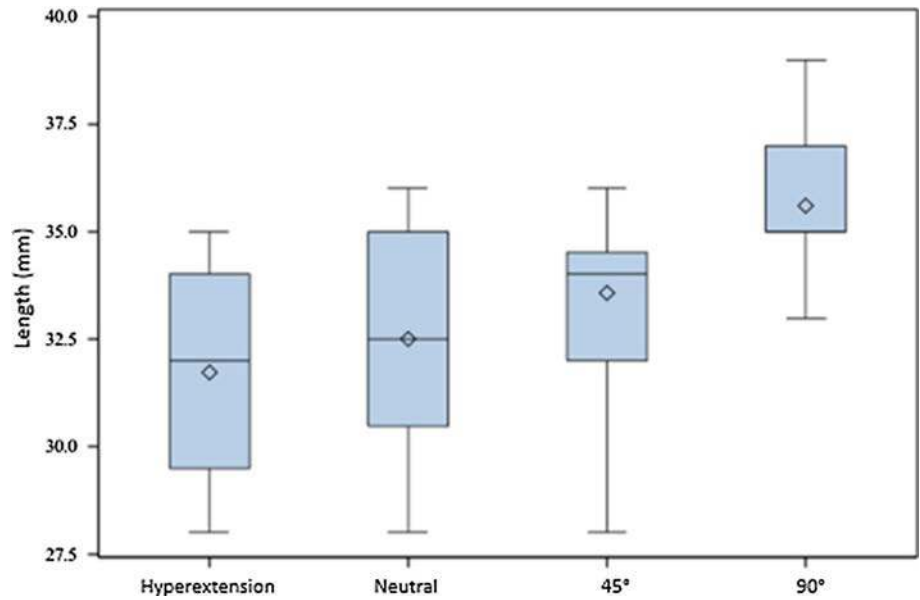
**Table 1** Summary of ACL measurements in different positions

	Hyperextension	Neutral position	45° Flexion	90° Flexion
Average	31.75	32.5	33.55	35.6
Standard deviation	2.5	2.6	1.8	1.6
Minimum	28	28	28	33
Maximum	35	36	36	39
Median	32	32.5	34	35



**Fig. 2** Oblique sagittal cuts showing ACL's elongation during flexion. **a** Hyperextension; **b** neutral position; **c** 45° flexion; **d** 90° flexion

**Fig. 3** Distribution of ACL length in various positions ( $p < 0.001$ )



**Table 2** Summary of angle measurements in various positions between the ACL and the anterior tibial tray

	Hyperextension	Neutral position	45° Flexion	90° Flexion
Average	133.2	134.95	138.35	149.15
Standard deviation	5.4	4.3	5.9	8.6
Minimum	119	125	126	135
Maximum	145	145	52	163
Median	134.5	135.5	139	149

### Distal angle

Mean values were measured at  $133.2^\circ \pm 5.4^\circ$  with hyperextension;  $134.95^\circ \pm 4.4^\circ$  in the neutral position;  $138.35^\circ \pm 5.9^\circ$  with a  $45^\circ$  flexion; and  $149.15^\circ \pm 8.6^\circ$  with a  $90^\circ$  flexion (Table 3; Fig. 5).

The statistical analysis showed a significant difference in the increase between the various positions ( $p < 0.0001$ ; global Wilcoxon test). Side by side post hoc test comparisons showed that these differences exist with all compared positions (with  $p$  values all  $< 0.0001$ ).

In general, the  $90^\circ$  flexion is the only position where a significant difference is demonstrated both for ACL elongation, the increased angle between the ACL and the anterior tibial plateau; as well as an increase between the antrum angle and Blumensaat's line.

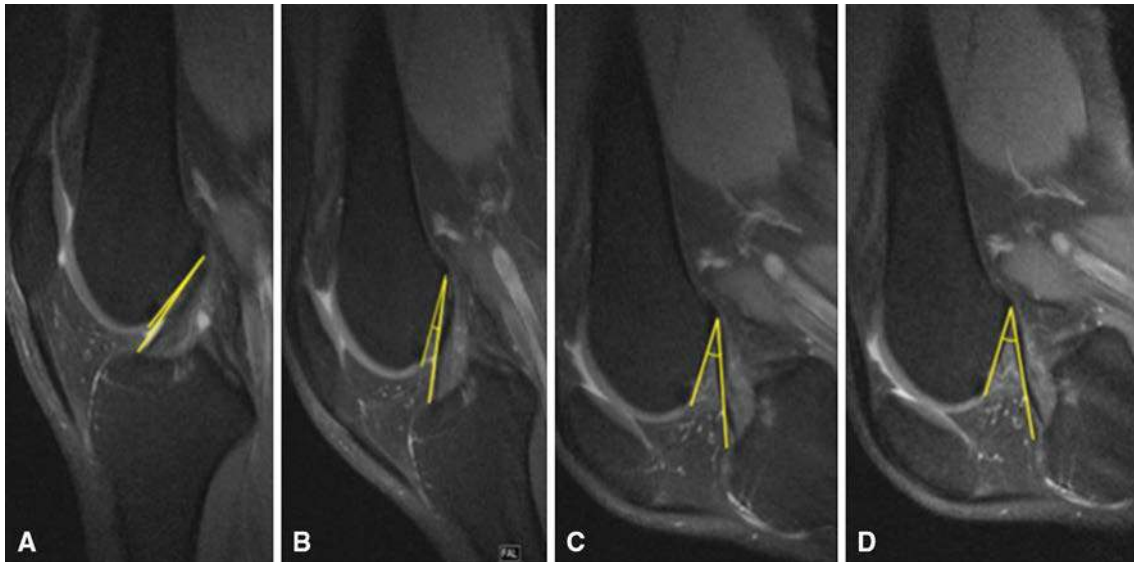### Discussion

The ACL, a key stabilizing element of the knee, prevents anterior tibial translation and medial rotation. This is a ligamentous structure, formed of dense connective intra-articular tissue, with an oblique, forward extra synovial

downward trajectory. Its distal fibers fan out in the tibial spines and are easily visible with conventional MRI sequencing. Its proximal fibers are, however, less distinct and more difficult to isolate with an MRI due to an insertion on the medial surface of the lateral femoral condyle [6], which can be responsible for partial volume artifacts [7, 14].

Its average measurement is 38 mm long and 11 mm wide [4, 6] from one knee to the other for the same patient [3]. It consists of two distinct bundles: an anteromedial (AM) and posterolateral (PL), which are named in function of their tibial inserts. The AM is longer ( $36.9 \pm 2.6$  mm) and wider than the PL ( $20.5 \pm 2.6$  mm). It is situated higher and behind the femur, and in front of the tibial spines. Because of this length difference and study design, the ACL's greatest length actually corresponds to the AM measurement. We were able to substantiate that our various benchmarks actually corresponded to the AM insertion points and that the structure visualized and measured was in fact the AM.

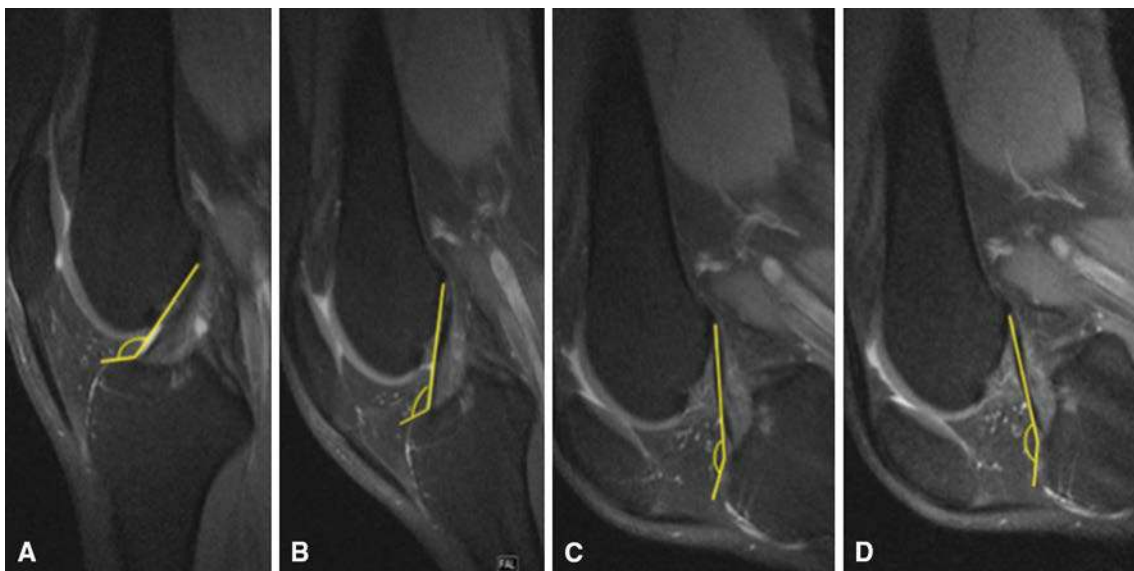
Digitally measuring, the ACL is one of the strengths of our study. Considering the ACL's short length, this type of measure is more accurate and less prone to error than the biomechanical techniques previously used on cadavers.



**Fig. 4** Angle increase of proximal insertion during bending: **a** hyperextension: 135°; **b** neutral position: 139°; **c** 45° flexion: 143°; **d** 90° flexion: 159°

**Table 3** Summary of angle measurements in different positions between the ACL and the cortex of the inter-condylar notch

	Hyperextension	Neutral position	45° Flexion	90° Flexion
Average	2.45	13.4	33.25	51.85
Standard deviation	3.7	9.7	9.3	9.3
Minimum	0	0	18	30
Maximum	11	33	47	65
Median	0	10.5	33	54



**Fig. 5** Angle increase of distal insertion during bending: **a** hyperextension: 135°; **b** neutral position: 139°; **c** 45° flexion: 143°; **d** 90° flexion: 159°

In addition, an open MRI allows imagery without any amplitude limits.

Our study is limited by the small number of patients examined. Similarly the choice of imagery protocol in the

oblique sagittal plane is debatable because it does not allow a distinction between AM and PL, but it is the only one to allow visualization and an accurate measurement of the ligament in its entirety on a single cut.



The ACL is the most commonly injured structure during knee trauma. Its rupture most often follows a lateral rotating mechanism, flexion and a forced valgus. The rupture diagnosis is essentially clinical, substantiated with a positive anterior drawer, Lachman test, and joint effusion.

In clinically doubtful cases, an MRI can assist with a diagnosis, especially when pre-operatively detecting any associated injuries. The MRI is the examination of reference for diagnosing ACL injuries because of its sensitivity (92–97 %) and specificity (92–99 %) [5, 11, 22]. Good visualization and knowledge of the ACL's normal appearance are essential for an accurate diagnosis [12]. In cases of a rupture, an early diagnosis is crucial because of the instability and stress related changes, which in turn, are responsible for early meniscal and cartilage degenerative lesions [2, 13].

The ACL normality criteria are well defined. The ligament presents as a T1- and T2-hypointense, continuous, sharply contoured and stretched with a parallel orientation to the roof notch (Blumensaat's line). However, due to its orientation and partial volume artifacts, the ACL is not completely viewed in 5–10 % of the cases [14], particularly to its proximal insertion where lesions are the most frequent [7, 14]. An MRI ACL tear diagnosis remains difficult and subjective with a 20 % false negative depending on the experience of the observer. This is most notable with partial lesions which represent between 10 and 48 % of ACL injuries (Se 40–75 %, Sp 51–89 %) [23, 24].

To improve the exam's sensitivity in doubtful cases, many indirect signs have been described to confirm an ACL rupture. These include a loss of parallelism relative to the Blumensaat's line; presence of bone bruises; a Segond fracture; a tibial plateau anterior subluxation >5 mm between the lateral femoral condyle and lateral tibial plateau; ACL verticality or the distension of the patellar tendon [7], with sensitivity and specificity varying greatly between studies.

Our study, the first to investigate the normal radio-anatomy of the ACL in vivo during dynamic maneuvers, demonstrates the significant ACL lengthening during flexion. The average ACL length measured was  $31.75 \pm 2.5$  mm hyperextended and  $35.6 \pm 1.6$  mm in 90° flexion (Table 1; Fig. 2), i.e. an average elongation of 3.85 mm between extension and a 90° flexion. This is in accord with recent literature which highlights an elongation observed during biomechanical cadaver studies [10, 25], despite limited and imprecise measurement techniques.

Indeed biomechanical measurements based on skin markings have an error risk due to the likelihood of mobilizing these markings. Measures taken on cadavers are error-prone because of manual measures and conservation

conditions of the knee which may modify the physiological tissue elasticity and suppress the muscular strength.

During flexing, the size of the two bundles varies non-uniformly since the AM extends (from 3 to 3.6 mm) while the PL shortens (–1 to –7.1 mm) [9, 21]. The ACL “global” lengthening highlighted during bending is mainly due to the AM lengthening and confirms its principal role in knee stability in this position [1, 8, 9, 21].

Because of tube size technical constraints and movement restrictions with rigid surface antennas, the vast majority of pre-existing ACL MRI studies was carried out on extended knees. A few dynamic studies that was done and showed the value of this technique by demonstrating better ligament visualization and flexion anomalies. This allowed a better distinction between simple deformation, irregularity and actual damage, most notably through an expansion of the space between the intertubercular groove and the tibial spines [18].

Niitsu, Muhle and Pereira all demonstrated better visualization of ACL damage when flexing. They were able to detect significant rupture increases of the ligament, by enhanced visualization of the femoral and tibial ligament insertions [15, 18, 19]. Despite the small number of patients (5), Pereira noted improved detection of ruptures (60 %) with a sensitivity of 96 % on flexion [19]. Comparing the results with arthroscopy, Muhle notes an improved overall sensitivity in detecting ruptures, particularly of partial lesions (50 vs 63 % in extension flexion to 55°) [15]. Since this mainly affects the AM [20], the ligament elongation caused by bending helps unmask those lesions as a result of the bundle's primary role in this position.

Nenezic, when comparing classical and flexion sequences of ACL centered oblique sagittal sections, showed a better visualization of partial ruptures on the flexion sequences relative to extension (78 vs. 48 %) without any significant differences between the flexion and oblique sagittal sequences [16]. However, the absence of an arthroscopic correlation limits his study.

There were no significant differences demonstrated in the meniscus or other associated injuries [15]. Other meniscal ligamentous structures are comparable in extension and flexion, with a sensitivity of 82 % for the lateral meniscus and between 81.5 and 96 % for the medial meniscus [18].

Additionally, we noted a significant increase in the proximal insertion angle with average values of  $133.2^\circ \pm 5.4^\circ$  during hyperextension and  $149.15^\circ \pm 8.6^\circ$  to 90° with flexion (Table 2; Fig. 3). There was also a closed distal angle with mean values of  $2.45^\circ \pm 3.7^\circ$  during hyperextension and  $51.85 \pm 9.3$  at 90° with flexion (Table 3; Fig. 4).

Only one study reviewed ACL angle insertion variations based on the degree of knee flexion. Zaffagnini demonstrated, as did we, a reduction of the angle insertion ( $56.5^\circ \pm 11.8^\circ$  vs  $33.5^\circ \pm 6.8^\circ$ ), and an increase of the proximal angle insertion ( $4.6^\circ \pm 11.4^\circ$  vs  $58.4^\circ \pm 7.3^\circ$ ) during flexion, first at the expense of the PL between  $0^\circ$  and  $80^\circ$  then the AM, confirming the latter's major role in the ligament tension during flexion [25]. Our distal angle measurements vary inversely due to using the tibial plateau anterior edge as our reference, while Zaffagnini used the posterior edge.

A dynamic MRI of a knee flexion could be significant in diagnosing traumatic ACL injuries by enhancing a full or partial ACL rupture, particularly regarding the AM. Furthermore, understanding both normal and pathological anatomy in different positions can provide additional semiotic analysis in any doubtful cases. Understanding ACL's normal lengthening may also be useful during a remote-site postoperative follow-up if there are persistent abnormal symptoms. The dynamic MRI could thus seek and detect defects or excessive elongations which signify kinetic disturbances in the operated knee. Moreover, an "anatomical" or a "non-anatomical" surgical techniques remain controversial, and the comparative study of post-operative ligament elongation versus either of the two techniques could help bring arguments in favor of the one that best restores knee kinetics.

Our study complements existing data by examining the ACL's morphology and biomechanics during full flexion with an open MRI and flexible antenna so as to circumvent the previous studies' technical limitations. Our results are consistent with the recent literature which confirm an ACL extension during flexion and the AM's central role.

## Conclusions

To the best of our knowledge, this study is the first descriptive radio-anatomical study to analyze a normal ACL in vivo in different positions, confirming it is significantly longer when flexed to  $90^\circ$  as a result of the AM's elongation. Understanding both the normal and abnormal ACL length in its different positions could allow us to improve diagnosing partial or complete ACL tears.

A study of traumatic ACL injuries using a dynamic MRI is imminent. Furthermore, the possibility of a dynamic knee joint examination with an open MRI may even extend to studying all articulations.

## Compliance with ethical standards

**Conflict of interest** The authors declare that they have no conflict of interest.

## References

- Amis AA, Dawkins GP (1991) Anterior cruciate ligament: functional anatomy of its bundles actions related to ligaments replacement and injuries. *J Bone Joint Surg Br* 73:260–267
- Arnoldi AP, Weckbach S, Nussbickel C, Horng A, Nöbauer I, Zysk S, Reiser M, Glaser C (2011) MRI based volumetric assessment of knee cartilage after ACL-reconstruction, correlated with qualitative morphologic changes in the joint and with clinical outcome. Is there evidence for early posttraumatic degeneration? *Rofo* 183:1138–1144. doi:10.1055/s-0031-1281685
- Clément B, Drouin G, Shorrock G, Gely P (1989) Statistical analysis of the knee ligaments lengths. *J Biomech* 22:767–774
- Cohen SB, Vanbeek C, Starman JS, Armfield D, Irrgang JJ, Fu FH (2009) MRI measurement of the two bundles of the normal anterior cruciate ligament. *Orthopedics* 32:687. doi:10.3928/01477447-20090728-35
- Cotten A, Delfaut E, Demondlon X, Lapegue F, Boukhelifa M, Boutry N (2000) MR imaging of the knee at 0.2 and 1.5 T: correlation with surgery. *AJR Am J Roentgenol* 174:1093–1097
- Girgis FG, Marshall JL, Al Monajem ARS (1975) The cruciate ligaments of the knee joint. Anatomical, functional and experimental analysis. *Clin Orthop Relat Res* 106:216–231
- Guenoun D, Le Corroller T, Amous Z, Pauly V, Sbihi A, Champsaur P (2012) Apport de l'IRM dans le diagnostic des ruptures traumatiques du ligament croisé antérieur. *Journal de Radiologie Diagnostique et Interventionnel* 93:357–367. doi:10.1016/j.jradio.2011.02.030
- Hirokawa S, Tsuruno R (1997) Hyper-elastic model of anterior cruciate ligament. *Med Eng Phys* (19) 7:637–651
- Hollis JM, Takai S, Adams DJ (1991) The effects of knee motion and external loading on the length of the anterior cruciate ligament (ACL): a kinematic study. *J Biomech Eng* 113(2):208–214
- Hoseini A, Gill TJ, Li G (2009) In vivo anterior cruciate ligament elongation in response to axial tibial loads. *J Orthop Sci* 14(3):298–306. doi:10.1007/s00776-009-1325-z
- Klass D, Toms AP, Greenwood R, Hopgood P (2007) MR imaging of acute anterior cruciate ligament injuries. *Knee* 14:339–347
- Lee JK, Yao L, Phelps CT, Writh CR, Czajka J, Lozman J (1998) Anterior cruciate ligament tears: MR imaging compared with arthroscopy and clinical tests. *Radiology* 166:861–864
- Logan MC, Williams A, Lavelle J, Gedroyc W, Freeman M (2004) Tibiofemoral kinematics following successful anterior cruciate ligament reconstruction using dynamic multiple resonance imaging. *Am J Sports Med* 32:984–992
- Mink JH, Reicher MA, Crues JV III, Deutsh AL (1987) MRI of the knee, 2nd edn. Raven, New York, NY, pp 145–162
- Muhle C, Mo Ahn J, Dieke C (2013) Diagnosis of ACL and meniscal injuries: MR imaging of knee flexion versus extension compared to arthroscopy. *Spring Open J* 2:213. doi:10.1186/2193-1801-2-213
- Nenezic D, Kocijancic I (2013) The value of the sagittal-oblique MRI technique for injuries of the anterior cruciate ligament in the knee. *Radiol Oncol* 47(1):19–25. doi:10.2478/raon-2013-0006
- Niitsu M, Ikeda K, Fukubayashi T, Anno I, Itai Y (1996) Knee extension and flexion: MR delineation of normal and torn anterior cruciate ligaments. *J Comput Assist Tomogr* 20:322
- Niitsu M, Ikeda K, Itai Y (1998) Slightly flexed knee position within a standard knee coil: MR delineation of the anterior cruciate ligament. *Eur Radiol* 8:113–115
- Pereira ER, Ryu KN, Ahn JM, Kayser F, Bielcki D, Resnick D (1998) Evaluation of the Anterior cruciate ligament of the knee: comparison between partial flexion true sagittal and extension



- sagittal oblique positions during MR imaging. *Clin Radiol* 53:574–578
20. Sbihi A, Frank A, Dorfmann H (2006) *Arthroscopie: genou, cheville, hanche, épaule, coude, poignet, extra-articulaire. Anatomie du ligament croisé antérieur et isométrie*, 2nd edn. Elsevier, Paris
  21. Takai S, Woo SL, Livesay GA, Adams DJ, Fu FH (1993) Determination of the in situ loads on the human anterior cruciate ligament. *J Orthop Res* 11:686–695
  22. Tsai KJ, Chiang H, Jiang CC (2004) Magnetic resonance imaging of anterior cruciate ligament rupture. *BMC Musculoskelet Disord* 5:21
  23. Umans H, Wimpfheimer O, Haramati N, Applbaum YH, Adler M, Bosco J (1995) Diagnosis of partial tears of the anterior cruciate ligament of the knee: value of MR imaging. *AJR Am Roentgenol* 165:893–897
  24. Yao L, Gentili A, Petrus L, Lee JK (1995) Partial ACL rupture: an MR diagnosis? *Skeletal Radiol* 24:247–251
  25. Zaffagini S, Martelli S, Acquarolli F (2004) Computer investigation of ACL orientation during passive range of motion. *Comput Biol Med* 34:153–163