



HAL
open science

Duality of Netherton syndrome manifestations and response to ixekizumab

Claire Barbieux, Mathilde Bonnet Des Claustres, Michel de La Brassinne, Guy Bricteux, Martine Bagot, Emmanuelle Bourrat, Alain Hovnanian

► **To cite this version:**

Claire Barbieux, Mathilde Bonnet Des Claustres, Michel de La Brassinne, Guy Bricteux, Martine Bagot, et al.. Duality of Netherton syndrome manifestations and response to ixekizumab. Journal of The American Academy of Dermatology, 2021, 84 (5), pp.1476-1480. 10.1016/j.jaad.2020.07.054 . hal-03543139

HAL Id: hal-03543139

<https://hal.science/hal-03543139>

Submitted on 24 Apr 2023

HAL is a multi-disciplinary open access archive for the deposit and dissemination of scientific research documents, whether they are published or not. The documents may come from teaching and research institutions in France or abroad, or from public or private research centers.

L'archive ouverte pluridisciplinaire **HAL**, est destinée au dépôt et à la diffusion de documents scientifiques de niveau recherche, publiés ou non, émanant des établissements d'enseignement et de recherche français ou étrangers, des laboratoires publics ou privés.



Distributed under a Creative Commons Attribution - NonCommercial 4.0 International License

1 **Article Type:** Research Letter

2

3 **Title:** Duality of Netherton syndrome manifestations and response to ixekizumab

4

5 Barbieux Claire*¹, PhD, Mathilde Bonnet des Claustres*¹, MSc, Michel de la Brassinne², MD,
6 PhD, Guy Bricteux³, MD, Martine Bagot⁴, MD, PhD, Emmanuelle Bourrat⁴, MD, Alain
7 Hovnanian^{1,5,6}, MD, PhD.

8

9 * These authors contributed equally to this work

10

11 ¹ INSERM UMR 1163, Laboratory of Genetic Skin Diseases, Imagine Institute, 75015 Paris,
12 France

13 ² Department of Dermatology, CHU Centre-Ville, University of Liège, 4020 Liège, Belgium

14 ³ Pediatrician, 4020 Liège, Belgium

15 ⁴ Department of Dermatology, Saint-Louis Hospital (AP-HP), 75010 Paris, France

16 ⁵ University of Paris, 75006 Paris, France

17 ⁶ Department of Genetics, Necker Hospital for sick children (AP-HP), 75015 Paris, France

18

19

20 **Corresponding author:**

21

22 Alain Hovnanian, MD, PhD

23 Imagine Institute, INSERM UMR 1163

24 Genetic Skin Diseases: From Disease Mechanisms to Therapies

25 24, boulevard du Montparnasse

26 75015 Paris, France

27 Mail: alain.hovnanian@inserm.fr

28 Tel: +33 1 42 75 42 89

29

30 **Funding sources:** This work was supported by the National Research Agency (ANR-17-CE14-
31 0025-03 Tfh Atopy and ANR-19-CE17-0017-01TARGET-NS) and Imagine Institute (Cross-lab
32 project).

33

34 **Conflicts of interest:** The authors have no conflict of interest to declare

35

36 **IRB approval status:** Reviewed and approved by IRB

37

38 **Manuscript word count:** 499/500

39 **References:** 5/5

40 **Figures:** 2

41 Supplementary figure: 1

42 Supplementary tables: 3

43 Supplemental files available at doi:10.17632/3b25453w6y.1

44 Attachments: Cover letter

45 **Keywords:** Netherton syndrome; IL-17; ixekizumab; ichthyosis linearis circumflexa; scaly
46 erythroderma; precision medicine

47

48 *To the editor:* Netherton Syndrome (NS) is a rare autosomal recessive ichthyosis due to loss-
49 of-function mutations in *SPINK5* encoding LEKTI¹. NS patients typically present with
50 ichthyosis linearis circumflexa (NS-ILC) or scaly erythroderma (NS-SE) associated with
51 trichorrhexis invaginata and severe atopic manifestations with high serum IgE levels².
52 Current NS treatment is only symptomatic. Recent studies revealed that NS patients display
53 a prevailing Th17 immune response^{3,4}, suggesting that blocking the Th17 axis could be a
54 therapeutic strategy. We report compassionate use of ixekizumab, a humanized anti-IL-
55 17A/F antibody in 3 NS patients per the dosing regimen used for plaque psoriasis⁵.
56 Patients 1 and 3 had NS-ILC and patient 2 presented with NS-SE (Table S1, Figure 1), each
57 patient displaying a severe form not responding to symptomatic treatment. All 3 patients
58 showed major psoriasiform epidermal hyperplasia (Figure 2). Immunostaining of lesional
59 skin showed increased neutrophils in the stratum corneum and papillary dermis in patients 1
60 and 3, and mast cell infiltrates in patient 2. Serum cytokine profiling revealed enhanced
61 levels of several inflammation-, allergy- and chemotaxis-related chemokines, in particular
62 CCL20/MIP-3 α and CXCL13/BCA-1, which are IL-17-induced chemokines (Table S2).
63 During the induction phase, cutaneous improvement was observed, especially in NS-ILC
64 patients. Flares and oozing disappeared, pruritus and scaling decreased and patients
65 reduced their use of topical corticosteroids. After 3 months of therapy, all clinical scores
66 except for IASI-E, showed a statistically significant reduction (Figure 1). During the
67 maintenance phase, clinical benefits were largely maintained in NS-ILC patients in contrast
68 to NS-SE patient. At 6 months of treatment, DLQI and pruritus scores remained decreased in
69 NS-ILC patients, while scores almost returned to baseline values in patient 2. IASI-E scores
70 remained unchanged in the 3 patients during this period. For these reasons, treatment was

71 stopped in patient 2, temporarily discontinued in patient 1 while patient 3 continued
72 monthly injections.

73 After 6 months of ixekizumab, neutrophil infiltrates were replaced by mast cells in patients 1
74 and 3. Mast cell infiltrates were unchanged in patient 2 (Figure 2). Of the 8 cytokines with
75 increased serum levels above 2 fold at baseline, only one (CXCL13/BCA-1) returned to
76 subnormal values, 6 cytokines remained unchanged (CCL26/Eotaxin-3, CXCL11/I-TAC,
77 CCL17/TARC, CCL22/MDC, CCL21/6Ckine and CCL19/MIP-3 β), and 1 cytokine increased
78 (CCL20/MIP-3 α) upon ixekizumab (Table S3). Persistence of elevated Th2-associated
79 CCL22/MDC, CCL17/TARC, CCL26/Eotaxin-3 and CCL13/MCP-4 chemokines could play a part
80 in mast cell infiltration in NS patients' skin after treatment. The decrease of serum levels of
81 CCL3/MIP-1 α and IL-8/CXCL8, which are neutrophil chemoattractants could contribute to
82 marked reduction of neutrophil infiltrates in NS-ILC patients. Importantly, discrepancy in the
83 course of CXCL13/BCA-1, IL-8/CXCL8 and CCL20/MIP-3 α , together with increased
84 inflammation markers including TNF- α and IFN- γ , suggest that other pathways overlapping
85 with IL-17A contribute to NS inflammation.

86 In conclusion, anti-IL-17A/F therapy was well tolerated and brought substantial cutaneous
87 improvement, especially during the induction phase in the 2 patients with NS-ILC. Clinical
88 benefit was partially sustained during the maintenance phase, suggesting that a longer
89 induction regimen could improve efficacy and that additional inflammatory and/or allergic
90 biological cascades should be targeted.

91 **Abbreviations**

- 92 CCL CC Chemokine Ligand
- 93 CXCL CXC Chemokine Ligand
- 94 DLQI Dermatology Life Quality Index
- 95 HC Healthy control
- 96 IASI-E Ichthyosis Area Skin Index-Erythema
- 97 IASI-S Ichthyosis Area Skin Index- Scales
- 98 IgE Immunoglobulin E
- 99 IL Interleukin
- 100 ILC ichthyosis linearis circumflexa
- 101 LEKTI Lympho-epithelial Kazal-type related inhibitor
- 102 MDC Macrophage-Derived Chemokine
- 103 NS Netherton Syndrome
- 104 SE Scaly Erythroderma
- 105 *SPINK5* Serine Protease Inhibitor Kazal-type 5
- 106 TARC Thymus and Activation Regulated Chemokine
- 107 Th Helper T cells
- 108

109 **References**

- 110 1. Chavanas S, Bodemer C, Rochat A, et al. Mutations in SPINK5, encoding a serine
111 protease inhibitor, cause Netherton syndrome. *Nat Genet.* 2000;25(2):141-142.
112 doi:10.1038/75977
- 113 2. Hovnanian A. Netherton syndrome: skin inflammation and allergy by loss of protease
114 inhibition. *Cell Tissue Res.* 2013;351(2):289-300. doi:10.1007/s00441-013-1558-1
- 115 3. Paller AS, Renert-Yuval Y, Suprun M, et al. An IL-17-dominant immune profile is
116 shared across the major orphan forms of ichthyosis. *J Allergy Clin Immunol.* 2017;139(1):152-
117 165. doi:10.1016/j.jaci.2016.07.019
- 118 4. Czarnowicki T, He H, Leonard A, et al. The Major Orphan Forms of Ichthyosis Are
119 Characterized by Systemic T-Cell Activation and Th-17/Tc-17/Th-22/Tc-22 Polarization in
120 Blood. *J Invest Dermatol.* 2018;138(10):2157-2167. doi:10.1016/j.jid.2018.03.1523
- 121 5. Langley RG, Kimball AB, Nak H, et al. Long-term safety profile of ixekizumab in
122 patients with moderate-to-severe plaque psoriasis: an integrated analysis from 11 clinical
123 trials. *J Eur Acad Dermatol Venereol.* 2019;33(2):333-339. doi:10.1111/jdv.15242

124

125

126 **Acknowledgements**

127 We would like to acknowledge Professor Hervé Bachelez for helpful discussions and valuable
128 advices. We are thankful to the French National Research Agency (ANR-17-CE14-0025-03 Tfh
129 Atopy and ANR-19-CE17-0017-01TARGET-NS) and Imagine Institute (Imagine cross-
130 laboratory project) for their support.

131 **Figure 1:** Clinical description of the 3 NS patients treated with ixekizumab and evolution of
132 clinical scores during treatment. Pictures of the 3 NS patients before and after 24 weeks of
133 ixekizumab. *Pictures of patient 3 result from a combination of 2 photographs. DLQI,
134 pruritus, IASI-E and IASI-S scores were collected during treatment. Data are represented as
135 the percentage of the scores at ixekizumab introduction. Each patient is represented by a
136 color coded line. Statistical analyses were performed with Kruskal-Wallis' test and
137 differences are statistically significant for $p < 0.05$. The black vertical arrow points to a score
138 reduction of statistical significance. *, $p < 0.05$

139 **Figure 2:** Lesional skin histopathological features showing mast cell and/or neutrophil
140 infiltrates in NS patients before and after ixekizumab. **Ixekizumab initiation.** Hematoxylin-
141 Eosin-Safranin (HES) coloration (upper panel) showing epidermal psoriasiform hyperplasia,
142 reduced or absent granular layer and stratum corneum detachment. The enlargement shows
143 a neutrophil subcorneal collection in patient 1. Immunostaining with tryptase antibody
144 (green) identified mast cell infiltrates predominant in patient 2 (middle panel).
145 Immunostaining with MPO antibody (red) revealed epidermal and dermal neutrophil
146 infiltrates in patients 1 and 3 (lower panel) at the initiation of ixekizumab treatment. **Week**
147 **24 of ixekizumab.** HES coloration (upper panel) showing slight reduction of epidermal
148 hyperplasia and stratum corneum detachment in patients 1 and 2. Mast cell infiltrates
149 stained with tryptase antibody now predominate in patient 1 and 2 (middle panel) and a
150 significant reduction of neutrophil infiltrates stained with MPO antibody is seen in patients 1
151 and 3 (lower panel) after 24 weeks of ixekizumab. Enlargements of HES pictures show
152 parakeratosis, absent, reduced or apparent granular layer or neutrophil subcorneal
153 collection. Original magnification: x40

154

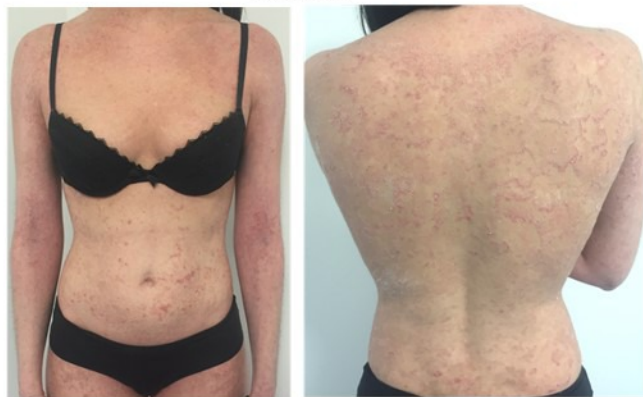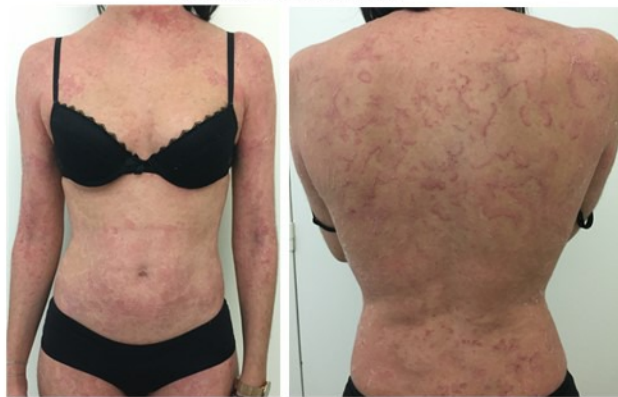155

156

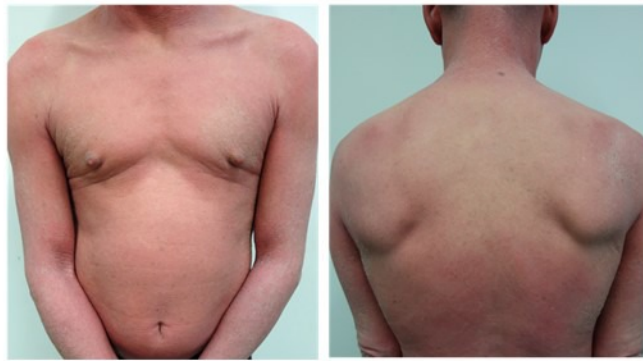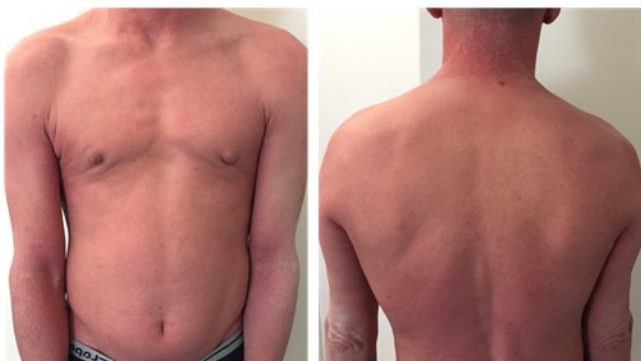Ixekizumab initiation

Week 24

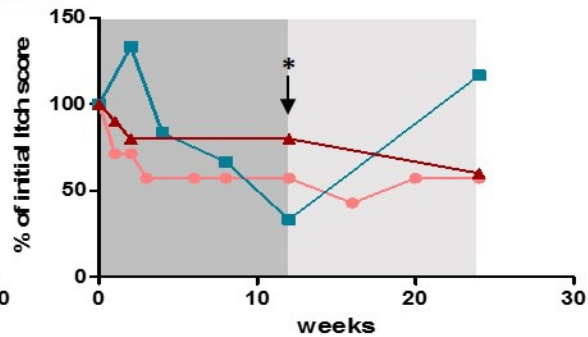
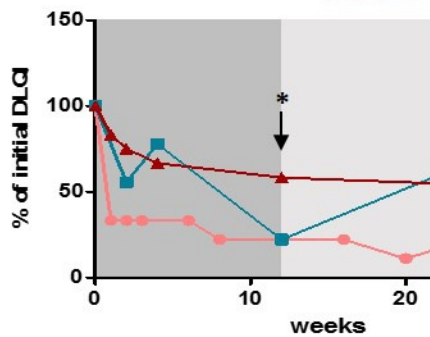
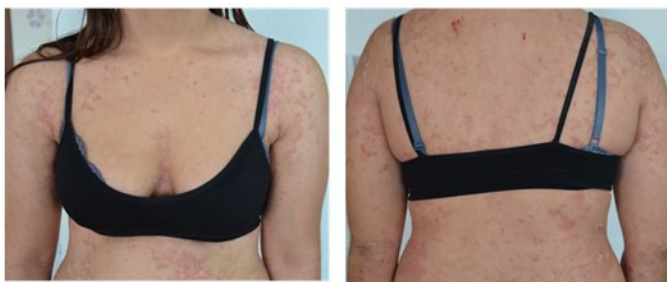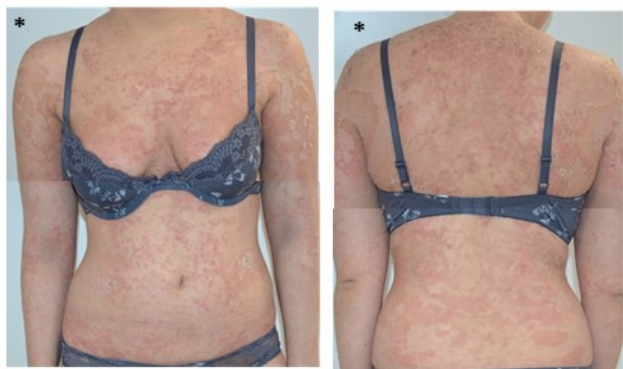Patient 1



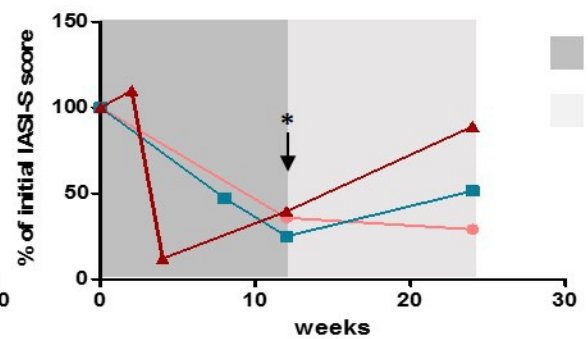
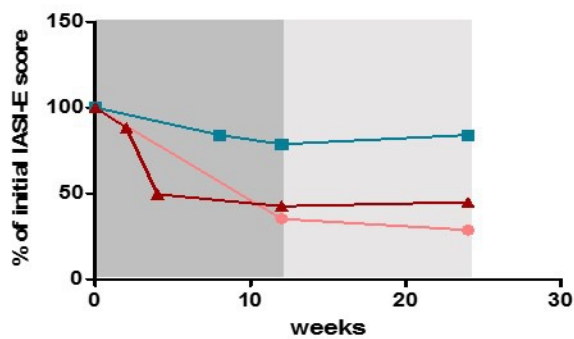
Patient 2



Patient 3



● Patient 1
 ■ Patient 2
 ▲ Patient 3

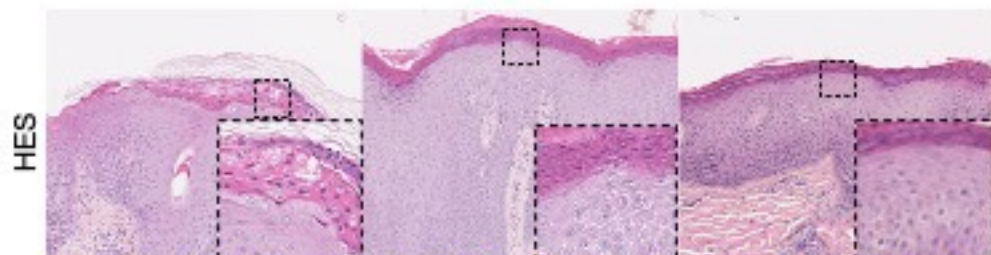


■ Induction phase
 □ Maintenance phase

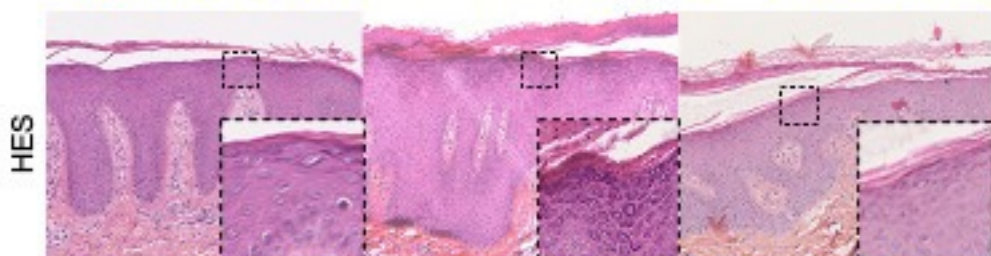
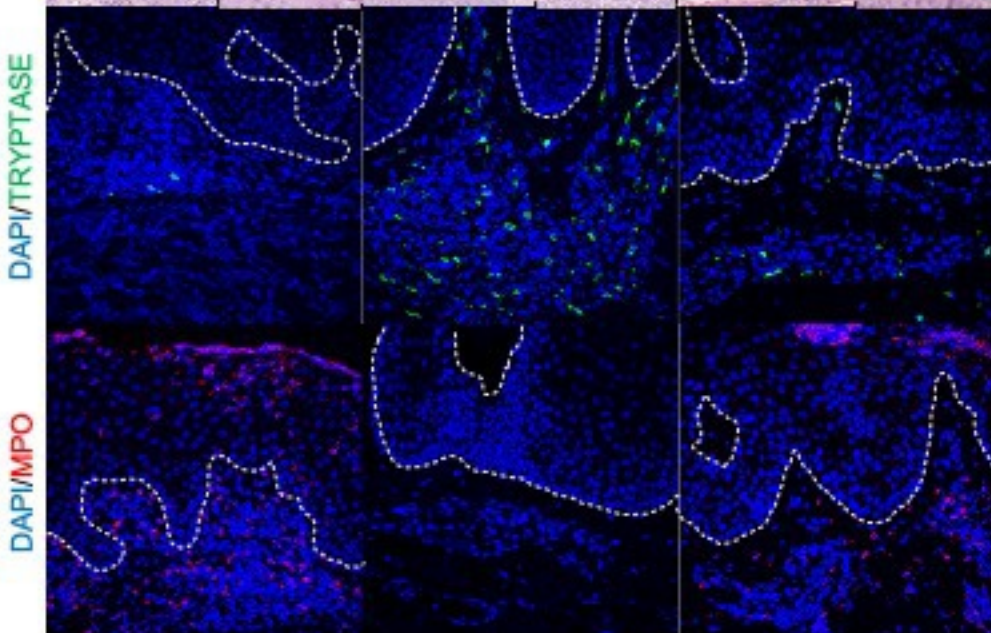
Patient 1

Patient 2

Patient 3

Ixekizumab
Initiation

DAPI/TRYPYPTASE



Week 24 of Ixekizumab

DAPI/TRYPYPTASE

