

Preclinical study of chronic radiation cystitis and cell therapy treatment

Brossard Clément (PhD student)

Supervisor: Chapel Alain
Team head: Milliat Fabien

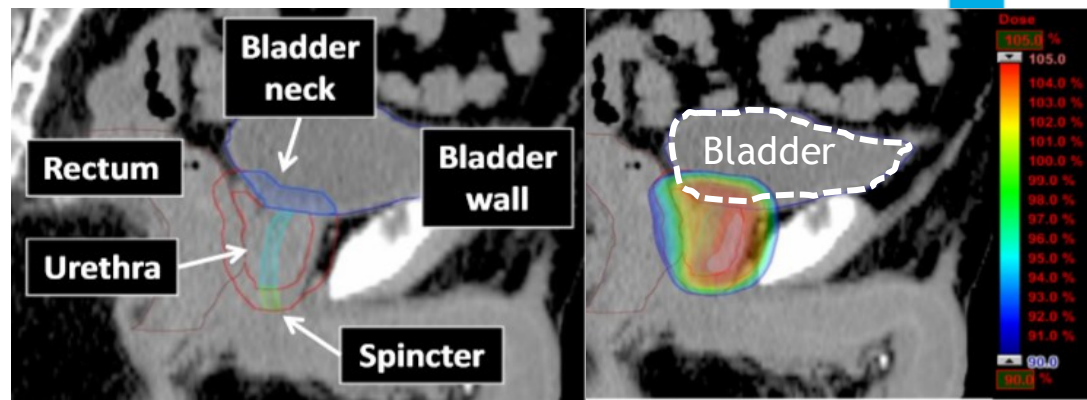
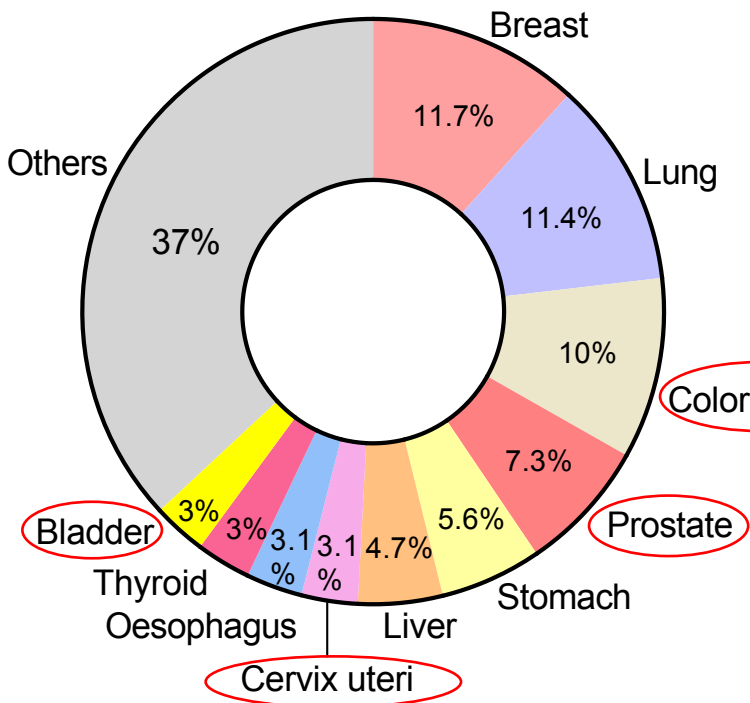
Mail contact: clement.brossard@irsn.fr

Clément Brossard^{* 1,2}, Anne-Charlotte Lefranc^{1,2}, Morgane Dos Santos^{1,3}, Mohamedamine Benadjaoud¹, Christelle Demarquay^{1,2}, Valérie Buard^{1,2}, Georges Tarlet^{1,2}, Claire Squiban^{1,2}, Christine Linard^{1,2}, Noëlle Mathieu^{1,2}, Romain Granger⁴, Amandine Sache⁴, Delphine Denais Lalieve⁴, Jean-Marc Simon⁵, Marc Benderitter¹, Fabien Milliat^{1,2}, Alain Chapel^{1,2}

¹Service de recherche en radiobiologie et en médecine régénérative (SERAMED), ²Laboratoire de Radiobiologie des expositions médicales (LRMED), ³Laboratoire de radiobiologie des expositions accidentelles (LRAcc), ⁴Service de recherche sur les effets biologiques et sanitaires des rayonnements ionisants (SESANE), Groupe de support à la recherche et à l'éthique animale (GSEA), Institut de Radioprotection et de Sûreté Nucléaire, Fontenay-aux-roses, ⁵Département de radio-oncologie, Hôpital universitaire de la Pitié-Salpêtrière, Paris, France



Cancers and radiotherapy



Inokuchiet al.; 2017

60% treated by RT



Radiotherapy :

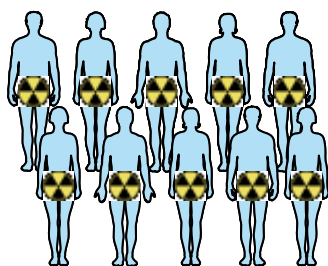
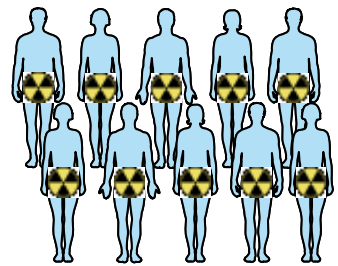
- Anal canal
- Cervix
- Endometrium
- Vulva
- Prostate

Organ at risk :
Bladder

Total : 19 millions of people
WHO Global Cancer Observatory

Acute and chronic radiation cystitis

Population concerned



Pelvic Radiotherapy

Days- months

6 months - 20 years

Acute complications
40% of patients

Chronic complications
5 - 10 % of patients

Acute radiation cystitis¹

Chronic radiation cystitis (CRC)^{1,2}

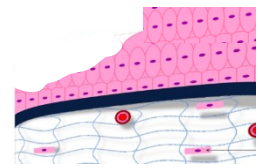
1 Rigaud et al., 2004
2 Martin et al., 2019

Clinical symptoms and major mechanisms


Majors mechanisms



Vascular lesion



Urothelium dysfunction



Clinical symptoms



Incontinence



Pain



Hematuria

Decrease bladder functionality

Decrease the quality of life

What is the problem today?



- Few studies on chronic radiation cystitis.
- Molecular mechanisms partially unknown.
- No curative treatment



Preclinical research to develop innovative treatments

How to choose a new treatment?

Clinical symptoms and majors biologicals mechanisms of Chronic radiation cystitis

Similar to

Interstitial cystitis⁴⁻⁶

Vascular lesion

Hemorrhagic cystitis^{3,4}

Inflammation

Urothelium dysfunction

Fibrosis

4 Chung et al., 2019
5 Song et al., 2015
6 Furuta et al., 2018

7 Ringdén et al., 2007
8 Yang et al., 2021

Ad-Mesenchymal Stem Cells (MSCs)



Tissue regeneration



Inflammation



Fibrosis

Hypothesis: MSCs reduced inflammation, fibrosis and increase tissue regeneration in CRC?



age: 12 weeks
proctoehtics committee: P19-09

Local bladder irradiation in rats with SARRP*

40 Gy

3 Injections of 5 million MSCs intravenously



Euthanasia of rats and analysis of the effects of MSCs on CRC (vascular damage, urothelium dysfunction, chronic inflammation, fibrosis)

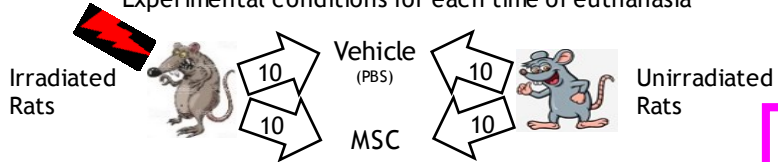
Urothelium regeneration
Urothelium thickness
Vascular damages

Tissue

Physiological:
Hematuria

Experimental conditions: 10 rats for each condition and for each euthanasia time.

Experimental conditions for each time of euthanasia

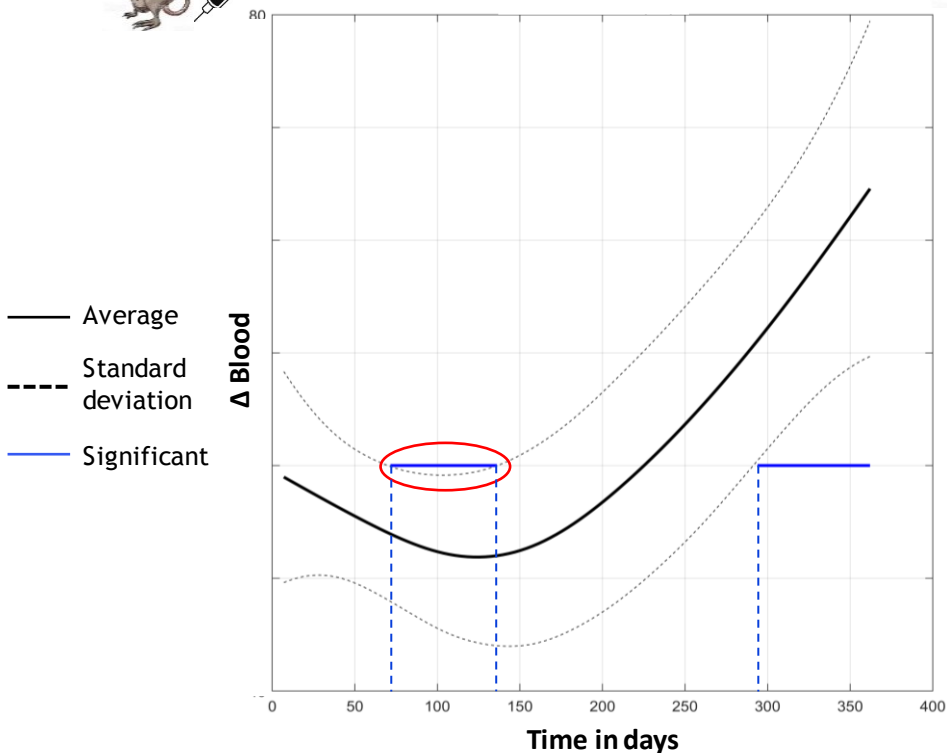


* Small Animal Radiation Research Platform

Hematuria in function of time after irradiation (40 Gy)



Irradiated treated Vs Irradiated untreated

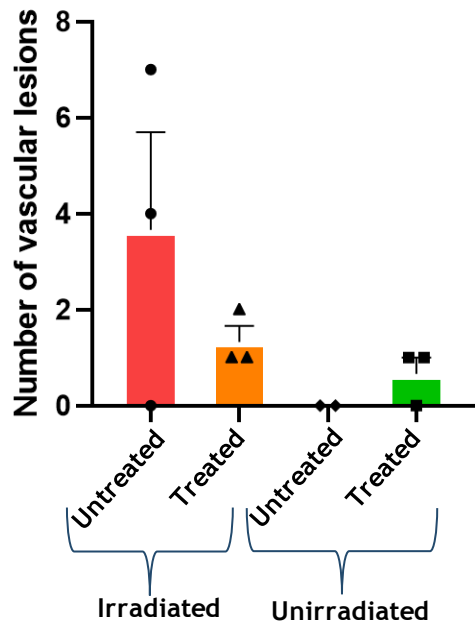


- Irradiated untreated = Early hematuria (75-130 days post irradiation)
- Irradiated treated = Late hematuria (>290 days post irradiation)

Hypothesis: MSCs treatment delays hematuria

Visualization of the bladder wall by cystoscopy

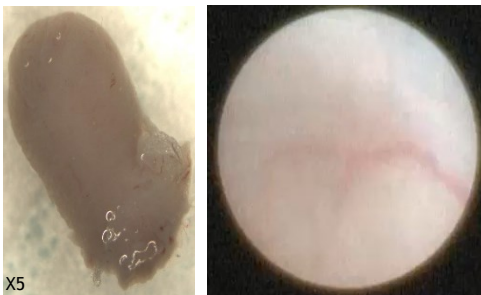
Number of vascular lesions in cystoscopy (12 months)



Cystoscopy at 12 months post-irradiation



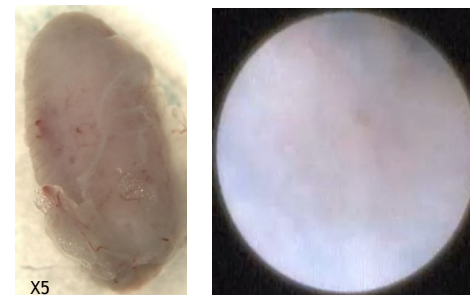
Unirradiated, untreated



3 rats tested by cystoscopy on 10 rats for this condition



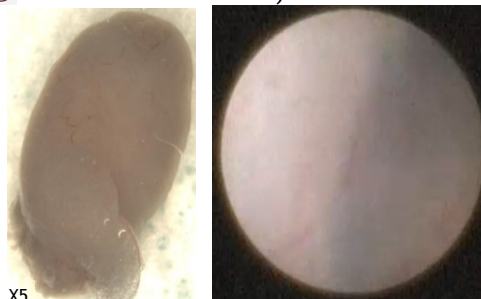
Irradiated, untreated



3 rats tested by cystoscopy on 10 rats for this condition



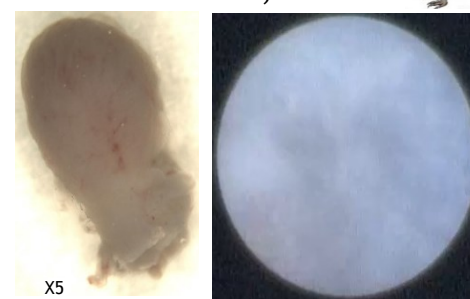
Unirradiated, treated



3 rats tested by cystoscopy on 10 rats for this condition



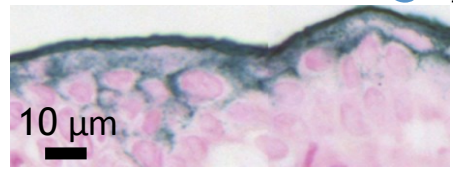
Irradiated, treated



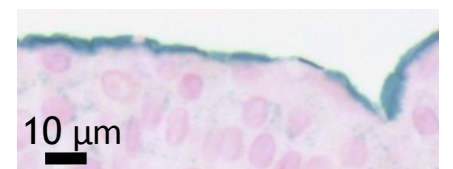
3 rats tested by cystoscopy on 10 rats for this condition

- Decrease Vascular lesions after MSC treatment

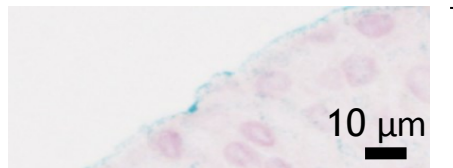
Urothelium integrity alteration: uroplakine 3



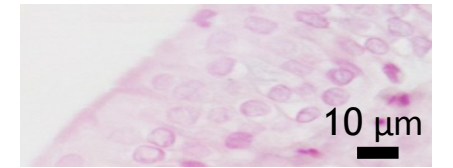
Grade 0: High expression of uroplakine 3



Grade 1: Basic expression of uroplakine 3



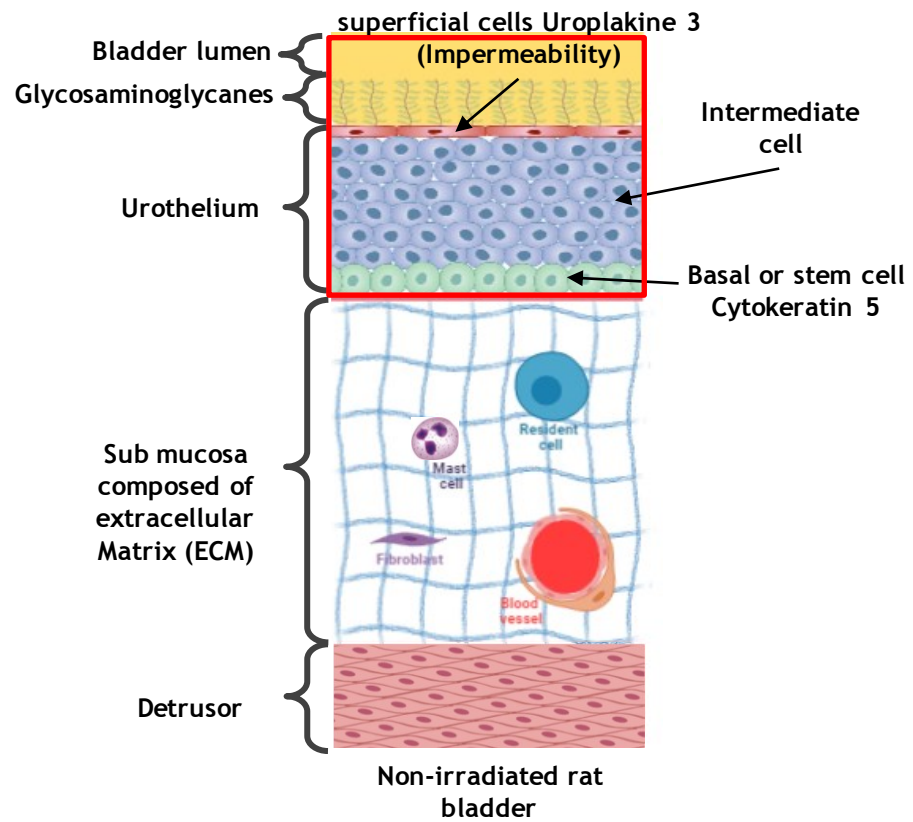
Grade 2: Low expression of uroplakine 3



Grade 3: Absence of uroplakine 3 expression

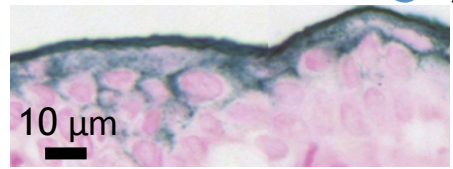
Normal expression of uroplakine 3

Abnormal expression of uroplakine 3

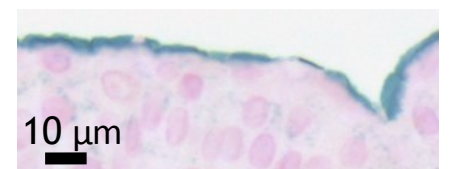


Non-irradiated rat bladder

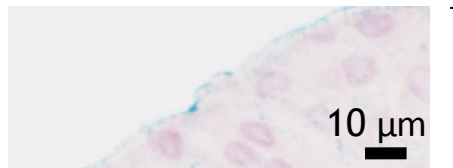
Urothelium integrity alteration: uroplakine 3



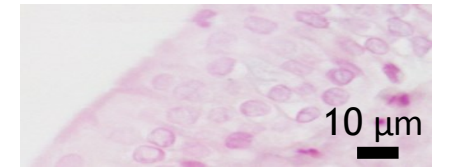
Grade 0: High expression of uroplakine 3



Grade 1: Basic expression of uroplakine 3



Grade 2: Low expression of uroplakine 3




Grade 3: Absence of uroplakine 3 expression

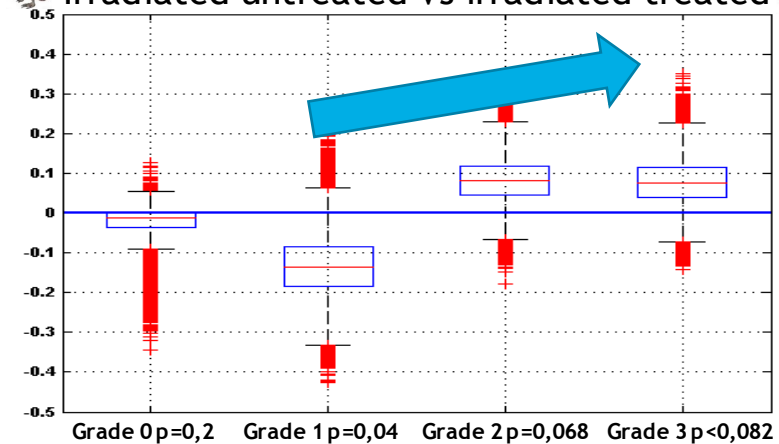
Normal expression of uroplakine 3

Abnormal expression of uroplakine 3

Grading of the whole urothelium for each animal

Δ expressions of uroplakine 3, 12 months

Irradiated untreated Vs irradiated treated  

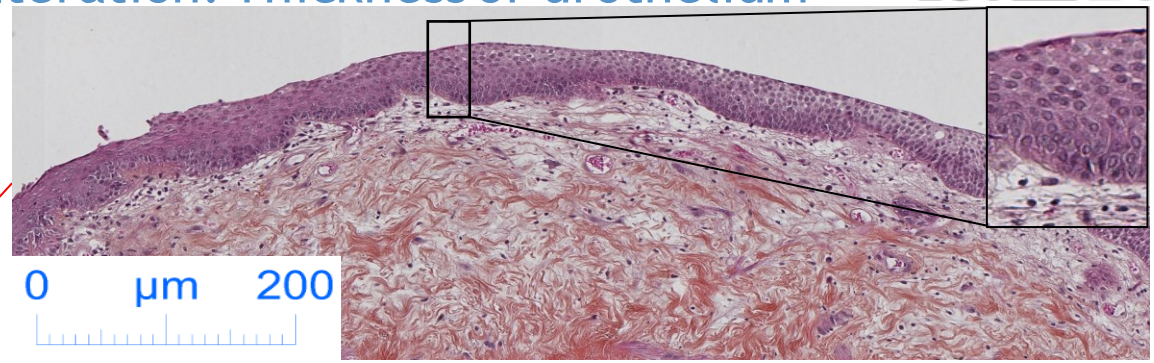
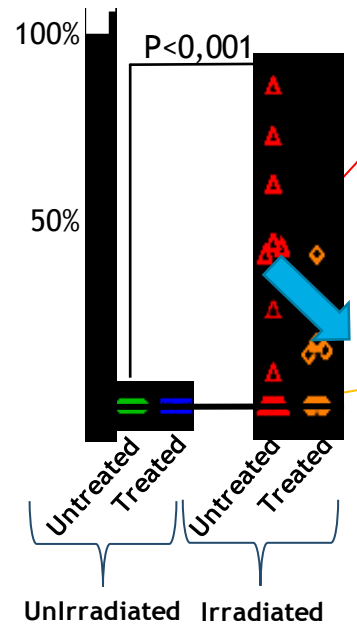


- MSC treatment has a protective effect by decreasing the percentage of grade 2 and 3 urothelium.

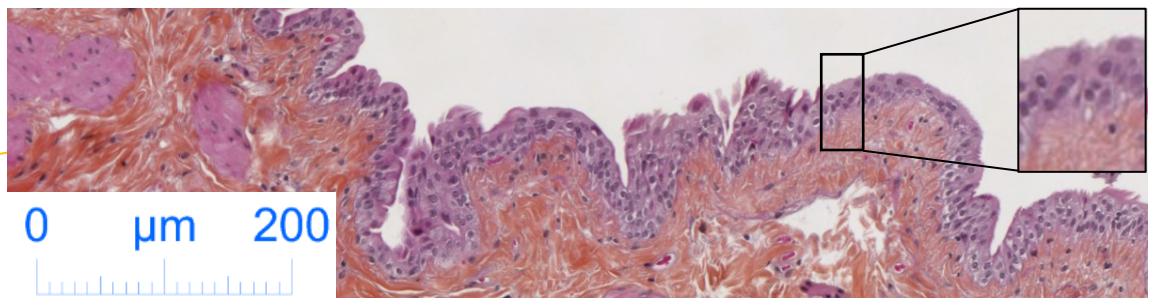


Urothelium integrity alteration: Thickness of urothelium

% of the urothelium concerned by an abnormal increase of thickness, 12 months




12 months irradiated, Untreated



12 months irradiated, treated

- **Decrease of urothelium thickness after MSC treatment**

Conclusion

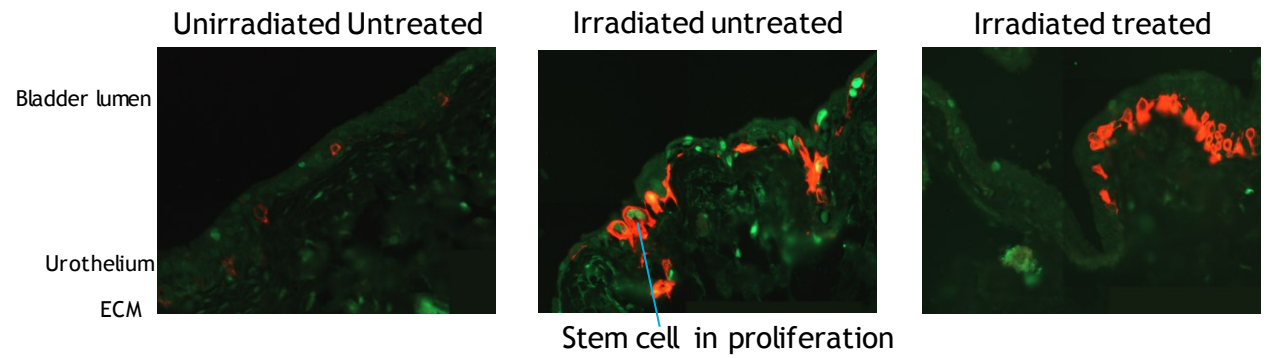
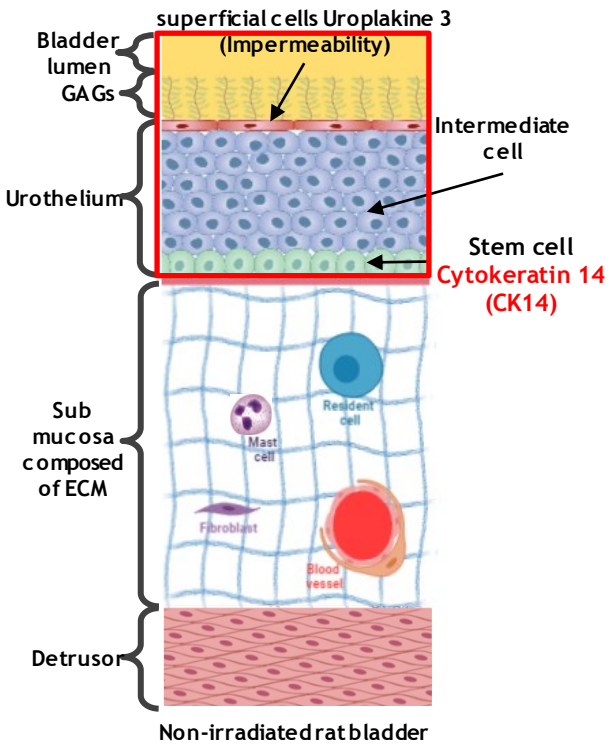


	Unirradiated untreated	Unirradiated treated	Irradiated untreated	Irradiated treated
Hematuria				
Vascular lesion in cytoscopy				
Lack of urothelium integrity (uroplakine 3)				
Thickness of urothelium				

Reduction of lesions after MSC treatment

Perspectives: Urothelium regeneration

Proliferation marker **PCNA**
Stem cell marker **CK14**



- **MSC treatment affect the basal stem cell compartment?**
 - Investigation at 6 and 8 months in progress

Thank you for your attention

GSEA member: Animal monitoring and assistance in animal experimentation

9 researchers
1 post-doctoral
4 technical
6 PhD students

C. Demarquay
MSC culture

C. Linard
Immunolabelling and inflammation

F. Milliat
Head laboratory

N. Mathieu
Cystoscopy

V. Buard
Microscopie and immunolabelling

Tarlet
PCR

Brossard

A. Benadjaoud :
Biostatistique

M. Dos Santos : rats
irradiation (SARRP)

Brossard clément: Preclinical study of chronic radiation cystitis and cell therapy treatment ESTRO: 27-31 August 2021 -Madrid, Spain
clement.brossard@irsn.fr

ESTRO 2021



Alain Chapel
Director thesis



Anne-charlotte Lefranc:
Master 2 in CRC project