



HAL
open science

A +3 variant at a donor splice site leads to a skipping of the MYH11 exon 32, a recurrent RNA defect causing Heritable Thoracic Aortic Aneurysm and Dissection and/or Patent Ductus Arteriosus

Bertrand Chesneau, Aurélie Plancke, Guillaume Rolland, Bertrand Marcheix, Yves Dulac, Thomas Edouard, Julie Plaisancié, Marion Aubert-mucca, Sophie Julia, Maud Langeois, et al.

► To cite this version:

Bertrand Chesneau, Aurélie Plancke, Guillaume Rolland, Bertrand Marcheix, Yves Dulac, et al.. A +3 variant at a donor splice site leads to a skipping of the MYH11 exon 32, a recurrent RNA defect causing Heritable Thoracic Aortic Aneurysm and Dissection and/or Patent Ductus Arteriosus. *Molecular Genetics & Genomic Medicine*, 2021, 9 (11), pp.e1814. 10.1002/mgg3.1814 . hal-03528915

HAL Id: hal-03528915

<https://hal.science/hal-03528915>

Submitted on 17 Jan 2022

HAL is a multi-disciplinary open access archive for the deposit and dissemination of scientific research documents, whether they are published or not. The documents may come from teaching and research institutions in France or abroad, or from public or private research centers.



L'archive ouverte pluridisciplinaire **HAL**, est destinée au dépôt et à la diffusion de documents scientifiques de niveau recherche, publiés ou non, émanant des établissements d'enseignement et de recherche français ou étrangers, des laboratoires publics ou privés.



Distributed under a Creative Commons Attribution - NonCommercial - NoDerivatives 4.0 International License

CLINICAL REPORT

A +3 variant at a donor splice site leads to a skipping of the *MYH11* exon 32, a recurrent RNA defect causing Heritable Thoracic Aortic Aneurysm and Dissection and/or Patent Ductus Arteriosus

Bertrand Chesneau^{1,2}  | Aurélie Plancke¹ | Guillaume Rolland¹ |
Bertrand Marcheix³ | Yves Dulac² | Thomas Edouard² | Julie Plaisancié⁴ |
Marion Aubert-Mucca^{2,4} | Sophie Julia⁴ | Maud Langeois^{2,4} |
Thierry Lavabre-Bertrand^{1,5,6} | Philippe Khau Van Kien^{1,5,6} 

¹UF de Génétique Médicale et Cytogénétique, Centre Hospitalier Régional Universitaire de Nîmes, Nîmes, France

²Centre de Référence du syndrome de Marfan et des syndromes apparentés, Hôpital des Enfants, CHU de Toulouse, Toulouse, France

³Département de Chirurgie Cardiaque, Hôpital Universitaire de Rangueil, Toulouse, France

⁴Service de Génétique Médicale, Hôpital Universitaire de Purpan, Toulouse, France

⁵Institut des Biomolécules Max Mousseron (IBMM), CNRS UMR5247, Université de Montpellier, Montpellier, France

⁶Faculté de Médecine Montpellier-Nîmes, Laboratoire d'Histologie-Embryologie-Cytogénétique, Institut des Biomolécules Max Mousseron (IBMM), CNRS UMR5247, Nîmes, France

Correspondence

Philippe Khau Van Kien, Unité de Génétique Médicale et Cytogénétique, Pôle Biologie, CHU de Nîmes - Hôpital Carémeau, Place du Pr. Robert Debré, 30029 NÎMES CEDEX 9, France.
Email: philippe.khauvankien@chu-nimes.fr

Funding information

No funds, grants, or other support was received.

Abstract

Background: Pathogenic variants in *MYH11* are associated with either heritable thoracic aortic aneurysm and dissection (HTAAD), patent ductus arteriosus (PDA) syndrome, or megacystis-microcolon-intestinal hypoperistalsis syndrome (MMIHS).

Methods and Results: We report a family referred for molecular diagnosis with HTAAD/PDA phenotype in which we found a variant at a non-conserved position of the 5' donor splice site of intron 32 of *MYH11* potentially altering splicing (NM_002474.3:c.4578+3A>C). Although its cosegregation with disease was observed, it remained of unknown significance. Later, aortic surgery in the proband gave us the opportunity to perform a transcript analysis. This showed a skipping of the exon 32, an RNA defect previously reported to be translated to an in-frame loss of 71 amino acids and a dominant-negative effect in the smooth muscle myosin rod. This RNA defect is also reported in 3 other HTAAD/PDA pedigrees.

Conclusion: This report confirms that among rare variants in *MYH11*, skipping of exon 32 is recurrent. This finding is of particular interest to establish complex genotype-phenotype correlations where some alleles are associated with

This is an open access article under the terms of the Creative Commons Attribution-NonCommercial-NoDerivs License, which permits use and distribution in any medium, provided the original work is properly cited, the use is non-commercial and no modifications or adaptations are made.

© 2021 The Authors. *Molecular Genetics & Genomic Medicine* published by Wiley Periodicals LLC

autosomal dominant HTAAD/PDA, while others result in recessive or dominant visceral myopathies.

KEYWORDS

genotype–phenotype correlation, heritable aortic aneurysm syndrome, *MYH11*, patent ductus arteriosus, splicing

1 | INTRODUCTION

Thoracic aortic aneurysms are mostly asymptomatic and tend to expand over time, which increases the risk for an acute ascending aortic dissection with a poor prognosis (Milewicz et al., 2017). One-quarter to one-third of patients with a personal and a familial history of non-syndromic thoracic aortic disease has a pathogenic or likely pathogenic variant in a gene of heritable thoracic aortic aneurysm and dissection (HTAAD) (Arnaud et al., 2019; Mariscalco et al., 2018). In the absence of a familial history, the detection rate decreases to around 10% (Li et al., 2021). Identification of a variant in one of these genes is, therefore, important both to detect affected family members, but also to adapt patient surveillance and care. Rare variants affecting the coiled-coil domain of the smooth muscle cell-specific isoforms of the myosin heavy chain (encoded by *MYH11*) lead to HTAAD, mostly

associated with patent ductus arteriosus (PDA) (Zhu et al., 2006; Milewicz et al., 2017, MIM#132900).

2 | PATIENTS AND METHODS

2.1 | Ethical compliance

Informed consent was obtained from all individual included in this study and the ethics committee of the Nîmes University Hospital approved the study (IRB-21.03.04).

2.2 | Clinical Report

We report a family referred for molecular diagnosis at our laboratory in 2016 with two siblings who presented type A aortic dissections (Figure 1, supplemental data).

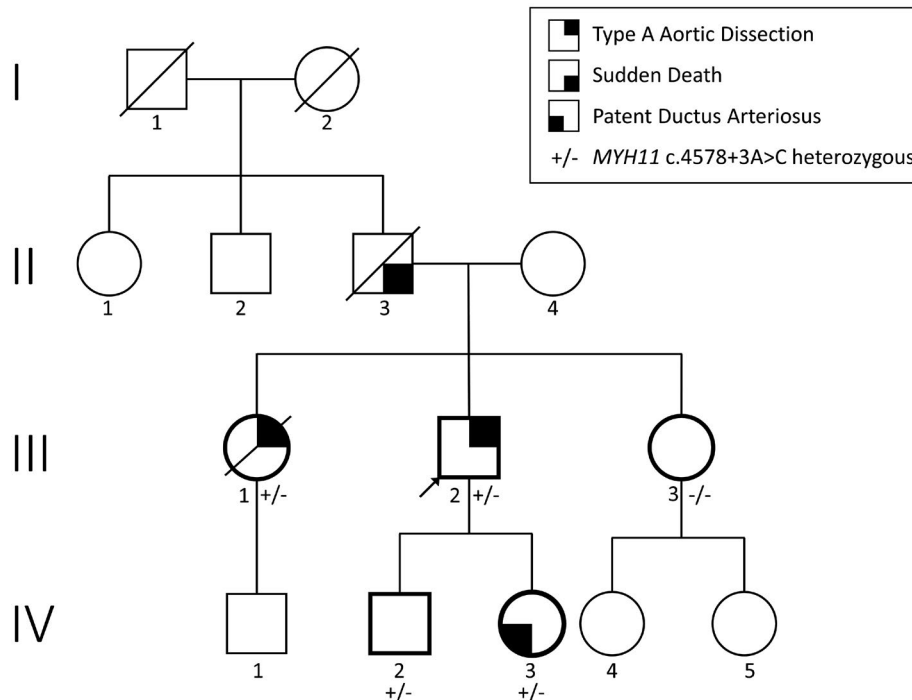


FIGURE 1 Pedigree of the family showing the segregation of the *MYH11* c.4578+3A>C variant with the cardiovascular phenotype. Tested individuals are figured by a thick line

At 22 years old, the proband (III.2) had a type A aortic dissection extended to the femoral arteries and was treated by valve-sparing root replacement (tricuspid valve). The chronic dissection monitored annually by CT scan was stable until the age of 46 years, when the patient suddenly presented with chest pain. The CT scan performed in emergency showed a progression with a dissecting aneurysm at the level of the descending aorta measured at more than 50 mm and a multitude of re-entries between the true and false channel all along the aorta, in favor of an acute type B dissection. In addition, echocardiography revealed an aortic valve regurgitation. Therefore, he benefited from the frozen elephant trunk technique and Bentall procedure to treat both conditions (Bentall & de Bono, 1968; Borst et al., 1983).

His oldest sister (III.1) had a type A aortic dissection at 45 years old. Her medical history revealed high blood pressure, narrow lumbar canal, recurrent spontaneous right pneumothorax (first at 37 years old), and tobacco smoking. Immediately afterward a valve-sparing aortic root replacement surgery in emergency (tricuspid valve), she developed a left middle cerebral artery stroke secondary to the occlusion of the M1 segment and an internal carotid dissection. This second dissection event was independent of the aortic dissection on imagery (supplementary material). A pathologic study report of the aorta noted “medial mucoid changes with foci of cystic medial degeneration, without atheromatous deposits or foci of parietal inflammation.” She kept important sequels with a grabby state, hemiplegia, aphasia, and loss of autonomy and died one year later in a palliative care unit. Previously, her father (II.3) had died suddenly at 28 years old without any known medical history and had no postmortem examination. The proband's daughter (IV.3) was diagnosed with a PDA in infancy and considered spontaneously closed at 3 years old. A recent transthoracic echocardiography and Doppler revealed normal aortic root diameters but an intermittent PDA. His son (IV.2) was asymptomatic at last follow-up with normal diameters of the aortic root (Valsalva 30 mm, +0.7SD) and absence of PDA (19 years old). Family history did not reveal other members potentially affected by aortic disease.

2.3 | Genetic Analyses

A targeted next-generation sequencing (NGS) panel of 15 HTAAD genes (detailed methods and gene list in supplementary data) performed on patient III.2 DNA revealed the heterozygous c.4578+3A>C variant in *MYH11* (NM_002474.3, *SM1A* transcript variant) or NC_000016.10:g.15721419T>G. This novel variant (submitted for public access through LOVD under accession

ID: #0000736497, MYH11.lovd.nl) was absent from GnomAD, our own database (>1000 patients), and the literature. Multiple splicing prediction software predicted an alteration of a wild type 5'splice site (ss). These predictions were, however, lower than those for previously reported pathogenic variant at the same ss (Supplemental material). The variant segregated with the cardiovascular phenotype in the family, as it was found in all three affected members. One asymptomatic member (IV.2) was also heterozygous for the variant. This position is not conserved and a variant at the same position c.4578+3A>G is reported mostly as likely benign in the ClinVar database (rs143288748), with a frequency of around 0.14% in the general population (GnomAD) and splicing prediction software did not predict an alteration of the 5'ss (Supplemental material). No other variant of interest was identified in NGS data, and oligonucleotide microarray analysis did not reveal any unbalanced chromosomal anomaly in the DNA of patient III.2.

Aortic surgery of patient III.2 four years later gave us the opportunity to conduct the transcript analysis. We, therefore, performed total RNA extraction using RNeasy Mini Kit (Qiagen, Hilden, Germany) on uncultured aortic biopsy taken during surgery according to the manufacturer's instructions. RNA was also extracted using the same kit from cultured skin fibroblasts of a control patient. We then conducted a one-step reverse transcription-polymerase chain reaction (RT-PCR) targeted to exons 31–33, and exon 32 to the 33–34 exon junction of *MYH11*. We used the *GUS* gene as a control (primers in supplementary data). Electrophoresis of the PCR product was performed with 4200 TapeStation System (Agilent Technologies, Santa Clara, California, USA) with D1000 DNA ScreenTape Analysis according to manufacturer protocol. Electrophoresis of the PCR product of exons 31 to 33 revealed one amplicon of the expected size (507 bp) and another about 200bp shorter (Figure 2a). For the PCR product of exons 32 to 33/34, electrophoresis displayed only one product of the expected size for (315bp). These data provide evidence for exon skipping of the 213 bp exon 32 of *MYH11*, which was confirmed by direct sequencing on an ABI 3500XL (ThermoFisher Scientific)(Figure 2b). This variant results in a 213bp in-frame deletion of exon 32 of the mature RNA (r.4366_4578del).

3 | DISCUSSION

We report a pedigree affected by HTAAD/PDA caused by a splice defect at a variable position +3 of a 5'ss of *MYH11* intron 32. Although recent progress has been made, interpretation of variants that could affect the splicing outside the canonical or cryptic dinucleotide GT/AG splice sites

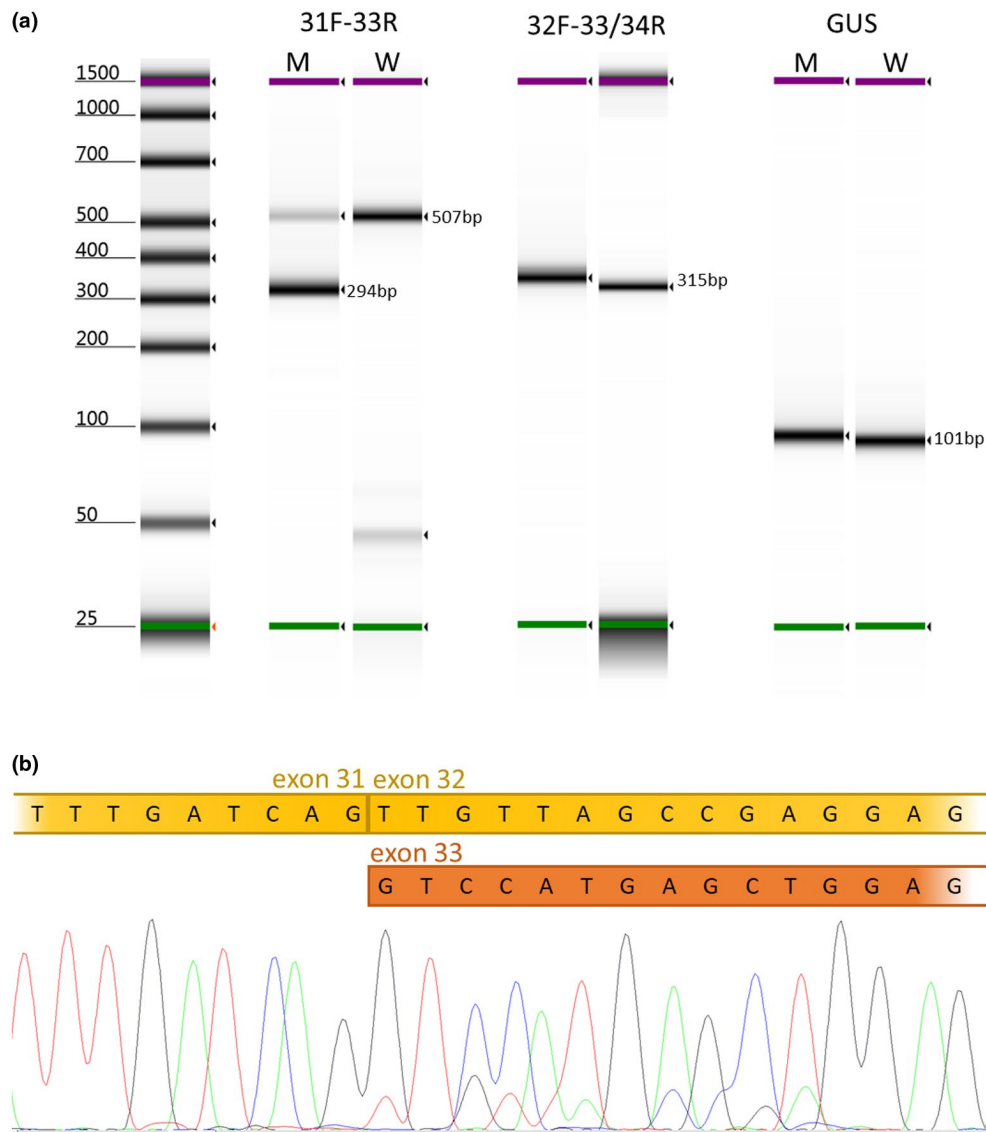


FIGURE 2 RT-PCR analysis demonstrates *MYH11* c.4578+3A>C leads to exon 32 skipping. a. RT-PCR products run on TapeStation System (Agilent Technologies). The expected 515-bp wild-type fragment was obtained in both the control (W) and the mutated individual (M); an additional 302-bp fragment was found in the mutated individual. b. Electropherogram from ABI 3500xl DNA analyzer (Applied Biosystems) showing that the variant causes the skipping of the exon 32

is challenging because of imperfect and sometimes conflicting results obtained with in silico prediction software (Jaganathan et al., 2019). In particular, the pathogenicity of variants at the position +3 of 5'ss is difficult to predict: data in the literature report some variants as pathogenic and others as benign. Moreover, the influence of the nucleotide environment has been previously suggested (Guédard-Méreuze et al., 2009). To illustrate this, we used currently available algorithms to calculate computational scores with known variants at this 5'ss (Supplemental material). Despite a tendency toward an effect for the pathogenic c.4578+3A>C variant compared to the likely-benign c.4578+3A>G one (−11.4 to −59.6% variation vs −3.2 to −11.2%) in silico predictions do not allow a conclusion

compared with the c.4578+1G>T/A/del variants. Thus, transcript analysis is mandatory to consider whether a +3 variant alters splicing or not.

Interestingly, the RNA defect caused by the c.4578+3A>C is the same as previously described about the c.4578+1G>T variant reported in a large HTAAD/PDA family (Khu Van Kien et al., 2004; Zhu et al., 2006). The authors visualized a shortened protein with a 71 amino acid deletion using immunoblotting of aortic tissue. This in-frame deletion (p.1456_1526del) alters the coiled-coil domain of the protein. In vitro and in vivo functional experiments were supportive of a dominant negative effect by altering the thick myosin filament formation. In addition to this family and the one we report

here, we identified two more reports of HTAAD/PDA pedigrees with other variants predicted (c.4578+1G>A) or shown (c.4578+1delG) to lead to exon skipping of exon 32 (LaHaye et al., 2016; Renard et al., 2013).

Other HTAAD/PDA patients have rarely been reported in the literature with variants affecting the coiled-coil domain or the ATPase head region (Pannu et al., 2007). Nonetheless, variant segregation seems to be imperfect in some individuals but functional studies that establish an effect on the protein have not been performed (Harakalova et al., 2013). Decreased penetrance like observed in patient IV.2 and literature is frequent and often age-related. It is also the case for other HTAAD genes such *ACTA2*, *TGFBR1* and *TGFBR2* (Pannu et al., 2005; van de Laar et al., 2019).

Moreover, predicted loss-of-function variants of *MYH11*, including the 16p13.11 recurrent microdeletion, are associated with recessive MMIHS (Gauthier et al., 2015; Kloth et al., 2019). Three other variants predicted to result in an elongated protein, and a strong impairment of dimerization predicting loss-of-function, are reported in three dominant pedigrees affected by Chronic Intestinal Pseudo-Obstruction or Myopathic Gastrointestinal Motility Disorder (Dong et al., 2019; Gilbert et al., 2020; Ikebe et al., 2001). In this context, *MYH11* variants may lead to two main different categories of variable phenotypes of smooth muscle cell dysfunction (HTAAD/PDA and “visceral myopathies”) through two different pathogenic mechanisms. It is also interesting to note that the 16p13.11 duplication that encompasses *MYH11* is associated with a 10-fold increased risk of aortic aneurysm and dissection (Kuang et al., 2011; Milewicz et al., 2017). This copy number variant is commonly considered as a susceptibility factor to neurodevelopmental disorders with low penetrance (8.4%) and variable expressivity, found in the general population (Allach El Khattabi et al., 2020).

Collectively, these facts highlight the unclear *MYH11* genotype/phenotype correlations that should be further studied and documented. As a first effort, our observation highlights that dominant HTAAD/PDA associated *MYH11* alleles, and in particular, the recurrent exon 32 skipping (dominant negative) or TAAD susceptibility (hypermorph), may confer other properties than predicted loss-of-function *MYH11* alleles (leading to recessive or dominant “visceral Myopathies”). Consequently, pathogenic assessment of a variant in the *MYH11* gene in HTAAD/PDA should be particularly cautious and curation of *MYH11* variants for specific disease phenotypes is critical due to differences in inheritance and mechanism. Further studies are necessary to evaluate several hypotheses that could explain the underlying pathophysiological mechanisms underlying these complex genotype/phenotype correlations. Among these hypotheses, loss

or gain-of-function, effect of the variant on particular smooth muscle cells strains or their phenotype switch, effect on contraction or relaxation, mechanotransduction, signaling, etc., could be considered.

We provide here data from a new family with HTAAD/PDA, which highlights the unclear genotype-phenotype correlations and molecular pathophysiological mechanisms observed in the few studies of *MYH11*. Skipping of the *MYH11* exon 32 is a recurrent RNA defect leading to HTAAD/PDA. Transcript analyses should be considered in cases of variation in a +3 position of a 5'ss in any gene of interest to help the interpretation.

ACKNOWLEDGMENTS

We warmly thank the patients for their participation and Timothy Tranbarger for his advice and proofreading of the manuscript.

CONFLICT OF INTERESTS

The authors have no relevant financial or non-financial interests to disclose.

AUTHOR'S CONTRIBUTION

BC, AP, GR, TLB and PKVK performed the genetic analysis; BC, BM, YD, TE, JP, MAM, SJ, ML, and PKVK evaluated for clinical data and follow-up the family members; all the authors participated to the redaction of this manuscript.

DATA AVAILABILITY STATEMENT

The data that support the findings of this study are available from the corresponding author upon reasonable request. The genetic variant has been submitted for public access through LOVD under accession ID: #0000736497, *MYH11*.lovd.nl.

ORCID

Bertrand Chesneau  <https://orcid.org/0000-0001-9729-7346>
Philippe Khau Van Kien  <https://orcid.org/0000-0001-7754-969X>

REFERENCES

- Allach El Khattabi, L., Heide, S., Caberg, J.-H., Andrieux, J., Doco Fenzy, M., Vincent-Delorme, C., Callier, P., Chantot-Bastaraud, S., Afenjar, A., Boute-Benejean, O., Cordier, M. P., Faivre, L., Francannet, C., Gerard, M., Goldenberg, A., Masurel-Paulet, A., Mosca-Boidron, A.-L., Marle, N., Moncla, A., ... Pipiras, E. (2020). 16p13.11 microduplication in 45 new patients: refined clinical significance and genotype-phenotype correlations. *Journal of Medical Genetics*, 57(5), 301–307. <https://doi.org/10.1136/jmedgenet-2018-105389>
- Arnaud, P., Hanna, N., Benarroch, L., Aubart, M., Bal, L., Bouvagnet, P., Busa, T., Dulac, Y., Dupuis-Girod, S., Edouard, T., Faivre, L., Gouya, L., Lacombe, D., Langeois, M., Leheup, B., Milleron,

- O., Naudion, S., Odent, S., Tchitchinadze, M., ... Boileau, C. (2019). Genetic diversity and pathogenic variants as possible predictors of severity in a French sample of nonsyndromic heritable thoracic aortic aneurysms and dissections (nshTAAD). *Genetics in Medicine*, *21*, 2015–2024. <https://doi.org/10.1038/s41436-019-0444-y>
- Bentall, H., & De Bono, A. (1968). A technique for complete replacement of the ascending aorta. *Thorax*, *23*(4), 338–339. <https://doi.org/10.1016/j.ejcts.2007.07.011>
- Borst, H. G., Walterbusch, G., & Schaps, D. (1983). Extensive aortic replacement using “Elephant Trunk” prosthesis. *The Thoracic and Cardiovascular Surgeon*, *31*(1), 37–40. <https://doi.org/10.1055/s-2007-1020290>
- Dong, W., Baldwin, C., Choi, J., Milunski, J. M. et al (2019). Identification of a dominant *MYH11* causal variant in chronic intestinal pseudo-obstruction: Results of whole-exome sequencing. *Clinical Genetics*, *96*(5), 473–477.
- Gauthier, J., Ouled Amar Bencheikh, B., Hamdan, F. F., Harrison, S. M., Baker, L. A., Couture, F., Thiffault, I., Ouazzani, R., Samuels, M. E., Mitchell, G. A., Rouleau, G. A., Michaud, J. L., & Soucy, J.-F. (2015). A homozygous loss-of-function variant in *MYH11* in a case with megacystis-microcolon-intestinal hypoperistalsis syndrome. *European Journal of Human Genetics*, *23*, 1266–1268. <https://doi.org/10.1038/ejhg.2014.256>
- Gilbert, M. A., Schultz-Rogers, L., Rajagopalan, R. et al (2020). Protein-elongating mutations in *MYH11* are implicated in a dominantly inherited smooth muscle dysmobility syndrome with severe esophageal, gastric and intestinal disease. *Human Mutation*, *41*(5), 973–982. <https://doi.org/10.1002/humu.23986>
- GuÃ©lard-MÃ©reuz, S. L., VachÃ©, C., Molinari, N., Vaudaine, J., Claustres, M., Roux, A.-F., & Tuffery-Giraud, S. (2009). Sequence contexts that determine the pathogenicity of base substitutions at position +3 of donor splice-sites. *Human Mutation*, *30*, 1329–1339. <https://doi.org/10.1002/humu.21070>
- Harakalova, M., van der Smagt, J., de Kovel, C. G. F., van't Slot, R., Poot, M., Nijman, I. J., Medic, J., Joziassse, I., Deckers, J., Roos-Hesselink, J. W., Wessels, M. W., Baars, H. F., Weiss, M. M., Pals, G., Golmard, L., Jeunemaitre, X., Lindhout, D., Cuppen, E., & Baas, A. F. (2013). Incomplete segregation of *MYH11* variants with thoracic aortic aneurysms and dissections and patent ductus arteriosus. *European Journal of Human Genetics*, *21*, 487–493. <https://doi.org/10.1038/ejhg.2012.206>
- Ikebe, M., Komatsu, S., Woodhead, J. L. et al (2001). The tip of the coiled-coil rod determines the filament formation of smooth muscle and nonmuscle myosin. *Journal of Biological Chemistry*, *276*(32), 30293–30300. <https://doi.org/10.1074/jbc.M101969200>
- Jaganathan, K., Kyriazopoulou Panagiotopoulou, S., McRae, J. F., Darbandi, S. F., Knowles, D., Li, Y. I., Kosmicki, J. A., Arbelaez, J., Cui, W., Schwartz, G. B., Chow, E. D., Kanterakis, E., Gao, H., Kia, A., Batzoglou, S., Sanders, S. J., & Farh, K.-H. (2019). Predicting splicing from primary sequence with deep learning. *Cell*, *176*, 535–548.e24. <https://doi.org/10.1016/j.cell.2018.12.015>
- Khau Van Kien, P., Wolf, J.-E., Mathieu, F., Zhu, L., Salve, N., Lalande, A., Bonnet, C., Lesca, G., Plauchu, H., Dellinger, A., Nivelon-Chevallier, A., Brunotte, F., & Jeunemaitre, X. (2004). Familial thoracic aortic aneurysm/dissection with patent ductus arteriosus: Genetic arguments for a particular pathophysiological entity. *European Journal of Human Genetics*, *12*, 173–180. <https://doi.org/10.1038/sj.ejhg.5201119>
- Kloth, K., Renner, S., Burmester, G. et al (2019). 16p13.11 microdeletion uncovers loss-of-function of a *MYH11* missense variant in a patient with megacystis-microcolon-intestinal-hypoperistalsis syndrome. *Clinical Genetics*, *96*:85–90. <https://doi.org/10.1111/cge.13557>
- Kuang, S.-Q., Guo, D.-C., Prakash, S. K., McDonald, M.-L., Johnson, R. J., Wang, M., Regalado, E. S., Russell, L., Cao, J.-M., Kwartler, C., Fraivillig, K., Coselli, J. S., Safi, H. J., Estrera, A. L., Leal, S. M., LeMaire, S. A., Belmont, J. W., & Milewicz, D. M. (2011). Recurrent chromosome 16p13.1 duplications are a risk factor for aortic dissections. *PLoS Genetics*, *7*(6), e1002118. <https://doi.org/10.1371/journal.pgen.1002118>
- LaHaye, S., Corsmeier, D., Basu, M. et al (2016). Utilization of whole exome sequencing to identify causative mutations in familial congenital heart disease. *Circulation: Cardiovascular Genetics*, *9*(4), 320–329. <https://doi.org/10.1161/CIRCGENETICS.115.001324>
- Li, Y., Kong, Y., Duan, W. et al (2021). Evaluating the monogenic contribution and genotype–phenotype correlation in patients with isolated thoracic aortic aneurysm. *European Journal of Human Genetics*, *29*(7), 1129–1138. <https://doi.org/10.1038/s41431-021-00857-2>
- Mariscalco, G., Debiec, R., Elefteriades, J. A., Samani, N. J., & Murphy, G. J. (2018). Systematic review of studies that have evaluated screening tests in relatives of patients affected by nonsyndromic thoracic aortic disease. *Journal of the American Heart Association*, *7*(15), e009302. <https://doi.org/10.1161/JAHA.118.009302>
- Milewicz, D. M., Trybus, K. M., Guo, D.-C., Sweeney, H. L., Regalado, E., Kamm, K., & Stull, J. T. (2017). Altered smooth muscle cell force generation as a driver of thoracic aortic aneurysms and dissections. *Arteriosclerosis, Thrombosis, and Vascular Biology*, *37*, 26–34. <https://doi.org/10.1161/ATVBAHA.116.303229>
- Pannu, H., Fadulu, V. T., Chang, J., Lafont, A., Hasham, S. N., Sparks, E., Giampietro, P. F., Zaleski, C., Estrera, A. L., Safi, H. J., Shete, S., Willing, M. C., Raman, C. S., & Milewicz, D. M. (2005). Mutations in transforming growth factor- β receptor type II cause familial thoracic aortic aneurysms and dissections. *Circulation*, *112*, 513–520. <https://doi.org/10.1161/CIRCULATIONAHA.105.537340>
- Pannu, H., Tran-Fadulu, V., Papke, C. L., Scherer, S., Liu, Y., Presley, C., Guo, D., Estrera, A. L., Safi, H. J., Brasier, A. R., Vick, G. W., Marian, A. J., Raman, C. S., Buja, L. M., & Milewicz, D. M. (2007). *MYH11* mutations result in a distinct vascular pathology driven by insulin-like growth factor 1 and angiotensin II. *Human Molecular Genetics*, *16*, 2453–2462. <https://doi.org/10.1093/hmg/ddm201>
- Renard, M., Callewaert, B., Baetens, M., Campens, L., MacDermot, K., Fryns, J.-P., Bonduelle, M., Dietz, H. C., Gaspar, I. M., Cavaco, D., Stattin, E.-L., Schrandt-Stumpel, C., Coucke, P., Loeys, B., De Paepe, A., & De Backer, J. (2013). Novel *MYH11* and *ACTA2* mutations reveal a role for enhanced TGF β signaling in FTAAD. *International Journal of Cardiology*, *165*(2), 314–321. <https://doi.org/10.1016/j.ijcard.2011.08.079>
- van de Laar, I. M. B. H., Arbustini, E., Loeys, B., Björck, E., Murphy, L., Groenink, M., Kempers, M., Timmermans, J., Roos-Hesselink, J., Benke, K., Pepe, G., Mulder, B., Szabolcs, Z., Teixidó-Turà, G., Robert, L., Emmanuel, Y., Evangelista, A., Pini, A., von Kodolitsch, Y., ... De Backer, J. (2019). European reference network for rare vascular diseases (VASCERN) consensus

statement for the screening and management of patients with pathogenic *ACTA2* variants. *Orphanet Journal of Rare Diseases*, 14, 264. <https://doi.org/10.1186/s13023-019-1186-2>

Zhu, L., Vranckx, R., Van Kien, P. K., Lalande, A., Boisset, N., Mathieu, F., Wegman, M., Glancy, L., Gasc, J.-M., Brunotte, F., Bruneval, P., Wolf, J.-E., Michel, J.-B., & Jeunemaitre, X. (2006). Mutations in myosin heavy chain 11 cause a syndrome associating thoracic aortic aneurysm/aortic dissection and patent ductus arteriosus. *Nature Genetics*, 38, 343–349. <https://doi.org/10.1038/ng1721>

SUPPORTING INFORMATION

Additional supporting information may be found in the online version of the article at the publisher's website.

How to cite this article: Chesneau, B., Plancke, A., Rolland, G., Marcheix, B., Dulac, Y., Edouard, T., Plaisancié, J., Aubert-Mucca, M., Julia, S., Langeois, M., Lavabre-Bertrand, T., & Khau Van Kien, P. (2021). A +3 variant at a donor splice site leads to a skipping of the *MYH11* exon 32, a recurrent RNA defect causing Heritable Thoracic Aortic Aneurysm and Dissection and/or Patent Ductus Arteriosus. *Molecular Genetics & Genomic Medicine*, 00, e1814. <https://doi.org/10.1002/mgg3.1814>