



HAL
open science

Topographical analysis of structural lesions between dominant and non-dominant hands in erosive osteoarthritis

Edem Allado, Ruth Wittoek, Eliane Albuissou, Stephanie Ferrero, Bruno Chenuel, Isabelle Chary-Valckenaere, Roux Christian, Damien Loeuille

► To cite this version:

Edem Allado, Ruth Wittoek, Eliane Albuissou, Stephanie Ferrero, Bruno Chenuel, et al.. Topographical analysis of structural lesions between dominant and non-dominant hands in erosive osteoarthritis. *Rheumatology International*, 2021, 41 (3), pp.617-623. 10.1007/s00296-020-04784-1 . hal-03524055

HAL Id: hal-03524055

<https://hal.science/hal-03524055>

Submitted on 11 Apr 2022

HAL is a multi-disciplinary open access archive for the deposit and dissemination of scientific research documents, whether they are published or not. The documents may come from teaching and research institutions in France or abroad, or from public or private research centers.

L'archive ouverte pluridisciplinaire **HAL**, est destinée au dépôt et à la diffusion de documents scientifiques de niveau recherche, publiés ou non, émanant des établissements d'enseignement et de recherche français ou étrangers, des laboratoires publics ou privés.

1 **Topographical analysis of structural lesions between dominant and non-dominant hands**
2 **in erosive osteoarthritis**

3
4 Edem Allado^{1,2,3}, Ruth Wittoek⁴, Eliane Albuissou^{5,6}, Stephanie Ferrero⁷, Bruno Chenuel^{2,3},
5 Isabelle Chary-Valckenaere^{1,8}, Christian Roux⁷, Damien Loeuille^{1,8}

6

7 **Affiliations**

8 ¹ Université de Lorraine, CHRU-Nancy, Department Rheumatology, F-54000, Nancy,
9 France.

10 ² Université de Lorraine, CHRU-Nancy, University Center of Sports Medicine and
11 Adapted Physical Activity F-54000, Nancy, France.

12 ³ Université de Lorraine, DevAH, F-54000 Nancy, France

13 ⁴ Department of Rheumatology, Faculty of Medicine and Health Sciences, Laboratory for
14 Molecular Immunology and Inflammation, Ghent University, C. Heymanslaan 10, 9000
15 Ghent, Belgium

16 ⁵ Université de Lorraine, InSciDenS, F-54000 Nancy, France

17 ⁶ Université de Lorraine, CNRS, IECL, F-54000 Nancy, France

18 ⁷ Department Rheumatology, University of Cote d'Azur, Nice Hospital, Laboratory
19 LAMHESS, EA6312. IBV CNRS IMR 7277 INSERM U1091 UNS

20 ⁸ Université de Lorraine, IMoPA, F-54000 Nancy, France

21

22 **Clinical trial:** NCT01068405

23 **Keywords:** erosive hand, osteoarthritis, topography, conventional radiography,

24 **Key messages:**

25 - No difference between both hands was observed for clinical and radiographical
26 presentations in EHOA patients.

27 - A bilateral and symmetrical relationship was found between hand joints.

28 **Highlights:**

- 29 • EHOA have symmetrical distribution and specific association in structural lesions.

30

31 **Corresponding author**

32 Edem Allado

33 Department Rheumatology, University Hospital of Nancy, F-54000. Nancy, France.

34 Tel: + 33 (0)3 83 15 32 03

35 Fax: + 33 (0)3 83 15 31 90

36 e-mail: e.allado@chru-nancy.fr

37

38 **Word count**

39 Abstract: 248 words

40 Articles: 2333 words

41

42 **Running title**

43 Topographical analysis of radiological structural lesions between dominant and non-dominant
44 hands in erosive osteoarthritis

45

46

47 **Abstract**

48

49 **Objective:** This study aims to analyse the preferential topographical distribution of clinical and
50 structural lesions between the dominant and non-dominant hands in erosive hand osteoarthritis
51 (EHOA) patients.

52

53 **Methods:** Both hands were assessed via radiography in EHOA patients. A comparative analysis
54 of the clinical features and structural lesions between the dominant and non-dominant hands
55 was performed. The structural lesions were assessed according to the anatomical radiographic
56 score of Verbruggen-Veys (VV). Next, a principal component analysis was performed to
57 describe and highlight the relationships observed between the joints.

58 **Results:** Sixty patients were included in this study: there were 57 women, and the mean age
59 was 66.1 (± 7.6) years. For the distal interphalangeal (DIP) joints, nodes were observed more
60 frequently on the dominant hand (4 vs 3; $p=0.005$). No difference in structural lesions was
61 observed between the two hands except for the 2nd proximal interphalangeal (PIP) ($p=0.045$).
62 A principal component analysis with varimax rotation described relationships between the 2nd
63 PIP, 3rd PIP, 4th PIP, 4th DIP and 5th DIP joints in both hands.

64

65 **Conclusion:** No significant differences between dominant and non-dominant hands were
66 observed for clinical and structural lesions in our sample of EHOA patients. A bilateral and
67 symmetrical injury was observed in most EHOA joints.

68 **Introduction**

69 Erosive hand osteoarthritis (EHOA) has a functional impact similar to rheumatoid
70 arthritis.[1, 2] This chronic disease mainly affects older women, presents inflammatory flare-
71 ups and evolves faster than non-erosive hand osteoarthritis (HOA).[3] The formal diagnosis of
72 EHOA is based upon specific clinical and radiographic patterns. In practice, conventional
73 radiography (CR) is the most relevant method used to evaluate structural lesions. [3]

74

75 In HOA, the topography of structural lesions between dominant and non-dominant hands is still
76 debated. Some studies have found that HOA preferentially affects the dominant hand and DIP
77 joints and assumes a mechanical origin, [4, 5] while others suggest that there are no
78 radiographic or clinical differences between the dominant and non-dominant hands.[6] In
79 particular, recent studies have shown a predisposition to bilateral involvement in EHOA.[7, 8]
80 In fact, the pathophysiology of EHOA needs to be clarified .

81

82 If the mechanical hypothesis is commonly accepted for HOA, recent results also suggest a
83 systemic component: structural lesions do not seem to be predominantly distributed in the
84 dominant hand and the two hands may evolve in association.[7–9].For a systemic component,
85 a specific topographical distribution can be observed: structural lesions are depicted on the same
86 rank and/or on the same row for the dominant hand compared with the non-dominant hand.

87

88 This study aims to characterize the topographical distribution of clinical and structural lesions
89 between the dominant and non-dominant hand in EHOA patients. The aim of this study is to
90 evaluate two topographical distribution hypotheses. Hypothesis 1: joints affected by
91 mechanical stress present more structural lesions compared with the non-dominant hand.
92 Hypothesis 2: joints affected by a systemic component presented symmetrical involvement
93 between dominant and non-dominant hands.

94

95 **METHODS**

96 This is an observational ancillary study which involved patients with symptomatic
97 EHOA. The principal, monocentric randomized, double-blind, placebo-controlled study
98 (NCT1968405) examined the effect of methotrexate on pain and structural progression in
99 symptomatic EHOA.

100

101 **Patients**

102 Patients with EHOA were included in the ADEM cohort by the Department of Rheumatology
103 of Nice (France). The inclusion criteria were as follows: patients 45-85 years old, suffering
104 from EHOA in the proximal interphalangeal (PIP) and distal interphalangeal (DIP) joints for
105 more than three months, according to the American College of Rheumatology (ACR) criteria
106 for HOA. To be included in this study, patients had to present with at least one eroded joint
107 from the PIP or DIP joints according to bilateral hand CR.

108

109 **Demographic and clinical data**

110 The patients underwent a specific physical examination of the hands for PIPs, DIPs, and
111 metacarpophalangeal joints (MCPs), for a total of 28 joints. The number of swollen nodes and
112 tender joints were counted (absent or present), and the visual analogue scale (VAS) was used
113 to score hand pain (0-100 mm); the VAS was implemented for physician global disease activity
114 and patient global disease activity. VAS was assessed in the last 48 hours preceding the
115 consultation. All patients were asked to fill out two questionnaires to measure the functional
116 ability of the hand: the Functional Index for Hand Osteoarthritis (FIHOA) and the Cochin Hand
117 Functional Scale.

118

119 **Conventional radiography**

120 Hand X-rays were performed for all patients at baseline and 12-month follow-up. Blind
121 evaluation of the radiographs was performed by a senior and junior independent reader (SF and
122 RW). A comparison of the two readings was performed on erosive joints (VV scoring system).
123 The concordance between evaluators was 82%. Only the senior reading (RW) was considered
124 for the analysis. The anatomical VV score was determined for both hands.

125

126 **Statistical analysis**

127 Both descriptive and comparative analyses were conducted according to the nature and
128 distribution of the variables (normality assessed by Shapiro-Wilk test). Qualitative variables
129 are described as frequencies and percentages; quantitative variables are reported as the mean \pm
130 standard deviation (SD) or as the median with 25th and 75th percentiles.

131 The Wilcoxon signed-rank test was used for the analysis of clinical features and structural
132 lesions between the dominant and non-dominant hand (paired data).

133 To observe proximities between the structural lesions, we used a principal component analysis
134 (PCA). This analysis describes joints groups with the same characteristics (structural lesion
135 stage).

136 To identify hand joints affected by mechanical stress (more structural lesions on dominant
137 hand); or joints affected by a systemic component (symmetric structural lesions were associated
138 between dominant and non-dominant hands) a PCA was performed.

139 A PCA with varimax rotation was performed to structure the results of all the relationships
140 between the radiographic structural lesions. Only the preferential projections (value of the
141 projection > 0.50) were retained on each of the first components, and the related variables were
142 then identified by component.

143 The p values <0.05 were considered statistically significant. We used IBM TM SPSS Statistics
144 Software v23 for data analysis.

145

146 **Ethical considerations**

147

148 This study is registered with the Information Technology and Freedoms Commission for the
149 University Hospital of Nice (09-029 at 18/01/2010) and was designed in accordance with the
150 general ethical principles outlined in the Declaration of Helsinki. All patients gave their
151 informed consent for the use of their medical data during the time when they received medical
152 care at the University Hospital of Nice.

153 **RESULTS**

154

155 **Demographic data and clinical characteristics**

156 Among the 64 patients included in this cohort, 60 patients were involved in the systematic
157 examination of the hands by CR and were selected for this study according to the inclusion
158 criteria. The sample mostly comprised women (n=57), the mean age was 66.1 (+/-7.6) years,
159 and most suffered from severe pain and dysfunction (table 1).

160

161 **Clinical characteristics of the interphalangeal joints**

162 The most painful joints were the DIP joints. They were more swollen and demonstrated more
163 nodes than the PIP joints. Regarding pain and swelling, no significant difference was observed
164 between the PIP and DIP joints in the dominant and contralateral hand. A significant difference
165 was only found in the number of nodes in the DIP joints ($p = 0.005$), where the dominant hand
166 showed more lesions than the non-dominant hand (table 2).

167

168 **Interphalangeal structural lesions in EHOA**

169 According to the CR results, we observed more structural lesions in DIP than in PIP joints.
170 Normal DIP and PIP joints were observed in 18.5% of the cases. No difference in the
171 distribution of structural lesions was found between the dominant and non-dominant hands
172 except for the 2nd PIP joint ($p=0.045$). On the 2nd PIP joint, the non-dominant hand
173 demonstrated more erosive and remodelled lesions than the dominant hand. The DIP joints were
174 generally more affected than the PIP joints, without a significant difference in terms of
175 prevalence between both hands (table 3).

176

177 **Structural lesions: relationship between dominant and non-dominant hands**

178 For the principal component analysis, VV was used to score the joint stage. Eight components
179 were necessary to explain 81.7% of the total variation. Concerning the eight components, three
180 included symmetric hand joint involvement (1, 2 and 3), and four components (4, 5, 7, and 8)
181 included unilateral hand joint involvement

182 For component 6, hands were bilaterally involved with an asymmetric pattern. The joints
183 projected into at least one axis except for the 2nd DIP and the 5th PIP joints of the non-dominant
184 hand (table 4).

185

186 Approximately half of the dispersion was explained by the first three components (56.8%)
187 corresponding to a symmetric joint involvement. Component 1 was related to the 2nd PIP; the
188 3rd PIP and the 4th PIP joints; component 2 was related to the 5th DIP joints and component 3
189 to the 4th DIP joints (figure 1).

190 **DISCUSSION**

191

192 Our study failed to demonstrate any predominance of clinical and structural lesions in the
193 dominant hand; no independence or preferential relationship of joint lesions was found in either
194 hand. More precisely, there seems to exist a specific association between the two 2nd PIP joints,
195 the two 3rds PIP joints, the two 4ths PIP joints, the two 5ths DIP joints, and the two 4ths DIP
196 joints.

197

198 In fact, the proximity existing here between the two 2nd PIP joints, the two 3rds PIP joints, the
199 two 4th PIP joints (first component), the two 5th PIP joints (second component) and the two
200 4th PIP joints (third component) represents a substantial contribution to all components,
201 explaining more than half of the dispersion.

202 Among the clinical features and structural lesions, no difference was found between the two
203 hands, except for the second PIP joint and for Heberden's nodes.

204

205 In the Framingham Community cohort, the authors observed a female predominance of
206 prevalent and incident EHOA with more structural lesions for DIP than for PIP. [10] Marshall
207 *et al.* included 80 patients with EHOA. [7] The study of Nakamura *et al.* highlighted a
208 difference in the incidence of Heberden's nodes in women with HOA depending on occupation:
209 a 19.2% incidence among cooks and 5.9% among municipal administrative officers. [4]

210 In our work, with a similar cohort including predominantly women and being representative of
211 EHOA, we found more structural lesions in the DIP joints than in the PIP joints. There was also
212 a predominance of Heberden's nodes on the dominant hand. The lack of difference in pain
213 sensation between the dominant and non-dominant hand described in our study has also been
214 observed in the literature. [6]

215

216 Egger and colleagues showed that the presence of DIP structural lesions in HOA increased the
217 risk of developing or observing PIP lesions (OR 3.1, [95% CI 1.4-6.8]), another DIP lesion (OR
218 10.0, [95% CI 7.3-13.7]) or symmetric bilateral DIP lesions (OR 38.8 [95% CI 14.5-103.5]).
219 [11] In EHOA, they noticed similar results: greater risk of developing a structural lesion in the
220 same joint in the opposite hand (OR 6.5, [95% CI 3.0-14.1]) but not in the same row or ray of
221 the ipsilateral hand. [7] In this study, it has been shown that the EHOA structural lesions rank
222 was the same in HOA for joints assessed as grade 4 according to the Kellgren & Lawrence
223 scoring system: first DIP2, second DIP3 and third DIP5.

224

225 The main component analysis of our study allowed us to observe the bilateral and symmetrical
226 proximity between the 3rd, 4th, and 5th joints, which had little mechanical stress compared to
227 the 1st and 2nd joints. The most commonly affected joints (DIP 2-3) were included in the
228 component, but the bilateral joints were not in the same component. We suppose an independent
229 evolution for these joints.

230

231 These results suggest the presence of miscellaneous pathophysiological factors responsible for
232 EHOA in addition to mechanical constraints. First, the female predominance in EHOA may
233 suggest hormonal involvement. The consequences of obesity and, more particularly, adipokines
234 have been reported in EHOA development. [7, 8, 12] Our results also support inflammatory
235 mechanisms, as suggested in the literature. Hussain *et al.* compared inflammatory and structural
236 ultrasound lesions in HOA and rheumatoid arthritis. Unexpectedly, no significant difference
237 between the two pathologies was demonstrated in the prevalence of grade 2 and 3 synovial
238 hypertrophies assessed by B-mode or synovitis assessed by power Doppler modes. [13]

239 Prospective studies have characterized synovitis at baseline as a major factor of central erosion
240 involvement during follow-up. [14–16] Biological markers have been studied, with one study
241 conducted in 2016 on 18 patients with HOA reporting a relationship between interleukin 1
242 levels and structural erosive lesions ($r=0.70$) as well as loss of function ($r=0.73$). [17]

243

244 Finally, a neurogenic component has also been suggested: no ipsilateral hand lesions were
245 found on the injured side following a stroke hemiparesis or poliomyelitis in the framework of
246 HOA. [18] Such a systematization of the distribution of EHOA may involve additional
247 mechanisms to local causes.

248

249 Our study presented some limitations, including the small sample size ($n=60$) and the lack of
250 data on professional and leisure activities. The lack of power explains the large inertia of the
251 results in the main component analysis (8 components). Furthermore, this cross-sectional study
252 did not confirm the robustness of this topography over time. In addition, since structural lesions
253 reflect prolonged impairment, they are not informative about either the early mechanisms
254 responsible for these lesions or about inflammatory lesions (bone marrow lesions, synovitis,
255 tenosynovitis).

256

257 This study, however, presents an original design, where the first 3 components underline a
258 symmetrical distribution. Despite the small sample size, the completeness of the clinical and
259 CR data of 1080 joints reinforces the relevance of the results. The use of a suitable radiographic
260 score and the realization of double-blind reading of the imaging with very good concordance
261 also reinforces the relevance of our conclusions. To confirm these findings, a longitudinal
262 analysis of structural and inflammatory lesions would be relevant to assess the constancy in
263 time of this topographic pattern, while clarifying the links between these lesions and their
264 mechanisms.

265

266 In conclusion, there is no significant difference between the two hands regarding clinical and
267 structural lesions. This study observed a symmetrical association of EHOA structural lesions.
268 Systemic mechanisms or central inflammatory mechanisms are strongly suspected. These
269 results raise the hypothesis of a continuum between inflammatory rheumatism and EHOA.
270 Further studies are needed to examine the effects of conventional or biological disease-
271 modifying antirheumatic drugs in EHOA.

272 **Acknowledgements**

273 This work was supported by a grant from the « Clinical Research Hospital Program » from the
274 French Ministry of Health obtained by Pr Christian Roux. We are grateful to Alain Canagas for
275 the graphical work.

REFERENCES

1. Haugen IK, Slatkowsky-Christensen B, Bøyesen P, et al (2013) Cross-sectional and longitudinal associations between radiographic features and measures of pain and physical function in hand osteoarthritis. *Osteoarthritis and Cartilage* 21:1191–1198. <https://doi.org/10.1016/j.joca.2013.04.004>
2. Slatkowsky-Christensen B, Mowinckel P, Loge JH, Kvien TK (2007) Health-related quality of life in women with symptomatic hand osteoarthritis: A comparison with rheumatoid arthritis patients, healthy controls, and normative data. *Arthritis & Rheumatism* 57:1404–1409. <https://doi.org/10.1002/art.23079>
3. Marshall M, Watt FE, Vincent TL, Dziedzic K (2018) Hand osteoarthritis: clinical phenotypes, molecular mechanisms and disease management. *Nature Reviews Rheumatology* 14:641–656. <https://doi.org/10.1038/s41584-018-0095-4>
4. Nakamura R, Ono Y, Horii E, et al (1993) The Aetiological Significance of Work-Load in the Development of Osteoarthritis of the Distal Interphalangeal Joint. *Journal of Hand Surgery* 18:540–542. [https://doi.org/10.1016/0266-7681\(93\)90167-E](https://doi.org/10.1016/0266-7681(93)90167-E)
5. Hadler NM, Gillings DB, Imbus HR, et al (1978) Hand structure and function in an industrial setting. *Arthritis & Rheumatism* 21:210–220. <https://doi.org/10.1002/art.1780210206>
6. Lane NE, Bloch DA, Jones HH, et al (1989) Osteoarthritis in the hand: a comparison of handedness and hand use. *The Journal of rheumatology* 16:637–642
7. Marshall M, Nicholls E, Kwok W-Y, et al (2015) Erosive osteoarthritis: a more severe form of radiographic hand osteoarthritis rather than a distinct entity? *Annals of the Rheumatic Diseases* 74:136–141. <https://doi.org/10.1136/annrheumdis-2013-203948>
8. Haara MM (2003) Osteoarthritis of finger joints in Finns aged 30 or over: prevalence, determinants, and association with mortality. *Annals of the Rheumatic Diseases* 62:151–158. <https://doi.org/10.1136/ard.62.2.151>
9. Bijsterbosch J, van Bommel JM, Watt I, et al (2011) Systemic and local factors are involved in the evolution of erosions in hand osteoarthritis. *Annals of the Rheumatic Diseases* 70:326–330. <https://doi.org/10.1136/ard.2010.138230>
10. Haugen IK, Englund M, Aliabadi P, et al (2011) Prevalence, incidence and progression of hand osteoarthritis in the general population: the Framingham Osteoarthritis Study. *Annals of the Rheumatic Diseases* 70:1581–1586. <https://doi.org/10.1136/ard.2011.150078>
11. Egger P, Cooper C, Hart DJ, et al (1995) Patterns of joint involvement in osteoarthritis of the hand: the Chingford Study. *J Rheumatol* 22:1509–1513
12. Fioravanti A, Cheleschi S, De Palma A, et al (2018) Can adipokines serum levels be used as biomarkers of hand osteoarthritis? *Biomarkers* 23:265–270. <https://doi.org/10.1080/1354750X.2017.1401665>

13. Hussain S, Sivakumaran P, Gill A, et al (2018) Ultrasonography-detected subclinical inflammation in patients with hand osteoarthritis and established rheumatoid arthritis: a comparison between two different pathologies using the same ultrasound examination protocol. *Musculoskeletal Care* 16:26–31. <https://doi.org/10.1002/msc.1197>
14. Haugen IK, Slatkowsky-Christensen B, Bøyesen P, et al (2016) MRI findings predict radiographic progression and development of erosions in hand osteoarthritis. *Annals of the Rheumatic Diseases* 75:117–123. <https://doi.org/10.1136/annrheumdis-2014-205949>
15. Mancarella L, Addimanda O, Pelotti P, et al (2015) Ultrasound detected inflammation is associated with the development of new bone erosions in hand osteoarthritis: a longitudinal study over 3.9 years. *Osteoarthritis and Cartilage* 23:1925–1932. <https://doi.org/10.1016/j.joca.2015.06.004>
16. Mancarella L, Addimanda O, Meliconi CC and R (2017) Synovial Inflammation Drives Structural Damage in Hand Osteoarthritis: a Narrative Literature Review. In: *Current Rheumatology Reviews*. <http://www.eurekaselect.com/145495/article>. Accessed 14 Nov 2019
17. Roux CH, Foltz V, Maheu E, et al MRI and serum biomarkers correlate with radiographic features in painful hand osteoarthritis. 8
18. Segal R, Avrahami E, Lebdinski E, et al (1998) The impact of hemiparalysis on the expression of osteoarthritis. *Arthritis & Rheumatism* 41:2249–2256. [https://doi.org/10.1002/1529-0131\(199812\)41:12<2249::AID-ART21>3.0.CO;2-O](https://doi.org/10.1002/1529-0131(199812)41:12<2249::AID-ART21>3.0.CO;2-O)

Tables/figures

Table 1. Baseline demographic and clinical characteristics (n=60)

Women	57 (95.0%)
Age, years	66.1 (7,6)
Body mass index, kg/m ²	24.0 (3,8)
Dominant hand (right-handed)	57 (95.0)
Visual analogue scale for pain [0-100] (mm)	64.9 (15.9)
Evaluator's global disease activity (mm)	61.7 (15.5)
Patient global disease activity (mm)	63.5 (14.1)
Joints with pain (DIP, PIP, and MCP joints of both hands [0-28])	10 [7 – 13]
Joints with nodes (DIP, PIP, and MCP joints of both hands [0-28])	8 [6 – 12.5]
Joints with swelling (DIP, PIP, and MCP joints of the dominant hand [0-28])	4 [2 – 6]
Cochin Hand Functional Scale [0 - 90]	25 [11.5-43.5]
Functional index for hand osteoarthritis (FIHOA) [0 – 30]	13 [8-17]

Data are presented as n (%) for dichotomous variables, mean (SD) for continuous demographic variables with normal distribution and median [25th - 75th percentiles] with non-normal distribution.

Table 2. The clinical features of the interphalangeal joints of the 1st–5th fingers

	Total (n=120)	Dominant hand (n=60)	Non-dominant hand (n=60)	*P value
DIP with pain	5 (3-6)	2.5(1 – 4)	2 (1 – 3)	0.172
PIP with pain	4 (2-5)	2 (1 – 3)	2 (1 – 3)	0.961
DIP with node	6 (4-8)	4 (2 – 4)	3 (1.25 - 4)	0.005
PIP with node	2 (0-5)	1 (0 – 3)	1 (0 – 3)	0.547
DIP with swelling	2.5 (1-4)	1 (0 - 2)	1 (0.25-2)	0.141
PIP with swelling	1 (0-2)	0 (0 - 1)	0 (0 - 1)	0.291

Data are presented as n (%) for dichotomous variables, mean (SD) for continuous demographic variables with normal distribution and median [25th - 75th percentiles] with non-normal distribution.

* We use the Wilcoxon signed-rank

Table 3. Verbruggen-Veys radiographic scores in the interphalangeal joints of the 1st-5th fingers

	Dominant hand (n=60)					Non-dominant hand (n=60)					*p-value
	N	S	J	E	R	N	S	J	E	R	
2nd DIP	6 (10)	20 (33.3)	1 (1.7)	19 (31.7)	14 (23.3)	8 (13.3)	14 (23.3)	2 (3.3)	24 (40)	12 (20)	0.682
3rd DIP	7 (11.7)	16 (26.7)	1 (1.7)	20 (33.3)	16 (26.7)	8 (13.3)	15 (25)	1 (1.7)	22 (36.7)	14 (23.3)	0.773
4th DIP	8 (13.3)	23 (38.3)	4 (6.7)	19 (31.7)	6 (10)	8 (13.3)	24 (40)	5 (8.3)	19 (31.7)	4 (6.7)	0.498
5th DIP	7 (11.7)	20 (33.3)	4 (6.7)	21 (35)	8 (13.3)	8 (13.3)	15 (25)	7 (11.7)	25 (41.7)	5 (8.3)	0.890
1st PIP	8 (13.3)	30 (50)	8 (13.3)	1 (1.7)	13 (21.7)	9 (15)	32 (53.3)	8 (13.3)	2 (3.3)	9 (15)	0.333
2nd PIP	20 (33.3)	26 (43.3)	1 (1.7)	8 (13.3)	5 (8.3)	16 (26.7)	24 (40)	1 (1.7)	9 (16.7)	10 (16.7)	0.045
3rd PIP	15 (25)	27 (45)	1 (1.7)	10 (16.7)	7 (11.7)	19 (31.7)	24 (40)	2 (3.3)	8 (13.3)	7 (11.7)	0.567
4th PIP	16 (26.7)	30 (50)	2 (3.3)	6 (10)	6 (10)	12 (40)	29 (48.3)	4 (6.7)	12 (20)	3 (5)	0.260
5th PIP	13 (21.7)	28 (46.7)	2 (3.3)	10 (16.7)	7 (11.7)	12 (40)	31 (51.7)	1 (1.7)	7 (11.7)	9 (15)	0.989
Total	100 (18.5)	220 (40.7)	24 (4.4)	114 (21.1)	82 (15.2)	100 (18.5)	208 (38.5)	31 (5.7)	128 (23.7)	73 (13.5)	

* We use the Wilcoxon signed-rank

The number (%) of affected joints is presented

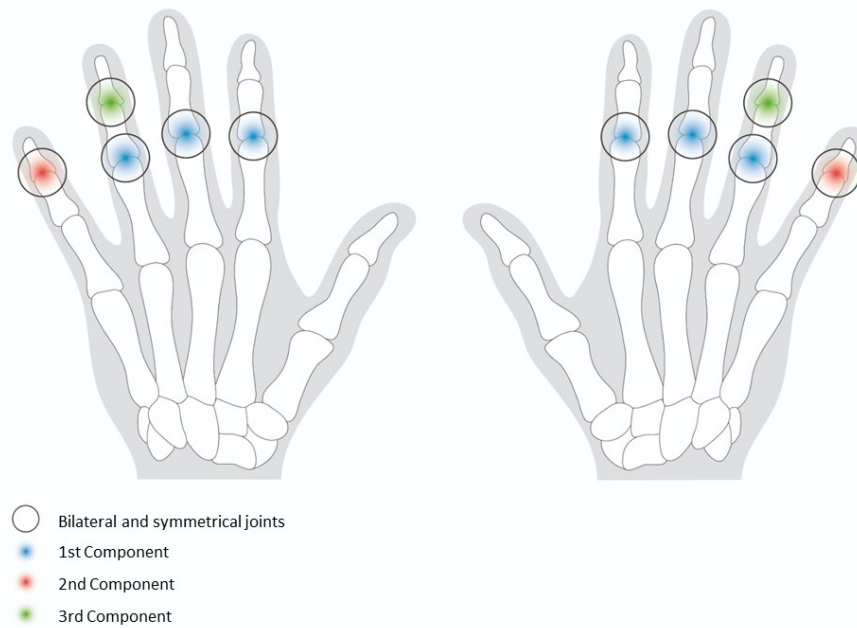
For VV score: N –Normal joint; S – Stationary phase, J - Joint space phase, E – Erosive phase R – Remodelling phase

Table 4. Principal component analysis after varimax rotation: Projections of the interphalangeal joints from Verbruggen-Veys radiographic score assessment on the eight retained components (n=60 patients).

	Components							
	1	2	3	4	5	6	7	8
2 nd DIP – Non-dominant hand								
3 rd DIP – Non-dominant hand						0.523		
4 th DIP – Non-dominant hand			0.882					
5 th DIP – Non-dominant hand		0.794						
1 st PIP – Non-dominant hand								0.909
2 nd PIP – Non-dominant hand	0.867							
3 rd PIP – Non-dominant hand	0.808							
4 th PIP – Non-dominant hand	0.753							
5 th PIP – Non-dominant hand								
2 nd DIP – Dominant hand							0.899	
3 rd DIP – Dominant hand					0.892			
4 th DIP – Dominant hand			0.714					
5 th DIP – Dominant hand		0.808						
1 st PIP – Dominant hand						0.905		
2 nd PIP – Dominant hand	0.532							
3 rd PIP – Dominant hand	0.677							
4 th PIP – Dominant hand	0.593							
5 th PIP – Dominant hand				0.822				
Variance (%)	37.2	11.8	7.8	6.3	5.4	5.1	4.5	3.5
Cumulative variance (%)	37.2	49.0	56.8	63.1	68.6	73.7	78.1	81.7

These results illustrate the relationship between variables with the components of the principal component analysis. Only projections with a value greater than 0.50 on a component are presented.

Figure 1. Projections of the interphalangeal joints from Verbruggen-Veys radiographic score assessment on the first three components on the eight retained components (n=60 patients)



Legend: These results illustrate the relationship between variables with the first three components of the principal component analysis after varimax rotation. Only projections with a value greater than 0.50 on a component are presented. We use the same colour by component (blue for first, red for second and green for third). We use circles to identify bilateral and symmetrical joints in the same component.