



**HAL**  
open science

## Frontal lobe seizures: overview and update

Aileen Mcgonigal

► **To cite this version:**

Aileen Mcgonigal. Frontal lobe seizures: overview and update. Journal of Neurology, 2022, 10.1007/s00415-021-10949-0 . hal-03522890

**HAL Id: hal-03522890**

**<https://hal.science/hal-03522890>**

Submitted on 12 Jan 2022

**HAL** is a multi-disciplinary open access archive for the deposit and dissemination of scientific research documents, whether they are published or not. The documents may come from teaching and research institutions in France or abroad, or from public or private research centers.

L'archive ouverte pluridisciplinaire **HAL**, est destinée au dépôt et à la diffusion de documents scientifiques de niveau recherche, publiés ou non, émanant des établissements d'enseignement et de recherche français ou étrangers, des laboratoires publics ou privés.

# Frontal lobe seizures: overview and update

<sup>1,2</sup>Aileen McGonigal

<sup>1</sup>APHM, Timone Hospital, Clinical Neurophysiology, Marseille, France

<sup>2</sup>Aix Marseille Univ, Inserm, INS, Institut de Neurosciences des Systèmes, Marseille, France

[aileen.mcgonigal@univ-amu.fr](mailto:aileen.mcgonigal@univ-amu.fr)

<https://orcid.org/0000-0001-6775-5318>

Abstract word count : 201

Main text : 2999

## Abstract

Frontal lobe seizures (FLS) are debilitating for patients, highly diverse and often challenging for clinicians to evaluate. Frontal lobe epilepsy is the second most common localization for focal epilepsy, and if pharmaco-resistant, can be amenable to resective surgery. Detailed study of frontal seizure semiology in conjunction with careful anatomical and electrophysiological correlation based on intracerebral recording with stereoelectroencephalography (SEEG) has allowed demonstration that ictal motor semiology reflects a hierarchical rostro-caudal axis of frontal lobe functional organization, thus helping with presurgical localization. Main semiological features allowing distinction between different frontal sublobar regions include motor signs and emotional signs. Frontal lobe seizure semiology also represents a valuable source of *in vivo* human behavioral data from a neuroscientific perspective.

Advances in defining underlying etiologies of FLE are likely to be crucial for appropriate selection and exploration of potential surgical candidates, which could improve upon current surgical outcomes. Future research on investigating the genetic basis of epilepsies and relation to structural substrate (e.g. focal cortical dysplasia) and seizure organization and expression, could permit a “genotype-phenotype” approach that could be complementary to anatomical electroclinical correlations in better defining the spectrum of FLS. This could help with optimizing patient selection and prognostication with regards to therapeutic choices.

## Keywords

Frontal lobe, seizure semiology, SEEG, behavior, rostro-caudal, epilepsy surgery

## Introduction

Frontal lobe seizures (FLS) are still considered among the most difficult for clinicians[57]. The challenges lie in the complexity and heterogeneity of their clinical expression, or *semiology*, as well as in typically rapid spread of electrical discharge that often makes surface electroencephalography (EEG) difficult to interpret. This is in contrast to mesial temporal seizures, for example, which can be characterized within a much more limited semiological and electrophysiological repertoire[50, 51]. Knowledge of how seizure semiology correlates with cortical seizure organization is important from a clinical point of view, with regards to correct diagnosis (e.g., distinguishing FLS from psychogenic non-epileptic seizures or extra-frontal epileptic seizures) and localization (i.e. formulating hypotheses of sublobar localization). Frontal lobe epilepsy is the second most common partial epilepsy after temporal lobe epilepsy (TLE) and, if focal and pharmaco-resistant, may be successfully treated by resective surgery[32]. Clues to cortical localization are indeed crucial when dealing with presurgical evaluation of pharmaco-resistant frontal lobe epilepsy (FLE), and analysis of seizure semiology is a main data source in this regard[20]. Despite the diversity and challenges of FLS, careful electroclinical correlations using intracerebral exploration with stereoelectroencephalography (SEEG) have revealed certain organizational principles of electroclinical expression at group level. These can help to orientate towards greater or lesser likelihood of sublobar frontal localizations for semiological patterns in individual patients. However, more work is needed to further elucidate how seizure onset and spread map onto to behavioral expression, and vice versa.

This article will review some aspects of frontal seizures, as studied using stereoelectroencephalography (SEEG), focusing on semiology. The possible role of specific etiologies, especially genetic ones, in clinical seizure expression will also be mentioned, as well as briefly reviewing data on outcome following surgery for FLE.

## Frontal lobe seizure semiology and neural correlates

Semiology is the clinical expression of seizure electrical activity. Both seizure onset and propagation phases of the discharge contribute to semiological expression; these are tightly linked and depend on underlying connectivity of the involved epileptogenic networks[10].

Observations of frontal lobe seizures are amongst the oldest reported cases in the literature. Seizures arising from pre-central regions, together with their underlying anatomical and physiological organization, were extensively described since the end of the 19th century (i.e., long before the EEG era)[38, 40, 67]. Once EEG recording became available from the 1930's onwards, much more detailed correlations of precentral and premotor seizure expression could be made; it should be noted however that these early electroclinical correlations tended to reflect data from cortical stimulation and intraoperative recording, rather than spontaneous seizures[2, 59]. Later, subdural grid explorations provided additional information, notably about the role of supplementary motor area in seizure organization[15]. A major advance came with the development of the stereoelectroencephalography (SEEG) method in France from the 1960's onwards, since this allowed placement of multiple depth electrodes and provided a method for dynamically correlating clinical phenomena with both electrical and anatomical data, throughout the course of the seizure[5]. SEEG data allowed simultaneous exploration of mesial and lateral surfaces of frontal cortex, thus refining knowledge of motor cortex seizures[21, 28]. Importantly, SEEG allowed the complexities of prefrontal seizure expression to start to be investigated, comparing semiology and neural correlates[27]. Amongst the many semiological features of FLS, motor signs and emotional signs may be particularly helpful in orienting towards possible sublobar localization and each will be briefly discussed below.

#### Motor semiology

Motor semiology can be broadly divided into *elementary motor signs* (e.g. clonic jerks, tonic signs, version) and *complex motor behavior*, referring to any more complex pattern of movement, usually involving gestures (Figure 1). While elementary motor signs are relatively straightforward for clinicians to recognize, describe and categorize, complex motor behavior as a feature of FLS may occur in very diverse and often idiosyncratic patterns (although habitually is fairly stereotyped for each patient). Frontal seizure discharges typically spread extremely rapidly within the brain, due to frontal lobe long and short-range connectivity patterns[7, 24] (Figure 2); these varied, fast propagation patterns contribute to the diverse and sometimes explosive appearance of ictal behavioral change, with many signs occurring almost simultaneously (in contrast to the generally slow progression of mesial temporal seizures for example)[44]. Thus, the spectrum of potential

semiological expressions of FLS is vast, and complex ictal behaviors provide particular challenges for clinician observers in observing, identifying and categorizing signs, especially for relatively inexperienced practitioners[65]. In addition, localizing value of surface EEG in FLE is often poor, especially in mesial frontal organization[16]. These combined difficulties in both clinical and EEG observations even led some previous authors to conclude that localization of semiological patterns in prefrontal seizures was not feasible[51].

However, a large series of 54 FLE patients explored with SEEG allowed identification of clusters of semiological signs that mapped onto clusters of brain regions involved in early seizure organization[20]. The most anterior regions of the prefrontal cortex were associated with the most naturalistic or “integrated” motor behaviors, with no concurrent elementary motor signs. Moving caudally, posterior regions of prefrontal cortex often showed co-involvement with anterior premotor cortex, characterized by a combination of elementary motor signs and complex motor behavior that looked more “unnatural” or “non-integrated”, often somehow hindered or fragmented by concurrent tonic/dystonic posturing that tended to involve axial and/or proximal body segments. The posterior premotor and precentral cases in our series (i.e., involving only the most caudal parts of frontal lobe, without prefrontal involvement) had only elementary motor signs with no complex motor behavior. While focal patterns limited to precentral cortex (Rolandic seizures[26]) or premotor cortex could occur, SEEG electrical patterns more often arose in both precentral and premotor structures, with varying combinations of lateral and mesial involvement [21, 26]. A general rule for more anterior premotor and prefrontal seizures was that seizure discharge more often projected from lateral to medial frontal structures than the reverse, with the medial premotor structures and anterior cingulate gyrus respectively representing a sort of “final common pathway”. This series demonstrated that a rostro-caudal gradient exists with regards to cortical regions associated with different patterns of FLS motor semiology, in keeping with current neuroscientific models of frontal lobe organization (Figure 3; see also Table 1)[4, 37]. This rostro-caudal gradient reflected both type of motor semiology (elementary motor signs, complex motor behavior, or both) and, to some degree, body segment involved (proximal versus distal) (Table 1).

Building on these observations of complex motor behavior patterns, a subsequent study of repetitive and sometimes rhythmic motor behaviors occurring during FLS, characterized as ictal “stereotypies”[31], showed that more distal stereotypies involving hands and feet were

associated with more anterior prefrontal localizations, while stereotypies involving more proximal/axial body segments (e.g. shoulders, pelvis, trunk) occurred with more posterior prefrontal involvement[55]. Interestingly, not only anatomical localization but also temporal features of seizure discharge appear to play a role in patterns of repetitive, rhythmic motor behaviors during FLS. For example, quantified frequency of axial rocking movements (stereotypies)[39] were compared to concomitant SEEG rhythmic changes and showed that these were time-locked to the rocking frequency, measured via phase amplitude coupling between gamma and delta (rocking frequency) bands[76]. This suggests that temporal patterns of behavior depend upon temporal features of cerebral electrical activity, and is an example of how not only spatial (anatomical) but also temporal aspects of electrical seizure discharge and behavioral expression are intertwined[53].

Thus, while challenges certainly remain at the level of individual patients' semiology, these observations from group level show that clear anatomical electroclinical correlations do exist in FLS, which can assist in orienting towards certain frontal sublobar regions along an antero-posterior axis. This lends weight to the use of seizure semiology as a behavioral data source that can not only give clinical clues as to cerebral organization of seizures but could also help shed light on some aspects of cerebral function that remain relatively poorly known in humans. Some ictal features such as altered consciousness and hyperkinetic motor behavior frequently occur during prefrontal seizures but are not associated with specific localizations within prefrontal cortex (and also occur in extra-frontal seizures). This highlights the importance of looking at clusters of associated signs rather than isolated features both when assessing individual seizures and investigating anatomical electroclinical correlations in case series. Ideally, future work should study even larger case series to compensate for the heterogeneity of the FLS clinical spectrum and to further refine sublobar brain-behavior correlations, as well as looking in more detail at differences between patterns of motor behavior between FLS and other seizure onset localizations, such as parietal and temporal lobe[34]. This is important given tight connectivity between frontal and extra-frontal structures (Figure 2), and the fact that seizures from extra-frontal regions can manifest motor patterns that may reflect altered connectivity to frontal regions during seizure spread[36] (see also Figure 3 for illustration of reciprocal frontal-parietal connections).

## Emotional semiology

Another characteristic aspect of prefrontal seizure semiology is ictal emotional behavioral change, with or without reported subjective emotional feeling. This reflects the key role of frontal cortex in emotion perception and expression[6, 47], although how exactly seizure discharge interacts with emotional systems to produce clinical phenomena remains poorly understood. Through SEEG observations of explosive onset of emotionally-charged behavior during FLS (hyperkinetic motor behavior with attempts to escape/attack, screaming, swearing, frightened face), it was noted that sudden, transient desynchronization at seizure onset produced decoupling of orbitofrontal cortex and amygdala[12], which was hypothesized as possibly removing the usual cortical control over subcortical emotional systems[58]. Emotional behaviors may occur in seizures arising from various cortical localizations, or indeed subcortical localizations, since laughing and crying (gelastic and dacrystic seizures, respectively) have been reported in hypothalamic hamartoma-related seizures[45]. However, from series comparing semiological patterns associated with different cortical epilepsy localizations explored with SEEG, objective emotional behaviors are more prevalent in prefrontal seizures compared to temporal[50], insular[73] or posterior cortex seizures[8, 52], and were absent in frontal seizures without prefrontal cortical involvement[20]. In a study of temporal lobe seizures, emotional behaviors with a hyperkinetic character were associated with prefrontal cortex propagation[71]. Up to half of patients with prefrontal epileptic seizures present some form of ictal emotional symptom or sign[20, 49].

The most commonly observed ictal emotional behaviors (across all cortical seizure localizations, but especially prefrontal) are negatively valenced and suggestive of threat detection/defense behaviors[17, 61, 70]. The commonest FLS emotional symptom is feeling of fear at seizure onset (i.e., aura), as noted in around 40% of a series of 42 patients with prefrontal seizures explored with SEEG (Singh et al, in preparation). The commonest objective emotional sign in FLS is anxious or fearful facial expression (observed in around 20%), with full-blown threat response behaviors occurring in around 10% (Singh et al, in preparation). Interestingly, these appear to occur within a spectrum of emotional behavioral intensity, from fearful facial expression +/-freezing (behavioral arrest); to defense-type gestures of raising the arms/hand in front of the face or burying the face in the pillow; to explosive onset of hyperkinetic motor behavior with attempts to escape or to fight. This



suggestion of a scaled response to threat could be in keeping with observations from affective neuroscience studies of animal models[1, 48]. In prefrontal seizures with apparent fear/anxiety (especially feeling of fear, anxious/fearful facial expression and defense posture of upper limbs), data so far indicate a main role for ventromesial prefrontal cortex and especially posterior orbitofrontal cortex with mesial temporal (amygdala +/- temporal pole) co-involvement[20, 61] though seizures arising from dorsolateral prefrontal cortex may produce violent defense and/or aggressive behaviors[9, 29].

Rarely, ictal prosocial emotional behaviors can be observed in FLS, in which patients may appear jovial with a happy facial expression, interact socially in a friendly or playful manner with the examiner, and often have humming or singing automatisms with rhythmic body movements[20]. From the limited number of electroclinical observations available, this type of pattern is associated with seizure involvement of the most anterior parts of frontal cortex (frontal pole, anterior cingulate, anterior orbitofrontal cortex)[20]; the occurrence of singing or humming may be associated with specific patterns of coherence between frontal lobe and temporal lobe components of the seizure discharge[11, 13]. In our experience, ictal prosocial behavior of this type appears fairly specific for anterior prefrontal involvement and is clearly different in character from the mechanical and sometimes mirthless character of laughter seen in gelastic seizures[3].

### Frontal seizures and genetics

Interesting recent developments in understanding of FLS (and amongst focal seizures more generally) have come from advances in genetics. Frontal lobe epilepsy was one of the first to have a specific genetic syndrome identified, autosomal dominant nocturnal frontal lobe epilepsy (ADNFLE)[62]. This phenotype had brief clusters of sleep-related seizures characterized by hyperkinetic and tonic (especially dystonic) motor features, and often vocalization[63]. In fact, ADNFLE was the likely diagnosis in some cases previously described as “nocturnal paroxysmal dystonia”, an entity considered to overlap with parasomnias[60]. In electroclinical terms, ADNFLE could be considered as part of the larger spectrum of the previously termed “nocturnal frontal lobe epilepsies (NFLE)”, many of which have confirmed frontal lobe localizations on intracerebral EEG (e.g. orbitofrontal cortex, anterior cingulate, supplementary motor area) and good outcome following surgery. It has since been

proposed to change the terminology of this broader group to “Sleep-Related Hypermotor Epilepsies (SHE)”, reflecting the fact that similar seizure phenotypes may also arise from extra-frontal localizations including insula[35].

A recently described group of genetic causes of focal epilepsies that can cause sleep-related frontal seizures amongst other clinical presentations display disruption of the mammalian Target of Rapamycin Receptor (mTOR) signaling pathway implicated in cell growth and proliferation. The most described so far are mutations of DEPDC5, which are associated with malformations of cortical development and epilepsy[30, 64], with a majority of cases published so far involving frontal lobes [14, 64]. The associated malformations of cortical development described in association with DEPDC5 include FCD types I and II, and band heterotopia[14, 64]. In patients with pharmaco-resistant focal epilepsy with confirmed FCD in the context of a DEPDC5 mutation (whether visible on MRI or not), good surgical outcome has been reported[14]. Such cases can be regarded within a larger spectrum of “mTORopathies”, which include other genetic abnormalities associated with focal epilepsies and cortical malformations, such as NPRL2 and NPRL3[74]. Thus, the “genetic landscape of focal cortical dysplasia” in focal epilepsies is becoming increasingly defined: at the time of writing, 9 genes have been found to cause canonical FCD type II[18]. Frontal lobe, particularly superior frontal sulcus and frontal pole, is a common FCD location, especially type IIA and IIB, in which associated focal epilepsies may have favorable surgical outcome[72]. While genetic profile may underlie susceptibility to seizure recurrence after surgery in some cases[42, 46], on the other hand the specific “mTORopathies” (e.g. DEPDC5, NPRL3) appear so far not to confer poorer outcome if an FCD-related focal epilepsy can be delineated and surgically treated, including in frontal lobe epilepsies. These developments in defining genetic profiles associated with clinical and pathological abnormalities highlights the interest of pursuing identification of “molecular signatures” of different focal epilepsy syndromes, that may ultimately help drive treatment decisions based on more informed prognostication[42, 66].

### Seizure outcomes following frontal lobe surgery

Around 30% of focal epilepsies are pharmaco-resistant[75]. Patterns of referral for epilepsy presurgical evaluation have changed in most world centers over the past decade, with

increasing proportions of extratemporal epilepsies including FLE[43], up to 20-40% of which may be “MRI-negative”[54]. Significant diversity exists for seizure freedom rates following FLE surgery, with overall around 45% achieving seizure-freedom (Engel Class 1) in a meta-analysis of 21 studies[32], varying across centers according to case selection, method of intracranial exploration, etiology and completeness of resection of the epileptogenic zone[19, 22, 41]. Outcome appears to be particularly good for surgical treatment for frontal epilepsies related to type II focal cortical dysplasia (FCD)[72], as long as the associated epileptogenic zone can be correctly localized and fully resected[22, 33, 54, 56]; satisfactory outcome in this scenario is possible even if the FCD is not visible on standard MRI[25, 54]. This highlights the importance of etiology in determining outcome of epilepsy surgery[42], since MRI-negative cases that are due to more diffuse type I FCD or that are “cryptogenic” appear to have poorer outcome than those with histologically confirmed FCD type II[69]. The method of intracranial exploration also seems to affect ultimate surgical outcome at least for MRI-negative FLE, with SEEG series showing better results than subdural grids[19, 41].

Given that significant numbers of patients with pharmaco-resistant FLE are not surgical candidates (e.g. because of functional cortical involvement or bilateral organization of seizures), there is growing interest in intracranial neuromodulation methods, including deep brain stimulation (e.g., open loop stimulation of anterior nucleus of the thalamus) and responsive neurostimulation, RNS (closed loop, on-demand stimulation to specific cortical region based on seizure detection)[68]. As knowledge and experience increase, these methods may become better tailored to individual patients in terms of anatomical target and stimulation parameters and may eventually supersede surgery in some cases.

## Conclusion

Frontal lobe seizures are highly diverse and challenging. Will a stage ever be reached where better knowledge of semiology allows purely non-invasive approaches to be used for surgical decision making in FLE, or is the is the interconnectivity of the frontal lobes inherently so multifaceted that we shall not reach that point? There are 3 main related issues here, as mentioned earlier: (1) heterogeneity of frontal lobe seizure semiology, at least for seizures with prefrontal involvement; (2) lack of specificity for some FLS semiologic

patterns; (3) complex and dense connectivity of frontal lobes. The question of lack of semiologic specificity remains a real problem, since in some cases a given pattern of motor behaviour could potentially arise from either a frontal or an extra-frontal (parietal, insular, or temporal) localisation, or from their co-involvement, because of the tight connections between these structures and their efferent outflow. This certainly limits the power of semiology as a “stand alone” data source at the individual patient level in some scenarios and highlights the need for combining multi-modal data (as we do in clinical practice) to help refine the hypothesis. However, new technology could allow advances. If we accept that semiology is linked to cortical organisation of seizures, then with larger data sets (ideally comprising thousands of seizures), real progress could be made in refining ability to recognise certain patterns (clusters) of signs as indicating probability of certain sublobar regions or structures being involved. Access to large-scale labelled seizure video databases, development of which is possible, though not without challenges, could allow artificial intelligence approaches to be used, which could potentially greatly accelerate our understanding of semiologic patterns and their cerebral correlates (Hou et al, submitted). In addition, as well as trying to better understand brain-behavior relations in FLE, future work will focus on investigating the genetic basis of epilepsies and relation to both structural substrate (e.g. focal cortical dysplasia) and to seizure organization and expression, thus not only analyzing anatomical electroclinical correlations but also linking this to a “genotype-phenotype” approach. An interesting question for example would be whether specific genotypes influence semiological expression, independent of cortical localization of associated FCD. This line of questioning reflects a multi-scale framework, encompassing multiple linked aspects of epilepsy from the behavioral to the molecular level (Figure 4).

#### Statements and declarations

No competing interests to declare. No funds, grants, or other support was received.

#### Acknowledgements

I thank Prof Patrick Chauvel, University of Pittsburgh Medical Center, USA. Many thanks to Prof Fabrice Bartolomei, Dr Francesca Bonini, Dr Bernard Giusiano and colleagues of the Clinical Neurophysiology department, Timone Hospital, Marseille, France. Thanks to Dr Rinki

Singh, Kings College, London. Many thanks to Prof Marco Catani (Kings College, London) and to Prof Joaquin Fuster (UCLA) for kind permission to reproduce figures.

**Table 1**

<b>Anatomical structure</b>	<b>Functional role in representing and integrating human movement[37]</b>	<b>Examples of frontal seizure semiology[20]</b>
Precentral cortex	Movements controlled by muscles and muscle groups	Clonic jerks, simple tonic posture
Premotor cortex	Movements defined by current trajectory and immediate goal	Proximal tonic posture (symmetric/asymmetric), head/eye version; axial/proximal complex motor behavior (e.g. reaching, ballistic movements) if co-involvement of posterior prefrontal cortex
Prefrontal cortex	Temporally integrated goal-directed action and behavior	More complex patterns of gestural motor behavior, which may have an integrated (naturalistic) appearance, sometimes with associated emotional features; altered level of awareness +/- vocalization common. Distal > proximal stereotypies (e.g. hand tapping) associated with more anterior prefrontal structures

**Table 1.** Hierarchical functional organization of frontal lobes along a rostro-caudal gradient is reflected in observed patterns of frontal lobe seizure semiology (especially motor features) and relation to cortical seizure organization measured using stereoelectroencephalography (SEEG).

**Figure 1.** Frontal lobe seizure (FLS) semiology, especially in terms of motor features, is correlated with cortical organization of electrical seizure onset and early propagation. This can be represented as a spatial hierarchy along a rostro-caudal (antero-posterior) axis, in which elementary motor signs are associated with primary (and supplementary) motor regions and increasingly complex motor behaviors occur with progressively more anterior prefrontal seizure organization. Ictal motor features can be divided into elementary motor signs (e.g., clonic jerks, tonic or dystonic posturing, head and/or eye version) and complex motor behavior (any movement pattern more elaborate than elementary signs). Complex motor behaviors may have a hyperkinetic character or not, may involve abnormally repetitive movements (stereotypies), and are frequently associated with altered contact, vocalization, autonomic signs and sometimes emotional expression. Elementary and complex motor signs may co-exist when co-involvement of premotor and prefrontal cortical regions occurs.

**Figure 2.** Frontal lobes are characterized by complex long and short cortical and subcortical connectivity. This gives rise to rapid and widespread propagation of seizure discharges and helps explain the rapid evolution of complex clinical signs as well as the rich semiological repertoire of FLS. The main frontal lobe regions and their association and projection pathways are shown here. The frontal lobe communicates with subcortical structures through descending and ascending projection pathways, indicated by dashed black lines. The association pathways establish direct connections among frontal areas (intralobar tracts indicated by white lines) or between frontal and extra-frontal cortical regions within the same hemisphere (interlobar fibers). The latter can be further subdivided into short U-shaped interlobar (white dashed lines) and long interlobar (black lines) fibers. Reproduced with permission from Catani, 2019[23]. Frontal projection tracts: TP, thalamic projections; DPS, descending projection system. Association interlobar: SLF, superior longitudinal

fasciculus I, II, II; AF, arcuate fasciculus, long segment; UF, uncinata fasciculus; IFOF, inferior fronto-occipital fasciculus; CB, cingulum bundle. Association intralobar: FSL/FIL, frontal superior/inferior longitudinal tracts; FAT, frontal aslant tract; FOP, frontal orbitopolar tract; FPC, frontal paracingulate tract. Association short U-shaped: perirolandic U-fibers; FIT, fronto-insular tracts; CUF, cingulate U-fibers; PUF, precentral U-fibers; FMT, fronto-marginal tract.

**Figure 3.** Demonstration of a rostrocaudal gradient of anatomical electroclinical correlations in FLS is in keeping with current neuroscientific thinking on the hierarchical model of cognitive and motor control. This figure illustrates highlights the reciprocal connectivity between posterior and frontal cortices along this gradient. Reproduced with permission from Fuster 2004[37].

**Figure 4.** Considering epilepsy as a disorder of brain networks, in which a seizure may be seen as an expression of a dynamical system, seizure semiology reflects a dynamic process operating on a different spatiotemporal scale from the cerebral electrical discharge, within the cognitive and behavioral domains. Attempts to understand correlations between brain activity and clinical signs during seizures must therefore take into account information collected across multiple scales: behavioral features, anatomical spread of seizure discharge and temporal organization of electrical changes (e.g., discharge frequency and synchrony between structures). Adapted and reproduced with permission from McGonigal et al. 2021[53].



Figure 1

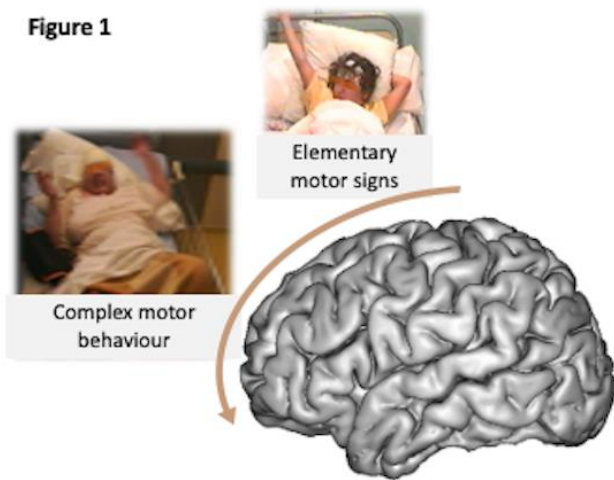


Figure 2

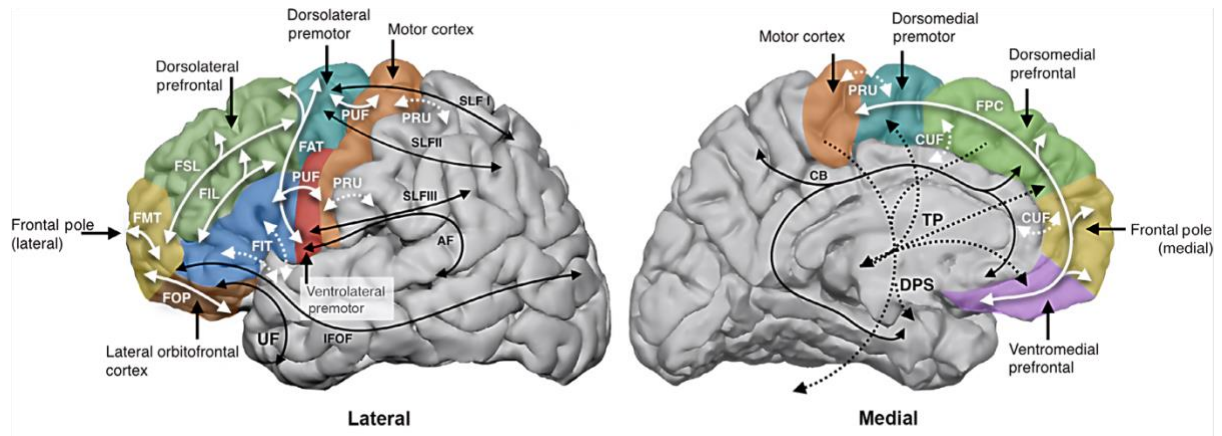


Figure 3

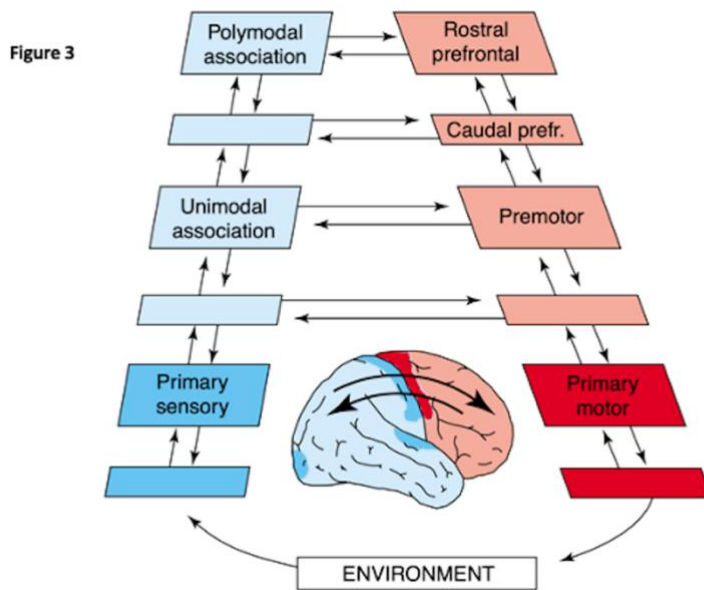
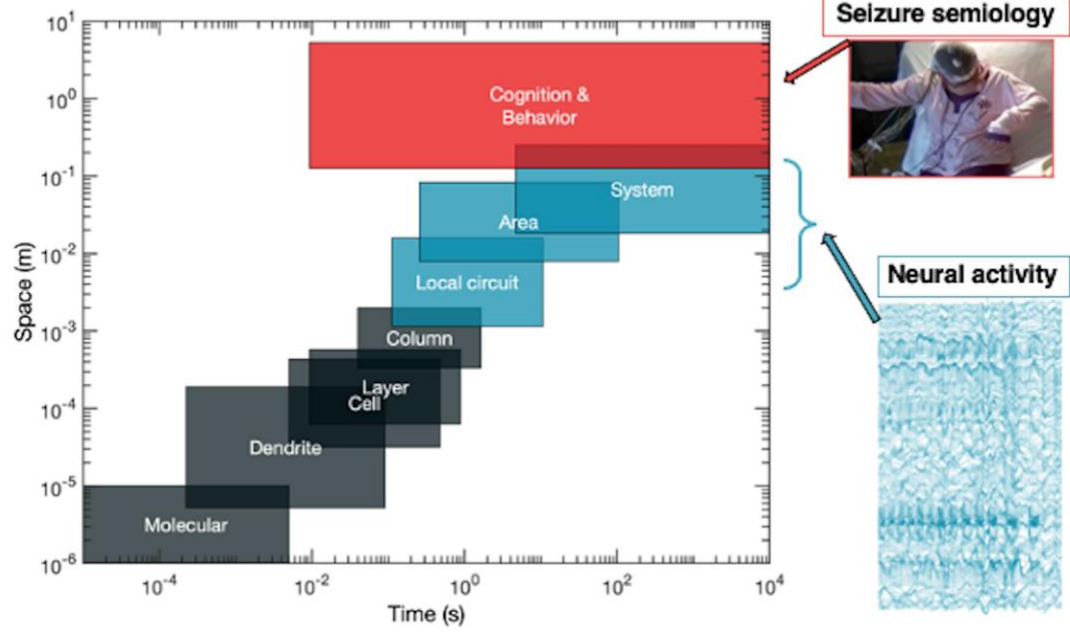


Figure 4



1. Adolphs R, Anderson DJ (2018) *The neuroscience of emotion: A new synthesis*. Princeton University Press
2. Ajmone-Marsan C, Goldhammer L (1973) Clinical ictal patterns and electrographic data in cases of partial seizures of frontal-central-parietal origin. *Epilepsy: Its Phenomena in Man*:235-258
3. Arroyo S, Lesser RP, Gordon B, Uematsu S, Hart J, Schwerdt P, Andreasson K, Fisher RS (1993) Mirth, laughter and gelastic seizures. *Brain* 116:757-780
4. Badre D, D'Esposito M (2009) Is the rostro-caudal axis of the frontal lobe hierarchical? *Nat Rev Neurosci* 10:659-669
5. Bancaud J, Talairach J (1965) *La stéréo-électroencéphalographie dans l'épilepsie: informations neurophysiopathologiques apportées par l'investigation fonctionnelle stéréotaxique*. Masson et Cie, Paris
6. Barbas H, García-Cabezas M (2017) Prefrontal cortex integration of emotion and cognition. In: Watanabe M (ed) *The Prefrontal Cortex as an Executive, Emotional, and Social Brain*. Springer Japan, Tokyo, pp 51–76
7. Barbas H, Pandya DN (1989) Architecture and intrinsic connections of the prefrontal cortex in the rhesus monkey. *J Comp Neurol* 286:353-375
8. Bartolomei F, Gavaret M, Hewett R, Valton L, Aubert S, Régis J, Wendling F, Chauvel P (2011) Neural networks underlying parietal lobe seizures: a quantified study from intracerebral recordings. *Epilepsy Res* 93:164-176
9. Bartolomei F, Lagarde S, Lambert I, Trébuchon A, Villalon SM, McGonigal A, Benar CG (2017) Brain connectivity changes during ictal aggression (a strangulation attempt). *Epileptic Disorders* 19:367-373
10. Bartolomei F, Lagarde S, Wendling F, McGonigal A, Jirsa V, Guye M, Bénar C (2017) Defining epileptogenic networks: Contribution of SEEG and signal analysis. *Epilepsia*
11. Bartolomei F, McGonigal A, Guye M, Guedj E, Chauvel P (2007) Clinical and anatomic characteristics of humming and singing in partial seizures. *Neurology* 69:490-492
12. Bartolomei F, Trébuchon A, Gavaret M, Régis J, Wendling F, Chauvel P (2005) Acute alteration of emotional behaviour in epileptic seizures is related to transient desynchrony in emotion-regulation networks. *Clin Neurophysiol* 116:2473-2479
13. Bartolomei F, Wendling F, Vignal JP, Chauvel P, Liégeois-Chauvel C (2002) Neural networks underlying epileptic humming. *Epilepsia* 43:1001-1012
14. Baulac S, Ishida S, Marsan E, Miquel C, Biraben A, Nguyen DK, Nordli D, Cossette P, Nguyen S, Lambrecq V (2015) Familial focal epilepsy with focal cortical dysplasia due to DEPDC 5 mutations. *Annals of neurology* 77:675-683

15. Baumgartner C, Flint R, Tuxhorn I, Van Ness P, Kosalko J, Olbrich A, Almer G, Novak K, Luders H (1996) Supplementary motor area seizures Propagation pathways as studied with invasive recordings. *Neurology* 46:508-511
16. Bautista RED, Spencer DD, Spencer SS (1998) EEG findings in frontal lobe epilepsies. *Neurology* 50:1765-1771
17. Biraben A, Taussig D, Thomas P, Even C, Vignal JP, Scarabin JM, Chauvel P (2001) Fear as the main feature of epileptic seizures. *J Neurol Neurosurg Psychiatry* 70:186-191
18. Blumcke I, Budday S, Poduri A, Lal D, Kobow K, Baulac S (2021) Neocortical development and epilepsy: insights from focal cortical dysplasia and brain tumours. *The Lancet Neurology* 20:943-955
19. Bonini F, McGonigal A, Scavarda D, Carron R, Régis J, Dufour H, Péragut J-C, Laguitton V, Villeneuve N, Chauvel P (2018) Predictive factors of surgical outcome in frontal lobe epilepsy explored with stereoelectroencephalography. *Neurosurgery* 83:217-225
20. Bonini F, McGonigal A, Trébuchon A, Gavaret M, Bartolomei F, Giusiano B, Chauvel P (2014) Frontal lobe seizures: From clinical semiology to localization. *Epilepsia* 55.2 264-277
21. Bonini F, McGonigal A, Wendling F, Régis J, Scavarda D, Carron R, Chauvel P, Bartolomei F (2013) Epileptogenic networks in seizures arising from motor systems. *Epilepsy Res*
22. Cardinale F, Rizzi M, Vignati E, Cossu M, Castana L, d’Orio P, Revay M, Costanza MD, Tassi L, Mai R, Sartori I, Nobili L, Gozzo F, Pelliccia V, Mariani V, Russo GL, Francione S (2019) Stereoelectroencephalography: retrospective analysis of 742 procedures in a single centre. *Brain* 142:2688-2704
23. Catani M (2019) The anatomy of the human frontal lobe. *Handbook of clinical neurology* 163:95-122 %@ 0072-9752
24. Catani M, Dell’Acqua F, Vergani F, Malik F, Hodge H, Roy P, Valabregue R, Thiebaut de Schotten M (2012) Short frontal lobe connections of the human brain. *Cortex* 48:273-291
25. Chassoux F, Devaux B, Landré E, Turak B, Nataf F, Varlet P, Chodkiewicz J-P, Dumas-Duport C (2000) Stereoelectroencephalography in focal cortical dysplasia A 3D approach to delineating the dysplastic cortex. *Brain* 123:1733-1751
26. CHAUVEL, #160, P., TROTTIER, S., VIGNAL, P. J, BANCAUD, J. (1992) Somatomotor seizures of frontal lobe origin. Lippincott - Raven, Philadelphia, PA, ETATS-UNIS
27. Chauvel P, Kliemann F, Vignal JP, Chodkiewicz JP, Talairach J, Bancaud J (1995) The clinical signs and symptoms of frontal lobe seizures. Phenomenology and classification. *Adv Neurol* 66:115-125; discussion 125-116
28. Chauvel P, Trottier S, Vignal JP, Bancaud J (1992) Somatomotor seizures of frontal lobe origin. *Adv Neurol* 57:185-232

29. Di Giacomo R, Didato G, Belcastro V, Deleo F, Pastori C, Arnaldi D, Rosa GJ, Villani F (2021) Rage and aggressive behaviour in frontal lobe epilepsy: description of a case and review of the mechanisms of aggressive behaviour in epilepsy and dementia. *Epileptic disorders* 23:419-425
30. Dibbens LM, De Vries B, Donatello S, Heron SE, Hodgson BL, Chintawar S, Crompton DE, Hughes JN, Bellows ST, Klein KM (2013) Mutations in DEPDC5 cause familial focal epilepsy with variable foci. *Nature genetics* 45:546-551
31. Edwards MJ, Lang AE, Bhatia KP (2012) Stereotypies: a critical appraisal and suggestion of a clinically useful definition. *Mov Disord* 27:179-185
32. Englot DJ, Wang DD, Rolston JD, Shih TT, Chang EF (2012) Rates and predictors of long-term seizure freedom after frontal lobe epilepsy surgery: a systematic review and meta-analysis: Clinical article. *Journal of neurosurgery* 116:1042-1048
33. Fauser S, Bast T, Altenmüller D-M, Schulte-Mönting J, Strobl K, Steinhoff BJ, Zentner J, Schulze-Bonhage A (2008) Factors influencing surgical outcome in patients with focal cortical dysplasia. *Journal of Neurology, Neurosurgery & Psychiatry* 79:103-105
34. Fayerstein J, McGonigal A, Pizzo F, Bonini F, Lagarde S, Braquet A, Trébuchon A, Carron R, Scavarda D, Julia S (2020) Quantitative analysis of hyperkinetic seizures and correlation with seizure onset zone. *Epilepsia* 61:1019-1026
35. Ferri L, Bisulli F, Mai R, Licchetta L, Leta C, Nobili L, Mostacci B, Pippucci T, Tinuper P (2017) A stereo EEG study in a patient with sleep-related hypermotor epilepsy due to DEPDC5 mutation. *Seizure* 53:51-54
36. Fonti D, Lagarde S, Pizzo F, Aboubakr W, Benar C, Giusiano B, Bartolomei F (2021) Parieto-Premotor functional connectivity changes during parietal lobe seizures are associated with motor semiology. *Clinical Neurophysiology* 132:1388-2457
37. Fuster JM (2004) Upper processing stages of the perception–action cycle. *Trends in cognitive sciences* 8:143-145
38. Gowers WR (1901) *Epilepsy and other chronic convulsive diseases: their causes, symptoms, and treatment*. Old Hickory Bookshop
39. Hou J-C, Thonnat M, Huys R, Bartolomei F, McGonigal A (2020) Rhythmic rocking stereotypies in frontal lobe seizures: A quantified video study. *Neurophysiologie Clinique*
40. Jackson JH (1931) *Selected Writings of John Hughlings Jackson: On Epilepsy and epileptiform convulsions*. Hodder and Stoughton, London
41. Jeha LE, Najm I, Bingaman W, Dinner D, Widdess-Walsh P, Lüders H (2007) Surgical outcome and prognostic factors of frontal lobe epilepsy surgery. *Brain* 130:574-584
42. Jehi L, Braun K (2021) Does etiology really matter for epilepsy surgery outcome? *Brain Pathology* 31:e12965
43. Jehi L, Friedman D, Carlson C, Cascino G, Dewar S, Elger C, Engel J, Knowlton R, Kuzniecky R, McIntosh A (2015) The evolution of epilepsy surgery between

- 1991 and 2011 in nine major epilepsy centers across the United States, Germany, and Australia. *Epilepsia* 56:1526-1533
44. Jobst BC, Siegel AM, Thadani VM, Roberts DW, Rhodes HC, Williamson PD (2000) Intractable seizures of frontal lobe origin: clinical characteristics, localizing signs, and results of surgery. *Epilepsia* 41:1139-1152
  45. Kahane P, Ryvlin P, Hoffmann D, Minotti L, Benabid AL (2003) From hypothalamic hamartoma to cortex: what can be learnt from depth recordings and stimulation? *Epileptic Disorders* 5:205-217
  46. Lagarde S, Scholly J, Popa I, Valenti-Hirsch MP, Trébuchon A, Mcgonigal A, Milh M, Staack AM, Lannes B, Lhermitte B (2019) Can histologically normal epileptogenic zone share common electrophysiological phenotypes with focal cortical dysplasia? SEEG-based study in MRI-negative epileptic patients. *Journal of neurology* 266:1907-1918
  47. LeDoux J (2012) Rethinking the emotional brain. *Neuron* 73:653-676
  48. LeDoux J, Daw ND (2018) Surviving threats: neural circuit and computational implications of a new taxonomy of defensive behaviour. *Nature Reviews Neuroscience* 19:269-282
  49. Machado S, Bonini F, McGonigal A, Singh R, Carron R, Scavarda D, Lagarde S, Trébuchon A, Giusiano B, Bartolomei F (2020) Prefrontal seizure classification based on stereo-EEG quantification and automatic clustering. *Epilepsy & Behavior* 112:107436
  50. Maillard L, Vignal JP, Gavaret M, Guye M, Biraben A, McGonigal A, Chauvel P, Bartolomei F (2004) Semiologic and electrophysiologic correlations in temporal lobe seizure subtypes. *Epilepsia* 45:1590-1599
  51. Manford M, Fish DR, Shorvon SD (1996) An analysis of clinical seizure patterns and their localizing value in frontal and temporal lobe epilepsies. *Brain* 119 ( Pt 1):17-40
  52. Marchi A, Bonini F, Lagarde S, McGonigal A, Gavaret M, Scavarda D, Carron R, Aubert S, Villeneuve N, Villalon SM (2016) Occipital and occipital “plus” epilepsies: A study of involved epileptogenic networks through SEEG quantification. *Epilepsy & Behavior* 62:104-114
  53. McGonigal A, Bartolomei F, Chauvel P (2021) On seizure semiology. *Epilepsia*
  54. McGonigal A, Bartolomei F, Régis J, Guye M, Gavaret M, Trébuchon-Da Fonseca A, Dufour H, Figarella-Branger D, Girard N, Péragut JC, Chauvel P (2007) Stereoelectroencephalography in presurgical assessment of MRI-negative epilepsy. *Brain* 130:3169-3183
  55. McGonigal A, Chauvel P (2013) Prefrontal seizures manifesting as motor stereotypies. *Movement Disorders*
  56. Nobili L, Francione S, Mai R, Cardinale F, Castana L, Tassi L, Sartori I, Didato G, Citterio A, Colombo N, Galli C, Lo Russo G, Cossu M (2007) Surgical treatment of drug-resistant nocturnal frontal lobe epilepsy. *Brain* 130:561-573
  57. O'Muircheartaigh J, Richardson MP (2012) Epilepsy and the frontal lobes. *Cortex* 48:144-155

58. Panksepp J, Biven L (2012) The archaeology of mind: Neuroevolutionary origins of human emotions. WW Norton & Company
59. Penfield W, Gage L (1933) Cerebral localization of epileptic manifestations. *Archives of Neurology & Psychiatry* 30:709-727
60. Provini F, Plazzi G, Lugaresi E (2000) From nocturnal paroxysmal dystonia to nocturnal frontal lobe epilepsy. *Clinical neurophysiology* 111:S2-S8
61. Rheims S, Ryvlin P, Scherer C, Minotti L, Hoffmann D, Guenet M, Mauguière F, Benabid AL, Kahane P (2008) Analysis of clinical patterns and underlying epileptogenic zones of hypermotor seizures. *Epilepsia* 49:2030-2040
62. Scheffer IE, Berkovic S, Bhatia K, Fish DR, Marsden CD, Lopes-Cendes I, Andermann F, Andermann E, Desbiens R, Cendes F (1994) Autosomal dominant frontal epilepsy misdiagnosed as sleep disorder. *The Lancet* 343:515-517
63. Scheffer IE, Bhatia KP, Lopes-Cendes I, Fish DR, Marsden CD, Andermann E, Andermann F, Desbiens R, Keene D, Cendes F (1995) Autosomal dominant nocturnal frontal lobe epilepsy: a distinctive clinical disorder. *Brain* 118:61-73
64. Scheffer IE, Heron SE, Regan BM, Mandelstam S, Crompton DE, Hodgson BL, Licchetta L, Provini F, Bisulli F, Vadlamudi L (2014) Mutations in mammalian target of rapamycin regulator DEPDC5 cause focal epilepsy with brain malformations. *Annals of neurology* 75:782-787
65. Seneviratne U, Rajendran D, Brusco M, Phan TG (2012) How good are we at diagnosing seizures based on semiology? *Epilepsia* 53:e63-e66
66. Sheidley BR, Malinowski J, Bergner AL, Bier L, Gloss DS, Mu W, Mulhern MM, Partack EJ, Poduri A (2021) Genetic testing for the epilepsies: A systematic review. *Epilepsia*
67. Sherrington CS (1906) Lecture VIII: Some aspects of the reactions of the motor cortex.
68. Sisterson ND, Kokkinos V (2020) Neuromodulation of epilepsy networks. *Neurosurgery Clinics* 31:459-470 %@ 1042-3680
69. Tassi L, Garbelli R, Colombo N, Bramerio M, Russo GL, Deleo F, Milesi G, Spreafico R (2010) Type I focal cortical dysplasia: surgical outcome is related to histopathology. *Epileptic Disorders* 12:181-191
70. Tharp BR (1972) Orbital frontal seizures. An unique electroencephalographic and clinical syndrome. *Epilepsia* 13:627
71. Vaugier L, Aubert S, McGonigal A, Trébuchon A, Guye M, Gavaret M, Regis J, Chauvel P, Wendling F, Bartolomei F (2009) Neural networks underlying hyperkinetic seizures of "temporal lobe" origin. *Epilepsy Res* 86:200-208
72. Wagstyl K, Whitaker K, Raznahan A, Seidlitz J, Vértes PE, Foldes S, Humphreys Z, Hu W, Mo J, Likeman M (2021) Atlas of lesion locations and postsurgical seizure freedom in focal cortical dysplasia: A MELD study. *Epilepsia*
73. Wang H, McGonigal A, Zhang K, Guo Q, Zhang B, Wang X, Wang X, Lin J, Song X, Feng Q (2020) Semiologic subgroups of insulo-opercular seizures based on connectional architecture atlas. *Epilepsia*



74. Weckhuysen S, Marsan E, Lambrecq V, Marchal C, Morin-Brureau M, An-Gourfinkel I, Baulac M, Fohlen M, Kallay Zetchi C, Seeck M (2016) Involvement of GATOR complex genes in familial focal epilepsies and focal cortical dysplasia. *Epilepsia* 57:994-1003
75. Wiebe S, Jette N (2012) Pharmacoresistance and the role of surgery in difficult to treat epilepsy. *Nature Reviews Neurology* 8:669-677 %@ 1759-4766
76. Zalta A, Hou J-C, Thonnat M, Bartolomei F, Morillon B, McGonigal A (2020) Neural correlates of rhythmic rocking in prefrontal seizures. *Neurophysiologie Clinique* 50:331-338