



28 – 31 March 2022, ITC Royal Bengal, Kolkata, India.

AORTIC ARCH ANATOMY CHARACTERIZATION FROM MRA: A CNN-BASED SEGMENTATION APPROACH

Mounir Lahlouh^{1,2,3}, Yasmina Chenoune^{2,4}, Raphaël Blanc^{3,5}, Jérôme Szewczyk^{3,6}, Nicolas Passat¹

¹ CReSTIC, Université de Reims Champagne-Ardenne, Reims, France

² ESME Sudria Research Lab, Paris, France

³ Basecamp Vascular, Paris, France

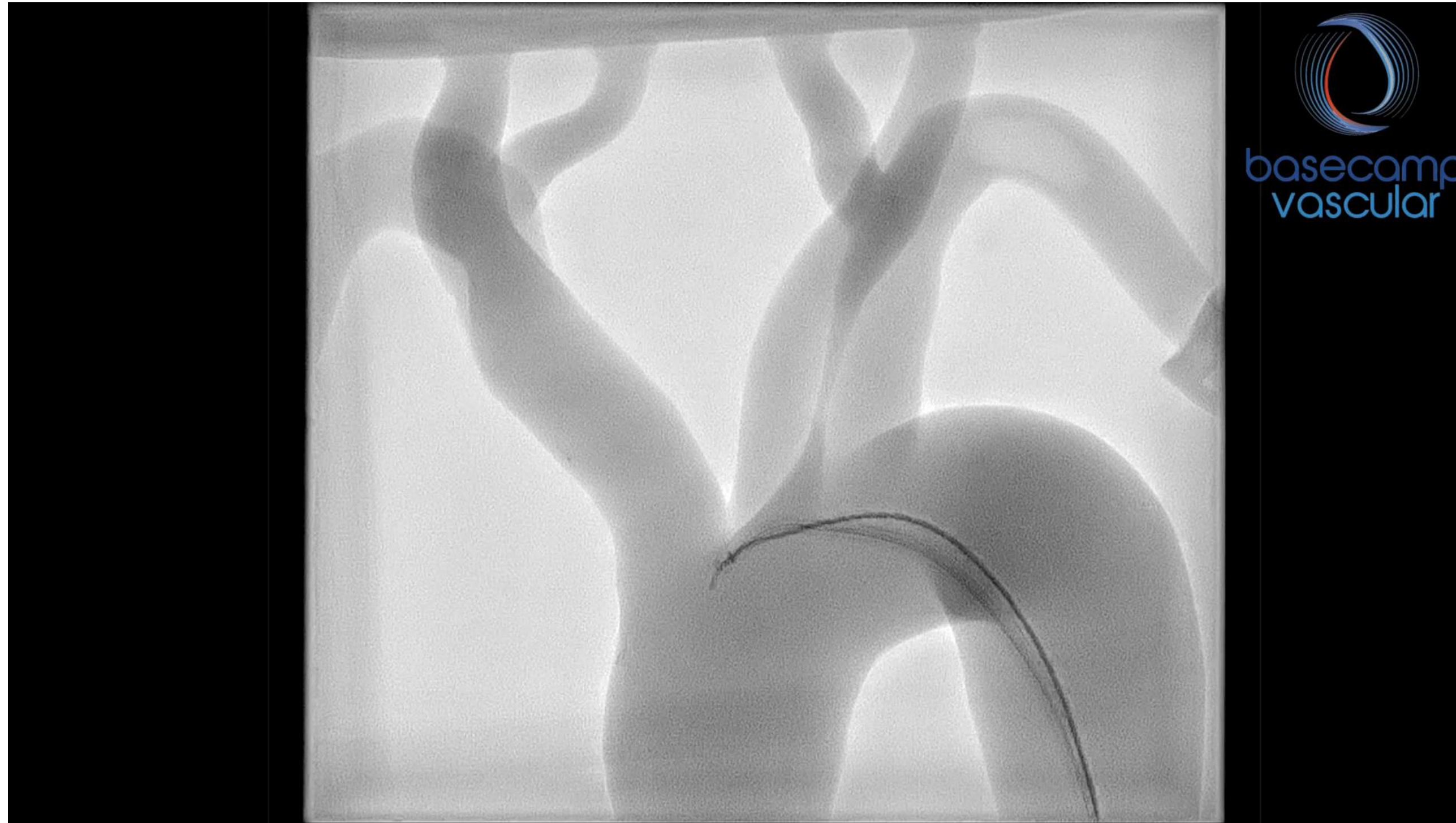⁴ LISSI, Université Paris-Est, Vitry-sur-Seine, France

⁵ Fondation Ophtalmologique de Rothschild, Interventional Neuroradiology Department, Paris, France

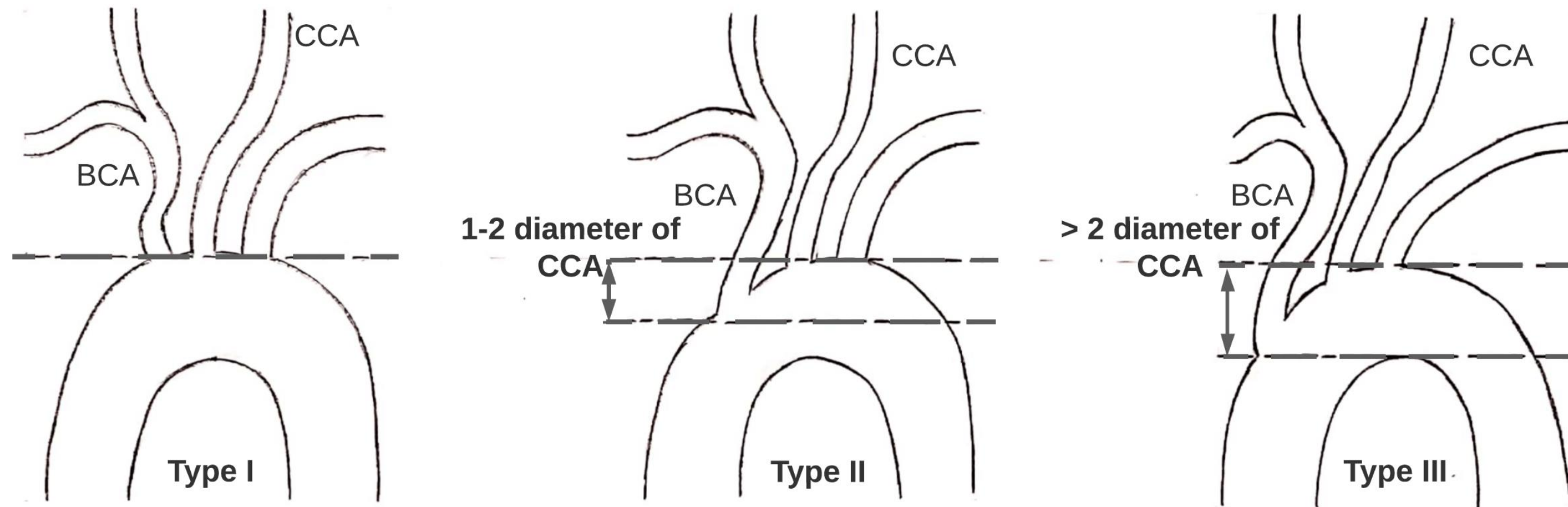
⁶ ISIR, Sorbonne Université, Paris, France



Clinical background



Clinical background



Madhwal's aortic arch anatomy classification [1]

- The type of aortic arch provides information on the complexity of navigation to the pathological area and can help physicians to better plan procedures and choose the most appropriate catheter.

[1] S. Madhwal, V. Rajagopal, D. L. Bhatt, C. T. Bajzer, P. Whitlow, and S. R. Kapadia, "Predictors of difficult carotid stenting as determined by aortic arch angiography," J Invasive Cardiol, vol. 20, pp. 200–204, 2008.

Technical background

3D Inception U-Net

- Localization and segmentation of the aortic valve in coronary CT images using U-Net-like architectures. The best results were obtained by 3D Inception U-Net [2].

[2] S. R. Ravichandran, B. Nataraj, S. Huang, Z. Qin, Z. Lu, A. Katsuki, W. Huang, and Z. Zeng, "3D inception U-Net for aorta segmentation using computed tomography cardiac angiography," in BHI, 2019, pp. 1–4.

Multiview 2D CNNs

- Segmentation of the aortic lumen: from the ascending aorta to the iliac arteries by aggregating voxel classifications in axial, sagittal and coronal sections of CTA volumes [3].

[3] A. Fantazzini et al., "3D Automatic Segmentation of Aortic Computed Tomography Angiography Combining Multi-View 2D Convolutional Neural Networks," *Cardiovasc. Eng. Technol.*, vol. 11, no. 5, pp. 576–586, 2020.

Cascaded CNNs

- Multi-stage segmentation pipeline for aortic dissection type B on CTA volumes. Two cascaded CNNs were used, the first for the segmentation of aortic branches and the second for the segmentation of the true and false lumen [4].

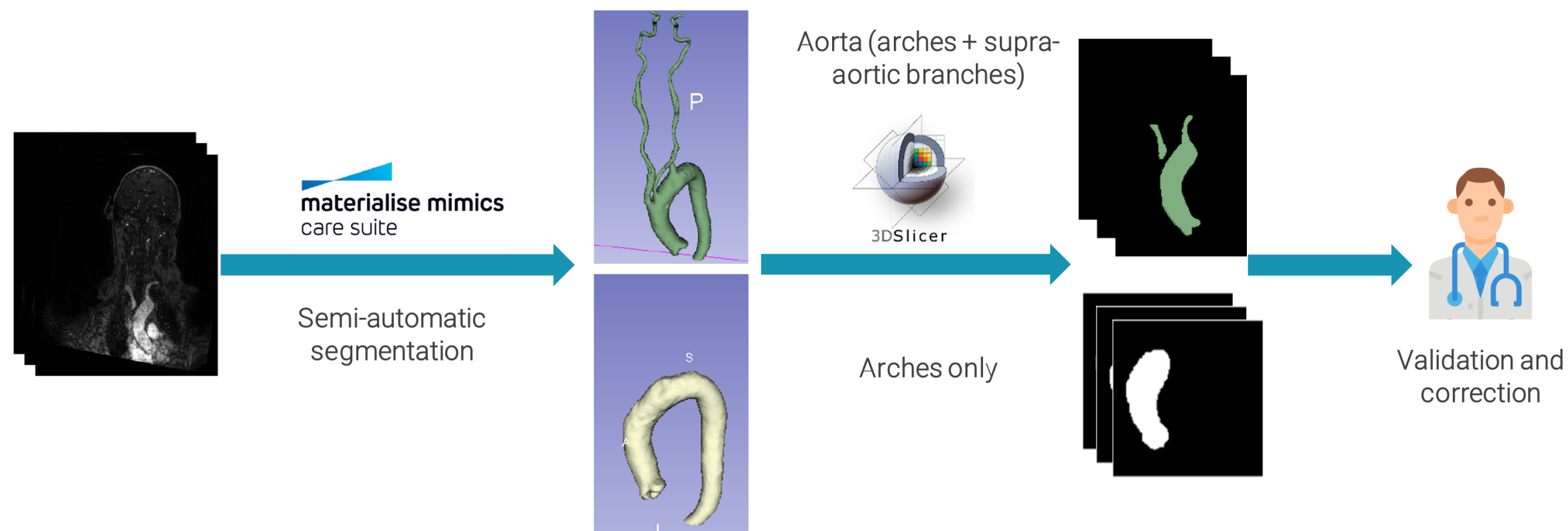
[4] D. Chen et al., "Multi-stage learning for segmentation of aortic dissections using a prior aortic anatomy simplification," *Med. Image Anal.*, vol. 69, p. 101931, 2021.

Data

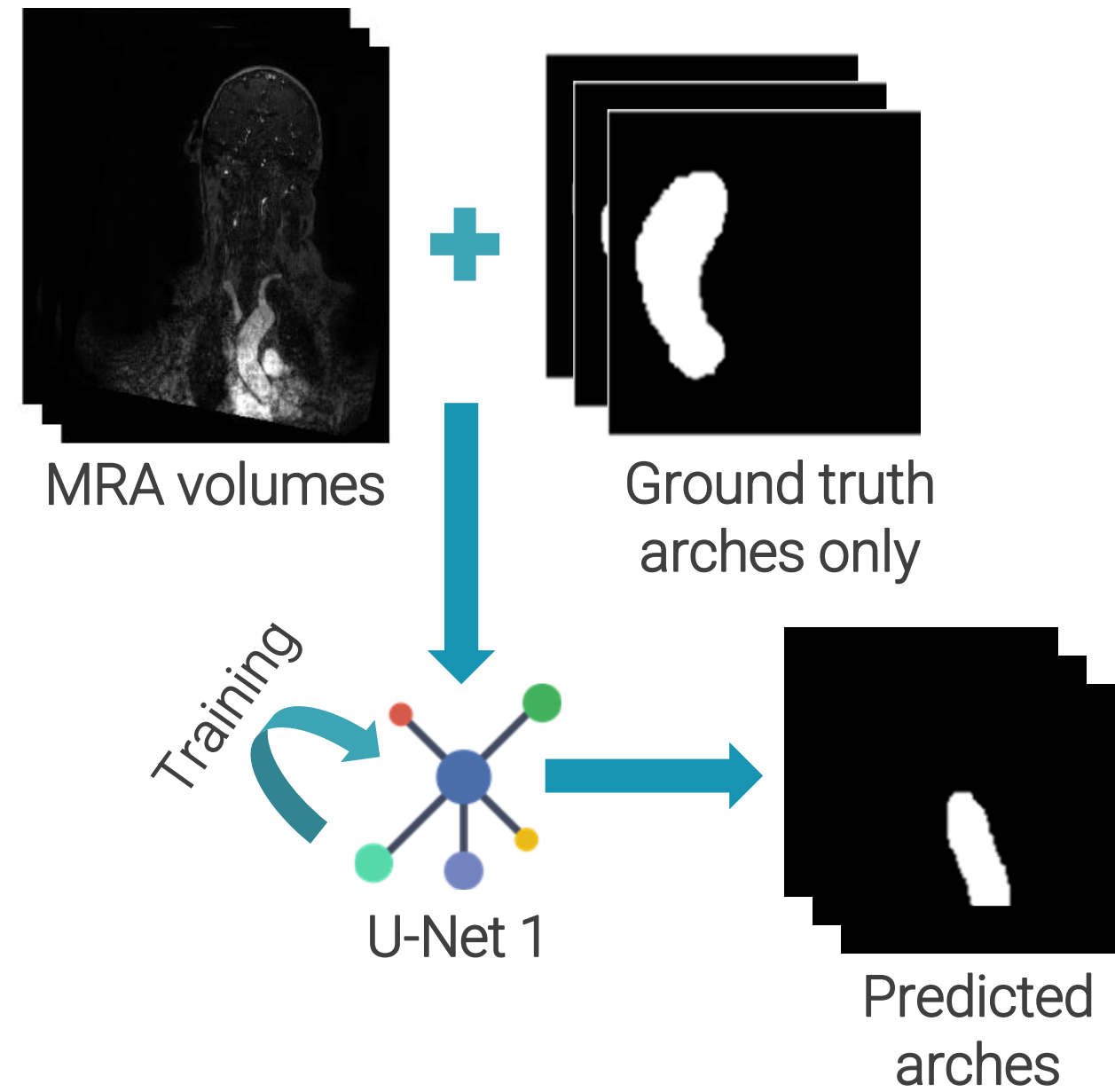
- The dataset used in our study was provided by the neuroradiology department of the Fondation Ophtalmologique Adolphe de Rothschild, Paris, France.

Dataset overview

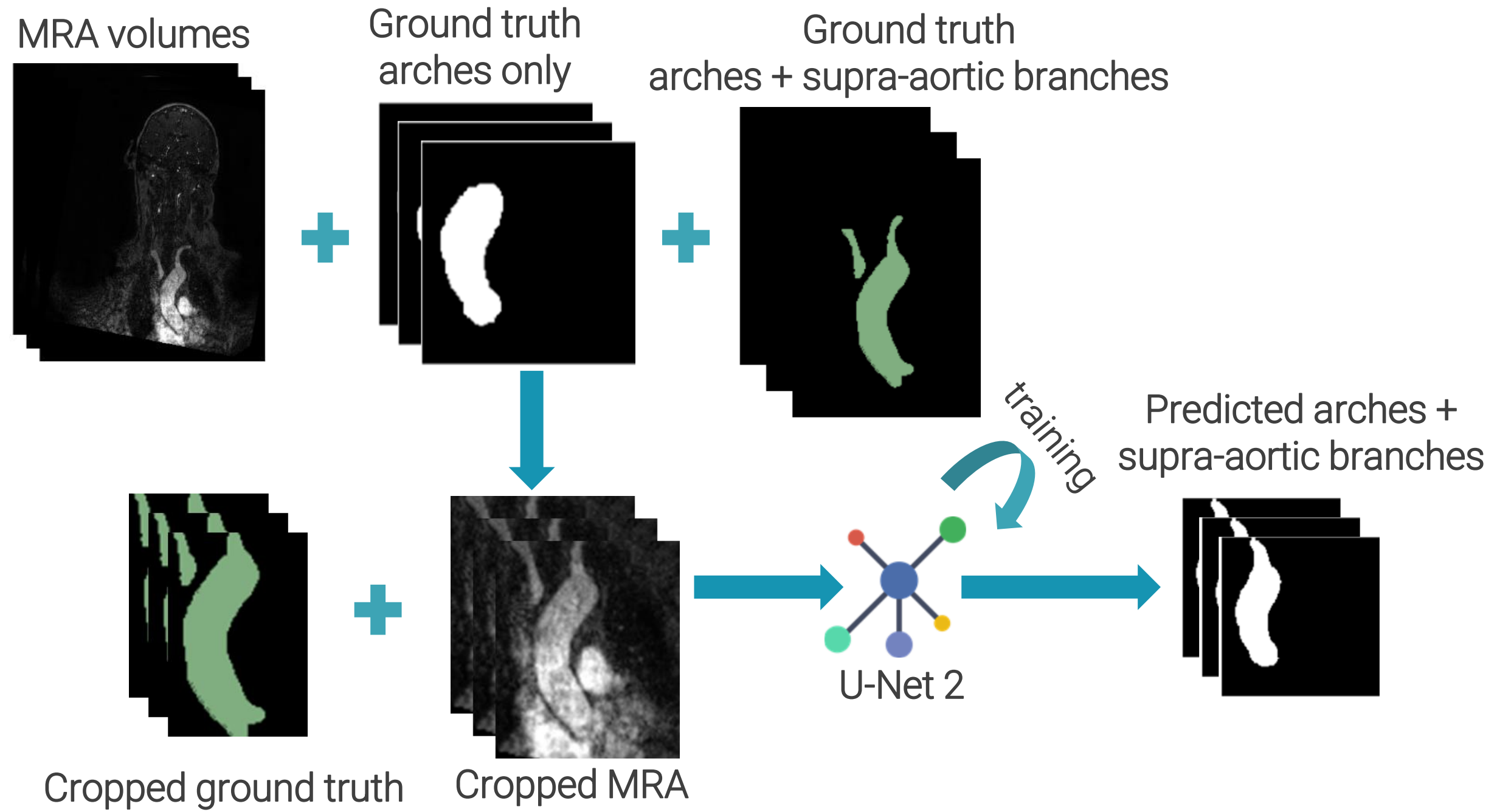
- 27 patients between 31 and 95 years old (average 72 years, 59% male).
- Contrast enhanced 3T MRA of aortic arch, supra-aortic branches and intracranial vessels.
- Types II or III were observed in 18.5% of patients compared to 63% of type I.
- 6849 coronal slices: 250 slices (on average) of 256×256 pixels
- The dataset is not homogeneous: most MRA volumes have a resolution of $0,495 \times 0,495 \times 0,500$ mm after interpolation.



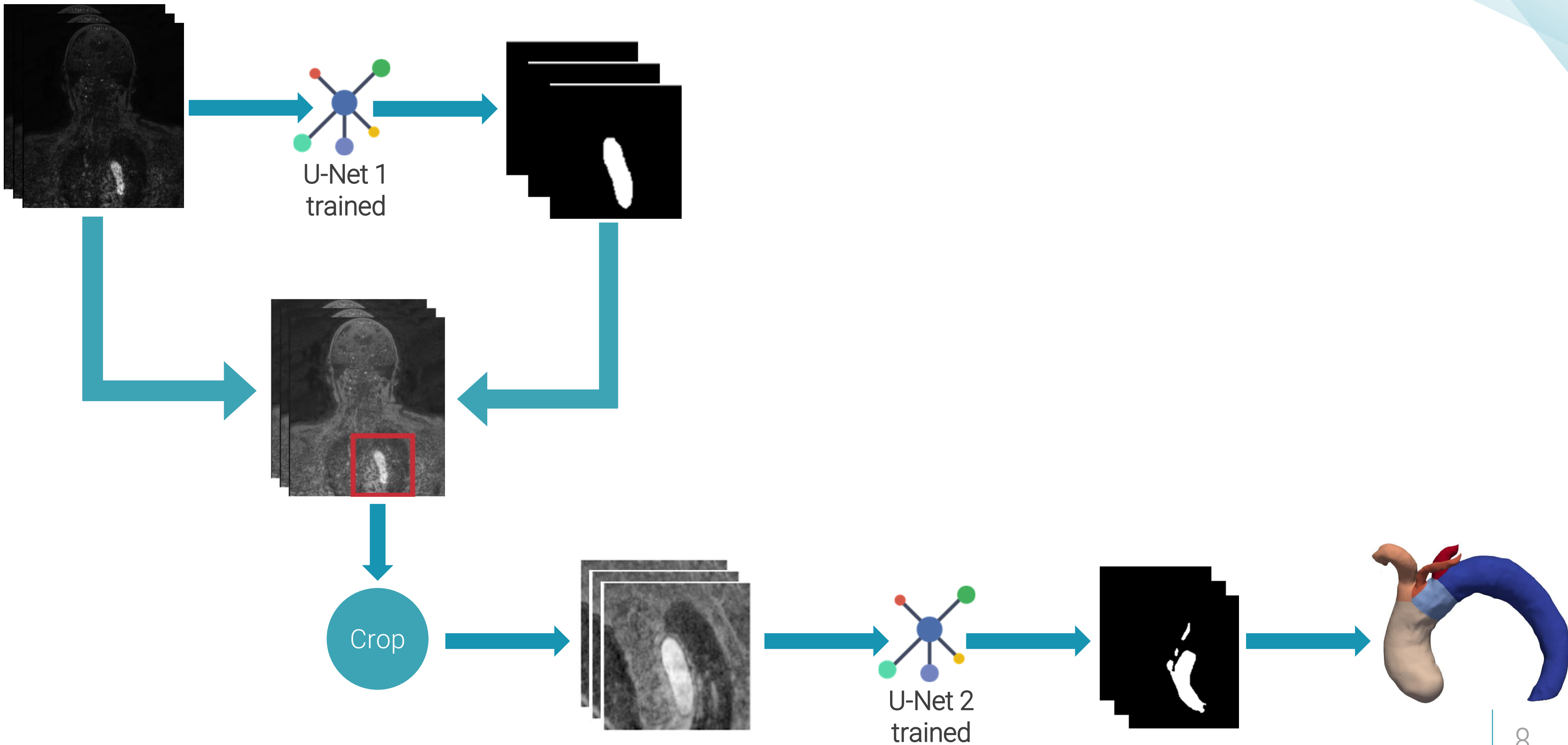
CNN-based pipeline



CNN-based pipeline



CNN-based pipeline



Pipeline results

Data split

Train	Validation	Test
20 patients	2 patients	5 patients

Localization module (standard U-Net)

Optimizer	Test DSC	Test IOU	Test Precision	Test Recall
SGD	81.51 %	75.93 %	82.96 %	88.59 %
Adam	88.11 %	83.79 %	94.58 %	88.07 %
Adabelief	89.65 %	85.75 %	93.75 %	91.08 %

Segmentation module (Inception U-Net)

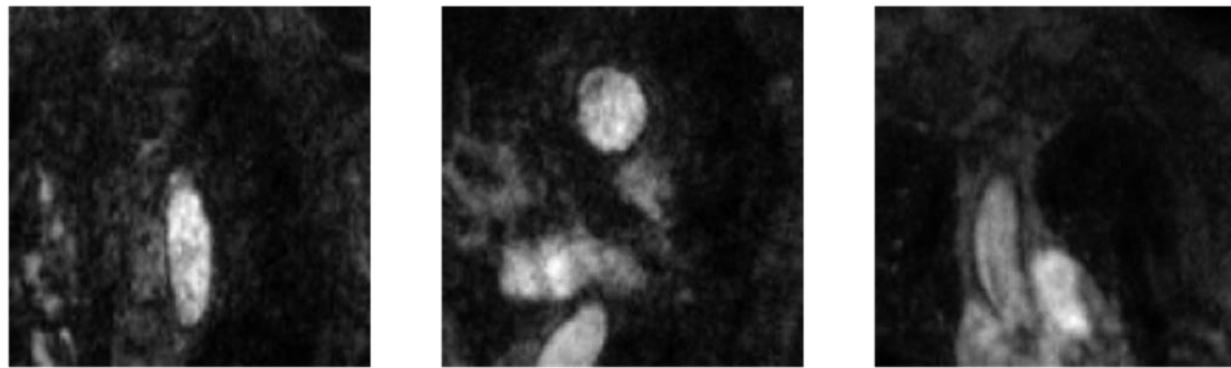
Optimizer	Test DSC	Test IOU	Test Precision	Test Recall
SGD	79.25 %	71.33 %	71.09 %	92.56 %
Adam	87.73 %	82.11 %	82.84 %	93.86 %
Adabelief	88.07 %	82.56 %	84.10 %	93.80 %

Gap
reduction

Pipeline results

Segmentation results of MRA slices


MRA



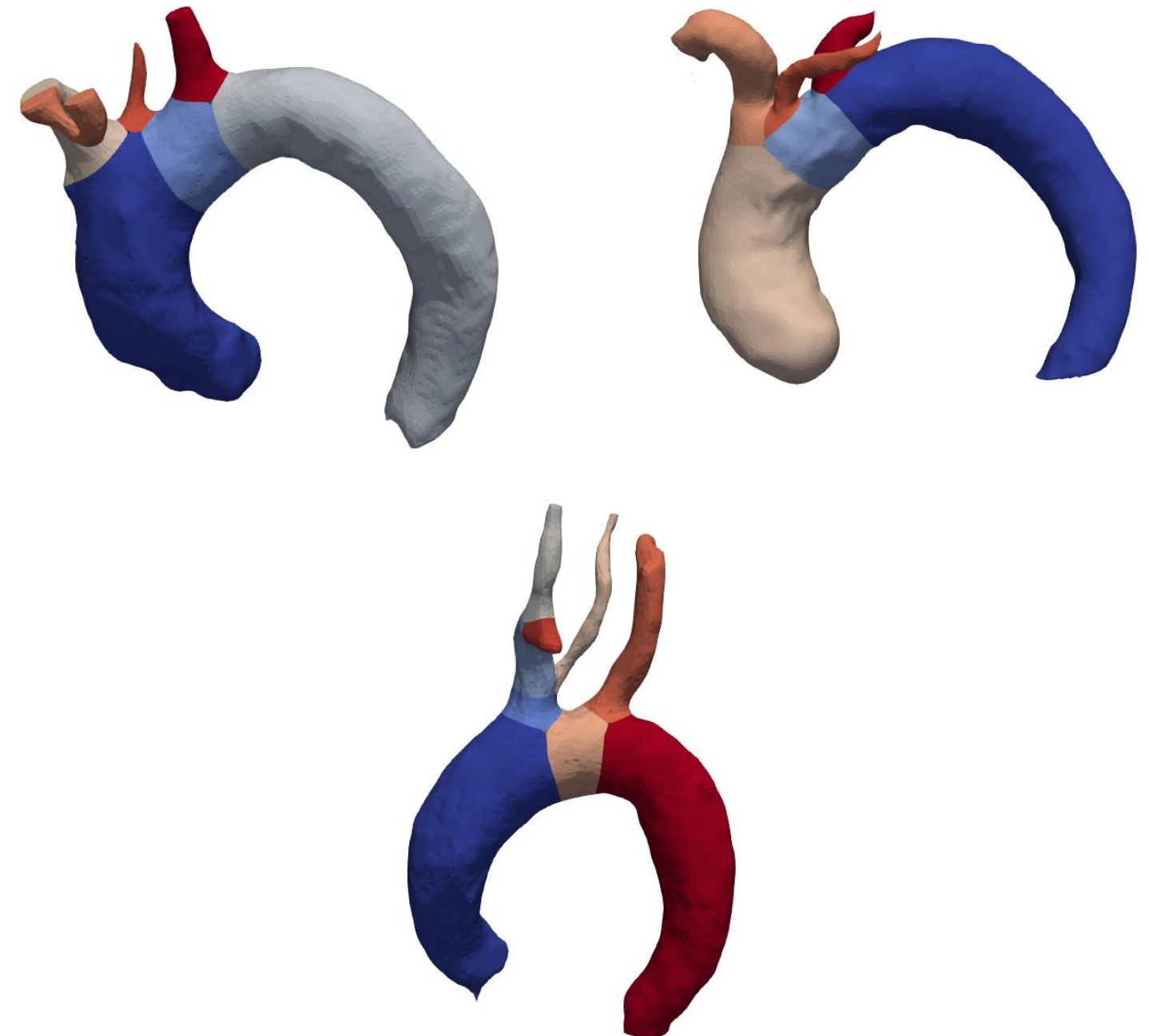
Ground truth



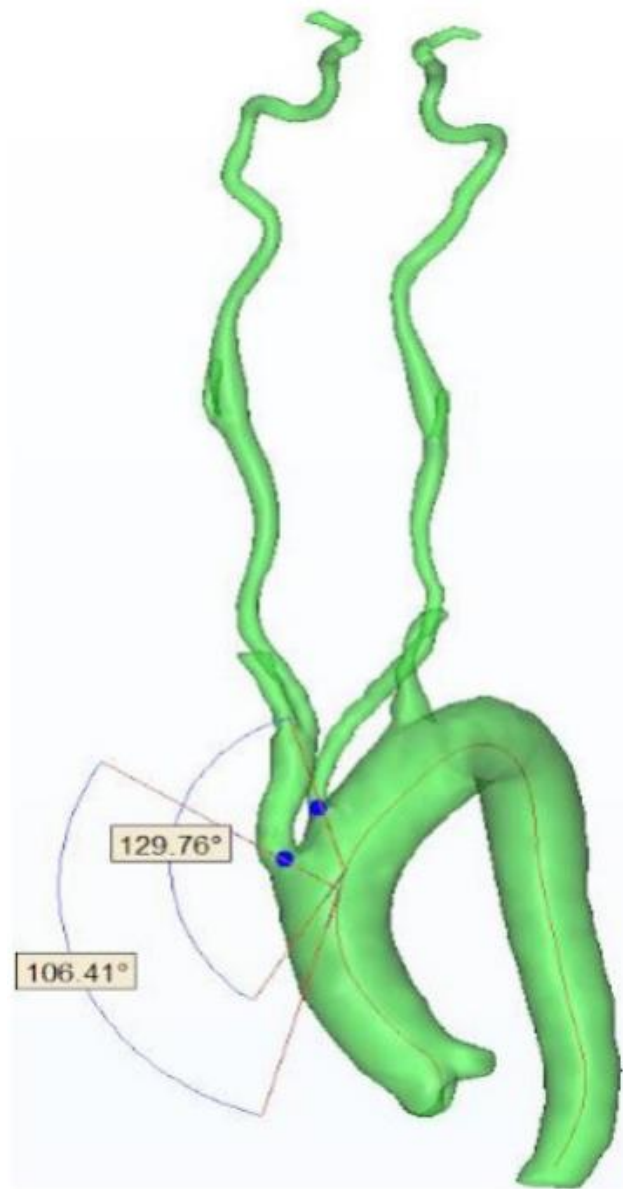
Predictions



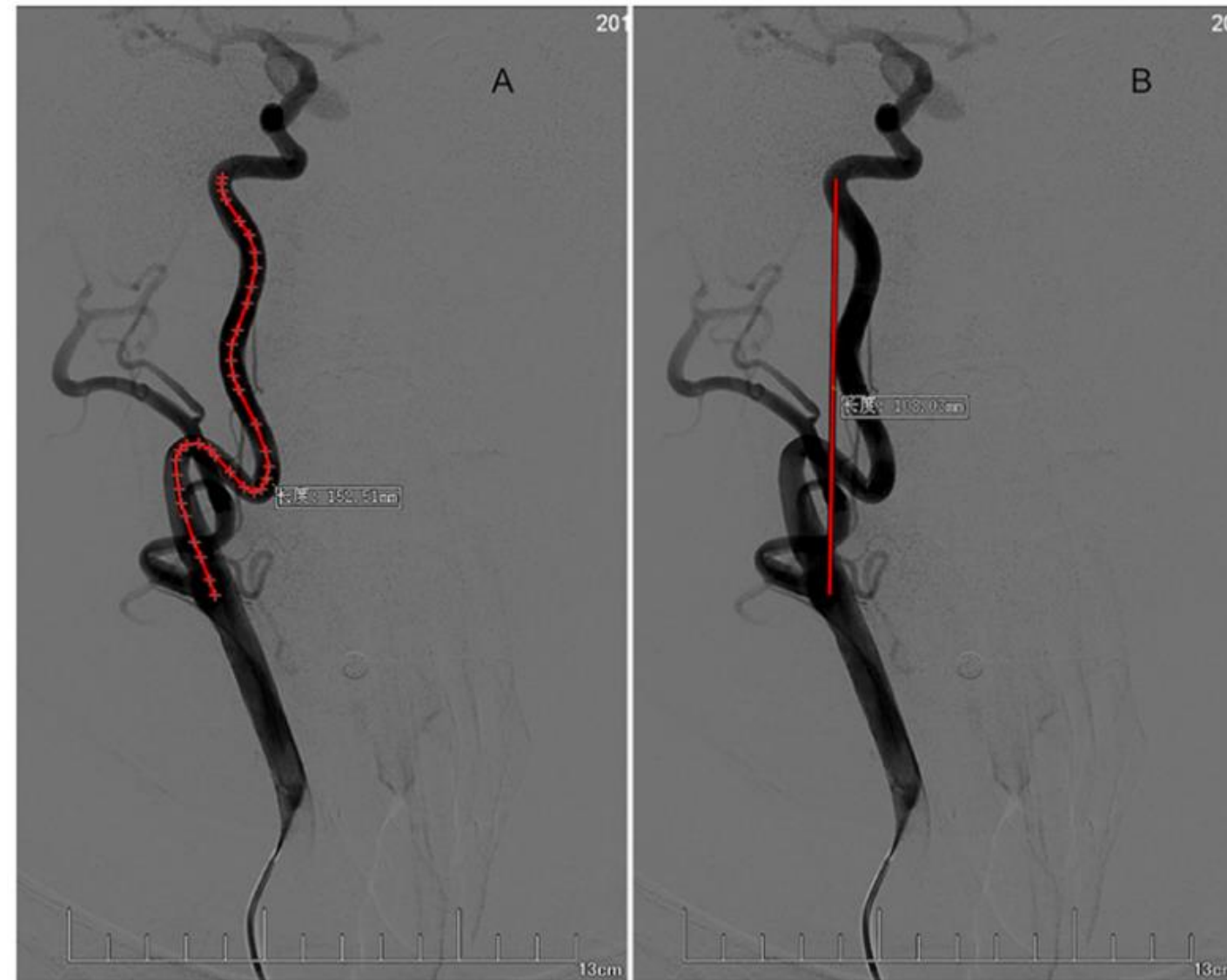
Results of 3D reconstructions



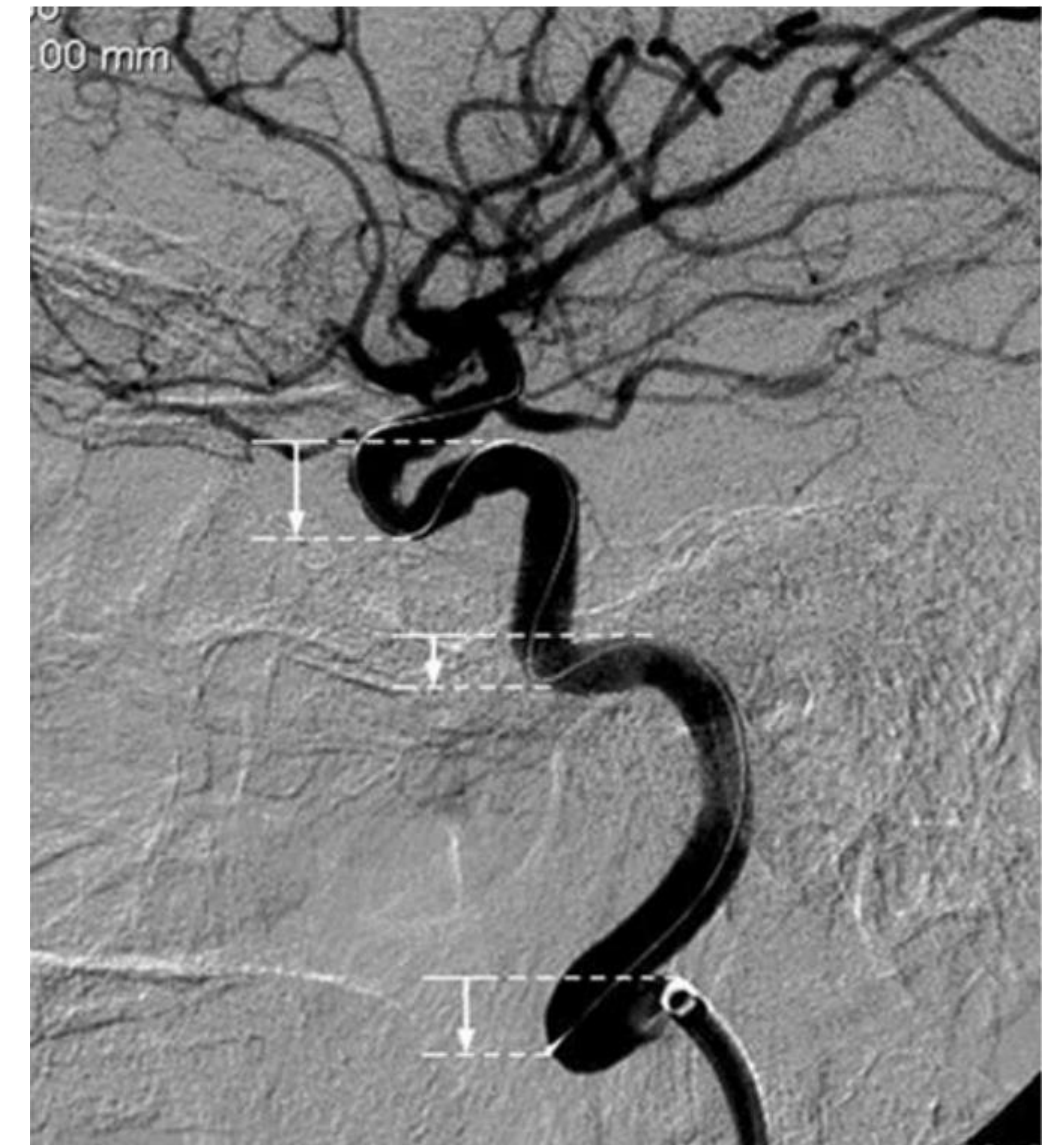Geometric characterization



Take off angles

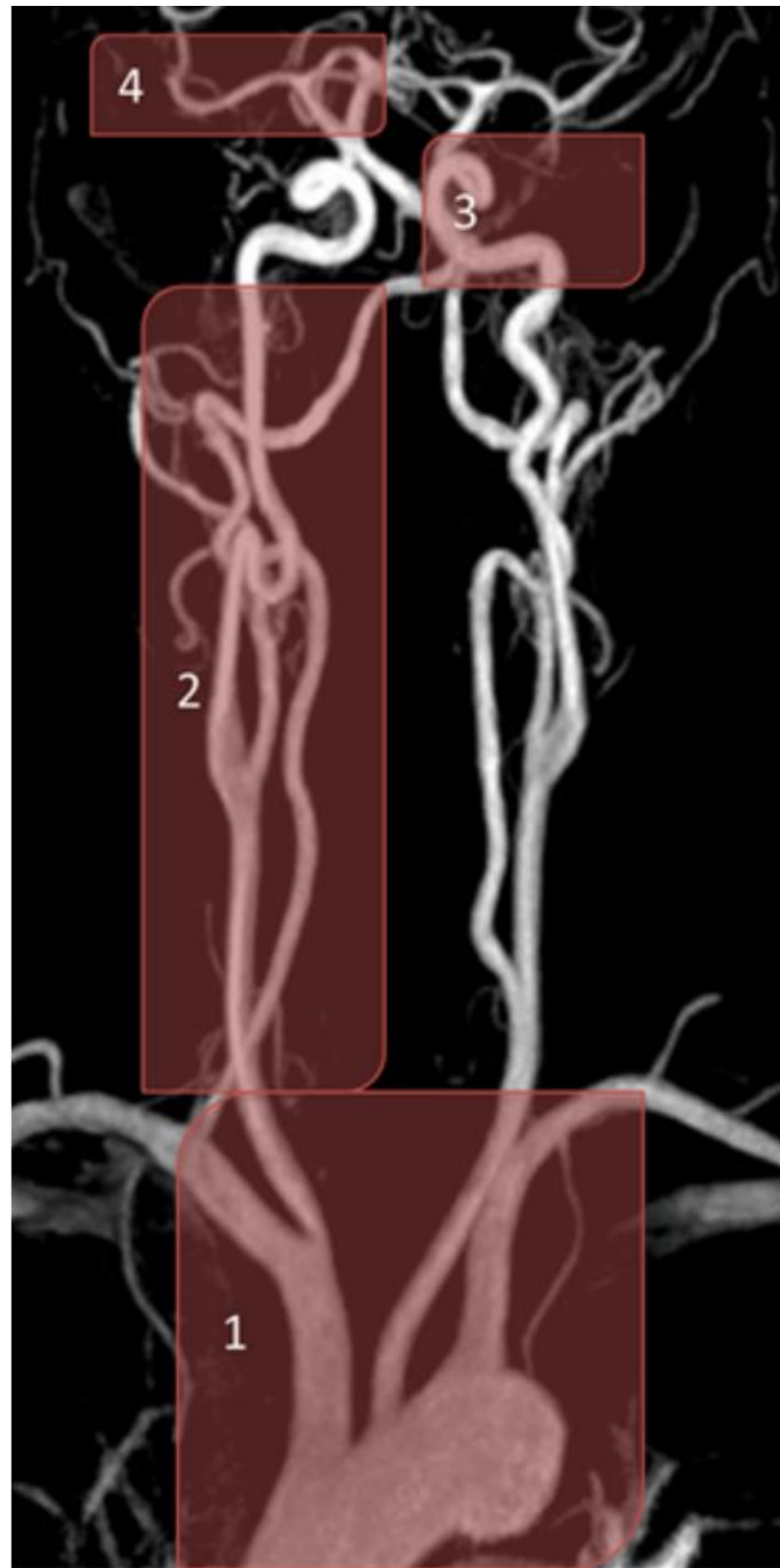


Tortuosity index



Reverse curves

Conclusion and perspectives



- Development of a CNN-based pipeline for the automatic localization and segmentation of aortic arches for geometric characterization.
- Quantitative validation by comparison to the medical reference with a good Dice similarity coefficient of 88.07%.

- Increasing our dataset size, enhancing the tested models or investigating variants like UNet++ [5] or TransUNet [6] for a better generalization.

[5] Z. Zhou et al., "Unet++: A nested u-net architecture for medical image segmentation," in Deep Learning in Medical Image Analysis and Multimodal Learning for Clinical Decision Support, 2018, pp. 3–11.

[6] J. Chen et al., "Transunet: Transformers make strong encoders for medical image segmentation," arXiv preprint arXiv:2102.04306, 2021.

1) and 2) Aortic arch and supra-aortic branches, 3) and 4) intracranial vessels.
Vascular structures of different anatomical characteristics: vessels become more tortuous, and their diameter decreases as they ascend to the brain.

- Extend the pipeline segmentation beyond the aortic arch characterization by proposing deep architectures able to capture the size variation of vessels.

Thank you for your
attention!