

# AORTIC ARCH ANATOMY CHARACTERIZATION FROM MRA: A CNN-BASED SEGMENTATION APPROACH

Mounir Lahlouh<sup>1,2,3</sup>, Yasmina Chenoune<sup>2,4</sup>, Raphaël Blanc<sup>3,5</sup>, Jérôme Szewczyk<sup>3,6</sup>, Nicolas Passat<sup>1</sup>

<sup>1</sup>CRESTIC, Université de Reims Champagne-Ardenne, Reims, France

<sup>2</sup>ESME Sudria Research Lab, Paris, France

<sup>3</sup>Basecamp Vascular, Paris, France

<sup>4</sup>LISSI, Université Paris-Est, Vitry-sur-Seine, France

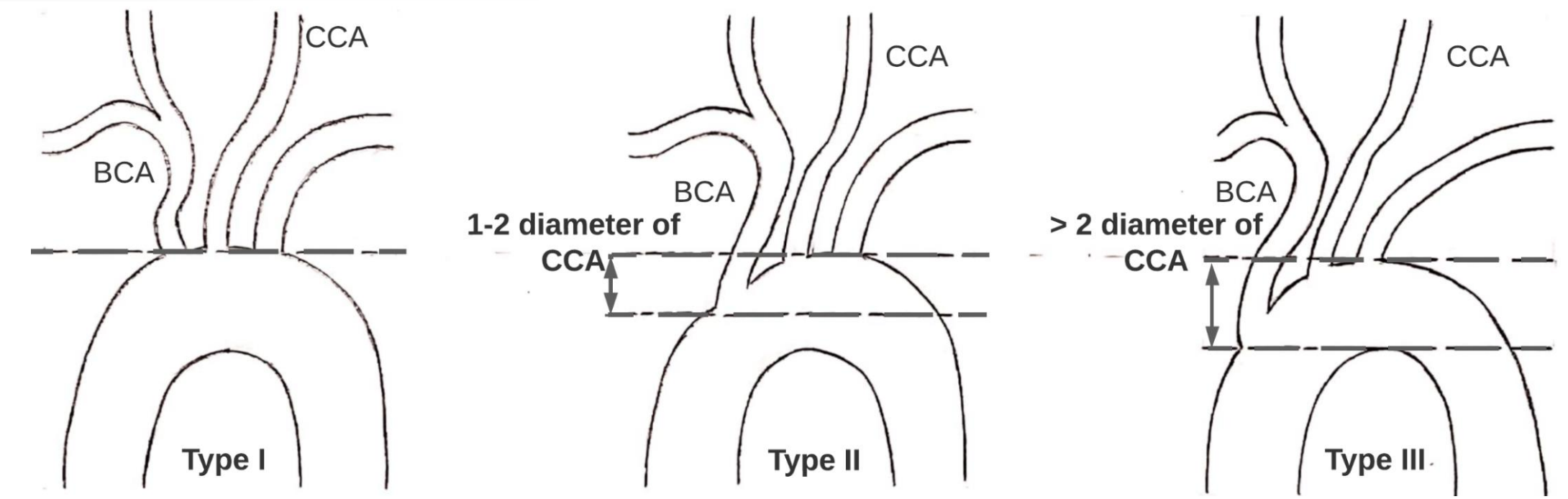
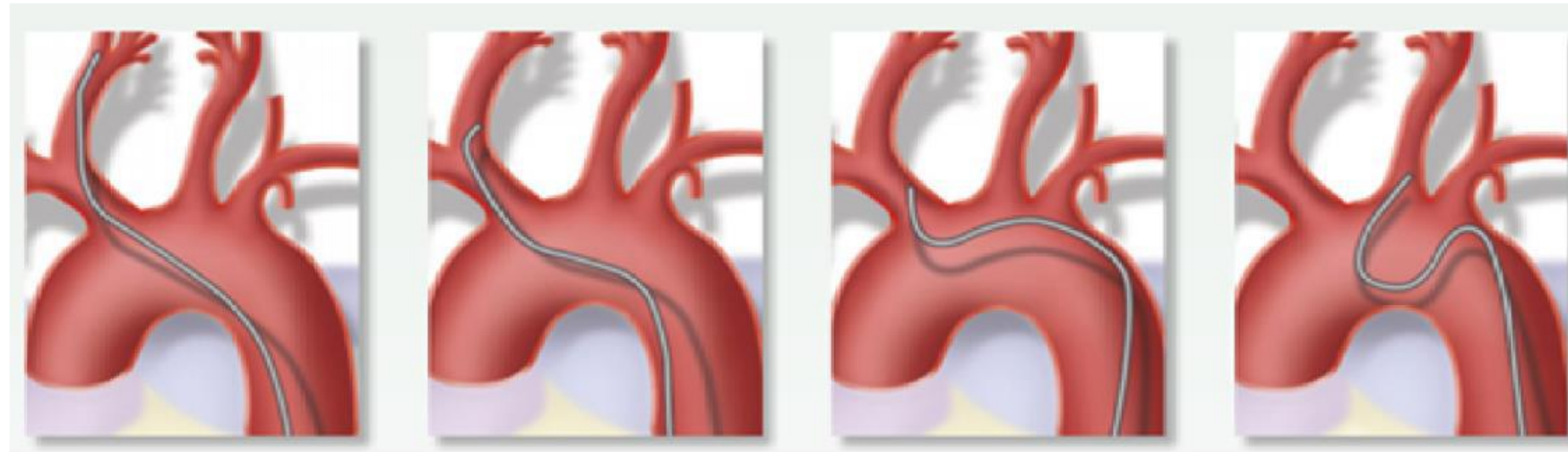
<sup>5</sup>Fondation Ophtalmologique de Rothschild, Interventional Neuroradiology Department, Paris, France

<sup>6</sup>ISIR, Sorbonne Université, Paris, France

## 1. Clinical background

Knowledge of the anatomy of the aortic arch is essential in interventional neuroradiology.

Tools used by physicians are not always maneuverable and intuitive. Thus, to choose the catheter best fitting the patient's morphology and to anticipate the neuroradiologist gesture, an anatomical study of the vessels is essential,



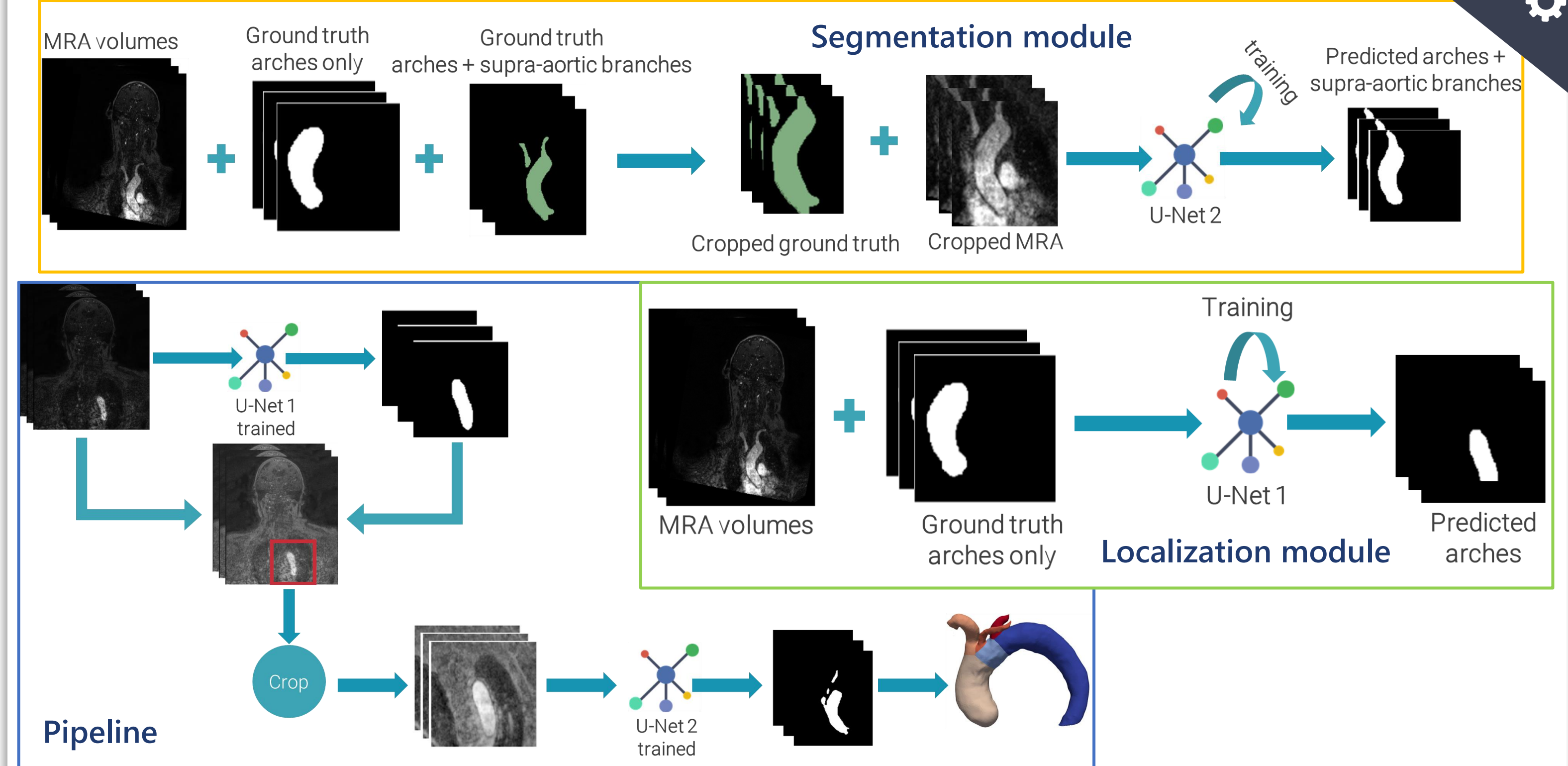
Madhwal's aortic arch anatomy classification [1]

The type of aortic arch provides information on the complexity of navigation to the pathological area and helps to better plan procedures and choose the appropriate catheter.

## 2. Technical background

Approach	Achievements
3D Inception U-Net [2]	<ul style="list-style-type: none"> <li>Localization and segmentation of the aortic valve in coronary CT images using U-Net-like architectures. The best results were obtained by 3D Inception U-Net.</li> </ul>
Multiview 2D CNNs [3]	<ul style="list-style-type: none"> <li>Segmentation of the aortic lumen from the ascending aorta to the iliac arteries by aggregating voxel classifications in axial, sagittal and coronal sections of CTA volumes.</li> </ul>
Cascaded CNNs [4]	<ul style="list-style-type: none"> <li>Multi-stage segmentation pipeline for aortic dissection type B on CTA volumes. Two cascaded CNNs were used, the first for the segmentation of aortic branches and the second for the segmentation of the true and false lumen.</li> </ul>

## 4. CNN-based pipeline

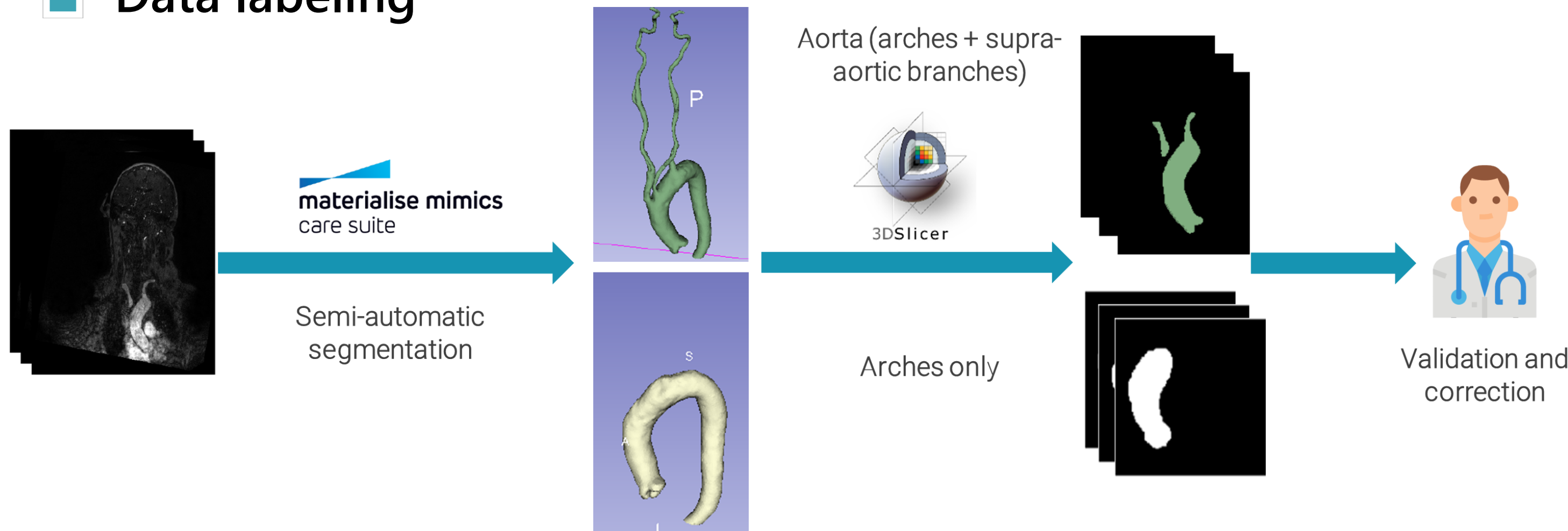


## 3. Data

27 patients underwent 3T MR exams of aortic arch, supra-aortic branches and intracranial vessels on Philips imaging system (Ingenia 3T, Best, The Netherlands).

Acquisition parameters: coronal plane covering: 250 slices; active TR/TE = 5.5/2.2 ms; flip angle = 27°; number of excitations = 1; acquisition bandwidth = 476.7 Hz; FOV = 380 x 321; voxel size = 0.5 x 0.5 x 1.0 mm; imaging time = 69 sec; Bolus track injection technique.

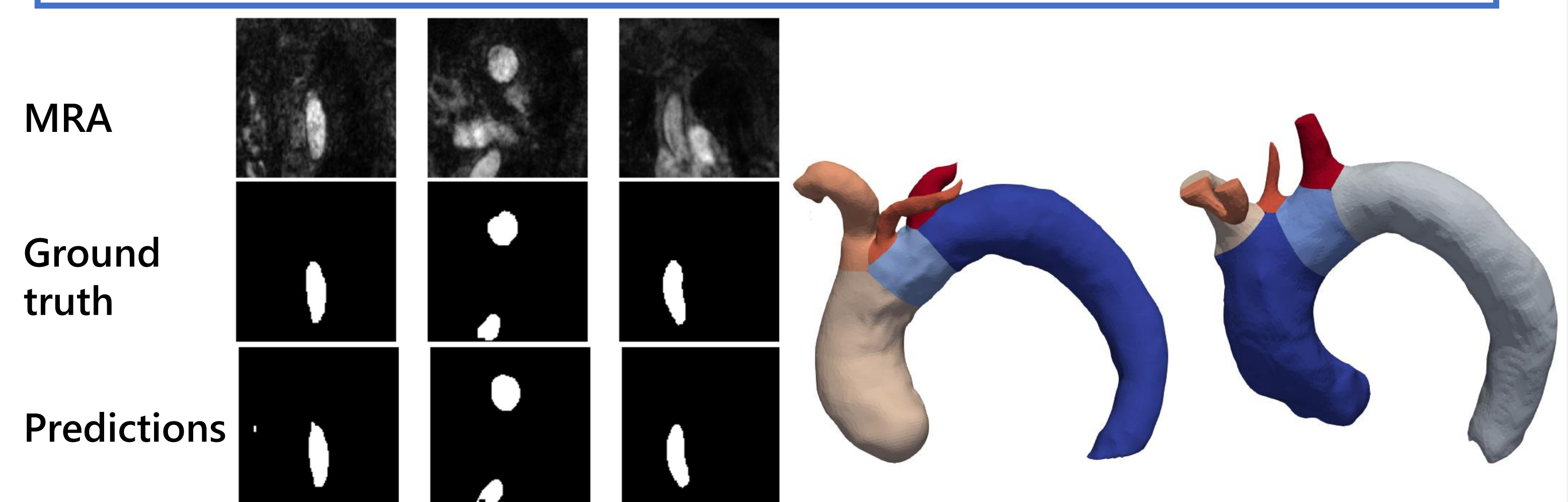
### Data labeling



## 5. Results

Results on the test set with Inception U-Net + Adabelief:

- Dice Similarity Coefficient (DSC) = 88.07% of similarity with the ground truth.
- Precision = 84.10%
- Recall = 93.80%



## 6. Conclusion and perspectives

- Development of a CNN-based pipeline for the automatic localization and segmentation of aortic arches for geometric characterization.
- Quantitative validation by comparison to the medical reference with a good DSC of 88.07%.

Increasing our dataset size, enhancing the tested models or investigating variants like UNet++ or TransUNet for a better generalization.

1) and 2) Aortic arch and supra-aortic branches, 3) and 4) intracranial vessels. Vascular structures of different anatomical characteristics: vessels become more tortuous, and their diameter decreases as they ascend to the brain.

Extend the pipeline segmentation beyond the aortic arch characterization by proposing deep architectures able to capture the size variation of vessels.

## References

- [1] S. Madhwal, V. Rajagopal, D. L. Bhatt, C. T. Bajzer, P. Whitlow, and S. R. Kapadia, "Predictors of difficult carotid stenting as determined by aortic arch angiography," *J. Invasive. Cardiol.*, vol. 20, pp. 200–204, 2008.
- [2] A. Fantazzini et al., "3D Automatic Segmentation of Aortic Computed Tomography Angiography Combining Multi-View 2D Convolutional Neural Networks," *Cardiovasc. Eng. Technol.*, vol. 11, no. 5, pp. 576–586, 2020.
- [3] S. R. Ravichandran et al., "3D Inception U-Net for Aorta Segmentation using Computed Tomography Cardiac Angiography," in 2019 IEEE EMBS International Conference on Biomedical Health Informatics (BHI), 2019, pp. 1–4.
- [4] D. Chen et al., "Multi-stage learning for segmentation of aortic dissections using a prior aortic anatomy simplification," *Med. Image Anal.*, vol. 69, p. 101931, 2021.