



HAL
open science

Management of adipose tumors in the limbs

Louis-Romée Le Nail, Vincent Crenn, Philippe Rosset, Mickaël Ropars

► To cite this version:

Louis-Romée Le Nail, Vincent Crenn, Philippe Rosset, Mickaël Ropars. Management of adipose tumors in the limbs. *Orthopaedics & Traumatology: Surgery & Research*, In press, <10.1016/j.otsr.2021.103162>. <hal-03516461>

HAL Id: hal-03516461

<https://hal.science/hal-03516461v1>

Submitted on 18 Jan 2022

HAL is a multi-disciplinary open access archive for the deposit and dissemination of scientific research documents, whether they are published or not. The documents may come from teaching and research institutions in France or abroad, or from public or private research centers.

L'archive ouverte pluridisciplinaire **HAL**, est destinée au dépôt et à la diffusion de documents scientifiques de niveau recherche, publiés ou non, émanant des établissements d'enseignement et de recherche français ou étrangers, des laboratoires publics ou privés.



Distributed under a Creative Commons CC BY-NC 4.0 - Attribution - Non-commercial use - International License

Review article

Management of adipose tumors in the limbs

Louis-Romée Le Nail* ^(1,4), Vincent Crenn ^(2,4), Philippe Rosset ^(1,4) and Mickaël Ropars ^(3,4)

1. Service de Chirurgie Orthopédique et Traumatologique, Hôpital Trousseau, CHRU de Tours, France ; Réunion de concertation pluridisciplinaire des tumeurs de l'appareil locomoteur, CHRU de Tours, France ; Faculté de Médecine de Tours, Université de Tours, France.
2. Service de Chirurgie Orthopédique et Traumatologique, Hôpital Hôtel Dieu, CHU de Nantes, 1, place Alexis-Ricordeau, 44093 Nantes Cedex 1, Faculté de Médecine, Université de Nantes, France
3. Service de Chirurgie Orthopédique et Traumatologique, CHU Pontchaillou, Université de Rennes 1, rue Henri-Le-Guillou, 35033 Rennes, France
4. Réseau HUGORTHO : réseau des services de chirurgie orthopédique et traumatologique adulte et enfant des Hôpitaux Universitaires du Grand Ouest, France.

* **Corresponding author:** L-R Le Nail,

Service de Chirurgie Orthopédique et Traumatologique, Hôpital Trousseau, CHRU de Tours, France ; Réunion de concertation pluridisciplinaire des tumeurs de l'appareil locomoteur, CHRU de Tours, France ; Faculté de Médecine de Tours, Université de Tours, France.

lr.lenail@chu-tours.fr

Abbreviations

FISH	Fluorescent <i>in situ</i> hybridization
FNCLCC	French Federation of Cancer Treatment Centers
MRI	Magnetic resonance imaging
LS	Liposarcoma
DDLS	Dedifferentiated liposarcoma
MLS	Myxoid liposarcoma
PLS	Pleomorphic liposarcoma
MDTB	Multidisciplinary tumor board
RRePS	French sarcoma pathology reference network
STS	Soft tissue sarcoma
ALT	Atypical lipomatous tumor

Abstract

Adipose tumors of the limbs are the most common soft tissue lesions and are essentially benign (lipomas). However, in some cases, they can be considered as tumors with intermediate malignancy (atypical lipomatous tumor [ALT]) or sarcoma lineage (liposarcoma [LS]).

The essential work-up for a potential adipose tumor consists of a clinical examination and initial ultrasound imaging to determine the size (more or less than 5 cm), the location (over or under the fascia) and any potential atypical vascularization. As needed, MRI will complete the assessment and validate the ultrasound results and confirm the fatty nature of the lesion. Percutaneous biopsy will be done when a deep fatty lesion is larger than 5 cm (long axis), with detection by amplification of the *MDM2* gene that guides the diagnosis towards ALT or dedifferentiated LS.

Superficial lesions without atypia are not challenging from a surgical point of view. However, large ALT can be more difficult to manage. Their local malignancy does not justify sacrificing any critical structures. As for true LS, their treatment is well defined, with tumor excision addressed at a center belonging to the Network of Sarcomas Reference Centers in France (NETSARC+) and for potential (neo)adjuvant treatment if needed. Inappropriate treatment of a malignant tumor can have serious consequences (loss of chance to survive or to be cured) for the patient. Furthermore, treatment at a specialized cancer center has been proven to be effective as it improves overall survival and reduces local recurrences.

Keywords: adipose tumor, limbs, atypical lipomatous tumor, liposarcoma

INTRODUCTION

Soft tissue tumors in the limbs are common and benign in most cases. However, it is difficult to estimate their incidence exactly. They represent about 3000 consultations per year per 1 million inhabitants [1]. The ratio of malignant to benign tumors is about 1 to 100. Tumors considered as malignant generally belong to the sarcoma family. They occur at every age and are mainly found in the lower limb (especially the thigh); they originate in connective tissue, which differs from most cancers, which originate in the epithelial tissue (carcinomas).

Sarcomas have an incidence of approximately 4000 to 5000 new cases per year in France, or 6 to 9 cases per 100,000 inhabitants [1,2]. Since there are at least 70 histological sarcoma subtypes [3], their histological diagnosis requires a pathologist with specific expertise [4].

Fatty tissue in itself is the source of several tumors; they make up about 50% of benign tumors and 25% of soft-tissue sarcomas (STS) called liposarcomas (LS).

The current study is justified by this high incidence of adipose tumors in soft tissues, their distinctive diagnostic characteristics and their treatment that may require a specialized center, depending on their malignancy.

We will limit this review to adult tumors in the limbs. After having enumerated the various types of adipose tumors (benign, intermediate malignancy or malignant), we will propose criteria for clinical and imaging orientation, while specifying the role of biopsy and its methods. We will then explain the surgical treatment options and the benefits of

using a national network specialized in sarcomas (clinical and pathological) and how to refer a patient.

1. What are the different fatty lesions found in the limbs?

Adipose tumors or those containing fat are highly diverse and are difficult to classify. To break them down in a simple manner, a classification based on their malignancy and histological characteristics is proposed.

1.1. Benign tumors

1.1.1. Tumors arising from white fat tissue

The lipoma is a benign tumor composed of mature adipocytes that may be encapsulated. This is the most common adipose tumor, corresponding to half of all soft tissue tumors [3][5]. While they can occur at any age, they are generally discovered between the 5th and 7th decade. They are most often isolated, superficial, soft, painless, slow-growing, known for a long time by the patient, and measuring less than 2 cm [6].

When deeply located within the muscles—often corresponding to an incidental finding—it may dissociate the muscle fibers, resulting in a comb-like appearance of the muscle on MRI (Fig. 1). This appearance must not be mistaken with intra-lesion septa that are suggestive of an ALT, especially if they are more than 2 mm thick, or a dedifferentiated liposarcoma (DDLs). The lipoma may also be intermuscular (Fig. 2).

With large lipomas measuring more than 10 cm in the long axis, especially in the thigh, areas of fat necrosis can be observed, which have a different color than the fat. This could lead to an incorrect diagnosis of DDLs; however, this area does not have increased uptake upon gadolinium injection [7], contrary to a site of dedifferentiation.

On histological evaluation, this is a lesion made up of mature adipocytes without atypia. These tumors have a low risk of local recurrence, like their variants (see below) (< 5%) with no risk of deterioration to liposarcoma (LS).

There are several lipoma variants:

1.1.1.1. Lipoma arborescens

In this intra-articular tumor, the synovial tissue is replaced by mature adipocytes [3]. This is a “lipoma-like” lesion that generally affects only one joint, typically the knee, where it is located in the supra-patellar recess (Fig. 3). In all likelihood, this lipoma is a reaction to an underlying degenerative or inflammatory (rheumatoid arthritis) disease [8]. Recurrence is rare when the excision is complete.

1.1.1.2. Spindle cell/pleomorphic lipomas

This rarer entity occurs mostly in the superficial tissues, around the shoulder. Its appearance may be suggestive of a more aggressive lesion on MRI, as it generally contains little to no fatty tissue (Fig. 4). Consequently, a biopsy is often recommended before excision [3][5].

1.1.1.3. Lipomatosis

This is a diffuse, infiltrating proliferation, sometimes hereditary, of benign and mature adipose tissue that is not strictly speaking a tumor. It can be localized, multifocal or diffuse [3][5].

1.1.1.4. Hyperplasia/hypertrophy of fatty tissue

This corresponds to a focal abnormality of distribution in superficial fatty tissue, poorly delimited, that can be uncomfortable or unsightly for the patient. MRI shows hypertrophy of subcutaneous fatty lobules, with no true capsule or atypia.

1.1.1.5. Angiolipoma

This presents as a small sensitive subcutaneous tumor, sometimes multiple tumors, often in the forearm. It has a fatty appearance on imaging, with potential non-fatty areas that have increased uptake of gadolinium [5].

1.1.2. Tumors arising from brown fat tissue

Hibernoma is a tumor with no risk of degeneration that makes up less than 2% of all benign adipose tumors. It consists of a variable amount of white and brown fat, also present in hibernating animals. It is generally diagnosed in adults between the 3rd and 6th decade, predominantly in males. A hibernoma is slow growing, develops superficially in the thigh or shoulder. On MRI, it looks like a vascularized mass, with septa and a unique signal, intermediate between that of subcutaneous fat and that of muscle, which may not be eliminated on fat-suppressed imaging (FATSAT)[3][5][9].

1.1.3. Tumors containing fat

Some non-adipose tumors may contain adipose tissue, such as angiomas and mature myositis ossificans.

1.2. Tumor of intermediate malignancy

ALT, previous known as “well-differentiated liposarcoma” is a low-grade tumor with zero metastatic potential. This is the most frequent type of LS (40-50%) that mainly occurs between 50 and 70 years of age.

This is a slow-growing tumor that exceptionally develops in subcutaneous tissue. It is most often found in the thigh and more rarely found distal to the knee and elbow (Fig. 5). This lesion has the ability to enlarge existing anatomical orifices. It is often painless but large in size once discovered.

ALT may sometimes be difficult to differentiate from an ordinary lipoma based on anatomical pathology analysis. The presence of *MDM2* gene amplification on FISH indicates the presence of ALT. Three subtypes of ALT have been described: the “lipoma-like” LS,

sclerosing LS and inflammatory LS. The last two are rare types of ALT. However, sclerosing LS has a higher risk of local recurrence [10].

Only surgical treatment is recommended and consists of excision. After the initial excision, there is a higher risk of local recurrence than for lipoma, which is the primary expression of this intermediate malignancy with a risk of repeated recurrences. This recurrence risk varies between 3% and 17% [11][12] and typically occurs at 5.5 years on average, although recurrence beyond 10 years has also been reported.

ALT also has a risk of dedifferentiation of about 1.1% [11]. This risk is 8% in cases of local recurrence [12], which is the second expression of this intermediate malignancy.

1.3. Malignant adipose tumors

1.3.1. Dedifferentiated liposarcoma

This can occur either from an ALT, as mentioned above, or *de novo*. It occurs primarily in males, especially between the 5th and 7th decade. The dedifferentiated site generally has high-grade malignancy [13]. On imaging, a non-adipose tissue component is visible within the tumor (Fig. 6). Sometimes, the adipose component may be small in size or even not visible.

To validate the diagnosis, the biopsy must target a fleshy, non-fatty area on imaging. In anatomical pathology analysis, the *MDM2* gene is amplified like is typical for ALT and we find another high-grade tissue component corresponding to the dedifferentiated areas. The treatment is the same as STS.

The survival of these two types of DDLS at 5 and 10 years is 67% and 48%, respectively [13].

1.3.2. Myxoid liposarcoma (MLS)

MLS is a very specific entity. It occurs in young adults, generally under 50 years of age and often presents as a painless mass, located in the legs in the vast majority of cases (90%), particularly the thigh (75%) [14]. It is more often deep but has also been found in subcutaneous area. Its highly myxoid nature, thus very hydrated on MRI, may lead to the incorrect diagnosis of a cystic lesion if no gadolinium was injected (Figure 7). MRI may reveal sites of adipose tissue [15].

The morphology of MLS varies greatly, thus the presence of specific fusion genes (*FUS-DDIT3* or *EWSR1-DDIT3*) contributes to the diagnosis during microscopic analysis of the biopsy tissue.

Use of histological prognosis grading by the FNCLCC is not entirely appropriate for these tumors; the presence of more than 5% round cells is the more reliable criterion for poor outcome to evaluate the risk of metastasis [14].

The treatment is surgical, with excision of the tumor. MLS is more sensitive to radiation therapy than other sarcomas, which means that neoadjuvant (preoperative) radiation therapy should be considered. In some instances will make it possible to reduce the excision margins and to preserve neurovascular structures during excision [14]. This decision should be made beforehand by the MDTB.

Local recurrence is correlated to the presence of microscopically contaminated resection margins and the absence of supplementary external radiation therapy [14].

Survival without metastasis ranges between 69% and 84% at 5 years and 46% and 77% at 10 years [14][16]. MLS has an atypical metastatic capacity, very often extra-pulmonary (bone and soft tissues) initially, justifying initial staging and post-treatment follow-up by whole-body MRI and CT scan of the chest [16].

1.3.3. Pleomorphic liposarcoma (PLS)

PLS is the less frequent but more aggressive LS (high-grade). It mainly occurs in men above 60 years of age [2][17][18]. It develops quickly, especially in the lower limb (thigh and girdle), in subfascial position.

Imaging is suggestive of a sarcoma, with a necrotic component and minimal adipose contingent [19].

On anatomical pathology analysis, there is no specific marker and genomic analysis will not find *MDM2* gene amplification. These tumors are genetically complex, similar to undifferentiated pleomorphic sarcoma.

At 5 years, the survival rate is around 60%; survival without local recurrence is 48% and survival without metastasis is 50% [3][18].

1.3.4. Malignant tumors containing fat

Solitary fibrous tumor is a rare malignant tumor in the limbs, often deep, that contains fat on imaging [3].

2. What clinical and imaging findings of fat-containing soft tissue masses are suggestive of an adipose tumor?

2.1. Clinical and imaging assessment

2.1.1. Clinical examination

2.1.1.1 History taking

The goal is to look for family and personal history of “lipoma”. It is focused on the location of the tumor (history of trauma, surgery or other). In case of local recurrence of a fatty mass removed at a non-specialized center, the slides can be re-read by an anatomical pathologist from the RRePS to correct the diagnosis of “recurring lipoma” to an ALT. Current treatments such as anticoagulants are important to detect so they can be suspended when the biopsy is done.

The disease history can point to:

- rapid development, more specifically towards a high-grade lesion if an hourglass-like lipoma between two muscles suddenly forms a hernia and mimics an aggressive lesion.
- development over several years, more specifically towards a benign or intermediate grade lesion. Caution - a MLS can progress over several years like certain synovial sarcomas, especially superficial ones.

2.1.1.2 Examination

The exact location contributes to the diagnosis. For example, adipose tumors in the hand are very rarely malignant [20].

A superficial, mobile and small-size mass is more likely to be a lipoma, subject to imaging findings. A deep, older and large lesion in the thigh is more likely to be an ALT. A deep, older, painless lesion that suddenly increases in size is more likely to be a DDLS.

Deterioration of general health is not a good criterion as it is rare and late in the progression of high-grade lesions.

In tumors at the base of the limb, one should always be suspicious of a tumor that is in reality a “hernia” of a tumor in the chest wall or base of the neck or pelvis in the adjacent limb. The latter lesions are not discussed here.

2.1.2. Imaging evaluation

2.1.2.1. Ultrasonography

This is a simple, non-invasive, but operator-dependent modality that should ideally help to answer four questions to suggest a benign lesion:

- Size less than 5 cm?
- Position above the muscular fascia (which defines the superficial nature, not the fascia superficialis)?
- Fatty component like that of adjacent subcutaneous adipose tissue?
- Absence of vascularization?

If the answer to all these questions is “yes”, the assessment can stop here. If there is at least one “no” answer, this evaluation must be supplemented by MRI with gadolinium injection.

2.1.2.2. Standard X-rays

This is not essential. The only purpose is to look for any calcifications and their shape. Calcifications can be found in adipose tumors. It is also possible to find calcifications in vascular abnormalities where they are more rounded (phleboliths).

2.1.2.3. MRI

This is the key imaging modality. Its primary goal is to characterize the tumor to further improve the diagnosis. Routine intra-vascular gadolinium injection is not recommended in all adipose tumors in the initial diagnostic stage. For superficial adipose tumors that appear benign on ultrasound, it is not essential. Conversely, it is essential when dedifferentiation is suspected [21]. Nevertheless, its routine use improves the confidence in the diagnosis [22]. The secondary goal is to plan the diagnostic strategy (biopsy path) and then the treatment (surgical approach, resection margins).

2.1.2.4. CT scan

This is the modality of choice if MRI is contraindicated. An intravenous injection of iodine must be done.

2.2. Clinical and imaging guiding elements

Lipomas present as homogeneous fatty masses with a suggestive clinical history. PLS present as genuine high-grade sarcomas with no real ambiguity: older age, fast development, imaging showing necrotic tumor. MLS are more likely to be the source of diagnostic errors as they can develop slowly and be incorrectly interpreted as cystic lesions given the hyperintensity on T2-weighted images of myxoid tissue.

The main challenge is differentiating a lipoma from an ALT. The elements that suggest an ALT are a size more than 10 cm and the presence of septa more than 2 mm thick that take up contrast product [21][23][24].

Fouque *et al* [22] also proposed major, intermediate or minor criteria to differentiate malignant adipose tumors from benign adipose tumors, but they are only orientation criteria.

Major criteria:

- Size > 10 cm for tumors containing only fat in the limbs
- Presence of one or more non-adipose tissue contingents within the tumor: nodule or tissue mass and/or band of fat with atypical signal (different than that of subcutaneous fat) that must bring up the possibility of a dedifferentiated contingent

Intermediate criteria:

- Presence of several thick (> 2 mm) and/or irregular and/or nodular internal septa that take up a notable amount of gadolinium
- Tumor progression: change in size that is objective, visible clinically or on two successive imaging exams
- Recurrence after surgical resection

Minor criteria

- Presence of intra-tumoral calcifications
- Multinodular tumors
- Invasion of adjacent structures and/or bony erosions (minor criteria since rarely observed).

3. Biopsy - When? How? What?

3.1. When should a biopsy be done?

The decision to biopsy a fatty lesion in the limbs is based on several criteria:

- in supra-fascial or superficial lesions, the indication is reserved to very large tumors (> 10 cm) that have atypical clinical or imaging elements, as described previously (Fig. 6).
- it is routine for any deep fatty lesion with atypical findings on MRI (thick septa, hyperintensity of septa) and for lesions with dual tissue components (one of them being non-adipose).
- the size of the lesion is a decision point for deep homogeneous fatty masses without atypia [22]:
 - lesions less than 5 cm can be considered as benign and be controlled or enucleated.
 - lesions larger than 10 cm must be biopsied.

- lesions 5 to 10 cm must be discussed during a MDTB meeting; a decision is made on a case-by-case basis; in there is any doubt, these lesions must be biopsied.
- fatty lesions that have a reassuring appearance on MRI, less than 5 cm, subfascial and near a neurovascular bundle must be discussed on a case-by-case basis. Here again, if there is any doubt about the diagnosis based on MRI, a biopsy is indicated. It is crucial to avoid marginal surgery or enucleation of a malignant lesion that is neither a lipoma nor an ALT, which could compromise the fate of the involved neurovascular bundle during a potential re-excision. This is especially the case in the upper limb [20].

3.2. How should a biopsy be done?

The biopsy must be a percutaneous-needle biopsy (PNB) done with ultrasound guidance or more rarely CT guidance if the site is difficult to access (proximal lower limb in overweight patient, for example). Performing a PNB instead of a surgical biopsy is one of the good practices recommended by the French Sarcoma and Bone Tumor Study Groups (GSF-GETO) [4]. The PNB must be done at a NETSARC+ cancer center or by a radiologist trained at such a center who regularly does this intervention and who works with a pathologist in the RRePS network who will subsequently analyze this biopsy.

The technical methods were restated by Rochwerger and Mattei [25]: the percutaneous biopsy must be done after the MRI, explained to the patient beforehand, performed in strict aseptic conditions and typically under local anesthesia. The biopsy tract must be discussed with the surgeon doing the excision. The needle used must be large enough (14G to 16G). Multiple samples must be taken in multiple directions but always through the same orifice in the lesion. If a non-adipose component is isolated during the imaging, it must always be biopsied. The samples must be preserved both fixed and fresh (for molecular analysis). Surgical biopsy currently has little to no role in the diagnostic arsenal of adipose tumors in the limbs.

3.3. What can we expect from a biopsy?

Initially, all the samples will be evaluated macroscopically. Next, a microscopic analysis consists of confirming whether the tumor is made up of differentiated or non-differentiated adipose tissue, with a nuclear analysis (size, type), mitosis determination, analysis of fibrous tracts in the lesion and its vascularization. One also looks for any necrosis and the absence of lipoblasts.

An immunohistochemical analysis will be done using antibodies against HMGA2 and MDM2 [26]. The presence of HMGA2 confirms the biopsy was inside the lesion (whether a benign or intermediate-malignancy adipose tumor). A FISH analysis is done next to look for amplification of the *MDM2* gene, which is used to validate the diagnoses of ALT and DDLS. Other antibodies can be used to validate other diagnoses (e.g., myxoid lineage).

4. Which surgical technique should be used for different histological types of adipose tumors?

After an appropriate imaging assessment and MDTB meeting, surgical treatment can be proposed depending on the type of adipose tumor. Various types of excisions are possible, as defined by Enneking [27]:

- intra-lesional or fragmented: the tumor is exposed; the excision is partial, and the entire surgical site is contaminated by the tumor. Similarly, enucleation is done through an incision shorter than the length of the major axis of the tumor, with potential intra-capsular dissection.
- marginal: the dissection passes through the tumor's pseudo-capsule. In this type of resection, some tumor tissue may be left behind on a microscopic scale.
- large, en bloc: the excision is done as one block taking the tumor, its pseudo-capsule and a layer of healthy tissues.
- radical: at a minimum, this type of excision removes the entire compartment in which the tumor is located.

The system used by the GSF-GETO quantifies the residual tumor (R). Three groups have been defined [28][29]:

- R0: clear margins
- R1: potential microscopic remains
- R2: macroscopic tumor remains.

4.1. How is a lipoma removed?

For superficial lipomas, less than 5 cm in size, the removal is done through a short incision while pressing on the lesion to easily externalize it (enucleation). The small pedicle that remains is coagulated. A routine anatomical pathology analysis is recommended.

Deep intra-muscular lipomas generally do not have a capsule (Fig. 1) and may be difficult to dissociate from the muscle plane, especially in minimally compartmentalized muscles like the deltoid, triceps and gluteus maximus [30]. Muscle fibers can be embedded in the tumor, thus must be removed with the lesion.

Deep intermuscular lipomas are easily individualized and non-infiltrating (Fig. 2). Consequently, marginal excision is easier, with no need to excise healthy tissue, although special attention is needed with lesions circumscribed by neurological or vascular branches in particular anatomical sites (Scarpa triangle, elbow fold) [30].

4.2. How is an ALT removed?

Macroscopically, these lesions have several distinctive features. They generally have several peripheral envelopes. The tumor "lathers" inside these sheaths, which constitute the tumor capsule. Deep sheaths may contain large veins (Fig. 5E). Sometimes, the tumor curls around anatomical structures like bone or a large nerve trunk (Fig. 5A), leading to the appearance of an hourglass or that the nerve structure itself is included in the tumor.

A scheduled R1 marginal excision is easy since this capsule is completely individualized but it increases the risk of local recurrence. In some anatomical locations, local recurrence may be difficult to manage if it is near critical structures. Excision passing outside the most peripheral sheath is recommended, which will help to reduce the risk of local recurrence, by accepting an R1 excision in contact with critical structures [10].

4.3. How is a sarcoma removed?

This type of procedure must be planned [29], both for the resection and the reconstruction (flap, vascular bypass, associated bone or joint procedure), if the latter is needed. Prerequisites for the resection are appropriate, recent imaging (< 1 month for surgery), prior biopsy whose tract is discussed with the radiologist, anatomical pathology analysis by a pathologist who is a member of the RRePS network and discussion of the case in MDTB meeting and with the patient.

The aim is local control to limit the risk of local recurrence and to preserve function. The surgeon has the option to ensure local control if the tumor excision is planned and has clear margins (R0). The surgeon must have been trained in this type of procedure [31]. R0 excision reduces the risk of local recurrence and thereby increases survival without metastasis [28]. (Neo)adjuvant radiation therapy is now often done alongside, which further reduces the risk of local recurrence [32], particularly in case of MLS. Adjuvant treatments (radiation and chemotherapy) are proposed in case of metastasis (chemotherapy) or lesions that are difficult to control locally or for marginal surgery.

4.4. Special case: how is a biopsy-excision performed?

This consists of removing a tumor while treating it as a malignant tumor, thus *en bloc* and with clear margins, with no prior biopsy. After an exhaustive non-invasive assessment and discussion at the MDTB meeting, biopsy-excision can be proposed for small tumors (1 cm) where a biopsy will risk contaminating the healthy adjacent tissue beyond the tumor, and where clear margins can be obtained without sacrificing any adjacent critical structures.

5. How is a patient referred to a designated referral center for an opinion and/or management of adipose tumor?

The challenge is not managing benign lesions (lipoma) but in detecting malignant lesions and ALT in order to treat them correctly at a specialized center. Given the rarity of the lesions, a network of designated referral centers has been implemented in France [4] and in several other European countries [29][31]. Treatment of patients at a designated referral center has resulted in a significant improvement in terms of lower recurrence rate and increased overall survival [33].

Incorrect initial care of a malignant tumor compromises the patient's health and places the referral center team in a difficult position for the subsequent care. In case of ALT, revision can be discussed on a case-by-case basis, while proposing a wait-and-see approach if the excision was complete or a systematic re-excision in case of R2 resection. For LS, independent of its histology, the strategy will be adjusted to the histological prognostic grade for the tumor, to the type of initial excision (enucleation, marginal

surgery) and to the patient's cancer status (metastatic or not, reoperable or not). The treatment decision should only be taken at a sarcoma-specific MDTB (NETSARC in France).

However, it is not appropriate to send every patient who has a mass, particularly an adipose one, to the designated sarcoma center. For this reason, recommendations have been made by expert groups [22][34][35] to help physicians in their daily practice. It is incumbent upon each practitioner to request the initial diagnostic work-up (ultrasound, MRI) and to send the patient's records when the lesion is suspicious.

Radiologists play a central role by pointing out suspect lesions. The French Radiology Society thereby recommends adding the following wording to the imaging report, if a sarcoma is suspected: *"In accordance with the recommendations of the ESMO (European Society for Medical Oncology), it is recommended that the methods for treating this type of lesion be discussed at a referral sarcoma center [...]. In France, you can find a list of expert centers on the NetSarc (National network of centers approved by the INCa)..."*.

In France, the network can be consulted at www.expertisesarcome.org where the methods for forwarding the patient's medical records can be found. For the advice provided to be reliable and appropriate, the following basic information must be provided: age, medical history, treatment (particularly anticoagulants, which will affect the planning of any biopsies). The clinical history is important, as is the imaging. This imaging must be available for analysis on a PACS, so the tumor can be reconstructed in various planes, potentially to allow the radiologist to compare the images from various sequences. Lastly, the patient must be informed that an opinion has been requested from a referral center, since he/she may be contacted later on for the treatment.

Conclusion

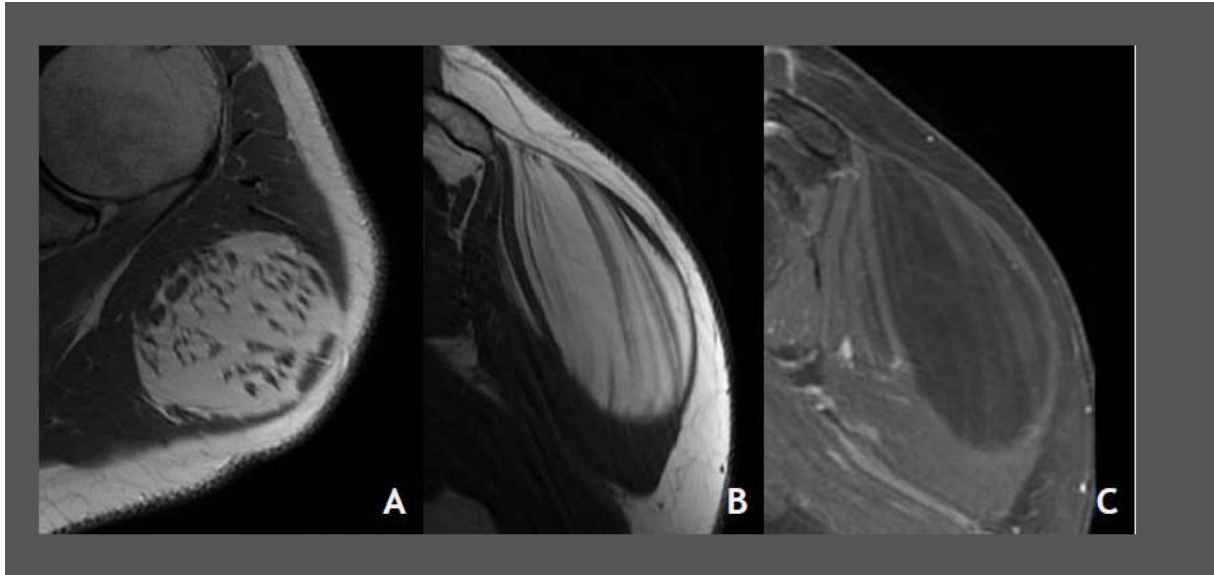
Adipose tumors are the most common tumors and are very often benign. They can be discovered incidentally or because they are symptomatic. Given their heterogeneity, a specialized opinion (surgical within the NETSARC and anatomical pathology within the RRePS) is needed when there are atypical clinical, imaging or pathological findings. By following certain treatment rules, non-planned excision of a sarcoma causing a loss of healing opportunity for the patient can also be avoided.

Conflicts of interest: no conflict to declare

Funding sources: none

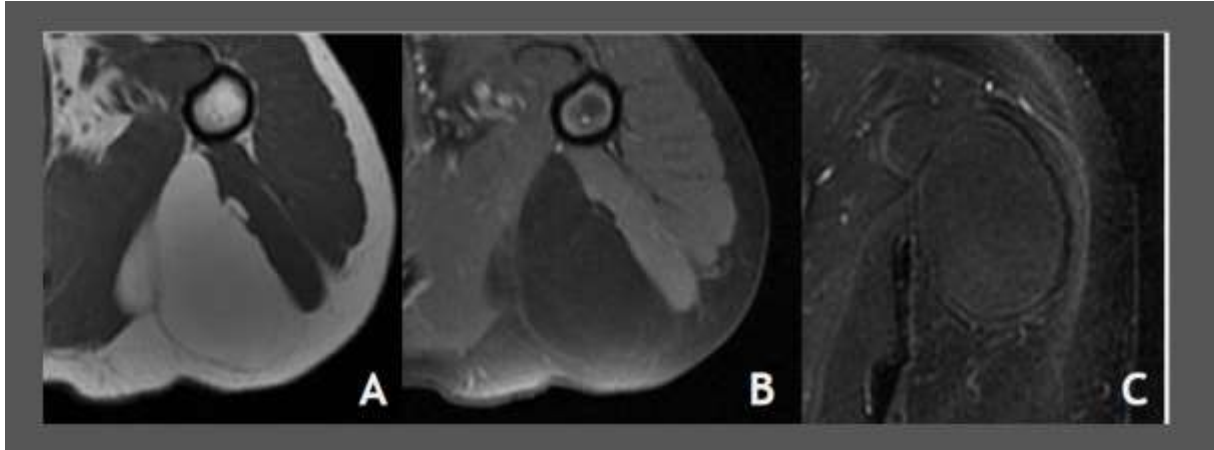
Author contribution: Louis-Romée Le Nail: design and drafting; Vincent Crenn: reviewing; Philippe Rosset: design and reviewing; Mickaël Ropars: design and drafting.

Figure 1 Deep intramuscular lipoma that developed in a deltoid muscle characterized by an MRI with axial T1-weighted sequence (A), sagittal T1-weighted sequence (B) showing a “combed” appearance of the muscle fibers. The tumor’s signal disappears on fat-saturated sequences and without uptake of gadolinium (C).



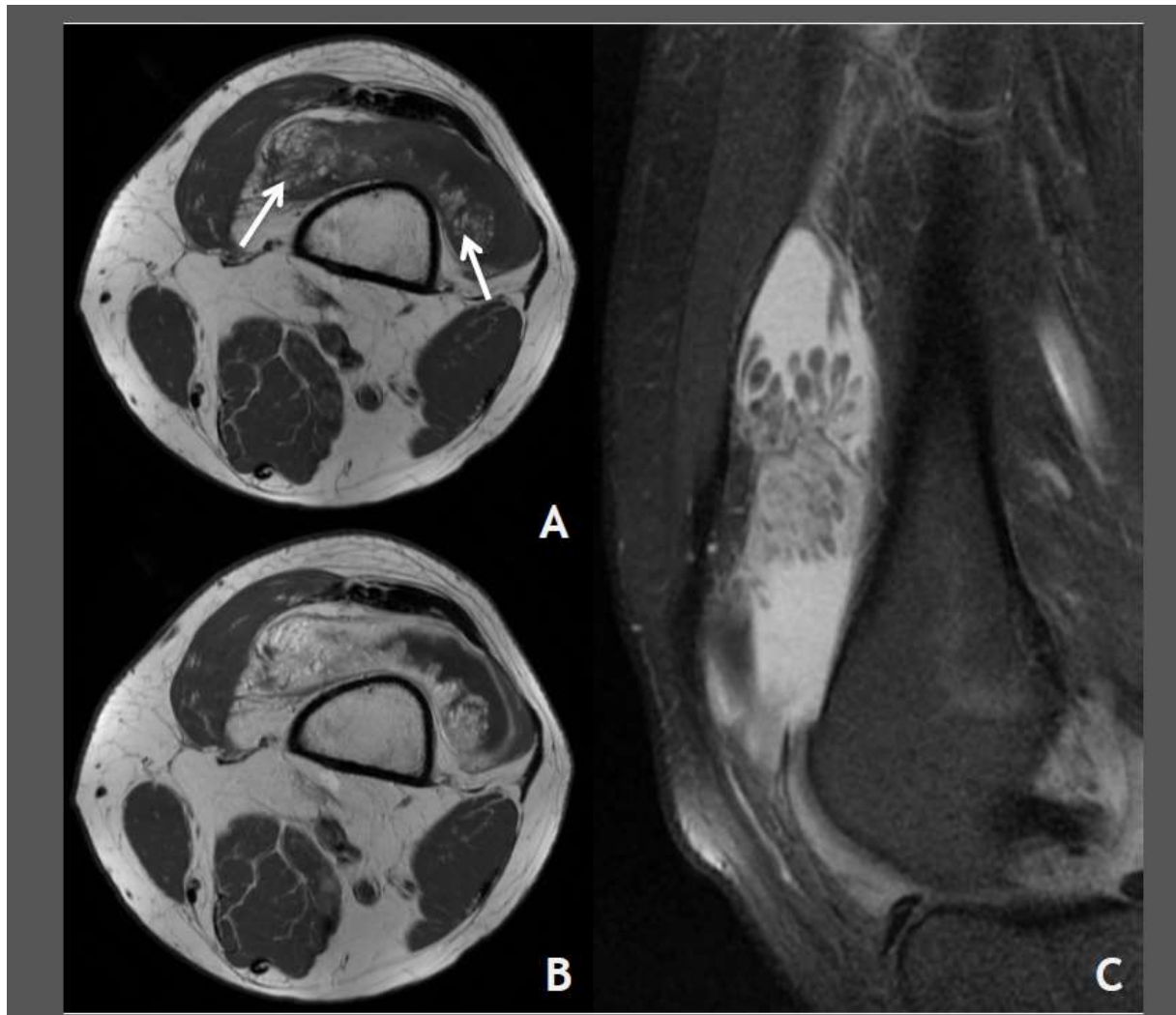
Journal Pre-proof

Figure 2 Deep intermuscular lipoma that developed between the heads of the triceps brachialis. Axial T1-weighted MRI (A) with fat-saturation and gadolinium injection (B) and coronal STIR (C) showing an adipose tumor without atypia.



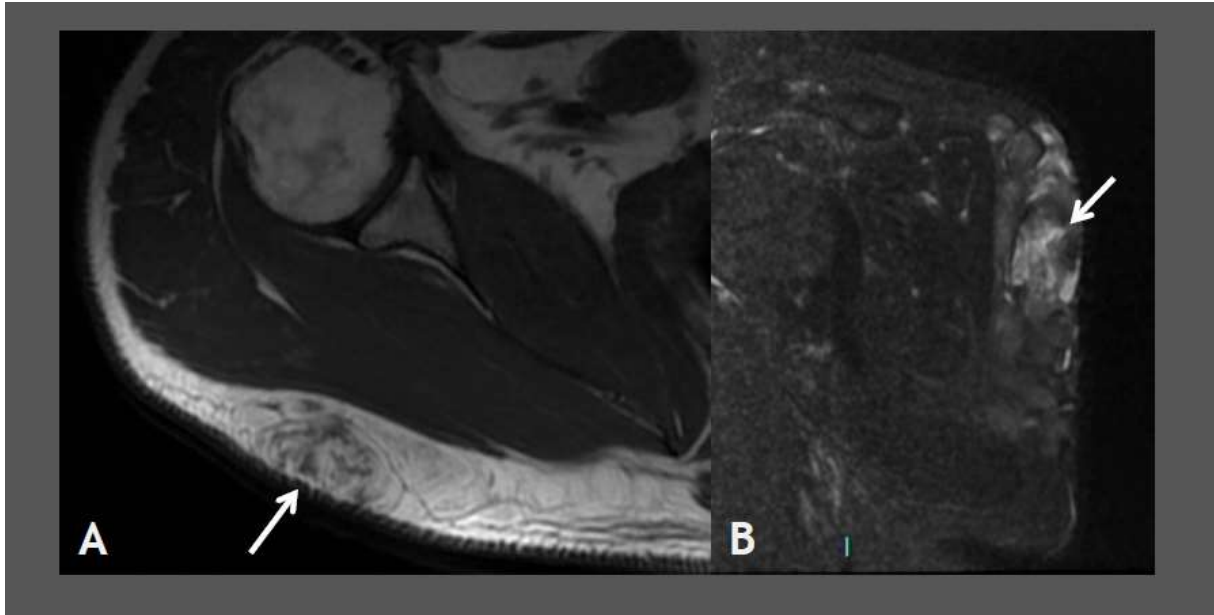
Journal Pre-proof

Figure 3 Arborescent lipoma in the knee quadriceps recess. Axial T1-weighted MRI (A) shows fatty regions inside the lesion (arrows) with gadolinium uptake in the remainder of the lesion (B). Sagittal T2-weighted sequence with fat-suppression showing the arborescent appearance (C).



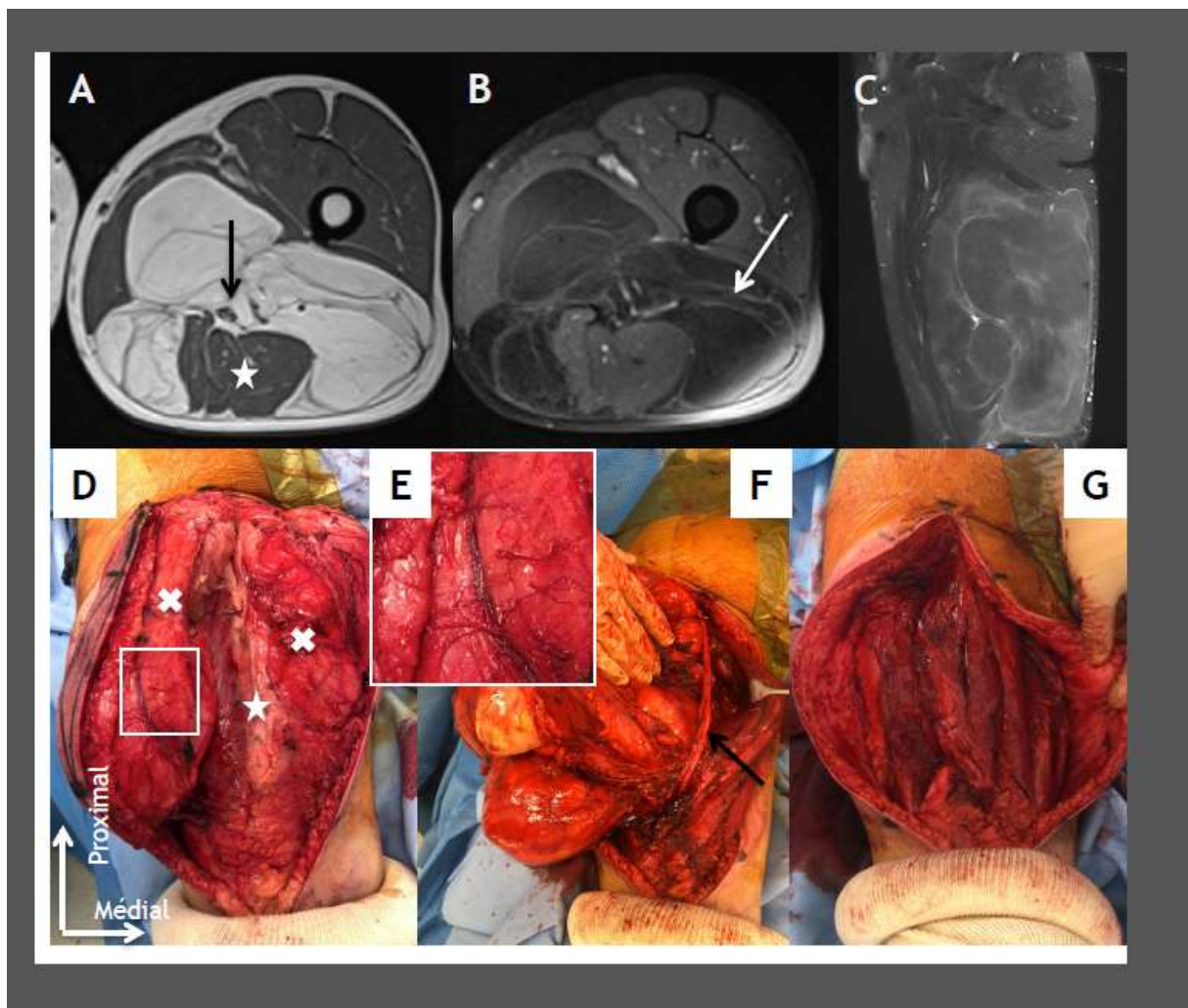
Journal Pre-proof

Figure 4 Subcutaneous spindle cell lipoma on the posterior side of the right shoulder on axial T1-weighted MRI slice (arrow) (A) showing uptake in the sagittal STIR slice (arrow) (B).



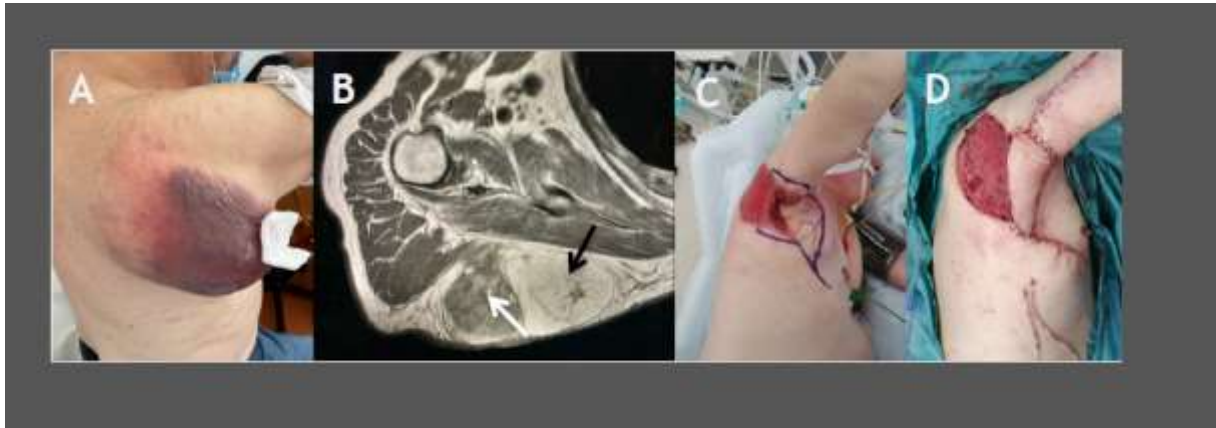Journal Pre

Figure 5 A 52-year-old patient who had a deep ALT in the thigh surrounding the sciatic nerve (black arrow) on MRI T1-weighted axial slice (A) and with backward repression of the hamstrings (star). Septa (white arrow) are present and have increased gadolinium uptake on T1-weighted sequences with fat suppression (B). Sagittal STIR sequence confirms the atypia (C). During planned R1 excision at the sciatic nerve (D), it was necessary to pass outside the tumor capsule which contains large veins (E) and to tilt the tumor (white X) around the sciatic nerve (black arrow) (F) to preserve it along with the hamstrings (G).



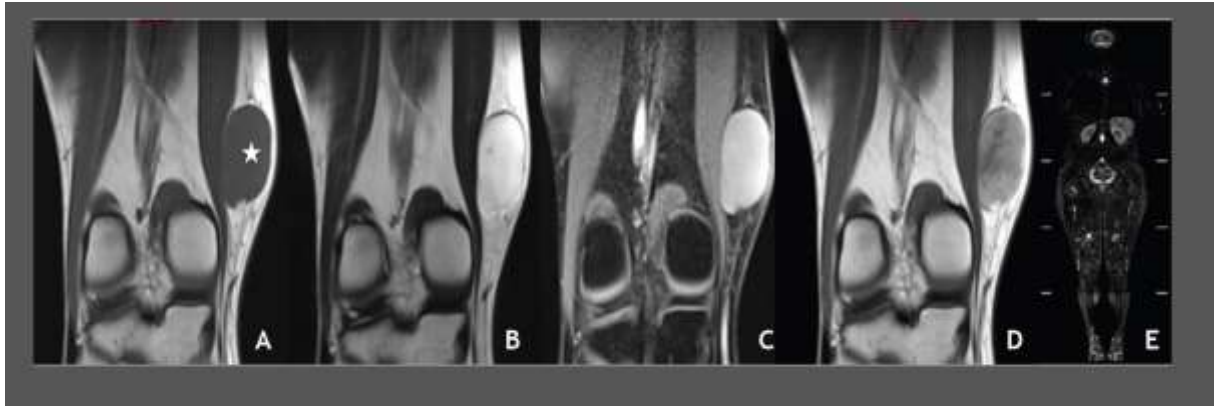
Journal Pre-proof

Figure 6 Dorsal superficial rapidly growing and worrisome lesion in an 87-year-old patient (A). Biopsy confirmed an atypical fatty tumor without dedifferentiation while MRI (B) shows a double tissue tumor component (white arrow) across the hematoma and fatty inside (black arrow); the biopsy did not target the non-adipose component. Given the hemorrhagic nature, urgent tumor resection that subsequently required revision of the margins (C) and coverage procedure (D). Confirmation of a DDLS.



Journal Pre-proof

Figure 7 A 25-year-old patient presenting with a myxoid liposarcoma on the medial side of the thigh (star). The lesion was painless and had been growing for 3 months. MRI provides effective characterization: the tumor has a hypointense signal on T1-weighted sequence (A), hyperintensity on T2-weighted sequence (B), has no fat content on T2 images with fat-suppression (C) and has gadolinium uptake on T1-weighted images (D). Extension assessment by whole-body MRI (E) and chest CT scan found no abnormalities.



References

- [1] De Pinieux G et Al. Nationwide incidence of sarcomas and connective tissue tumors of intermediate malignancy over four years using an expert pathology review network. *PLoS One*. 2021 Feb 25;16(2):e0246958.
doi: 10.1371/journal.pone.0246958.
- [2] Ducimetière F et al. Incidence of Sarcoma Histotypes and Molecular Subtypes in a Prospective Epidemiological Study with Central Pathology Review and Molecular Testing. *PLoS One* 2011;6(8):e20294. doi: 10.1371/journal.pone.0020294.
- [3] Soft tissue and bone tumours. Lyon, France: World Health Organization Classification of Tumours Editorial Board, 2020.
- [4] Honoré C, Méeus P, Stoeckle E, Bonvalot S. Soft tissue sarcoma in France in 2015: Epidemiology, classification and organization of clinical care. *J Visc Surg*. 2015 Sep;152(4):223-30.
doi: 10.1016/j.jviscsurg.2015.05.001.
- [5] Gupta P, Potti T, Wuertzer S, Lenchik L, and Pacholke D. Spectrum of Fat-containing Soft-Tissue Masses at MR Imaging: The Common, the Uncommon, the Characteristic, and the Sometimes Confusing. *Radiographics* May-Jun 2016;36(3):753-66.
doi: 10.1148/rg.2016150133.
- [6] Dalal K, Antonescu C, Singer S. Diagnosis and management of lipomatous tumors. *J Surg Oncol* 2008 Mar 15;97(4):298-313.
doi: 10.1002/jso.20975.
- [7] Chan L, Gee R, Keogh C, Munk P. Imaging Features of Fat Necrosis. *Am J Roentgenol* 2003 Oct;181(4):955-9. doi: 10.2214/ajr.181.4.1810955
- [8] Bancroft L, Kransdorf M, Peterson J, and O'Connor M. Benign fatty tumors: classification, clinical course, imaging appearance, and treatment. *Skeletal Radiol* 2006 Oct;35(10):719-33.
doi: 10.1007/s00256-006-0189-y.
- [9] Furlong M, Fanburg-Smith J, Miettinen M. The morphologic spectrum of hibernoma: a clinicopathologic study of 170 cases. *Am J Surg Pathol* 2001 Jun;25(6):809-14.
doi: 10.1097/00000478-200106000-00014.
- [10] Mussi C. Atypical Lipomatous Tumors: Should They be Treated Like Other Sarcoma or Not? Surgical Consideration from a Bi-Institutional Experience. *Ann Surg Oncol* 2014 Dec;21(13):4090-7.
doi: 10.1245/s10434-014-3855-7.
- [11] Choi K, Jost E, Mack L, Bouchard-Fortier. Surgical management of truncal and extremities atypical lipomatous tumors/well-differentiated liposarcoma: A systematic review of the literature. *Am J Surg* 2020 May;219(5):823-827.
doi: 10.1016/j.amjsurg.2020.01.046.
- [12] Rauh J et al. The role of surgical margins in atypical lipomatous tumours of the extremities. *BMC Musculoskelet Disord* 2018 May 17;19(1):152.
doi: 10.1186/s12891-018-2053-3.
- [13] Gootee J, Aurit S, Curtin C, and Silberstein P. Primary anatomical site, adjuvant therapy, and other prognostic variables for dedifferentiated liposarcoma. *J Cancer Res Clin Oncol* 2019 Jan;145(1):181-192. doi: 10.1007/s00432-018-2777-3.

- [14] Moreau L et al. Myxoid/round cell liposarcoma (MRCLS) revisited: an analysis of 418 primarily managed cases. *Ann Surg Oncol* 2012 Apr;19(4):1081-8.
doi: 10.1245/s10434-011-2127-z.
- [15] Petscavage-Thomas J, Walker E, Logie C, Clarke L, Duryea D, Murphey M. Soft-Tissue Myxomatous Lesions: Review of Salient Imaging Features with Pathologic Comparison. *RadioGraphics* 2014;34:964-80 doi.org/10.1148/rg.344130110
- [16] Gouin F et al. Early detection of multiple bone and extra-skeletal metastases by body magnetic resonance imaging (BMRI) after treatment of Myxoid/Round-Cell Liposarcoma (MRCLS). *Eur J Surg Oncol* 2019 Dec;45(12):2431-2436.
doi: 10.1016/j.ejso.2019.08.014.
- [17] Carvalho S, Pissaloux D, Crombé A, Coindre JM, Le Loarer F. Pleomorphic Sarcomas. *Surg Pathol Clin* 2019 Mar;12(1):63-105. doi: 10.1016/j.path.2018.10.004.
- [18] Gebhard S et al. Pleomorphic liposarcoma: clinicopathologic, immunohistochemical, and follow-up analysis of 63 cases: a study from the French Federation of Cancer Centers Sarcoma Group. *Am J Surg Pathol* 2002 May;26(5):601-16.
doi: 10.1097/00000478-200205000-00006.
- [19] Jagannathan J, Tirumani S, Ramaiya N. Imaging in Soft Tissue Sarcomas : Current Updates. *Surg Oncol Clin N Am* 2016 Oct;25(4):645-75. doi: 10.1016/j.soc.2016.05.002.**
- [20] Marteau E. Epidemiological, clinical and histological features of adipose tumors in the hand and wrist: Findings from a continuous series of 37 cases. *Orthop Traumatol Surg* 2020 Apr;106(2):329-334. doi: 10.1016/j.otsr.2019.12.011.
- [21] Kransdorf M, Murphey M. Imaging of Soft-Tissue Musculoskeletal Masses: Fundamental Concepts. *Radiographics*. 2016 Oct;36(6):1931-1948.
doi: 10.1148/rg.2016160084.
- [22] Fouque O et al. Stratégie diagnostique devant une tumeur graisseuse des tissus mous de l'adulte. *J Imag Diagn Interv* 2018;1:265-283 Doi : 10.1016/j.jidi.2017.11.001
- [23] Al-Ani Z, Fernando M, Wilkinson V, Kotnis N. The management of deep-seated, lowgrade lipomatous lesions. *Br J Radiol* 2018 Jun;91(1086):20170725.
doi: 10.1259/bjr.20170725.
- [24] Brisson M et al. MRI characteristics of lipoma and atypical lipomatous tumor/well-differentiated liposarcoma: retrospective comparison with histology and MDM2 gene amplification. *Skeletal Radiol* 2013 May;42(5):635-47.
doi: 10.1007/s00256-012-1517-z.
- [25] Rochwerger A, Mattei J-C. Management of soft tissue tumors of the musculoskeletal system. *Orthop Traumatol Surg Res* 2018 Feb;104(1S):S9-S17.
doi: 10.1016/j.otsr.2017.05.031.
- [26] Italiano A. Clinical and Biological Significance of CDK4 Amplification in Well-Differentiated and Dedifferentiated Liposarcomas. *Clin Cancer Res* 2009 Sep 15;15(18):5696-703.
doi: 10.1158/1078-0432.CCR-08-3185.
- [27] Enneking W, Spanier S, Goodman M. A system for the surgical staging of musculoskeletal sarcoma. *Clin Orthop Relat Res*. Nov-Dec 1980;(153):106-20.

- [28] Lintz F, Moreau A, Odri G-A, Waast D, Maillard O, Gouin F. Critical study of resection margins in adult soft-tissue sarcoma surgery. *Orthop Traumatol Surg Res* 2012 Jun;98(4 Suppl):S9-18. doi: 10.1016/j.otsr.2012.04.006.
- [29] Stoeckle E, Coindre J-M, Kind M, Kantor G, Bui B. Evaluating Surgery Quality in Soft Tissue Sarcoma. *Treatment of Bone and Soft Tissue Sarcomas. Recent Results Cancer Res* . 2009;179:229-42.
doi: 10.1007/978-3-540-77960-5_14.
- [30] Nishida J et al. Imaging characteristics of deep-seated lipomatous tumors: intramuscular lipoma, intermuscular lipoma, and lipoma-like liposarcoma. *J Orthop Sci* 2007 Nov;12(6):533-41. doi: 10.1007/s00776-007-1177-3.
- [31] Andritsch E et al. ECCO Essential Requirements for Quality Cancer Care: Soft Tissue Sarcoma in Adults and Bone Sarcoma. A critical review. *Crit Rev Oncol Hematol* 2017 Feb;110:94-105.
doi: 10.1016/j.critrevonc.2016.12.002.
- [32] Yang J et al. Randomized prospective study of the benefit of adjuvant radiation therapy in the treatment of soft tissue sarcomas of the extremity. *J Clin Oncol* 1998 Jan;16(1):197-203.
doi: 10.1200/JCO.1998.16.1.197.
- [33] Blay J-Y et al. Surgery in reference centers improves survival of sarcoma patients: a nationwide study. *Ann Oncol* 2019 Jul 1;30(7):1143-1153.
doi: 10.1093/annonc/mdz124.
- [34] Casali P et al. Soft tissue and visceral sarcomas: ESMO-EURACAN Clinical Practice Guidelines for diagnosis, treatment and follow-up. *Ann Oncol* 2018 Oct 1;29(Suppl 4):iv51-iv67.
doi: 10.1093/annonc/mdy096.
- [35] Dangoor A, Seddon B, Gerrand C, Grimer R, Whelan J, and Judson I. UK guidelines for the management of soft tissue sarcomas. *Clin Sarcoma Res* 2016 Nov 15;6:20.
doi: 10.1186/s13569-016-0060-4.