



**HAL**  
open science

## **Interventional magnetic-resonance-guided cryotherapy combined with microsurgery for recurrent glioblastoma: An innovative treatment?**

Hélène Cebula, Julien Garnon, Julien Todeschi, Georges Noel, B. Lhermitte, Charles-Henry Mallereau, S. Chibbaro, Hélène Burckel, R. Schott, Michel de Mathelin, et al.

► **To cite this version:**

Hélène Cebula, Julien Garnon, Julien Todeschi, Georges Noel, B. Lhermitte, et al.. Interventional magnetic-resonance-guided cryotherapy combined with microsurgery for recurrent glioblastoma: An innovative treatment?. Neurochirurgie, 2021, 10.1016/j.neuchi.2021.11.004 . hal-03511506

**HAL Id: hal-03511506**

**<https://hal.science/hal-03511506>**

Submitted on 22 Jul 2024

**HAL** is a multi-disciplinary open access archive for the deposit and dissemination of scientific research documents, whether they are published or not. The documents may come from teaching and research institutions in France or abroad, or from public or private research centers.

L'archive ouverte pluridisciplinaire **HAL**, est destinée au dépôt et à la diffusion de documents scientifiques de niveau recherche, publiés ou non, émanant des établissements d'enseignement et de recherche français ou étrangers, des laboratoires publics ou privés.



Distributed under a Creative Commons Attribution - NonCommercial 4.0 International License

## **Interventional Magnetic-Resonance-Guided Cryotherapy Combined with Microsurgery for Recurrent Glioblastoma: An Innovative Treatment?**

### **AUTHOR INFORMATION**

\* Helene CEBULA <sup>1</sup>, Julien GARNON <sup>2</sup>, Julien TODESCHI<sup>1</sup>, Georges NOEL <sup>3</sup>, Benoit LHERMITTE <sup>4</sup>, Charles-Henry MALLEREAU <sup>1</sup>, Salvatore CHIBBARO <sup>1</sup>, Helene BURCKEL <sup>5</sup>, Roland SCHOTT <sup>5</sup>, Michel DE MATHELIN <sup>6</sup>, Afshin GANGI <sup>2</sup>, Francois PROUST <sup>1</sup>.

<sup>1</sup>Department of Neurosurgery, University Hospital of Strasbourg, France

<sup>2</sup>Department of Interventional Radiology, University Hospital of Strasbourg, France

<sup>3</sup>Department of Radiation Therapy, ICANS, Strasbourg, France

<sup>4</sup>Department of Histology, University Hospital of Strasbourg, France

<sup>5</sup>Department of Medical Oncology, ICANS, Strasbourg, France

<sup>6</sup>Icube-UMR 7357 Télécom Physique, Strasbourg, France

Corresponding Author:

\* Helene CEBULA

Email: [helene.cebula@hotmail.fr](mailto:helene.cebula@hotmail.fr)

Hautepierre Hospital,

1, Avenue Molière

67200 Strasbourg

Disclosure of interest : the authors have no conflicts of interest to disclose

## **ABSTRACT**

**Background:** Glioblastoma invariably recurs after primary Stupp tumor therapy and portends a poor prognosis. Cryoablation is a well-established treatment strategy for extra-cranial tumors. The safety and efficacy of interventional MR-guided cryoablation (iMRgC) has not been explored in recurrent glioblastoma.

**Methods:** A retrospective analysis of data collected over a period of 24 months was performed. The inclusion criteria were: (I) recurrent glioblastoma despite Stupp protocol; (II) MRI followed by histological confirmation of recurrent glioblastoma; (III) location allowing iMRgC followed by microsurgical resection; and (IV) patient's consent. The primary objective was to assess feasibility in terms of complications. The secondary objective was to analyze progression-free survival (PFS), post-iMRgC survival and overall survival (OS).

**Results:** The study included 6 patients, with a mean age of  $67 \pm 7.6$  years [range, 54-70 years].

No major complications were observed.

Median PFS was 7.5 months [IQR 3.75-9.75] and 6-month PFS was 50%. Median post-iMRgC survival was 9 months [IQR 7.5-15.25] and 6-month post-iMRgC survival was 80%. Median OS was 22.5 months [IQR 21.75-30].

**Conclusion:** iMRgC for recurrent glioblastoma demonstrated a good safety profile, with no major complications. Our data suggest improved PFS and OS.

## **RESUME :**

**Introduction :** La récurrence de glioblastome est inéluctable malgré le protocole STUPP, avec pronostic sombre. La cryothérapie est une thérapie bien établie dans les tumeurs extra-cérébrales. La faisabilité et l'efficacité de la cryothérapie guidée par IRM n'a pas encore été étudiée dans la prise en charge des glioblastomes.

**Méthodes :** Une analyse rétrospective a été réalisée sur 24 mois. Les critères d'inclusion étaient : 1) récurrence de Glioblastome après le protocole STUPP ; 2) confirmation de la récurrence par IRM et histologie ; 3) localisation permettant de réaliser le traitement combiné de cryothérapie guidée par IRM suivi par la résection microchirurgicale; 4) consentement du patient. L'objectif primaire était l'analyse de la faisabilité de la technique par le taux de complications. L'objectif secondaire était l'analyse des taux de survie : survie sans progression, survie post cryothérapie, survie globale.

Résultats : L'étude a inclus 6 patients. L'âge moyen était de 67 ans  $\pm$  7.6 [54-70]. Aucune complication majeure n'a été observée. La survie sans progression était de 7.5 mois [IQR 3.75-9.75] et le taux de survie sans progression à 6 mois de 50%. La médiane de survie post cryothérapie était de 9 mois [IQR 7.5-15.25] et le taux de survie post cryothérapie à 6 mois de 80%. La médiane de survie globale était de 22.5 mois [IQR 21.75-30].

Conclusion : La cryothérapie guidée par IRM pour la récurrence de glioblastome est une technique qui a démontré sa faisabilité sans complications majeures. Nos résultats suggèrent une amélioration de la survie sans progression et de la survie globale.

**Key Words:** Recurrent glioblastoma, MRI guided, iMRI, cryotherapy, immunomodulation

Mots-clés: récurrence de glioblastome, cryothérapie guidée par IRM, cryothérapie, immunomodulation

**Short Title:** Cryotherapy for recurrent glioblastomas

Trial registration number: n° IRB00011687 retrospectively registered on July 7<sup>th</sup> 2021.

## **INTRODUCTION**

Glioblastoma is the most aggressive malignant primary brain tumor in adults with a median overall survival (OS) of around 14 months [1]. Recurrent Glioblastoma (GBM) invariably follows primary tumor therapy and portends a poor prognosis. No standard treatment exists for recurrent GBM despite several randomized studies [1][2]. Repeat surgery, repeat irradiation, and second-line chemotherapy typically achieve 13% to 52% 6-months progression-free survival rates with a median OS from the time of recurrence of 8 months or less [2][1][3]. Thus, with each innovative treatment modality resides a real opportunity to improve outcomes of patients with glioblastoma.

Significant progress has been made in understanding the molecular characteristics of GBM, as well as potential targeted therapy and immunotherapy. New therapeutic strategies including carmustine wafer implantation, laser-induced interstitial thermotherapy, high-intensity focused ultrasound ablation therapy, molecular targets, cell-based immunotherapy, vaccine therapy have been described, advocating promising results[4][5][6][7].[8]

In parallel, iMRgC has been developed as an established treatment for extra-cranial tumors such as skin, lung, breast, esophagus, hepatic, kidney, prostate and bone tumors [9]. A complex cascade has been recognized of well described anti-tumoral effects: direct cellular injury, apoptotic and necrotic response, micro-circulatory occlusion and immunomodulatory effects[10][11][12].

In the current study, we introduce our experience of treating recurrent glioblastomas with iMRgC. The primary objective was to analyze the safety of this technique with the analysis of potential complications. The secondary objective was to assess progression-free survival (PFS), post-iMRgC survival (PCS) and the OS.

## **METHODS**

### **1. Study design**

A retrospective analysis of collected data was performed to evaluate iMRgC combined with microsurgical resection for recurrent of GBM (n° IRB00011687). Data on these patients was collected over a period of 24 months (February 2018 to December 2020). Each case was discussed in our institutional multidisciplinary tumor board with radiologists, medical oncologists, radiation oncologists and neurosurgeons, in order to optimize the therapeutic

strategies and to plan both surgical and iMRgC procedures. The primary objective was to assess the safety of iMRgC as an adjunct treatment for recurrent glioblastomas by describing the postoperative complications.

The secondary objective was to analyze the survival rates and the secondary endpoints were the Karnofsky Performance Status (KPS) pre and post-treatment, the PFS, PCS and OS[13].

The hospital's Ethics Committee approved this study and all patients gave informed consent. All patients were informed about the experimental character of this type of surgical therapy and provided informed consent. The present collection of patient data was not from a planned, prospective study and retrospective data were intensely discussed with the local ethical committee.

## **2. Population**

The inclusion criteria were : (I) patients with recurrent Glioblastoma after Stupp protocol, concomitant radiochemotherapy and 6 cycles of temozolomide according to the European Organisation for Research and Treatment of Cancer (EORTC)[14]; (II) MRI imaging followed by histological confirmation of recurrent glioblastoma; (III) location accessible to iMRgC followed by micro surgical resection: this had to be focal, without ventricular and / or meningeal dissemination and at a distance from eloquent areas.; (IV) delay between the recurrence's diagnosis and the iMRgC was between 15 days and one month without modification of the size of the tumor and (V) patient's consent.

Exclusion criteria were: (I) patients younger than 18 years; (II) tumors not amenable to surgical resection and (III) altered cognitive status, by a joint evaluation between the neurosurgeon, the oncologist and the radiotherapist.

## **3. Pre-iMRgC period**

Variables extracted from medical records included; patient demographics data (age, gender), clinical evaluation according to the KPS score on admission; initial characteristics of the glioblastomas (location, side, histology, methylation MGMT); delay of any recurrence and radiological analysis of the lesions. All patients underwent a preoperative MRI including T1 before and after gadolinium injection, T2-weighted and perfusion sequences. Volumetric analysis was achieved by manually segmenting the lesion enhanced by gadolinium as demonstrated on each image in the sequence (the contoured area was then extrapolated in accordance to the acquired slice thickness).

#### **4. iMRgC procedure**

Magnetic resonance imaging-guidance was used to perform cryoablation on recurrent glioblastomas under general anesthesia. The number of cryoprobes required depended upon the size of the tumors. All procedures were performed in an operating suite utilizing intraoperative 1.5 Tesla MRI (Magnetom Area, Siemens Healthcare, Germany).

Three stages succeeded one another. First, the surgeon (HC, FP) initiated surgical dissection (skin incision, bone flap and dura opening) on a detachable table in the operating room next to the MR suite to expose the tumor and resected biopsy samples to confirm GBM recurrence. Following draping of the exposed surgical wound, the patient was transferred to the interventional MRI suite (Magnetom Aera, Siemens, Germany) under general anesthesia equipped with an MRI compatible cryoablation generator (Visual Ice MRI, Boston Medical, USA). The first two patients were positioned head first and the remaining four were positioned feet first to facilitate access for probe placement inside the brain. Axial, sagittal and coronal T2 and T1 contrast-enhanced images were acquired for planning using a flexible coil that was wrapped around the patient's skull. The number and types of cryoprobes (MR compatible IceRod and IceSeed, Boston Medical, USA) were chosen to generate an iceball that would approximate the size of the lesion, with a typical interprobe distance of 15 mm. Under near real-time MR fluoroscopic guidance in three orthogonal planes (BEAT-IRTTT sequence, Siemens Corporate Research & Technology, Center for Applied Medical Imaging, Baltimore, MD, USA), the probes were advanced by the interventional radiologists (JG, AG) and the surgeons (HC; FP) into the target tumor along pre-planned trajectories avoiding non-target sulci, gyri and vessels (Figure 1). Proper positioning of the probes was confirmed using fast-spin echo T2 weighted imaging. Following initiation of freezing, the growth of the iceball was monitored every 2 minutes using fast-spin echo T2 weighted imaging in three orthogonal planes. Freezing was stopped as soon as the iceball encompassed the entirety of the target tumor without looking for safety margins to avoid any damage to the normal surrounding parenchyma. After 30 seconds of active thawing, the probes were withdrawn, without attempting a second freezing phase (i.e. single freeze protocol). The final step was to resect the necrotic foci as a result of cryoablation. For this step, patients were transferred back to the operating room. The surgeon resected the necrotic margins and took further biopsies followed by closure (dura closure, replacement of the bone flap, skin closure). Histological analysis was conducted on all tumor samples.

At the end of the procedure, following extubation, patients were admitted to the neurosurgical intensive care unit for postoperative observation. One patient received steroids (Case no. 1 on Table 1).

## **5. Outcome evaluation**

The variables extracted after iMRgC from the medical records were:

- *Clinical evaluation* according the KPS at one-month after iMRgC.
- *Adjuvant treatments* following iMRgC and for recurrent disease Post-iMRgC (radiotherapy and/or chemotherapy such as temozolomide, lomustine, bevacizumab or irinotecan).
- *Radiological analysis* included a detailed postoperative MRI including T1 before and after gadolinium injection and T2-weighted sequences, a perfusion sequence (one per day for five days after iMRgC procedure) and subsequently at 3-month intervals. Conventional anatomic and gadolinium-enhanced MR images were acquired at each imaging time point following the same MR imaging protocol. All MR images were obtained with a 3Tesla MR imaging scanner with 1.2-mm section thickness and a 0.9-mm intersection gap. Postcontrast MRI images were acquired 10 minutes after intravenous injection of 0.5 mL/kg Gd-based contrast agent (gadoteric acid). A volumetric analysis was realized by contouring the gadolinium enhancing section by section to obtain a Region of Interest (ROI) volume in cubic centimeters. Enhancing ROI were manually drawn on each slide. All radiological analysis were realized by an independent blinded senior neuroradiologist.
- *Postoperative complications were classified as:* new neurological deficit, surgical site infection and medical complications (venous thrombosis, pulmonary embolism, urinary tract infection).
- *Progression free survival:* the time from the iMRgC procedure to recorded disease recurrence on MRI according to RANO criteria [15].
- *Six-month PFS:* percentage of patients who remained alive and progression-free at 6 months after iMRgC.
- *Survival Post-iMRgC:* the length time between the iMRgC procedure and death.
- *Overall survival:* the length time between the initial diagnosis and death.

## **6. Statistical analysis**

Using JMP software (version 6.0.3 from SAS Institute Inc.), numeric variables (age, Karnosky performance Status, volume) were considered as continuous variables and expressed as means and standard deviations. Categorical variables (gender ratio; surgical procedures; surgical complications) considered as ordinal variables and expressed in



proportions taking into account a CI 95%. Survival analysis and follow-up were performed using the Kaplan-Meier method with CI 95%. Median values were reported for survival measures with interquartile ranges (IQR) [Q1-Q3].

## RESULTS

### Patient characteristics

The study included 6 patients with recurrent GBM. Demographic characteristics are summarized in table 1. The mean patient age at the time of the iMRgC procedure was 67 yr  $\pm$  7.6 [range 54-70 yr] and gender ratio was 1:1(3 males: 3 females). The mean pre-iMRgC KPS was 70  $\pm$  15 [range 50-90].

Tumor locations were frontal (Cases #1-4-5-6), temporal (Case #2) and parietal (Case #3). All recurrences were localized to the same site as the initial diagnosis. The mean pretreatment tumor volume was 8.3 cm<sup>3</sup>  $\pm$  2.6 [range 3.6-10.4]. Four patients (Cases #2-3-4-5) presented with MGMT methylation of the initial tumor and IDH1 was positive for one patient (Case #5).

Characteristics of iMRgC are summarized in Table 1. The majority of patients required 3 (n=4) or 4 (n=2) probe trajectories. A single freeze protocol was performed in all cases with a total freezing time of 8 min (n=2) and 10 min (n=4) (Table 1).

Postoperative MRI showed complete resection for all patients. Between one and six months, increased contrast enhancement after gadolinium injection in the surgical bed was observed in all patients. For four patients, this contrast enhancement decreased after six months without signs of tumoral recurrence (Cases #1-4-5-6). One patient required a biopsy secondary to postcontrast enhancement on MRI and the biopsy excluded recurrence (described on the Illustrative Case -Figure 2, Case #1 in Table 1). The perfusion sequence at the onset of contrast enhancement showed the absence of neoangiogenesis with a rCBV <2. Since three of the six patients had not received treatment, we believe that the contrast enhancement corresponded more to an opening of the blood-brain barrier. Contrast enhancement appeared between the first and sixth months on average at 2.83 months, while the postoperative MRI showed no contrast enhancement. The volume of the contrast enhancement was 9.6 cm<sup>3</sup> (1.52-23.55 cm<sup>3</sup>).

The choice of adjuvant therapy following iMRgC was decided following multidisciplinary tumor board discussion. Three patients received a follow-up without adjuvant treatment since

a new recurrence (Cases #1-2-3). Two other patients received temozolomide (Cases #4-5) and one irinotecan and bevacizumab (Case #6) after iMRgC.

### **Postoperative Complications**

The observed complications were summarized in Table 1. All patients described self-limiting lethargy for one week. One patient had a transient ptosis secondary to temporary paresis of the levator eyelid muscle (Case #5). One patient was reoperated for scar revision 1 month later without deep infection (Case #1). No other neurological deficit was observed.

### **Clinical outcome**

Clinical results were summarized in Table 1. The mean post-iMRgC KPS was  $68 \pm 15$  [ range 50-90].

The median follow-up after the initial diagnosis and the iMRgC were 30 months [IQR 22.25-47.5] and 11 months [IQR 8.5-15.75] respectively. The median PFS and the 6-months PFS rate were 7.5 months [IQR 3.75-9.75] and 50%, respectively (Figure 3a). The median PCS and the 6-month PCS rate were 9 months [IQR 7.5-15.25] and 80%, respectively (Figure 3b). The median OS was 22.5 months [IQR 21.75-30] (Figure 3c). At present time, two patients remain alive after 12 and 17 months of follow-up following iMRgC.

## **DISCUSSION**

iMRgC is feasible for recurrent glioblastomas without major complications and neurological deterioration. However, this strategy requires strong multidisciplinary collaboration between the interventional radiologists, neurosurgeons, medical oncologists and radiation oncologists.

### *Feasibility of iMRgC*

iMRgC is a locoregional procedure, which is followed by micro surgical resection to decrease potential postoperative complications. Two articles have described iMRgC for brain tumors and the potential complications especially edema and hematoma[16][17].

Li et al. described iMRgC of cystic metastatic brain tumors in six patients[16]. The localizations were: left temporal lobe, cerebellum, parietal and basal ganglia area. A drill hole was made and the dura was opened. The patient was transferred into the MRI device. Tumor cyst aspiration was performed before the iMRgC. One patient died of a secondary

complication 12 days following iMRgC. All the other patients tolerated the procedure without neurological deficits. The second study, published by Martynov et al., analyzed 88 patients with supratentorial gliomas, not suitable for microsurgical resection, treated by stereotactic cryodestruction[17]. These were located in the cerebral lobes, insula, internal capsules, thalami, and corpus callosum and the histology of the lesions were variable (oligodendroglioma, diffuse astrocytomas, anaplastic astrocytomas and glioblastomas). Surgical complications were identified in 11.4% of cases (hematoma n=4, brain edema n=2, infection=4) with 1.1% postoperative mortality. Three patients underwent a craniotomy after cryodestruction to evacuate blood clot or necrotic tissue. Neurological deficit was observed in 42 % of cases including 8% permanent deterioration of neurological function.

This last study assessed iMRgC without tumor resection and the rate of complication was higher than the study published by Li et al[16]. In this study, aspiration of the cyst prior to iMRgC could explain the lack of complication by reducing mass effect. These potential complications are explained by the complex cascade secondary to iMRgC: direct cellular injury by extra and intra-cellular ice crystal formation, induction of rapid membrane-based apoptotic response and post-thaw necrosis, micro-circulatory occlusion associated with coagulative necrosis due to vascular stasis[18].

In our study, the combination of iMRgC and microsurgery was found to decrease the risk of intracranial hypertension by edema and hematoma. We removed the necrotic area providing cerebral oedema but the effect of cryotherapy is not counteracted by the excision of this necrotic area because the main mechanisms are around the iceball with an immunomodulatory effect in particular.

The aim was to combine cryotherapy with microsurgery in order to stimulate the immune system, unlike surgery alone. In subsequent studies, cryotherapy could be combined with awake surgery effectively and allow to increase the surgical indications.

### *Clinical outcome*

Despite many clinical trials, there are no established guidelines for the treatment of recurrent GBMs.

Tumor resection represents an adjuvant treatment strategy for recurrent glioblastomas[19]. Prospectively collected clinical data from the DIRECTOR cohort found a PFS of 2 months after surgery at recurrence and a survival post recurrence of 11.4 months and a longitudinal study identified a median postoperative survival at 12.4 months[20][21]. If we assess our survival against the results of the COCHRANE study on a meta-analysis of recurrence of

GBM, the PFS obtained at 7.5 months is higher than the results found ranging from 1.5 to 4.2 months[8]. The limit of this criterion is the time taken to perform the MRI to analyze the progression. In our study, an MRI was performed every 3 months (according to RANO criteria) or earlier depending on the occurrence of clinical deterioration.

Repeated radiotherapy is an option for patients with recurrent glioblastoma[22]. A prospective study reported a PFS of 3,9 months with combination of stereotactic radiosurgery and bevacizumab and cohort study found after re-irradiation using fractionated stereotactic radiotherapy a median survival of 7 months[23][24].

A plethora of monotherapy and combination of chemotherapy have been evaluated in patients with recurrent GBM [2,17,23]. Six-months PFS with nitrosourea agents, temozolomide or bevacizumab ranged between 17.5% and 52%, 18% and 21% and 29% and 42%, respectively [19][25]. With bevacizumab, median PFS ranged between 4 and 4.2 months[25]. The BELOB trial, a phase 2 trial randomizing Lomustine alone, Bevacizumab alone and combination of both treatments, reported a 6-months PFS of 16%, 13%, and 50%, and a median PFS of 3, 1 and 11 months respectively[26].

In summary, in these studies, 6-months and median PFS remains difficult to interpret because of the heterogeneous cohorts, disease heterogeneity and selection biases. In this context, our results seem favorable with a 6-months PFS of 50% and a median PFS of 7.5 months. **Any** conclusion affirming a gain in survival would be hasty. We have demonstrated the feasibility of the technique with the absence of serious adverse effects with preservation or even a slight improvement in survival in these 6 patients.

### *Study Limitations*

Limitations of the present study are its' single center design, the surgical location and the small sample size. The different adjuvant treatments represent a possible bias for the interpretation of the survival curve. However, this study is the prospective collected data including a multidisciplinary decision, precise criteria to include patient and a strict MRI procedure for the follow-up.

## **CONCLUSION**

IMRgC is a safe, precise and effective treatment for recurrent glioblastomas. IMRgC could represent a new tool in the management of recurrent glioblastomas, amplifying the efficiency of radiotherapy, chemotherapy or immunotherapy. Its role as a treatment strategy in relapsing

patients remains poorly understood, warranting the need for strong collaborations and multicenter randomized trials.

## **DECLARATIONS**

The authors confirm that the institution or independent ethics committee approved the study. Approval was obtained from the ethics committee of University of Strasbourg in view of the retrospective nature of the study.

Informed consent was obtained from all individual participants included in the study. The authors consent for publication. The work has been carried out in accordance with the Code of Ethics of the World Medical Association (Declaration of Helsinki).

Availability of data and material: Not applicable

The authors declare they have no financial interests.

No Funding was received to assist with the preparation of this manuscript.

Code availability: Not applicable

Authors' contributions: All authors contributed to the study conception and design. Material preparation, data collection and analysis were performed by CEBULA H el ene, GANGI Afshin, GARNON Julien, PROUST Fran ois, NOEL Georges, MALLEREAU Charles-Henry, SCHOTT Roland, DE MATHELIN Michel and CHIBBARO Salvatore. The first draft of the manuscript was written by CEBULA H el ene. TODESCHI Julien, LHERMITTE Benoit and BURCKEL Helene commented and supervised on previous versions of the manuscript

## **REFERENCES:**

- [1] Ringel F, Pape H, Sabel M, Krex D, Bock HC, Misch M, et al. Clinical benefit from resection of recurrent glioblastomas: results of a multicenter study including 503 patients with recurrent glioblastomas undergoing surgical resection. *Neuro-Oncol* 2016;18:96–104. <https://doi.org/10.1093/neuonc/nov145>.
- [2] Weller M, Cloughesy T, Perry JR, Wick W. Standards of care for treatment of recurrent glioblastoma--are we there yet? *Neuro-Oncol* 2013;15:4–27. <https://doi.org/10.1093/neuonc/nos273>.
- [3] Friedman HS, Prados MD, Wen PY, Mikkelsen T, Schiff D, Abrey LE, et al. Bevacizumab alone and in combination with irinotecan in recurrent glioblastoma. *J Clin Oncol Off J Am Soc Clin Oncol* 2009;27:4733–40. <https://doi.org/10.1200/JCO.2008.19.8721>.
- [4] Bozinov O, Yang Y, Oertel MF, Neidert MC, Nakaji P. Laser interstitial thermal therapy in gliomas. *Cancer Lett* 2020;474:151–7.

<https://doi.org/10.1016/j.canlet.2020.01.024>.

[5] Quadri SA, Waqas M, Khan I, Khan MA, Suriya SS, Farooqui M, et al. High-intensity focused ultrasound: past, present, and future in neurosurgery. *Neurosurg Focus* 2018;44:E16. <https://doi.org/10.3171/2017.11.FOCUS17610>.

[6] Fecci PE, Sampson JH. The current state of immunotherapy for gliomas: an eye toward the future. *J Neurosurg* 2019;131:657–66. <https://doi.org/10.3171/2019.5.JNS181762>.

[7] Ishikawa E, Muragaki Y, Yamamoto T, Ohno T, Matsumura A. Vaccine Therapy of High-Grade Gliomas. *Prog Neurol Surg* 2018;32:101–11. <https://doi.org/10.1159/000469684>.

[8] McBain C, Lawrie TA, Rogozińska E, Kernohan A, Robinson T, Jefferies S. Treatment options for progression or recurrence of glioblastoma: a network meta-analysis. *Cochrane Database Syst Rev* 2021. <https://doi.org/10.1002/14651858.CD013579.pub2>.

[9] Cazzato RL, Garnon J, Ramamurthy N, Koch G, Tsoumakidou G, Caudrelier J, et al. Percutaneous image-guided cryoablation: current applications and results in the oncologic field. *Med Oncol Northwood Lond Engl* 2016;33:140. <https://doi.org/10.1007/s12032-016-0848-3>.

[10] Gage AA, Baust J. Mechanisms of tissue injury in cryosurgery. *Cryobiology* 1998;37:171–86. <https://doi.org/10.1006/cryo.1998.2115>.

[11] Cebula H, Noel G, Garnon J, Todeschi J, Burckel H, de Mathelin M, et al. The Cryo-immunologic effect: A therapeutic advance in the treatment of glioblastomas? *Neurochirurgie* 2020;66:455–60. <https://doi.org/10.1016/j.neuchi.2020.06.135>.

[12] Sabel MS. Cryo-immunology: a review of the literature and proposed mechanisms for stimulatory versus suppressive immune responses. *Cryobiology* 2009;58:1–11. <https://doi.org/10.1016/j.cryobiol.2008.10.126>.

[13] West HJ, Jin JO. JAMA Oncology Patient Page. Performance Status in Patients With Cancer. *JAMA Oncol* 2015;1:998. <https://doi.org/10.1001/jamaoncol.2015.3113>.

[14] Stupp R, Mason WP, van den Bent MJ, Weller M, Fisher B, Taphoorn MJB, et al. Radiotherapy plus concomitant and adjuvant temozolomide for glioblastoma. *N Engl J Med* 2005;352:987–96. <https://doi.org/10.1056/NEJMoa043330>.

[15] Wen PY, Macdonald DR, Reardon DA, Cloughesy TF, Sorensen AG, Galanis E, et al. Updated Response Assessment Criteria for High-Grade Gliomas: Response Assessment in Neuro-Oncology Working Group. *J Clin Oncol* 2010;28:1963–72. <https://doi.org/10.1200/JCO.2009.26.3541>.

[16] Li C, Wu L, Song J, Liu M, Lv Y, Sequeiros RB. MR imaging-guided cryoablation of metastatic brain tumours: initial experience in six patients. *Eur Radiol* 2010;20:404–9. <https://doi.org/10.1007/s00330-009-1554-8>.

[17] Martynov BV, Kholyavin AI, Nizkovolos VB, Parfenov VE, Trufanov GE, Svistov DV. Stereotactic Cryodestruction of Gliomas. *Prog Neurol Surg* 2018;32:27–38. <https://doi.org/10.1159/000469677>.

[18] Baust JG, Gage AA, Bjerklund Johansen TE, Baust JM. Mechanisms of cryoablation: clinical consequences on malignant tumors. *Cryobiology* 2014;68:1–11. <https://doi.org/10.1016/j.cryobiol.2013.11.001>.

[19] Seystahl K, Wick W, Weller M. Therapeutic options in recurrent glioblastoma--An update. *Crit Rev Oncol Hematol* 2016;99:389–408. <https://doi.org/10.1016/j.critrevonc.2016.01.018>.

[20] Suchorska B, Weller M, Tabatabai G, Senft C, Hau P, Sabel MC, et al. Complete resection of contrast-enhancing tumor volume is associated with improved survival in recurrent glioblastoma-results from the DIRECTOR trial. *Neuro-Oncol* 2016;18:549–56. <https://doi.org/10.1093/neuonc/nov326>.

[21] Yong RL, Wu T, Mihatov N, Shen MJ, Brown MA, Zaghoul KA, et al. Residual tumor volume and patient survival following reoperation for recurrent glioblastoma. *J*

Neurosurg 2014;121:802–9. <https://doi.org/10.3171/2014.6.JNS132038>.

[22] Antoni D, Jastaniah Z, Haoming QC, Gaultier C, Ahle G, Couchot J, et al. Patterns of relapse in patients with high grade glioma receiving combined treatments including stereotactic re-irradiation for a first relapse. *Cancer Radiother J Soc Francaise Radiother Oncol* 2016;20:282–91. <https://doi.org/10.1016/j.canrad.2016.03.006>.

[23] Cabrera AR, Cuneo KC, Desjardins A, Sampson JH, McSherry F, Herndon JE, et al. Concurrent stereotactic radiosurgery and bevacizumab in recurrent malignant gliomas: a prospective trial. *Int J Radiat Oncol Biol Phys* 2013;86:873–9. <https://doi.org/10.1016/j.ijrobp.2013.04.029>.

[24] Combs SE, Edler L, Rausch R, Welzel T, Wick W, Debus J. Generation and validation of a prognostic score to predict outcome after re-irradiation of recurrent glioma. *Acta Oncol Stockh Swed* 2013;52:147–52. <https://doi.org/10.3109/0284186X.2012.692882>.

[25] Kamiya-Matsuoka C, Gilbert MR. Treating recurrent glioblastoma: an update. *CNS Oncol* 2015;4:91–104. <https://doi.org/10.2217/cns.14.55>.

[26] Taal W, Oosterkamp HM, Walenkamp AME, Dubbink HJ, Beerepoot LV, Hanse MCJ, et al. Single-agent bevacizumab or lomustine versus a combination of bevacizumab plus lomustine in patients with recurrent glioblastoma (BELOB trial): a randomised controlled phase 2 trial. *Lancet Oncol* 2014;15:943–53. [https://doi.org/10.1016/S1470-2045\(14\)70314-6](https://doi.org/10.1016/S1470-2045(14)70314-6).

## LEGENDS:

Table 1: Baseline characteristics and clinical outcomes of 6 patients treated for a recurrent glioblastoma by association of cryotherapy and microsurgical resection.

UTI= urinary tract infection

TMZ= temozolomide

PFS= progression free survival after iMRgC procedure

KPS: Karnofsky Performance status

R= Right

L= Left

Y= Yes

N= No

GBM= Glioblastoma

MO=month

RXT: Radiotherapy

Figure 1: The cryotherapy was assessed under MRI control. Under near-real-time MR fluoroscopic guidance in three orthogonal planes (BEAT-IRTTT sequence, Siemens Corporate Research & Technology, Center for Applied Medical Imaging, Baltimore, MD, USA), the probes (red star) were advanced into the target tumor.

Figure 2: Case of 54-year-old woman (number 1 on Table 1 and 2) with confirmed recurrence right frontal glioblastoma (MGMT/IDH-1 negative) 18-month following initial resection and standard chemoradiotherapy. (a) Pre-operative, intra-operative and post-operative contrast-enhanced T1-weighted (b, c) and T2 BLADE images (b).

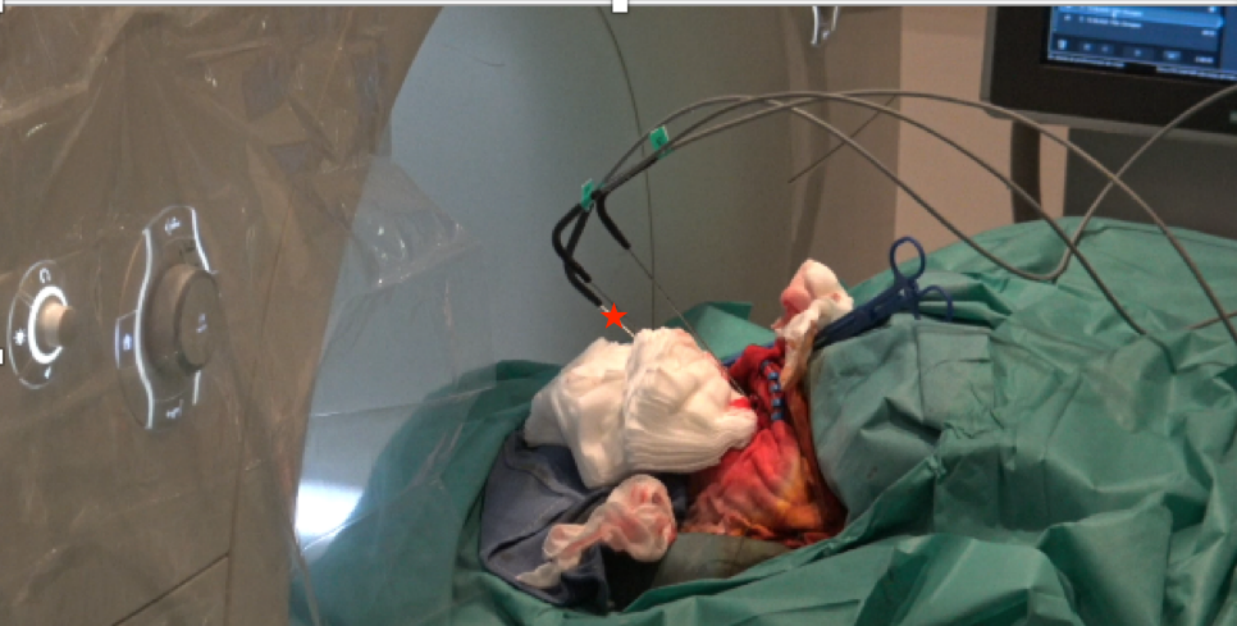Three cryo-probes were positioned within the tumor under real-time MR-Fluoroscopy-guidance (clearly demarcated hypointense ablation-zone (“ice-ball”) completely covering lesion during iMRgC (b), followed by complementary surgical resection (c). 3-month follow-up MRI demonstrated a probable recurrent enhancing soft tissue on T1-weighted imaging with gadolinium (volume  $11.68\text{cm}^3$ ) at the operative site (d) associated with edema on T2 weighted images. However, biopsy revealed secondary necrosis with an inflammatory lesion (including macrophages, neutrophils and CD3+ T-lymphocyte), and subcortical vasculitis reaction (including micro-bleeds) without tumor. At 5 months, the enhancement of the lesion had significantly enlarged ( $17.36\text{cm}^3$ ; 148% increase) and the patient developed aphasia requiring glucocorticoid therapy (e). However, at 8-months follow-up, the lesion markedly reduced in volume ( $6.37\text{cm}^3$ ; 272% decrease on T1-weighted images) with reduction of edema and resolution of aphasia, despite lack of adjuvant therapy (f).

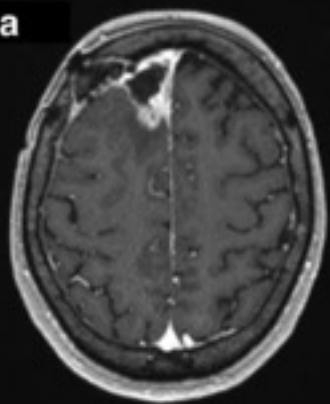
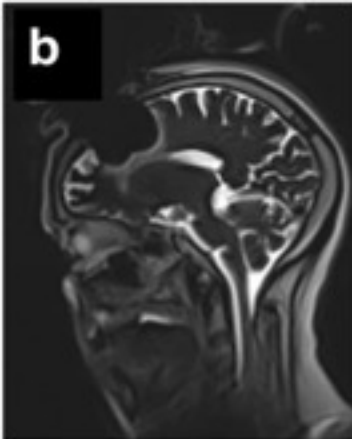
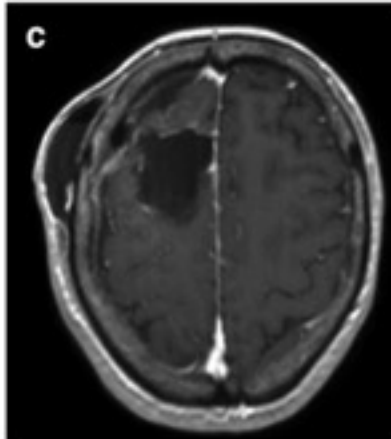
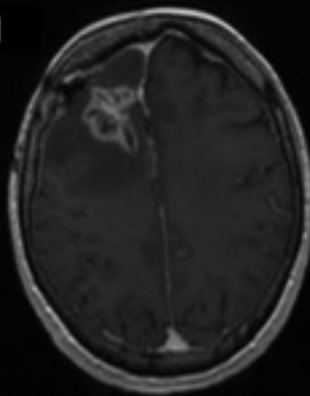
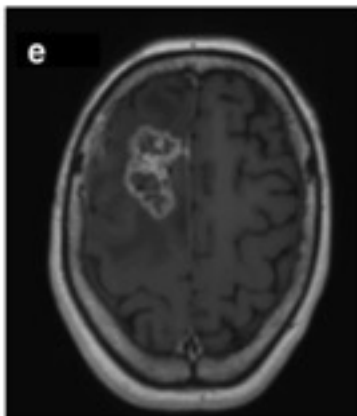
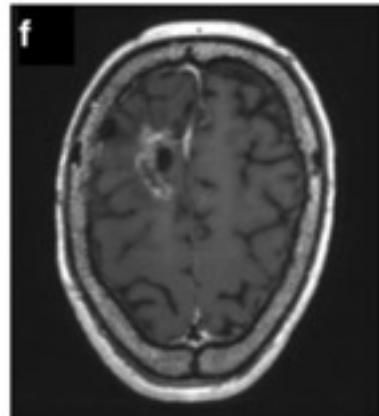
Figure 3a: Kaplan Meier curve showing progression free-survival

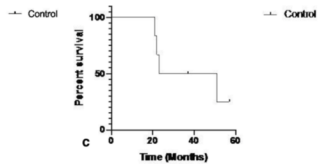
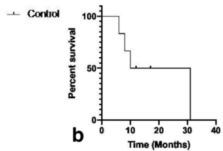
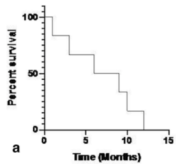
Figure 3b: Kaplan Meier curves showing Survival Post-iMRgC

Figure 3c: Kaplan Meier curve showing overall survival





**a****b****c****d****e****f**



<b>31NO</b>	<b>1</b>	<b>2</b>	<b>3</b>	<b>4</b>	<b>5</b>	<b>6</b>
<b>AGE (YR)</b>	54	79	70	70	64	65
<b>SEX</b>	F	M	F	F	M	M
<b>INITIAL DIAGNOSIS</b>						
LOCATION	Frontal	Temporal	Parietal	Frontal	Frontal	Frontal
SIDE	R	L	R	R	L	L
KPS	90	90	60	90	90	90
HISTOLOGY	GBM	GBM	GBM	GBM	GBM	GBM
METHYLATION MGMT	-	+	+	+	+	-
<b>RECURRENCE</b>						
KPS PREOP	90	60	60	70	90	50
LOCATION	Frontal	Temporal	Parietal	Frontal	Frontal	Frontal
SIDE	R	L	R	R	L	L
HISTOLOGY	GBM	GBM	GBM	GBM	GBM	GBM
METHYLATION MGMT	-	+	+	+	+	-
VOLUME (CM <sup>3</sup> )	9.15	10.21	10.44	3.58	6.15	10.27
<b>CRYOTHERAPY</b>						
PROBE NUMBER	3	4	3	4	3	3
DURATION FREEZING (MIN)	10	10	10	8	10	8
<b>COMPLICATIONS</b>						
NEUROLOGICAL DEFICIT	/	/	/	/	Transient paresis of elevator eyelid muscle	/
SURGICAL SITE INFECTION	Cutaneous	/	/	/	/	/
MEDICAL	/	/	UTI	UTI	UTI	/
<b>POST CRYO OUTCOME</b>						
KPS 1 MO	80	60	60	70	90	50
PFS (MO)	12	3	6	9	10	1
ADJUVANT THERAPY	/	/	/	TMZ	TMZ	Irinotecan + bevacizumab
ADJUVANT THERAPY AT THE RECURRENCE	RXT + TMZ	Lomustine+ bevacizumab	/	Irinotecan + bevacizumab	Irinotecan + bevacizumab	Irinotecan + bevacizumab
TIME FROM INITIAL DIAGNOSIS TO RECURRENCE (MO)	20	17	14	20	45	11
SURVIVAL POST CRYO (MO)	31	6	8	/	/	10
OVERALL SURVIVAL (MO)	51	23	22	/	/	21
FOLLOW-UP (MO)	51	23	22	37	57	21
DEATH (Y/N)	Y	Y	Y	N	N	Y

Table 1: Baseline characteristics and clinical outcomes of 6 patients treated for a recurrent glioblastoma by association of cryotherapy and microsurgical resection.

UTI= urinary tract infection

TMZ= temozolomide

PFS= progression-free survival after iMRgC procedure

KPS: Karnofsky Performance status

CRYO: cryotherapy

R= Right

L= Left

Y= Yes

N= No

GBM= Glioblastoma

MO= month

RXT: Radiotherapy