



HAL
open science

Probable Diffuse Idiopathic Skeletal Hyperostosis (DISH) in Pre-Pottery Neolithic Cyprus

Françoise Le Mort, Henri Duda

► **To cite this version:**

Françoise Le Mort, Henri Duda. Probable Diffuse Idiopathic Skeletal Hyperostosis (DISH) in Pre-Pottery Neolithic Cyprus: Evidence from Khirokitia. *Paléorient*, 2021, 47 (1), pp.109-123. 10.4000/paleorient.937 . hal-03510933

HAL Id: hal-03510933

<https://hal.science/hal-03510933>

Submitted on 4 Jan 2022

HAL is a multi-disciplinary open access archive for the deposit and dissemination of scientific research documents, whether they are published or not. The documents may come from teaching and research institutions in France or abroad, or from public or private research centers.

L'archive ouverte pluridisciplinaire **HAL**, est destinée au dépôt et à la diffusion de documents scientifiques de niveau recherche, publiés ou non, émanant des établissements d'enseignement et de recherche français ou étrangers, des laboratoires publics ou privés.



Distributed under a Creative Commons Attribution 4.0 International License

PROBABLE DIFFUSE IDIOPATHIC SKELETAL HYPEROSTOSIS (DISH) IN PRE-POTTERY NEOLITHIC CYPRUS: EVIDENCE FROM KHIROKITIA

F. LE MORT and H. DUDAY

Abstract. *The site of Khirokitia in Cyprus (7th-early 6th millennium BC) yielded one of the largest series of human remains for the Pre-Pottery Neolithic period in the Eastern Mediterranean and Near Eastern region (MNI = 243). The paleopathological study of this series allowed us to diagnose a probable case of diffuse idiopathic skeletal hyperostosis (DISH) affecting a male aged between 30 and 49 years, who also suffered from osteoarthritis. DISH has rarely been identified among prehistoric populations, especially in the Eastern Mediterranean and Near Eastern region; the case described here is currently the only one known for the Pre-Pottery Neolithic period. It provides new elements to our knowledge of the health status of the early Neolithic populations.*

Résumé. *Le site de Khirokitia à Chypre (VII^e-début VI^e millénaire avant J.-C.) a livré l'une des plus grandes séries de restes humains pour la période du Néolithique précéramique en Méditerranée orientale et au Proche-Orient (NMI = 243). L'étude paléopathologique de cette série a permis de diagnostiquer un cas probable de maladie hyperostotique (DISH) affectant un homme âgé de 30 à 49 ans qui souffrait également d'arthrose. La maladie hyperostotique a rarement été identifiée chez les populations préhistoriques, en particulier dans la région de la Méditerranée orientale et du Proche-Orient ; le cas décrit ici est actuellement le seul connu pour la période du Néolithique précéramique. Il apporte de nouveaux éléments à notre connaissance de l'état de santé des populations du début du Néolithique.*

Keywords. *Diffuse idiopathic skeletal hyperostosis (DISH), Neolithic, Cyprus, Khirokitia*

Mots-clés. *Maladie hyperostotique, Néolithique, Chypre, Khirokitia*

Ancient cases of diffuse idiopathic skeletal hyperostosis (DISH) have been reported as early as during the Middle Palaeolithic. Indeed, the pathological conditions observed on one of the Neandertal skeletons discovered at Shanidar in Iraq (Shanidar 1) support the diagnosis of DISH (Crubézy and Trinkaus 1992). The Kiiik Koba 1 Neandertal skeleton (Crimea) might also have been affected by DISH (Trinkaus et al. 2008). Cases are known in past populations from all around the world and from all periods as well as in various contemporary populations (Bloom 1984; Cassim et al. 1990; Kim et al. 2004; Westerweld et al. 2008; Mori et al. 2017; Sirasanagandla et al. 2018 inter alia) but the disease has rarely been recognized in

prehistoric populations (Faccia et al. 2016). Most of the known cases in past populations come from medieval and post-medieval European populations (Mays 2000; Kacki and Villotte 2006; Giuffra et al. 2010; Kacki et al. 2018; Tristaroli 2018 inter alia). DISH has also been reported, among other examples, in contexts as various as Meroitic Nubians from Sudan (Arriaza et al. 1993), royal mummies of ancient Egypt (Saleem and Hawass 2014), pre-Columbian North America (Ostendorf Smith et al. 2013), ancient northern Chile (Arriaza et al. 1993), ancient Chinese (Hukuda et al. 2000) and Korean (Kim et al. 2012) populations. As far as Near Eastern post-Paleolithic prehistory is concerned, data are very few; three

cases have been identified in the Natufian population, according to Bocquentin (2003, 88-89 and appendix IIE 13); they concern one adult male from Mallaha (Israel) and two adult individuals from Hayonim cave (Israel). Unfortunately, the description of the pathological changes observed on these individuals has not been published yet.

DISH is a systemic noninflammatory disorder characterized by ossification of spinal ligaments and possibly ossification of extra-spinal ligaments and tendons (Resnick and Niwayama 1976; Utsinger 1985; Crubézy and Crubézy-Ibanez 1993; Rogers and Waldron 2001; Kacki and Villotte 2006; Mader, Sarzi-Puttini et al. 2009; Waldron 2009, 2019; Pilai and Littlejohn 2014; Holgate and Steyn 2016). According to Mader et al. (2017), its average prevalence in today's population is approximately 10% of people over 50 years of age. Studies of DISH prevalence in Eastern Mediterranean and Middle Eastern populations are scarce; a prevalence of 10% has been observed among elderly subjects in a national tertiary care referral hospital in Oman (Sirasanagandla et al. 2018) and a prevalence of 17.9% in a Jerusalem hospital population (Bloom 1984). The aetiology of DISH remains uncertain; various causes have been suggested for this condition. Given its frequent association with other disorders such as obesity, diabetes or hyperinsulinemia, metabolic factors are often mentioned (Littlejohn and Smythe 1981; El Miedany et al. 2000; Denko and Malemud 2006; Mader and Lavi 2009; Mader, Novofestovki et al. 2009; Pillai and Littlejohn 2014 inter alia). According to several authors, mechanical factors or genetic predisposition may also be involved in the development of DISH (Pappone et al. 1996; Kim et al. 2004; Gorman 2005). A link with age has been established, most of the affected individuals being older than 40 years of age; males are more frequently suffering from DISH than females (Waldron 2009). As far as past populations are concerned, the condition is often considered to be linked to a particular way of life including rich diets that is frequently associated to a high social status (Rogers and Waldron 2001; Jankauskas 2003; Kacki and Villotte 2006 inter alia).

This paper reports on a new case dating back to the 7th millennium BC, discovered on the Pre-Pottery Neolithic site of Khirokitia in Cyprus (burial 641), which adds to the rare cases of DISH known in prehistoric populations.

MATERIAL AND METHODS

THE ARCHAEOLOGICAL CONTEXT

The site of Khirokitia, situated on a hill, at about 6 km directly from the present southern coast of the Cyprus island, was first excavated by Dikaïos between 1936 and 1946 (Dikaïos 1953). After a few soundings (Stanley Price and Christou 1973; Le Brun and Stanley Price 1977), the excavations directed by A. Le Brun were renewed in 1977 and completed in 2009. The occupation of the site, which illustrates the last phase of the Pre-Pottery Neolithic of Cyprus, took place in the 7th and early 6th millennium cal. BC. The settlement area could be evaluated at approximately 3 hectares of which only a part has been explored. The village consists of houses composed of several round-shape buildings. It is divided into two sectors, east and west. In the course of recent excavations, nine stratigraphic levels have been recognized in the east sector (A to H, J) which was occupied first and three (I to III) in the west sector; it also appeared that the boundaries of the village fluctuated during its occupation (Le Brun 1984, 1989a, 1994a, in press; Le Brun and Daune-Le Brun 2003, 2009; Daune-Le Brun and Le Brun 2016; Daune-Le Brun et al. 2017). The inhabitants of Khirokitia were engaged in farming, herding, hunting and gathering activities (Le Brun 1996; Davis 2003, in press; Pares and Tengberg 2017).

THE HUMAN REMAINS

Many burials were discovered at the site. These are primary burials. The bodies lie in a contracted position in burial pits that were dug into the floors of houses while those houses were occupied. There does not appear to be a preferred location for graves within the houses. The dead are buried in the same way, whatever their age is (Dikaïos 1953; Le Brun 1984, 1989a, 1989b, 1994a; Le Mort 1994, 2003). The study of the human remains from recent excavations and the reappraisal of the skeletons uncovered during the old excavations and in the course of the soundings allowed us to identify at least 243 individuals¹ including 135 juveniles and 108 adult individuals.

1. In a few cases, when bones from several burials uncovered during Dikaïos' excavations were mixed together, it was necessary to estimate the minimum number of individuals.

BURIAL 641

Structure 126 (East sector) was occupied from level B5 to level B2; it yielded three burials. One of them (infant burial 746) belongs to level B5; the two others were sealed by floor 541, the most recent in the structure, they include an infant burial (locus 624) and an adult burial (locus 641; Le Brun 1994b; Le Mort 1994). Burial 641 (fig. 1) contained the remains of an adult male aged between 30 and 49 years. The age at death was estimated according to the method developed by Schmitt (2005) and sex was determined using the method of Murail et al. (2005). The body, oriented south north, was resting in a contracted position in a pit 0.55 m deep; a quern (0.37 × 0.20 m), placed on the deceased before filling the pit, was covering the left hip bone, the sacrum, the inferior portion of the vertebral column and of the left hemithorax, as well as the left elbow.




Fig. 1 – Adult burial 641 in structure 126, level B.
Photo French Archaeological Mission at Khirokitia.

The preservation is rather good in regard to the relative completeness of the skeleton. On the other hand, most of the bones themselves are not in very good condition. The skull is almost complete. The majority of the ribs are present but fragmentary. The sternum is missing. The vertebrae are in a relative good condition compared to the other adult skeletons from the site. As far as the thoracic and lumbar vertebrae are concerned, the body is relatively well preserved, with the exception of the eighth thoracic vertebra (T8) and the fourth lumbar vertebra (L4), but the transverse processes as well as the spinous process are usually not complete. The sacrum appears very fragmentary. Regarding the hip bones, the areas of the iliac tuberosity

and of the auricular surface are partly fragmentary, as well as the ischium and the pubis. Most of the extremities of the long bones are fragmentary, as well as most of the tarsal bones (fig. 2). As is usually the case with prehistoric skeletal remains (human and animal) from Cyprus, the skeleton was covered with concretions. The bones were therefore cleaned with a dilute acetic acid solution in order to dissolve the concretions and to allow study of the skeleton, which gave quite good results.

DIAGNOSING DISH

After the first recognition of the disease by Forestier and Rotes-Quérol (1950), various diagnostic criteria, more or less restrictive, have been published (Kuperus et al. 2017; Holgate and Steyn 2016). They mainly focus on spinal changes although extra-spinal sites may also be concerned (Resnick and Niwayama 1976; Utsinger 1985; Crubézy and Crubézy-Ibanez 1993; Rogers and Waldron 2001; Kacki and Villotte 2006; Waldron 2009, 2019; Foster et al. 2018). Some authors have identified several DISH categories—definite, probable, possible—according to the observed criteria (e.g., Utsinger 1985; Crubézy and Crubézy-Ibanez 1993; Kacki and Villotte 2006; Foster et al. 2018). Diagnostic criteria for probable DISH include spinal and extra-spinal changes while diagnostic criteria for possible DISH involve spinal or extra-spinal changes (table 1). Currently, research is being conducted to better understand the pathogenesis of DISH by identifying the early stages of the disease (Mader et al. 2017; Kuperus et al. 2018, 2019; Castells Navarro and Buckberry 2020).

Skeleton from burial 641 was inspected for spinal and extra-spinal changes as far as the state of preservation of the bones allowed it² and the diagnostic was done according to the Utsinger criteria.

DESCRIPTION AND DIAGNOSIS OF PATHOLOGICAL CHANGES

CERVICAL VERTEBRAE

The first four cervical vertebrae (fig. 3) are fused together by concretions, as are the 5th and 6th cervical vertebrae (fig. 4).

2. At the time of the study, it was not possible to take X-rays.

Table 1 – Diagnostic criteria for DISH categories—definite, probable, possible—in the literature. After Kacki et al. 2018, completed.

	Definite DISH	Probable DISH	Possible DISH
Utsinger 1985	<i>Spinal changes</i> Bridging of four continuous vertebral bodies in the thoracolumbar spine <i>Exclusion criteria</i> Signs of degenerative disc disease, apophyseal joint ankyloses	<i>Spinal changes</i> Bridging of two vertebral bodies <i>Extra-spinal changes</i> Bilateral patellar tufting, heel spurring, olecranon tufting	<i>Spinal changes</i> Two vertebrae joined Or <i>Extra-spinal changes</i> Symmetrical enthesophytes
Crubézy and Crubézy-Ibanez 1993	<i>Spinal changes</i> Bridging of three vertebral bodies in the lower thoracic region or of four vertebral bodies at any level of the spine <i>Exclusion criteria</i> Sacroiliac joint erosion, sclerosis, or intraarticular osseous fusion	<i>Spinal changes</i> Bridging of two vertebral bodies <i>Extra-spinal changes</i> Symmetrical enthesopathies (posterior calcanei, olecranons, and upper patellae)	<i>Spinal changes</i> Bridging of two vertebral bodies Or <i>Extra-spinal changes</i> Symmetrical enthesopathies
Kacki and Villotte 2006	<i>Spinal changes</i> Flowing ossification along the anterolateral aspect of four contiguous vertebral bodies in the thoracic spine, with or without ankyloses <i>Exclusion criteria</i> Intervertebral disc space narrowing, apophyseal joint ankyloses	<i>Spinal changes</i> Flowing ossification along the anterolateral aspect of two contiguous vertebral bodies in the thoracic spine, with or without ankyloses <i>Extra-spinal changes</i> Symmetrical enthesal changes (patellar tufting, heel spurring, olecranon tufting)	
Foster et al. 2018	<i>Spinal changes</i> Flowing anterior longitudinal ligament ossification and ankylosis of at least four contiguous thoracic vertebrae <i>Extra-spinal changes</i> Bilateral enthesophytes at the olecranon, patella, tibial tuberosity or posterior calcaneus of at least moderate development	<i>Spinal changes</i> Evidence for ossification of the anterior longitudinal ligament or ankyloses of at least two vertebrae in the thoracic or lumbar spine <i>Extra-spinal changes</i> Bilateral enthesophytes at the olecranon, patella, tibial tuberosity or posterior calcaneus of at least moderate development	<i>Spinal changes</i> Evidence for anterior longitudinal ligament ossification, vertebral ankyloses Or <i>Extra-spinal changes</i> Bilateral enthesophytes at the olecranon, patella, tibial tuberosity or posterior calcaneus of at least moderate development

The atlas shows a slight ossification of the atlanto-odontoid joint capsule on the right side. The anterior margin of the lower surface of the body of the 3rd cervical vertebra (C3) is slightly extroverted, scalloped and slightly protruding; the lesion is more severe on the right side. On the 4th cervical vertebra (C4), one finds the scalloped aspect of collar-like osteophytes which form the anterior and right lateral part of the margin of the upper surface of the body as well as the whole anterior margin of its lower surface; the right uncus is clearly flattened and everted, the left one being only very slightly everted. These lesions determine a noticeable narrowing of the intervertebral foramen, bilateral, but more pronounced on the right side (hourglass aspect). Similar lesions are found on the anterior and lateral margins of the upper and lower surfaces of the body of the 5th (C5) and 6th (C6) cervical vertebrae, the uncus being also everted. At the C4-C5 level, the narrowing of the vertebral foramen is more pronounced on the right side (as at the C3-C4 level), whereas at the C5-C6 level, a major narrowing is observed on the left side: at the level of the constriction, the transverse diameter of the foramen is hardly 1.8 mm. The posterior joints of all these vertebrae (C1 to C6) don't show any change.

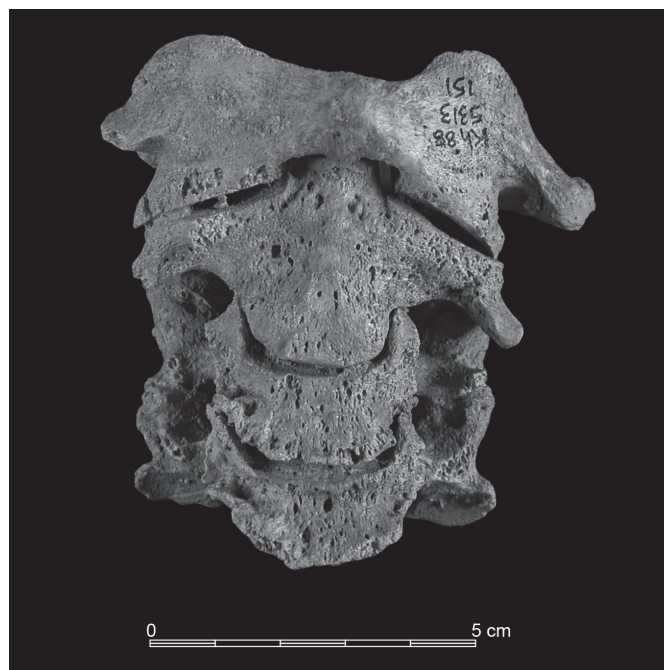


Fig. 3 – Anterior view of the first four cervical vertebrae showing evidence of osteoarthritis.

With regard to the 7th cervical vertebra (C7), the uncus are slightly flattened. The right inferior articular process is irregular, with numerous holes giving it a spongy appearance; its lower edge is everted backwards, thickened, and irregular bone appositions are observed on the posterior surface. The thickness of the process measured about 2 mm above the lower edge of the articular surface is about 2.7 mm on the left and 5.2 mm on the right.

Due to the blocks fused together by the concretion, only some of the upper and lower surfaces of the vertebral bodies can be observed. At the C4-C5 level, a few holes are visible in the posterior part of the surfaces. There are also a few holes at the C6-C7 level, associated with some more dense irregularities.

The pathological changes observed on the cervical vertebrae are strongly suggestive of spinal osteoarthritis, as defined by Waldron (2019).




Fig. 4 – Anterosuperior view of the fifth and sixth cervical vertebrae showing evidence of osteoarthritis.

THORACIC VERTEBRAE

On the first thoracic vertebra (T1), the only significant anomaly concerns the right superior articular process in

relation to the anomalies observed on C7. Its lower limit is bordered by a ridge which determines the formation of a gutter in which the thickened articular process of C7 fits. The spinous processes of C7 and T1 are slightly deviated to the right; however, there is no asymmetry of the bodies which would lead to the suspicion of scoliosis. From the second thoracic vertebra (T2) onwards, the orientation of the spinous processes is normal. The second thoracic vertebra (T2) does not show any pathological change.

On the 3rd thoracic vertebra (T3), a very small spicule is visible at the superior-lateral end of the left transverse process (beginning of ossification of the intertransverse ligament). The lower surface of the 4th thoracic vertebra (T4) presents an expansion beyond the vertebral listel which mainly concerns the right lateral and anterior parts; this area is very irregular, vacuolated. On the 5th thoracic vertebra (T5), a small horizontal overflow can be seen in the anterolateral part of the upper surface of the body. The lower surface has a vacuolar appearance in its left half, particularly pronounced in the periphery of the listel in an enlarged and irregular area. The left costal facet for the 6th rib is also very enlarged with a vacuolar appearance.

On the 6th thoracic vertebra (T6), the left half of the upper surface of the body shows some holes immediately inside the listel; major irregularities of the listel are observed on the lower surface of the body. An almost circular cavity with a diameter of 8-9 mm which seems, at least in part, to be old, is present on the left. The vertebral arch is normal with only small spicules corresponding to minor enthesal changes of the yellow ligament.

With regard to the 7th thoracic vertebra (T7), minor enthesal changes of the yellow ligament are visible on the anteroinferior surface of the laminae. The right anterolateral side of the body presents a big syndesmophyte, which protrudes about 1 cm above the upper surface and 8.6 mm in front of and to the right of the original limit of the vertebral body (fig. 5). The left anterolateral part of the upper surface has been partly destroyed postmortem but the preserved part is normal. The lower surface of the body shows several non-taphonomic large holes in its posterior half as well as small excrescences predominating on the right margin.

The arch of the 8th thoracic vertebra (T8) also shows a minor enthesal change of the yellow ligament on the anteroinferior surface of the laminae. The upper surface of the body shows a few holes very likely to be of taphonomic origin and a right anterolateral scalloped excrescence (maximum development: 4.6 mm), made of spicules pointing forward or outwards and upwards. Small excrescences are also observed on the




Fig. 5 – Right lateral view of the seventh thoracic vertebra exhibiting an ascending syndesmophyte.

preserved part of the margin of the lower surface of the body, especially on the right anterolateral side.

The 9th and 10th thoracic vertebrae (T9-T10) form a bi-vertebral block with fused syndesmophytes on the right anterolateral side (fig. 6a-b). The upper surface of the vertebral body of T9 has a vacuolar appearance in its posterior half. Between T9 and T10, the disc space is preserved and the posterior joints are free (fig. 6a). The changes exclusively concern the right half of the circumferential surface of the vertebral bodies. We also note excrescences, in the form of a collar with ascending spicules, on the right anterolateral side of the upper surface of the vertebral body of T9 and collar-like osteophytes on the right anterolateral side of the lower surface of the vertebral body of T10. On the anterior/lateral surface of the body of T10, one can observe enlarged vascular foramens as well as disorganized bone production.

On the 11th thoracic vertebra (T11), excrescences are present around the upper and lower surfaces of the body, more developed on the lower part of the right half of the body (fig. 7). The lower surface shows a very irregular spongy appearance immediately inside the listel. The 12th thoracic vertebra shows the same lesions but they are more extensive around the upper surface of the body. As on T10, enlarged vascular foramens and disorganized bone production are visible on the anterior/lateral surface of the bodies of T11 and T12.

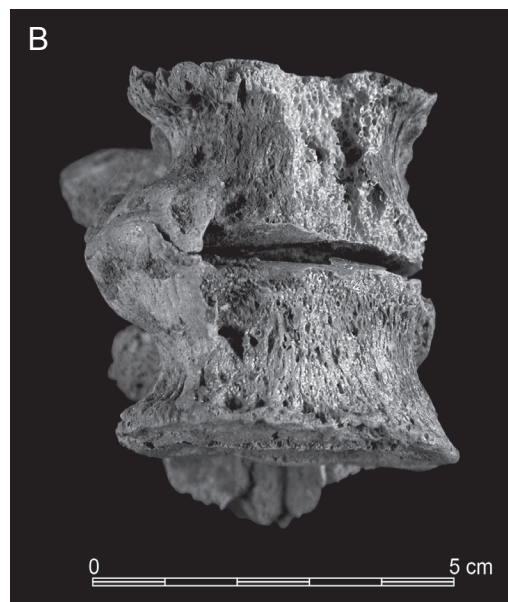



Fig. 6 – Right lateral view (A) and anterior view (B) of fused ninth and tenth thoracic vertebrae.

LUMBAR VERTEBRAE AND SACRUM

On the first lumbar vertebra (L1), we notice large vacuoles on the upper surface of the body, important loss of substance on the lower surface, excrescences along the anterior margin of the upper surface with a small ascending syndesmophyte on

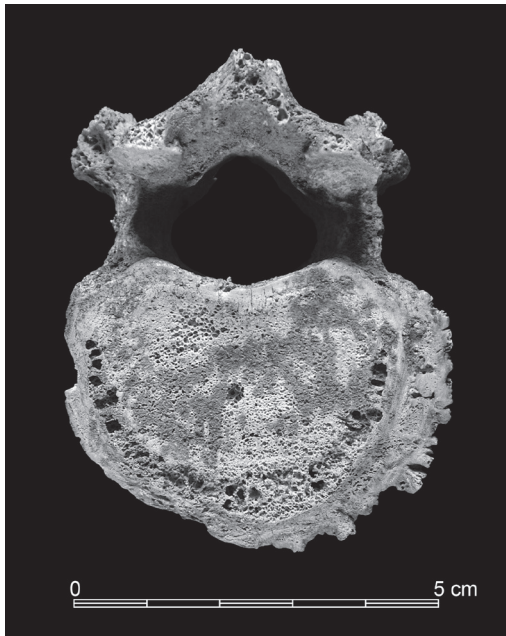


Fig. 7 – Inferior view of the eleventh thoracic vertebra showing excrescences more developed on the lower part of the right half of the body as well as a spongy appearance immediately inside the listel.

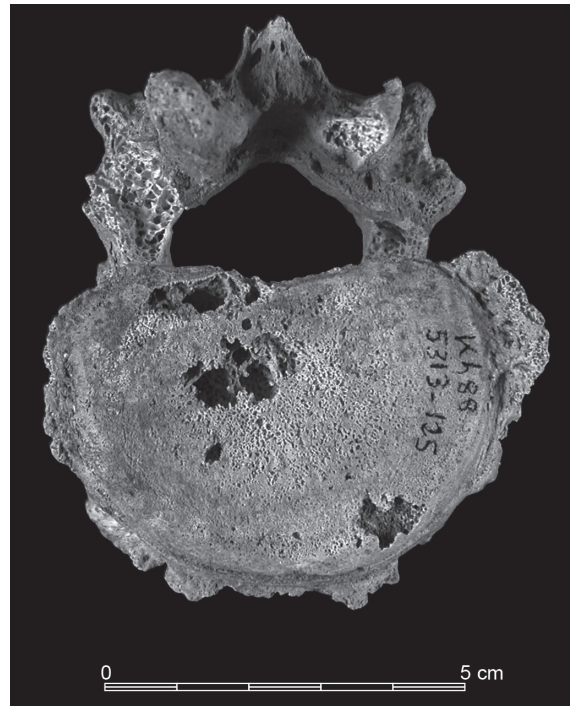


Fig. 8 – Inferior view of the first lumbar vertebra exhibiting collar-like osteophytes and a descending syndesmophyte on the right side.

the left, and collar of excrescences all around the lower surface more developed in the posterolateral right angle of the body (fig. 8). The left inferior articular process is enlarged with a pitted appearance partly masked by encrustation; all around, the bone has a spiky appearance with numerous neoformed spicules.

The upper surface of the body of the 2nd lumbar vertebra (L2) shows a huge, very deep hole (maximum anterior-posterior diameter: 5.6 mm, transverse diameter: 7 mm) suggestive of a Schmorl node and a large collar of osteophytes which protrudes 9.1 mm in the left anterolateral angle and 5.1 mm in the left posterolateral angle. The lower surface presents some irregularities and a slight collar of excrescences on the left lateral half. On the upper surface of the body of the 3rd lumbar vertebra (L3), there is a lacuna of uncertain origin on the left, vacuoles on the posterior margin and excrescences along the anterior margin with a small ascending syndesmophyte on the left anterolateral side. The lower part of the body exhibits another ascending syndesmophyte in the left anterolateral side connected to the previous one by a very dense bone column (fig. 9); the whole anterior margin of the lower surface is remodelled and everted upwards. The superior articular processes of L2 and L3 are normal but all around there are multiple ossified spicules which form irregular collars.

The 4th lumbar vertebra (L4) is very fragmentary and incomplete. The vertebral arch shows many irregularities. Peri-articular spicules can be seen especially above the left superior articular surface. In anterior and right anterolateral position with respect to the upper surface of the body, two enormous ascending syndesmophytes (maximum heights 28.8 and 30.2 mm respectively) protrude 23 and 22 mm above the upper surface (fig. 10a-b). The lower part of the body exhibits a descending syndesmophyte along the right margin of the lower surface.

The vertebral arch of the 5th lumbar vertebra (L5) is normal with however a few spicules around the right inferior articular surface. The upper surface of the body has been damaged post-mortem; there is an irregular area in the right posterolateral angle; a slight collar of excrescences develops in the right anterolateral part. The left anterolateral part of the lower surface of the body is depressed, irregular and vacuolated; on the periphery of the body, a collar of excrescences with a small descending syndesmophyte is observed on the lateral and left anterolateral side.

Furthermore, as on the lower thoracic vertebrae, enlargement of vascular foramen and disorganized bone production are observed on the anterior/lateral surface of the bodies of L1, L2, L3 and L4 (figs. 9, 10a).




Fig. 9 – Left lateral view of the third lumbar vertebra showing two syndesmophytes connected by a dense bone column.

A small bony beak is observed at the upper part of the right superior articular process of the first sacral vertebra (S1). We also notice an irregularity of the upper surface of the body with, in the left anterolateral area, a small ascending syndesmophyte (fig. 11), responding perfectly to the lower syndesmophyte of the body of L5. The preserved portions of the auricular surfaces don't show any change.




Fig. 10 – **A.** Anterior view of the fourth lumbar vertebra with two ascending syndesmophytes, one of them being broken. **B.** Fragment of syndesmophyte from the fourth lumbar vertebra.




Fig. 11 – Anterior view of the upper part of the sacrum showing a slight syndesmophyte.

APPENDICULAR SKELETON

Due to the state of preservation of the skeleton, peripheral sites where enthesal changes are frequently observed in subjects affected by DISH, that is olecranon, upper patella and tibial tuberosity (e.g., Utsinger 1985; Crubézy and Crubézy-Ibanez 1993; Kacki and Villotte 2006; Mader et al. 2009; Foster et al. 2018), could not be observed. No change is visible on the hip bone and the proximal femur where DISH related changes often occur (Mader et al. 2009). Enthesophytes of moderate development are present on the two calcanei at the insertion of the Achilles tendon. Moreover, a bone spur 12 mm long, which could correspond to the ossification of a tract belonging to the supercostal muscle, is observed on the 11th left rib.

The only other extra-spinal pathological changes regard the metacarpals as well as the hand and foot phalanges. Osteophytes are observed at the metacarpophalangeal joint and at the interphalangeal joint of the right thumb, as well as at the second, third, fourth and fifth right distal interphalangeal joints. The left hand shows osteophytes at the fifth proximal interphalangeal joint and at the third, fourth and fifth distal interphalangeal joints. An osteophyte is also present on the right foot, at the second proximal interphalangeal joint.

DIFFERENTIAL DIAGNOSIS

The skeleton of the individual from burial 641 at Khirokitia show various pathological changes, most of them regarding the spine. All the changes exhibited by the cervical vertebrae are strongly suggestive of osteoarthritis, as are those observed at the metacarpophalangeal and interphalangeal joints (Waldron 2019).

The changes present on the thoracic and lumbar spine include bony outgrowths, osteolytic lesions at endplates, enlarged vascular foramen and disorganized bone production on the anterior/lateral surface of the vertebral body.

Diffuse idiopathic skeletal hyperostosis and ankylosing spondylitis both produce bone proliferation but the absence of change on the sacroiliac joint (Olivieri et al. 2009) allows us to rule out ankylosing spondylitis. The pathological changes observed on the thoracic and lumbar vertebrae consist mainly of ossification along the anterolateral aspect of vertebral bodies in the lower thoracic and lumbar regions. The right side is the only affected in the region of descending aorta (thoracic). The spinal outgrowths which are observed from T7 to S1 vary in size and there is a continuous new bone formation resulting in

the fusion of T9 and T10. This is suggestive of DISH. The association with symmetrical enthesal changes on the calcanei provides an additional criterion to support the diagnosis of probable DISH, according to the criteria proposed by Utsinger (1985; table 1). Furthermore, it has to be noticed that the bivertebral block does not show any narrowing of the intervertebral disc space and that posterior joints of the two vertebrae are not affected, reinforcing the probability that the individual was affected by the disease.

DISH and osteoarthritis are the result of different processes, but both conditions are usually age-related (Ortner 2003; Mader et al. 2009; Waldron 2009, 2019 *inter alia*) which may explain their simultaneous presence on the same individual.

The vacuoles observed on certain vertebral endplates cannot be linked to a possible spondylodiscitis as there is no vertebral collapse and, where their height can be assessed, the intervertebral discs seem to have retained their normal height (Aufderheide and Rodriguez-Martin 1998; Resnick and Niwayama 2002; Ortner 2003). They might be related to the limitation of mobility of the lower thoracic and lumbar spine (Munir et al. 2018; Zehra et al. 2019). The disorganized bone production associated with enlarged vascular foramens visible on the bodies of the lower thoracic and lumbar vertebrae might suggest an inflammatory process. However, an infectious origin due to tuberculosis is most likely to be excluded as there is no evidence of classical expression of vertebral tuberculosis (spondylodiscitis; Aufderheide and Rodriguez-Martin 1998; Resnick and Niwayama 2002; Ortner 2003).

According to the age and sex of the individual, the spinal changes might also be suggestive of fluorosis. Nevertheless, the lack of other bone changes such as increased density of bones or rib enlargement, and the absence of enamel defects (Petrone et al. 2013; Nelson et al. 2016, 2019; Walser et al. 2020) make it possible to exclude the hypothesis of fluorosis.

DISCUSSION

The individual from burial 641 at Khirokitia was most probably affected by DISH. It is the only one with this condition at the site and no other case is known from prehistoric Cyprus. Despite the presence of relatively extensive lesions in the thoracolumbar spine, it is likely that this subject presented only moderate disorders (stiffness, reduced mobility) related to DISH. The development of the bony outgrowths is indeed very insufficient to envisage a conflict with the viscera or vessels located in the vicinity of the spine. On the other hand, it is

likely that advanced degenerative damage to the cervical spine, with marked narrowing of several intervertebral foramina, was the cause of cervicobrachialgia.

As DISH could be linked to a particular way of life including rich diets that is frequently associated to a high social status (Rogers and Waldron 2001; Jankauskas 2003; Kacki and Villotte 2006 *inter alia*), the question of the social status of this individual has to be asked.

Regarding diet, the inhabitants of Khirokitia cultivated wheat, barley, pulses and flax and collected fruits from wild trees (pistachio, figs, olives and almonds). They raised sheep, goats and pigs; fallow deer was hunted (Le Brun 1996; Davis 2003, *in press*; Pares and Tengberg 2017). Preliminary isotopic analyses performed on a small set of samples suggest a diet significantly based on terrestrial resources, despite the proximity of the sea, as well as a low quantity of animal proteins or a high consumption of food resources with low $\delta^{15}\text{N}$ values as lentils (Lange-Badré and Le Mort 1998; E. Herrscher personal communication). A larger study is in progress; until now no difference in diet between individuals could be identified.

Mortuary practices are homogeneous on the site and the burial is not different from the others, whether by its location in a house, its type (primary pit burial under a floor), the position and orientation of the deceased or the grave goods. Its only possibly distinguishing feature is the location of the quern on the body. Querns were found in 18.5% of the adult burials and in two child burials. They were placed on the deceased, either on the head, the trunk or the pelvis before the pit is filled but the quern has been found on the pelvis in only three cases, including burial 641 (Dikaios 1953; Le Brun 1984, 1989a, 1989b; Le Mort 1994). The two other cases (burials VIII/II and XV[II]/III) were uncovered during Dikaios' excavations; unfortunately, only the skulls of the skeletons uncovered by Dikaios have been preserved, and there is no detailed description of the infracranial skeleton. In general, the significance of the querns in the graves is difficult to determine. They were found in different sectors and in different levels of the site and their presence does not seem to be linked to the age or sex of the deceased (Dikaios 1953; Le Brun 1984, 1989a-b, 1994; Le Mort 1994). Nevertheless, we cannot exclude that it is related to the social or health status of the individual, although if this cannot be proved.

Paleopathological comparison data are missing for the Pre-Pottery Neolithic of the Near East and very scarce for ancient Cyprus. According to the literature, there does not seem to be any other case prior to the Hellenistic period. DISH has been diagnosed by S. Fox (2005) on two adult individuals from one of the largest known collection of human remains

(MNI = 275) from the Cypriot Hellenistic and Roman periods, coming from the eastern necropolis of the ancient city of Nea Paphos.

CONCLUSION

The new case of probable DISH from the Pre-Pottery Neolithic site of Khirokitia in Cyprus described in this study is in addition to the scarce cases of DISH known from the prehistoric period. This study thus contributes to a better knowledge of the distribution of DISH in prehistoric populations. Although, according to the current state of knowledge, the oldest case was discovered in Iraq, it is the first time that a case dating to the Pre-Pottery Neolithic has been described in the Near East. Furthermore, this case comes from an island context, which makes it even more outstanding. The question arises as to whether the lack of described cases in other regions of the Pre-Pottery Neolithic Near East reflects a state of research or an actual absence of cases.

The fluctuating relationships of Cyprus with the neighbor mainland during the Neolithic period are only partly understood but it appears that connection between the island and the continent decreased during the 8th millennium, leading to the specificity of the late phase of the Pre-Pottery Neolithic in Cyprus (7th-early 6th millennium BC; Le Brun and Daune-Le Brun 2003). The numerous excavations carried out in the Near East have yielded an important anthropological documentation concerning the Neolithic period and bioarchaeological research is currently intensifying in the region. Nevertheless, certain approaches such as isotopic analysis of human remains or even deep palaeopathological studies are still rare for prehistoric periods. Future research in these domains should lead to a better understanding of the evolution of diet and health status of these populations during the Neolithization process. It would indeed be very interesting to be able to establish the prevalence of rheumatic diseases during the successive phases of the Neolithization process in the Near East and to analyze the influence of the island context.

ACKNOWLEDGMENTS

This work was financially supported by the French Archaeological Mission at Khirokitia (French Ministry for Foreign Affairs) and by the Archéorient laboratory. The first author wishes to express her gratitude to A. Le Brun who have entrusted to her the study of the burials and skeletal remains from Khirokitia. Thanks are also given to O. Le Brun, C. Baron and A. Fontaine for their help on the field and during the cleaning and reconstruction of the skeleton. Technical assistance in the illustration of this paper was provided by B. Chamel and F. Notter-Truxa. The authors are also grateful to the anonymous reviewers for their constructive comments.

FRANÇOISE LE MORT
Archéorient, UMR 5133
CNRS, Université Lyon 2
Lyon – FRANCE
francoise.le-mort@mom.fr

HENRI DUDAY
PACEA, UMR 5199
CNRS, Université de Bordeaux, Ministère de la Culture
Pessac – FRANCE
henri.duday@u-bordeaux.fr

BIBLIOGRAPHY

- AUFDERHEIDE A. and RODRIGUEZ-MARTIN C.
1998 *The Cambridge Encyclopedia of Human Paleopathology*. Cambridge: Cambridge University Press.
- ARRIAZA B. T.
1993 Seronegative spondyloarthropathies and diffuse idiopathic skeletal hyperostosis in ancient northern Chile. *American Journal of Physical Anthropology* 91: 263-278.
- ARRIAZA B. T., MERBS C. F. and ROTHCHILD B. M.
1993 Diffuse Idiopathic Skeletal Hyperostosis in Meroitic Nubians from Semna South, Sudan. *American Journal of Physical Anthropology* 92: 243-248.
- BOCQUENTIN F.
2003 *Pratiques funéraires, paramètres biologiques et identités culturelles au Natoufien : une analyse archéo-anthropologique*. Doctoral thesis, Université Bordeaux 1.
- BLOOM R. A.
1984 The prevalence of ankylosing hyperostosis in a Jerusalem population: with description of a method of grading the extent of the disease. *Scandinavian Journal of Rheumatology* 13: 181-189.
- CASSIM B., MODY G. M. and RUBIN D. L.
1990 The prevalence of diffuse idiopathic skeletal hyperostosis in African blacks. *British Journal of Rheumatology* 29: 131-132.
- CASTELLS NAVARRO L. and BUCKBERRY J.
2020 Back to the beginning: Identifying lesions of diffuse idiopathic skeletal hyperostosis prior to vertebral ankylosis. *International Journal of Paleopathology* 28: 59-68.
- CRUBÉZY E. and CRUBÉZY-IBANEZ E.
1993 Évaluation sur une série de squelettes de critères diagnostiques de la maladie hyperostotique. Implications épidémiologiques. *Revue du rhumatisme* 60: 586-590.
- CRUBÉZY E. and TRINKAUS E.
1992 Shanidar 1: A Case of Hyperostotic Disease (DISH) in the Middle Paleolithic. *American Journal of Physical Anthropology* 89: 411-420.
- DAUNE-LE BRUN O., HOURANI F. and LE BRUN A.
2017 Khirokitia (Chypre, VII^e-VI^e millénaires av. J.-C.), la séquence stratigraphique dans son contexte. In: VIGNE J.-D., BRIOIS F. and TENGBERG M. (eds.), *Nouvelles données sur les débuts du Néolithique à Chypre*: 217-228. Paris: Société préhistorique française (Séance de la Société préhistorique française 9).
- DAUNE-LE BRUN O. and LE BRUN A.
2016 “Singing in the Rain”: Khirokitia (Cyprus) in the Second Half of the Seventh Millennium cal. B.C. In: BIEHL P. F. and NIEUWENHUYSE O. (eds.), *Climate and Cultural Change in Prehistoric Europe and the Near East*: 153-168. Albany: State University of New York Press (IEMA proceedings 6).
- DAVIS S. J. M.
2003 The zoo-archaeology of Khirokitia (Neolithic Cyprus), including a view from the Mainland. In: GUILAINE J. and LE BRUN A. (eds.), *Le Néolithique de Chypre*: 253-268. Athens: École Française d’Athènes (Bulletin de Correspondance Hellénique, Supplément 43).
- DAVIS S. J. M.
In press The Neolithic mammals from Khirokitia, Cyprus: *stasis* and change on an oceanic Island. In: LE BRUN A. (ed.), *Fouilles récentes à Khirokitia (Chypre), 1993-2009*: 297-406. Nicosia: Department of Antiquities of Cyprus and CNRS.
- DENKO C. W. and MALEMUD C. J.
2006 Body mass index and blood glucose: correlations with serum insulin, growth hormone, and insulin-like growth factor-1 levels in patients with diffuse idiopathic skeletal hyperostosis. *Rheumatology International* 26: 292-297.

- DIKAIOS P.
1953 *Khirokitia. Final Report on the Excavation of a Neolithic Settlement in Cyprus on Behalf of the Department of Antiquities 1936-1946.* Oxford: Oxford University Press (Monograph of the Department of Antiquities of the Government of Cyprus 1).
- EL MIEDANY Y. M., WASSIF G. and EL BADDINI M.
2000 Diffuse idiopathic skeletal hyperostosis (DISH): is it of vascular aetiology? *Clinical and Experimental Rheumatology* 18: 193-200.
- FACCIA K., WATERS-RIST A., LIEVERSE A. R., BAZALIISKII V. I., STOCK J. T. and KATZENBERG M. A.
2016 Diffuse idiopathic skeletal hyperostosis (DISH) in a middle Holocene forager from Lake Baikal, Russia: Potential causes and the effect on quality of life. *Quaternary International* 405: 66-79.
- FORESTIER J. and ROTES-QUEROL J.
1950 Senile ankylosing hyperostosis of the spine. *Annals of the Rheumatic Diseases* 9: 321-330.
- FOSTER A., KINASTON R., SPRIGGS M., BEDFORD S., GRAY A. and BUCKLEY H.
2018 Possible diffuse idiopathic skeletal hyperostosis (DISH) in a 3000-year-old Pacific Island skeletal assemblage. *Journal of Archaeological Science: Reports* 18: 408-419.
- FOX S. C.
2005 Health in Hellenistic and Roman times. The case studies of Paphos, Cyprus and Corinth, Greece. In: KING H. (ed.), *Health in Antiquity: 59-82.* London and New York: Routledge.
- GIUFFRÀ V., GIUSIANI S., FORNACIARI A., VILLARI N., VITIELLO A. and FORNACIARI G.
2010 Diffuse idiopathic skeletal hyperostosis in the Medici, Grand Dukes of Florence (XVI century). *European Spine Journal* 19: 103-107.
- GORMAN C.
2005 A family with diffuse idiopathic skeletal hyperostosis. *Annals of the Rheumatic Diseases* 64: 1794-1795.
- HOLGATE R. L. V. and STEYN M.
2016 Diffuse Idiopathic Skeletal Hyperostosis: Diagnostic, Clinical, and Paleopathological Considerations. *Clinical Anatomy* 29: 870-877.
- HUKUDA S., INOUE K., USHIYAMA T., SARUHASHI Y., IWASAKI A., HUANG J., MAYEDA A., NAKAI M., LI F.X. and YANG Z. Q.
2000 Spinal degenerative lesions and spinal ligamentous ossifications in ancient Chinese populations of the Yellow River Civilization. *International Journal of Osteoarchaeology* 10: 108-124.
- JANKAUSKAS R.
2003 The incidence of skeletal hyperostosis and social status in Lithuanian skeletal materials. *International Journal of Osteoarchaeology* 13: 289-293.
- KACKI S. and VILLOTTE S.
2006 Maladie hyperostotique et mode de vie : intérêt d'une démarche bioarchéologique. Exemple du cimetière du Couvent des Sœurs Grises de Beauvais (Oise), xv^e-xviii^e siècles. *Bulletins et mémoires de la Société d'Anthropologie de Paris* 18,1-2: 55-64.
- KACKI S., VELEMÍNSKÝ P., LYNNERUP N., KAUPOVÁ S., LACOSTE JEANSON A., POVÝŠIL C., HORÁK M., KUČERA J., LUND RASMUSSEN K., PODLIŠKA J., DRAGON Z., SMOLÍK J., VELLEJ J. and BRŮŽEK J.
2018 Rich table but short life: Diffuse idiopathic skeletal hyperostosis in Danish astronomer Tycho Brahe (1546-1601) and its possible consequences. *PLOS One* 13,4: e0195920. doi.org/10.1371/journal.pone.0195920
- KIM S. K., CHOI B. R., KIM C. G., CHUNG S. H., CHOE J. Y., JOO K. B., BAE S. C., YOO D. H. and JUN J. B.
2004 The prevalence of diffuse idiopathic skeletal hyperostosis in Korea. *Journal of Rheumatology* 31: 2032-2035.
- KIM M. J., LEE I. S., KIM Y. S., OH C. S., PARK J. B., SHIN M. H. and SHIN D. H.
2012 Diffuse idiopathic skeletal hyperostosis cases found in Joseon Dynasty Human Sample Collection of Korea. *International Journal of Osteoarchaeology* 22: 235-244.
- KUPERUS J. S., DE GENDT E. E. A., ONER F. C., DE JONG P. A., BUCKENS S. C. F. M., VAN DER MERWE A. E., MAAT G. J. R., REGAN E. A., RESNICK D. L., MADER R. and VERLAAN J.-J.
2017 Classification criteria for diffuse idiopathic skeletal hyperostosis: a lack of consensus. *Rheumatology* 56: 1123-1134.
- KUPERUS J. S., BUCKENS C. F., ŠPREM J., ONER F. C., DE JONG P. A. and VERLAAN J.-J.
2018 The natural course of diffuse idiopathic skeletal hyperostosis in the thoracic spine of adult males. *Journal of Rheumatology* 45,8: 1116-1123.
- KUPERUS J. S., OUDKERK S. F., FOPPEN W., HOESEIN F. A. M., GIELIS W. P., WAALWIJK J., REGAN E. A., LYNCH D.A., ONER F. C., DE JONG P. A. and VERLAAN J.-J.
2019 Criteria for early-phase diffuse idiopathic skeletal hyperostosis: Development and validation. *Radiology* 291: 420-426.
- LANGE-BADRÉ B. and LE MORT F.
1998 Isotopes stables du carbone et de l'azote et éléments traces, indicateurs du régime alimentaire de la population néolithique de Khirokitia (Chypre). In: CAMPS G. (ed.), *L'homme préhistorique et la mer: 415-426.* Paris: Éditions du CTHS.
- LE BRUN A. (ed.)
1984 *Fouilles récentes à Khirokitia (Chypre), 1977-1981.* Paris: Éditions Recherche sur les Civilisations.
1989a *Fouilles récentes à Khirokitia (Chypre), 1983-1986.* Paris: Éditions Recherche sur les Civilisations.
1989b Le traitement des morts et les représentations des vivants à Khirokitia. In: PELTENBURG E. (ed.), *Early Society in Cyprus: 71-81.* Edinburgh: Edinburgh University Press.
1994a *Fouilles récentes à Khirokitia (Chypre), 1988-1991.* Paris: Éditions Recherche sur les Civilisations.

- 1994b Les vestiges architecturaux. In: LE BRUN A. (ed.), *Fouilles récentes à Khirokitia (Chypre), 1988-1991*: 33-154. Paris: Éditions Recherche sur les Civilisations.
- 1996 L'économie de Chypre au Néolithique. In: KARAGEORGHIS V. and MICHAELIDES D. (eds.), *The Development of the Cypriot Economy from the Prehistoric Period to the Present Day*: 1-16. Nicosia: The University of Cyprus and the Bank of Cyprus.
- In press *Fouilles récentes à Khirokitia (Chypre), 1993-2009*. Nicosia: Department of Antiquities of Cyprus and CNRS.
- LE BRUN A. and DAUNE-LE BRUN O.
2003 Deux aspects du Néolithique pré-céramique récent de Chypre : Khirokitia et Cap Andreas-Kastros. In: GUILAINE J. and LE BRUN A. (eds.), *Le Néolithique de Chypre*: 45-59. Athens: École Française d'Athènes (Bulletin de Correspondance Hellénique, suppl. 43).
- 2009 Khirokitia (Chypre) : la taille et les pulsations de l'établissement néolithique pré-céramique, nouvelles données. *Paléorient* 35,2: 67-76.
- LE BRUN A. and STANLEY PRICE N. P.
1977 Khirokitia 1976. *Bulletin de Correspondance Hellénique* 101: 733-736.
- LE MORT F.
1994 Les sépultures. In: Le Brun A (ed.), *Fouilles récentes à Khirokitia (Chypre), 1988-1991*: 157-198. Paris: Éditions Recherche sur les Civilisations.
- 2003 Les restes humains de Khirokitia : particularités et interprétations. In: GUILAINE J. and LE BRUN A. (eds.), *Le Néolithique de Chypre*: 313-325. Athens: École Française d'Athènes (Bulletin de Correspondance Hellénique, suppl. 43).
- LITTLEJOHN G. O. and SMYTHE H. A.
1981 Marker hyperinsulinemia after glucose challenge in patients with diffuse idiopathic skeletal hyperostosis. *Rheumatology* 8: 965-968.
- MADER R. and LAVI I.
2009 Diabetes mellitus and hypertension as risk factors for early diffuse idiopathic skeletal hyperostosis (DISH). *Osteoarthritis and Cartilage* 17: 825-828.
- MADER R., NOVOFESTOVSKI I., ADAMI M. and LAVI I.
2009 Metabolic syndrome and cardiovascular risk in patients with diffuse idiopathic skeletal hyperostosis. *Seminars in Arthritis and Rheumatism* 38: 361-365.
- MADER R., SARZI-PUTTINI P., ATZENI F., OLIVIERI I., PAPPONE N., VERLAAN J.-J. and BUSKILA D.
2009 Extraspinal manifestations of diffuse idiopathic skeletal hyperostosis. *Rheumatology* 48: 1478-1481.
- MADER R., VERLAAN J.-J., ESHED I., BRUGES-ARMAS J., SARZI PUTTINI P., ATZENI F., BUSKILA D., REINSSTEIN E., NOVOFESTOVSKI I., FAWAZ A., DE VLAM K. and BARALIAKOS X.
2017 Diffuse idiopathic skeletal hyperostosis (DISH): where we are now and where to go next. *Rheumatic & Musculoskeletal Diseases Open* 2017,3: e000472. doi:10.1136/rmdopen-2017-000472
- MAYS S.
2000 Diffuse idiopathic skeletal hyperostosis (DISH) in skeletons from two Mediaeval English cemeteries. *Journal of Paleopathology* 12: 25-36.
- MORI K., KASAHARA T., MIMURA T., NISHIZAWA K., NAKAMURA A. and IMAI S.
2017 Prevalence of thoracic diffuse idiopathic skeletal hyperostosis (DISH) in Japanese: Results of chest CT-based cross-sectional study. *Journal of Orthopaedic Science* 22: 38-42.
- MUNIR S., FREIDIN M., RADE M., MAÄTTÄ J., LIVSHITS G. and WILLIAMS F. M. K.
2018 Endplate defect is heritable, associated with low back pain and triggers intervertebral disc degeneration. A longitudinal study from TwinsUK. *Spine* 43,21: 1496-1501.
- MURAIL P., BRUZEK J., HOUËT F. and CUNHA E.
2005 DSP: A Tool for Probabilistic Sex Diagnosis Using Worldwide Variability in Hip-Bone Measurements. *Bulletins et Mémoires de la Société d'Anthropologie de Paris* 17,3-4: 167-176.
- NELSON E. A., HALLING C. L. and BUIKSTRA J.
2016 Investigating fluoride toxicity in a Middle Woodland population from west-central Illinois: A discussion of methods for evaluating the influence of environment and diet in paleopathological analyses. *Journal of Archaeological Science: Reports* 5: 664-671.
- 2019 Evidence of Skeletal Fluorosis at the Ray Site, Illinois, USA: a pathological assessment and discussion of environmental factors. *International Journal of Paleopathology* 26: 48-60.
- OLIVIERI I., D'ANGELO S., PALAZZI C., PADULA A., MADER R. and KHAN M. A.
2009 Diffuse Idiopathic Skeletal Hyperostosis: Differentiation from Ankylosing Spondylitis. *Current Rheumatology Reports* 11: 321-328.
- ORTNER D. J.
2003 *Identification of pathological conditions in human skeletal remains*. London: Academic Press.
- OSTENDORF SMITH M., DORSZ J. R. and BETSINGER T. K.
2013 Diffuse idiopathic skeletal hyperostosis (DISH) in pre-Columbian North America: Evidence from the eastern Tennessee River Valley. *International Journal of Paleopathology* 3,1: 11-18.
- PAPPONE N., DI GIROLAMO C., PUENTE A. D., SCARPA R. and ORIENTE P.
1996 Diffuse idiopathic skeletal hyperostosis (DISH): a retrospective analysis. *Clinical Rheumatology* 15: 121-124.
- PARES A. and TENGBERG M.
2017 Étude des pratiques d'exploitation et d'utilisation des ressources végétales du village de Khirokitia (Chypre) au Néolithique précéramique récent chypriote (VII^e-VI^e millénaires av. J.-C. In: VIGNE J.-D., BRIOIS F. and TENGBERG M. (eds.), *Nouvelles données sur les débuts du Néolithique à Chypre*: 241-252. Paris: Société préhistorique française (Séance de la Société préhistorique française 9).

- PETRONE P., GUARINO F., GIUSTINO S. and GOMBOS F.
2013 Ancient and recent evidence of endemic fluorosis in the Naples area. *Journal of Geochemical Exploration* 131: 14-27.
- PILLAI S. and LITTLEJOHN G.
2014 Metabolic factors in diffuse idiopathic skeletal hyperostosis: a review of clinical data. *The Open Rheumatology Journal* 8: 116-128.
- RESNICK D. and NIWAYAMA G.
1976 Radiographic and pathologic features of spinal involvement in diffuse idiopathic skeletal hyperostosis (DISH). *Radiology* 119: 559-568.
2002 *Diagnosis of bone and joint disorders*. Philadelphia: Saunders.
- ROGERS J. and WALDRON T.
2001 DISH and the monastic way of life. *International Journal of Osteoarchaeology* 11: 357-365.
- SALEEM S. N. and HAWASS Z.
2014 Brief report: Ankylosing spondylitis or diffuse idiopathic skeletal hyperostosis in royal Egyptian mummies of the 18th-20th dynasties? Computed tomography and archaeology studies. *Arthritis & Rheumatology* 66: 3311-3316.
- SCHMITT A.
2005 Une nouvelle méthode pour estimer l'âge au décès des adultes à partir de la surface sacro-pelvienne iliaque. *Bulletins et Mémoires de la Société d'Anthropologie de Paris* 17,1-2: 89-101.
- SIRASANAGANDLA S. R., AL DHUHLI H., AL ABRI A., SALMI A., JAYAPAL S. K., CROSETTO S. and JAJU S.
2018 Prevalence of diffuse idiopathic skeletal hyperostosis among elderly subjects referred for radiological investigation in tertiary hospital at Oman. *Anatomy & Cell Biology* 51: 174-179.
- STANLEY PRICE N. P. and CHRISTOU D.
1973 Excavations at Khirokitia, 1972. *Report of the Department of Antiquities, Cyprus* 1973: 1-33.
- TRINKAUS E., MALEY B. and BUZHILOVA A. P.
2008 Brief Communication: Paleopathology of the Kiik-Koba 1 Neandertal. *American Journal of Physical Anthropology* 137: 106-112.
- TRITSAROLI P.
2018 Skeletal evidence of Diffuse Idiopathic Skeletal Hyperostosis (DISH) in a collective burial from Byzantine Greece. *Anthropological Review* 81,1: 53-65.
- UTSINGER P. D.
1985 Diffuse idiopathic skeletal hyperostosis. *Clinics of Rheumatic Diseases* 11: 325-329.
- WALDRON T.
2009 *Palaeopathology*. Cambridge: Cambridge University Press.
2019 Joint disease. In: BUIKSTRA J. (ed.), *Ortner's Identification of Pathological Conditions in Human Skeletal Remains*, third edition: 719-747. London: Academic Press.
- WALSER J. W., GOWLAND R. L., DESNICA N. and KRISTJÁNSDÓTTIR S.
2020 Hidden dangers? Investigating the impact of volcanic eruptions and skeletal fluorosis in medieval Iceland. *Archaeological and Anthropological Sciences* 12: 77. doi.org/10.1007/s12520-020-01026-0
- WESTERVELD L. A., VAN UFFORD H. M., VERLAAN J. J. and ONER F. C.
2008 The prevalence of diffuse idiopathic skeletal hyperostosis in an outpatient population in The Netherlands. *Journal of Rheumatology* 35: 1635-1638.
- ZEHRA U., PUI YIN CHEUNG J., BOW C., LU W. and SAMARTZIS D.
2019 Multidimensional vertebral endplate defects are associated with disc degeneratin, modic changes, facet joint abnormalities, and pain. *Journal of Orthopaedic Research* 37,5: 1080-1089.

