



HAL
open science

Postictal stereo-EEG changes following bilateral tonic-clonic seizures

Aileen Mcgonigal, Patrick Marquis, Samuel Medina, Fabrice Bartolomei, Sylvain Rheims, Christophe Bernard, Christian G. Bénar

► **To cite this version:**

Aileen Mcgonigal, Patrick Marquis, Samuel Medina, Fabrice Bartolomei, Sylvain Rheims, et al.. Postictal stereo-EEG changes following bilateral tonic-clonic seizures. *Epilepsia*, 2019, 60 (8), pp.1743-1745. 10.1111/epi.16252 . hal-03509324

HAL Id: hal-03509324

<https://hal.science/hal-03509324>

Submitted on 4 Jan 2022

HAL is a multi-disciplinary open access archive for the deposit and dissemination of scientific research documents, whether they are published or not. The documents may come from teaching and research institutions in France or abroad, or from public or private research centers.

L'archive ouverte pluridisciplinaire **HAL**, est destinée au dépôt et à la diffusion de documents scientifiques de niveau recherche, publiés ou non, émanant des établissements d'enseignement et de recherche français ou étrangers, des laboratoires publics ou privés.

Postictal stereo-EEG changes following bilateral tonic-clonic seizures

Aileen McGonigal^{1,2}, Patrick Marquis^{1,2}, Samuel Medina^{1,2}, Fabrice Bartolomei^{1,2}, Sylvain Rheims^{3,4,5},
Christophe Bernard¹, Christian Bénar¹

¹Aix Marseille Univ, Inserm, INS, Institut de Neurosciences des Systèmes, Marseille, France

²APHM, Timone Hospital, Clinical Neurophysiology, Marseille, France

³Lyon University, Claude Bernard University, Lyon, France

⁴Department of Functional Neurology and Epileptology, Hospices Civils de Lyon (Lyon University Hospital), Lyon, France

⁵Lyon's Neuroscience Research Center (INSERM U1028, CNRS 5292), Lyon, France

Corresponding author : Dr Aileen McGonigal, Service de Neurophysiologie Clinique, CHU Timone, AP-
HM, Marseille, France

Email : aileen.mcgonigal@univ-amu.fr

Tel: 00 33 491384995

Fax: 00 33 491385826

To the Editors:

We read with interest Bateman et al's study¹ on postictal electroclinical changes following bilateral tonic-clonic seizures using subdural grids, depth electrodes or both. They observed post-ictal gamma

band activity in the majority of 31 seizures, while other frequencies were suppressed. This calls into question whether post-ictal generalized electroencephalographic (EEG) suppression (PGES) is characterized by absence of activity, as previously suggested. Gamma activity was hypothesized by the authors as possibly representing persistent brainstem activity.

We recently studied post-ictal electrical activity in 100 bilateral tonic-clonic seizures using stereoelectroencephalography (SEEG)². Different patterns were described: PGES (all electrodes involved), regional suppression (RS) (subset of electrodes), or no suppression. We used a 70Hz high frequency filter; therefore, observed absence of activity in PGES and RS was within the 0-70Hz range. Our definitions used different EEG criteria, notably higher sensitivity, to increase detection of low amplitude changes (<20 μ V/mm in our study versus a fixed 50 μ V/mm cut-off in Bateman et al.). This may help explain higher prevalence of “post-ictal attenuation” (24/31 seizures, 84%) in Bateman et al.’s series, compared to prevalence of PGES in our study (27/100 seizures, 27%). We acknowledge that the term “generalized” in PGES must be used with caution in the context of intracranial recording since the whole brain is not sampled, as previously discussed². We also highlight that in Marchi et al., we reported on 52 patients explored with SEEG, whereas Bateman et al. report 16 patients of whom 3 had stereotactically implanted depth electrodes and the remainder subdural recording. To investigate whether high gamma band activity was present in our cases, we randomly selected 3 previously described SEEG cases with PGES², all post-ictally unresponsive and immobile with no obvious muscle contraction. We studied unfiltered monopolar and bipolar recordings, sampled at 512Hz, using time-frequency analysis. This detected marked increase in gamma activity (20-120Hz) in both monopolar and bipolar recordings during PGES (Fig 1A) in all 3. We noticed an anatomical gradient, whereby gamma activity was seen in the most external electrode contacts, that is, closest to skull entry point. Indeed, some contacts displaying gamma activity were extra-cortical, within CSF space (Fig 1B). This raises the question of a non-cerebral cause. Previously, high gamma band power increases observed in SEEG electrodes close to periorbital regions were demonstrated to be contamination from ocular saccades³.

Association between tonic electromyographic (EMG) activity in frontalis muscles and presence of PGES was recently highlighted using surface EEG⁴, interpreted as possibly relating to seizure-induced hypoxemia as observed in rat models⁵. Authors excluded large EMG fluctuations associated with visible movements. Might it therefore be possible that some of the gamma activity observed by Bateman et al. is related to facial/scalp muscular contraction? They observed “rigid immobility” post-ictally in around 1/3 of cases; it would be interesting to look at association with gamma band activity and, most importantly, evaluate anatomical distribution of gamma.

In the light of these observations, we prospectively tested a single patient interictally, comparing SEEG signal with electromyography (EMG) of frontalis muscle. This showed gamma activity in external contacts of frontal SEEG electrode during voluntary facial contraction (Fig 1C and 1D), confirming muscle activity as a possible confounding factor.

Animal models of SUDEP show a large post-ictal DC shift in brainstem, likely reflecting depolarization block, which can underlie spreading depression⁶. This could explain both cardiorespiratory shutdown and PGES, observed in clinical cases of SUDEP⁷. However, widespread depolarization block would be expected to produce absence of broadband activity. Thus, further investigation is crucial to confirm whether observed gamma activity is of cerebral origin or not.

Acknowledgements

This work has been carried out within the Federation Hospitalo-Universitaire (FHU) EPINEXT thanks to the support of the A*MIDEX project (ANR-11-IDEX-0001-02) funded by the "Investissements d'Avenir" French Government program managed by the French National Research Agency (ANR).

Conflicts of Interest

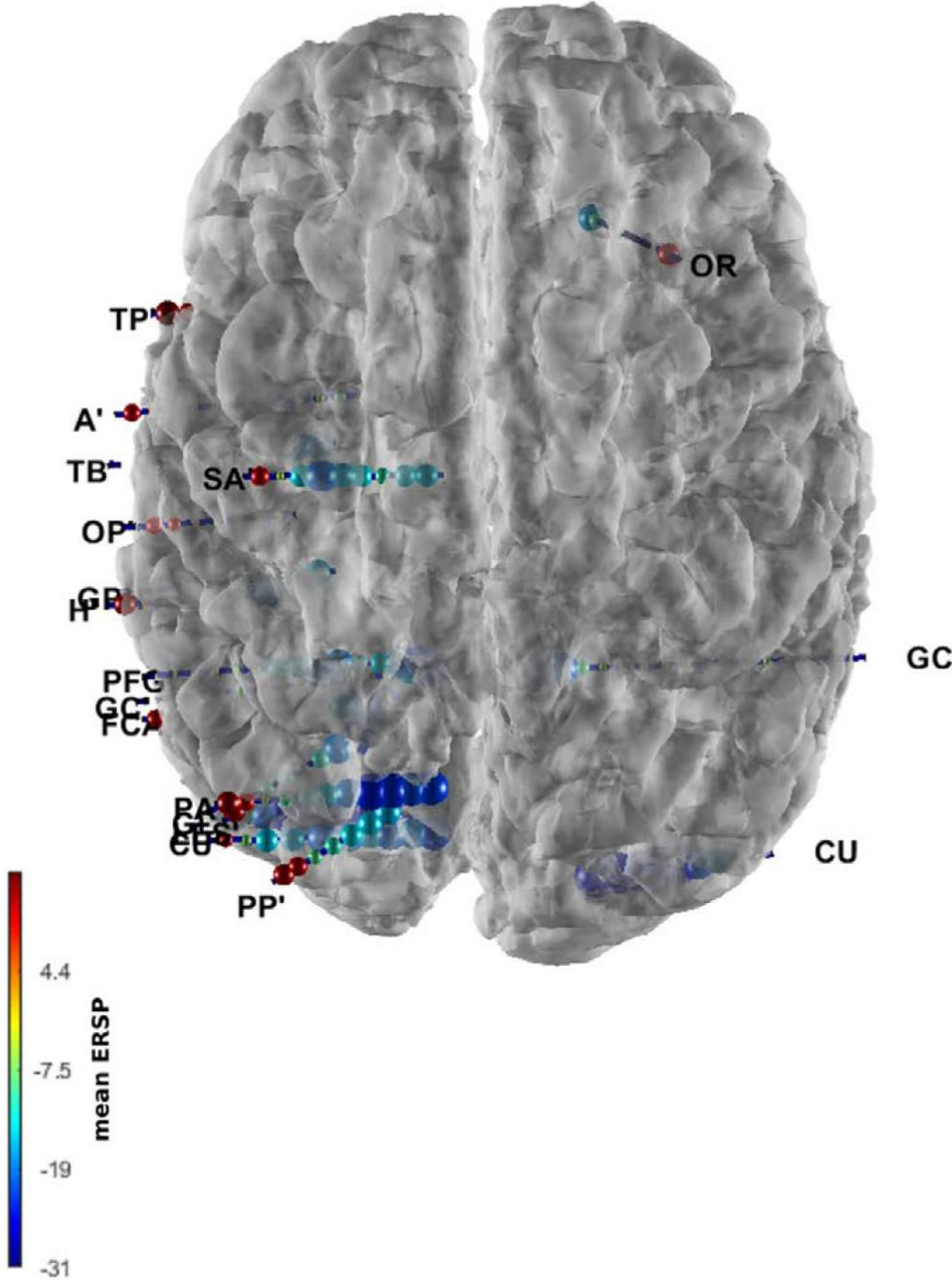
None of the authors has any conflict of interest to disclose.

Ethical Publication Statement

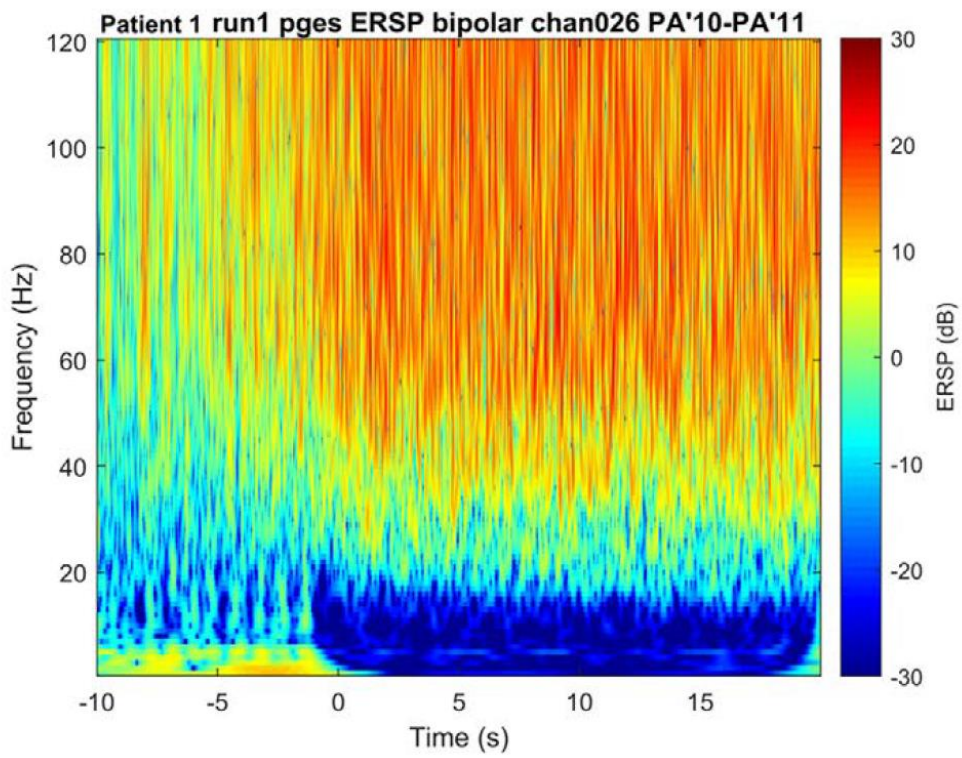
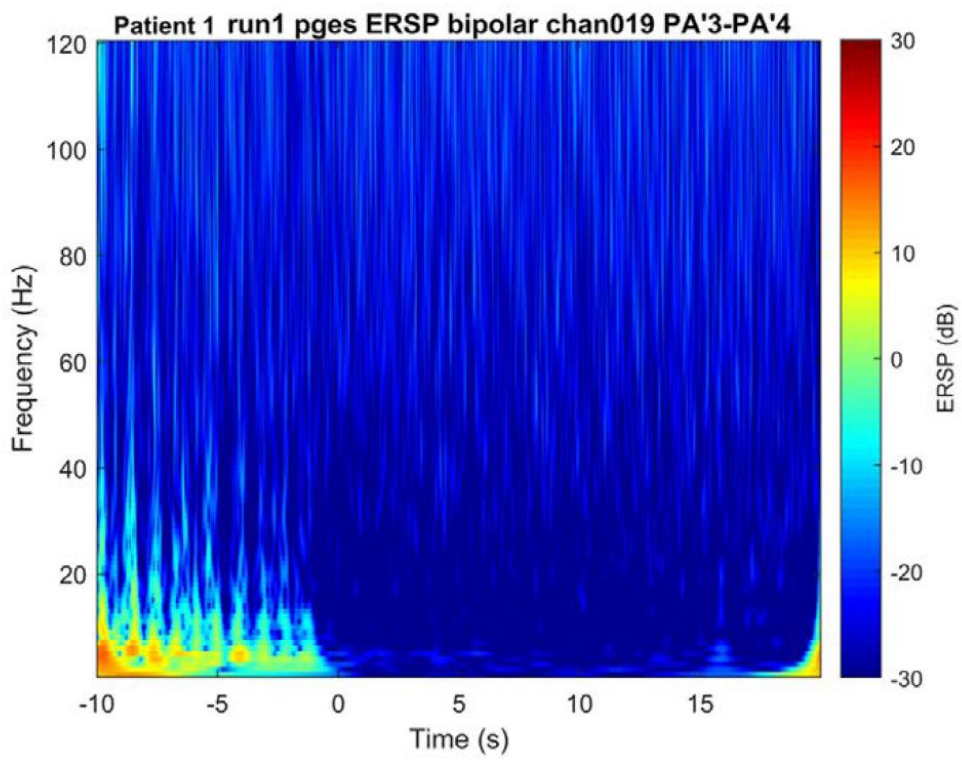
We confirm that we have read the journal's position on issues involved in ethical publication and affirm that this report is consistent with those guidelines.

Figure 1

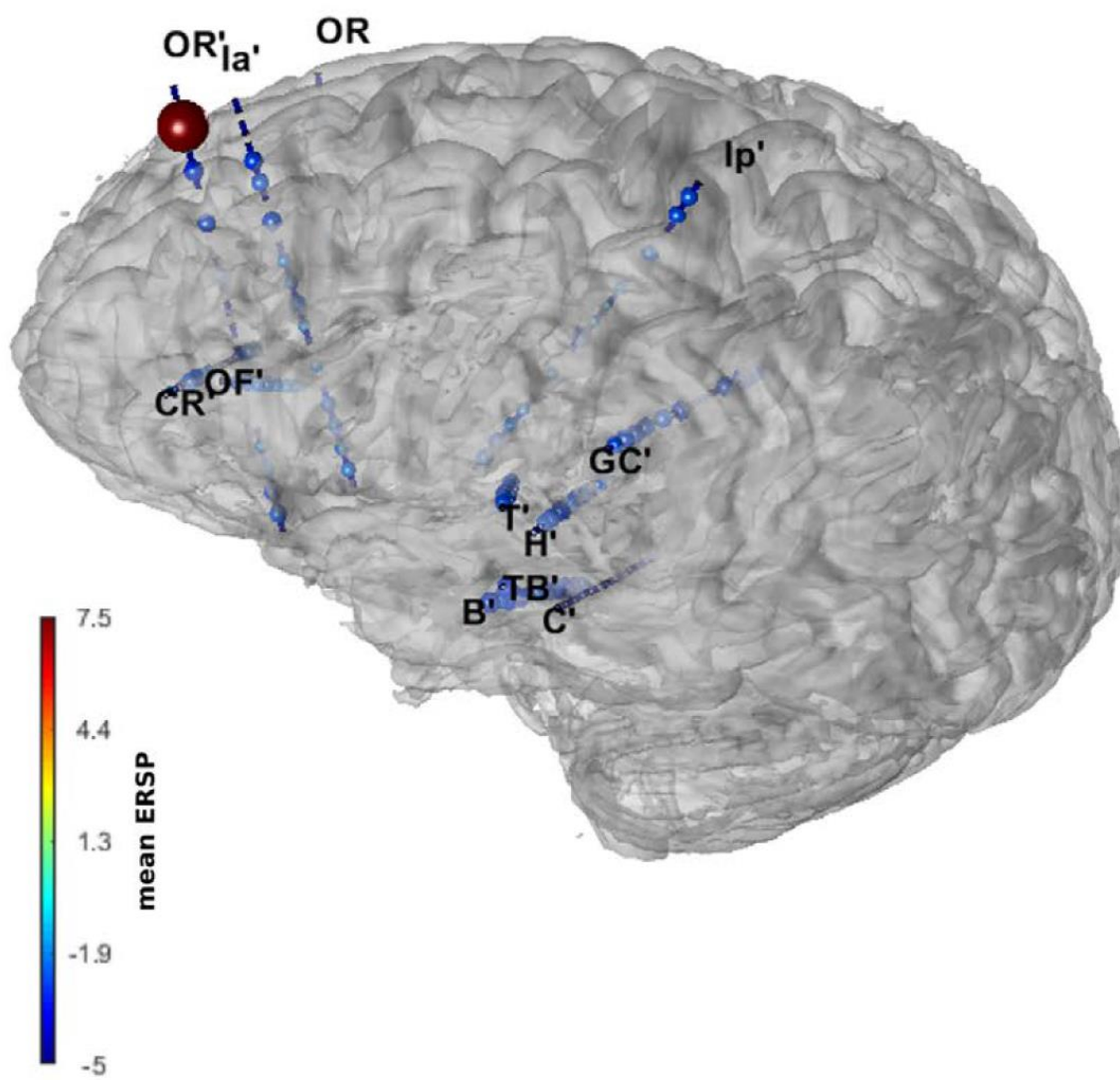
A



B



C



D

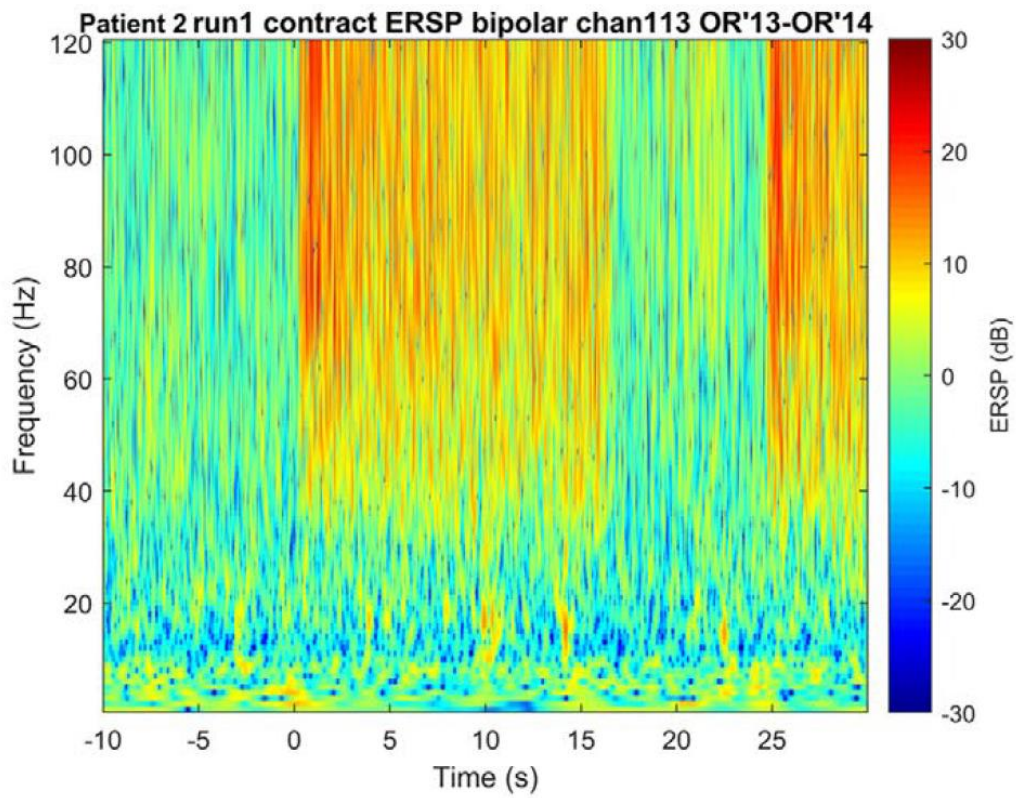
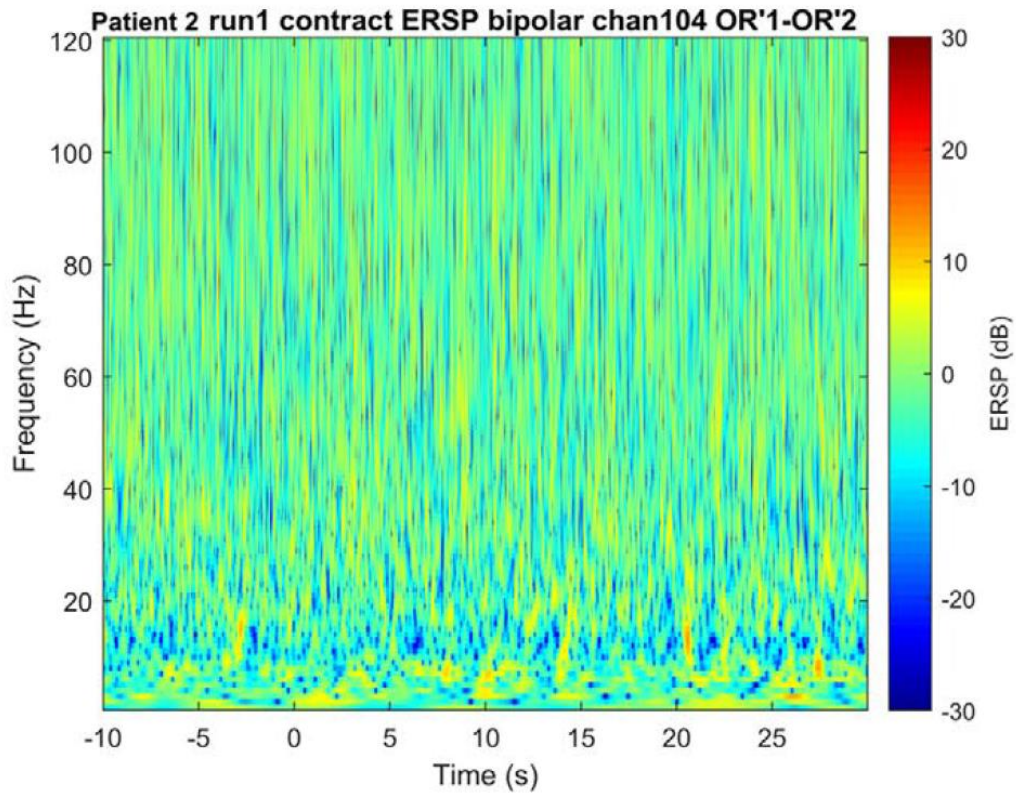


Figure 1a) shows the 3D cortical mesh with reconstructed electrodes of an adult male patient explored with stereoelectroencephalography (SEEG) for presurgical evaluation of left posterior cortex epilepsy, who presented generalized tonic-clonic seizures during SEEG (included in the series of Marchi et al²).

Each point of the TF plane (square amplitude) was divided by the mean in the baseline and represented in dB ($10 \cdot \log_{10}$). The spheres' size and color represent the values of event-related spectral perturbation (ERSP) averaged across time and frequency, measured during a 15-second time window during post-ictal generalized electroencephalographic (EEG) suppression (PGES). The red spheres indicate presence of gamma band activity (40-120Hz) and the blue spheres indicate suppression in the same frequency band. It can be seen that gamma activity is present in a superficial cortical and sometimes extracortical distribution across multiple electrodes. Figure 1b) shows ERSP for a selected deep contact of the left parietal electrode PA' (top) of the same patient during the period of transition from seizure termination (at time=0 sec) to PGES, and a superficial contact of the same electrode (bottom) during the same time window. The deep contact shows broadband suppression of activity whereas the superficial electrode shows marked increase in gamma activity from 40-120Hz. Figure 1c) and 1d) show the same processing as in 1a) and 1b) respectively, but for another patient during a facial contraction task. The adult female patient, who was being explored with SEEG for temporo-frontal epilepsy, performed voluntary facial contractions during the interictal period, with simultaneous electromyography (EMG) of bilateral frontalis muscle. During periods of facial contraction, gamma band increase (40-120Hz) was seen in the superficial contacts of the oblique electrode OR' exploring left dorsolateral prefrontal cortex, which corresponded with timing of EMG signal increase. These electrode contacts were anatomically closest to the muscle being contracted. Other deeper contacts of the same electrode and other electrodes did not show gamma activity during voluntary muscle contraction of frontalis.

References

1. Bateman LM, Mendiratta A, Liou JY, et al. Postictal clinical and electroencephalographic activity following intracranially recorded bilateral tonic–clonic seizures. *Epilepsia* 2019;60:74-84.
2. Marchi A, Giusiano B, King M, et al. Postictal electroencephalographic (EEG) suppression: A stereo-EEG study of 100 focal to bilateral tonic–clonic seizures. *Epilepsia* 2019;60:63-73.
3. Jerbi K, Freyermuth S, Dalal S, et al. Saccade related gamma-band activity in intracerebral EEG: dissociating neural from ocular muscle activity. *Brain Topogr.* 2009;22:18-23.
4. Park KJ, Seyal MJE. Tonic electromyographic activity following bilateral tonic–clonic seizures is associated with periictal respiratory dysfunction and postictal generalized EEG suppression. *Epilepsia* 2019.
5. Lee K-Z, Fuller DDJRp, neurobiology. Hypoxia-induced short-term potentiation of respiratory-modulated facial motor output in the rat 2010;173:107-111.
6. Bernard C. Spreading depression: Epilepsy's wave of death. *Sci. Transl. Med.* 2015;7:282fs214-282fs214.
7. Ryvlin P, Nashef L, Lhatoo SD, et al. Incidence and mechanisms of cardiorespiratory arrests in epilepsy monitoring units (MORTEMUS): a retrospective study. *Lancet Neurol* 2013;12:966-977.