



HAL
open science

Back to basics: the neuronal substrates and mechanisms that underlie the electroencephalogram in premature neonates

Fabrice Wallois, Laura Routier, Claire Heberlé, Mahdi Mahmoudzadeh, Emilie Bourel-Ponchel, Sahar Moghimi

► To cite this version:

Fabrice Wallois, Laura Routier, Claire Heberlé, Mahdi Mahmoudzadeh, Emilie Bourel-Ponchel, et al.. Back to basics: the neuronal substrates and mechanisms that underlie the electroencephalogram in premature neonates. *Neurophysiologie Clinique = Clinical Neurophysiology*, 2021, 51 (1), pp.5-33. 10.1016/j.neucli.2020.10.006 . hal-03499633

HAL Id: hal-03499633

<https://hal.science/hal-03499633>

Submitted on 14 Feb 2023

HAL is a multi-disciplinary open access archive for the deposit and dissemination of scientific research documents, whether they are published or not. The documents may come from teaching and research institutions in France or abroad, or from public or private research centers.

L'archive ouverte pluridisciplinaire **HAL**, est destinée au dépôt et à la diffusion de documents scientifiques de niveau recherche, publiés ou non, émanant des établissements d'enseignement et de recherche français ou étrangers, des laboratoires publics ou privés.



Distributed under a Creative Commons Attribution - NonCommercial 4.0 International License

COMPREHENSIVE REVIEW

BACK TO BASICS: THE NEURONAL SUBSTRATES AND
MECHANISMS THAT UNDERLIE THE ELECTROENCEPHALOGRAM
IN PREMATURE NEONATES

Fabrice Wallois*^{1,2}, Laura Routier^{1,2}, Claire Heberlé^{1,2}, Mahdi Mahmoudzadeh^{1,2}, Emilie Bourel-Ponchel^{1,2}, Sahar Moghimi^{1,2}

¹ INSERM U1105, Research Group on Multimodal Analysis of Brain Function, Jules Verne University of Picardie, Amiens, France

² Service d'explorations fonctionnelles du système nerveux pédiatrique, Amiens-Picardie Medical Center, Amiens, France

Corresponding author: Fabrice Wallois. INSERM U1105, Research Group on Multimodal Analysis of Brain Function, Jules Verne University of Picardie, Amiens, France

Tel: +33 683120714

*: fabrice.wallois@u-picardie.fr

Running title: Neuronal substrates of EEG in premature neonates

Abstract

Electroencephalography is the only clinically available technique that can address the premature neonate normal and pathological functional development week after week. The changes in the electroencephalogram (EEG) result from gradual structural and functional modifications that arise during the last trimester of pregnancy. Here, we review the structural changes over time that underlie the establishment of functional immature neural networks, the impact of certain anatomical specificities (fontanelles, connectivity, etc.) on the EEG, limitations in EEG interpretation, and the utility of high-resolution EEG (HR-EEG) in premature newborns (a promising technique with a high degree of spatiotemporal resolution). In particular, we classify EEG features according to whether they are manifestations of endogenous generators (i.e. theta activities that coalesce with a slow wave or delta brushes) or come from a broader network. Furthermore, we review publications on EEG in premature animals because the data provide a better understanding of what is happening in premature newborns. We then discuss the results and limitations of functional connectivity analyses in premature newborns. Lastly, we report on the magnetoencephalographic studies of brain activity in the fetus. A better understanding of complex interactions at various structural and functional levels during normal neurodevelopment (as assessed using electroencephalography as a benchmark method) might lead to better clinical care and monitoring for premature neonates.

Keywords: coalescence, connectivity, coupling, delta brush, endogenous generator, immature, magnetoencephalography, nested activity, network, phase amplitude coupling, subplate, theta temporal.

Contents

Introduction.....	3
Anatomical overview of immature neural networks	5
High-resolution EEG recording in preterm neonates	6
Specific features of the EEG in premature neonates	8
Network-based dynamics.....	9
Bursts.....	9
Spontaneous activity transients (SATs)	12
Generator-based dynamics	12
Endogenous generators	13
Coalescence between generators: nested activity.....	13
The coalescence between theta activities and slow waves	13
Delta brushes in neonates.....	15
Delta brushes in newborn animals.....	17
Frontal sharp transients	19
The impact of sleep stages on spontaneous activity in premature neonates	19
Connectivity analyses	20
Connectivity of the TTA-SW	21
Aspects of magnetoencephalography in fetuses	22
Functions of immature networks	23
Conclusion	24

Introduction

The structural and functional maturation of premature neonates is characterized by highly dynamic changes in EEG features. By placing electrodes on the scalp, the EEG quantifies the potentials created by electrically dynamic regions in the brain. Interpretation of the EEG must take account of these maturation processes; the EEG changes week after week, and so electroencephalography constitutes a unique tool for evaluating the physiological and pathological features of the brain as a function of the gestational age. The premature neonate EEG results from synaptic interactions within the cortical plate and subplate. The micro-scale electric fields produced by these interactions can then be synchronized across a large set of parallel neurons into macro-scale electric fields that (if they extend to the surface) can be recorded on the scalp [159]. In the adult, brain activity mainly corresponds to complex networks involving the thalamocortical loop and short- and long-range cortical connections. In contrast, the premature neonate brain activity results mainly from local and regional developmental processes [102]. The analysis of EEGs in premature newborns must take account of the specific features of neurodevelopment under normal and pathological circumstances. During normal development, the macroscopic maturation of the brain (especially gyrification), changes in bone thickness, and closure of the fontanelles affect the amplitude and spatial distribution of the brain activities that give rise to the EEG. Pathological factors such as preterm brain injury, intraventricular haemorrhage, white matter damage (periventricular leukomalacia), and perinatal inflammation can influence the brain's structure and function and thus the EEG in preterm neonates [185].

[FIGURE 1]

On the cellular level, many mechanisms operate simultaneously (Figure 1). Cell proliferation is almost complete at 22 weeks of gestational age (wGA) [89], radial neuronal migration ends at around 26 wGA, and tangential neuronal migration ends after birth [89]. Neuronal density, synaptogenesis, cell differentiation, optimization, synaptic reorganization, and apoptosis are developing quickly at this time. At between 23-25 wGA, subplate neurons start to interact with thalamic afferent fibres [83]. After 26 wGA, thalamocortical fibres start to relocate to the cortical plate [83,89]. This provides the first direct thalamic input to the postsynaptic cortical plate neurons, connects the cortical plate to the environment [84,85,87,88,90,91,117] and thus marks the onset of "sensory-expectant" cortical functions [89]. During this early step in neurodevelopment, transient complex circuits comprising the subplate, the initial cortical plate and the thalamus are involved in the processing of sensory information [85]. At this time point, the vascular system is fragile and lacks a robust cerebrovascular self-regulatory mechanism; this might explain the occurrence of intraventricular haemorrhage in

premature neonates [64]. The vascular system develops in parallel with the neural networks and thus establishes the first cortical columns [54]. The subplate has an important role in the latter process [89]. Myelination (which will ultimately increase the speed of transmission of information and optimize early connectivity between various structures) occurs in a gradual, asynchronous manner in different cortical areas [38].

These and other complex processes are likely to account for the specific nature of the EEG during maturation of the underlying neural networks. Hence, electroencephalography is the benchmark tool for performing functional analyses with an excellent time resolution (<1 msec). In the 1950s and 1960s, Dreyfus-Brisac et al. and Monod et al. [35,119] defined a number of maturation and prognostic criteria for premature neonates. In addition to clinical aspects, analysis of the EEG in premature neonates provides a detailed understanding of the functional maturation of neuronal circuits in early-stage development. The development of high-resolution 64-electrode electroencephalography in preterm neonates below 32 wGA (Seenel Imaging®, LF Neocap) (Figure 3) and 128 electrodes electroencephalography for those over 32 wGA (EGI®, Geodesic sensor) (Figure 7) significantly improved the technique's spatial resolution [106,148,150].

Electroencephalography is and will remain the benchmark method for non-invasive analysis of the normal and pathological operation of neural networks in premature neonates.

[FIGURE 2]

[FIGURE 3]

With a view to understanding the origin of the EEG in premature neonates, the following sections describe anatomic and functional aspects of the infant's brain and focus on the mechanisms of neural activity. First, we discuss the origin of the brain's electrical activity on various spatial scales, ranging from micro-scale electrical signals to the macro-scale signals that can be measured on the scalp surface. We then describe the different types of EEG neurobiomarker observed in premature neonates.

Anatomical overview of immature neural networks

Significant human brain growth occurs during the third trimester of pregnancy, with a doubling of the whole-brain volume and a fourfold increase in cortical grey matter volume. This is also the period during which cortical folding and gyrification take place [97]. Differential progression of cortical folding occurs during the pre-term period; it starts slowly and then progresses quickly from around 31 wGA until term, with smaller changes after term and during early infancy. The substantial increase in cortical folding between 31 and 39 wGA might correspond to the expansion of cortical tissue

caused by migration of neurons from the subplate into the cortex, with successive waves triggering the primary, secondary and tertiary folding events [3,39].

The subplate is the key functional structure in the developing neonatal cerebral cortex [117]. In premature neonates, the subplate is 1.5 to 4 times thicker than the cortical plate. It is defined as a transient layer located above the intermediate zone and below the cortical plate in the developing cerebral cortex [101]. In premature neonates, the subplate's thickness peaks at around 28 wGA [85]. The population of subplate neurons is quite complex and comprises a variety of morphologically and biochemically distinct subpopulations [88]: pyramidal-like and inverted pyramidal-like neurons, horizontally orientated neurons, neurogliaform cells, and polymorphic neurons (see [101] for a review). The neurons' high electrical membrane resistance suggests that they might be excited by small postsynaptic currents. The development of the subplate's synaptic connectivity is depicted in Figure 4. The subplate neurons' inputs arise from the thalamus, the cortical plate and other subplate neurons, while the outputs are directed to the cortex [52,125], thalamus (which might participate in developing corticothalamic feedback loops [73,125]) and (via corpus callosum fibres) the contralateral hemisphere. The subplate neurons' functional role was recently reviewed by Luhman et al. [101]. The subplate has a role in (i) the establishment and functional maturation of thalamocortical connections via projections to the growing cortical plate, (ii) feedback projections to the thalamus, (iii) the activity-dependent development of cortical columns, which might result from gap junctional coupling between radial glial cells and migrating neurons [43,44,144], and (iv) radial neuronal migration [101]. Indeed, the subplate is ideally positioned for active participation in the transmission and amplification of information arising from non-cortical structures within the neuronal network during a critical period in early cortical development. Some pathological situations (such as hypoxic-ischemic injury) affects the subplate's functions, structure [154], and interaction with the endogenous generators [145]. Dysfunction of subplate neurons has been implicated in neurodevelopmental disorders such as epilepsy as a result of hyperconnectivity, which (during this developmental period) is mainly related to interactions between the subplate and the cortical plate [128]. Lastly, the subplate is involved in some forms of drug-resistant epilepsy, in which heterotopy involves neurons similar to those found in the subplate [83,146].

[FIGURE 4]

It is in the subplate that the first thalamocortical connections are established. The thalamic afferents "wait" in the subplate before relocating to the cortical plate. The widespread arborization of the thalamocortical fibres enables synaptic interactions with subplate neurons [85,88,141]. With relocation of the thalamic afferents, the first synapses in the cortical plate arise after 26 wGA, when

synaptogenesis in the subplate is still ongoing [83]. The presence of thalamocortical afferents and their synapses with neurons located in the cortical plate constitutes the anatomical substrate for processing peripheral sensory impulses entering the cortex. This leads to dual, transient innervation of the brain, with complex interactions between the thalamic afferents and the permanent cortical plate (which develop continuously) and between the thalamic afferents and the transient subplate (which disappear around term). These transient dual circuits subserve the amplification and monitoring of sensory information via feedback loops that progressively arise between the thalamus and the cortex [125]. The subplate neurons are the first cortical neurons to respond to sensory stimuli [191].

[FIGURE 5]

The pyramidal cells migrate through the subplate to their final destination. During this crossing, they acquire information that will be required for their differentiation, synaptogenesis, final destination, and eventually apoptosis [59]. Synaptogenesis starts deep in the cortex before developing in the surface layers after 28 wGA [88]. Interneurons develop progressively after the pyramidal cells that they subsequently control [109]. By 30 wGA, non-myelinated callosal fibres are present in the subplate [88] and inhibit bursts of electrical activity [72]. Intra- and interhemispheric connectivity starts to arise in the last trimester of pregnancy (29 to 34 wGA), with the establishment of long and short pathways [166]. By term, all the major fibre systems are in place [37]. The early laminar organization of the cerebrum (with a cortical plate, subplate zone, intermediate zone, subventricular and periventricular zones, and germinal matrix) have been delineated in 25–27 w GA preterm neonates [103].

The EEG activity recorded in premature neonates reflects these very dynamic mechanisms (synaptogenesis, differentiation, migration, gyrification, and myelination) arising during the third trimester of pregnancy. Accordingly, it is not surprising that the premature neonate's EEG changes week after week as a function of the various ongoing processes (Figure 8).

High-resolution EEG recording in preterm neonates

Specific structural and developmental features must be taken into account when interpreting the EEG in preterm neonates. Firstly, the absence of gyri means that all the dipoles resulting from synchronized neuronal activity are oriented much more perpendicularly to the surface of the scalp, which results in a denser electromagnetic field (Figure 6). Secondly, the absence or immaturity of inter and intra-hemispheric connections among the pyramidal neurons minimizes the dispersion of the electromagnetic field. Thirdly, the thinness of the skull and the relative absence of an

intermediate layer make the bone tissue less dispersive [58,60]. Fourthly, the low densities of neurons and synapses reduce synchronization among neuronal populations inside the cortical networks. Fifthly, greater bone conductivity facilitates ion transfer to the surface [60,92,148,167] and allows the recording of deeper dipoles [148,150,177]. Sixthly, the source location (which change with synaptogenesis during the development of deep and then superficial layers [88]) impacts the cortical representation of the source. Deep synaptogenesis before 28 wGA is likely to produce positive cortical surface potentials [86,116] while later superficial synaptogenesis (after 28 wGA) might induce negative cortical surface potentials [57] (see [160] for a summary of the changes in electrical field potential elicited by the activation/inhibition of deep/superficial synapses in the central nervous system).

[FIGURE 6]

As in adults, the cerebrospinal fluid is one of the most important parameters in premature neonates [7–9,150,182]. In premature neonates, the presence of fontanelles is likely to create an additional error (of a few centimetres) in the location of the physiological and pathological sources - notably when these are located under the fontanelles [7,55,95,143,148] Figure 6). A recent simulation study of a head model of a term newborn highlighted the lack of a ceiling effect when using 11 to 85 electrodes [167]. Moreover, the optimal interelectrode distance was no greater than 2 or 3 cm [132]. Using 68 electrodes, the HR EEG recordings revealed epileptic discharges that are recorded only under one electrode: this means that more electrodes are required in neonates than in adults. In particular, source localization and solution of the inverse problem require the capture of information from many electrodes [150]. Therefore, increasing the electrode number and decreasing the electrode diameter might be an elegant solution for HR EEG - particularly for premature neonates in which immaturity has an even greater the impact on the EEG features. Furthermore, the electrode's "equivalent" size is related to linkage of the areas of gel around the electrodes. In the future, it might be possible to minimize this effect by using dry electrodes or electrocorticography strips.

The introduction of HR electroencephalography systems [1,58,106,132,136,148,150,167,184] has enabled the characterization of spatiotemporal changes in neuronal networks during early-stage neonatal development. It is now feasible to record an EEG in preterm neonates from 26 wGA onwards with a 64-channel set-up or from 32 wGA onwards with a 128-channel set-up. Various theoretical studies have sought to determine the optimum number of electrodes [58,132,148,167].

[FIGURE 7]

In neonates, the linked mastoid montage is better than longitudinal or transverse montages with 19 electrodes [167], the benchmark average montage is best when more than 32 are used, and the Laplacian montage is best when more than 66 electrodes are used [167]. The latter montage becomes unreliable at lower electrode numbers because of its sensitivity to edge effects [68,104]. Furthermore, one should be cautious when using the average montage with fewer than 36 electrodes in measurements on premature and full-term neonates [192] because this might reintroduce very-high-amplitude signals (theta temporal and slow-wave activity (TTA-SW) or delta brushes) into other electrodes; the high-amplitude signals cannot be minimized by averaging a small number of electrodes.

Regardless of the recording method *per se*, the EEGs in premature neonates are frequently polluted by artefacts such as electrical activity of the eye, heart and muscles, mains electricity noise, etc. With a view to solving this problem, several signal pre-processing strategies have been used to produce signals with less contamination and that facilitate identification of “relevant” data.

Since the EEG electrodes record electrical activity generated by all sources in their vicinity (i.e. eye movements and heart activity), the premature neonate’s EEG signals are regularly contaminated by electrooculographic and electrocardiographic activities. There are five main strategies for dealing with EEG artefacts. The first, most direct strategy is to avoid recording undesirable activity. The correct use of an EEG cap and the presence of conductive gel between the electrodes and the scalp can remove environmental activity and increase the signal-to-noise ratio. The second strategy is to use an averaging reference montage; one assumes that the noise in the recording is common between all electrodes and that the signal of interest is more focal. The third strategy involves rejecting the parts of the EEG that contain artefacts. The fourth strategy is based on filtering; this is probably the quickest, most straightforward approach for removing artifacts from the premature neonate’s EEG. In the fifth strategy, data decomposition methods (such as independent component analysis) are used to choose the relevant activity and remove electrooculographic and electrocardiographic artifacts.

Specific features of the EEG in premature neonates

[FIGURE 8]

Most of our knowledge about the development of cortical activity during the last trimester of the pregnancy in humans is based on scalp EEG recordings of premature neonates and (more recently)

from fetal magnetoencephalography recordings (see the section of magnetoencephalography below). The earliest recordings (obtained in the 1950s) had already outlined the characteristics of the EEG in preterm neonates. This early research was translated rapidly into the clinic for the routine characterization of age-related normal brain activity, the identification of early dysfunctions in brain activity, monitoring during treatment in the neonatal intensive care unit, and the definition of prognostic markers for neurodevelopment. The analysis of EEG features during neurodevelopment can be based on network-based and generator-based dynamics (Figure 8).

In the first network-based dynamics, the newborn's EEG is characterized by the alternation of bursts of activity (“up” periods) and quiescent periods (from the Latin verb *quiescere*, to rest or to be quiet; also referred to as the “down” period or the interburst interval (IBI). The bursts are composed of relatively long-lasting, complex activities, the frequencies of which change over the course of development. These complex activities may include and modulate the cerebral manifestation of the spontaneous endogenous generators (see below the endogenous generator dynamics section). The discontinuity should not be confused with the burst suppression observed in certain pathological situations in the term neonate or adult and which results from different mechanisms [74]. The physiological discontinuity progressively diminishes during maturation and leads to a “tracé alternant” at term [35]. Simultaneously, the EEG’s amplitude decreases gradually and the frequency content increases gradually up to 40 wGA [4,17]. This initial change corresponds to the progressive implementation of functional interactions within cortical and subcortical neural networks, including the dual network of cortical plate and subplate neuronal interactions. Similarly, the gradual development of sleep stages from 28 wGA [29] suggests the presence of early, progressive interactions between neural networks in subcortical structures and those in cortical structures.

The second dynamic is based on the identification of age-specific cortical and/or subcortical generators in premature newborns. These generators have different spatiotemporal and spectral characteristics and appearing sequentially during neurodevelopment. Frontal activities appear at between 24 and 28 wGA and are followed by TTA-SW at between 26 and 32 wGA, delta brushes between 29 and 36 wGA, and frontal transient and slow anterior dysrhythmia between 36 and 42 wGA. These generator-based changes result from interactions between thalamic afferents, the subplate and the cortical plate, which are likely to be related to the functional status of cortical neural networks (guidance, synaptogenesis, receptor function, etc.).

Network-based dynamics: Bursts (Figure 9 and 10)

Burst activity in neuronal circuits is considered to be vital for normal cortical development [12,77,78,127]. Spontaneous discontinuous activity or intermittent activity is observed in many cortical structures (including the hippocampus and the neocortex) and in many different species. This activity is present even before sensory mechanisms become functional [78,121,133,156,169,176].

[FIGURE 9]

The burst pattern is not specific to human premature neonates but can also be observed in other species [25]. Bursts are observed from 20 wGA onwards in premature cortical brain slices and thus are not directly related to or induced by peripheral stimulation or thalamic afferents [121], at least in the earliest stages of development. These spontaneous activities are recorded from subplate neurons. In the developing human cortex at 20 wGA, subplate neurons generate spontaneous, unprovoked, electrical activity in vitro (duration: 200 ms to 30 s), with sustained plateau depolarization, bursts of action potential firing, and a slow oscillation pattern [121]. The EEG signal in preterm neonates might therefore primarily reflect the physiological function of the subplate zone. Nevertheless, synaptic inputs to subplate neurons are scarce [121] and the various orientations of the subplate neurons [101] would not favour the generation of an electromagnetic field orientated perpendicular to the surface of the cortex and that could be recorded by surface EEG electrodes. Alternatively, the recorded EEG signals might represent the overall output of synchronized interactions between subplate neuronal networks and migrating pyramidal cells, providing the ascending pyramidal cells (pyramidal-like and inverted pyramidal-like cells with the main dendrite with a ventricular orientation [101]) with guidance for gene expression, neuronal migration, axonal growth, transmitter receptor activation, programmed cell death, the development of mature ion channels, and synapse formation [120,121,161]. The period of plateau depolarization and action potentials within the subplate network may be associated with (i) the functional shaping of the future cortical plate and (ii) establishment of the human cortical network prior to subplate involution and the formation of thalamocortical synapses (from 26-28 wGA onwards)[85].

In premature neonates, these intermittent bursts increase in duration and decrease in amplitude with gestational age [4,17,169]. This feature has been implemented in some algorithms for the automatic characterization of the gestational age of premature newborns [164]. Before 28 wGA, these bursts are made up of spontaneous activities that are not exogenously sensory-driven in an immaturely wired brain [115,150]. These intermittent, spontaneous activities are the key functional drivers of early neuronal development; in animal models, neuron deprivation and the disruption of these events leads to disorganized thalamocortical connectivity and apoptotic cell death [21,80,168].

Furthermore, the cortical bursts' various characteristics (duration and amplitude) predict the long term neurodevelopmental outcome [67,72]. The bursts' content can be altered in certain disease states (i.e. intraventricular haemorrhage) with regard to the time domain, the disappearance of spontaneous generators, and changes in the frequency content, shape and mean sharpness); these features are significant diagnostic and prognostic factors for the child's neurodevelopmental outcome [72]. This way of characterizing the bursts is efficient enough to predict the outcome (burst suppression) in hypoxic full-term neonates [72,147].

The dominant frequency and amplitude within the burst

The decrease in the burst's dominant amplitude and the increase in dominant frequency with age within the bursts have been studied ever since the first neonatal EEGs were described [4,134,169,176]. These changes have been attributed to the progressive development of connectivity in functional cortical networks (see the section on functional connectivity below). This suggests that the mechanism responsible for continuous activity at these frequencies builds up gradually within the cortex during the last trimester of pregnancy.

Discontinuity, quiescence, and synchrony (Figure 10)

Apart from a transient asynchronous period between 32 and 34 wGA, burst discontinuity occurs simultaneously in both hemispheres (Figure 10) [183]. This is suggestive of a general mechanism that repeatedly modifies the excitability of the whole subplate in both hemispheres at the same time. In premature neonates, burst synchronization is observed on the EEG from 23 wGA onwards. Therefore, it is unlikely to be solely based on synchronized thalamocortical afferents or synchronized, bilateral thalamic inputs to the subplate. Furthermore, interhemispheric connections (notably via the callosal fibres) [88] are still very immature and do not myelinate until late in the third trimester [19,40,82,83]. The callosal fibres inhibit the occurrence of some of the endogenous generators [72].

In very premature neonates, interhemispheric synchrony is therefore unlikely to be solely dependent on callosal connections [110]. Asynchronous activity ("tracé alternant") has been described in full-term neonates with corpus callosum agenesis but is not pathognomonic [51], suggesting that interactions through the corpus callosum are involved in the interhemispheric synchronization of the "up" and "down" states in full-term neonates [111]. Alternatively, it has been suggested that burst onset is due to coupling between cortical, corticothalamic and neurovegetative brain structures (mediated by Mayer-Traub-Hering haemodynamic waves at 0.1 Hz) [152,193]. The burst onset might

be associated with high-frequency interhemispheric interactions from frontal to posterior regions [111]. Lastly, the interhemispheric synchronization of the burst onset might well be based on non-synaptic events, such as changes in pH or the Ca^{2+} concentration or the presence of chemical compounds that interfere with the activity of connexin (known to modulate the length of time that subplate neurons spend in the “up” state [122]). In line, the durations of the bursts and IBIs are modulated in certain pathological situations (such as intraventricular haemorrhage and anaesthetic overdoses), although intra- and interhemispheric synchronization is maintained [149]. Furthermore, cerebral blood flow and cerebral blood volume are modified concomitantly with bursts of activity, and these changes might precede the burst onset [130,131,149]. As well as highlighting early neurovascular coupling, these haemodynamic changes also synchronously modify oxygen availability in the whole brain just before the burst onset [130,131,149]; this might trigger the burst. There are pathological situations in which cortical bursts can be observed at various ages. These features should be considered with caution; as mentioned above, the premature neonate’s discontinuous activity comprises quiescent periods rather than suppressive ones. Nevertheless, in extreme pathological situations (such as anoxia, with increased lactate concentration) and metabolic disorders (i.e. nonketotic hyperglycinaemia) the EEG activities might be paroxysmic or considered as suppression bursts [42]. In such a case, they are always synchronous over both hemispheres. These synchronizations probably reflect systemic changes in the overall nervous system input, rather than physiological neuronal interactions at the network level.

[FIGURE 10]

At term, the interhemispheric synchrony consists of coincidental bursts during spontaneous “tracé alternant” background EEG activity [69,98]. These bursts constitute an important feature in the normal neonatal brain [69]. The transient asynchrony in the burst occurrence between 32 and 34 wGA might reflect complex, competitive interactions between non-synaptic mechanisms and the progressive impact of the developing callosal fibres [85]. Therefore, the interhemispheric synchronies observed before 32 wGA and after 35 wGA might have different underlying mechanisms. One major feature of the burst is that its different components (generators) are not synchronously recorded over the two hemispheres. This lability within the burst and between the hemispheres is considered to have prognostic value [4].

Various approaches have been used to automatically detect the burst in very preterm or extremely preterm neonates. These approaches are mainly based on filtering, envelope extraction, adaptive thresholding, or non-linear energy operators (the latter having been validated for premature neonates before 30 wGA) [22,56,126,129,137,139,140]. An activation synchrony index has also been

developed for studies of term neonates. It seems to be stable enough to constitute an objective guide to EEG normality at 36-42 wGA, and has diagnostic value at the individual level [82]. These approaches are intended to lead to automatic tools that can classify the EEG as normal or abnormal (for clinical purposes), objectively extract the time and spectral content of bursts of activity, or assess connectivity.

Spontaneous activity transients (SATs)

Another way to assess the EEG activities is to consider the recording made in direct current mode (full-band EEG) rather than in alternating current mode [180]. Direct current amplifiers are not commonly used in clinical settings but the absence of a built-in high-pass hardware filter enables ultraslow brain waves to be recorded. These ultraslow, high-amplitude SATs (200-700 μ V, lasting 1 to 5 sec) were first described in the “tracé alternant” of near-term premature neonates [179] and were then described in more detail in premature neonates at 32 wGA [178] (Figure 11). The ultraslow wave subtending the SAT corresponds to the burst’s direct current envelope.

[FIGURE 11]

The SATs are not oscillatory [176] in that they do not occur in series. They have been characterized as the coincidence of infraslow (<0.5 Hz) activity containing 1 to 5 repetitions of nested, low-frequency waves (0.7-1.5 Hz). In turn, these waves contain another set of nested waves at several higher frequency bands [169,178], which might include TTA-SW and delta brushes [4,153,176,181]. Therefore, SATs have been considered as slow “carrier waves” for burst activities. During maturation, the SATs arise independently within each area of the cortex and then tend to synchronize loosely at around 30 wGA. More precisely, consistent temporal synchrony of SATs starts at about 35 wGA, at the same time as the establishment of callosal connections between the cortical plate and the onset of long-distance connectivity [169,176]. The SATs can be generated by the cortex alone [2] or in response to input from the underlying subplate [41]. The SATs’ frequency of occurrence and amplitude decline until term. The age-related decrease in the amplitude of the SAT’s slow component might be related to gyrification, which modifies the orientation of the electromagnetic dipoles [176]. Lastly, SATs disappear when functional GABAergic inhibition arises [178]. The SAT’s, as the bursts, are built from a mixture of activities arising from different generators and network interactions. On the one hand, their presence and their modulation might be related to the “generator-based dynamics”. On the other hand, the age-related modulation of their frequency and amplitude might be considered to be related to the “network-based dynamics”.

Generator-based dynamics

The bursts of activity are composed of waves of different frequencies. They generate endogenous activity that modulates the formation of functional units [25]. The formation of fetal neural networks involved in the integration of sensory information is a key element in neuronal development and depends on intimate interactions between genetically determined guidance and the activity-dependent refinement of synaptic connections [135,172]. Spontaneous correlated activity is a ubiquitous feature of the developing nervous system, and is thought to provide a robust source of depolarization prior to the maturation of neural circuits [50] and for the development of the cortical columnar architecture [41]. Within a brief developmental period during the last trimester of pregnancy, the cortical network switches progressively from a subplate-driven, gap-junction-coupled syncytium to a synaptic network generating synchronized oscillatory activity.

Endogenous generators

Different types of endogenous generator emerge transiently as the brain develops between 24 and 42 wGA. These include frontal activities, theta activities that coalesce with a slow wave (TA-SW), delta brushes, frontal transient activities, and slow anterior dysrhythmia [4,17](Figure 12). TA-SW and delta brushes have different generators, functions and spatial locations, and must be considered separately.

[FIGURE 12]

Coalescence between generators: nested activity

The notion of coalescence (from the Latin *coalescere*, meaning “to unite and grow with”) refers to the simultaneous occurrence of two generators, without considering a strict temporal relationship between them. By definition, nested oscillatory activities represent a specific type of coalescence in which oscillatory activities with different timescales are coupled together with a strict phase relationship (Figure 13). These consist of slow waves within which rapid activity of various higher frequencies is nested: theta band activity for TA-SW, and alpha-beta band activity for delta brushes. The strength of this relationship is measured using phase-amplitude coupling (PAC) indices [115]. In adults, it corresponds to precise temporal relationships between modulating and modulated frequencies in (for instance) the thalamocortical and hippocampal networks during sleep [163]. In general, the mechanisms underlying PAC lead to specific temporal coupling patterns across several

frequencies at both local and remote sites [65,71]. These patterns can be modulated by structural changes [66,151]. Fine-tuning of this coupling between generators might be important for optimizing the generators' functional status; hence, any disturbance in this fine-tuning is likely to interact with the function and structure of the immature network. Phase coupling between generators was recently characterized in temporal areas (yielding TTA-SW) [115]. This type of interaction has also been observed (albeit to a lesser extent and during a shorter period of development) in more frontocentral and parieto-occipital areas.

[FIGURE 13]

The coalescence between theta activities and slow waves

The TA-SW over temporal structures has previously been described as temporal sharp transient [99], temporal sawtooth [190], or a temporal theta burst [170]. These (normal) activities are not the same as the (abnormal) repetitive sharp waves seen in the theta range [45]. Recently, coalescence between theta activity and slow-wave activity in the temporal areas has been identified as TTA-SW [115,150]. Coalescence between theta activity and a slow wave has also been recorded in frontocentral and occipital areas (referred to hereafter as FTA-SW and OTA-SW, respectively, see Figure 14). Given that TTA-SW has been studied most intensively, we shall focus on it here. However, it must be borne in mind that TTA-SW, FTA-SW and OTA-SW are similar patterns of nested activity over different cortical sensory areas, albeit with slight differences in the frequency content of the slow and rapid nested activities.

[FIGURE 14]

Time of occurrence

These generators are present from 24 wGA onwards [150], i.e. at a time when thalamic afferents still project into the subplate and before they are relocated in the cortical plate and establish the first thalamocortical connections (around 26-28 wGA) [88].

Characteristics and phase coupling

The PAC occurs between the slow-wave generator and the theta activities [115], suggesting that time and phase dependencies are important for these two generators. TTA-SW arises with an irregular, negative, slow deflection that has been termed a "blup", followed by theta activity nested in the first slope of the first half-wave of an SW [115].

Location

The coalesced activities appear under temporal electrodes. Source localization suggests that they may be related to the activation of local neural networks in the temporal planum regions [150]. The activities' emergence at the scalp surface during development in the premature neonate suggests that they reflect interactions between subplate neurons, thalamic afferents, and pyramidal cells migrating towards their final destinations within the cortical plate [150]. These interactions might be involved in neuronal guidance, synaptogenesis, and the functional development of migrating cortical cells. Surface EEG recording detects these complex interactions between the subplate and the cortical plate. The high amplitude of both slow waves and theta activities is suggestive of the synchronization of a relatively large population of neurons within a smaller number of cortical columns because TTA-SW is recorded over very few electrodes in HR EEGs (Figure 15 and 16). Source localization of the two generators suggests that they are close together [150].

[FIGURE 15]

The mechanisms and their functional roles

The mechanisms underlying the development of these generators in the newborn are still poorly understood. Studies of TTA-SW in the newborn animal (see below) are not very informative; in the newborn rat (corresponding functionally to a premature neonate of about 28 wGA), for example, thalamic afferents are already likely to interact with the endogenous generators. The TTA-SW is initially independent of exogenous auditory inputs (at least up to 28 wGA [115,150]), which makes the hypothesis of a cortical spontaneous generator in the subplate more likely. Moreover, TTA-SW activities are recorded spontaneously and can occur asynchronously in the right and left temporal regions. The persistence of TTA-SW interhemispheric asynchrony during binaural auditory stimulation is suggestive of systemic or generalized modification of the excitability threshold (due to interactions between the sub-plate and the cortical plate) rather than exogenous auditory sensory inputs processed in the subplate through thalamic afferents (whose endings are still localized in the subplate in most cases). Given that the auditory nerves cross in the brainstem, it is hard to understand why they do not generate a bilateral response. Alternatively, and as described in animals (see the section below), independent, spontaneous, endogenous cochlear or visual waves on each side might propagate to the sensory cortices through their subcortical or brainstem links [172]. Spontaneous endogenous waves traveling all along the afferent network might be involved in the elaboration of sensory functions from the sense organ to the cortex. It is also noteworthy that the

frequency of occurrence and the amplitude of TTA-SW tend to decrease when thalamic afferents start to relocate to the cortical plate at around 28 wGA.

The PAC between the slow-wave and the theta activities is fixed, suggesting that the two oscillators are part of a well-oiled horology. Specifically, the theta power is significantly higher during the slow wave's descending slope and around its trough (over Fp2-T4) (Figure 13). The preferred phase of this TTA-SW modulation clusters during the slow wave's descending slope, indicating that the theta event is consistently timed during the slow wave's cycle. More generally, it has been suggested that oscillator coupling enhances combinatorial opportunities for storing complex temporal patterns and facilitates synaptic plasticity [13,20]. In the hypothetical mechanism, the phase of the slower oscillation reflects greater excitability among postsynaptic neurons; in turn, this synchronizes the synaptic input and increases the amplitude of the faster oscillations [13]. The coupling between the phase of the slow oscillation and the amplitude of the theta oscillations in this early neural biomarker suggests that dynamic networks develop in very premature neonates [115].

Functional connectivity studies

Functional connectivity studies of the TTA-SW have revealed functional connections with ipsilateral frontal and parieto-occipital structures [1] (see below for connectivity studies in preterm neonates).

Delta brushes in neonates (Figure 16 and 18)

Delta brushes have variously been described as “spindle-delta bursts”, “brushes” [100,188], “rapid bursts” [34], “spindle-like fast rhythms” [187] and even “ripples of prematurity” [45]. Like the TTA-SW, the delta brushes consist of a slow wave within which faster activities are nested.

[Figure 16]

Time of occurrence

The delta brushes appear when the thalamic afferents relocate to the cortical plate (28 – 40 wGA), thus establishing the first functional cortical connections able to mediate sensory information. In the temporal regions, this feature of the thalamic connections is evidenced by evoked potentials with much the same characteristics as those described in the adult (albeit with clearly different amplitudes and latencies) [106]. Thus, during this period of development, auditory stimulation with phonemes (“ba ba ba”) induces synchronization (evoked potentials) and habituation to the repetition

of the syllables, just as a mismatch response is observed in response to the presentation of deviant phonemes (“ba ba ga”) or a deviant voice (male vs. female). This observation demonstrates this early network’s ability to discriminate between voices and between phonemes as soon as thalamocortical connections have been established (i.e. before learning can refine the networks’ complexity) and indicates that innate mechanisms are involved [105,106]. This coding of the physical information in auditory stimuli involves structures similar to those solicited in the adult, suggesting the early functional prewiring of the neural networks with a hemispheric dominance or a tendency towards specific lateralization according to the type of deviation (left for phonemes and right for voices and slow rate modulation) [28,105].

[Figure 17]

The delta brushes occur in a functional context of early interaction between sensory afferents and the establishment of the definitive cortical plate, which nevertheless maintains a strong relationship with the subplate. The delta brushes emerge while TTA-SW decreases in frequency of occurrence and amplitude.

Characteristics and phase coupling (Figure 16 and 18)

Like the TTA-SW and the theta band, delta brushes correspond to the coalescence of a slow wave with fast rhythms (in the alpha and beta bands, in this case (see Figure 18). However, delta brushes differ with regard to the temporal characteristics, frequency, spatial signature, slow-wave pattern and the phase coupling between the slow-wave and the fast activity. In contrast to the fixed coupling of the TTA-SW, the alpha-beta activities in the delta brushes are likely to be more widely distributed in the rising slope or in the peak of the ascending slow wave between 28 and 34 wGA; they then cover the whole of the negative deflection until term, when they disappear [170,186].

Location

Initially, the delta brushes’ spatial representation in HR EEG appears to be localized (Figure 18). Towards 28 wGA, delta brush activity is more parieto-occipital than the TTA-SW (Figure 16 and 19) that sometimes appears during the same period [4]. This observation suggests that the respective generators have different spatial distributions. Later (soon after 28 wGA), delta brushes can be recorded over most of the scalp (Figure 16). Ultimately, the TTA-SW appears alone [115,150], whereas delta brushes can consist of an oscillatory pattern of delta activities within which alpha/beta

oscillations are nested (Figure 19). Therefore, the slow wave in the TTA-SW is not strictly oscillatory. These considerations highlight the differences between TTA-SW and delta brushes: the TTA-SW is a unique: neonate-specific feature that has not been described in animal studies [102].

[Figure 18]

[Figure 19]

Mechanism and functional role

The delta brush pattern changes over time. The brushes are initially relatively smooth with a high amplitude. The amplitude then decreases gradually as the subplate disappears - suggesting that delta brushes are linked to complex interactions between the subplate and the cortical plate, which shrinks during development (see the animal section). In some cases, the fast alpha-beta band activities at around 28 wGA can be located in the rising part of the slow wave of the spontaneous delta brushes, which evidences successive interactions between generators (Figure 12). The complexity of the mechanisms involved requires detailed characterization of the duration, frequency, and coupling between generators whose functional impacts are potentially very different. These time, frequency, and coupling variables might vary when the cortical circuitry's function and structure are impaired.

According to some studies with visual or automatic feature detection, the probability of occurrence of the delta brushes between 33 and 40 wGA increases two-fold over a time interval of 2 seconds in response to somesthetic, auditory or visual stimulation; this change is suggestive of facilitation by sensory stimuli [23,25,75]. The lability in the delay of onset following sensory stimulation suggests the presence of complex interactions between thalamic inputs and cortical networks that might involve the subplate. The delta brushes' probability of occurrence decreases with development [23,75]; the delta brushes might thus have a transient functionality. This complex interaction disappears as the subplate disappears and/or the peripheral sensory inputs become more intense. The delta brushes' functional role has been mainly studied in animals (see the section below on newborn animals).

Delta brushes in newborn animals

In vivo and *in vitro* studies have revealed that synchronized neuronal activities in the immature cerebral cortex (such as spindle shape oscillations) in newborn rats are a self-organized patterns generated by intrinsic mechanisms driven or modulated by various different simultaneous or successive factors [78]: (i) peripheral exogenous inputs [25,61,81,195]; (ii) spontaneous activity in the

sense organ, (iii) spontaneous thalamic activity directed to the subplate and mediated by calcium waves [123], (iv) spontaneous generation by intracortical circuits [61,78,112,165], and (v) activation by different metabotropic receptors (for a review, see [26,78]. These complex interactions suggest that in functional terms, the immature network progressively switches from a subplate-driven, gap-junction-coupled syncytium to a cortical synaptic network [41].

Studies in newborn animals (the rat, mainly) have evidenced described electrographic patterns similar to those recorded in preterm neonates at between 29 and 31 wGA [25,75,79,114,194]. A large body of evidence indicates that the delta spindles or spindle bursts observed in animals correspond to the delta brushes described in the human neonate (the spindle/brush frequency; coalescence with a slow wave; spontaneous and sensory-driven aspects; and the spatial distribution) even though the slow wave's amplitude is lower than what is observed in animals [25]. Unlike premature neonates, however, rats show spindles with a broader frequency signature (ranging from the alpha band to the beta band) [25]. In animals, multi-unit activity recording [195] has identified three specific patterns: (i) Spontaneous and periphery-driven 10 Hz spindle bursts lasting 1–2s and occurring approximately every 10 s; (ii) spontaneous and sensory-driven 30–40 Hz gamma oscillations lasting 150–300 ms and occurring every 10–30 s. (iii) high-amplitude (250–750 mV) lasting up to 40 s and occurring every 20 min or so. The spindle bursts and gamma oscillations are spatially confined and synchronize spontaneous activities in either a wide or restricted column-like neocortical network, whereas the long oscillations synchronize larger ensembles. Hence, these activity patterns synchronize the local developing networks and may propagate over large regions, including neocortical areas [78]. GABAergic and glutamatergic signaling underlies cortical spindle bursts [79,113,195]. Multi-unit activity recordings indicate a source deep in the neocortex and a sink in the subplate, as has been described for slow waves within which the delta spindles are nested [79,195]).

The delta brushes' probability of occurrence increases in response to various somatosensory, visual or auditory stimuli (for a review, see [81]). In view of the spontaneous endogenous activity at the sense organ (i.e. the visual system), these oscillations are strongly correlated with the retinal waves, the blockade of which halves the frequency of the spindle burst [61] in much the same way as peripheral deafferentation [195]. Hence, even though sensory input is not the only trigger for these activity patterns, it substantially drives and modulates neocortical activity [81]. This was confirmed by a very elegant study by Murata and Colonnese [125]. By simultaneously recording the visual cortex (VC) and lateral geniculate nucleus (LGN), silencing the retina, the LGN or the VC, or optogenetically stimulating the VC, the researchers found that (i) 80% of the spindle burst oscillations recorded in the VC require the thalamus and the retina, (ii) the transmission of retinal waves requires

corticothalamic feedback, (iii) the VC's role in this feedback loop is initially limited to amplification but then develops to amplification and transformation of the retinal input into LGN, (iv) the role of corticothalamic feedback is limited to the period of the retinal waves and, lastly, (v) this feedback excitation specifically amplifies the spindle bursts' oscillations. Similarly, in the auditory cortex, spontaneous activities from the cochlea are transmitted through the auditory nerves to the colliculus before the onset of hearing [172]. Furthermore, [10] the silencing of cochlear information during *in vivo* imaging of changes in neuronal calcium levels in newborn mice before hearing onset demonstrated that (i) the spontaneous activity in the inferior colliculus originates in the cochlea, and (ii) the spontaneous activity originating in the cochlea propagates to the auditory cortex. As in the study in rats [125], they suggest a role of amplification of the sensory information's from the thalamus to the cortex at this period of development. However, in contrast to Murata and Colonnese's results, the activity of the inferior colliculus in this pre-hearing model is not greatly modulated by descending projections from the auditory cortex - although the studies differed with regard to the developmental age, the recording system, and the animal model. Taken as a whole, these data suggest that sensory input processing is coordinated throughout the entire neural system.

Furthermore, spindle bursts become more frequent after callosotomy [107], suggesting that the corpus callosum fibers convey inhibitory interhemispheric information to the spindle burst generators. Likewise, similar oscillations are recorded in reduced-brain preparations *in vitro*, which indicates that isolated neocortical neuronal networks are capable of generating spindle bursts [81,195]. The subplate, gap junctional coupling, and NMDA receptors might also be involved in the genesis of these oscillations [196]. In the earliest stages of development, the subplate's role is complex (for a review, see [26]). The presence of the subplate is required for generation of the spindle bursts [168]. The subplate might amplify the transmission of thalamic oscillations towards the cortex in early development [62] and might be involved in the thalamocortical loop later in development [26]. The thalamus and subplate appear to be active areas that transform the incoming sensory signal into network oscillations within the cortex [81].

The TTA-SW that appears at 24 wGA in premature neonates has not been described in animals; this would probably require early recording in the rat (before P0, the equivalent of 27-28 wGA in humans). Regardless of the age, however, surface EEGs in the premature neonate reflect the complex interactions between the thalamus, the subplate and cortical plate as part of a developing, dynamic network.

Frontal sharp transients (Figure 20)

Time of occurrence

These activities (first described by Monod as “encoches frontales” [118] are observed around term. They are more frequent in active sleep (AS) [148] and at the transition from AS than in quiet sleep (QS). These transients are usually bilateral and synchronous, although asynchrony should not necessarily be considered as abnormal [27]. The features disappear at around 43-44 wGA [4,17].

[Figure 20]

Characteristics

The frontal sharp transient corresponds to a biphasic or triphasic wave that varies between 36 and 41 wGA - attesting to changes in the underlying mechanisms. Although these transients have not been extensively studied, they are empirically considered to be of high predictive value because they are generally absent in extremely abnormal EEGs [6,118]. There is no evidence of sensitivity to exogenous stimulation. Unlike TTA-SW and delta brushes, coalescence with a rapid activity is not apparent but still needs to be investigated.

Location

Source localization is difficult because the frontal sharp transients can occur simultaneously in both hemispheres. Localization performed on a few isolated, unilateral, frontal sharp transients returned a dipole located in a retro-ocular position within the frontal lobe [148].

Mechanism and functional role

One might consider that frontal sharp transients can be generated in the well-laminated retina (which builds up well-orientated electromagnetic fields), rather than in the cortex. The frontal transients first appear as the time when the photoreceptors mature. The concomitance of the frontal sharp transients and the underlying retinal process might be of relevance.

The impact of sleep stages on spontaneous activity in premature neonates

The vigilance states AS and QS develop progressively from 28 wGA onwards ([29]; see Bourel-Ponchel et al [17,18] for a detailed description of sleep stages in premature and full-term neonates) and affect

the duration and frequency content of bursts and IBIs and the probability of occurrence of specific generators within bursts, such as frontal sharp transients [27], TTA-SW, and delta brushes [4]. The TTA-SW and delta brushes persist longer in QS than in AS [4,93], which suggests interactions between the subcortical networks involved in sleep and the mechanisms that increase the probability of occurrence of certain specific generators. The vigilance states also modify the discontinuity that persists during AS up to 32 wGA and which will persist during QS until the end of pregnancy as a “tracé alternant” [4,17]. Furthermore, some abnormalities (such as positive Rolandic spikes and excessive discontinuities) are more pronounced and more easily identifiable in QS than in AS. This modulation of brain activity by the vigilance state suggests that the subcortical neural networks can significantly influence and interact with the thalamocortical networks, as evidenced by analysis of the surface EEG. It is therefore important to (i) record the brain activity of premature neonates in the different vigilance states, and (ii) identify and accurately characterize the discontinuity, temporal characteristics, and content of bursts of physiological and pathological spontaneous activities.

Many sensitive, specific algorithms for the automatic detection of vigilance stages in term and preterm neonates have been developed [5,29,56,94,142,174].

Connectivity analyses

The connectivity analyses performed during different periods of development have highlighted functional alterations in interactions within complex networks. In premature neonates, structural alterations (e.g. the size, complexity and structure of grey and white matter) might therefore have a functional counterpart in terms of connectivity [11]. Nevertheless, functional connectivity in premature and full-term neonates must be interpreted with caution. The analytical methodology must be appropriate for the neonate’s level of immaturity and specific features, for several reasons. Firstly, the premature neonate’s neuronal networks are driven by spontaneous endogenous generators that are not synchronously located in both hemispheres – in contrast from the network-based activity observed in adults. Secondly, the activity is strongly driven by thalamic afferents that relay either spontaneous generators located in the sense organ and/or sensory afferents when the organs are stimulated (notably outside the womb). Thirdly, the characteristics of the EEG at this early stage of development are mainly related to its discontinuity, which is synchronous on both hemisphere (except at around 34 wGA) and thus differs from the continuous neuronal activity recorded in adults. Fourthly, immature intrinsic activity is generated in thalamocortical circuits. Fifthly, neurovascular coupling is present but immature [105,131,149]. The immature haemodynamic response to the burst of activity is complex and differs from one premature neonate to another. The

response is combined with a positive or negative canonical blood-oxygen-level-dependent response (i.e. an increase or decrease in cerebral blood flow alone or an increase or decrease in cerebral blood volume alone). Both types of response can be observed in a given premature neonate [131], which makes connectivity analyses (based on the blood-oxygen-level-dependent response) difficult to interpret. In general, functional connectivity analyses in premature neonates should (i) take account of these specific brain activity features in early stages of development and (ii) use measurement technique with a high time resolution (e.g. HR EEG, rather than rely on neurovascular dynamic studies). Therefore, thalamocortical “resting state” activity (as described in adult) is probably absent or barely present in preterm neonates [24]. In premature neonates, “resting state” cortical activity (or, more appropriately, cortical activity at rest) is driven by the establishment of networks and results from interactions between the subplate, the cortical plate and thalamic afferents that might be influenced by direct input from the sense organs. This departs from the notion of the “resting state” as described in the adult, where the thalamocortical loops correspond to networks involved in internal tasks or cognitive functions [15].

Although the spatial topology of brain function is very complex, it is generally believed that brain networks evolve from a local architecture in neonates (dominated by frontal, temporal and parietal regions) to a more diffuse topology in adults [31,49,157,162]. The results of functional connectivity analysis in term neonates (measuring either frequency-specific amplitude correlations or phase synchronization) strongly suggest that the functional organization of brain networks in term neonates is dominated by the short-range connections and is highly centralized: shorter central pathways are combined with more peripheral nodes in the frontal, temporal and posterior regions [1,136,171]. Hence, as the brain matures, communication between more distant brain regions become progressively functional. The neuronal system appears to evolve from a more random network into a more ordered, “small-world” network [14,136,157,167,171], in line with the relative immaturity of direct anatomical connections between remote cortical sites at this age [38]. The various studies also suggest that this functional connectivity is frequency-specific organization [136,167,171]. A “small-world” network has an optimal balance between separate and closely spaced brain areas or, in other terms, between segregation (clustering) and integration (path length) [162].

Interestingly, Omidvarina et al.’s study of functional connectivity in premature neonates [136] evidenced a “high mode” (bursts of activity) and a “low mode” (quiescence) described in premature neonates. The researchers also found that the interhemispheric amplitude relationship was significantly stronger in each pair of signals during the high mode; they suggested that long-range connectivity is preferentially established during brief periods of endogenous network activity (i.e. with burst), even though a simultaneous increase in both hemispheres might be related to other

mechanisms (see the section on bursts). Lastly, functional connectivity was more ordered in high mode (similarly to the “small-world” network) than in “low mode” [136].

Connectivity of the TTA-SW

In premature neonates at 31 wGA, the influence of TTA-SW on the spatial organization of the early preterm network has been evaluated using 64-channel electroencephalography (Figure 21) by measuring the power envelope correlation of orthogonalized signals [1]. TTA-SW in the left temporal region induced an increase in functional connectivity with left frontal areas and left parietal areas, while TTA-SW in the right temporal region was associated with an increase in functional connectivity in that region only. The observation of long-range functional connectivity between the left frontal and left parietal areas suggests that they (along with the temporal region) form a basis for coherent neuronal activation across distant cortical regions. It also suggests that these frontal and parietal areas have a special functional relationship with the perisylvian regions. The regions of interest and the connectivity supports the hypothesis in which endogenous generators are involved in auditory tonotopia and/or the elaboration of the perisylvian networks’ functions - especially those related to auditory function, language, and communication in a broad sense [1]. Interestingly, similar patterns of coalescence between a slow wave and theta activity are observed over other sensory areas (CTA-SW in central areas, and OTA-SW in parieto-occipital areas). Hence, coalescence between TA and SW might be a general mechanism for sensory processing in a developing network.

In view of (i) similar generator patterns for coalescences over different sensory areas (namely the temporal, central and parieto-occipital areas) and (ii) the modulation of connectivity with frontal and parieto-occipital areas by TTA-SW [1], one can hypothesize that such coalescent generators are involved in a “proto-resting state network” (regard to the caution required when considering a notional resting state network in premature neonates). Consciousness can be defined simply as awareness of one’s body, oneself, and the outside world [138]. Neonates have various modules of consciousness that arise from visual, auditory, sensorimotor and proprioceptive sensing [138]. The modules gradually unify during development to form a single consciousness [70]. It remains to be determined whether TA-SW generators in different sensory areas are involved in this very initial creation of bodily awareness and thus consciousness.

[Figure 21]

A connectivity approach might be of value for monitoring brain dysfunctions in which abnormal connectivity has been described (i.e. autism)[30]. Analyses of connectivity (i.e. amplitude-amplitude coherence and phase-phase coherence between two areas) have highlighted dysconnectivity of the frontal cortical network in premature neonates tested at term-equivalent age, relative to term neonates [167]. This confirmed the results of a functional MRI study that reported altered connectivity in the preterm brain tested at term-equivalent age [11,158] and MRI studies describing significant alterations in the size, complexity and structure of white and grey matter in preterm neonates relative to term counterparts [16,36,76,96]. This dysconnectivity might constitute the structural and functional basis of the neurodevelopmental disorders subsequently observed in premature neonates [185].

Aspects of magnetoencephalography in fetuses

Fetal MEG provides an opportunity to record the fetus's brain activity in his natural *in utero* environment; this mitigates the effect of premature birth and the environment (i.e. the neonatal intensive care unit) on the developing neuronal networks. Furthermore, magnetoencephalography and electroencephalography are complementary because they record different aspects of the electromagnetic field.

Magnetoencephalography has notably been used to investigate spontaneous brain activity in fetuses of between 27 and 39 wGA [175]. The characteristic EEG features described in the premature neonates (such as delta brushes, transient bursts and "tracé alternant") were also recorded *in utero* [47] (Figure 22). It should be noted that as in standard EEG of premature neonates, in MEG, the occurrence of discontinuity and delta brushes decreases by 35 wGA - suggesting that the fetal brain matures in much the same way as in the premature newborn. Furthermore, prenatal auditory evoked potentials [33] and visual evoked potentials [48] have been recorded in functional magnetoencephalography studies; indeed, discriminative responses to auditory stimulation in fetuses have been reported as early as 30 wGA [32,155], which corresponds to what is seen with HR electroencephalography in premature neonates at 28 wGA [105,106]. Alterations in functional evoked magnetoencephalography responses have been reported for certain abnormal fetal or maternal situations; for example, visual evoked potentials are perturbed in cases of intrauterine growth restriction [124], and auditory evoked potentials are impaired in gestational diabetes [96]. Furthermore, intrauterine growth restriction is associated with cognitive alterations at the age of two [63]. Furthermore, there is initial evidence to suggest that maternal drug supplementation directly affects spontaneous brain activity in the fetus [46].

Functions of immature networks

The presence of spontaneous oscillatory activities - whether modulated or not by endogenous activities originating from the sense organ (i.e. retinal waves or cochlear waves) or by exogenous somatosensory, auditory or visual sensory stimulation - in many species suggests that this oscillation has a role in the maturation of neural networks. A neural network's connectivity results from genetic factors, spontaneous electrical activities, and (when the system is afferented) evoked responses and network interactions. Spontaneous TTA-SW before 28 wGA provides electrical input to the functional and structural wiring of the immature network in the auditory cortex [1,115,148,150]. With regard to the functional network that develops (at least in part) from the endogenous TTA-SW (rather than sensory driven TTA-SW) from 28 wGA, the encoding of auditory stimuli might be subtended by a variety of potentially complementary processes. One response resembles the classical evoked adult response (occurring within 400 ms of the stimulus), and the other corresponds to the modulation of endogenous activity. The first response includes synchronization, habituation and mismatch [105,106]. The second response is likely to be induced, and consists (according to Colonnese *et al.*) of gamma burst/delta brush activity with longer, variable latency (more than 400 msec) [25]. The evoked response is likely to develop into the adult response, whereas the induced response starts to disappear progressively around term. This suggests that the two parallel procedures might have different functional targets (spontaneous TTA-SW, induced delta brushes, and evoked responses) with different time courses.

These spontaneous activities participate in the basic mechanisms that develop within the neocortical network. The developing neuronal networks are fine-tuned by neurogenesis, cell death, cell migration, neuronal differentiation, and the development of functional synaptic pathways (i.e. the refinement and maintenance of visual and tonotopic maps, somatotopic organization, and barrel formation) [113,173]. In the sensory neocortex, for example, spontaneous correlated activity generated before the onset of sensory inputs may be essential for the functional development that prepares the areas to process incoming information [53,108,189]. Furthermore, fine-tuning and time-domain relationships between the different generators (i.e. the coalescence between theta activity and slow waves or between spindles and slow waves) might help to optimize the functional complexity of this immature network. It is known that early sensory deprivation and subplate removal have dramatic effects on the structural and functional development of the corresponding cortical networks [168]. Impaired fine-tuning of the various mechanisms at different steps in

neuronal development is likely to be responsible for neurodevelopmental disorders that are revealed when the sensorimotor and learning abilities start to develop [185].

Conclusion

Appropriate neural dynamics are essential in situations with significant neurodevelopmental risk, such as prematurity. The various elements required for normal development of the brain attest to the establishment of a large number of cortical and subcortical networks involving the thalamic afferents, the subplate, and the cortical plate. With advanced signal processing techniques, it is now possible to characterize the endogenous generators that give rise to functional neural networks and help the latter to develop. Although much research on the significance of each of these parameters is required, this type of knowledge is important for improving the management of premature neonates. Nevertheless, the results of animal studies have highlighted the importance of the correct establishment of neural networks in the early stage of development. The spontaneous generators (some of which are sensitive to peripheral stimulations) are involved in the establishment of somatotopic, tonotopic and retinotopic maps. One can reasonably hypothesize that disturbance of these early interactions causes significant dysfunction in the corresponding sensorimotor and cognitive modalities. In turn, this dysfunction might contribute to the onset of well-known, frequent neurodevelopmental disorders in the premature neonate [185].

Acknowledgments

The authors are grateful to the Amiens university hospital EEG technicians for data acquisition.

This work has been supported by Agence Nationale de la Recherche (ANR 2015 CE MAIA), Cognitive Sciences and Technology Council (COGC) Iran (Neurobiom), Eiffel Excellence scholarship (P729740-H) and French-Iranian Project Hubert Curien Jundishapur (40616RJ).

Conflict of interest

The authors disclose no conflict of interest related to this work.

References

- [1] Adebimpe A, Routier L, Wallois F. Preterm Modulation of Connectivity by Endogenous Generators: The Theta Temporal Activities in Coalescence with Slow Waves. *Brain Topogr* 2019;32: 762–72.
- [2] Adelsberger H, Garaschuk O, Konnerth A. Cortical calcium waves in resting newborn mice. *Nat Neurosci* 2005;8: 988–90.
- [3] Adibpour P, Dubois J, Dehaene-Lambertz G. How do electrophysiological measures in infants relate to the brain structural maturation? *Neurophysiologie Clinique/Clinical Neurophysiology* 2017;47: 186.
- [4] André M, Lamblin M-D, d’Allest AM, Curzi-Dascalova L, Moussalli-Salefranque F, S Nguyen The T, et al. Electroencephalography in premature and full-term infants. Developmental features and glossary. *Neurophysiol Clin* 2010;40: 59–124.
- [5] Ansari AH, Cherian PJ, Caicedo Dorado A, Jansen K, Dereymaeker A, De Wispelaere L, et al. Weighted Performance Metrics for Automatic Neonatal Seizure Detection Using Multiscored EEG Data. *IEEE J Biomed Health Inform* 2018;22: 1114–23.
- [6] Arfel G, Leonardon N, Moussalli F. [Density and dynamic of frontal sharp waves (encoques pointues frontales) during sleep in new-borns and infants (author’s transl)]. *Rev Electroencephalogr Neurophysiol Clin* 1977;7: 351–60.
- [7] Azizollahi H, Aarabi A, Wallois F. Effects of uncertainty in head tissue conductivity and complexity on EEG forward modeling in neonates. *Hum Brain Mapp* 2016;37: 3604–22.
- [8] Azizollahi H, Aarabi A, Wallois F. Effect of structural complexities in head modelling on the accuracy of EEG source localization in neonates. *Journal of Neural Engineering* 2020 In press;
- [9] Azizollahi H, Aarabi A, Wallois F. Effect of head modelling errors on the accuracy of EEG source localization in preterm newborns. *Brain Topography* In press.
- [10] Babola TA, Li S, Gribizis A, Lee BJ, Issa JB, Wang HC, et al. Homeostatic Control of Spontaneous Activity in the Developing Auditory System. *Neuron* 2018;99: 511-24.

- [11] Ball G, Aljabar P, Arichi T, Tusor N, Cox D, Merchant N, et al. Machine-learning to characterise neonatal functional connectivity in the preterm brain. *Neuroimage* 2016;124: 267–75.
- [12] Ben-Ari Y, Gaiarsa J-L, Tyzio R, Khazipov R. GABA: a pioneer transmitter that excites immature neurons and generates primitive oscillations. *Physiol Rev* 2007;87: 1215–84.
- [13] Bergmann TO, Born J. Phase-Amplitude Coupling: A General Mechanism for Memory Processing and Synaptic Plasticity? *Neuron* 2018;97: 10–3.
- [14] Betzel RF, Byrge L, He Y, Goñi J, Zuo X-N, Sporns O. Changes in structural and functional connectivity among resting-state networks across the human lifespan. 2014;102: 345-57.
- [15] Biswal B, Yetkin FZ, Haughton VM, Hyde JS. Functional connectivity in the motor cortex of resting human brain using echo-planar MRI. *Magn Reson Med* 1995;34: 537–41.
- [16] Boardman JP, Counsell SJ, Rueckert D, Kapellou O, Bhatia KK, Aljabar P, et al. Abnormal deep grey matter development following preterm birth detected using deformation-based morphometry. *Neuroimage* 2006;32: 70–8.
- [17] Bourel-Ponchel E, Gueden S, Hasaerts D, Héberlé C, Malifâtre G, Mony L, et al. Normal EEG during the neonatal period: maturational aspects from premature to full-term newborns. *Neurophysiologie Clinique/Clinical Neurophysiology* 2021; in press.
- [18] Bourel-Ponchel E, Hasaerts D, Challamel MJ, Lamblin MD. Behavioral-state development and sleep-state differentiation during early ontogenesis. *Neurophysiologie Clinique/Clinical Neurophysiology* 2021; in press.
- [19] Braga RM, Roze E, Ball G, Merchant N, Tusor N, Arichi T, et al. Development of the Corticospinal and Callosal Tracts from Extremely Premature Birth up to 2 Years of Age. *PLoS ONE* 2015;10: e0125681.
- [20] Buzsáki G, Draguhn A. Neuronal oscillations in cortical networks. *Science* 2004;304: 1926–9.

- [21] Catalano SM, Shatz CJ. Activity-dependent cortical target selection by thalamic axons. *Science* 1998;281: 559–62.
- [22] Chauvet PE, Tich SNT, Schang D, Clément A. Evaluation of automatic feature detection algorithms in EEG: application to interburst intervals. 2014;54: 61-71.
- [23] Chipaux M, Colonnese MT, Mauguen A, Fellous L, Mokhtari M, Lezcano O, et al. Auditory stimuli mimicking ambient sounds drive temporal “delta-brushes” in premature infants. *PLoS ONE* 2013;8: e79028.
- [24] Colonnese M, Khazipov R. Spontaneous activity in developing sensory circuits: Implications for resting state fMRI. *Neuroimage* 2012;62: 2212–21.
- [25] Colonnese MT, Kaminska A, Minlebaev M, Milh M, Bloem B, Lescure S, et al. A conserved switch in sensory processing prepares developing neocortex for vision. *Neuron* 2010;67: 480–98.
- [26] Colonnese MT, Phillips MA. Thalamocortical function in developing sensory circuits. 2018;52-72-9.
- [27] Crippa AC, Silvado CE, Paola L de, Scola RH, Fernandes RM, Werneck LC. Analysis of frontal sharp transients in 32 neonatal polysomnography in healthy fullterm newborns. *Arq Neuropsiquiatr* 2007;65: 222–7.
- [28] Daneshvarfard F, Abrishami Moghaddam H, Dehaene-Lambertz G, Kongolo G, Wallois F, Mahmoudzadeh M. Neurodevelopment and asymmetry of auditory-related responses to repetitive syllabic stimuli in preterm neonates based on frequency-domain analysis. *Sci Rep* 2019;9: 10654.
- [29] Dereymaeker A, Pillay K, Vervisch J, De Vos M, Van Huffel S, Jansen K, et al. Review of sleep-EEG in preterm and term neonates. *Early hum Dev* 2017;113-87-103.
- [30] Desaunay P, Clochon P, Doidy P, Wantzen P, Wallois F, Guile JM, et al. Exploring the ERP time-course of associative recognition in Autism. *Autism research* 2020; In press
- [31] Dosenbach NUF, Nardos B, Cohen AL, Fair DA, Power JD, Church JA, et al. Prediction of individual brain maturity using fMRI. *Science* 2010;329: 1358–61.

- [32] Draganova R, Eswaran H, Murphy P, Lowery C, Preissl H. Serial magnetoencephalographic study of fetal and newborn auditory discriminative evoked responses. *Early Hum Dev* 2007;83: 199–207.
- [33] Draganova R, Schollbach A, Schleger F, Braendle J, Brucker S, Abele H, et al. Fetal auditory evoked responses to onset of amplitude modulated sounds. A fetal magnetoencephalography (fMEG) study. *Hear Res* 2018;363:70-7.
- [34] Dreyfus-Brisac C. The electroencephalogram of the premature infant. *World Neurol* 1962;62;3:5-15.
- [35] Dreyfus-Brisac C, Samsondollfus D, Fischgold H. Cerebral electrical activity in premature and newborn infants. *Sem Hop* 1955;31: 1783–90.
- [36] Dubois J, Benders M, Lazeyras F, Borradori-Tolsa C, Leuchter RH-V, Mangin JF, et al. Structural asymmetries of perisylvian regions in the preterm newborn. *Neuroimage* 2010;52: 32–42.
- [37] Dubois J, Dehaene-Lambertz G, Kulikova S, Poupon C, Hüppi PS, Hertz-Pannier L. The early development of brain white matter: a review of imaging studies in fetuses, newborns and infants. *Neurosciences* 2014;276: 48-71.
- [38] Dubois J, Dehaene-Lambertz G, Perrin M, Mangin J-F, Cointepas Y, Duchesnay E, et al. Asynchrony of the early maturation of white matter bundles in healthy infants: Quantitative landmarks revealed noninvasively by diffusion tensor imaging. *Human Brain Mapping* 2008;29: 14–27.
- [39] Dubois J, Lefèvre J, Angleys H, Leroy F, Fischer C, Lebenberg J, et al. The dynamics of cortical folding waves and prematurity-related deviations revealed by spatial and spectral analysis of gyrification. *Neuroimage* 2019;185: 934-46.
- [40] Dudink J, Kerr JL, Paterson K, Counsell SJ. Connecting the developing preterm brain. *Early Hum Dev* 2008;84: 777–82.
- [41] Dupont E, Hanganu IL, Kilb W, Hirsch S, Luhmann HJ. Rapid developmental switch in the mechanisms driving early cortical columnar networks. *Nature* 2006;439: 79–83.

- [42] Eisermann M, Kaminska A, Moutard M-L, Soufflet C, Plouin P. Normal EEG in childhood: From neonates to adolescents. *Neurophysiologie Clinique/Clinical Neurophysiology* 2013;43: 35–65.
- [43] Elias LAB, Kriegstein AR. Gap junctions: multifaceted regulators of embryonic cortical development. *Trends Neurosci* 2008;31: 243–50.
- [44] Elias LAB, Wang DD, Kriegstein AR. Gap junction adhesion is necessary for radial migration in the neocortex. *Nature* 2007;448: 901–7.
- [45] Engel R. In: *Abnormal electroencephalogram in the neonatal period*. Springfield, Illinois: Charles C. Thomas; 1975.
- [46] Escalona-Vargas D, Coker JL, Ray-Griffith S, Siegel ER, Lowery CL, Stowe ZN, et al. Fetal assessment in buprenorphine-maintained women using fetal magnetoencephalography: a pilot study. *Addiction* 2018;113: 1895–904.
- [47] Eswaran H, Haddad NI, Shihabuddin BS, Preissl H, Siegel ER, Murphy P, et al. Non-invasive detection and identification of brain activity patterns in the developing fetus. *Clin Neurophysiol* 2007;118: 1940–6.
- [48] Eswaran H, Lowery CL, Wilson JD, Murphy P, Preissl H. Functional development of the visual system in human fetus using magnetoencephalography. *Exp Neurol* 2004;190:S51-8.
- [49] Fair DA, Cohen AL, Power JD, Dosenbach NUF, Church JA, Miezin FM, et al. Functional brain networks develop from a “local to distributed” organization. *PLoS Comput Biol* 2009;5: e1000381.
- [50] Feller M. Cortical development: the sources of spontaneous patterned activity. *Curr Biol* 2012;22: R89-91.
- [51] Ferrari F, Torricelli A, Giustardi A, Benatti A, Bolzani R, Ori L, et al. Bioelectric brain maturation in fullterm infants and in healthy and pathological preterm infants at term post-menstrual age. *Early Hum Dev* 1992;28: 37–63.

- [52] Friauf E, McConnell SK, Shatz CJ. Functional synaptic circuits in the subplate during fetal and early postnatal development of cat visual cortex. *J Neurosci* 1990;10: 2601–13.
- [53] Galli L, Maffei L. Spontaneous impulse activity of rat retinal ganglion cells in prenatal life. *Science* 1988;242: 90–1.
- [54] Gardner JL. Is cortical vasculature functionally organized? *NeuroImage* 2010;49: 1953–6.
- [55] Gargiulo P, Belfiore P, Friðgeirsson EA, Vanhatalo S, Ramon C. The effect of fontanel on scalp EEG potentials in the neonate. *Clin Neurophysiol* 2015;126: 1703–10.
- [56] Ghimatgar H, Kazemi K, Helfroush MS, Pillay K, Dereymaker A, Jansen K, et al. Neonatal EEG sleep stage classification based on deep learning and HMM. *J Neural Eng* 2020;17: 036031.
- [57] Graziani LJ, Katz L, Cracco Q, Cracco JB, Weitzman ED. The maturation and interrelationship of EEF patterns and auditory evoked response in premature infants. *Electroencephalogr Clin Neurophysiol* 1974;36: 367–75.
- [58] Grieve PG, Isler JR, Izraelit A, Peterson BS, Fifer WP, Myers MM, et al. EEG functional connectivity in term age extremely low birth weight infants. *Clin Neurophysiol* 2008;119: 2712–20.
- [59] Hadders-Algra M. Early human brain development: Starring the subplate. *Neurobiorev* 2018;92:276-290.
- [60] Hallez H, Vanrumste B, Grech R, Muscat J, De Clercq W, Vergult A, et al. Review on solving the forward problem in EEG source analysis. *J NeuroEngineering Rehabil* 2007;4:46.
- [61] Hanganu IL, Ben-Ari Y, Khazipov R. Retinal waves trigger spindle bursts in the neonatal rat visual cortex. *J Neurosci* 2006;26: 6728–36.

- [62] Hanganu IL, Okabe A, Lessmann V, Luhmann HJ. Cellular mechanisms of subplate-driven and cholinergic input-dependent network activity in the neonatal rat somatosensory cortex. *Cereb Cortex* 2009;19: 89–105.
- [63] Hartkopf J, Schleger F, Keune J, Wiechers C, Pauluschke-Froehlich J, Weiss M, et al. Impact of Intrauterine Growth Restriction on Cognitive and Motor Development at 2 Years of Age. *Front Physiol* 2018;9: 1278.
- [64] Haruda FD. The Structure of Blood Vessels in the Germinal Matrix and the Autoregulation of Cerebral Blood Flow in Premature Infants. *Pediatrics* 2001;108: 1050.
- [65] Hashemi NS, Dehnavi F, Moghimi S, Ghorbani M. Slow spindles are associated with cortical high frequency activity. *Neuroimage* 2019;189:71-84.
- [66] Helfrich RF, Mander BA, Jagust WJ, Knight RT, Walker MP. Old Brains Come Uncoupled in Sleep: Slow Wave-Spindle Synchrony, Brain Atrophy, and Forgetting. *Neuron* 2018;97: 221-30.
- [67] Hellström-Westas L, Rosén I. Electroencephalography and brain damage in preterm infants. *Early Hum Dev* 2005;81: 255–61.
- [68] Hjorth B. An on-line transformation of EEG scalp potentials into orthogonal source derivations. *Electroencephalogr Clin Neurophysiol* 1975;39: 526–30.
- [69] Holmes GL, Logan WJ, Kirkpatrick BV, Meyer EC. Central nervous system maturation in the stressed premature. *Ann Neurol* 1979;6: 518–22.
- [70] Humphrey N. The society of selves. *Philos Trans R Soc Lond, B, Biol Sci* 2007;362: 745–54.
- [71] Hyafil A, Giraud A-L, Fontolan L, Gutkin B. Neural Cross-Frequency Coupling: Connecting Architectures, Mechanisms, and Functions. *Trends Neurosci* 2015;38: 725–40.
- [72] Iyer KK, Roberts JA, Hellström-Westas L, Wikström S, Hansen Pupp I, Ley D, et al. Cortical burst dynamics predict clinical outcome early in extremely preterm infants. *Brain* 2015;138: 2206–18.

- [73] Jacobs EC, Campagnoni C, Kampf K, Reyes SD, Kalra V, Handley V, et al. Visualization of corticofugal projections during early cortical development in a tau-GFP-transgenic mouse. *Eur J Neurosci* 2007;25: 17–30.
- [74] Japaridze N, Muthuraman M, Reinicke C, Moeller F, Anwar AR, Mideksa KG, et al. Neuronal Networks during Burst Suppression as Revealed by Source Analysis. *PLoS ONE* 2015;10: e0123807.
- [75] Kaminska A, Delattre V, Laschet J, Dubois J, Labidurie M, Duval A, et al. Cortical Auditory-Evoked Responses in Preterm Neonates: Revisited by Spectral and Temporal Analyses. *Cereb Cortex* 2018;28: 3429–44.
- [76] Kapellou O, Counsell SJ, Kennea N, Dyet L, Saeed N, Stark J, et al. Abnormal cortical development after premature birth shown by altered allometric scaling of brain growth. *PLoS Med* 2006;3: e265.
- [77] Katz LC, Shatz CJ. Synaptic activity and the construction of cortical circuits. *Science* 1996;274: 1133–8.
- [78] Khazipov R, Luhmann HJ. Early patterns of electrical activity in the developing cerebral cortex of humans and rodents. *Trends Neurosci* 2006;29: 414–8.
- [79] Khazipov R, Milh M. Early patterns of activity in the developing cortex: Focus on the sensorimotor system. *Semin Cell Dev Biol* 2018;76:120-9.
- [80] Kilb W, Kirischuk S, Luhmann HJ. Role of tonic GABAergic currents during pre- and early postnatal rodent development. *Front Neural Circuits*. 2013;7: 139.
- [81] Kilb W, Kirischuk S, Luhmann HJ. Electrical activity patterns and the functional maturation of the neocortex. *Eur J Neurosci* 2011;34: 1677–1686.
- [82] Koolen N, Dereymaeker A, Räsänen O, Jansen K, Vervisch J, Matic V, et al. Interhemispheric synchrony in the neonatal EEG revisited: activation synchrony index as a promising classifier. *Front Hum Neurosci*. 2014; 8: 1030.
- [83] Kostović I, Jovanov-Milošević N. The development of cerebral connections during the first 20–45 weeks' gestation. *Seminars in Fetal and Neonatal Medicine* 2006;11: 415–22.

- [84] Kostović I, Judaš M. The Role of the Subplate Zone in the Structural Plasticity of the Developing Human Cerebral Cortex. *NBA* 2002;1: 145–53.
- [85] Kostović I, Judas M. The development of the subplate and thalamocortical connections in the human foetal brain. *Acta Paediatr* 2010;99: 1119–27.
- [86] Kostović I, Judas M. Early development of neuronal circuitry of the human prefrontal cortex. In: *The Cognitive Neurosciences*. Cambridge, MA –: London: The MIT Press 2009: 29–48.
- [87] Kostovic I, Rakic P. Development of prestriate visual projections in the monkey and human fetal cerebrum revealed by transient cholinesterase staining. *J Neurosci* 1984;4: 25–42.
- [88] Kostovic I, Rakic P. Developmental history of the transient subplate zone in the visual and somatosensory cortex of the macaque monkey and human brain. *J Comp Neurol* 1990;297: 441–70.
- [89] Kostović I, Sedmak G, Judaš M. Neural histology and neurogenesis of the human fetal and infant brain. *Neuroimage* 2019;188: 743-73.
- [90] Krmpotić-Nemanić J, Kostović I, Kelović Z, Nemanić D. Development of acetylcholinesterase (AChE) staining in human fetal auditory cortex. *Acta Otolaryngol* 1980;89: 388–92.
- [91] Krmpotić-Nemanić J, Kostović I, Kelović Z, Nemanić D, Mrzljak L. Development of the human fetal auditory cortex: growth of afferent fibres. *Acta Anat (Basel)* 1983;116: 69–73.
- [92] Lai Y, van Drongelen W, Ding L, Hecox KE, Towle VL, Frim DM, et al. Estimation of in vivo human brain-to-skull conductivity ratio from simultaneous extra- and intracranial electrical potential recordings. *Clin Neurophysiol* 2005;116: 456–65.
- [93] Lamblin MD, André M, Challamel MJ, Curzi-Dascalova L, d’Allest AM, De Giovanni E, et al. [Electroencephalography of the premature and term newborn. Maturation aspects and glossary]. *Neurophysiol Clin* 1999;29: 123–219.

- [94] Lavanga M, De Wel O, Caicedo A, Heremans E, Jansen K, Dereymaeker A, et al. Automatic quiet sleep detection based on multifractality in preterm neonates: Effects of maturation. 2017 Epub.
- [95] Lew S, Sliva DD, Choe M, Grant PE, Okada Y, Wolters CH, et al. Effects of sutures and fontanels on MEG and EEG source analysis in a realistic infant head model. *Neuroimage* 2013;76: 282–93.
- [96] Linder K, Schleger F, Kiefer-Schmidt I, Fritsche L, Kümmel S, Böcker M, et al. Gestational Diabetes Impairs Human Fetal Postprandial Brain Activity. *J Clin Endocrinol Metab* 2015;100: 4029–36.
- [97] Lodygensky GA, Vasung L, Sizonenko SV, Hüppi PS. Neuroimaging of cortical development and brain connectivity in human newborns and animal models. *Journal of Anatomy* 2010;217: 418–28.
- [98] Lombroso CT. Quantified electrographic scales on 10 pre-term healthy newborns followed up to 40-43 weeks of conceptional age by serial polygraphic recordings. *Electroencephalogr Clin Neurophysiol* 1979;46: 460–74.
- [99] Lombroso CT. Normal and abnormal EEG in full-term neonates. In: *Current clinical neurophysiology. Updates on EEG and evoked potentials*. New York: Elsevier/North holland; 1980: 83–150.
- [100] Lombroso CT. Neurophysiological observations in diseased newborns. *Biol Psychiatry* 1975;10: 527–58.
- [101] Luhmann HJ, Kirischuk S, Kilb W. The Superior Function of the Subplate in Early Neocortical Development. *Front Neuroanat*. 2018; 12: 97.
- [102] Luhmann HJ, Sinning A, Yang J-W, Reyes-Puerta V, Stüttgen MC, Kirischuk S, et al. Spontaneous Neuronal Activity in Developing Neocortical Networks: From Single Cells to Large-Scale Interactions. *Front Neural Circuits* 2016;10: 40.
- [103] Maas LC, Mukherjee P, Carballido-Gamio J, Veeraraghavan S, Miller SP, Partridge SC, et al. Early laminar organization of the human cerebrum demonstrated with

- diffusion tensor imaging in extremely premature infants. *Neuroimage* 2004;22: 1134–40.
- [104] MacKay DM. On-line source-density computation with a minimum of electrodes. *Electroencephalogr Clin Neurophysiol* 1983;56: 696–8.
- [105] Mahmoudzadeh M, Dehaene-Lambertz G, Fournier M, Kongolo G, Goudjil S, Dubois J, et al. Syllabic discrimination in premature human infants prior to complete formation of cortical layers. *Proc Natl Acad Sci USA* 2013;110: 4846–51.
- [106] Mahmoudzadeh M, Wallois F, Kongolo G, Goudjil S, Dehaene-Lambertz G. Functional Maps at the Onset of Auditory Inputs in Very Early Preterm Human Neonates. *Cereb Cortex* 2017;27: 2500-12.
- [107] Marcano-Reik AJ, Blumberg MS. The corpus callosum modulates spindle-burst activity within homotopic regions of somatosensory cortex in newborn rats. *Eur J Neurosci* 2008;28: 1457–66.
- [108] Marcotti W, Johnson SL, Holley MC, Kros CJ. Developmental changes in the expression of potassium currents of embryonic, neonatal and mature mouse inner hair cells. *J Physiol (Lond)* 2003;548: 383–400.
- [109] Marín-Padilla M. Cajal-Retzius cells and the development of the neocortex. *Trends Neurosci* 1998;21: 64–71.
- [110] Meyerson BA. Ontogeny of interhemispheric functions. An electrophysiological study in pre- and postnatal sheep. *Acta Physiol Scand Suppl* 1968;312: 1-111.
- [111] Milde T, Putsche P, Schwab K, Wacker M, Eiselt M, Witte H. Dynamics of directed interactions between brain regions during interburst-burst EEG patterns in quiet sleep of full-term neonates. *Neurosci Lett* 2011;488: 148–153.
- [112] Minlebaev M, Ben-Ari Y, Khazipov R. NMDA receptors pattern early activity in the developing barrel cortex in vivo. *Cereb Cortex* 2009;19: 688–96.

- [113] Minlebaev M, Ben-Ari Y, Khazipov R. Network mechanisms of spindle-burst oscillations in the neonatal rat barrel cortex in vivo. *J Neurophysiol* 2007;97: 692–700.
- [114] Mitrukhina O, Suchkov D, Khazipov R, Minlebaev M. Imprecise Whisker Map in the Neonatal Rat Barrel Cortex. *Cereb Cortex* 2015;25: 3458–67.
- [115] Moghimi S, Shadkam A, Mahmoudzadeh M, Calipe O, Panzani M, Edalati M, et al. The intimate relationship between coalescent generators in very premature human newborn brains: Quantifying the coupling of nested endogenous oscillations. *Human Brain Mapping* 2020; In press.
- [116] Molliver ME. An ontogenetic study of evoked somesthetic cortical responses in the sheep. *Prog Brain Res* 1967;26:78-91.
- [117] Molliver ME, Kostovic´ I, Van Der Loos H. The development of synapses in cerebral cortex of the human fetus. *Brain Research* 1973;50: 403–7.
- [118] Monod N, Dreyfus-Brisac C, Ducas P, Mayer M. [The EEG of the newborn infant at term. Comparative study in the newborn infant in cephalic presentation and breech presentation]. *Rev Neurol (Paris)* 1960;102:375-9.
- [119] Monod N, Pajot N. Le sommeil du nouveau-né et du prématuré. *NEO* 1965;8: 281–307.
- [120] Moody WJ, Bosma MM. Ion channel development, spontaneous activity, and activity-dependent development in nerve and muscle cells. *Physiol Rev* 2005;85: 883–941.
- [121] Moore AR, Zhou W-L, Jakovcevski I, Zecevic N, Antic SD. Spontaneous electrical activity in the human fetal cortex in vitro. *J Neurosci* 2011;31: 2391–98.
- [122] Moore AR, Zhou W-L, Sirois CL, Belinsky GS, Zecevic N, Antic SD. Connexin hemichannels contribute to spontaneous electrical activity in the human fetal cortex. *Proc Natl Acad Sci USA* 2014;111: E3919-28.

- [123] Moreno-Juan V, Filipchuk A, Antón-Bolaños N, Mezzera C, Gezelius H, Andrés B, et al. Prenatal thalamic waves regulate cortical area size prior to sensory processing. *Nat Commun* 2017;8: 14172.
- [124] Morin EC, Schleger F, Preissl H, Braendle J, Eswaran H, Abele H, et al. Functional brain development in growth-restricted and constitutionally small fetuses: a fetal magnetoencephalography case-control study. *BJOG* 2015;122: 1184–90.
- [125] Murata Y, Colonnese MT. An excitatory cortical feedback loop gates retinal wave transmission in rodent thalamus. *eLife* 2016; 5: e18816.
- [126] Murphy K, Stevenson NJ, Goulding RM, Lloyd RO, Korotchikova I, Livingstone V, et al. Automated analysis of multi-channel EEG in preterm infants. *Clin Neurophysiol* 2015;126: 1692–702.
- [127] Myers MM, Grieve PG, Izraelit A, Fifer WP, Isler JR, Darnall RA, et al. Developmental profiles of infant EEG: overlap with transient cortical circuits. *Clin Neurophysiol* 2012;123: 1502–11.
- [128] Nagode DA, Meng X, Winkowski DE, Smith E, Khan-Tareen H, Kareddy V, et al. Abnormal Development of the Earliest Cortical Circuits in a Mouse Model of Autism Spectrum Disorder. *Cell Rep* 2017;18: 1100–8.
- [129] Navakatikyan MA, O'Reilly D, Van Marter LJ. Automatic measurement of interburst interval in premature neonates using range EEG. *Clin Neurophysiol* 2016;127: 1233–46.
- [130] Nourhashemi M, Kongolo G, Mahmoudzadeh M, Goudjil S, Wallois F. Relationship between relative cerebral blood flow, relative cerebral blood volume, and relative cerebral metabolic rate of oxygen in the preterm neonatal brain. *Neurophotonics* 2017;4: 021104.
- [131] Nourhashemi M, Mahmoudzadeh M, Goudjil S, Kongolo G, Wallois F. Neurovascular coupling in the developing neonatal brain at rest. *Hum Brain Mapp* 2020;41: 503–19.

- [132] Odabae M, Freeman WJ, Colditz PB, Ramon C, Vanhatalo S. Spatial patterning of the neonatal EEG suggests a need for a high number of electrodes. *Neuroimage* 2013;68:229-35.
- [133] O'Donovan MJ. The origin of spontaneous activity in developing networks of the vertebrate nervous system. *Curr Opin Neurobiol* 1999;9: 94–104.
- [134] Okumura A, Kubota T, Toyota N, Kidokoro H, Maruyama K, Kato T, et al. Amplitude spectral analysis of maturational changes of delta waves in preterm infants. *Brain Dev* 2003;25: 406–10.
- [135] O'Leary DDM, Chou S-J, Hamasaki T, Sahara S, Takeuchi A, Thuret S, et al. Regulation of laminar and area patterning of mammalian neocortex and behavioural implications. *Novartis Found Symp* 2007;288:141-59.
- [136] Omidvarnia A, Fransson P, Metsäranta M, Vanhatalo S. Functional bimodality in the brain networks of preterm and term human newborns. *Cereb Cortex* 2014;24: 2657–68.
- [137] O'Toole JM, Boylan GB, Lloyd RO, Goulding RM, Vanhatalo S, Stevenson NJ. Detecting bursts in the EEG of very and extremely premature infants using a multi-feature approach. *Med Eng Phys* 2017; 45: 42–50.
- [138] Padilla N, Lagercrantz H. Making of the mind. *Acta Paediatrica* 2020;109: 883–92.
- [139] Palmu K, Stevenson N, Wikström S, Hellström-Westas L, Vanhatalo S, Palva JM. Optimization of an NLEO-based algorithm for automated detection of spontaneous activity transients in early preterm EEG. *Physiol Meas* 2010;31: N85-93.
- [140] Palmu K, Wikström S, Hippeläinen E, Boylan G, Hellström-Westas L, Vanhatalo S. Detection of “EEG bursts” in the early preterm EEG: visual vs. automated detection. *Clin Neurophysiol* 2010;121: 1015–22.
- [141] Penn AA, Shatz CJ. Brain waves and brain wiring: the role of endogenous and sensory-driven neural activity in development. *Pediatr Res* 1999;45: 447–58.

- [142] Piryatinska A, Terdik G, Woyczynski WA, Loparo KA, Scher MS, Zlotnik A. Automated detection of neonate EEG sleep stages. *Comput Methods Programs Biomed* 2009;95: 31–46.
- [143] Pursiainen S, Lew S, Wolters CH. Forward and inverse effects of the complete electrode model in neonatal EEG. *J Neurophysiol* 2017;117: 876–84.
- [144] Rakic P. Specification of cerebral cortical areas. *Science* 1988;241: 170–6.
- [145] Ranasinghe S, Or G, Wang EY, Ievins A, McLean MA, Niell CM, et al. Reduced Cortical Activity Impairs Development and Plasticity after Neonatal Hypoxia Ischemia. *J Neurosci* 2015;35: 11946–59.
- [146] Richter Z, Janszky J, Sétáló G, Horváth R, Horváth Z, Dóczi T, et al. Characterization of neurons in the cortical white matter in human temporal lobe epilepsy. *Neuroscience* 2016;333: 140-50.
- [147] Roberts JA, Iyer KK, Finnigan S, Vanhatalo S, Breakspear M. Scale-free bursting in human cortex following hypoxia at birth. *J Neurosci* 2014;34: 6557–72.
- [148] Roche-Labarbe N, Aarabi A, Kongolo G, Gondry-Jouet C, Dümpelmann M, Grebe R, et al. High-resolution electroencephalography and source localization in neonates. *Human Brain Mapping* 2008;29: 167–76.
- [149] Roche-Labarbe N, Zaaimi B, Berquin P, Nehlig A, Grebe R, Wallois F. NIRS-measured oxy- and deoxyhemoglobin changes associated with EEG spike-and-wave discharges in children. *Epilepsia* 2008;49: 1871–80.
- [150] Routier L, Mahmoudzadeh M, Panzani M, Azizollahi H, Goudjil S, Kongolo G, et al. Plasticity of neonatal neuronal networks in very premature infants: Source localization of temporal theta activity, the first endogenous neural biomarker, in temporoparietal areas. *Human Brain Mapping* 2017;38: 2345–58.
- [151] Salimpour Y, Anderson WS. Cross-Frequency Coupling Based Neuromodulation for Treating Neurological Disorders. *Front Neurosci* 2019; 13: 125.

- [152] Schwab K, Groh T, Schwab M, Witte H. Nonlinear analysis and modeling of cortical activation and deactivation patterns in the immature fetal electrocorticogram. *Chaos* 2009;19: 015111.
- [153] Selton D, Andre M, Hascoët JM. Normal EEG in very premature infants: reference criteria. *Clin Neurophysiol* 2000;111: 2116–24.
- [154] Sheikh A, Meng X, Liu J, Mikhailova A, Kao JPY, McQuillen PS, et al. Neonatal Hypoxia-Ischemia Causes Functional Circuit Changes in Subplate Neurons. *Cereb Cortex* 2019;29: 765–76.
- [155] Sheridan CJ, Preissl H, Siegel ER, Murphy P, Ware M, Lowery CL, et al. Neonatal and fetal response decrement of evoked responses: a MEG study. *Clin Neurophysiol* 2008;119: 796–804.
- [156] Sipilä ST, Huttu K, Soltesz I, Voipio J, Kaila K. Depolarizing GABA acts on intrinsically bursting pyramidal neurons to drive giant depolarizing potentials in the immature hippocampus. *J Neurosci* 2005;25: 5280–89.
- [157] Smit DJA, Stam CJ, Posthuma D, Boomsma DI, de Geus EJC. Heritability of “small-world” networks in the brain: a graph theoretical analysis of resting-state EEG functional connectivity. *Hum Brain Mapp* 2008;29: 1368–78.
- [158] Smyser CD, Inder TE, Shimony JS, Hill JE, Degnan AJ, Snyder AZ, et al. Longitudinal analysis of neural network development in preterm infants. *Cereb Cortex* 2010;20: 2852–62.
- [159] Speckmann E-J, Caspers H, Elger CE. Neuronal Mechanisms Underlying the Generation of Field Potentials. In: Elbert T, Rockstroh B, Lutzenberger W, Birbaumer N, editors. *Self-Regulation of the Brain and Behavior*. Berlin, Heidelberg: Springer; 1984: 9–25.
- [160] Speckmann E-J, Elger CE. Introduction to the neurophysiological basis of the EEG and DC potentials. In: *Electroencephalography: Basic Principles, Clinical Applications and Related Fields*,. Baltimore: Williams and Wilkins,; 1999: 15–27.

- [161] Spitzer NC. Electrical activity in early neuronal development. *Nature* 2006;444: 707–12.
- [162] Stam CJ, van Straaten ECW. The organization of physiological brain networks. *Clin Neurophysiol* 2012;123: 1067–87.
- [163] staresina. 2015;
- [164] Stevenson NJ, Oberdorfer L, Koolen N, O’Toole JM, Werther T, Klebermass-Schrehof K, et al. Functional maturation in preterm infants measured by serial recording of cortical activity. *Sci Rep* 2017;7: 12969.
- [165] Sun J-J, Luhmann HJ. Spatio-temporal dynamics of oscillatory network activity in the neonatal mouse cerebral cortex. *Eur J Neurosci* 2007;26: 1995–2004.
- [166] Takahashi E, Folkerth RD, Galaburda AM, Grant PE. Emerging cerebral connectivity in the human fetal brain: an MR tractography study. *Cereb Cortex* 2012;22: 455–64.
- [167] Tokariev A, Vanhatalo S, Palva JM. Analysis of infant cortical synchrony is constrained by the number of recording electrodes and the recording montage. *Clin Neurophysiol* 2016;127: 310–23.
- [168] Tolner EA, Sheikh A, Yukin AY, Kaila K, Kanold PO. Subplate neurons promote spindle bursts and thalamocortical patterning in the neonatal rat somatosensory cortex. *J Neurosci* 2012;32: 692–702.
- [169] Tolonen M, Palva JM, Andersson S, Vanhatalo S. Development of the spontaneous activity transients and ongoing cortical activity in human preterm babies. *Neuroscience* 2007;145: 997–1006.
- [170] Torres F, Anderson C. The normal EEG of the human newborn. *J Clin Neurophysiol* 1985;2: 89–103.
- [171] Tóth B, Urbán G, Háden GP, Márk M, Török M, Stam CJ, et al. Large-scale network organization of EEG functional connectivity in newborn infants. *Hum Brain Mapp* 2017;38: 4019–33.

- [172] Tritsch NX, Bergles DE. Developmental regulation of spontaneous activity in the Mammalian cochlea. *J Neurosci* 2010;30: 1539–50.
- [173] Tritsch NX, Yi E, Gale JE, Glowatzki E, Bergles DE. The origin of spontaneous activity in the developing auditory system. *Nature* 2007;450: 50–5.
- [174] Turnbull JP, Loparo KA, Johnson MW, Scher MS. Automated detection of tracé alternant during sleep in healthy full-term neonates using discrete wavelet transform. *Clin Neurophysiol* 2001;112: 1893–900.
- [175] Vairavan S, Govindan RB, Haddad N, Preissl H, Lowery CL, Siegel E, et al. Quantification of fetal magnetoencephalographic activity in low-risk fetuses using burst duration and interburst interval. *Clin Neurophysiol* 2014;125: 1353–9.
- [176] Vanhatalo S, Kaila K. Development of neonatal EEG activity: from phenomenology to physiology. *Semin Fetal Neonatal Med* 2006;11: 471–8.
- [177] Vanhatalo S, Lauronen L. Neonatal SEP - back to bedside with basic science. *Semin Fetal Neonatal Med* 2006;11: 464–70.
- [178] Vanhatalo S, Palva JM, Andersson S, Rivera C, Voipio J, Kaila K. Slow endogenous activity transients and developmental expression of K⁺-Cl⁻ cotransporter 2 in the immature human cortex. *Eur J Neurosci* 2005;22: 2799–2804.
- [179] Vanhatalo S, Tallgren P, Andersson S, Sainio K, Voipio J, Kaila K. DC-EEG discloses prominent, very slow activity patterns during sleep in preterm infants. *Clin Neurophysiol* 2002;113: 1822–5.
- [180] Vanhatalo S, Voipio J, Kaila K. Full-band EEG (fbEEG): a new standard for clinical electroencephalography. *Clin EEG Neurosci* 2005;36: 311–17.
- [181] Vecchierini M-F, d'Allest A-M, Verpillat P. EEG patterns in 10 extreme premature neonates with normal neurological outcome: qualitative and quantitative data. *Brain Dev* 2003;25: 330–7.
- [182] Vorwerk H, Mohr J, Huber C, Wensel O, Schmidt-Hohagen K, Gripp E, Josenhans C, Schomburg D, Eisenreich W, Hofreuter D. A guideline for head volume conductor modeling in EEG and MEG. *Mol Microbiol.* 2014; 93(6):1224-45.

- [183] Wallois F. Synopsis of maturation of specific features in EEG of premature neonates. *Neurophysiol Clin* 2010;40: 125–6.
- [184] Wallois F, Patil A, Kongolo G, Goudjil S, Grebe R. Haemodynamic changes during seizure-like activity in a neonate: a simultaneous AC EEG-SPIR and high-resolution DC EEG recording. *Neurophysiol Clin* 2009;39: 217–27.
- [185] Wallois F, Routier L, Bourel-Ponchel E. Impact of prematurity on neurodevelopment. In: *Handbook of Clinical Neurology*. Elsevier/North holland; 2020.
- [186] Watanabe K, Hayakawa F, Okumura A. Neonatal EEG: a powerful tool in the assessment of brain damage in preterm infants. *Brain Dev* 1999;21: 361–72.
- [187] Watanabe K, Iwase K. Spindle-like fast rhythms in the EEGs of low-birth weight infants. *Dev Med Child Neurol* 1972;14: 373–81.
- [188] Watanabe K, Iwase K, Hara K. Development of slow-wave sleep in low-birthweight infants. *Dev Med Child Neurol* 1974;16: 23–31.
- [189] Weliky M, Katz LC. Correlational structure of spontaneous neuronal activity in the developing lateral geniculate nucleus in vivo. *Science* 1999;285: 599–604.
- [190] Werner SS, Stockard JE, Bickford RR. *Atlas of neonatal electroencephalography*. New York: Raven Press; 1977.
- [191] Wess JM, Isaiah A, Watkins PV, Kanold PO. Subplate neurons are the first cortical neurons to respond to sensory stimuli. *Proc Natl Acad Sci USA* 2017;114: 12602–12607.
- [192] Witte H, Putsche P, Eiselt M, Schwab K, Wacker M, Leistriz L. Time-variant analysis of phase couplings and amplitude-frequency dependencies of and between frequency components of EEG burst patterns in full-term newborns. *Clin Neurophysiol* 2011;122: 253–66.

- [193] Witte H, Putsche P, Schwab K, Eiselt M, Helbig M, Suesse T. On the spatio-temporal organisation of quadratic phase-couplings in “tracé alternant” EEG pattern in full-term newborns. *Clin Neurophysiol* 2004;115: 2308–15.
- [194] Yang J-W, An S, Sun J-J, Reyes-Puerta V, Kindler J, Berger T, et al. Thalamic network oscillations synchronize ontogenetic columns in the newborn rat barrel cortex. *Cereb Cortex* 2013;23: 1299–1316.
- [195] Yang J-W, Hanganu-Opatz IL, Sun J-J, Luhmann HJ. Three patterns of oscillatory activity differentially synchronize developing neocortical networks in vivo. *J Neurosci* 2009;29: 9011–25.
- [196] Zhao C, Kao JPY, Kanold PO. Functional excitatory microcircuits in neonatal cortex connect thalamus and layer 4. *J Neurosci* 2009;29: 15479–88.

Legends for figure

Fig. 1. Schematic representation of the main cortical histogenic and neurogenic events and their intensities at different stages of development in human. Note the predominance of proliferation and migration during the first trimester of pregnancy, the growth of axons and dendrites during the second and third trimesters, and prolonged synaptogenesis, myelination, and neurochemical maturation in the postnatal period. (Kostović et al., 2019)

Figure 2: Comparison of normal EEGs in a 14-year-old child and a 25 wGA premature neonate

Figure 3: A: HR EEG with 64 electrodes in a 25 wGA premature showing the TTA-SW over left temporal electrodes B: Bipolar montage, C: Amplitude topography of TTA-SW

Figure 4: The subplate (in yellow), cortical plate (in green) and thalamic afferents (in red) at different gestational ages (adapted from (Kostović & Judas, 2010))

Figure 5: A: Schematic of inputs to the cortical and subplate neurons likely to modulate the excitability of the neuronal network at both, generator based and network based dynamic levels. This includes intra and interhemispheric fibers, thalamic afferents to the subplate before 28 wGA and to both the subplate and the cortical plate after 28 wGA. Note also the effect of non-synaptic environment (hemodynamic and/or metabolic) that might also modulate the threshold of bursts or activation of endogenous generators. B: Schematic of changes in thalamo-cortical and subplate circuits in the developing ferret auditory cortex. At a young age, the subplate receives thalamic input and projects to the cortical plate. The sensory organs are not fully functional at this early stage (in grey) but might convey spontaneous endogenous activities from the immature sensory organs to the subplate neurons. Later in development, the thalamo-cortical afferents innervate the cortical plate, and the subplate neurons receive input from the cortical plate. The sensory organs are functional at this stage (in black). (Adapted from (Wess et al., 2017)). C: Occurrence of defined sleep stages from 28 wGA. D: schematic representation of the modulation of the sleep network on the background activity, including the discontinuity or the occurrence of bursts.

Figure 6: A: The dipoles in the premature brain are mostly radially oriented. B: Impact of fontanelles on the magnification factor in the forward model (Azizollahi et al., 2016) and on source localization in the inverse model (Azizollahi et al., 2020 a and b). The maximum error caused by the presence of a fontanelle is measured over the temporal pole and beneath the central fontanelle.

Figure 7: High-resolution HR EEG recordings with a 128-electrode set-up in twins (32 wGA) (personal data).

Figure 8: Summary of EEG maturation in premature neonates (adapted from Wallois et al., 2010). N: Network based dynamic. G: Generator based dynamic

Figure 9: EEGs recorded at different ages and during different sleep stages (personal data)

Figure 10: A: An EEG recorded in a premature neonate (28 wGA), showing a quiescent period and the synchrony between the hemispheres with asynchrony between oscillators. B: A HR (64-channel) recorded in a premature neonate (28 wGA), showing the asynchrony between the hemispheres and between the oscillators (personal data)

Figure 11: Spatiotemporal features of the scalp EEG during quiet sleep in a preterm baby (32 wGA). (A) Scrutiny of the full-band EEG demonstrates that most of the electrical activity at this age is composed of high-amplitude SATs lasting for up to several seconds. Conventional filtering (>0.5 Hz) eliminates the characteristic slow component of SATs. (Vanhatalo et al., 2005a)

Figure 12: Normal oscillatory activities recorded at specific gestational ages (personal data)

Figure 13: A: EEG recorded in a premature infant (age 25 wGA; band-pass filter: 0.5–20 Hz). A TTA-SW event is clearly seen over FP1-T3 and T3-O1. B: The unit circle of preferred phases of SW to TTA modulation in 25 newborns. The preferred phases of SW to TTA modulation is around the trough of SW, as shown by the red line.

C: Event-related histograms showing the timing of the beginning of TTA events in relation with the trough of the SW. D: Grand average of SW trough–locked time frequency representation (zero at SW trough) (adapted from Moghimi et al. 2020).

Figure 14: Top EEG recorded in bipolar (top) or HR (bottom) montage in a 27 WGA showing in TTA-SW, TO-SW and CTC_SW (personal data)

Figure 15: A: TTA-SW recorded in High Resolution with an average montage in a 31 wGA premature neonate. Inlet: Zoom on temporal electrodes. B: Bipolar Montage showing the TTA-SW over the right temporal areas. C: Topoplot of the TTA-SW at the peak of the TTA. D: Source localization of the TTA (Routier et al., 2019). Note how TTA-SW are restricted to temporal area.

Figure 16: A: High resolution EEG Showing the TTA-SW (green inlet) and diffuse Delta brushes (blue inlet). B: Low resolution bipolar EEG showing the TTA-SW (green inlet) and the diffuse Delta Brushes (Blue Inlet. C: labelling and position of the electrodes. Note that the TTA-SW are not located on the same electrodes than the Delat Brushes

Figure 17: Optical imaging of the neuronal network activated in response to phonemes and voices in 28 wGA premature neonates (Mahmoudzadeh et al., 2013). B Repetitive stimulation of phonemes induces synchronization and habituation (B1) and a specific lateralized Mismatch in response to voice and phonemes (Mahmoudzadeh et al., 2016) (A) and personal unpublished figures (B)

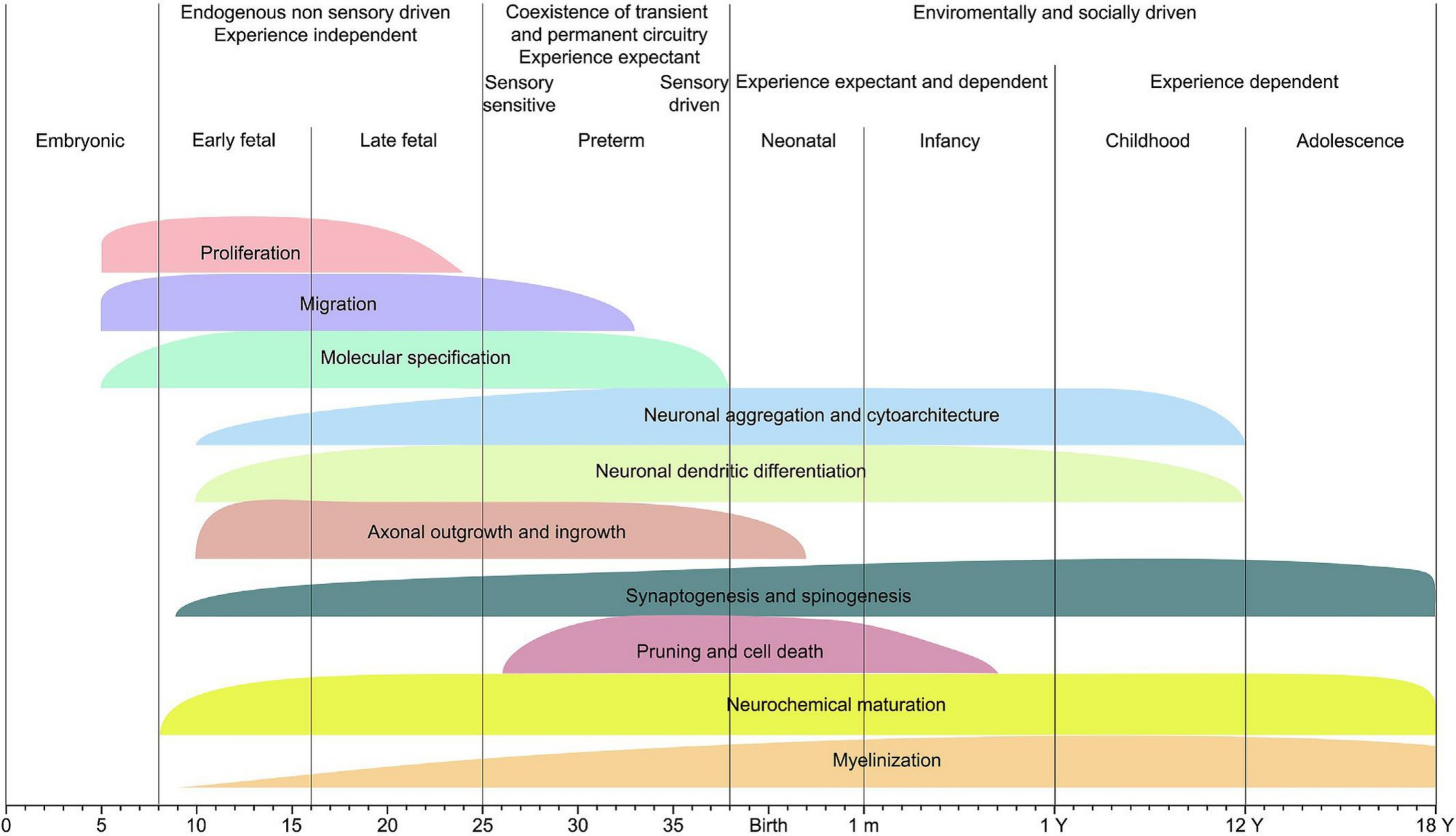
Figure 18: A: High Resolution EEG with 128 electrodes showing localized delta brushes in a 32 wGA premature. B: Low resolution bipolar EEG showing focal Delta Brushes. C: Topoplot of the slow wave of the Delta Brushes

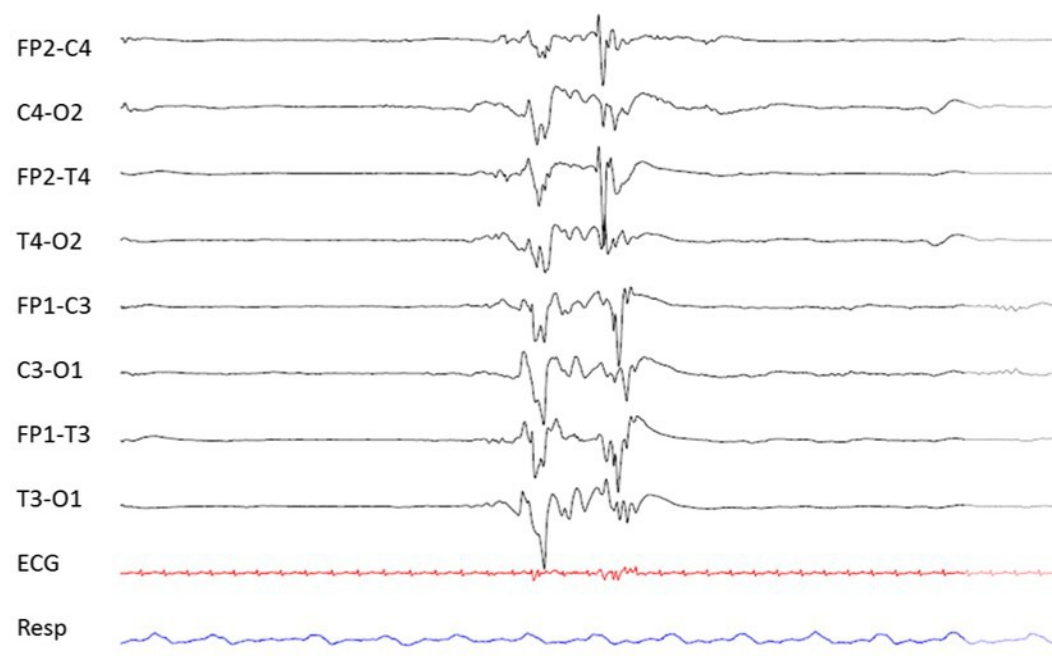
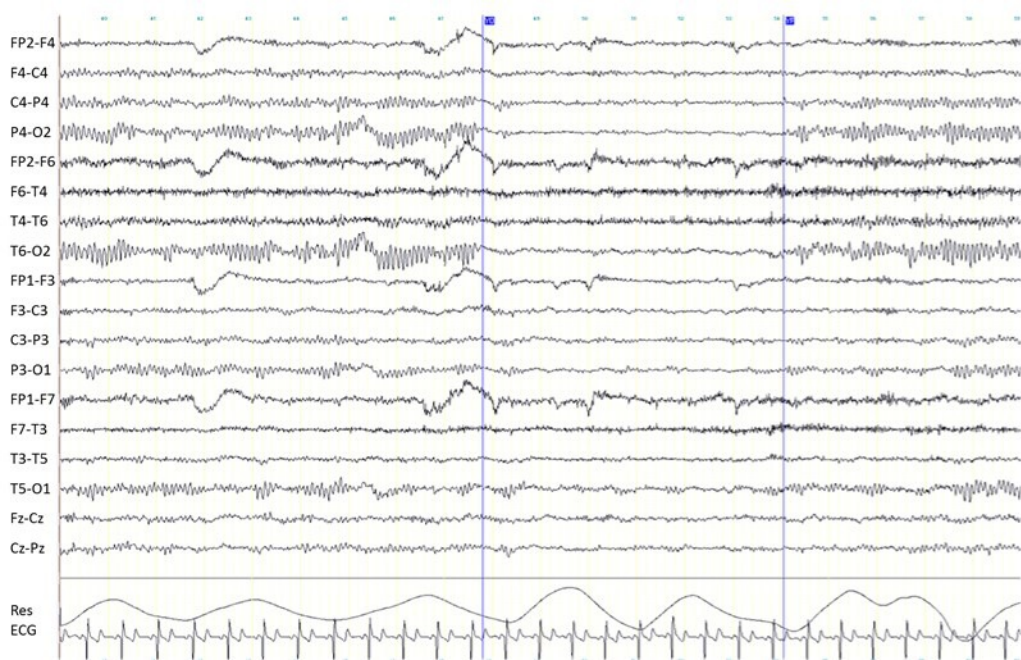
Figure 19: High Resolution EEG using 64 electrodes at 28 wGA showing TTA SW (red) followed by a focal Delta Brushes (green and finally a diffuse Delta brushes with an oscillatory pattern (Blue).

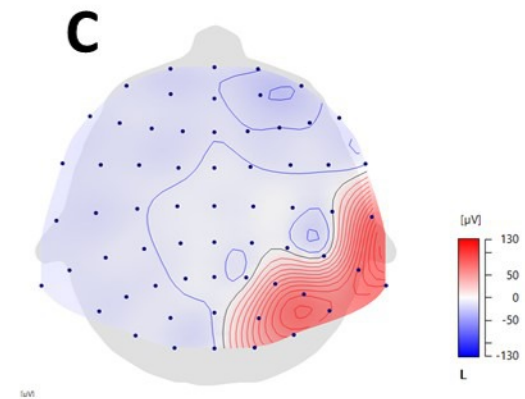
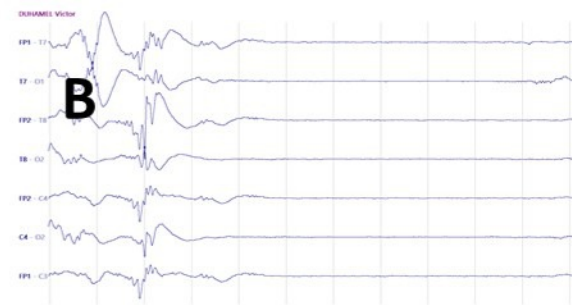
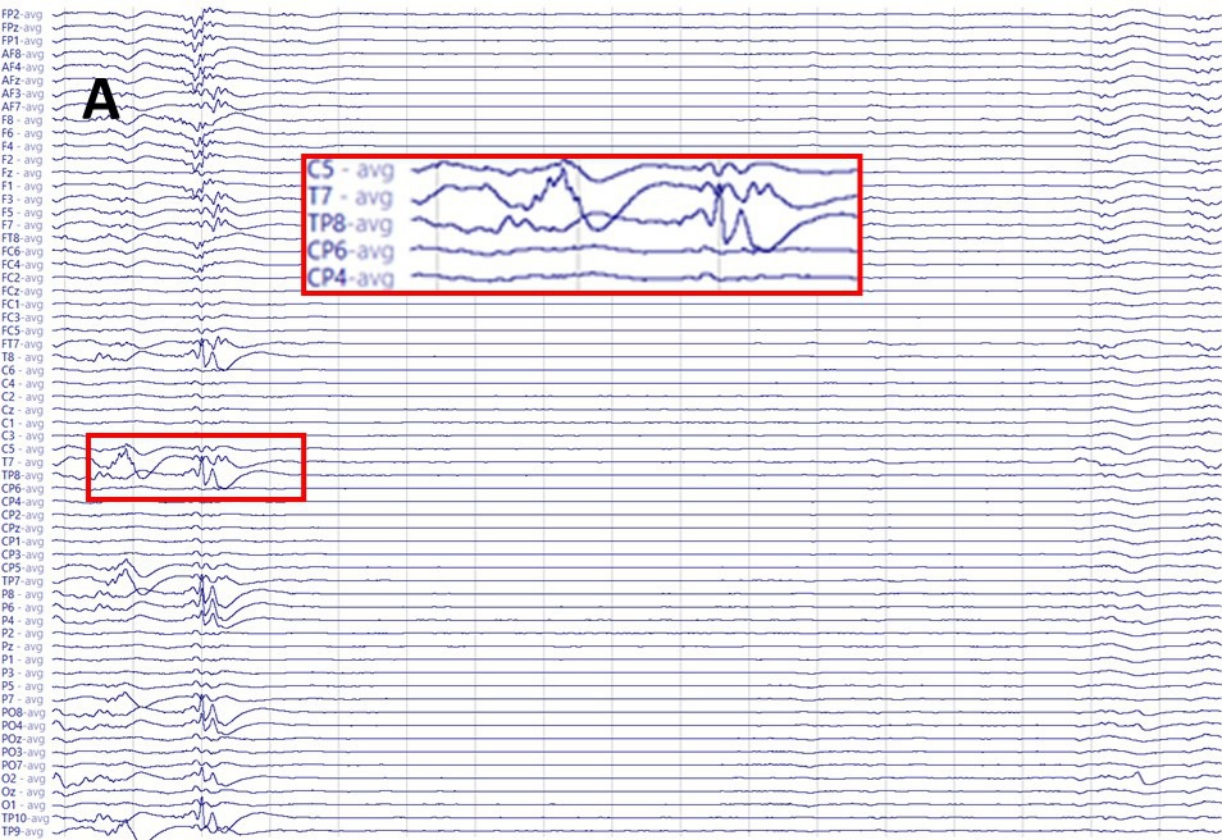
Figure 20: A and B High resolution EEG with 128 electrodes in a 40 WGA full term neonate showing right hemispheric frontal transient (A) and bilateral frontal transient (B). C: Bilateral slow anterior dysrhythmia. 14 first blue traces: Right frontal area, 3 green traces: Midline frontal area, 15 red traces: left frontal area. D: Amplitude topography of the isolated right frontal transient.

Figure 21: Functional connectivity pattern during TTA-SW. Comparison of functional connectivity during TTA-SW (DT) and before TTA-SW (BF) in the theta band (4-8 Hz) revealed (a) functional connectivity in the left temporal region of left TTA-SW subjects' group and connectivity from the left temporal region to the frontal and posterior regions. (b) Right TTA-SW subjects also presented significant FC in the right temporal region and from the central to the frontal regions (Adebimpe et al., 2019)

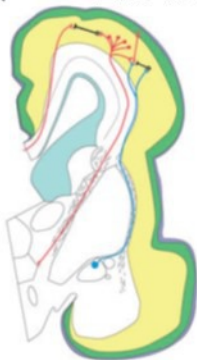Figure 22: MEG tracings at 33 weeks of gestation. (a) Segment showing existence of delta brush activity. (b) A cartoon of fetal position as observed by ultrasound. (c) Isofield map of the magnetic activity. (Eswaran et al., 2007).



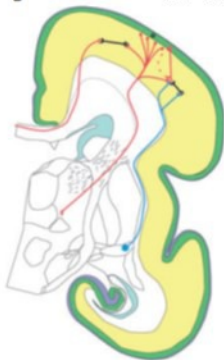



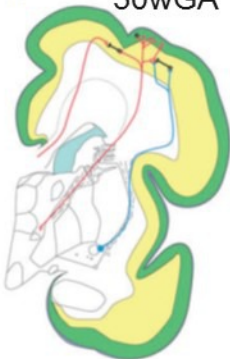
A 20wGA



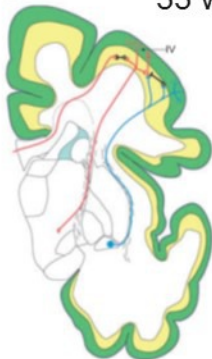
B 28 wGA



C 30wGA



D 33 wGA

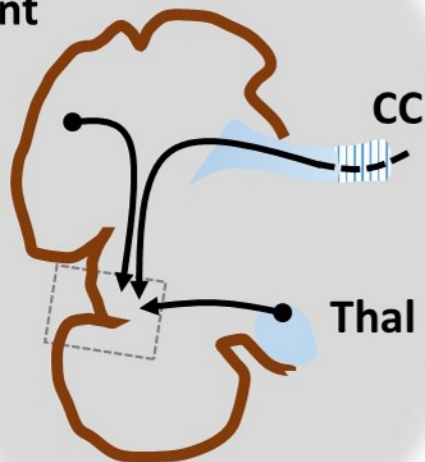
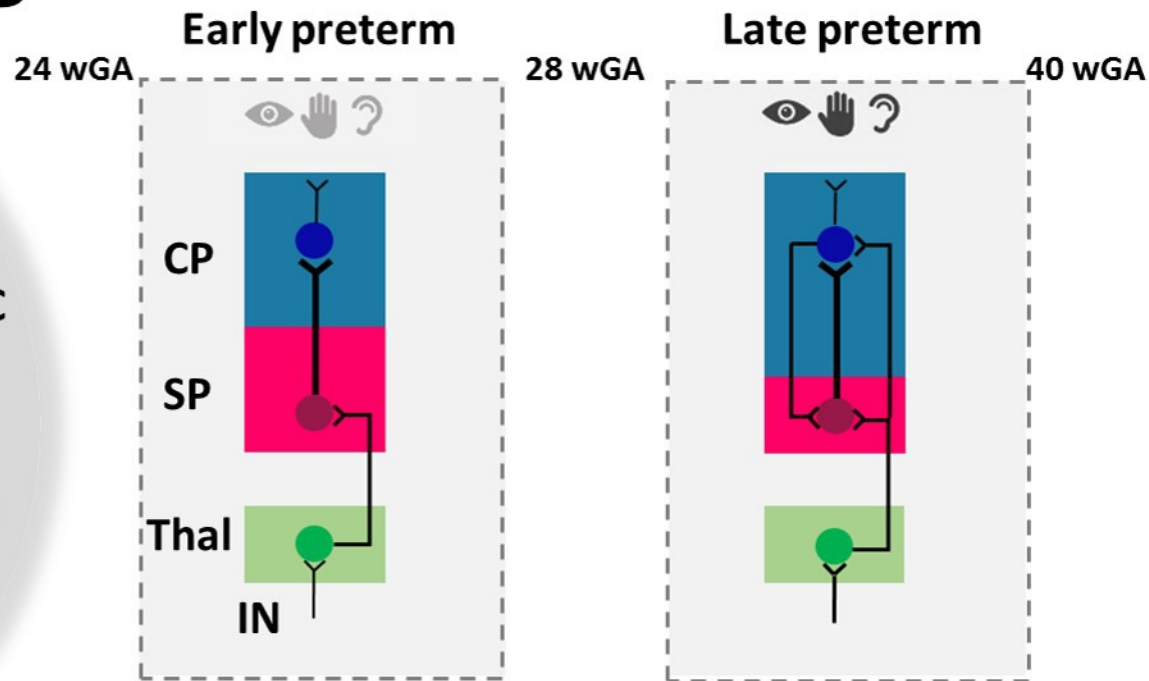


■ Marginal zone
 ■ Cortical plate
 ■ Subplate zone
 ■ Ventricular zone and ganglionic eminence

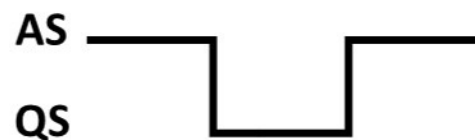
—◆— Cholinergic
 —◆— GABAergic
 —◆— Glutamatergic

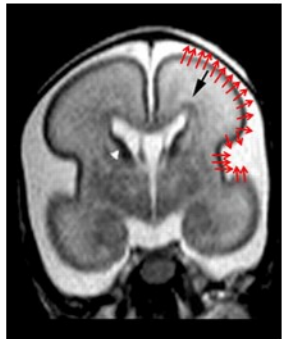A

Non-synaptic environment

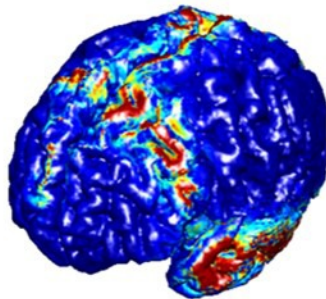
**B****C**

Sleep —————

**D**Discontinous
Activity in sleepContinous Activity AS
Discontinous Activity QS

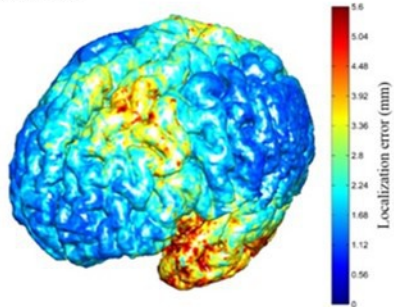
A**MAG****B**

Forward



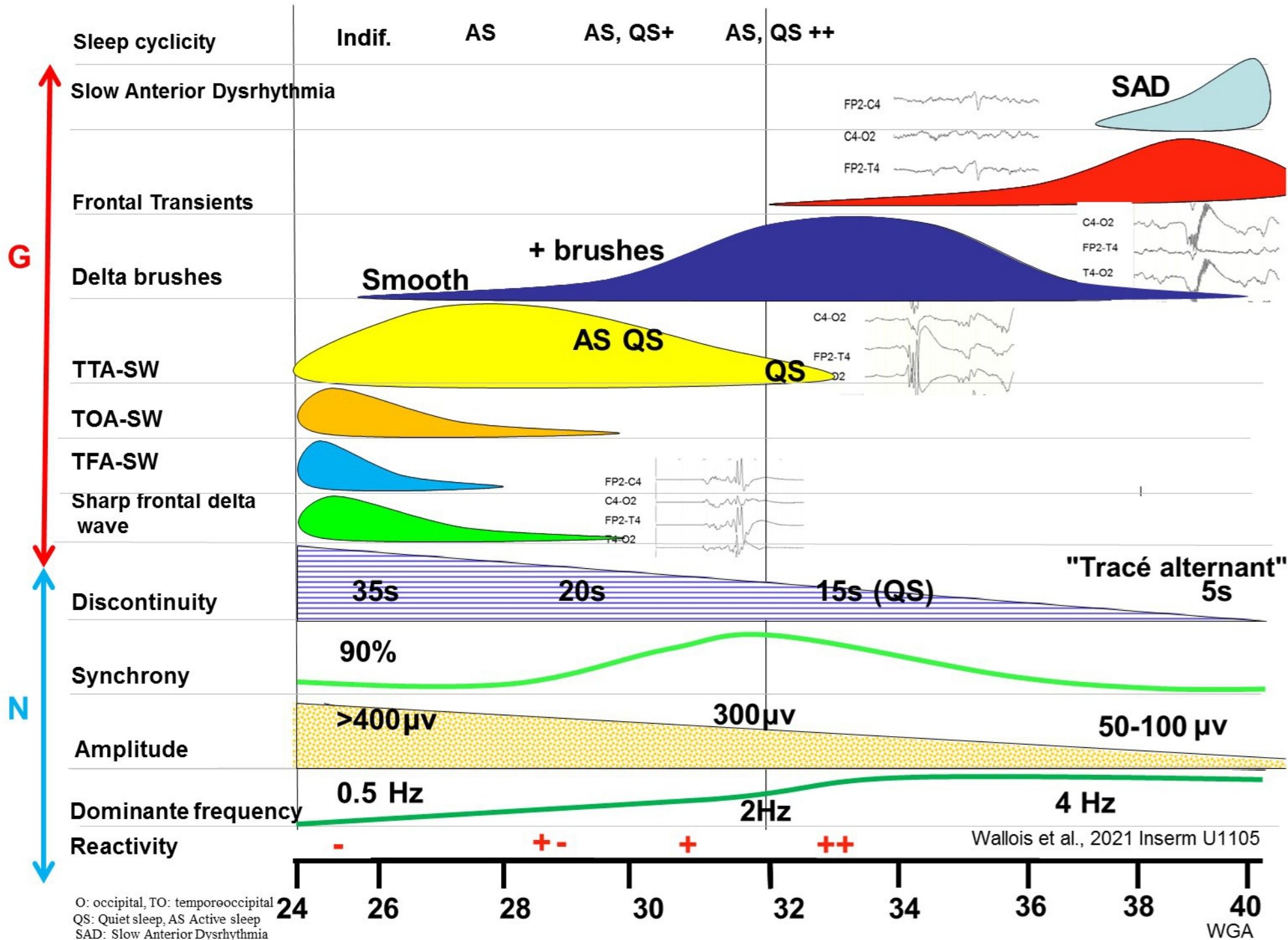
Azizollahi et al., 2016

Inverse

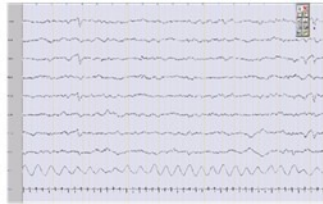
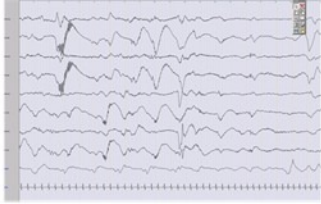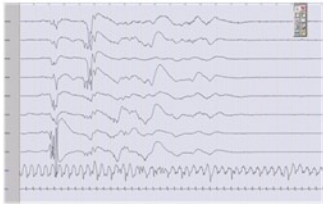


Azizollahi et al., 2020

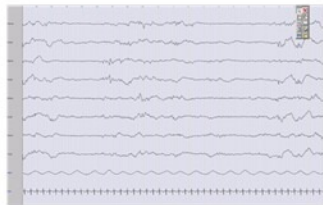
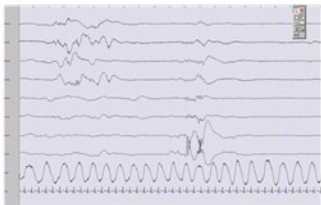
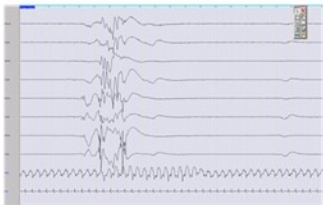




AS



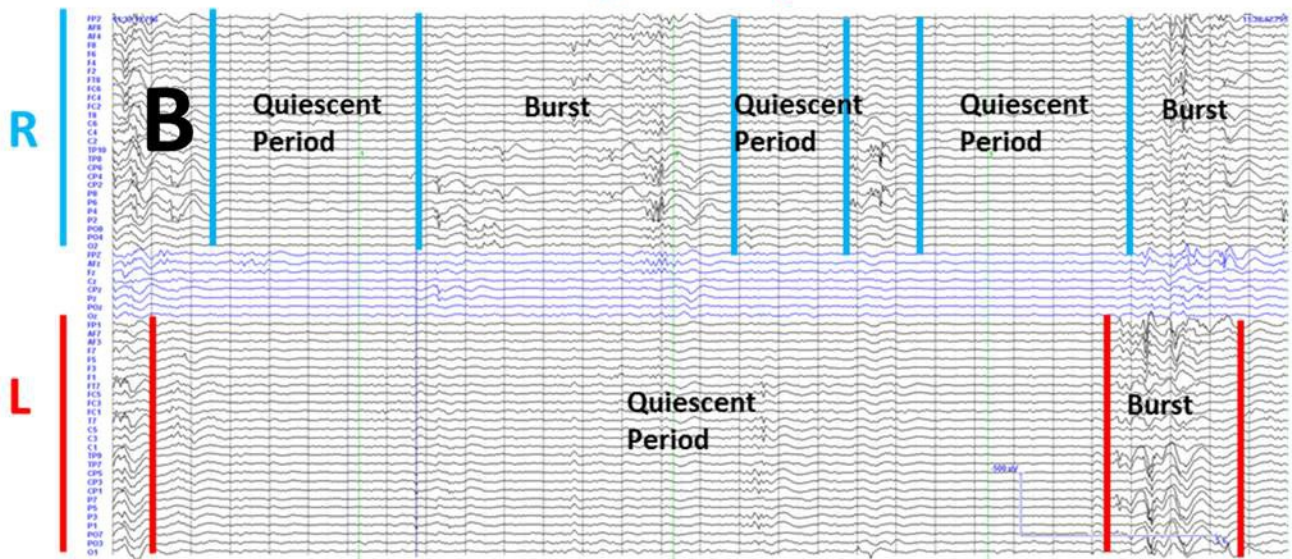
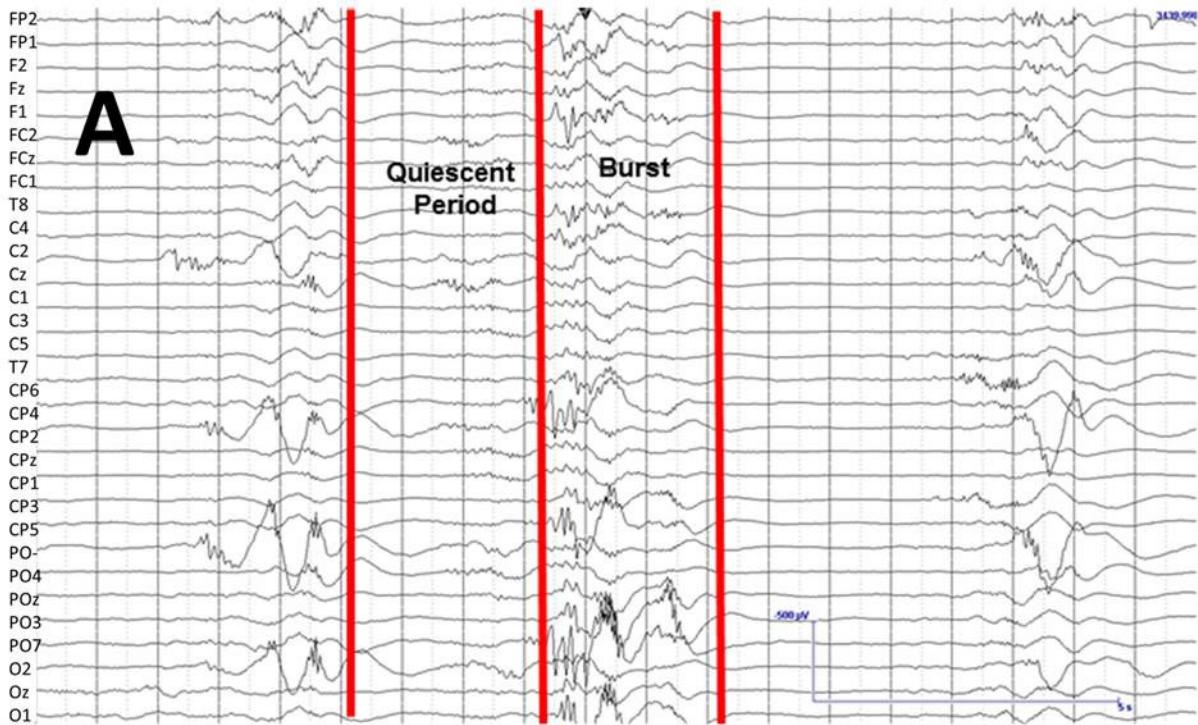
QS

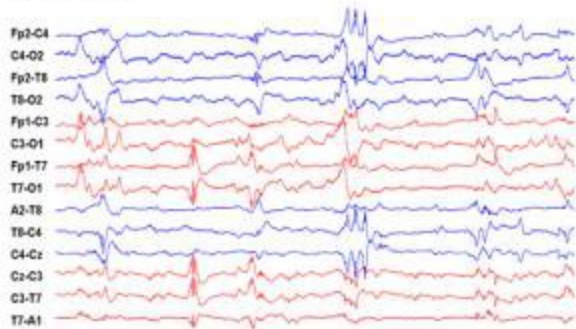
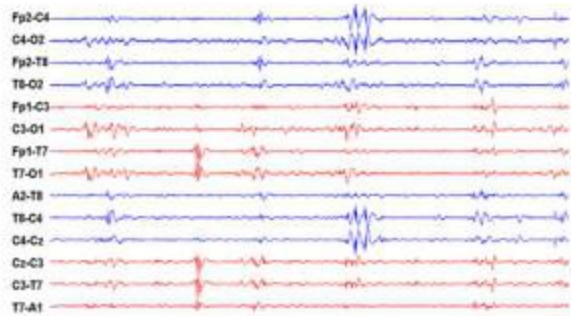


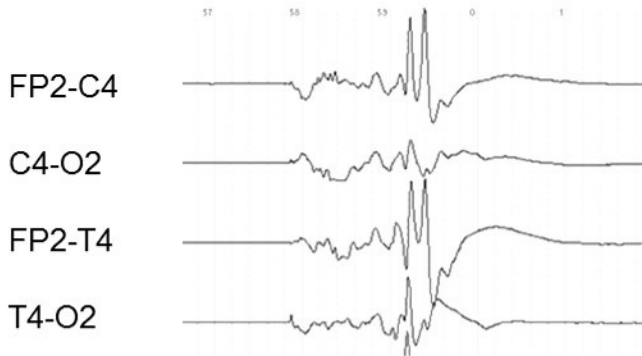
28 WGA

32 WGA

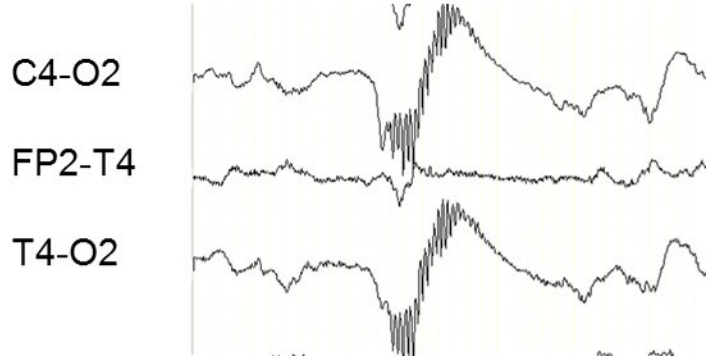
37 WGA



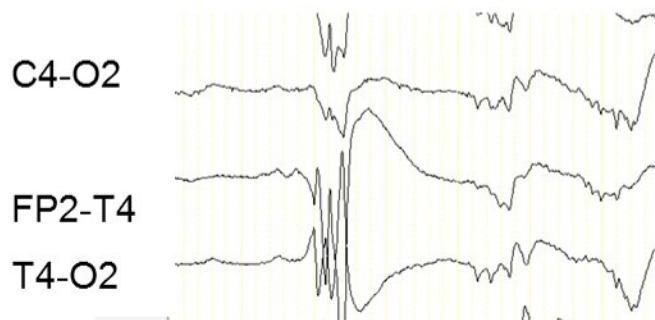
A **Full-band****Conventional, >0.5Hz**



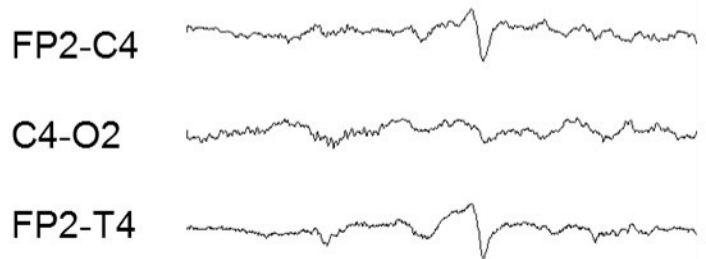
Frontal sharp waves
(25 wGA)



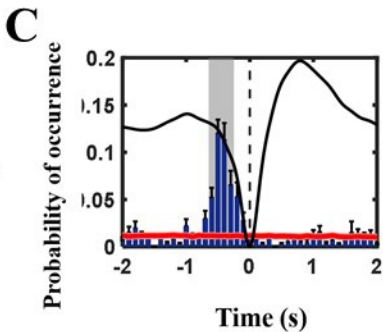
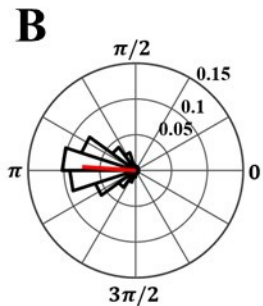
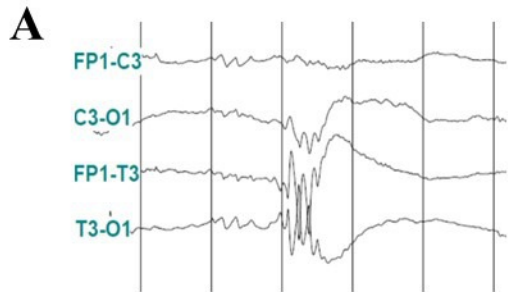
Delta brushes
(32-34 wGA)



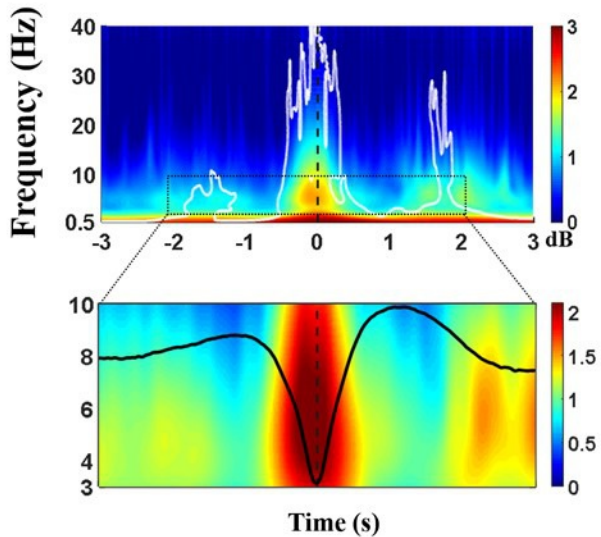
Theta Temporal and slow wave
(32-34 wGA)

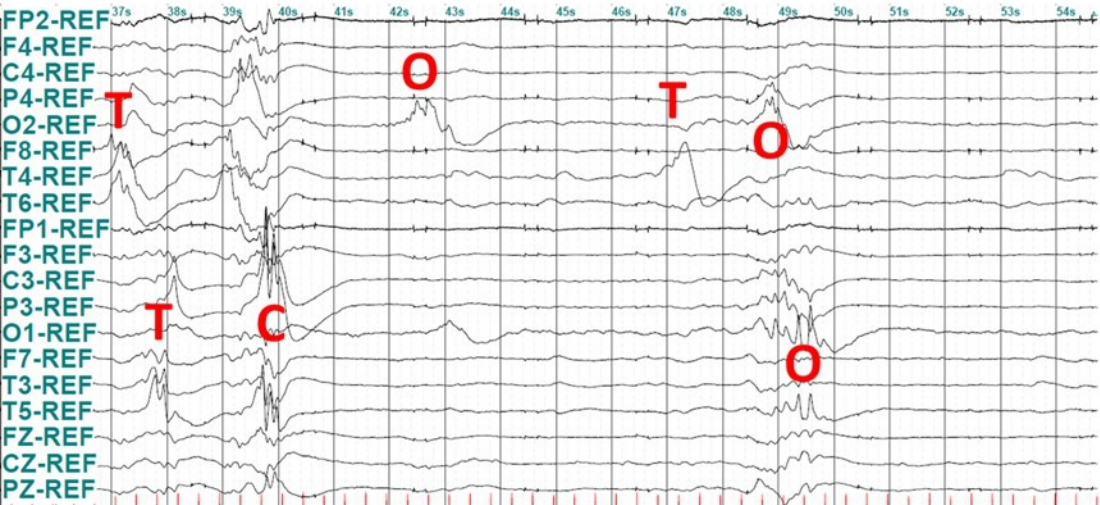
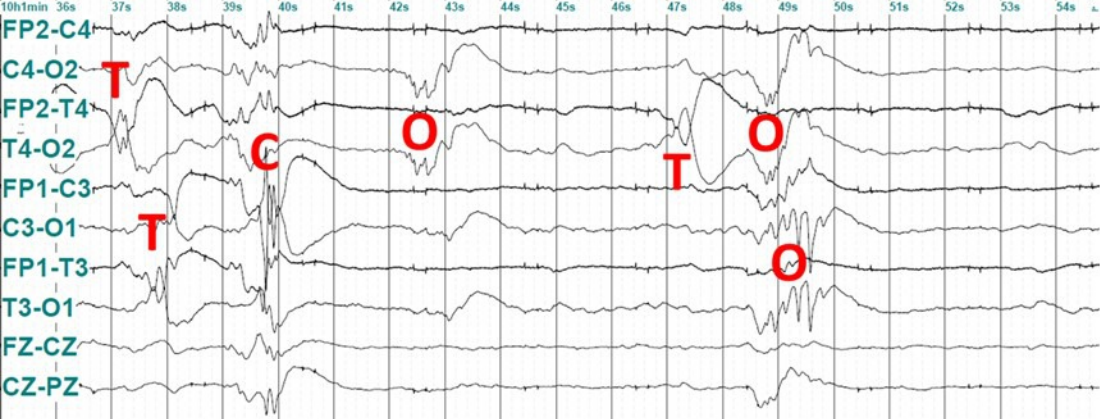


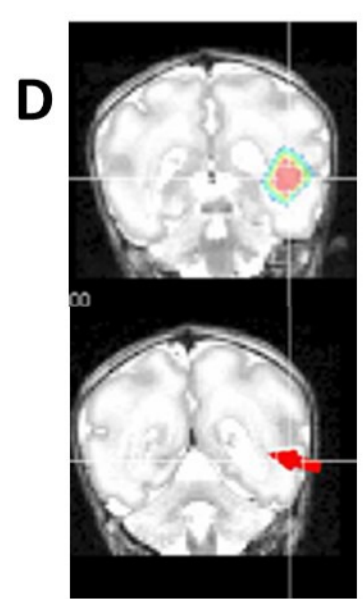
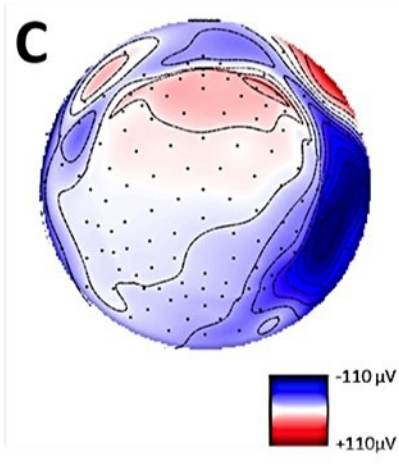
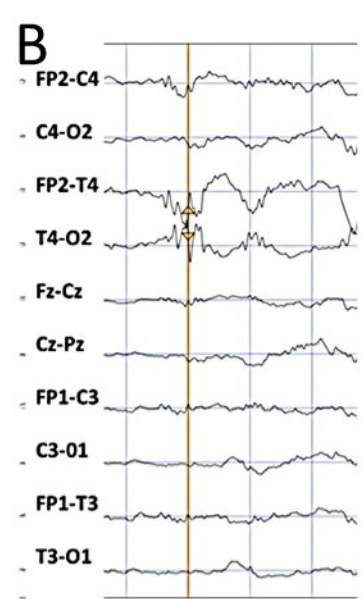
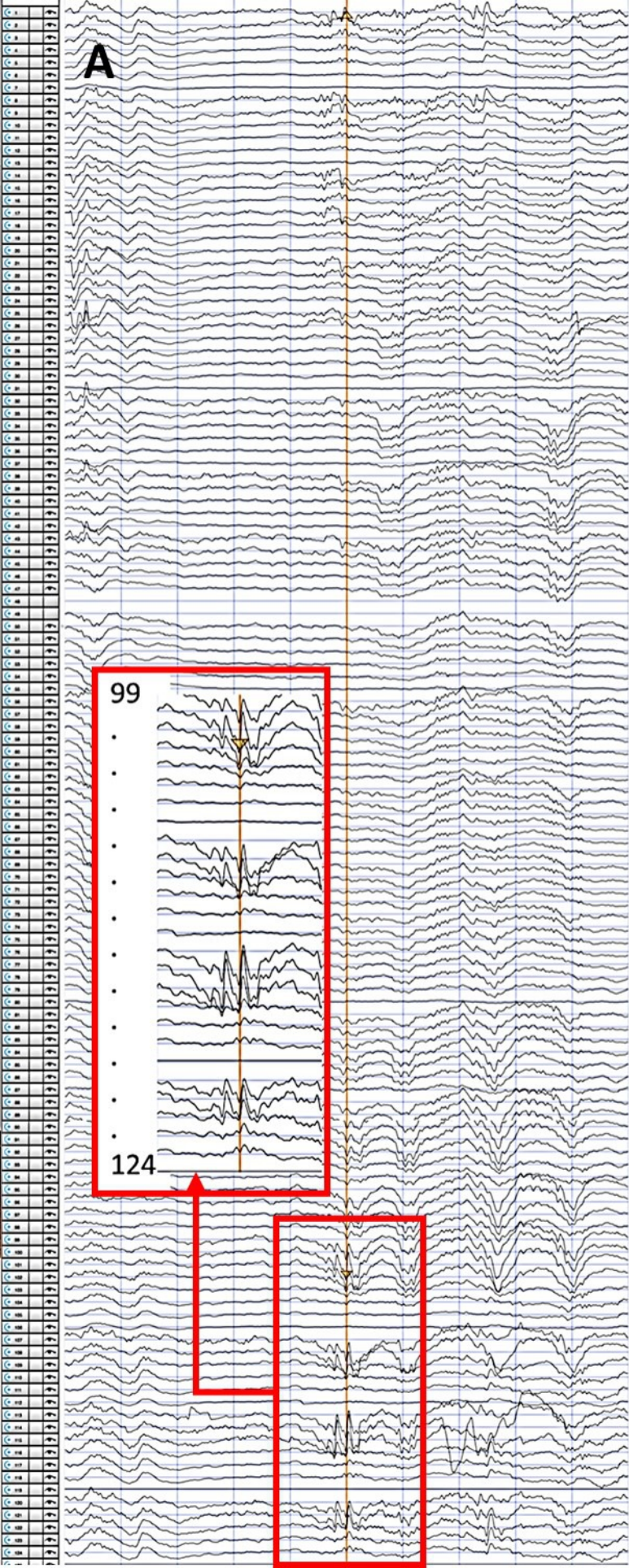
Frontal transients
(34-41 wGA)

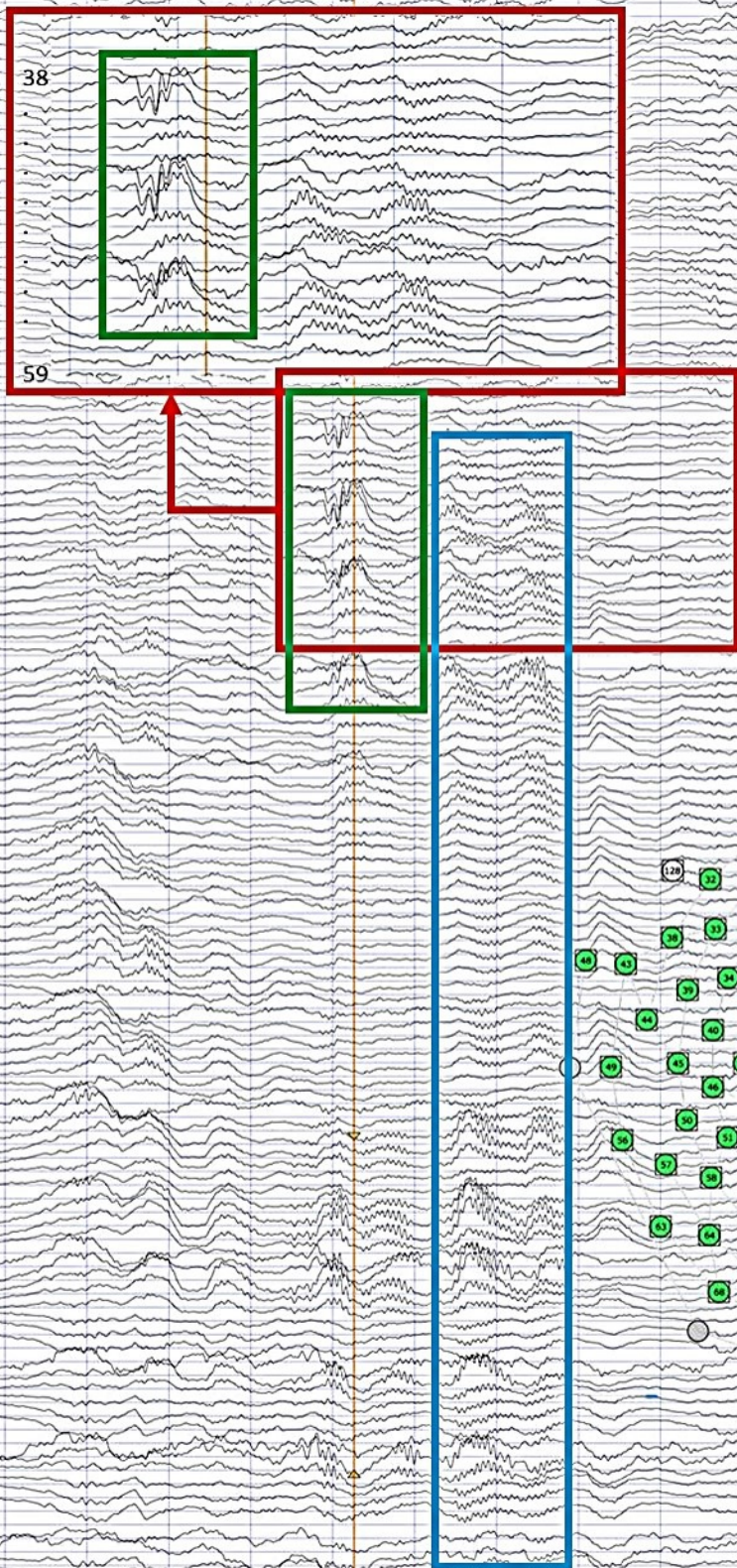
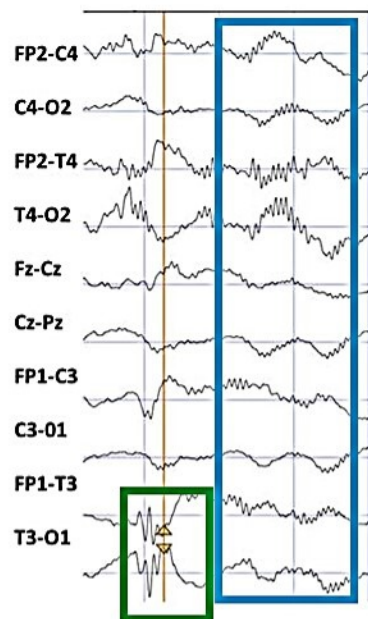
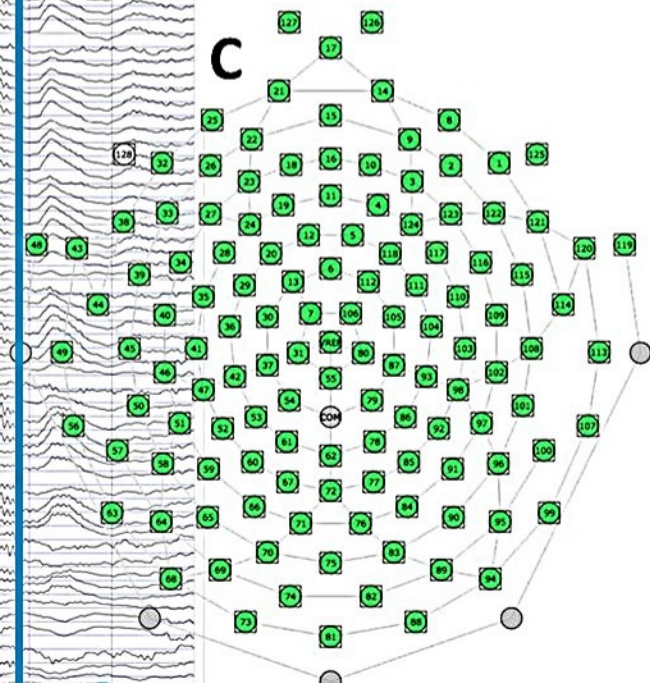


D

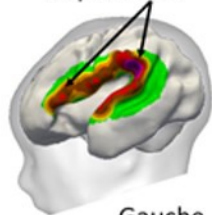




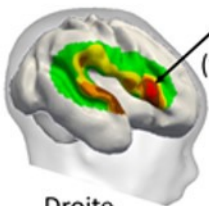


A**B****C**

Réponse au seul changement de phonème



Gauche

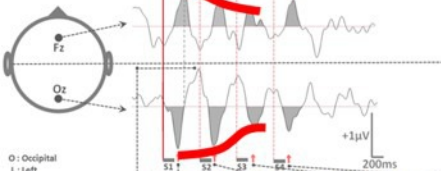


Droite

Réponse à la
Nouveauté
(voix et phonème)

Syllable	S1	S2	S3	S4
Latency to each Syllable (ms)	344	336	310	343
Latency to onset of trial (ms)	344	936	1510	2143

Topoplot of Peaks in Anterior




O: Occipital

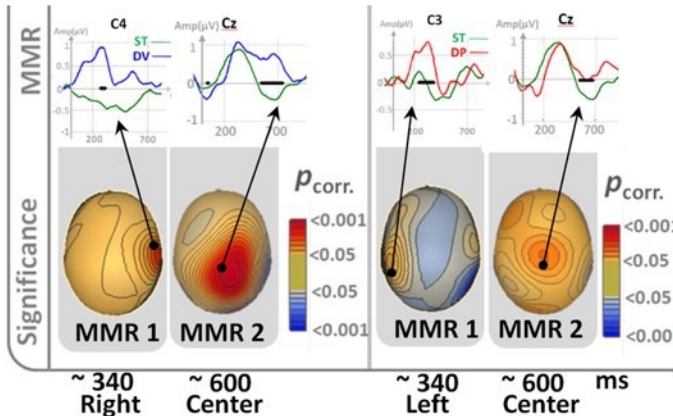
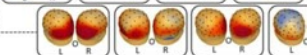
L: Left

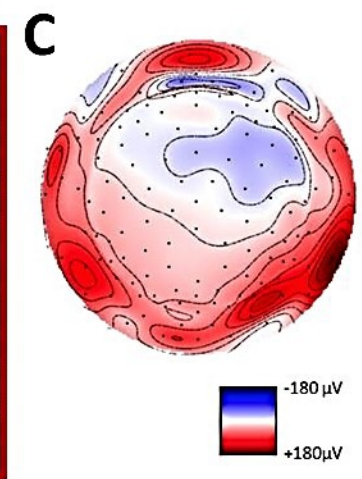
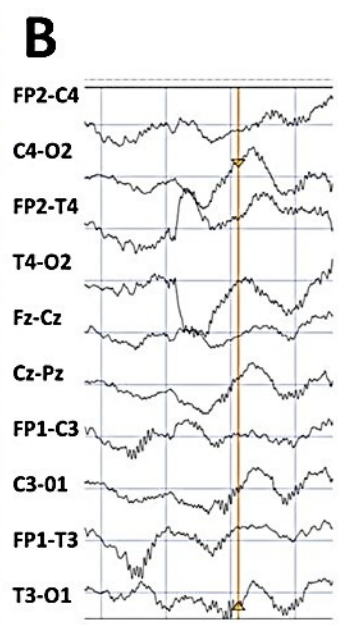
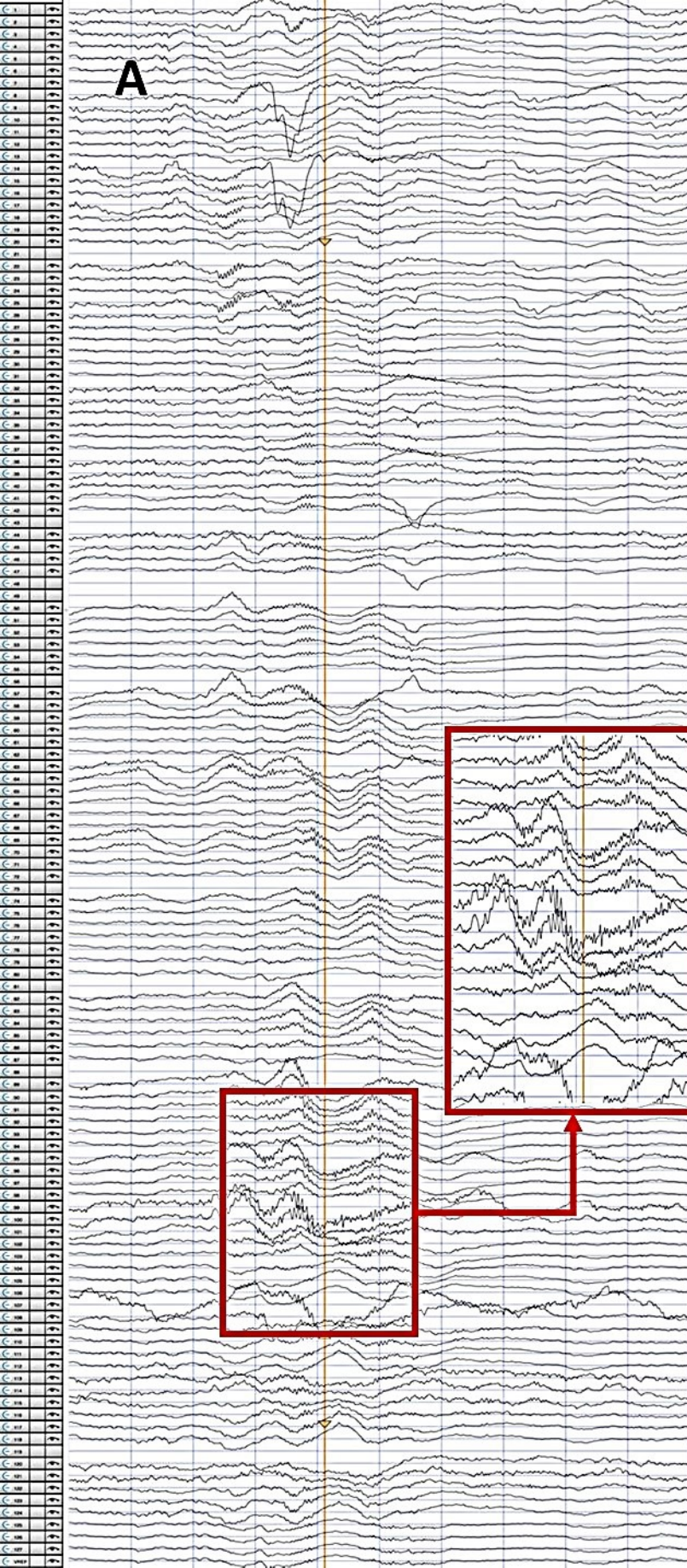R: Right

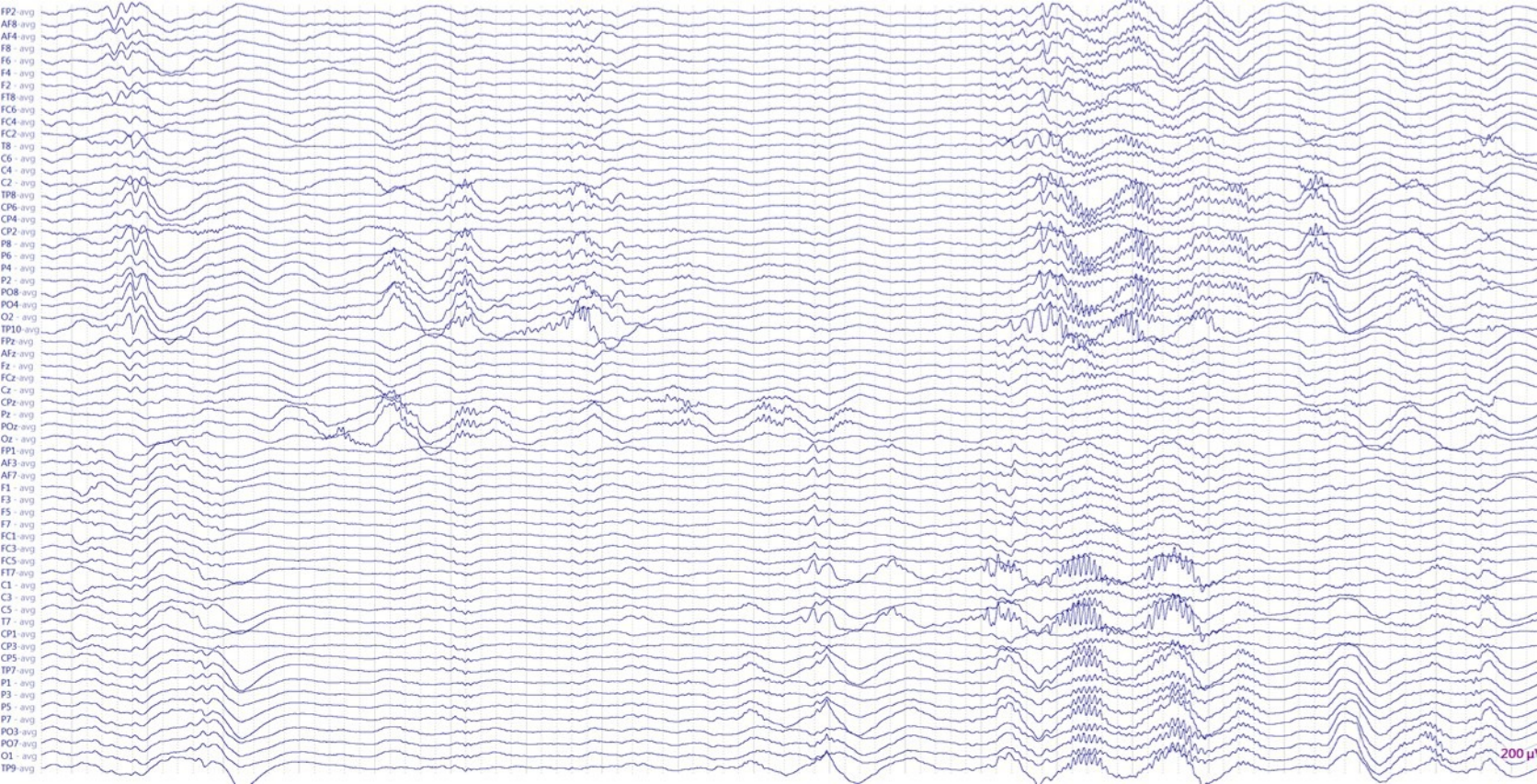
Topoplot of troughs in Posterior

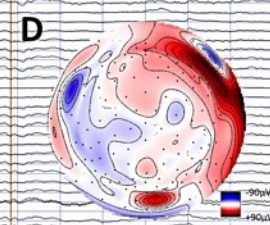
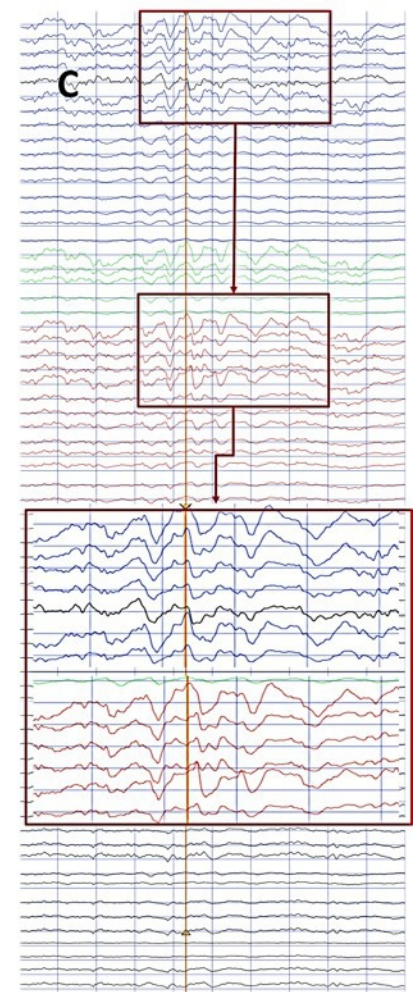
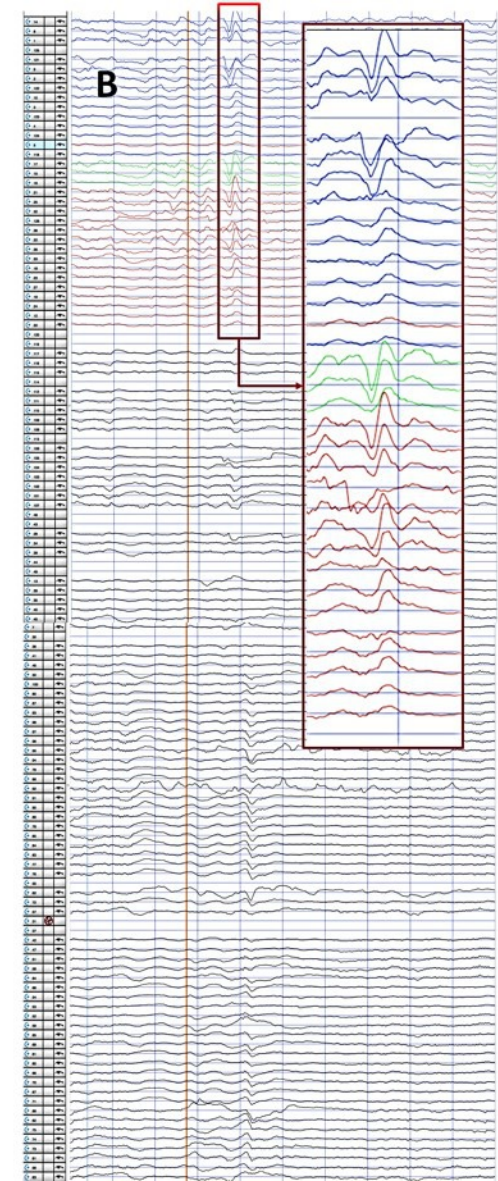
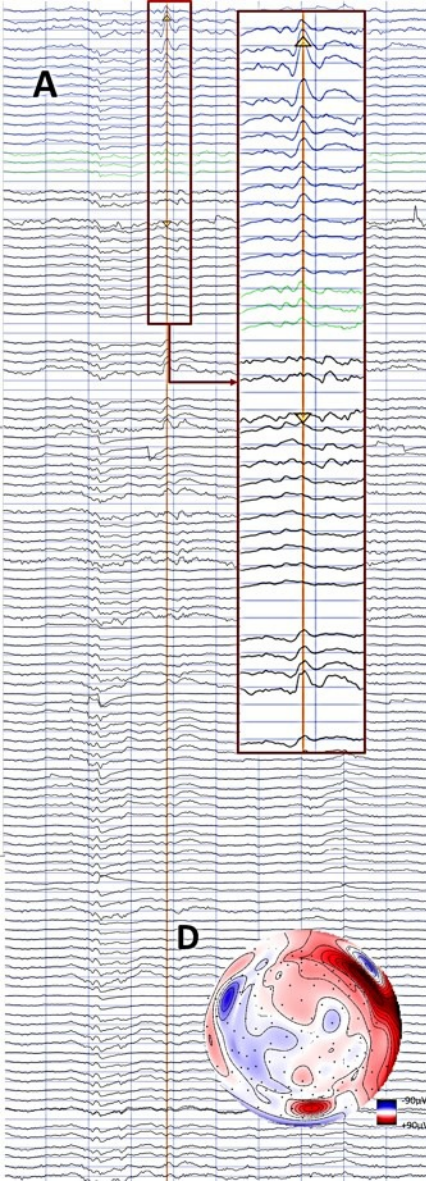


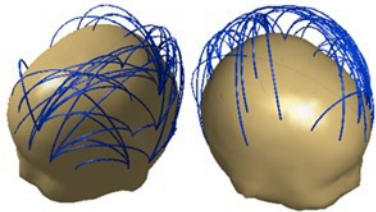
Topoplot of peaks in Posterior









a**b**