



**HAL**  
open science

## **Pressurized intraperitoneal aerosol chemotherapy (PIPAC) for unresectable peritoneal metastasis from gastric cancer**

Mohammad Alyami, Pierre-Emmanuel Bonnot, Frederic Mercier, Nathalie Laplace, Laurent Villeneuve, Guillaume Passot, Naoual Bakrin, Vahan Kepenekian, Olivier Glehen

► **To cite this version:**

Mohammad Alyami, Pierre-Emmanuel Bonnot, Frederic Mercier, Nathalie Laplace, Laurent Villeneuve, et al.. Pressurized intraperitoneal aerosol chemotherapy (PIPAC) for unresectable peritoneal metastasis from gastric cancer. *EJSO - European Journal of Surgical Oncology*, 2021, 47, pp.123 - 127. 10.1016/j.ejso.2020.05.021 . hal-03494076

**HAL Id: hal-03494076**

**<https://hal.science/hal-03494076v1>**

Submitted on 2 Jan 2023

**HAL** is a multi-disciplinary open access archive for the deposit and dissemination of scientific research documents, whether they are published or not. The documents may come from teaching and research institutions in France or abroad, or from public or private research centers.

L'archive ouverte pluridisciplinaire **HAL**, est destinée au dépôt et à la diffusion de documents scientifiques de niveau recherche, publiés ou non, émanant des établissements d'enseignement et de recherche français ou étrangers, des laboratoires publics ou privés.



Distributed under a Creative Commons Attribution - NonCommercial 4.0 International License

**Pressurized intraperitoneal aerosol chemotherapy (PIPAC) for unresectable peritoneal metastasis from gastric cancer.**

Mohammad Alyami, MD<sup>1,2,3</sup>, Pierre-Emmanuel Bonnot MD<sup>1,2</sup> , Frederic Mercier MD, MSc<sup>1,4</sup>, Nathalie Laplace MD<sup>1,2</sup> , Laurent Villeneuve, PhD<sup>1,2</sup>, Guillaume Passot MD, PhD<sup>1,2</sup> , Naoual Bakrin, MD, PhD<sup>1,2</sup>, Vahan Kepenekian, MD<sup>1,2</sup> ,Olivier Glehen, MD, PhD<sup>1,2</sup> ,

Department of General surgery & Surgical Oncology, Centre Hospitalier Lyon-Sud, Hospices Civils de Lyon, Pierre-Bénite, France<sup>1</sup>.

EMR 3738, Lyon 1 University, Lyon, France<sup>2</sup>.

Department of General surgery and Surgical oncology, oncology Center, King Khalid Hospital, Najran , Saudi Arabia<sup>3</sup>

Department of Surgical Oncology, Centre Hospitalo-Universitaire de Montreal, Montreal, Canada<sup>4</sup>

**Disclosure:** The authors report no conflicts of interest relevant to this article.

**Corresponding author:**

Mohammad ALYAMI, MD.

Department of General surgery and Surgical oncology,

Oncology Center, King Khalid Hospital,

Najran , Saudi Arabia

E-mail: swar\_ms@hotmail.com

Tel: +966 55 44 55 975

**Running Head:** PIPAC for gastric peritoneal metastasis

**Word count:** manuscript: 1917; abstract 250

**Key words:** Peritoneal carcinomatosis, unresectable PM, PIPAC, CRS, HIPEC

**Synopsis:**

PIPAC is a relatively new method of intraperitoneal chemotherapy treatment in palliative set up, for unresectable peritoneal metastasis from gastric cancer. Survival data are encouraging and justify further clinical studies in this indication.

**Abstract:**

**Background:** PIPAC is a recent approach with promising results for patients with peritoneal metastasis (PM). We aimed to evaluate survival and postoperative outcome of patients with unresectable PM from gastric origin treated with chemotherapy and PIPAC.

**Methods:** A retrospective analysis of a prospective maintained PIPAC database was queried for all patients diagnosed with unresectable PM from gastric cancer who underwent PIPAC before 2018. PIPAC with Cisplatin 7.5 mg/m<sup>2</sup> and doxorubicin 1.5 mg/m<sup>2</sup> were given for 30 min at 6-week intervals. Outcome criteria were overall survival and adverse events according to (CTCAE) version 4.0.

**Results:** One hundred Sixty-three PIPAC were done in 42 consecutive patients. Twenty-two (52%) of the patients were female. Signet-ring cells were observed in 33/42 patients (78.6%). At the first PIPAC, median age was 51.5 years (32-74). Median PCI was 17 (1-39). Twenty (47.6%) patients underwent more than 2 lines of pre-PIPAC chemotherapy. All patients had systemic chemotherapy alternating with PIPAC. Median consecutive PIPAC procedures were 3 (1-12). Overall and major complications (CTCAE - III, IV) occurred in 10 (6.1%) and 5 procedures (3.1%), respectively. Two patients (4.7%) died within 30 days of a PIPAC procedure, one related to small bowel obstruction and a pulmonary embolism for the other. Overall Survival was 19.1 months. Six (14.3%) patients became resectable during treatment and underwent curative intent CRS and HIPEC.

**Conclusions:** PIPAC with low-dose cisplatin and doxorubicin is safe and feasible in association with systemic chemotherapy for gastric PM. Survival data are encouraging and justify further clinical studies in this indication.

## **Introduction :**

Peritoneal metastasis (PM) is a common evolution of abdominal cancers, especially gastric cancer (1). This metastatic spread within the abdominal cavity is frequent, concerning approximately 15 % of patients with gastric cancer at diagnosis(2). Worldwide, gastric cancer is the fifth most common cancer, and is usually associated with a poor prognosis in the absence of aggressive multimodal therapeutic approaches particularly, in the presence of signet-ring cell histology. (3, 4)

In a recent study, FLOT4 (5-fluorouracil, leucovorin, oxaliplatin and taxol) based perioperative chemotherapy became a new standard achieving 50 months overall survival. The MAGIC study previously reported less than 30 months of overall survival with ECF (epirubicine, cisplatin and 5-fluorouracil) for locally advanced disease(5). On the other hand, the overall survival is still limited for patients with PM and does not exceed 10.7 months with the best systemic chemotherapy(6).

Currently, several potentially effective treatments for patients with isolated PM from gastric cancer are under development. The first one is complete cytoreductive surgery (CRS) combined with Hyperthermic IntraPeritoneal Chemotherapy (HIPEC) for patients with limited and resectable disease. This strategy showed good result as published by a French group (FREGAT and BIG-RENAPE) recently (7). However, this approach is recommended only in limited PM with Peritoneal Cancer Index (PCI) lower than 6 (7, 8). Secondly, intraperitoneal chemotherapy has been proposed as an alternative approach for these patients, improving tissue concentrations and limiting systemic toxicity in the neoadjuvant setting(9). Thirdly, pressurized intraperitoneal

aerosol chemotherapy (PIPAC) has been proposed as an alternative method of intraperitoneal drug delivery in certain situations, claiming improved distribution, enhanced tissue uptake, better tolerance and repeatability using minimally invasive access(10, 11). PIPAC preliminary results in gastric PM are promising with overall survival estimated up to 15.4 months (12). In a recent systemic review, PIPAC is considered a safe and promising treatment alternative for patients with advanced isolated refractory peritoneal disease(13). Furthermore, PIPAC techniques are homogeneous throughout expert centers(14)

We aimed to evaluate survival and postoperative outcome of PIPAC in patients with unresectable PM from gastric cancer.

## **METHODS**

### **Study design**

A retrospective analysis from a prospectively maintained single institution PM database was conducted to identify all patients who underwent PIPAC for unresectable PM from gastric cancer that were diagnosed before 2018. The study was performed in accordance with the precepts established by the Declaration of Helsinki.

### **Patient selection**

Every case was discussed at the multidisciplinary tumor board and the PIPAC indication was decided on an individual basis. The PIPAC approach was only considered in patients with unresectable PM with an Eastern Cooperative Oncology Group (ECOG) performance status  $<2$ . Patients with intestinal obstruction, extra-peritoneal disease, or a history of allergic reactions to platinum compounds(15) or doxorubicin were not considered. For those patients, the following data were recorded: gender, age at the time of first PIPAC procedure, history of chemotherapy regimen before PIPAC, extent of PM determined by the Peritoneal Cancer Index (PCI) (16) through peritoneal malignancy Stage Evaluation (PROMISE) application (17), ascites volume, delay between PIPAC and systemic chemotherapy, length of hospital stay, morbidity and mortality. Adverse events were assessed according to the Common Terminology Criteria for Adverse Events (CTCAE) version 4.0(18). The treatment schedule proposed repeating 2 systemic chemotherapy treatments followed by 1 PIPAC procedure.



## **PIPAC surgical technique**

Under general anesthesia, a balloon trocar (Applied Medical, Paris, France) was placed in the midline, in accordance with the open laparoscopic technique, and a capnoperitoneum of 12 mmHg at 37°C was applied. Another balloon trocar was placed in the midline under visualization. Explorative laparoscopy was performed, and the PCI was determined. Parietal biopsies were performed; ascites was aspirated, quantified and sent for peritoneal cytology. A nebulizer CAPNOPEN® (Reger Medizintechnik, GmbH, Villingendorf, Germany) was then connected to a high-pressure injector and inserted into the abdomen through a trocar. The safety protocol with checklist containing all safety aspects, as described previously (10, 19, 20), was systematically double-checked before administration of cytotoxic. A pressurized aerosol containing chemotherapy agents was then applied. The chemotherapies administrated were cisplatin (7.5 mg/m<sup>2</sup> of body surface in 150 ml NaCl 0.9%) immediately followed by doxorubicin (1.5 mg/m<sup>2</sup> in 50 ml NaCl 0.9%). The system was then kept in steady state for 30 minutes (application time). Remaining toxic aerosol was exhausted in a closed surgical smoke evacuation system. Trocars were removed and anti-adhesive gel was applied. The goal was to repeat PIPAC every 6 to 8 weeks for at least three procedures, and the delay of the systemic chemotherapy is 2 weeks before and after each PIPAC procedure. If PM was considered to become resectable during PIPAC, patients were discussed at the multidisciplinary tumor board for curative intent CRS and HIPEC

## **Statistical analysis**

Descriptive results were presented as a number (percentage) for qualitative variables and as a mean  $\pm$  standard deviation (SD) or median (minimum-maximum) for quantitative variables. Estimates of survival were calculated using the Kaplan-Meier method.

## Results:

One hundred sixty-three PIPAC procedures were done in 42 consecutive patients. Twenty-two patients were female (52%), median BMI was 21.3 (13.6-32). At the time of the first PIPAC, median age was 51.5 years (32-74). Most of the patients presented with synchronous PM 32 (76.2%) and a majority of the primary tumor were classified as signet-ring cell histology (33/42, 78.6%). Median PCI was 17 (1-39). Eight patients presented with ascites, with a median volume was 1 liter (0.5 - 4 L). Twenty (47.6%) patients underwent more than 2 lines of prePIPAC chemotherapy. All patients had systemic chemotherapy alternating with PIPAC. Median consecutive PIPAC procedures were 3 (1-12). Thirty four (80.1%), 30 (71.4%), 13 (31.9%), 13 (31.9%), 11 (26.2%) , 6 (14.3%) , 5 (11.9%) , 3 ( 7.1%) , 2 (4.8%) patients underwent a second, third, fourth, fifth, sixth , seventh , eighth , ninth and twelfth PIPAC, respectively (Table1).

Median hospital stay for each PIPAC procedure was 3 days (2-56). The median delay for restarting chemotherapy after PIPAC was 14 days (4-28). Four (50%) patients presented with the complete disappearance of ascites after 3rd PIPAC. Overall and major complications (CTCAE - III, IV) at 30 days are detailed in Table 2 and occurred in 10 (6.1%) and 5 (3.1%) procedures, respectively. Five patients (3.1%) experienced abdominal pain (CTCAE- I, II). Among patients with major complication, complications were as follow; ascites drainage (1 patient), intestinal obstruction (1 patient), allergy to chemotherapy (2 patients) and pulmonary embolism (1 patient). Two patients (4.7%) died within 30 days of a PIPAC procedure, one related to small bowel obstruction and the other from a pulmonary embolism. Overall Survival was 19.1 months

(survival curves are represented in figure 1). Six (14.3%) patients became resectable after a median of 3 PIPAC (1–6) and underwent curative intent cytoreductive surgery and HIPEC. Their initial PCI was 13 (1–17) and the PCI at the time of CRS and HIPEC was 3 (1-12). Among the 6 patients who underwent CRS and HIPEC, 3 patients are alive and disease-free.

## **DISCUSSION :**

Our study suggests that following appropriate patient selection, PIPAC with low-dose Cisplatin and doxorubicin is feasible with very low risk of major morbidity. Furthermore, PIPAC in addition to IV chemotherapy seems to provide better outcomes than those previously reported with exclusive systemic chemotherapy. CRS and HIPEC could be possible for selected patients after PIPAC with good response.

PM is a common occurrence in intra-abdominal cancers especially for gastric cancer (2) and is associated with a dismal prognosis in the absence of an aggressive therapeutic approach.(1) PM remains an unsolved challenge in modern oncology, and patients with PM have been barely included in randomized trials (21). For unresectable PM, systemic chemotherapy remains the standard of care. However, efficacy is limited due to a weak penetration of agents into the peritoneum (low blood flow, interstitial fibrosis, plasma-peritoneal barrier) with consecutive relative chemoresistance and non-negligible toxicity(22, 23). Standard intraperitoneal chemotherapy by lavage still has important pharmacokinetic limitations, such as unequal distribution, poor tissue penetration, and the highly invasive administration of repeated HIPEC for those patients with unresectable disease. Thus, 20 years ago the PIPAC was introduced to overcome these limitations by improving the penetration of chemotherapy into the tumor nodules and a more uniform distribution inside the abdominal cavity by a simple minimal invasive procedure (24-27). Ten years after its implementation in the clinical setting, multiple studies (12, 28-30) demonstrate the feasibility, safety, and tolerance

of repeated PIPAC treatment for patients with unresectable gastric PM. Our study confirms the previous findings of this innovative technology .

In our study, 10 complications (6.1%) and 5 major complications (3.1%) were documented. Two patients over 42 (4.7% mortality rate) died within 30 days of the PIPAC procedure. In the current literature, a recent systemic review published by our group (13) found that major adverse events (CTCAE >2) occurred after 12-15% of procedures. Whereas the mortality rate was 2.7%. We believe that PIPAC is associated with a certain risk of postoperative complications even in teams that are highly experienced in PM management. Therefore, it is important to undertake formal training. Adherence to the standardized procedure and established safety protocol could decrease complication to the lowest possible level. Patient selection is of utmost importance. In the setting of malignant pleural effusion, extra peritoneal metastases or bowel obstructions, or when the general condition deteriorates beyond ECOG PS 2, PIPAC should be avoided since it has probably no clinical benefit (12, 13). Finally, in our study, all patients had systemic chemotherapy alternating with PIPAC. They were restarted on systemic chemotherapy after PIPAC within a median delay of 14 (4-28) days. Our treatment schedule proposing alternating systemic chemotherapy and PIPAC procedure as previously described by our group(31-34) seemed feasible and did not delayed the systemic treatment scheduled.

For gastric PM, multiple studies have estimated a survival between 8.4 to 15.4 months in patients treated by PIPAC. Clinical response (salvage and

upfront) was between 50 and 91% (12, 13, 28-30). In our study, the overall survival of 19.1 months was reached. Furthermore, six patients (14.3%) became eligible for a curative intent CRS and HIPEC, supporting the fact that this approach could be used as neoadjuvant treatment in patients with unresectable PM(35). Moreover, among the patients who underwent CRS and HIPEC in our study, 3 patients are alive and disease-free. This gives hope for potential curative treatment in the future in very selected patient. These preliminary results in gastric PM are promising compared to current data in patients treated with systematic chemotherapy alone, in whom the reported median survival did not exceed 10.7 months(6). However, PIPAC should only be performed within the framework of clinical studies when competing with an evidence-based therapy. Some of these questions are currently being investigated in prospective study protocol such as PIPAC EstoK 01, a randomized and multicentre phase II study of PIPAC with cisplatin and doxorubicin in gastric PM (36).

These data should be evaluated in the context of their limitations. First, this study represents a retrospective analysis of patients treated at a single institution. However, the databases analyzed are prospectively maintained and managed by trained, full time personnel using abstracted data and standardized algorithms similar to those used in the management of large, national data sets. Second, the number of patients included in this study is relatively limited. Third, there is a highly variable number of pre PIPAC chemotherapy lines and the initial status regarding chemo-sensitivity were not well defined.

**CONCLUSION:**

PIPAC with low-dose cisplatin and doxorubicin is safe and feasible even when associated with systemic chemotherapy in patients with gastric PM. Survival data are encouraging and justify further clinical studies in this indication.

**Acknowledgements**

The authors would like to thank Isabelle Bonnefoy for her help in data collection.



## References:

1. Sadeghi B, Arvieux C, Glehen O, Beaujard AC, Rivoire M, Baulieux J, et al. Peritoneal carcinomatosis from non-gynecologic malignancies: results of the EVOCAPE 1 multicentric prospective study. *Cancer*. 2000;88(2):358-63.
2. Thomassen I, van Gestel YR, van Ramshorst B, Luyer MD, Bosscha K, Nienhuijs SW, et al. Peritoneal carcinomatosis of gastric origin: a population-based study on incidence, survival and risk factors. *International journal of cancer*. 2014;134(3):622-8.
3. Ferlay J, Shin HR, Bray F, Forman D, Mathers C, Parkin DM. Estimates of worldwide burden of cancer in 2008: GLOBOCAN 2008. *International journal of cancer*. 2010;127(12):2893-917.
4. Heger U, Blank S, Wiecha C, Langer R, Weichert W, Lordick F, et al. Is preoperative chemotherapy followed by surgery the appropriate treatment for signet ring cell containing adenocarcinomas of the esophagogastric junction and stomach? *Annals of surgical oncology*. 2014;21(5):1739-48.
5. Al-Batran SE, Homann N, Pauligk C, Goetze TO, Meiler J, Kasper S, et al. Perioperative chemotherapy with fluorouracil plus leucovorin, oxaliplatin, and docetaxel versus fluorouracil or capecitabine plus cisplatin and epirubicin for locally advanced, resectable gastric or gastro-oesophageal junction adenocarcinoma (FLOT4): a randomised, phase 2/3 trial. *Lancet (London, England)*. 2019;393(10184):1948-57.
6. Al-Batran SE, Homann N, Pauligk C, Illerhaus G, Martens UM, Stoehlmacher J, et al. Effect of Neoadjuvant Chemotherapy Followed by Surgical Resection on Survival in Patients With Limited Metastatic Gastric or

Gastroesophageal Junction Cancer: The AIO-FLOT3 Trial. *JAMA Oncol.* 2017;3(9):1237-44.

7. Bonnot PE, Piessen G, Kepenekian V, Decullier E, Pocard M, Meunier B, et al. Cytoreductive Surgery With or Without Hyperthermic Intraperitoneal Chemotherapy for Gastric Cancer With Peritoneal Metastases (CYTO-CHIP study): A Propensity Score Analysis. *Journal of clinical oncology : official journal of the American Society of Clinical Oncology.* 2019;37(23):2028-40.

8. Chia CS, You B, Decullier E, Vaudoyer D, Lorimier G, Abboud K, et al. Patients with Peritoneal Carcinomatosis from Gastric Cancer Treated with Cytoreductive Surgery and Hyperthermic Intraperitoneal Chemotherapy: Is Cure a Possibility? *Annals of surgical oncology.* 2016.

9. Yonemura Y, Bandou E, Sawa T, Yoshimitsu Y, Endou Y, Sasaki T, et al. Neoadjuvant treatment of gastric cancer with peritoneal dissemination. *European Journal of Surgical Oncology (EJSO).* 2006;32(6):661-5.

10. Solass W, Giger-Pabst U, Zieren J, Reymond MA. Pressurized intraperitoneal aerosol chemotherapy (PIPAC): occupational health and safety aspects. *Annals of surgical oncology.* 2013;20(11):3504-11.

11. Solass W, Kerb R, Murdter T, Giger-Pabst U, Strumberg D, Tempfer C, et al. Intraperitoneal chemotherapy of peritoneal carcinomatosis using pressurized aerosol as an alternative to liquid solution: first evidence for efficacy. *Annals of surgical oncology.* 2014;21(2):553-9.

12. Nadiradze G, Giger-Pabst U, Zieren J, Strumberg D, Solass W, Reymond MA. Pressurized Intraperitoneal Aerosol Chemotherapy (PIPAC) with Low-Dose Cisplatin and Doxorubicin in Gastric Peritoneal Metastasis.

Journal of gastrointestinal surgery : official journal of the Society for Surgery of the Alimentary Tract. 2016;20(2):367-73.

13. Alyami M HM, Grass F, Bakrin N, Villeneuve L, Laplace N, Passot G, Glehen O, Kepenekian V. Pressurised intraperitoneal aerosol chemotherapy: rationale, evidence, and potential indications. *The Lancet Oncology*. 2019;20(7):e368-e377.

14. Nowacki M, Alyami M, Villeneuve L, Mercier F, Hubner M, Willaert W, et al. Multicenter comprehensive methodological and technical analysis of 832 pressurized intraperitoneal aerosol chemotherapy (PIPAC) interventions performed in 349 patients for peritoneal carcinomatosis treatment: An international survey study. *European journal of surgical oncology : the journal of the European Society of Surgical Oncology and the British Association of Surgical Oncology*. 2018;44(7):991-6.

15. Siebert M, Alyami M, Mercier F, Gallice C, Villeneuve L, Berard F, et al. Severe hypersensitivity reactions to platinum compounds post-pressurized intraperitoneal aerosol chemotherapy (PIPAC): first literature report. *Cancer chemotherapy and pharmacology*. 2018.

16. Jacquet P, Sugarbaker P. Clinical research methodologies in diagnosis and staging of patients with peritoneal carcinomatosis. In: Sugarbaker P, editor. *Peritoneal Carcinomatosis: Principles of Management*. Cancer Treatment and Research. 82: Springer US; 1996. p. 359-74.

17. Villeneuve L, Thivolet A, Bakrin N, Mohamed F, Isaac S, Valette PJ, et al. A new internet tool to report peritoneal malignancy extent. *Peritoneal Malignancy Stage Evaluation (PROMISE) application*. *European journal of*

surgical oncology : the journal of the European Society of Surgical Oncology and the British Association of Surgical Oncology. 2016;42(6):877-82.

18. National Cancer Institute. Cancer Therapy Evaluation Program. Common terminology criteria for adverse events v4.0 (CTCAE). Available at: [http://ctep.cancer.gov/protocolDevelopment/electronic\\_applications/ctc.htm](http://ctep.cancer.gov/protocolDevelopment/electronic_applications/ctc.htm). [accessed 10.06.13].

19. Hubner M, Grass F, Teixeira-Farinha H, Pache B, Mathevet P, Demartines N. Pressurized IntraPeritoneal Aerosol Chemotherapy - Practical aspects. European journal of surgical oncology : the journal of the European Society of Surgical Oncology and the British Association of Surgical Oncology. 2017;43(6):1102-9.

20. Cazauran JB, Alyami M, Lasseur A, Gybels I, Glehen O, Bakrin N. Pressurized Intraperitoneal Aerosol Chemotherapy (PIPAC) Procedure for Non-resectable Peritoneal Carcinomatosis (with Video). Journal of gastrointestinal surgery : official journal of the Society for Surgery of the Alimentary Tract. 2017.

21. Franko J, Shi Q, Meyers JP, Maughan TS, Adams RA, Seymour MT, et al. Prognosis of patients with peritoneal metastatic colorectal cancer given systemic therapy: an analysis of individual patient data from prospective randomised trials from the Analysis and Research in Cancers of the Digestive System (ARCAD) database. The Lancet Oncology. 2016;17(12):1709-19.

22. Minchinton AI, Tannock IF. Drug penetration in solid tumours. Nature reviews Cancer. 2006;6(8):583-92.

23. Markman M. Intraperitoneal antineoplastic drug delivery: rationale and results. The Lancet Oncology. 2003;4(5):277-83.

24. Solass W, Hetzel A, Nadiradze G, Sagynaliev E, Reymond MA. Description of a novel approach for intraperitoneal drug delivery and the related device. *Surgical endoscopy*. 2012;26(7):1849-55.
25. Khosrawipour V, Khosrawipour T, Kern AJ, Osma A, Kabakci B, Diaz-Carballo D, et al. Distribution pattern and penetration depth of doxorubicin after pressurized intraperitoneal aerosol chemotherapy (PIPAC) in a postmortem swine model. *Journal of cancer research and clinical oncology*. 2016;142(11):2275-80.
26. Grass F, Vuagniaux A, Teixeira-Farinha H, Lehmann K, Demartines N, Hubner M. Systematic review of pressurized intraperitoneal aerosol chemotherapy for the treatment of advanced peritoneal carcinomatosis. *The British journal of surgery*. 2017;104(6):669-78.
27. Tempfer C, Giger-Pabst U, Hilal Z, Dogan A, Rezniczek GA. Pressurized intraperitoneal aerosol chemotherapy (PIPAC) for peritoneal carcinomatosis: systematic review of clinical and experimental evidence with special emphasis on ovarian cancer. *Archives of gynecology and obstetrics*. 2018;298(2):243-57.
28. Khomyakov V, Ryabov A, Ivanov A, Bolotina L, Utkina A, Volchenko N, et al. Bidirectional chemotherapy in gastric cancer with peritoneal metastasis combining intravenous XELOX with intraperitoneal chemotherapy with low-dose cisplatin and Doxorubicin administered as a pressurized aerosol: an open-label, Phase-2 study (PIPAC-GA2). *Pleura and Peritoneum* 2016. p. 159.
29. Gockel I, Jansen-Winkel B, Haase L, Rhode P, Mehdorn M, Niebisch S, et al. Pressurized Intraperitoneal Aerosol Chemotherapy (PIPAC) in Gastric

Cancer Patients with Peritoneal Metastasis (PM): Results of a Single-Center Experience and Register Study. *Journal of gastric cancer*. 2018;18(4):379-91.

30. Struller F, Horvath P, Solass W, Weinreich FJ, Strumberg D, Kokkalis MK, et al. Pressurized intraperitoneal aerosol chemotherapy with low-dose cisplatin and doxorubicin (PIPAC C/D) in patients with gastric cancer and peritoneal metastasis: a phase II study. *Therapeutic advances in medical oncology*. 2019;11:1758835919846402.

31. Alyami M, Gagniere J, Sgarbura O, Cabelguenne D, Villeneuve L, Pezet D, et al. Multicentric initial experience with the use of the pressurized intraperitoneal aerosol chemotherapy (PIPAC) in the management of unresectable peritoneal carcinomatosis. *European journal of surgical oncology : the journal of the European Society of Surgical Oncology and the British Association of Surgical Oncology*. 2017;43(11):2178-83.

32. Larbre V, Alyami M, Mercier F, Vantard N, Bonnefoy I, Opsomer MA, et al. No Renal Toxicity After Repeated Treatment with Pressurized Intraperitoneal Aerosol Chemotherapy (PIPAC) in Patients with Unresectable Peritoneal Metastasis. *Anticancer research*. 2018;38(12):6869-75.

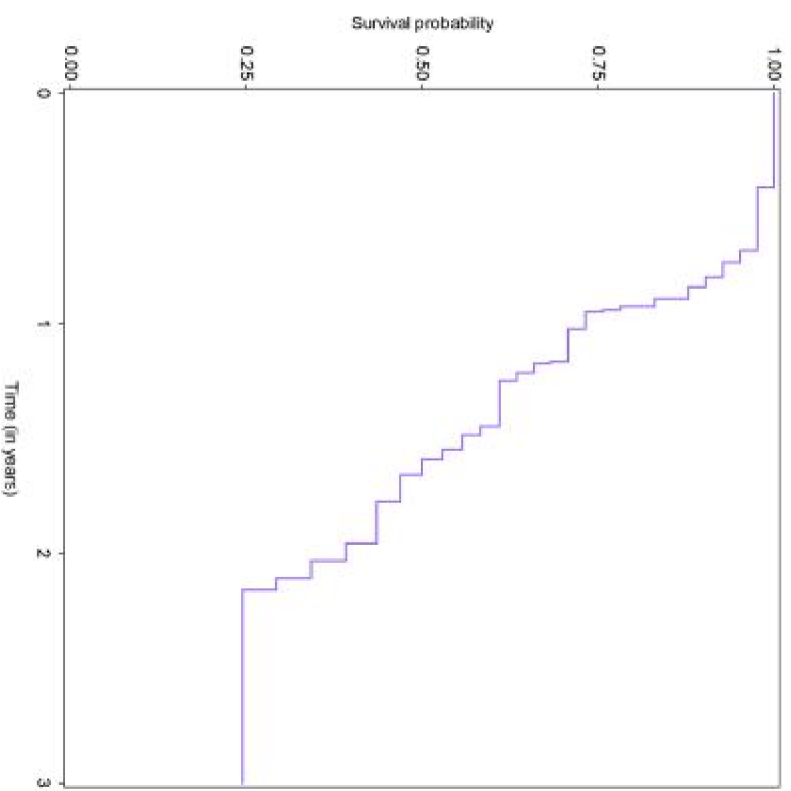
33. Siebert M, Alyami M, Mercier F, Gallice C, Villeneuve L, Laplace N, et al. Pressurized intraperitoneal aerosol chemotherapy (PIPAC) in association with systemic chemotherapy and bevacizumab, evaluation of safety and feasibility. A single center comparative study. *European journal of surgical oncology : the journal of the European Society of Surgical Oncology and the British Association of Surgical Oncology*. 2019.

34. Sgarbura O, Hubner M, Alyami M, Eveno C, Gagniere J, Pache B, et al. Oxaliplatin use in pressurized intraperitoneal aerosol chemotherapy

(PIPAC) is safe and effective: A multicenter study. *European journal of surgical oncology : the journal of the European Society of Surgical Oncology and the British Association of Surgical Oncology*. 2019;45(12):2386-91.

35. Alyami M, Mercier F, Siebert M, Bonnot PE, Laplace N, Villeneuve L, et al. Unresectable peritoneal metastasis treated by pressurized intraperitoneal aerosol chemotherapy (PIPAC) leading to cytoreductive surgery and hyperthermic intraperitoneal chemotherapy. *European journal of surgical oncology : the journal of the European Society of Surgical Oncology and the British Association of Surgical Oncology*. 2019.

36. Eveno C, Jouvin I, Pocard M. PIPAC EstoK 01: Pressurized IntraPeritoneal Aerosol Chemotherapy with cisplatin and doxorubicin (PIPAC C/D) in gastric peritoneal metastasis: a randomized and multicenter phase II study. *Pleura and Peritoneum*2018.



**Figure 1:** Overall survival of 42 consecutive patients treated with pressurized intraperitoneal aerosol chemotherapy (PIPAC) with low dose cisplatin and doxorubicin combined with systemic chemotherapy.



Table 1: Clinicopathological data for patients treated with PIPAC <sup>a</sup>.

Variable	Value N	Percentage
Number of patients	42	
Sex (M:F)	20:22	47.6:52.4
Age, median years (range)	51.5 (32.3-74.7)	
BMI, median	21.3 (13.6-32)	
Synchronous Pm	32	76.2
Metachronous PM	10	23.8
Signet ring histology	33	78.5
Preoperative Chemotherapy		
1 line	42	100
2 lines	20	47.6
3 lines	5	11.9
Median number of cycle (range)	8 (0-57)	
Systemic chemotherapy associated with PIPAC	42	100
PCI median at time of first PIPAC	17 (1-39)	
Total PIPAC sessions	163	
PIPAC session / patient median (range)	3 (1-12)	

CRS and HIPEC after PIPAC

6

14.3

---

<sup>a</sup> Values in table are numbers of patients (percentages) unless otherwise indicated.

Table 2: Post-operative outcomes after PIPAC <sup>a</sup>

Variable	Value	Percentage
	N=163	
Chemotherapy regimen for PIPAC		
cisplatinium-doxorubicin	163	100
Median hospital stay (range)	3 (2-56)	
Overall complication	10	6.13
Major complications (30 days)	5	3.06
Type of major complication		
Ascites drainage	1	
Intestinal obstruction	2	
Allergy to chemotherapy	1	
Pulmonary embolism	1	
Mortality (30 days)	2	4.76
Causes of mortality		
Pulmonary embolism	1	
Intestinal obstruction	1	

<sup>a</sup> Values in table are numbers of patients (percentages) unless otherwise indicated.