



**HAL**  
open science

## Osteosarcoma of the jaws: An overview of the pathophysiological mechanisms

Hélios Bertin, A. Gomez-Brouchet, F. Rédini

### ► To cite this version:

Hélios Bertin, A. Gomez-Brouchet, F. Rédini. Osteosarcoma of the jaws: An overview of the pathophysiological mechanisms. *Critical Reviews in Oncology/Hematology*, 2020, 156, pp.103126 - . 10.1016/j.critrevonc.2020.103126 . hal-03494071v2

**HAL Id: hal-03494071**

**<https://hal.science/hal-03494071v2>**


Submitted on 8 Apr 2023

**HAL** is a multi-disciplinary open access archive for the deposit and dissemination of scientific research documents, whether they are published or not. The documents may come from teaching and research institutions in France or abroad, or from public or private research centers.

L'archive ouverte pluridisciplinaire **HAL**, est destinée au dépôt et à la diffusion de documents scientifiques de niveau recherche, publiés ou non, émanant des établissements d'enseignement et de recherche français ou étrangers, des laboratoires publics ou privés.



Distributed under a Creative Commons Attribution - NonCommercial 4.0 International License



European School of Oncology – Review

## Osteosarcoma of the jaws: An overview of the pathophysiological mechanisms

Hélios Bertin<sup>a,b,\*</sup>, A. Gomez-Brouchet<sup>c</sup>, F. Rédini<sup>b</sup><sup>a</sup> Department of Maxillofacial Surgery, Nantes University Hospital, 1 Place Alexis Ricordeau, 44093 Nantes Cedex 1, France<sup>b</sup> Bone Sarcoma and Remodeling of Calcified Tissues (PhyOs, UMR 1238), Nantes Medical School, 1 Rue Gaston Veil, 44035 Nantes Cedex, France<sup>c</sup> Department of Pathology, IUCT Oncopole, Toulouse University Hospital, 1 Avenue Irène Joliot-Curie, 31059 Toulouse Cedex 9, France

## ARTICLE INFO

## Keywords:

Osteosarcoma  
Mandible  
Tumour environment  
Immunity  
Molecular biology  
Vascularization

## ABSTRACT

Osteosarcoma (OS) is the most common cancer of bone. Jaw osteosarcoma (JOS) is rare and it differs from long-bone OS (LBOS) in terms of the time of onset (two decades later), lower metastatic spread, and better survival. OS is characterized by the proliferation of osteoblastic precursor cells and the production of osteoid or immature bone. OS arises from a combination of genetic aberrations and a favourable microenvironment. This local microenvironment includes bone cells, blood vessels, stromal cells, and immune infiltrates, all of which may constitute potential targets for anti-cancer drugs. Differences in the clinical and biological behaviour of JOS versus LBOS are likely to at least in part be due to differences in the microenvironment between the two sites. The present review provides a brief overview of the known pathophysiological parameters involved in JOS.

## 1. Introduction

Osteosarcomas (OS) is the most common cancer of bone, accounting for 40–60 % of all primary bone tumours (Lacour et al., 2010; Ottaviani and Jaffe, 2009). It usually affects the metaphysis of the long bones during skeletal growth in children and adolescents (Baumhoer et al., 2014). Jaw osteosarcoma (JOS) is rare, accounting for only 6% of all OS (Baumhoer et al., 2014; Boon et al., 2017; Thariat et al., 2012). It develops mainly in the mandible and it differs from long-bone osteosarcomas (LBOS) in several important ways (Baumhoer et al., 2014; Thariat et al., 2012):

- 1 JOS tends to be diagnosed approximately two decades later than LBOS (Kontio et al., 2019; Lee et al., 2015; van den Berg and Merks, 2013), at an average age of 35 years.
- 2 It entails a lower risk of lung metastases, reported to be 20–25 % (Baumhoer et al., 2014; Canadian Society of Otolaryngology-Head and Neck Surgery Oncology Study Group, 2004) for JOS versus 44 %–49 % for LBOS (Boon et al., 2017). Twenty-five percent of patients have primary metastases at the time of the diagnosis in case of LBOS, whereas metastases occur in 17–20 % of patients within two years in case of JOS (Baumhoer et al., 2014; Nissanka et al., 2007).

- 3 The overall survival rate is better for JOS, with 77 % survival at 5 years for localised disease and after complete resection (Granowski-LeCornu et al., 2011; Nissanka et al., 2007; Thariat et al., 2012).

OS is a disease of mesenchymal cell origin characterized by the proliferation of osteoblastic precursors and the production of osteoid or immature bone. According to the 2013 WHO classification, OS can be classified into high-grade, intermediate-grade, and low-grade lesions (Flechter et al., 2013). Most of JOS are high-grade lesions and include conventional OS (osteoblastic, chondroblastic, fibroblastic) and other rare variants (telangiectasic, small cell, epithelioid, giant cell-rich) depending on the amount of osteoid, cartilage, or collagen produced by the tumour (Fig. 1). The chondroblastic subtype is predominant which may be a factor for the better overall prognosis of JOS compared to LBOS (Lee et al., 2015; Thariat et al., 2012; van den Berg and Merks, 2013). The aetiology of OS remains largely unknown. There is a lack of recurrent molecular alterations, and there is often a complex karyotype (Mirabello et al., 2020; Scotlandi et al., 2020). The tumour suppressor genes p53 and RB1 are frequently altered and they appear to be involved in initiation of the disease (Miller et al., 1996; Toguchida et al., 1992; Wadayama et al., 1994). It has been well established that the bone microenvironment plays a major role in the development, progression,

\* Corresponding author at: Department of Maxillofacial Surgery, Nantes University Hospital, 1 place Alexis Ricordeau, 44093 Nantes Cedex 1, France.

E-mail addresses: [helios.bertin@chu-nantes.fr](mailto:helios.bertin@chu-nantes.fr) (H. Bertin), [brouchet.anne@chu-toulouse.fr](mailto:brouchet.anne@chu-toulouse.fr) (A. Gomez-Brouchet), [francoise.redini@univ-nantes.fr](mailto:francoise.redini@univ-nantes.fr) (F. Rédini).

<https://doi.org/10.1016/j.critrevonc.2020.103126>

Received 5 July 2020; Received in revised form 18 September 2020; Accepted 2 October 2020

Available online 10 October 2020

1040-8428/© 2020 The Author(s).

Published by Elsevier B.V. This is an open access article under the CC BY-NC-ND license

(<http://creativecommons.org/licenses/by-nc-nd/4.0/>).

and chemoresistance of OS (Alfranca et al., 2015; Bouaoud et al., 2019; Rubio et al., 2014). The local tumour environment includes bone cells, blood vessels, stromal cells, and immune infiltrates (Heymann et al., 2019). The *in vivo* interactions between the tumour cells and the host are still largely unknown (Bertin et al., 2019); however, various anti-cancer drugs have been developed to target the tumour microenvironment in OS (Brown et al., 2018). There have been very few studies to date investigating the tumour microenvironment in JOS (Bertin et al., 2019). The differences observed in the clinical and biological behaviour between JOS and LBOS are likely to be due to differences in the microenvironment between the two sites.

Despite the biological and clinical differences, and due to the lack of specific data, the treatment of JOS is extrapolated from that for LBOS, and it can vary between institutions (Bouaoud et al., 2019; Lee et al., 2015; Thariat et al., 2012). The primary treatment of JOS is radical surgical removal with clear margins (Bouaoud et al., 2019; Lee et al., 2015; Thariat et al., 2013, 2012). The margin status is considered to be the most important factor for local control and survival (Canadian Society of Otolaryngology-Head and Neck Surgery Oncology Study Group, 2004; Jasnaoui et al., 2008; Smith et al., 2003; Thariat et al., 2013, 2012). The 3-year disease-free survival rate can reach 100 % with complete resection (R0), falling to 38 % in case of incomplete removal (R1) (Bouaoud et al., 2019). With LBOS, multimodal treatment is well established and based on neoadjuvant chemotherapy (neo-CT) followed by surgical resection and adjuvant chemotherapy. The most commonly used chemotherapy drugs are high-dose methotrexate, and associations of cisplatin, ifosfamide, etoposide, and doxorubicin (Luetke et al., 2014; Patel et al., 2002). The adjuvant chemotherapy protocol is based on the histological response to the neo-CT on the resected specimen (Crenn et al., 2017). Due to a lack of specific data, the use of neo-CT is controversial in JOS (Kontio et al., 2019). Some studies indicate that there is a significant positive effect of neo-CT on disease-free and overall survival (Boon et al., 2017; Smeele et al., 1998; Thariat et al., 2013). Other studies have failed to show a beneficial effect of neo-CT on overall survival and on tumour progression in JOS patients (Baumhoer et al., 2014; Bouaoud et al., 2019; Kassir et al., 1997). While the response to chemotherapy usually reaches 38–47 % in LBOS (Piperno-Neumann et al., 2020), the rate of favourable responses drops to 27 % in JOS (Thariat et al., 2013). The use of adjuvant radiation therapy for JOS is also a matter of controversy and not well defined, with variable results on survival reported in the literature (Guadagnolo et al., 2009; Lee et al., 2015; Petrovic et al., 2019; Smeele et al., 1998). Furthermore, radiotherapy exposes to significant complications in the head and neck region, including failure of the reconstruction with free flaps,

osteoradionecrosis, trismus, and complications in dental rehabilitation (Chen et al., 2020b; Koudougou et al., 2020; Mijiti et al., 2020). However, most authors agree that adjuvant radiotherapy should be considered in case of positive margins or high-grade OS (Baumhoer et al., 2014; Thariat et al., 2012).

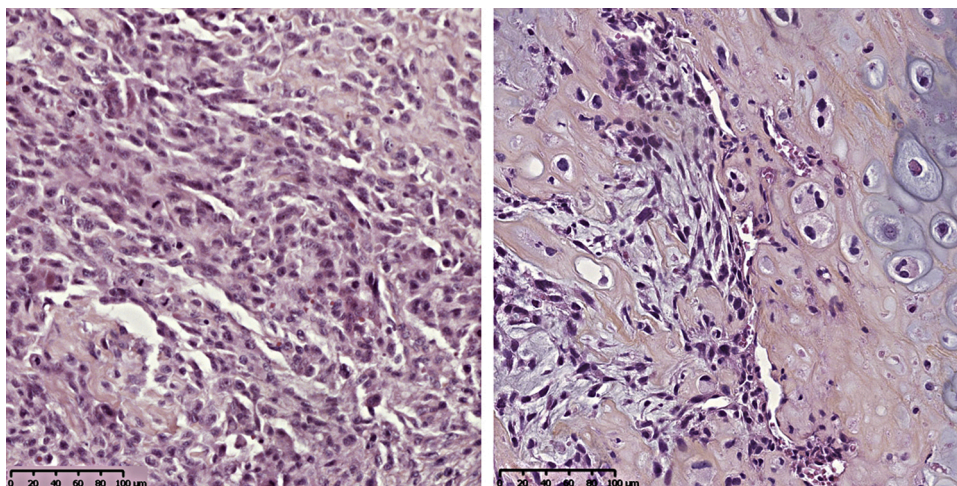
Due to the rarity of JOS, there is limited data regarding the factors that influence the prognosis or survival in patients with these tumours. Identification of predisposing factors and markers in the tumour microenvironment could allow for a better understanding of the biological and clinical differences between JOS and LBOS. Furthermore, new targeted therapies could be developed against these markers to reduce the tumour volume and to limit the need for damaging surgery. We here present an overview of the state of knowledge regarding the specific tumour microenvironment of JOS.

## 2. Embryogenesis

The embryological origin of the gnathic bones could account for many of the differences between LBOS and JOS (Baumhoer, 2017; Hameed et al., 2020). Indeed, most of the bones of the skeleton are of mesodermal origin, whereas the craniofacial skeleton originates from neural crest. During early embryogenesis, a mandibular prominence develops from the first pharyngeal arch; this arch subsequently undergoes a membranous ossification to form the mandibular bone (Baumhoer, 2017). The condyle region undergoes endochondral ossification, as in the long bones, although it does not represent a usual location for JOS development. Furthermore, the later onset of JOS in non-growing skeleton suggests that bone growth is not a major factor for JOS development (Chaudhary and Chaudhary, 2012; Granowski-LeCornu et al., 2011; Nissanka et al., 2007). Indeed, no studies to date in the literature have reported that the differential growth pattern is a key factor for the biological differences observed between JOS and LBOS.

## 3. Molecular alterations (genes and pathways)

A number of high-interest cancer-susceptibility genes have been identified in osteosarcoma (Mirabello et al., 2020). Whole-genome sequencing studies have shown that OS has exceptionally high rates of mutations and genomic alterations (Chen et al., 2014; Perry et al., 2014). Most of these alterations involve the p53 and RB1 tumour suppressor genes (80–90 % and 10–39 %, respectively), and to a lesser extent also the ATRX, DLG2, RUNX2, and PTEN genes (Bousquet et al., 2016). There have been few reports to date of the molecular alterations



**Fig. 1.** Haematoxylin-eosin staining of a JOS section. Conventional osteosarcoma features with osteoblastic tumour cells in an osteoid stroma, various nuclear atypia with a high mitotic index (left). Conventional osteosarcoma with substantial chondroblastic differentiation and nuclear atypia (right).

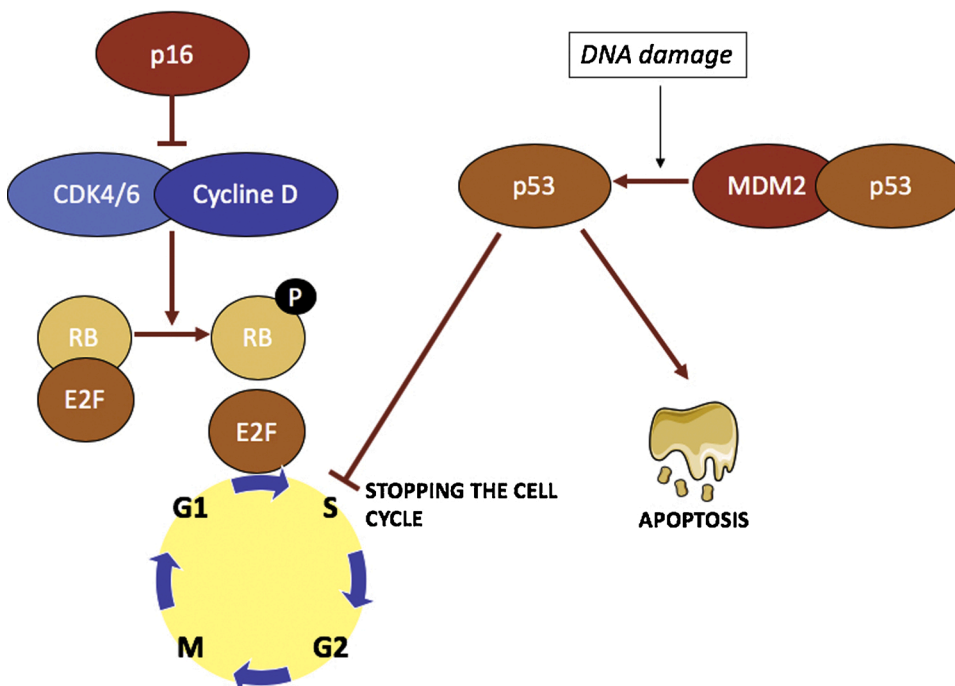
that occur in JOS. The p53 tumour suppressor gene is located on chromosome 17 and it encodes protein isoforms involved in the cell cycle, apoptosis, and genomic stability (Surget et al., 2013) (Fig. 2). TP53 mutations can be inherited or they can arise from mutations early in embryogenesis or in germ cells (Ginat et al., 2018). Immunohistochemical studies have found a high positivity for p53 in JOS samples, ranging from 46.6–88% (Junior et al., 2003; Lopes et al., 2001; Oliveira et al., 1997). In a series of 25 head and neck OS, Junior et al. found a significant correlation between p53 levels and the grade of malignancy, with 73 % positivity for high-grade tumours versus 36 % for intermediate- and low-grade JOS (Junior et al., 2003). Jawad et al. compared the expression of p53 in LBOS and JOS samples and they found no statistical difference in protein levels (Jawad and Abdullah, 2010). There is currently no recommendation for testing p53 in OS, except in cases of personal or family history of cancers to investigate a genetic predisposition (e.g., Li-Fraumeni syndrome) (Kratz et al., 2017). Furthermore, there is no clear relationship between p53 deletion or mutation and clinical outcomes in OS (Wunder et al., 2005).

MDM2 (murine double minute 2) is an E3 ligase that negatively regulates the transcriptional activity of p53 (Deb, 2003). CDK4 is a cyclin-dependent kinase implicated in cell cycle progression (Lee and Yang, 2003) (Fig. 2). These two genes are located on the chromosomal region 12q13–15 and they are frequently co-amplified in various malignancies, including OS (Mejia-Guerrero et al., 2010; Wunder et al., 1999). Expression of MDM2 and CDK4 has been investigated in craniofacial OS samples at the protein (immunohistochemistry) and transcript (PCR) levels (Guérin et al., 2016; Hirose et al., 2017; Junior et al., 2003; Limbach et al., 2020; Lopes et al., 2001; Yoshida et al., 2010). Various expression levels were found in JOS, ranging from 8 to 100 % for MDM2, and from 33 to 88.8 % for CDK4, with no correlation with the prognosis in patients. However, as observed in LBOS, amplification of MDM2 and CDK4 was not observed in benign fibro-osseous lesions, thus making it a valuable tool for differential diagnosis between low-grade OS and benign tumours (Dujardin et al., 2011; Jo and Doyle, 2016; Mejia-Guerrero et al., 2010). This is particularly the case for craniofacial bones, for which distinction between OS and benign tumours such as fibrous dysplasia (FD) and juvenile ossifying fibroma (JOF) can be challenging with small biopsies (Guérin et al., 2016; Limbach et al., 2020). Furthermore, a subtype of high-grade JOS

exhibits co-amplification of MDM2 and RASAL1 (a telomeric gene on chromosome 12), which has also been reported in JOF (Tabareau-Delalande et al., 2015). Co-amplification of MDM2 and RASAL1 could thus constitute an early signature for the risk of transformation of JOF into high-grade JOS (Guérin et al., 2016). Parks et al. investigated the possible role of ezrin (a membrane cytoskeleton linker involved in metastasis) and of the metastatic tumour antigen (MTA) in 31 JOS, but they were unable to correlate this with the tumour grade and the prognosis in patients (Park et al., 2009).

The proliferating cell nuclear antigen (PCNA) and the Ki-67 antigen have been identified as effective biomarkers of a poor prognosis in OS (Mardanpour et al., 2016; Wang et al., 2017). PCNA is a cell-cycle regulatory protein, while Ki-67 is a cellular marker of proliferation. Junior et al. found high levels of PCNA and Ki-67 (92 % and 88 %, respectively) by immunohistochemistry in 25 samples of intermediate- and high-grade head and neck OS, although they found no correlation with survival rates (Junior et al., 2003). In an immunohistochemical study, Jawad et al. found significantly lower expression of Ki-67 in JOS compared to LBOS samples (mean positive nuclei:  $13.13 \pm 20.41$  vs.  $32.27 \pm 25.05$ ,  $p = 0.03$ ), but no correlation with clinical parameters (Jawad and Abdullah, 2010). The results from the immunohistochemical and molecular studies are presented in Table 1.

P16 is a cyclin-dependent kinase inhibitor encoded by the CDKN2A gene that is involved in regulation of the cell cycle by inhibition of the transition from G1 to S phase of the cell cycle (Lukas et al., 1995) (Fig. 2). Overexpression of p16 is common in human papillomavirus-induced head and neck squamous cell carcinomas (Klussmann et al., 2003), and it is associated with a better 5-year survival rate (Chen et al., 2020a; Molony et al., 2020). Alteration of the expression of p16 protein has been correlated with the pathogenesis and progression of OS (Mohseny et al., 2009), and it could constitute a predictive marker of the pathologic response after neo-CT (Tang et al., 2017). In an immunohistochemical study of 37 high-grade OS, Asioli et al. found nuclear expression of p16 in 56.7 % of the samples, as well as a significant correlation between the negativity of p16 and the risk of a negative outcome (Asioli et al., 2017).



**Fig. 2.** Molecular mechanisms involved in the development of JOS. The p53 protein acts as a transcription factor for the genes regulating cell cycle, DNA repair and apoptosis. Under the effect of intracellular stress (DNA damage, cell cycle abnormality and abnormal cell metabolism), MDM2 breaks away p53 allowing its activation. There is a usual overexpression of MDM2 in the OS leading to the inactivation of p53. The p16 protein inhibits the CDK4/CDK6-cycline complex responsible for the phosphorylation of the RB protein. Unphosphorylated RB protein can bind to the transcription factor E2F, which controls the expression of the genes indispensable to the S phase of DNA synthesis. The phosphorylation of RB prevents its binding to E2F and thus allows the transition from the G1 phase to the S phase of the cell cycle under the action of E2F.

**Table 1**  
Literature review of p53, MDM2, CDK4, PCNA, and Ki-67 markers in head and neck osteosarcomas.

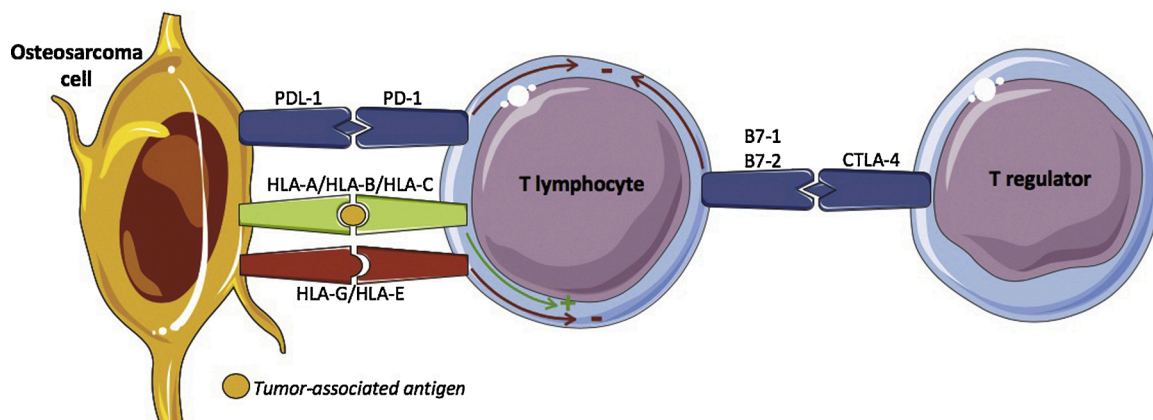
Study	Nb of specimens	p53	MDM2	CDK4	PCNA	Ki67	Grade	Positivity in benign lesions
Lopes et al., 2001	9	88.8 % (IHC)	55.5 % (IHC)66.6 % (PCR)	88.8 % (IHC)66.6 % (PCR)			Low High Intermediate	NC
Junior et al., 2003	25	52.0% (IHC)	24.0 % (IHC)	84.0 % (IHC)	92.0 % (IHC)	88.0 % (IHC)	Intermediate High	NC
Yoshida et al., 2010	3		100 % (IHC)	33.3 % (IHC)			Low	1/40 (3.0 %) EC POP
Guerin et al., 2016	36		8.3% (IHC) 35.7 % (PCR)			75.0 % (IHC)	High	0/25 CF (FD and OF)
Hirose et al., 2017	1		100 % (IHC and PCR)	100 % (IHC and PCR)			High	NC
Limbach et al., 2020	11		63.6 % (IHC) 25.0 % (FISH)	63.6 % (IHC)			Low Intermediate High High	0/14 CF (FD, OF, OF, CGCL, EO, OFM)
Oliveira et al., 1997	17	46.5% (IHC)					High	NC
Jawad et al., 2010	15	80.0% (IHC)				100 % (IHC)	Low Intermediate High	NC
Total	117	62.1%	29.4 % (IHC)	77.5 % (IHC)	92.0 %	84.2 %	All	1/79 (1.3 %)

IHC, immunohistochemistry; PCR, polymerase chain reaction; FISH, fluorescence in-situ hybridization; EC, extra-cranial; POP, parosteal osteochondromatous proliferation; CF, craniofacial; FD, fibrous dysplasia; OF, ossifying fibroma; CGCL, central giant-cell lesion; EO, endosteal osteoma; OFM, odontogenic fibromyxoma; NC, no comparison.

**4. Immune environment**

Immune infiltrates are a key component of the complex local environment of OS (Heymann et al., 2019). This microenvironment produces all the factors needed to control proliferation, drug resistance, and the dissemination of OS cells (Alfranca et al., 2015; Brown et al., 2017; Cortini et al., 2017). The bone and immune systems are functionally interconnected, as reflected by the term ‘osteimmunology’ (Heymann et al., 2019). Identification of the immune environment involved in JOS could help with gaining an understanding of the differences in clinical behaviour relative to LBOS. Furthermore, immune infiltrates may represent a potential therapeutic target, as indicated by various trials testing immunotherapies as adjuvant treatments for LBOS (Miwa et al., 2019). Macrophages are the most highly represented cells in immune infiltrates and they have central functions in osteoimmunology (Heymann et al., 2019). Tumour-associated macrophages (TAMs) control local immunity and angiogenesis, and they also regulate tumour cell

migration (Brown et al., 2018). The M1-subtype is considered to have anti-tumour activity, and several studies have shown that macrophages are associated with higher survival rates in patients with LBOS (Gomez-Brouchet et al., 2017). Tumour-infiltrating lymphocytes (TILs) are the second most represented cells in OS immune infiltrates. TILs constitute a selected population of T cells with a higher immunological specificity against tumour cells compared to non-infiltrating lymphocytes (Alvarez et al., 2019). The CD8<sup>+</sup>/FOXP3<sup>+</sup> subtype of T cells is particularly associated with better survival rates in patients with LBOS (Fritzsching et al., 2015; Gomez-Brouchet et al., 2017). TILs are thus able to recognize and kill antigen-presenting cells (APC) as CD8<sup>+</sup> effector T cells and they can regulate the immune response as CD4<sup>+</sup> helper T cells. These actions may be inhibited by OS cells by the secretion of immunosuppressive molecules and by the activation of immune checkpoints (Alvarez et al., 2019; Koirala et al., 2016). The most investigated checkpoint components are cytotoxic T lymphocyte-associated antigen 4 (CTLA-4) and programmed cell death 1



**Fig. 3.** Schematic representation of the immune environment of OS. PD-1 is expressed by activated T, B, and natural killer (NK) cells. Programmed cell death ligand 1 (PDL-1) is expressed by osteosarcoma cell. The binding of PDL-1 to PD-1 inhibits the T-cell response, thereby leading to a favourable environment for tumour proliferation. CTLA-4 is expressed on regulatory T lymphocytes and memory T cells. It binds to B7-1 and B7-2 on APCs, thereby inducing functional inhibition of T cells and immune tolerance. HLA-G directly interacts with inhibitory receptors expressed on NK and T lymphocytes: immunoglobulin-like transcript (ILT)2, ILT4, KIR2DL4, and CD160. HLA-E binds inhibitory CD94/NKG2 A receptors, which also are expressed on NK and T lymphocytes, causing inhibition of these immunocompetent cells. HLA-A, -B, and -C molecules bind the tumour-associated antigens and interact with antigen-specific T-cell receptors expressed on cytotoxic CD8<sup>+</sup> T cells and NK cells, thereby activating the immune response.

(PD-1) protein (Fig. 3). The use of targeted therapies against PD-1 (pembrolizumab, nivolumab) and CTLA-4 (ipilimumab) is currently undergoing phase I/II clinical trials in advanced OS (Heymann et al., 2019; Miwa et al., 2019). There have been very few reports to date of the immune effectors involved in JOS. Alves et al. explored the immune profile (CD4<sup>+</sup>, CD8<sup>+</sup>, CTLA-4<sup>+</sup>, and PD-1<sup>+</sup>) of JOS samples by immunohistochemistry (Alves et al., 2019). They found low levels of CD4<sup>+</sup> (30 %) and CD8<sup>+</sup> (45 %) lymphocytes, as well as a significantly lower number of CTLA-4<sup>+</sup> (4.8 %) and PD-1<sup>+</sup> (0%) cells. While a low level of CD8<sup>+</sup> cells has been reported to be associated with the occurrence of metastases and poor outcomes in limb OS (Gomez-Brouchet et al., 2017), no association was found between the immune profile and the clinicopathological features of JOS (Alves et al., 2019). Arantes et al. investigated the presence of human leukocyte antigens (HLAs) G and E and programmed cell death ligand 1 (PDL-1) in high-grade oral osteosarcomas relative to normal bone (Costa Arantes et al., 2017). They found that these proteins were overexpressed in 69.2 % of oral sarcomas samples, with significantly higher rates than in normal bone samples. These results highlight the capacity of malignant osteoblastic cells to evade immune-based elimination by the expression of immunomodulators on their cell surface. HLA-G and HLA-E are non-classical major histocompatibility complex (MHC) class I molecules that exert inhibitory effects on natural killers (NK) cells and cytotoxic lymphocytes (Morandi and Pistoia, 2014). The expression of these inhibitory molecules has also been reported in metastatic oral squamous cell carcinomas (Gonçalves et al., 2014; Mosconi et al., 2017). HLA-G and HLA-E differ from classical HLA-1 molecules (HLA-A, -B, and -C) that activate T cells by presentation of the tumour-associated antigen to the T-cell receptor (Braciale, 1992) (Fig. 3). HLA-A, -B, and -C, therefore, correlate with better survival in LBOS (Sundara et al., 2017). Studying the HLA system in JOS could help with the development of new treatment approaches.

More studies are needed to investigate the role of the immune microenvironment in JOS development. It is likely that there are differences in the maturity of the immune system in children and adolescents with LBOS relative to the adult population in case of JOS.

## 5. Angiogenesis

New blood vessel formation is fundamental to tumour growth, invasion, and metastatic dissemination by most solid tumours, including OS (Jerez et al., 2017; Xie et al., 2017). Angiogenesis is regulated by the balance between pro-angiogenic and anti-angiogenic factors. Overexpression of pro-angiogenic factors is common in OS (Li et al., 2019). Vascular endothelial growth factor (VEGF) is the predominant pro-angiogenic factor. VEGF promotes endothelial cell growth, migration, proliferation, and maturation, as well as the formation of new blood vessels, by interaction with its transmembrane receptor (VEGFR) on endothelial cells (Li et al., 2019). Hypoxia is a frequent stimulus of angiogenesis in OS, acting through the expression of hypoxia-inducible factor-1 $\alpha$  (HIF-1 $\alpha$ ), which acts as an active transcription factor for VEGF (Li et al., 2019; Versleijen-Jonkers et al., 2014). Chen et al. studied the expression of HIF-1 $\alpha$  and microvessel density (MVD) (CD34) in 25 samples of JOS using immunohistochemistry (Chen et al., 2008). They showed overexpression of HIF-1 $\alpha$  in JOS compared to normal bone and benign lesions, and this correlated with the MVD and the clinicopathological parameters (i.e., the tumour size, the pathological grade, and recurrence). In another immunohistochemical study with the same samples, the authors found overexpression of inducible nitric oxide synthase (iNOS) in JOS and a significant correlation with the clinicopathological parameters (Chen et al., 2007). The authors suggested that HIF-1 $\alpha$  and iNOS may promote tumour angiogenesis and that these could, therefore, represent potential targets for antitumoural therapy. Jawad et al. compared the VEGF staining in JOS and LBOS and they found significantly lower expression in JOS, which could explain the lower metastatic potential (Jawad and Abdullah, 2010) and the poor responses obtained with neo-CT in JOS. The results from

immunohistochemical studies regarding the vascular environment are presented in Table 2.

VEGF appears to have a paradoxical effect in osteosarcoma. On the one hand, it is associated with pulmonary metastasis, a higher rate of cancer recurrence, and poor survival (Charity et al., 2006; Kaya et al., 2000). On the other hand, the expression of VEGF increases the MVD and it can contribute to the penetration of chemotherapeutic drugs into the tumour during the neo-CT, which makes VEGF a marker for a good response to chemotherapy in LBOS (Qu et al., 2011; Rossi et al., 2010). Various therapies targeting angiogenesis are available for second-line chemotherapy in advanced disease (Versleijen-Jonkers et al., 2014; Xie et al., 2017).

## 6. Perspectives

OS arises in a specialized, complex, and dynamic microenvironment involving communication by various environmental signals including cytokines, chemokines, soluble growth factors, and extracellular vesicles (Alfranca et al., 2015; Corre et al., 2020). In addition to the immune and vascular components, the microenvironment includes bone cells (osteocytes, osteoblasts, osteoclasts), stromal cells (MSCs, fibroblasts), and mineralized extracellular matrix (Fig. 4). There have not been any studies to date describing the specific tumour microenvironment in JOS. On the other hand, the significance of the bone microenvironment in the development of LBOS is well established (Alfranca et al., 2015; Rubio et al., 2014), as indicated by the role of the triad represented by osteoprotegerin (OPG), the receptor activator of NF $\kappa$ B ligand (RANKL), and its receptor RANK in bone resorption and tumor proliferation. Indeed, the tumour cells secrete various factors including RANKL, thereby inducing the differentiation and activation of osteoclasts. The activated osteoclasts degrade bone tissue, which leads to the release of additional factors that promote tumour cell proliferation such as transforming growth factor (TGF)- $\beta$  and insulin growth factor (IGF) (Guise, 2002; Wittrant et al., 2004). OPG acts as a soluble decoy receptor, thereby preventing the binding of RANKL to RANK and hence also bone degradation. Although this signaling triad is currently thought to be involved in periodontal and dental diseases (Alvarez et al., 2019; Belibasakis and Bostanci, 2012), its role in the pathophysiology of JOS has not been clearly established. It is likely that the jaw microenvironment differs overall from that of the metaphysis of long-bones, and this could account for the differences in the clinical behaviour and in the response to anti-cancer treatments.

There is an urgent need for specific basic research in head and neck sarcomas in light of the following considerations:

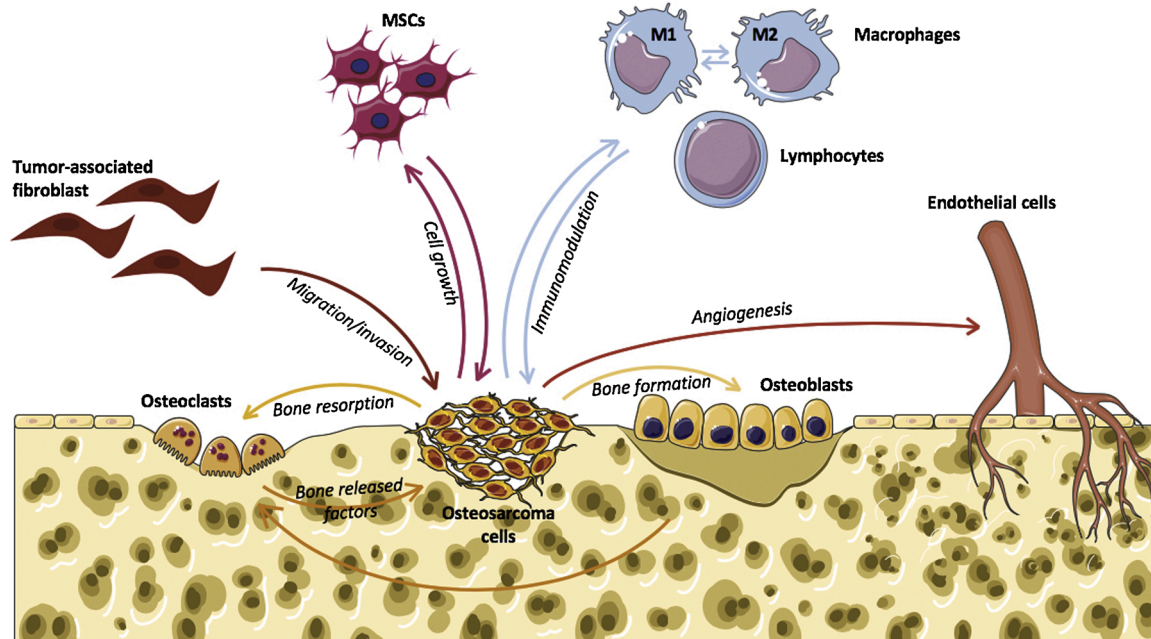
- 1 While LBOS is a rare disease, its jaw counterpart is even more so, thereby making difficult to conduct therapeutic trials that involve large patient cohorts.
- 2 Histological diagnosis remains difficult with a maxillofacial localization. Various frequent benign bone tumours of the face can mimic authentic OS, thus necessitating the identification of specific markers of the disease.
- 3 Comparative studies of the bone microenvironment between JOS and LBOS could result in a better understanding of the differences in the biological and clinical behaviours.
- 4 Although overall survival remains better in JOS compared to LBOS, survival has not improved in the past three decades. Further research should be aimed at the identification of therapeutics that specifically target the jaw localization.
- 5 Neo-CT remains controversial in JOS as the disease may progress during the neo-CT phase. There is a need to identify tumour markers that are predictive of the efficacy of neo-CT.

The recent development of JOS models in mice (Bertin et al., 2019) could allow further exploration of the pathophysiology of bone sarcomas and testing of several drugs (Blattmann et al., 2015; Nanni et al., 2019).

**Table 2**Literature review of immunohistochemical studies of HIF-1 $\alpha$ , iNOS, CD34, and VEGF markers in jaw osteosarcomas.

Study	Nb of specimens	HIF-1 $\alpha$	iNOS	CD34	VEGF	Grade	Positivity in benign lesions
Chen et al., 2008	25	68.0%		Unknown		Low High	0/15 NB, 1/10 FD
Chen et al., 2007	25		80.0%	Unknown		Low High	0/15 NB, 2/10 FD
Jawad et al., 2010	15				60.0%	Low Intermediate High	NC
Guerin et al., 2016	36			63.9%		High	25/25 (FD and OF)

NB, normal bone; FD, fibrous dysplasia; OF, ossifying fibroma; NC, no comparison.

**Fig. 4.** Schematic representation of the interactions between osteosarcoma cells and the environment in the tumour niche. MSCs, mesenchymal stem cells.

The Patient-Derived Xenograft models (PDX) are based on grafting of neoplastic cells or tissues obtained from patients in immunodeficient mice (Lai et al., 2017; Wagner et al., 2016). These models have the advantage to preserve the host tumor microenvironment and the mechanisms involved in tumor and metastatic progression (Guijarro et al., 2014; Lu et al., 2018). Furthermore, PDX models are particularly useful for rare cancers as they allow a wide range of drugs to be tested by means of a personalized approach for patients (Bousquet and Janin, 2016; Houghton et al., 2007).

## 7. Conclusion

Jaw osteosarcoma is a rare form of bone sarcoma. It differs from long-bone osteosarcomas in terms of a number of biological and clinical parameters. Changes in crosstalk and the relationship of the tumour to its environment could explain these differences between JOS and LBOS. The main challenge going forward will be to elucidate this particular microenvironment in JOS and to devise specific anti-cancer treatments.

## Funding

This work was supported by the “Fondation les Gueules Cassées” (2018-51). The sponsors had no role in the study design, the collection, analysis and interpretation of the data, or writing of the study.

## CRediT authorship contribution statement

**Hélios Bertin:** Conceptualization, Methodology, Writing - original draft. **A. Gomez-Brouchet:** Supervision, Writing - review & editing. **F. Rédini:** Supervision, Writing - review & editing.

## Declaration of Competing Interest

The authors report no declarations of interest.

## Acknowledgments

The authors thank Mrs Sophie Domingues for her careful reading and correction of the English version of this manuscript. The authors thank Dr Benoit Piot, Dr Julie Longis and Dr Anne Moreau for their help in illustrating this manuscript.

## References

- Alfranca, A., Martinez-Cruzado, L., Tornin, J., Abarategi, A., Amaral, T., de Alava, E., Menendez, P., Garcia-Castro, J., Rodriguez, R., 2015. Bone microenvironment signals in osteosarcoma development. *Cell. Mol. Life Sci. CMLS* 72, 3097–3113. <https://doi.org/10.1007/s00018-015-1918-y>.
- Alvarez, C., Monasterio, G., Cavalla, F., Córdova, L.A., Hernández, M., Heymann, D., Garlet, G.P., Sorsa, T., Pärnänen, P., Lee, H.-M., Golub, L.M., Vernal, R., Kantarci, A., 2019. Osteoimmunology of oral and maxillofacial diseases: translational applications based on biological mechanisms. *Front. Immunol.* 10, 1664. <https://doi.org/10.3389/fimmu.2019.01664>.

- Alves, P.M., de Arruda, J.A.A., Arantes, D.A.C., Costa, S.F.S., Souza, L.L., Pontes, H.A.R., Fonseca, F.P., Mesquita, R.A., Nonaka, C.F.W., Mendonça, E.F., Batista, A.C., 2019. Evaluation of tumor-infiltrating lymphocytes in osteosarcomas of the jaws: a multicenter study. *Virchows Arch. Int. J. Pathol.* 474, 201–207. <https://doi.org/10.1007/s00428-018-2499-6>.
- Asioli, S., Righi, A., Rucci, P., Tarsitano, A., Marchetti, C., Bacchini, P., Balbi, T., Bertoni, F., Foschini, M.P., 2017. p16 protein expression and correlation with clinical and pathological features in osteosarcoma of the jaws: experience of 37 cases. *Head Neck* 39, 1825–1831. <https://doi.org/10.1002/hed.24835>.
- Baumhoer, D., 2017. Bone-related lesions of the jaws. *Surg. Pathol. Clin.* 10, 693–704. <https://doi.org/10.1016/j.path.2017.04.007>.
- Baumhoer, D., Brunner, P., Eppenberger-Castori, S., Smida, J., Nathrath, M., Jundt, G., 2014. Osteosarcomas of the jaws differ from their peripheral counterparts and require a distinct treatment approach. Experiences from the DOESAK Registry. *Oral Oncol.* 50, 147–153. <https://doi.org/10.1016/j.oraloncology.2013.10.017>.
- Belibasakis, G.N., Bostanci, N., 2012. The RANKL-OPG system in clinical periodontology. *J. Clin. Periodontol.* 39, 239–248. <https://doi.org/10.1111/j.1600-051X.2011.01810.x>.
- Bertin, H., Guilho, R., Brion, R., Amiaud, J., Battaglia, S., Moreau, A., Brouchet-Gomez, A., Longis, J., Piot, B., Heymann, D., Corre, P., Rédini, F., 2019. Jaw osteosarcoma models in mice: first description. *J. Transl. Med.* 17, 56. <https://doi.org/10.1186/s12967-019-1807-5>.
- Blattmann, C., Thiemann, M., Stenzinger, A., Roth, E.K., Dittmar, A., Witt, H., Lehner, B., Renker, E., Jugold, M., Eichwald, V., Weichert, W., Huber, P.E., Kulozik, A.E., 2015. Establishment of a patient-derived orthotopic osteosarcoma mouse model. *J. Transl. Med.* 13. <https://doi.org/10.1186/s12967-015-0497-x>.
- Boon, E., van der Graaf, W.T.A., Gelderblom, H., Tesselaa, M.E.T., van Es, R.J.J., Oosting, S.F., de Bree, R., van Meerden, E., Hoeben, A., Smeele, L.E., Willems, S.M., Witjes, M.J.H., Buter, J., Baatenburg de Jong, R.J., Flucke, U.E., Peer, P.G.M., Bovée, J.V.M.G., Van Herpen, C.M.L., 2017. Impact of chemotherapy on the outcome of osteosarcoma of the head and neck in adults. *Head Neck* 39, 140–146. <https://doi.org/10.1002/hed.24556>.
- Bouaoud, J., Beinse, G., Epailard, N., Amor-Sehlil, M., Bidault, F., Brocheriou, I., Hervé, G., Spano, J.-P., Janot, F., Boudou-Rouquette, P., Benassarou, M., Schouman, T., Goudot, P., Malouf, G., Goldwasser, F., Bertolus, C., 2019. Lack of efficacy of neoadjuvant chemotherapy in adult patients with maxillo-facial high-grade osteosarcomas: a French experience in two reference centers. *Oral Oncol.* 95, 79–86. <https://doi.org/10.1016/j.oraloncology.2019.06.011>.
- Bousquet, G., Janin, A., 2016. Patient-derived xenograft: an adjuvant technology for the treatment of metastatic disease. *Pathobiol. J. Immunopathol. Mol. Cell. Biol.* 83, 170–176. <https://doi.org/10.1159/000444533>.
- Bousquet, M., Noirot, C., Accadbled, F., Sales de Gauzy, J., Castex, M.P., Brousset, P., Gomez-Brouchet, A., 2016. Whole-exome sequencing in osteosarcoma reveals important heterogeneity of genetic alterations. *Ann. Oncol. Off. J. Eur. Soc. Med. Oncol.* 27, 738–744. <https://doi.org/10.1093/annonc/mdw009>.
- Braciale, T.J., 1992. Antigen processing for presentation by MHC class I molecules. *Curr. Opin. Immunol.* 4, 59–62. [https://doi.org/10.1016/0952-7915\(92\)90126-y](https://doi.org/10.1016/0952-7915(92)90126-y).
- Brown, H.K., Tellez-Gabriel, M., Heymann, D., 2017. Cancer stem cells in osteosarcoma. *Cancer Lett.* 386, 189–195. <https://doi.org/10.1016/j.canlet.2016.11.019>.
- Brown, H.K., Schiavone, K., Gouin, F., Heymann, M.-F., Heymann, D., 2018. Biology of bone sarcomas and new therapeutic developments. *Calcif. Tissue Int.* 102, 174–195. <https://doi.org/10.1007/s00223-017-0372-2>.
- Canadian Society of Otolaryngology-Head and Neck Surgery Oncology Study Group, 2004. Osteogenic sarcoma of the mandible and maxilla: a Canadian review (1980–2000). *J. Otolaryngol.* 33, 139–144.
- Charity, R.M., Foukas, A.F., Deshmukh, N.S., Grimer, R.J., 2006. Vascular endothelial growth factor expression in osteosarcoma. *Clin. Orthop.* 448, 193–198. <https://doi.org/10.1097/01.blo.0000205877.05093.c9>.
- Chaudhary, M., Chaudhary, S.D., 2012. Osteosarcoma of jaws. *J. Oral Maxillofac. Pathol. JOMFP* 16, 233–238. <https://doi.org/10.4103/0973-029X.99075>.
- Chen, W.-L., Feng, H.-J., Li, J.-S., Li, H.-G., 2007. Expression and pathological relevance of inducible nitric oxide synthase in osteosarcoma of the jaws. *Int. J. Oral Maxillofac. Surg.* 36, 541–544. <https://doi.org/10.1016/j.ijom.2007.02.012>.
- Chen, W., Feng, H., Li, H., 2008. Expression and significance of hypoxemia-inducible factor-1alpha in osteosarcoma of the jaws. *Oral Surg. Oral Med. Oral Pathol. Oral Radiol. Endod.* 106, 254–257. <https://doi.org/10.1016/j.tripleo.2008.01.029>.
- Chen, X., Bahrami, A., Pappo, A., Easton, J., Dalton, J., Hedlund, E., Ellison, D., Shurtleff, S., Wu, G., Wei, L., Parker, M., Rusch, M., Nagahawatte, P., Wu, J., Mao, S., Boggs, K., Mulder, H., Yergeau, D., Lu, C., Ding, L., Edmonson, M., Qu, C., Wang, J., Li, Y., Navid, F., Daw, N.C., Mardis, E.R., Wilson, R.K., Downing, J.R., Zhang, J., Dyer, M.A., St. Jude Children's Research Hospital–Washington University Pediatric Cancer Genome Project, 2014. Recurrent somatic structural variations contribute to tumorigenesis in pediatric osteosarcoma. *Cell Rep.* 7, 104–112. <https://doi.org/10.1016/j.celrep.2014.03.003>.
- Chen, C., Lohavanichbut, P., Zhang, Y., Houck, J.R., Upton, M.P., Abedi-Ardekani, B., Agudo, A., Ahrens, W., Alemany, L., Anantharaman, D., Conway, D.I., Futran, N.D., Holcatova, I., Günther, K., Hansen, B.T., Healy, C.M., Itani, D., Kjaerheim, K., Monroe, M.M., Thomson, P.J., Witt, B.L., Nakoneshny, S., Peterson, L.A., Schwartz, S.M., Zarins, K.R., Hashibe, M., Brennan, P., Rozek, L.S., Wolf, G., Dort, J. C., Wang, P., 2020a. Prediction of survival of HPV16-negative, p16-negative oral cavity cancer patients using a 13-gene signature: a multicenter study using FFPE samples. *Oral Oncol.* 100, 104487. <https://doi.org/10.1016/j.oraloncology.2019.104487>.
- Chen, D., Chen, Xiaoju, Chen, Xinmei, Jiang, N., Jiang, L., 2020b. The efficacy of positioning stents in preventing Oral complications after head and neck radiotherapy: a systematic literature review. *Radiat. Oncol. Lond. Engl.* 15, 90. <https://doi.org/10.1186/s13014-020-01536-0>.
- Corre, I., Verrecchia, F., Crenn, V., Redini, F., Trichet, V., 2020. The osteosarcoma microenvironment: a complex but targetable ecosystem. *Cells* 9. <https://doi.org/10.3390/cells9040976>.
- Cortini, M., Avnet, S., Baldini, N., 2017. Mesenchymal stroma: role in osteosarcoma progression. *Cancer Lett.* 405, 90–99. <https://doi.org/10.1016/j.canlet.2017.07.024>.
- Costa Arantes, D.A., Gonçalves, A.S., Jham, B.C., Duarte, E.C.B., de Paula, É.C., de Paula, H.M., Mendonça, E.F., Batista, A.C., 2017. Evaluation of HLA-G, HLA-E, and PD-L1 proteins in oral osteosarcomas. *Oral Surg. Oral Med. Oral Pathol. Oral Radiol.* 123, e188–e196. <https://doi.org/10.1016/j.oooo.2016.12.002>.
- Crenn, V., Biteau, K., Amiaud, J., Dumars, C., Guiho, R., Vidal, L., Nail, L.-R.L., Heymann, D., Moreau, A., Gouin, F., Redini, F., 2017. Bone microenvironment has an influence on the histological response of osteosarcoma to chemotherapy: retrospective analysis and preclinical modeling. *Am. J. Cancer Res.* 7, 2333–2349.
- Deb, S.P., 2003. Cell cycle regulatory functions of the human oncoprotein MDM2. *Mol. Cancer Res. MCR* 1, 1009–1016.
- Dujardin, F., Binh, M.B.N., Bouvier, C., Gomez-Brouchet, A., Larousserie, F., Muret, Ade, Louis-Brennetot, C., Aurias, A., Coindre, J.-M., Guillou, L., Pedetout, F., Duval, H., Collin, C., de Pinieux, G., 2011. MDM2 and CDK4 immunohistochemistry is a valuable tool in the differential diagnosis of low-grade osteosarcomas and other primary fibro-osseous lesions of the bone. *Mod. Pathol. Off. J. U. S. Can. Acad. Pathol. Inc* 24, 624–637. <https://doi.org/10.1038/modpathol.2010.229>.
- Flechter, C.D.M., Bridge, J.A., Hogendoorn, P.C.W., Mertens, F., 2013. WHO Classification of Tumours of Soft Tissue and Bone, 4th edition. IRC Press, Lyon.
- Fritzsche, B., Fellenberg, J., Moskovszky, L., Sági, Z., Krénacs, T., Machado, I., Poeschl, J., Lehner, B., Szendrői, M., Bosch, A.L., Bernd, L., Csóka, M., Mechttersheimer, G., Ewerbeck, V., Kinscherf, R., Kunz, P., 2015. CD8+/FOXP3+ ratio in osteosarcoma microenvironment separates survivors from non-survivors: a multicenter validated retrospective study. *Oncotarget* 4, e990800. <https://doi.org/10.4161/2162402X.2014.990800>.
- Ginat, D., Schulte, J., Gooi, Z., Cipriani, N., 2018. High-grade conventional osteosarcoma of the mandible associated with P53 germline mutation. *J. Craniofac. Surg.* 29, 738–740. <https://doi.org/10.1097/SCS.0000000000004336>.
- Gomez-Brouchet, A., Illac, C., Gilhodes, J., Bouvier, C., Aubert, S., Guinebretiere, J.-M., Marie, B., Larousserie, F., Entz-Werlé, N., de Pinieux, G., Filleron, T., Minard, V., Minville, V., Mascard, E., Gouin, F., Jimenez, M., Ledeley, M.-C., Piperno-Neumann, S., Brugieres, L., Rédini, F., 2017. CD163-positive tumor-associated macrophages and CD8-positive cytotoxic lymphocytes are powerful diagnostic markers for the therapeutic stratification of osteosarcoma patients: An immunohistochemical analysis of the biopsies from the French OS2006 phase 3 trial. *Oncotarget* 6, e1331193. <https://doi.org/10.1080/2162402X.2017.1331193>.
- Gonçalves, A.S., Wastowski, L.J., Capeletti, L.R., Sacono, N.T., Cortez, A.P., Valadares, M. C., Silva, T.A., Batista, A.C., 2014. The clinicopathologic significance of the expression of HLA-G in oral squamous cell carcinoma. *Oral Surg. Oral Med. Oral Pathol. Oral Radiol.* 117, 361–368. <https://doi.org/10.1016/j.oooo.2013.12.001>.
- Granowski-LeCornu, M., Chuang, S.-K., Kaban, L.B., August, M., 2011. Osteosarcoma of the jaws: factors influencing prognosis. *J. Oral Maxillofac. Surg. Off. J. Am. Assoc. Oral Maxillofac. Surg.* 69, 2368–2375. <https://doi.org/10.1016/j.joms.2010.10.023>.
- Guadagnolo, B.A., Zagars, G.K., Raymond, A.K., Benjamin, R.S., Sturgis, E.M., 2009. Osteosarcoma of the jaw/craniofacial region: outcomes after multimodality treatment. *Cancer* 115, 3262–3270. <https://doi.org/10.1002/cncr.24297>.
- Guérin, M., Thariat, J., Ouali, M., Bouvier, C., Decouvelaere, A.-V., Cassagnau, E., Aubert, S., Lepreux, S., Coindre, J.-M., Valmary-Degano, S., Larousserie, F., Meilleroux, J., Progetti, F., Stock, N., Galant, C., Marie, B., Peyrottes, I., de Pinieux, G., Gomez-Brouchet, A., 2016. A new subtype of high-grade mandibular osteosarcoma with RASAL1/MDM2 amplification. *Hum. Pathol.* 50, 70–78. <https://doi.org/10.1016/j.humpath.2015.11.012>.
- Guijarro, M.V., Ghivizzani, S.C., Gibbs, C.P., 2014. Animal models in osteosarcoma. *Front. Oncol.* 4, 189. <https://doi.org/10.3389/fonc.2014.00189>.
- Guise, T.A., 2002. The vicious cycle of bone metastases. *J. Musculoskelet. Neuronal Interact.* 2, 570–572.
- Hameed, M., Horvai, A.E., Jordan, R.C.K., 2020. Soft tissue special issue: gnathic fibro-osseous lesions and osteosarcoma. *Head Neck Pathol.* 14, 70–82. <https://doi.org/10.1007/s12105-019-01094-2>.
- Heymann, M.-F., Lézot, F., Heymann, D., 2019. The contribution of immune infiltrates and the local microenvironment in the pathogenesis of osteosarcoma. *Cell. Immunol.* 343, 103711. <https://doi.org/10.1016/j.cellimm.2017.10.011>.
- Hirose, K., Okura, M., Sato, S., Murakami, S., Ikeda, J.-I., Noda, Y., Fukuda, Y., Morii, E., Toyosawa, S., 2017. Gnathic giant-cell-rich conventional osteosarcoma with MDM2 and CDK4 gene amplification. *Histopathology* 70, 1171–1173. <https://doi.org/10.1111/his.13141>.
- Houghton, P.J., Morton, C.L., Tucker, C., Payne, D., Favours, E., Cole, C., Gorlick, R., Kolb, E.A., Zhang, W., Lock, R., Carol, H., Tajbakhsh, M., Reynolds, C.P., Maris, J.M., Courtright, J., Keir, S.T., Friedman, H.S., Stopford, C., Zeidner, J., Wu, J., Liu, T., Billups, C.A., Khan, J., Ansher, S., Zhang, J., Smith, M.A., 2007. The pediatric preclinical testing program: description of models and early testing results. *Pediatr. Blood Cancer* 49, 928–940. <https://doi.org/10.1002/pbc.21078>.
- Jasnau, S., Meyer, U., Potratz, J., Jundt, G., Kevric, M., Joos, U.K., Jürgens, H., Bielack, S. S., Cooperative Osteosarcoma Study Group COSS, 2008. Craniofacial osteosarcoma Experience of the cooperative German-Austrian-Swiss osteosarcoma study group. *Oral Oncol.* 44, 286–294. <https://doi.org/10.1016/j.oraloncology.2007.03.001>.
- Jawad, S.N., Abdullah, B.H., 2010. Proliferative, apoptotic and angiogenic potentials in jaws and long bones osteosarcomas: a comparative immunohistochemical study.



- J. Oral Pathol. Med. Off. Publ. Int. Assoc. Oral Pathol. Am. Acad. Oral Pathol. 39, 681–686. <https://doi.org/10.1111/j.1600-0714.2010.00923.x>.
- Jerez, S., Araya, H., Thaler, R., Charlesworth, M.C., López-Solis, R., Kalergis, A.M., Céspedes, P.F., Dudakovic, A., Stein, G.S., van Wijnen, A.J., Galindo, M., 2017. Proteomic Analysis of Exosomes and Exosome-Free Conditioned Media From Human Osteosarcoma Cell Lines Reveals Secretion of Proteins Related to Tumor Progression. *J. Cell. Biochem.* 118, 351–360. <https://doi.org/10.1002/jcb.25642>.
- Jo, V.Y., Doyle, L.A., 2016. Refinements in sarcoma classification in the current 2013 world health organization classification of tumours of soft tissue and bone. *Surg. Oncol. Clin. N. Am.* 25, 621–643. <https://doi.org/10.1016/j.soc.2016.05.001>.
- Junior, A.T., de Abreu Alves, F., Pinto, C.A.L., Carvalho, A.L., Kowalski, L.P., Lopes, M. A., 2003. Clinicopathological and immunohistochemical analysis of twenty-five head and neck osteosarcomas. *Oral Oncol.* 39, 521–530.
- Kassir, R.R., Rassekh, C.H., Kinsella, J.B., Segas, J., Carraru, R.L., Hokanson, J.A., 1997. Osteosarcoma of the head and neck: meta-analysis of nonrandomized studies. *Laryngoscope* 107, 56–61. <https://doi.org/10.1097/00005537-199701000-00013>.
- Kaya, M., Wada, T., Akatsuka, T., Kawaguchi, S., Nagoya, S., Shindoh, M., Higashino, F., Mezawa, F., Okada, F., Ishii, S., 2000. Vascular endothelial growth factor expression in untreated osteosarcoma is predictive of pulmonary metastasis and poor prognosis. *Clin. Cancer Res. Off. J. Am. Assoc. Cancer Res.* 6, 572–577.
- Klussmann, J.P., Gültekin, E., Weissenborn, S.J., Wieland, U., Dries, V., Dienes, H.P., Eckel, H.E., Pfister, H.J., Fuchs, P.G., 2003. Expression of p16 protein identifies a distinct entity of tonsillar carcinomas associated with human papillomavirus. *Am. J. Pathol.* 162, 747–753. [https://doi.org/10.1016/S0002-9440\(10\)63871-0](https://doi.org/10.1016/S0002-9440(10)63871-0).
- Koirala, P., Roth, M.E., Gill, J., Piperdi, S., Chinai, J.M., Geller, D.S., Hoang, B.H., Park, A., Fremed, M.A., Zang, X., Gorlick, R., 2016. Immune infiltration and PD-L1 expression in the tumor microenvironment are prognostic in osteosarcoma. *Sci. Rep.* 6, 30093. <https://doi.org/10.1038/srep30093>.
- Kontio, R., Hagström, J., Lindholm, P., Böhlting, T., Sampo, M., Mesimäki, K., Saarihtai, K., Koivunen, P., Mäkitie, A.A., 2019. Craniomaxillofacial osteosarcoma - the role of surgical margins. *J. Cranio-Maxillo-fac. Surg. Off. Publ. Eur. Assoc. Cranio-Maxillo-fac. Surg.* <https://doi.org/10.1016/j.jcms.2019.03.020>.
- Koudougou, C., Bertin, H., Lecaplain, B., Badran, Z., Longis, J., Corre, P., Hoornaert, A., 2020. Postimplantation radiation therapy in head and neck cancer patients: literature review. *Head Neck* 42, 794–802. <https://doi.org/10.1002/hed.26065>.
- Kratz, C.P., Achatz, M.I., Brugières, L., Freiburg, T., Garber, J.E., Greer, M.L.-C., Hansford, J.R., Janeway, K.A., Kohlmann, W.K., McGee, R., Mullighan, C.G., Onel, K., Pajitler, K.W., Pfister, S.M., Savage, S.A., Schiffman, J.D., Schneider, K.A., Strong, L.C., Evans, D.G.R., Wasserman, J.D., Villani, A., Malkin, D., 2017. Cancer screening recommendations for individuals with Li-Fraumeni syndrome. *Clin. Cancer Res. Off. J. Am. Assoc. Cancer Res.* 23, e38–e45. <https://doi.org/10.1158/1078-0432.CCR-17-0408>.
- Lacour, B., Guyot-Goubin, A., Guissou, S., Bellec, S., Désandes, E., Clavel, J., 2010. Incidence of childhood cancer in France: national children Cancer registries, 2000–2004. *Eur. J. Cancer Prev. Off. J. Eur. Cancer Prev. Organ. ECP* 19, 173–181.
- Lai, Y., Wei, X., Lin, S., Qin, L., Cheng, L., Li, P., 2017. Current status and perspectives of patient-derived xenograft models in cancer research. *J. Hematol. Oncol. J. Hematol Oncol* 10, 106. <https://doi.org/10.1186/s13045-017-0470-7>.
- Lee, M.-H., Yang, H.-Y., 2003. Regulators of G1 cyclin-dependent kinases and cancers. *Cancer Metastasis Rev.* 22, 435–449. <https://doi.org/10.1023/a:1023785332315>.
- Lee, R.J., Arshi, A., Schwartz, H.C., Christensen, R.E., 2015. Characteristics and prognostic factors of osteosarcoma of the jaws: a retrospective cohort study. *JAMA Otolaryngol. Head Neck Surg.* 141, 470–477. <https://doi.org/10.1001/jamaoto.2015.0340>.
- Li, Y.-S., Liu, Q., Tian, J., He, H.-B., Luo, W., 2019. Angiogenesis process in osteosarcoma: an updated perspective of pathophysiology and therapeutics. *Am. J. Med. Sci.* 357, 280–288. <https://doi.org/10.1016/j.amjms.2018.12.004>.
- Limbach, A.L., Lingen, M.W., McElherne, J., Mashek, H., Fitzpatrick, C., Hyjek, E., Mostofi, R., Cipriani, N.A., 2020. The utility of MDM2 and CDK4 immunohistochemistry and MDM2 FISH in craniofacial osteosarcoma. *Head Neck Pathol.* <https://doi.org/10.1007/s12105-020-01139-x>.
- Lopes, M.A., Nikitakis, N.G., Ord, R.A., Sauk Jr., J., 2001. Amplification and protein expression of chromosome 12q13-15 genes in osteosarcomas of the jaws. *Oral Oncol.* 37, 566–571.
- Lu, W., Chao, T., Ruiqi, C., Juan, S., Zhihong, L., 2018. Patient-derived xenograft models in musculoskeletal malignancies. *J. Transl. Med.* 16 <https://doi.org/10.1186/s12967-018-1487-6>.
- Luetke, A., Meyers, P.A., Lewis, I., Juergens, H., 2014. Osteosarcoma treatment - where do we stand? A state of the art review. *Cancer Treat. Rev.* 40, 523–532. <https://doi.org/10.1016/j.ctrv.2013.11.006>.
- Lukas, J., Parry, D., Aagaard, L., Mann, D.J., Bartkova, J., Strauss, M., Peters, G., Bartek, J., 1995. Retinoblastoma-protein-dependent cell-cycle inhibition by the tumour suppressor p16. *Nature* 375, 503–506. <https://doi.org/10.1038/375503a0>.
- Mardanpour, K., Rahbar, M., Mardanpour, S., 2016. Coexistence of HER2, Ki67, and p53 in osteosarcoma: a strong prognostic factor. *North Am. J. Med. Sci.* 8, 210–214. <https://doi.org/10.4103/1947-2714.183013>.
- Mejía-Guerrero, S., Quejada, M., Gokgoz, N., Gill, M., Parkes, R.K., Wunder, J.S., Andrusis, L.L., 2010. Characterization of the 12q15 MDM2 and 12q13-14 CDK4 amplicons and clinical correlations in osteosarcoma. *Genes Chromosomes Cancer* 49, 518–525. <https://doi.org/10.1002/gcc.20761>.
- Mijiti, A., Kuerbantay, N., Zhang, Z.-Q., Su, M.Y., Zhang, X.H., Huojia, M., 2020. Influence of preoperative radiotherapy on head and neck free-flap reconstruction: systematic review and meta-analysis. *Head Neck.* <https://doi.org/10.1002/hed.26136>.
- Miller, C.W., Aslo, A., Won, A., Tan, M., Lampkin, B., Koeffler, H.P., 1996. Alterations of the p53, Rb and MDM2 genes in osteosarcoma. *J. Cancer Res. Clin. Oncol.* 122, 559–565.
- Mirabello, L., Zhu, B., Koster, R., Karlins, E., Dean, M., Yeager, M., Gianferante, M., Spector, L.G., Morton, L.M., Karyadi, D., Robison, L.L., Armstrong, G.T., Bhatia, S., Song, L., Pankratz, N., Pinheiro, M., Gastier-Foster, J.M., Gorlick, R., de Toledo, S.R. C., Petrilli, A.S., Patino-Garcia, A., Lecanda, F., Gutierrez-Jimeno, M., Serra, M., Hattinger, C., Picci, P., Scotlandi, K., Flanagan, A.M., Tirabosco, R., Amary, M.F., Kurucu, N., Ilhan, I.E., Ballinger, M.L., Thomas, D.M., Barkauskas, D.A., Mejia-Baltodano, G., Valverde, P., Hicks, B.D., Zhu, B., Wang, M., Hutchinson, A.A., Tucker, M., Sampson, J., Landi, M.T., Freedman, N.D., Gapstur, S., Carter, B., Hoover, R.N., Chanock, S.J., Savage, S.A., 2020. Frequency of pathogenic germline variants in cancer-susceptibility genes in patients with osteosarcoma. *JAMA Oncol.* <https://doi.org/10.1001/jamaoncol.2020.0197>.
- Miwa, S., Shirai, T., Yamamoto, N., Hayashi, K., Takeuchi, A., Igarashi, K., Tsuchiya, H., 2019. Current and emerging targets in immunotherapy for osteosarcoma. *J. Oncol.* 2019, 7035045. <https://doi.org/10.1155/2019/7035045>.
- Mohseny, A.B., Szuhai, K., Romeo, S., Buddingh, E.P., Briaire-de Bruijn, I., de Jong, D., van Pel, M., Cleton-Jansen, A.-M., Hogendoorn, P.C.W., 2009. Osteosarcoma originates from mesenchymal stem cells in consequence of aneuploidization and genomic loss of Cdkn2. *J. Pathol.* 219, 294–305. <https://doi.org/10.1002/path.2603>.
- Molony, P., Werner, R., Martin, C., Callanan, D., Nauta, I., Heidemann, D., Sheehan, P., Heffron, C., Feeley, L., 2020. The role of tumour morphology in assigning HPV status in oropharyngeal squamous cell carcinoma. *Oral Oncol.* 105, 104670. <https://doi.org/10.1016/j.oraloncology.2020.104670>.
- Morandi, F., Pistoia, V., 2014. Interactions between HLA-G and HLA-E in physiological and pathological conditions. *Front. Immunol.* 5 <https://doi.org/10.3389/fimmu.2014.00394>.
- Mosconi, C., Arantes, D.A.C., Gonçalves, A.S., Alencar, R. de C.G., Oliveira, J.C., Silva, T. A., Mendonça, E.F., Batista, A.C., 2017. Immunohistochemical investigations on the expression of programmed cell death ligand 1, human leukocyte antigens G and E, and granzyme B in intraoral mucoepithelial carcinoma. *Arch. Oral Biol.* 83, 55–62. <https://doi.org/10.1016/j.archoralbio.2017.07.004>.
- Nanni, P., Landuzzi, L., Manara, M.C., Righi, A., Nicoletti, G., Cristalli, C., Pasello, M., Parra, A., Carrabotta, M., Ferracin, M., Palladini, A., Ianzano, M.L., Giusti, V., Ruzzi, F., Magnani, M., Donati, D.M., Picci, P., Lollini, P.-L., Scotlandi, K., 2019. Bone sarcoma patient-derived xenografts are faithful and stable preclinical models for molecular and therapeutic investigations. *Sci. Rep.* 9, 12174. <https://doi.org/10.1038/s41598-019-48634-y>.
- Nissanka, E.H., Amarantunge, E.A.P.D., Tilakaratne, W.M., 2007. Clinicopathological analysis of osteosarcoma of jaw bones. *Oral Dis.* 13, 82–87. <https://doi.org/10.1111/j.1601-0825.2006.01251.x>.
- Oliveira, P., Nogueira, M., Pinto, A., Almeida, M.O., 1997. Analysis of p53 expression in osteosarcoma of the jaw: correlation with clinicopathologic and DNA ploidy findings. *Hum. Pathol.* 28, 1361–1365. [https://doi.org/10.1016/s0046-8177\(97\)90224-0](https://doi.org/10.1016/s0046-8177(97)90224-0).
- Ottaviani, G., Jaffe, N., 2009. The epidemiology of osteosarcoma. *Cancer Treat. Res.* 152, 3–13. [https://doi.org/10.1007/978-1-4419-0284-9\\_1](https://doi.org/10.1007/978-1-4419-0284-9_1).
- Park, H.-R., Cabrin, R.L., Araujo, E.S., Paparella, M.L., Brandizzi, D., Park, Y.-K., 2009. Expression of ezrin and metastatic tumor antigen in osteosarcomas of the jaw. *Tumori* 95, 81–86.
- Patel, S.G., Meyers, P., Huvos, A.G., Wolden, S., Singh, B., Shaha, A.R., Boyle, J.O., Pfister, D., Shah, J.P., Kraus, D.H., 2002. Improved outcomes in patients with osteogenic sarcoma of the head and neck. *Cancer* 95, 1495–1503. <https://doi.org/10.1002/cncr.10849>.
- Perry, J.A., Kiezun, A., Tonzi, P., Van Allen, E.M., Carter, S.L., Baca, S.C., Cowley, G.S., Bhatt, A.S., Rheinbay, E., Pedamallu, C.S., Helman, E., Taylor-Weiner, A., McKenna, A., DeLuca, D.S., Lawrence, M.S., Ambrogio, L., Sougnez, C., Sivachenko, A., Walensky, L.D., Wagle, N., Mora, J., de Torres, C., Lavarino, C., Dos Santos Aguiar, S., Yunes, J.A., Brandalise, S.R., Mercado-Celis, G.E., Melendez-Zajgla, J., Cárdenas-Cárdos, R., Velasco-Hidalgo, L., Roberts, C.W.M., Garraway, L. A., Rodriguez-Galindo, C., Gabriel, S.B., Lander, E.S., Golub, T.R., Orkin, S.H., Getz, G., Janeway, K.A., 2014. Complementary genomic approaches highlight the PI3K/mTOR pathway as a common vulnerability in osteosarcoma. *Proc. Natl. Acad. Sci. U. S. A.* 111, E5564–E5573. <https://doi.org/10.1073/pnas.1419260111>.
- Petrovic, I., Ahmed, Z.U., Hay, A., Rosen, E.B., Lu, C., Hameed, M., Shah, J.P., 2019. Sarcomas of the mandible. *J. Surg. Oncol.* <https://doi.org/10.1002/jso.25477>.
- Piperno-Neumann, S., Ray-Coquard, I., Occean, B.-V., Laurence, V., Cupissol, D., Perrin, C., Penel, N., Bompas, E., Rios, M., Le Cesne, A., Italiano, A., Anract, P., de Pinieux, G., Collard, O., Bertucci, F., Duffaud, F., Le Deley, M.-C., Delaye, J., Brugières, L., Blay, J.-Y., 2020. Results of API-AI based regimen in osteosarcoma adult patients included in the French OS2006/Sarcome-09 study. *Int. J. Cancer* 146, 413–423. <https://doi.org/10.1002/ijc.32526>.
- Qu, Y., Xu, J., Jiang, T., Zhao, H., Gao, Y., Zheng, C., Shi, X., 2011. Difference in pre- and postchemotherapy vascular endothelial growth factor levels as a prognostic indicator in osteosarcoma. *J. Int. Med. Res.* 39, 1474–1482. <https://doi.org/10.1177/147323001103900436>.
- Rossi, B., Schinzari, G., Maccauro, G., Scaramuzza, L., Signorelli, D., Rosa, M.A., Fabriciani, C., Carlo, B., 2010. Neoadjuvant multidrug chemotherapy including high-dose methotrexate modifies VEGF expression in osteosarcoma: an immunohistochemical analysis. *BMC Musculoskelet. Disord.* 11, 34. <https://doi.org/10.1186/1471-2474-11-34>.
- Rubio, R., Abarrategi, A., Garcia-Castro, J., Martinez-Cruzado, L., Suarez, C., Tornin, J., Santos, L., Astudillo, A., Colmenero, I., Mulero, F., Rosu-Myles, M., Menendez, P., Rodriguez, R., 2014. Bone environment is essential for osteosarcoma development

- from transformed mesenchymal stem cells. *Stem Cells Dayt.* Ohio 32, 1136–1148. <https://doi.org/10.1002/stem.1647>.
- Scotlandi, K., Hattinger, C.M., Pellegrini, E., Gambarotti, M., Serra, M., 2020. Genomics and therapeutic vulnerabilities of primary bone tumors. *Cells* 9. <https://doi.org/10.3390/cells9040968>.
- Smeele, L.E., Snow, G.B., van der Waal, I., 1998. Osteosarcoma of the head and neck: meta-analysis of the nonrandomized studies. *Laryngoscope* 108, 946. <https://doi.org/10.1097/00005537-199806000-00030>.
- Smith, R.B., Apostolakis, L.W., Karnell, L.H., Koch, B.B., Robinson, R.A., Zhen, W., Menck, H.R., Hoffman, H.T., 2003. National Cancer Data Base report on osteosarcoma of the head and neck. *Cancer* 98, 1670–1680. <https://doi.org/10.1002/ncr.11716>.
- Sundara, Y.T., Kostine, M., Cleven, A.H.G., Bovée, J.V.M.G., Schilham, M.W., Cleton-Jansen, A.-M., 2017. Increased PD-L1 and T-cell infiltration in the presence of HLA class I expression in metastatic high-grade osteosarcoma: a rationale for T-cell-based immunotherapy. *Cancer Immunol. Immunother.* CII 66, 119–128. <https://doi.org/10.1007/s00262-016-1925-3>.
- Surget, S., Khoury, M.P., Bourdon, J.-C., 2013. Uncovering the role of p53 splice variants in human malignancy: a clinical perspective. *OncoTargets Ther.* 7, 57–68. <https://doi.org/10.2147/OTT.S53876>.
- Tabareau-Delalande, F., Collin, C., Gomez-Brouchet, A., Bouvier, C., Decouvelaere, A.-V., de Muret, A., Pagès, J.-C., de Pinieux, G., 2015. Chromosome 12 long arm rearrangement covering MDM2 and RASAL1 is associated with aggressive craniofacial juvenile ossifying fibroma and extracranial psammomatoid fibro-osseous lesions. *Mod. Pathol. Off. J. U. S. Can. Acad. Pathol. Inc* 28, 48–56. <https://doi.org/10.1038/modpathol.2014.80>.
- Tang, Y., Yang, C., Guo, Z., Fu, Y., Yu, X., Liu, B., Zhou, H., Wang, J., Li, W., Pang, Q., 2017. P16 protein expression as a useful predictive biomarker for neoadjuvant chemotherapy response in patients with high-grade osteosarcoma: a systematic meta-analysis under guideline of PRISMA. *Medicine (Baltimore)* 96, e6714. <https://doi.org/10.1097/MD.00000000000006714>.
- Thariat, J., Julieron, M., Brouchet, A., Italiano, A., Schouman, T., Marcy, P.-Y., Odin, G., Lacout, A., Dassonville, O., Peyrottes-Birstwiesles, I., Miller, R., Thyss, A., Isambert, N., 2012. Osteosarcomas of the mandible: are they different from other tumor sites? *Crit. Rev. Oncol. Hematol.* 82, 280–295. <https://doi.org/10.1016/j.critrevonc.2011.07.001>.
- Thariat, J., Schouman, T., Brouchet, A., Sarini, J., Miller, R.C., Reycher, H., Ray-Coquard, I., Italiano, A., Verite, C., Sohawon, S., Bompas, E., Dassonville, O., Salas, S., Aldabbagh, K., Maingon, P., de La MotteRouge, T., Kurtz, J.E., Usseglio, J., Kerbrat, P., Raoul, G., Lotz, J.P., Bar-Sela, G., Brugières, L., Chaigneau, L., Saada, E., Odin, G., Marcy, P.Y., Thyss, A., Julieron, M., 2013. Osteosarcomas of the mandible: multidisciplinary management of a rare tumor of the young adult a cooperative study of the GSF-GETO, Rare Cancer network, GETTEC/REFCOR and SFCE. *Ann. Oncol. Off. J. Eur. Soc. Med. Oncol. ESMO* 24, 824–831. <https://doi.org/10.1093/annonc/mds507>.
- Toguchida, J., Yamaguchi, T., Ritchie, B., Beauchamp, R.L., Dayton, S.H., Herrera, G.E., Yamamuro, T., Kotoura, Y., Sasaki, M.S., Little, J.B., 1992. Mutation spectrum of the p53 gene in bone and soft tissue sarcomas. *Cancer Res.* 52, 6194–6199.
- van den Berg, H., Merks, J.H.M., 2013. Incidence and grading of cranio-facial osteosarcomas. *Int. J. Oral Maxillofac. Surg.* <https://doi.org/10.1016/j.ijom.2013.06.017>.
- Versleijen-Jonkers, Y.M.H., Vlenterie, M., van de Luijngaarden, A.C.M., van der Graaf, W. T.A., 2014. Anti-angiogenic therapy, a new player in the field of sarcoma treatment. *Crit. Rev. Oncol. Hematol.* 91, 172–185. <https://doi.org/10.1016/j.critrevonc.2014.02.001>.
- Wadayama, B., Toguchida, J., Shimizu, T., Ishizaki, K., Sasaki, M.S., Kotoura, Y., Yamamuro, T., 1994. Mutation spectrum of the retinoblastoma gene in osteosarcomas. *Cancer Res.* 54, 3042–3048.
- Wagner, F., Holzappel, B.M., Thibaudeau, L., Straub, M., Ling, M.-T., Grifka, J., Loessner, D., Lévesque, J.-P., Hutmacher, D.W., 2016. A validated preclinical animal model for primary bone tumor research. *J. Bone Joint Surg. Am.* 98, 916–925. <https://doi.org/10.2106/JBJS.15.00920>.
- Wang, X., Wang, D., Yuan, N., Liu, F., Wang, F., Wang, B., Zhou, D., 2017. The prognostic value of PCNA expression in patients with osteosarcoma: a meta-analysis of 16 studies. *Medicine (Baltimore)* 96, e8254. <https://doi.org/10.1097/MD.00000000000008254>.
- Wittrant, Y., Théoleyre, S., Chipoy, C., Padrines, M., Blanchard, F., Heymann, D., Rédini, F., 2004. RANKL/RANK/OPG: new therapeutic targets in bone tumours and associated osteolysis. *Biochim. Biophys. Acta* 1704, 49–57. <https://doi.org/10.1016/j.bbcan.2004.05.002>.
- Wunder, J.S., Eppert, K., Burrow, S.R., Gokgoz, N., Bell, R.S., Andrulis, I.L., Gokgoz, N., 1999. Co-amplification and overexpression of CDK4, SAS and MDM2 occurs frequently in human parosteal osteosarcomas. *Oncogene* 18, 783–788. <https://doi.org/10.1038/sj.onc.1202346>.
- Wunder, J.S., Gokgoz, N., Parkes, R., Bull, S.B., Eskandarian, S., Davis, A.M., Beauchamp, C.P., Conrad, E.U., Grimer, R.J., Healey, J.H., Malkin, D., Mangham, D. C., Rock, M.J., Bell, R.S., Andrulis, I.L., 2005. TP53 mutations and outcome in osteosarcoma: a prospective, multicenter study. *J. Clin. Oncol. Off. J. Am. Soc. Clin. Oncol.* 23, 1483–1490. <https://doi.org/10.1200/JCO.2005.04.074>.
- Xie, L., Ji, T., Guo, W., 2017. Anti-angiogenesis target therapy for advanced osteosarcoma (Review). *Oncol. Rep.* 38, 625–636. <https://doi.org/10.3892/or.2017.5735>.
- Yoshida, A., Ushiku, T., Motoi, T., Shibata, T., Beppu, Y., Fukayama, M., Tsuda, H., 2010. Immunohistochemical analysis of MDM2 and CDK4 distinguishes low-grade osteosarcoma from benign mimics. *Mod. Pathol. Off. J. U. S. Can. Acad. Pathol. Inc* 23, 1279–1288. <https://doi.org/10.1038/modpathol.2010.124>.

**Dr Hélio Bertin** is a French medical doctor specialized in oral and maxillo-facial surgery in adult and children. His research focuses on the microenvironment of primary bone tumors of the jaws, in particular osteosarcoma.

**Pr Anne Gomez-Brouchet** is a medical doctor in human pathology. She is specialized in the diagnosis and research on primary bone tumors.

**Dr Françoise Rédini** is a biomedical expert in biology, biochemistry and chemical medicine. She is the head of a French academic research unit on primary malignant bone tumors.