



**HAL**  
open science

## Methylprednisolone-related liver injury: A descriptive study using the French pharmacovigilance database

Judith Cottin, Sabrina Pierre, Véronique Pizzoglio, Corinne Simon, Geneviève Durrieu, Nathalie Bleyzac, Aurore Gouraud, Jérôme Dumortier

### ► To cite this version:

Judith Cottin, Sabrina Pierre, Véronique Pizzoglio, Corinne Simon, Geneviève Durrieu, et al.. Methylprednisolone-related liver injury: A descriptive study using the French pharmacovigilance database. *Clinics and Research in Hepatology and Gastroenterology*, 2020, 44, pp.662 - 673. 10.1016/j.clinre.2019.12.008 . hal-03493827

**HAL Id: hal-03493827**

**<https://hal.science/hal-03493827>**

Submitted on 17 Oct 2022

**HAL** is a multi-disciplinary open access archive for the deposit and dissemination of scientific research documents, whether they are published or not. The documents may come from teaching and research institutions in France or abroad, or from public or private research centers.

L'archive ouverte pluridisciplinaire **HAL**, est destinée au dépôt et à la diffusion de documents scientifiques de niveau recherche, publiés ou non, émanant des établissements d'enseignement et de recherche français ou étrangers, des laboratoires publics ou privés.



Distributed under a Creative Commons Attribution - NonCommercial 4.0 International License



26 **Key words:** liver injury; methylprednisolone; pharmacovigilance; safety

27

28 **Key points:**

29 Intravenous methylprednisolone causality should be considered in case of acute liver injury

30 Liver injury was mainly hepatocellular

31 Data for oral methylprednisolone is insufficient to draw any conclusion

32 Systematic liver monitoring for high-dose intravenous methylprednisolone may be of value

33

34 **Number of words:** 2406 words

35

36 **Statement about prior postings and presentations:**

37 This manuscript has not been previously published except in the form of an abstract that

38 appeared in Drug Safety 2018; 41 (11): 1167 (Abstract 119).

39 **Abstract:**

40 **Purpose:** Hepatotoxicity associated with methylprednisolone (MP) is rarely reported in the  
41 literature. The aim of the present study was to review the characteristics of acute liver injury  
42 associated with intravenous (IV) or oral MP registered in the French pharmacovigilance  
43 database (FPD).

44 **Methods:** All cases with MP coded as suspected, concomitant, or interacting drug associated  
45 with liver injury as the adverse effect reported up to May 2016 were extracted from the FPD.  
46 Cases were identified using the “Drug related hepatic disorders” Standard Medical Query.

47 **Results:** A total of 97 cases of liver injury associated with MP were analysed; 58.8% were  
48 women and the median age was 46 years (range: 1-91). MP was used for an autoimmune  
49 disease in 47.6% of cases including 26 cases of multiple sclerosis, and was IV in 79.4% of  
50 cases. Nearly three-quarters of patients (73,2%) had a hepatocellular type of injury, the  
51 severity of which was mainly mild (45%) or moderate (31%). Most patients (92%)  
52 spontaneously and fully recovered within a mean 38.4 days. A rechallenge using the IV route  
53 was performed in 13 patients and for 10 (76.9%) this was positive (the initial type of injury  
54 was hepatocellular for all these cases). Regarding IV route of administration (n=77), MP was  
55 coded as the only suspected drug in 22% of cases.

56 **Discussion:** The results suggest that IV MP causality should be considered in case of acute  
57 liver injury while data for oral MP is insufficient; systematic liver monitoring for high-dose  
58 IV MP may be recommended.

59

60

61 **Introduction**

62 Glucocorticoids are compounds that have long been used for a variety of diseases, both as  
63 chronic therapy and in acute cases. Methylprednisolone (MP) pulses are recommended for  
64 critical events that require urgent treatment for an exacerbation of a known disease or when  
65 vital organs are compromised <sup>(1)</sup>.

66 Although generally well tolerated, several side effects are attributed to MP, many of which  
67 are dose and duration dependent <sup>(2)</sup>. Before June 2018, the summary of product characteristics  
68 for MP mentioned transient increase in serum liver enzyme levels and hepatomegaly, but not  
69 clinically relevant hepatotoxicity <sup>(3)</sup>. However, over the past 20 years, many case reports of  
70 hepatotoxicity induced by MP and a few case series have been published <sup>(3-26)</sup>; all concerned  
71 the use of high-dose intravenous (IV) MP, mainly in patients with multiple sclerosis or  
72 Basedow disease. MP-induced seems rare, but the reintroduction of this drug in the majority  
73 of reported cases illustrates the under-recognition of this effect.

74 In 2016, a case of high-dose MP-induced acute hepatitis in a 27-year-old with multiple  
75 sclerosis notified to the pharmacovigilance centre of Lyon (France) <sup>(8)</sup> led us to retrospectively  
76 analyse all cases of liver damage associated with the use of IV or oral MP registered in the  
77 French pharmacovigilance database (FPVD); a particular focus was made on the route of MP  
78 administration.

## 79 **Methods**

80 This study was performed in the FPVD, in which spontaneously reported cases have been  
81 registered since 1985 by 31 French pharmacovigilance centres. The present dataset analysis  
82 was approved by 31 regional pharmacovigilance centres and the French medicines agency  
83 (*Agence nationale de sécurité du médicament et des produits de santé*, ANSM), which  
84 manages the database and helped us with data extraction.

85 For each reported ADR, information on patient (e.g. age, gender), description of the ADR  
86 (e.g. date of occurrence, progression) and drug exposure (e.g. dates of introduction and  
87 withdrawal, dose) are recorded in the FPVD, along with a summary of the clinical report. The  
88 regional pharmacovigilance centre analyses each ADR (coded according to the Medical  
89 Dictionary for Regulatory Activities, MedDRA – version 21 <sup>(28)</sup>) and evaluates the  
90 relationship between drugs and ADR. For each report, causality is assessed according to the  
91 French national pharmacovigilance system's standard procedure <sup>(29)</sup>. If a drug is considered  
92 probably responsible for the ADR, it is defined as “suspect”; if not, it is defined as  
93 “concomitant”. If an ADR is considered probably caused by drug-drug interaction, drugs are  
94 coded as “interacting” drugs. An ADR is categorized as “serious” when it leads to  
95 hospitalization or prolongation of hospitalization, permanent disability/incapacity, is life-  
96 threatening, or leads to the death of the patient. Concerning outcome, a favourable outcome of  
97 ADR is defined as full or on-going recovery at the time of notification

### 98 *Selection of cases*

99 All cases with MP coded as suspected, concomitant, or interacting drug associated with liver  
100 injury as ADR reported since 1985 up to 22 May 2016 were extracted from the FPVD. Cases  
101 were identified using the broad-ranging “Drug related hepatic disorders” standardized

102 MedDRA Query (SMQ); this was chosen so as not to omit cases of liver injury coded under  
103 another MedDRA term.

104 Selected cases were then checked individually by a pharmacologist, irrespective of the level  
105 of MP causality and filtered by applying the following exclusion criteria: MP associated with  
106 any cytotoxic agent in cancer protocols, cases other than liver injury, cases with a possible  
107 other cause, chronology of events incompatible with MP causality (MP intake occurring after  
108 liver injury), cases insufficiently documented.

#### 109 *Liver injury criteria*

110 Diagnosis criteria described by Aithal *et al.*, considering transaminase above 5N as clinically  
111 significant, were used <sup>(30)</sup>. We also used their classification of liver injuries into 4 grades of  
112 severity (Table 1) and only retained grade  $\geq 1$  cases. When laboratory normal values of liver  
113 enzymes were not documented, the following were used: alanine aminotransferase (ALT) [10-  
114 50 UI/l], alkaline phosphatase (ALP) [0-120 UI/l], total bilirubin [5-17  $\mu\text{mol/l}$ ].

115 The type of liver injury was defined according the ratio  $R = \text{ALT}/\text{ALP}$ :  $R \geq 5$  for hepatocellular  
116 pattern,  $R \leq 2$  for cholestasis pattern,  $2 < R < 5$  for mixed liver injury <sup>(31)</sup>. When R could not  
117 be calculated, information was drawn from MedDRA codes or the narrative.

118

119 **Results**

120 The first search using the “drug induced liver disorders” SMQ found 414 cases; among these  
121 97 were included in the final analysis (Figure 1).

122 *Demographic data*

123 Among the 97 patients, 58.8% were female (sex ratio H/F: 0.7) and the mean age was 45.7  
124 years (SD=18.3); patients were most frequently aged 40-49 and 50-59 years. The most  
125 frequent route of MP administration was IV (79.4%) followed by the oral route (17.5%); the  
126 intramuscular route concerned 3 cases (3.1%). The most frequent MP indication was multiple  
127 sclerosis (26.8%), followed by other auto-immune diseases (20.6%, including thyroiditis,  
128 polyarthritis, alopecia areata, Crohn’s disease...; Table 2).

129 *Characteristics of liver injuries*

130 The most frequent type of liver injury was hepatocellular (73.2%), and most cases were of  
131 grade 1 (45.4%) or 2 (30.9%) irrespective of injury type; higher grades ( $\geq 3$ ) were found in 6  
132 cases (Table 3) :

133 - fulminant hepatitis (prothrombin rate 27 %) which recovered spontaneously but slowly after  
134 stopping suspected drugs (amoxicillin/clavulanic acid and IV MP)

135 - cholestasis and decreased prothrombin rate in a patient treated by oral MP for 3 months.

136 Liver recovered after stopping all the drugs recently introduced excepted MP.

137 - severe liver cytolysis (prothrombin rate 32%, factor V 37%, transaminases x30 N) after the  
138 third course of MP for alopecia aerata

139 - severe liver deficiency with encephalopathy and hypovolemic shock, leading to death,  
140 occurring 3 weeks after one dose of cyclophosphamide and a course of IV MP for multiple  
141 sclerosis



142 - severe liver deficiency thirteen days after the patient received piperacillin/tazobactam,  
143 tobramycin, ciprofloxacin and IV MP.

144 - hepatocellular failure 2 months after the 4th course of IV MP for alopecia aerata. The  
145 evolution was not known.

146

#### 147 *Outcomes*

148 Favourable outcome (n=82) was observed for 92% of cases with known outcome (n=89).

149 Deaths were reported in 3 cases, 2 of which had multiple potent causes and could not be

150 reliably attributed to MP. The first one was a patient with metastatic prostate cancer,

151 hospitalised for bilateral bronchopneumopathy, presenting with hepatocellular liver injury 3

152 days after administration of IV MP (120 mg/d), leading to death 5 days later; other drugs,

153 including leuprorelin, paracetamol, morphine, ofloxacin, ceftriaxone, and midazolam, could

154 be suspected. The second case was a patient with progressive glioma who presented with

155 hepatitis 21 days after initiation of oral MP (100 mg/day); other drugs could also have been

156 responsible for liver injury, including temozolomide, esomeprazole, and levetiracetam. The

157 third case was woman presenting with acute hepatocellular liver injury, occurring 3 weeks

158 after one dose of cyclophosphamide and a course of IV MP for multiple sclerosis; this rapidly

159 progressed to severe liver deficiency with encephalopathy and hypovolemic shock, leading to

160 death. According to the time to onset after cyclophosphamide introduction only MP was

161 retained as the suspect drug. In addition, 4 patients did not recover at the time of last follow-

162 up (one month), which was too short to draw any conclusion.

163

#### 164 *Intravenous MP*

165 Among the 77 (79.4%) cases in which MP was used intravenously it was the only suspected

166 drug in 17 cases (22%), making causality more probable. Liver injuries occurred a median 9.5

167 days (range: 1-267 days) after starting MP treatment. Moreover, 46.8% of liver injuries  
168 (n=36) were observed >24 hours after the end of MP course. The median number of MP  
169 courses before the first liver event was 1 (range: 0-35), the median cumulative dose (since the  
170 first dose of MP) was 2 g (range: 0.06-42.7), and 23 patients developed liver toxicity after  
171 the first exposure of IV MP. When available, the daily dose at the moment of liver injury was  
172 <100 mg for 16 patient, included between 100 mg and 1 g for 18 patients, <1 g for 23 patients  
173 and > 2g for 1 patient (median daily dose 500 mg (range 10-3000 mg)).

174 The distribution of liver injury types was similar to that observed in the total population  
175 analysis: 79.2% hepatocellular and 11.7 % of both cholestasis and hepatocellular. Most cases  
176 were of grade 1 (45.5%, n=35) or 2 (28.6%, n=22) irrespective of injury type; higher grades  
177 ( $\geq 3$ ) were found in 5 cases (Table 3).

178 Clinical signs were observed in 18 cases (23.3%) and were mainly asthenia (27.8%) and  
179 digestive disorders (38.9%). Among the 38 cases with data available the duration of liver  
180 injury was a median of 38 days (range: 4-140 days); two of these patients died, but only one  
181 death could be related to MP (see above).

182 Liver biopsy was performed in 13 patients (16.9%). It was not contributory in 2 cases and  
183 found mainly fibrosis (n=1), necrosis (n=1), lymphocytic infiltrate (n=2), undefined infiltrate  
184 (n=2), inflammatory disorders (n=1). In 2 cases, histology was compatible with autoimmune  
185 hepatitis despite a negative auto-immune blood tests, but also with a toxic event for one of  
186 them owing to centrolobular damage and eosinophils. Non drug-related causes were  
187 investigated in 51 cases (66.2%), without success: viral serology was measured in 43 cases  
188 (all were negative), abdominal ultrasound was performed in 36 cases (all without  
189 abnormalities), and auto-immune blood tests in 17 cases (all negative).

190 Data regarding MP rechallenge were available for 19 patients (24.7%); MP was not re-  
191 introduced for 6 patients, and was re-introduced for 13 patients. Among the latter, 10 had a

192 new episode of liver injury (76.9%). One recurrence was reported for 5 patients, and  $\geq 2$   
193 recurrences for the remaining 5 patients (4 in one patient); there were a total 18 recurrences in  
194 10 patients. All recurrences were hepatocellular liver injury (which was the initial injury for  
195 all patients concerned) and the grade was the same in all but one patient who had severe liver  
196 deficiency (prothrombin rate 36%) after the second MP course. Autoimmune blood tests were  
197 positive, and histology was compatible with autoimmune hepatitis. Liver recovered without  
198 specific treatment in all patients in whom a recurrence was reported (n=10). In one case of  
199 recurrence, a lower single dose of MP was re-introduced, and for a second case MP was re-  
200 introduced orally.

201

#### 202 *Oral MP*

203 Among the 17 (17.5%) cases in which MP was used orally, 52.9% (n=9) of liver injuries were  
204 hepatocellular and 29.4% (n=5) were mixed. Most cases were of grade 1 (n=7, 41.2%) or 2  
205 (n=8, 47%). Only one case could be classified as severe, with a decreased prothrombin rate  
206 (value unknown) (Table 3). Clinical signs were mentioned in 7 cases (31.2%) and were  
207 digestive disorders in 57.1% (n=4).

208 Liver injuries occurred a median 13 days (range: 2-3360) after starting MP treatment, or 2 to  
209 15 days from MP discontinuation in 6 cases. The median cumulative dose before liver injury  
210 was 0.864 g (range: 0.004-3). When available, the daily dose at the moment of liver injury  
211 was <10mg for 1 patient, included between 20 and 50 mg for 5 patients and > 50mg for 2  
212 patients (median daily dose 40 mg (range 4-240 mg) . Among the 16 for whom MP was  
213 continued and who had outcome data, 6 (37.5%) recovered without sequelae. No positive re-  
214 introduction of MP was reported.

215 In the majority of cases (94.1%), MP was associated to at least one other drug classified as  
216 chronologically suspect: 8 cases with antibiotics (47.1%), 3 cases with temozolomide

217 (17.6%). Viral serology, abdominal ultrasound, autoimmune blood tests were negative  
218 (47.1%).

219 MP was the only suspected drug and the only potent cause of liver injury in one case: a 26-  
220 year-old woman receiving MP (daily dose not available) for Gougerot-Sjogren disease and  
221 who presented with hepatocellular liver injury 3 days after treatment initiation. One month  
222 previously, she had corticosteroids (unknown drug name) which were discontinued after 6  
223 days owing to abnormal serum liver enzymes (without any further detail). Histology at the  
224 time of this event was found to be compatible with toxic hepatitis. The patient later had a  
225 similar event without any drug exposure. Prednisolone was re-introduced later and was well  
226 tolerated.

227

## 228 **Discussion**

229 The present study found that liver injury associated with MP was more frequently reported  
230 with MP administered intravenously. A majority were female and this is probably due to the  
231 indication of MP (multiple sclerosis in over a quarter of cases). For nearly three-quarters of  
232 patients liver injury was hepatocellular, the severity of which was mainly evaluated as mild or  
233 moderate. Most patients spontaneously and fully recovered, and, among the 3 deaths reported,  
234 only one could be reliably related to MP. Mortality herein was thus 1%, which is concordant  
235 with a previously published observational study <sup>(33)</sup>. The responsibility of IV MP was  
236 supported by 10 cases of positive re-introduction or the absence of other suspected drugs in  
237 nearly a quarter of cases. With regards to MP delivered via the oral route, it is difficult to  
238 draw any conclusion as many other suspect drugs were associated with MP and there was no  
239 case of re-introduction. It is of note that the summary of product characteristics have been  
240 recently updated to consider this adverse reaction <sup>(3)</sup>.

241 The results are consistent with the 38 published cases of MP-related liver injuries <sup>(4-7,10-</sup>  
242 <sup>23,25,26,32,34-36)</sup> (Table 4). These were reported between 2000 and 2018, and the main  
243 indications were auto-immune (multiple sclerosis, n=25, 64.1%; Basedow ophthalmopathy,  
244 n=10, 28.2%), patients were aged from 11 to 71 years, and the majority were female (n=31,  
245 79.5%). This can be explained by the high incidence of MS and thyroid disorders among  
246 women <sup>(37)</sup>. Most received high-dose IV MP pulse therapy; only in two cases MP was  
247 administered orally. Clinical presentation varied from isolated increase in transaminases to  
248 fulminant hepatitis, with fatal outcome in 4 cases <sup>(22,32)</sup>. The time to liver injury onset varied  
249 greatly, occurring during MP treatment up to a few days to several months after the end of  
250 pulse therapy. There were 13 cases of re-introduction (all IV), 12 of which were positive,  
251 strengthening the causal link, in particular for IV MP. These positive rechallenges occurred  
252 between a few weeks <sup>(7,16)</sup> and several years (1 to 4 years) <sup>(4,5,10,11,18,25,34)</sup> after the last liver

253 injury event. As found herein, MP dosage regimens varied, making it difficult to evaluate the  
254 correlation between the treatment duration or the cumulative dose and the risk for liver injury.  
255 However, published data does suggest a dose effect, and in particular for IV MP. For instance,  
256 in a prospective observational study that included 29 patients with Graves' ophthalmopathy  
257 with either dysthyroid optic neuropathy (treated with high-dose IV MP) or moderately severe  
258 disease (low-dose IV MP) and followed for 24 weeks, AST and ALT were increased in 38%  
259 of the high-dose group, and 14% of the low-dose group (relative risk: 1.8, 95% CI [1.2; 2.6])  
260 <sup>(38)</sup>. A similar finding was found in a study conducted in the World Health Organization  
261 database; liver injuries occurred in 3.6% of those receiving high-doses IV MP ( $\geq 2\text{g}$ ) *versus*  
262 0.9% of those receiving low-doses ( $\leq 1\text{g}$ ) <sup>(39)</sup>.

263 Some authors have proposed a systematic monitoring of liver enzymes during and after the  
264 administration of MP bolus <sup>(7,38)</sup>, because of the delayed discovering of the liver injury. In our  
265 study, liver injuries were discovered after discontinuation of MP in 46.8% of patients  
266 receiving MP intravenously and in 35.3% patients receiving MP orally. In the setting of long  
267 treatment protocols, such as for thyroid-induced orbitopathy for which weekly MP infusions  
268 (500 mg) are given for 6 weeks, followed by another 6 weeks at 250 mg <sup>(40)</sup>, early  
269 identification during treatment of increased liver function test values may allow prompt  
270 withdrawal of MP. Conversely, the treatment protocol for multiple sclerosis is 1g daily for 3  
271 days, and changes in liver function tests were generally discovered when patients had  
272 symptoms, late after MP administration. For both situations, therefore, performing liver  
273 function test routinely during MT administration could be beneficial, as the timely recognition  
274 of this complication and early drug withdrawal may prevent progression of necrosis hepatic  
275 injury. In general, monitoring of liver enzymes can be provided during and after treatment.  
276 This would make it possible to better document these cases of liver damage and the  
277 responsibility of MP. Considering the appreciable number of positive rechallenge, prescribers

278 should be informed about the possible and delayed toxic effect of MP to avoid re-introduction  
279 as very severe liver failure is possible although not frequent. In any case, liver function test  
280 should be performed systematically in case of symptoms.

281 The mechanism of methylprednisolone-induced liver injury is unclear due to the small  
282 number of reported cases. Use of steroids may cause three forms of hepatic injury: steatosis/  
283 steatohepatitis, hepatitis B virus reactivation and DILI (drug-induced liver injury) (41).  
284 However, the cases in our study or those found in the literature do not support viral  
285 reactivation or steatosis. The cause of this apparent hepatotoxicity it may represent severe  
286 autoimmune hepatitis triggered by the sudden profound immunosuppression and subsequent  
287 immune reconstitution (26).

## 288 **Conclusion** 289

290 In conclusion, the results suggest that IV MP causality should be considered in case of acute  
291 liver injury while data for oral MP is insufficient. It would be interesting to further investigate  
292 the value of systematic liver monitoring for high-dose IV MP.

## 293 294 **Acknowledgements**

295 We thank Philip Robinson (DRCI, Hospices Civils de Lyon) for help in manuscript  
296 preparation.

297

298 **References:**

- 299 1. Bone RC, Fisher CJ, Clemmer TP, Slotman GJ, Metz CA, Balk RA. A controlled clinical trial of high-  
300 dose methylprednisolone in the treatment of severe sepsis and septic shock. *N Engl J Med.* 10  
301 sept 1987;317(11):653-8.
- 302 2. McDonough AK, Curtis JR, Saag KG. The epidemiology of glucocorticoid-associated adverse  
303 events. *Curr Opin Rheumatol.* mars 2008;20(2):131-7.
- 304 3. Résumé des caractéristiques du produit - METHYLPREDNISOLONE MYLAN 1 g, poudre pour  
305 solution injectable (IV) - Base de données publique des médicaments [Internet]. [cité 30 janv  
306 2019]. Disponible sur: [http://base-donnees-](http://base-donnees-publique.medicaments.gouv.fr/affichageDoc.php?specid=63341221&typedoc=R)  
307 [publique.medicaments.gouv.fr/affichageDoc.php?specid=63341221&typedoc=R](http://base-donnees-publique.medicaments.gouv.fr/affichageDoc.php?specid=63341221&typedoc=R)
- 308 4. Carrier P, Godet B, Crepin S, Magy L, Debette-Gratien M, Pillegand B, et al. Acute liver toxicity  
309 due to methylprednisolone: Consider this diagnosis in the context of autoimmunity. *Clin Res*  
310 *Hepatol Gastroenterol.* 1 févr 2013;37(1):100-4.
- 311 5. D'Agnolo HMA, Drenth JPH. High-dose methylprednisolone-induced hepatitis in a patient with  
312 multiple sclerosis: a case report and brief review of literature. *Neth J Med.* mai  
313 2013;71(4):199-202.
- 314 6. Das D, Graham I, Rose J. Recurrent acute hepatitis in patient receiving pulsed  
315 methylprednisolone for multiple sclerosis. *Indian J Gastroenterol Off J Indian Soc Gastroenterol.*  
316 déc 2006;25(6):314-6.
- 317 7. Davidov Y, Har-Noy O, Pappo O, Achiron A, Dolev M, Ben-Ari Z. Methylprednisolone-induced  
318 liver injury: Case report and literature review. *J Dig Dis.* janv 2016;17(1):55-62.
- 319 8. Dumortier J, Cottin J, Lavie C, Guillaud O, Hervieu V, Chambon-Augoyard C, et al.  
320 Methylprednisolone liver toxicity: A new case and a French regional pharmacovigilance survey.  
321 *Clin Res Hepatol Gastroenterol.* 1 sept 2017;41(4):497-501.
- 322 9. Eguchi H, Tani J, Hirao S, Tsuruta M, Tokubuchi I, Yamada K, et al. Liver Dysfunction Associated  
323 with Intravenous Methylprednisolone Pulse Therapy in Patients with Graves' Orbitopathy. *Int J*  
324 *Endocrinol* [Internet]. 2015 [cité 11 sept 2017];2015. Disponible sur:  
325 <http://www.ncbi.nlm.nih.gov/pmc/articles/PMC4499413/>
- 326 10. Furutama D, Kimura F, Shinoda K, Maeda T, Tanaka T, Ohsawa N. Recurrent High-Dose  
327 Intravenous Methylprednisolone Succinate Pulse Therapy-Induced Hepatopathy in a Patient  
328 with Multiple Sclerosis. *Med Princ Pract.* 2011;20(3):291-3.
- 329 11. Grilli E, Galati V, Petrosillo N, Del Nonno F, Baiocchini A. Incomplete septal cirrhosis after high-  
330 dose methylprednisolone therapy and regression of liver injury. *Liver Int.* 1 févr  
331 2015;35(2):674-6.
- 332 12. Gutkowski K, Chwist A, Hartleb M. Liver Injury Induced by High-Dose Methylprednisolone  
333 Therapy: A Case Report and Brief Review of the Literature. *Hepat Mon.* 1 août 2011;11(8):656-  
334 61.



- 335 13. Hidalgo de la Cruz M, Miranda Acuña JA, Lozano Ros A, Vega Catalina M, Salinero Paniagua E,  
336 Clemente Ricote G, et al. Hepatotoxicity after high-dose intravenous methylprednisolone in  
337 multiple sclerosis patients. *Clin Case Rep.* 9 juin 2017;5(8):1210-2.
- 338 14. Loraschi A, Banfi P, Mauri M, Sessa F, Bono G, Cosentino M. Hepatotoxicity After High-dose  
339 Methylprednisolone for Demyelinating Disease. *Clin Neuropharmacol.* 1 janv 2010;33(1):52-4.
- 340 15. Maàmouri N, Ketari S, Ben Hariz F, Belkahla N, Ben Romdhane S, Chouaib S, et al. Bolus de  
341 méthylprednisolone révélant une hépatite auto-immune chez une patiente atteinte de sclérose  
342 en plaques. *J Afr Hépatogastroentérologie.* déc 2009;3(4):195-7.
- 343 16. Melamud B, Lurie Y, Goldin E, Levi I, Esayag Y. Methylprednisolone-induced liver injury: a  
344 diagnostic challenge. *Isr Med Assoc J IMAJ.* mars 2014;16(3):180-1.
- 345 17. Reuß R, Retzlaff K, Vogel S, Franke FE, Oschmann P. Autoimmune hepatitis after high-dose  
346 intravenous methylprednisolone pulse in RR-MS. *Cent Eur J Med.* 1 sept 2007;2(3):356-9.
- 347 18. Rivero Fernández M, Riesco JM, Moreira VF, Moreno A, López San Román A, Arranz G, et al.  
348 [Recurrent acute liver toxicity from intravenous methylprednisolone]. *Rev Espanola*  
349 *Enfermedades Dig Organo Of Soc Espanola Patol Dig.* nov 2008;100(11):720-3.
- 350 19. Salvi M, Vannucchi G, Sbrozzi F, Del Castello AB, Carnevali A, Fargion S, et al. Onset of  
351 Autoimmune Hepatitis During Intravenous Steroid Therapy for Thyroid-Associated  
352 Ophthalmopathy in a Patient with Hashimoto's Thyroiditis: Case Report. *Thyroid.* 1 août  
353 2004;14(8):631-4.
- 354 20. Takahashi A, Kanno Y, Takahashi Y, Sakamoto N, Monoe K, Saito H, et al. Development of  
355 autoimmune hepatitis type 1 after pulsed methylprednisolone therapy for multiple sclerosis: A  
356 case report. *World J Gastroenterol WJG.* 21 sept 2008;14(35):5474-7.
- 357 21. Topal F, Ozaslan E, Akbulut S, Küçükazman M, Yüksel O, Altiparmak E. Methylprednisolone-  
358 induced toxic hepatitis. *Ann Pharmacother.* oct 2006;40(10):1868-71.
- 359 22. Weissel M, Hauff W. Fatal liver failure after high-dose glucocorticoid pulse therapy in a patient  
360 with severe thyroid eye disease. *Thyroid Off J Am Thyroid Assoc.* juin 2000;10(6):521.
- 361 23. Ferraro D, Mirante VG, Losi L, Villa E, Simone AM, Vitetta F, et al. Methylprednisolone-induced  
362 Toxic Hepatitis After Intravenous Pulsed Therapy for Multiple Sclerosis Relapses. *The*  
363 *Neurologist.* juin 2015;19(6):153-4.
- 364 24. Oliveira AT, Lopes S, Cipriano MA, Sofia C. Induced liver injury after high-dose  
365 methylprednisolone in a patient with multiple sclerosis. *BMJ Case Rep [Internet].* 21 juill 2015  
366 [cité 13 août 2018];2015. Disponible sur:  
367 <https://www.ncbi.nlm.nih.gov/pmc/articles/PMC4513529/>
- 368 25. Adamec I, Pavlović I, Pavičić T, Ruška B, Habek M. Toxic liver injury after high-dose  
369 methylprednisolone in people with multiple sclerosis. *Mult Scler Relat Disord.* 1 oct  
370 2018;25:43-5.
- 371 26. Bresteau C, Prevot S, Perlemuter G, Voican C. Methylprednisolone-induced acute liver injury in  
372 a patient treated for multiple sclerosis relapse. *BMJ Case Rep.* 5 mars 2018;2018.

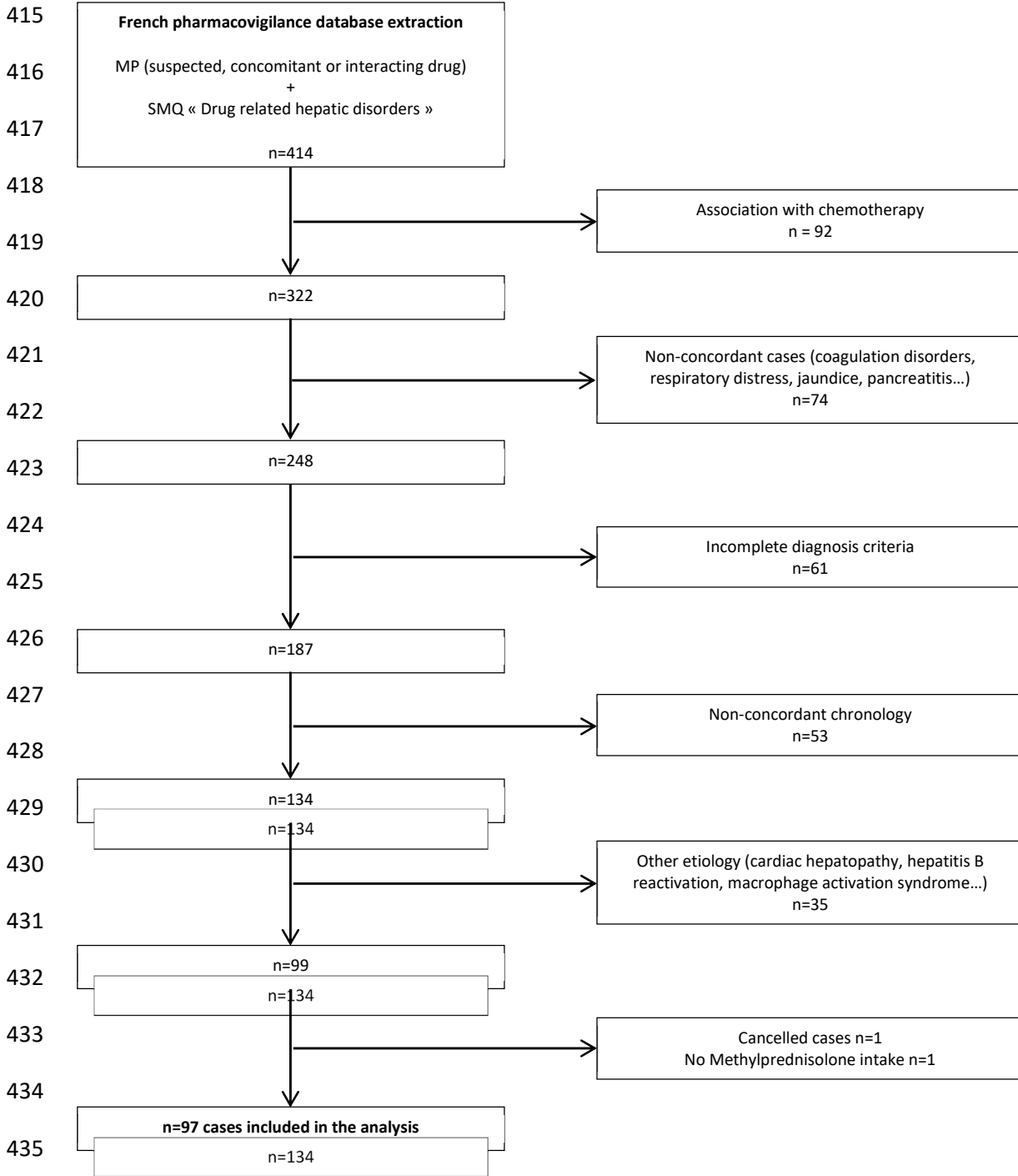
- 373 27. Marinó M, Morabito E, Brunetto MR, Bartalena L, Pinchera A, Marocci C. Acute and severe liver  
374 damage associated with intravenous glucocorticoid pulse therapy in patients with Graves'  
375 ophthalmopathy. *Thyroid Off J Am Thyroid Assoc.* mai 2004;14(5):403-6.
- 376 28. Brown EG, Wood L, Wood S. The medical dictionary for regulatory activities (MedDRA). *Drug*  
377 *Saf.* févr 1999;20(2):109-17.
- 378 29. Bégaud B, Evreux JC, Jouglard J, Lagier G. [Imputation of the unexpected or toxic effects of  
379 drugs. Actualization of the method used in France]. *Therapie.* avr 1985;40(2):111-8.
- 380 30. Aithal G, Watkins P, Andrade R, Larrey D, Molokhia M, Takikawa H, et al. Case Definition and  
381 Phenotype Standardization in Drug-Induced Liver Injury. *Clin Pharmacol Ther.* 1 juin  
382 2011;89(6):806-15.
- 383 31. Bénichou C. Criteria of drug-induced liver disorders. Report of an international consensus  
384 meeting. *J Hepatol.* sept 1990;11(2):272-6.
- 385 32. Marinó M, Morabito E, Brunetto MR, Bartalena L, Pinchera A, Marocci C. Acute and Severe Liver  
386 Damage Associated with Intravenous Glucocorticoid Pulse Therapy in Patients with Graves'  
387 Ophthalmopathy. *Thyroid.* 1 mai 2004;14(5):403-6.
- 388 33. Sisti E, Coco B, Menconi F, Leo M, Rocchi R, Latrofa F, et al. Age and Dose Are Major Risk  
389 Factors for Liver Damage Associated with Intravenous Glucocorticoid Pulse Therapy for Graves'  
390 Orbitopathy. *Thyroid.* 3 juin 2015;25(7):846-50.
- 391 34. Hofstee HMA, Nanayakkara PWB, Stehouwer CDA. Acute hepatitis related to prednisolone. *Eur*  
392 *J Intern Med.* juin 2005;16(3):209-10.
- 393 35. Marinò M, Morabito E, Altea MA, Ambrogini E, Oliveri F, Brunetto MR, et al. Autoimmune  
394 hepatitis during intravenous glucocorticoid pulse therapy for Graves' ophthalmopathy treated  
395 successfully with glucocorticoids themselves. *J Endocrinol Invest.* mars 2005;28(3):280-4.
- 396 36. Alva AS, Bhasin A, Vijayaraghavan S. A rare case of methylprednisolone induced hepatitis. *J Clin*  
397 *Exp Hepatol.* 1 mars 2013;3(1):S37.
- 398 37. Alonso A, Hernán MA. Temporal trends in the incidence of multiple sclerosis. *Neurology.* 8 juill  
399 2008;71(2):129-35.
- 400 38. Le Moli R, Baldeschi L, Saeed P, Regensburg N, Mourits MP, Wiersinga WM. Determinants of  
401 Liver Damage Associated with Intravenous Methylprednisolone Pulse Therapy in Graves'  
402 Ophthalmopathy. *Thyroid.* 1 avr 2007;17(4):357-62.
- 403 39. Caster O, Conforti A, Viola E, Edwards IR. Methylprednisolone-induced hepatotoxicity:  
404 experiences from global adverse drug reaction surveillance. *Eur J Clin Pharmacol.* 1 avr  
405 2014;70(4):501-3.
- 406 40. He Y, Mu K, Liu R, Zhang J, Xiang N. Comparison of two different regimens of intravenous  
407 methylprednisolone for patients with moderate to severe and active Graves'  
408 ophthalmopathy: a prospective, randomized controlled trial. *Endocr J.* 2017;64(2):141-9.

409 41. Corticosteroids. In: LiverTox: Clinical and Research Information on Drug-Induced Liver Injury  
410 [Internet]. Bethesda (MD): National Institute of Diabetes and Digestive and Kidney Diseases;  
411 2012 [cité 19 nov 2019]. Disponible sur: <http://www.ncbi.nlm.nih.gov/books/NBK548400/>

412

413

414



436

437 **Figure 1:** Flow chart

438

439 **Table 1.** Criteria of liver injury severity according to Aithal *et al.* <sup>(30)</sup>

Grade	Severity	Criteria
1	Mild	ALAT $\geq 5N$ or ALP $\geq 2N$ and TB $< 2N$
2	Moderate	ALAT $\geq 3N$ or ALP $\geq 2N$ and TB $\geq 2N$ or symptomatic hepatitis
3	Severe	ALAT $\geq 3N$ or ALP $\geq 2N$ and TB $\geq 2N$ + one of following criteria: INR $\geq 1.5$ ; Ascites and/or encephalopathy; Other organ failure due to liver injury
4	Life threatening or transplantation	

440 ALT: alanine aminotransferase; ALP: alkaline phosphatase; TB: total bilirubin

441

442 **Table 2.** Characteristics of the study population

	Total population n = 97
Mean age, years (SD)	45.7 (18.3)
Age-group, years, n (%)	
<10	5 (5.2)
10-20	4 (4.1)
20-30	12 (12.4)
30-40	14 (14.4)
40-50	21 (21.7)
50-60	26 (26.8)
60-70	8 (8.3)
70-80	4 (4.1)
> 80	3 (3.1)
Sex, female, n (%)	57 (58.8)
Methylprednisolone indication, n (%)	26 (26.8)
Multiple sclerosis	20 (20.6)
Auto-immune disease	18 (18.6)
Not specified	9 (9.3)
Infection	7 (7.2)
Brain tumour	6 (6.2)
Pain	4 (4.1)
Other	3 (3.1)
Neurological disorder	2 (2.1)
Haematological malignancy	2 (2.1)
Bone marrow transplant	
Route of administration, n (%)	
Intravenous	77 (79.4)
Oral	17 (17.5)
Intramuscular	3 (3.1)
443 MP: methylprednisolone	

444

445

446

447

448

449

450

451

452 **Table 3.** Characteristics of liver injuries

	Intravenous MP	Oral MP	Total population n = 97
Type of liver injury, n (%)			
Hepatocellular	61 (79.2)	9 (52.9)	71 (73.2)
Cholestatic	6 (7.8)	2 (29.4.8)	15 (15.5)
Mixed	9 (11.7)	5 (6.5)	9 (9.3)
Not specified	1 (1.3)	1 (5.9)	2 (2.1)
Severity grade, n (%)			
1	35 (45.5)	7 (41.2)	44 (45.4)
2	22 (28.6)	8 (47)	30 (30.9)
3	4 (5.2)	1 (5.9)	5 (5.2)
4	1 (1.3)	0	1 (1)
Unknown	15 (19.5)	1 (5.9)	17 (17.5)

453

454

455

456

457

458

459

460

461

462

463

464 **Table 4.** Published cases of methylprednisolone-induced liver injury

465

466

467



Reference	Age/ sex	Indication	Route	Cumulative dose/ treatment duration	Time after treatment initiation (days)	ALT (xN)	PAL (xN)	R value	Recovery time (weeks)	Histology	Rechallenge	Outcome
<b>Weissel et al. 2000</b> <sup>(32)</sup>	71/F	Basedow ophthalmopathy	IV	3g/3 days	28	NA	NA	NA	NA	Post-mortem: hepatic parenchymal necrosis	NA	Death
<b>Marino et al. 2004</b> <sup>(32)</sup>	56/NA	Basedow ophthalmopathy	IV	15g/NA	During treatment	49.8	4.2	12.0	NA	Hepatic necrosis	NA	Death
<b>Marino et al. 2004</b> <sup>(32)</sup>	63/NA	Basedow ophthalmopathy	IV	9.3g/NA	During treatment	3.6	0.8	4.3	NA	NA	NA	Death
<b>Marino et al. 2004</b> <sup>(32)</sup>	47/NA	Basedow ophthalmopathy	IV	8.3g/NA	29	NA	NA	NA	NA	NA	NA	Death after liver transplantation
<b>Marino et al. 2004</b> <sup>(32)</sup>	45/NA	Basedow ophthalmopathy	IV	9.3g/NA	During treatment	39.4	1.5	26.6	22	Hepatic necrosis	NA	Recovery
<b>Marino et al. 2004</b> <sup>(32)</sup>	30/NA	Basedow ophthalmopathy	IV	7.2g/NA	45	18.6	2.0	9.4	18	Lymphocyte and eosinophil infiltration	NA	Recovery
<b>Marino et al. 2004</b> <sup>(32)</sup>	55/NA	Basedow ophthalmopathy	IV	10.7g/NA	29	20.9	2.0	10.2	9	NA	NA	Recovery
<b>Marino et al. 2004</b> <sup>(32)</sup>	54/NA	Basedow ophthalmopathy	IV	4g/NA	During treatment	36.3	1.5	23.8	20	Lymphocyte and plasma cell infiltration	NA	Recovery
<b>Salvi et al. 2004</b> <sup>(19)</sup>	43/F	Hashimoto thyroiditis	IV	7.5 mg/kg/NA	77	23.0	NA	NA	30	Lobular hepatitis with central lobular necrosis, lymphomonocytic and plasmacellular infiltrates, acidophil bodies, and Kupffer cell hyperplasia	NA	Recovery
<b>Marino et al. 2005</b> <sup>(35)</sup>	43/F	Basedow ophthalmopathy	IV	4.7g/NA	42	28.4	NA	NA	9	Lymphocyte and plasma cell infiltration, involving mainly one interlobular bile duct. Focal centrilobular necrosis	NA	Recovery
<b>Hofstee et al. 2005</b> <sup>(34)</sup>	46/F	Multiple sclerosis	IV	3g/3 days	42	21.9	1.2	18.8	18	NA	Positive	Recovery
<b>Das et al. 2006</b> <sup>(6)</sup>	48/F	Multiple sclerosis	IV	NA/NA	42	32.0	1.7	19.2	NA	Lymphocyte and eosinophil infiltration,	NA	Recovery

										rare plasma cells in zone 3		
<b>Topal et al. 2006</b> (21)	47/F	Central nervous system vasculitis	O	0.224g/7 days	7	50.0	1.2	43.5	7	NA	NA	Recovery
<b>Reub et al. 2007</b> (17)	42/F	Multiple sclerosis	IV	NA/NA	21	21.6			NA	Active hepatitis with portal lymphocyte infiltration and fibrosis	NA	Ongoing
<b>Rivero et al. 2008</b> ((18)	57/F	Multiple sclerosis	IV	3g/3 days	5	53.7	1.0	56.0	13	Acute hepatitis with necrosis and ceroid-pigmented hyperplastic macrophages	Positive	Recovery
<b>Takahashi et al. 2008</b> (20)	47/F	Multiple sclerosis	IV	1g/6 days	28	21.3	3.1	6.8	12	Bridging perivenular necrosis with infiltration of inflammatory cells including eosinophils	Negative	Recovery (prednisolone 10g/d)
<b>Maàouri et al. 2009</b> (15)	37/F	Multiple sclerosis	IV	3g/6 days	21	NA	NA	NA	NA	Portal lymphocyte infiltration, hepatitis, fibrosis	NA	Recovery
<b>Loraschi et al. 2010</b> (14)	33/H	Multifocal demyelinating disease	IV	2.5g/NA	35	20.8	NA	NA	3	Focal necrosis of ascinus area 2 and 3, monocyte and macrophage infiltration, Kupffer cell hyperplasia, acidophilic inclusions, focal microvesicular steatosis	NA	Recovery
<b>Loraschi et al. 2010</b> (14)	27/F	Retrolbulbar neuritis	IV	4.5g/NA	6	2.4	NA	NA	1	NA	NA	Recovery
<b>Furutama et al. 2011</b> (10)	11/F	Multiple sclerosis	IV	3g/3 days	40	8.6	NA	NA	2	NA	Positive	Recovery
<b>Gutkowski et al. 2011</b> (12)	24/F	Multiple sclerosis	IV	0.5g/6 days	90	22.6	1.4	16.5	6	NA	NA	Recovery
<b>Carrier et al. 2013</b> (4)	30/F	Multiple sclerosis	IV	1g/NA	14	56.5	1.2	45.8	9	Necrotic lesions, lymphocyte infiltration, plasma cells and rare eosinophils, intrahepatic cholestasis	Positive	Recovery
<b>D'Agnolo et al.</b>	48/F	Multiple sclerosis	IV	3g/3 days	19	60.6	NA	NA	NA	NA	Positive	Recovery

<b>2013 (5)</b>												
<b>Alva et al. 2013 (36)</b>	38/F	Interstitial pneumonitis	O	0.96g/30 days	During treatment	52.4	1.1	46.9	25	Cholestatic hepatitis with early fibrosis	NA	Recovery
<b>Melamud et al. 2014 (16)</b>	52/F	Basedow ophthalmopathy	IV	0.5g/week during 4 weeks then 0.25g/week	30	9.3	0.7	14.0	30	NA	Positive	Recovery
<b>Grilli et al. 2015 (11)</b>	35/F	Multiple sclerosis/ optic neuritis	IV	5g/5 days	30	40.0	1.0	42.1	4	Partial cirrhosis, portal lymphocyte infiltration, plasma cells, eosinophils, neutrophils. Necrosis	Positive	Recovery
<b>Ferraro et al. 2015 (23)</b>	50/F	Multiple sclerosis	IV	1g/5 days	4	7	NA	NA	3	NA	NA	Recovery
<b>Ferraro et al. 2015 (23)</b>	30/F	Multiple sclerosis	IV	1g/5 days	3	12	NA	NA	2	NA	NA	Recovery
<b>Ferraro et al. 2015 (23)</b>	38/F	Multiple sclerosis	IV	1g/5 days	60	5	NA	NA	4	Inflammatory infiltrates, focal piecemeal necrosis, periportal fibrosis and numerous ceroid-laden macrophages	NA	Recovery
<b>Ferraro et al. 2015 (23)</b>	24/F	Multiple sclerosis	IV	1g/5 days	120	13	NA	NA	8	Inflammatory infiltrates, focal piecemeal necrosis, periportal fibrosis and numerous ceroid-laden macrophages	Positive	Recovery
<b>Davidov et al. 2016 (7)</b>	23/F	Multiple sclerosis	IV	3g/3 days	21	40.2	1.2	32.6	14	Decrease in hepatocyte number in central area, chronic inflammation, portal lymphocyte infiltration, eosinophils and plasma cells, acidophil bodies	Positive	Recovery
<b>Cruz et al. 2017 (13)</b>	28/F	Multiple sclerosis	IV	1g/3 days then 0.5g/3 days	30	NA	NA	NA	4	lymphocyte oedematous background and fibrotic changes related to mild chronic hepatitis	NA	Recovery

<b>Cruz et al. 2017 (13)</b>	37/H	Multiple sclerosis	IV	5g/5 days	42	18	18	1	8	No inflammation	NA	Recovery
<b>Cruz et al. 2017 (13)</b>	35/F	Multiple sclerosis	IV	5g/5 days	3	42	42	NA	NA	NA	NA	Recovery
<b>Adamec et al. 2018 (25)</b>	37/F	Multiple sclerosis	IV	6g/6 days	30	63	NA	NA	NA	Centrilobular with some and eosinophilic infiltration compatible with toxic liver necrosis	Positive	Recovery
<b>Adamec et al. 2018 (25)</b>	46/F	Multiple sclerosis	IV	3g/3 days	30	11	NA	NA	NA	Mild diffuse hepatic steatosis	Positive	Recovery
<b>Adamec et al. 2018 (25)</b>	44/F	Multiple sclerosis	IV	3g/3 days	120	37	NA	NA	NA	Portoportal and portocentral necrosis with some lymphocytic infiltration compatible with toxic liver necrosis	NA	Recovery
<b>Breseau et al. 2018 (26)</b>	35/F	Multiple sclerosis	IV	5g/5 days	60	43	1	43	6	Confluent necrosis, more severe near the terminal hepatic venule, portal tracts inflammation without damage of the bile ducts	NA	Recovery

468 NA: not available, F: female, M: male, IV: intravenous, O: oral; g: grams, ALT: alanine aminotransferase, PAL, phosphatase alkaline, R: rati