



HAL
open science

Bilateral radical neck dissection with immediate reconstruction of the internal jugular vein

Mathieu Daurade, Philippe Céruse, Ilyes Berania, Pierre Philouze

► **To cite this version:**

Mathieu Daurade, Philippe Céruse, Ilyes Berania, Pierre Philouze. Bilateral radical neck dissection with immediate reconstruction of the internal jugular vein. *International Journal of Oral and Maxillofacial Surgery*, 2020, 49, pp.1545 - 1547. <10.1016/j.ijom.2020.07.019>. <hal-03493732>

HAL Id: hal-03493732

<https://hal.science/hal-03493732v1>

Submitted on 21 Nov 2022

HAL is a multi-disciplinary open access archive for the deposit and dissemination of scientific research documents, whether they are published or not. The documents may come from teaching and research institutions in France or abroad, or from public or private research centers.

L'archive ouverte pluridisciplinaire **HAL**, est destinée au dépôt et à la diffusion de documents scientifiques de niveau recherche, publiés ou non, émanant des établissements d'enseignement et de recherche français ou étrangers, des laboratoires publics ou privés.



Distributed under a Creative Commons CC BY-NC 4.0 - Attribution - Non-commercial use - International License

Running heads:

Recto: Bilateral RND with immediate reconstruction of IJV

Verso: Daurade et al.

Correspondence:

Mathieu Daurade, Department of Maxillofacial Surgery, Croix Rouse Hospital, 103 Grande Rue de la Croix Rouse, 69004, Lyon, France. Tel: +33630450921. E-mail: mathieu.daurade@gmail.com

[ARTICLE TYPE – CASE REPORT, HEAD AND NECK ONCOLOGY]

Bilateral radical neck dissection with immediate reconstruction of the internal jugular vein

Mathieu Daurade¹, Philippe Céruse^{2,3}, Ilyes Berania⁴, Pierre Philouze²

¹Department of Maxillofacial Surgery, Croix Rouse Hospital, Lyon, France

²Department of Head and Neck Surgery, Croix Rouse Hospital, Lyon, France

³University Claude Bernard Lyon 1, Lyon, France

⁴Department of Head and Neck Surgery, Montreal University Hospital, Montreal, Canada

Abstract

Head and neck surgery for advanced neck disease may require ablation of critical structures, including the internal jugular vein (IJV). Although unilateral ligation of the IJV is not commonly associated with a significant increase in morbidity, bilateral sacrifice of the internal venous system may cause severe complications. We present the case of a 60-year-old man with a T4N2cM0 tumour of the left and right hypopharynx [Au?1]. The evolution of the disease required a bilateral modified radical neck dissection and sacrifice of both IJVs. We describe a vein grafting technique for the IJV using the external jugular vein as a donor vessel. Postoperative computed tomography imaging confirmed adequate blood perfusion. This report describes two new and accessible surgical options for immediate IJV grafting. Although this modification slightly increases the surgery time and technical difficulty [Au?2], it allows immediate restoration of venous perfusion, which may improve the prognosis and patient outcomes.

Key words: head and neck cancer, internal jugular vein, radical neck dissection, vein graft

Introduction

In head and neck oncological surgery, the ipsilateral or bilateral cervical lymph nodes often need to be addressed, due to the rich lymphatic drainage of most primary tumours in the upper aerodigestive tract. The radical neck dissection (RND) and modified radical neck dissection (MRND) have been recognized as a standard of care.

The morbidity associated with immediate bilateral ligation of the internal jugular veins (IJVs) has been described in the literature¹. Serious complications associated with a rapid increase in intracranial pressure with a reduced central venous return have been attributed to bilateral ligation of the IJVs².

A two-stage bilateral sacrifice of the IJVs in the setting of a MRND, performed over a period of 4–6 weeks in order to avoid potential vascular complications and allow the reestablishment of collateral blood flow, has been described previously³. However, this strategy delays the initiation of adjuvant therapy and increases the risk of disease progression. Although MRND and RND have been associated with higher complications rates, previous studies have shown an oncological benefit with improved disease-free interval for patients presenting bulky regional disease⁴.

Case report

We present the case of a 60-year-old male diagnosed with a T4N2cM0 left and right hypopharynx tumour according to the eighth edition of the American Joint Committee on Cancer staging manual. The patient's case was discussed at the institutional multidisciplinary tumour board meeting and he underwent six cycles of induction chemotherapy with docetaxel (40 mg/m²), cisplatin (40 mg/m²), and 5-fluorouracil (2400 mg/m²). The initial post-treatment computed tomography (CT) imaging assessment demonstrated a favourable therapeutic response at the primary site, estimated at 80%, but only a 50% response rate for the regional neck disease. The patient was consented for salvage bilateral RMND followed by adjuvant chemoradiotherapy. No treatment of the primary site was planned [Au?1].

The patient presented bilateral bulky regional disease including level II and III lymph nodes on the right and level II, III, and Vb lymph nodes on the left, in addition to bilateral IJV involvement. Intraoperative examination confirmed invasion of both IJVs, which required partial resection of both vessels. IJV graft reconstruction allowed preservation of the bilateral venous perfusion (Fig. 1).

[Figure 1 here]

Right neck dissection

The MRND was performed with conservation of the spinal nerve, sternocleidomastoid muscle, and the hypoglossal nerve [Au?1]. The tumour involved less than 180 degrees of the circumference of the IJV, which allowed a limited lateral wall resection of the vessel. The IJV was clamped with adequate bulldog forceps during vessel resection and patch reconstruction. An autologous vein patch was harvested using the ipsilateral external jugular vein (EJV) after ligation. Venous anastomosis was performed using two 6-0 hemirunning Prolene sutures (isotactic polypropylene; Ethicon). Immediate IJV patency was confirmed following unclamping.

Left neck dissection

The MRND required resection of the spinal accessory nerve and a short segment of the IJV, due to circumferential involvement of the IJV. The IJV was clamped during venous resection and graft reconstruction, similar to the other side. An autologous vein segment was harvested using the ipsilateral EJV after ligation. End-to-end

anastomosis was performed using two 6–0 hemirunning Prolene sutures (isotactic polypropylene; Ethicon). Immediate IJV patency was also confirmed following unclamping.

Postoperative outcome

Imaging on postoperative day 3 (CT scan with contrast and Doppler ultrasound) revealed adequate perfusion of the left IJV and absent venous flow on the right side (Fig. 2). The patient was started on prophylactic oral acetylsalicylic acid (75 mg, once daily) for a total course of 4 weeks following surgery. The patient remained asymptomatic during the entire duration of hospitalization and was discharged on postoperative day 5.

[Figure 2 here]

A postoperative CT scan with contrast imaging was performed 4 weeks following surgery (Fig. 2) confirming bilateral perfusion of the IJVs, with a reduced vein calibre on the right side. Doppler ultrasound confirmed maintained perfusion of both IJVs at the junction with the brachiocephalic axis.

Discussion

In the case of advanced bulky neck disease, MRND and RND may require ligation of the IJV. Interruption of venous blood perfusion following bilateral ligation of the IJVs, either in a single or two-stage procedure, significantly increases the morbidity of

the surgery. In this report, we have presented the case of a patient with advanced neck disease, who underwent resection of both IJVs and immediate reconstruction using a local vein patch from the EJV. This technique of IJV reconstruction appears not to have been reported previously in the literature. This alternative procedure has the potential to reduce complications associated with an acute interruption of the central venous flow and reduce complications associated with extensive neck dissections. In addition, this procedure reduces any time delay before initiating adjuvant therapy when compared to a two-stage procedure.

Several authors have described different techniques for reconstructing the IJV⁵⁻⁸. Katsuno et al.⁵ described a classification system for IJV reconstruction. Among the three techniques described (type A, type B, and type C), two require the use of the great saphenous vein as the donor site for IJV grafting. Recently, Kamizono et al.⁶ proposed a novel type K method using the anterior jugular vein with preservation of the EJV to improve facial drainage. From our experience, we favour the use of the EJV. This corresponds to a modification of the type B reconstruction technique in the classification of Katsuno et al. This new procedure has the potential to reduce the operative time. In particular, it offers an accessible venous donor within the operative field and avoids an additional scar from a separate donor site. A further argument for the use of the EJV for this reconstruction is its inner diameter. According to Shima et al.⁹, it ranges from 3.4 mm distally to 4.6 mm proximally compared to a maximum of 3.3 mm for the anterior jugular vein. Although there is still a significant mismatch with the IJV diameter (i.e., 7.9 mm in this study), the EJV appears to be more suitable for anastomosis than the anterior jugular vein.

Potential limitations of this procedure include the need for surgeon experience in the vascular anastomosis technique and the requirement for magnification for graft suturing [Au?1].

Although limited to a single case, the early favourable postoperative outcome of this patient who underwent bilateral MRND and immediate IJV resection and grafting indicates this to be a promising technique. Another limitation of this procedure is the interruption of the remaining venous return arising from the EJV. Although venous return may be maintained with preservation of the anterior jugular vein system, failure of reperfusion using this grafting technique may significantly exacerbate the loss of central venous blood flow.

In conclusion, the indication for bilateral MRND requiring bilateral resection of the IJVs is relatively uncommon in head and neck oncological surgery [Au?1]. Although typically considered surgically contraindicated, bilateral MRND may be possible in a single procedure when combined with an immediate reconstruction using a local vein graft [Au?1]. Through our experience, we consider these modifications as a useful surgical tool that has the potential to reduce postoperative morbidity while minimizing the number of surgical interventions.

Funding

None.

Competing interests

None.

Ethical approval

Not required. [Au?3]

Patient consent

Not required.

References

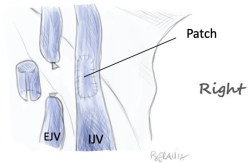
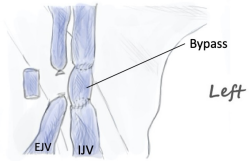
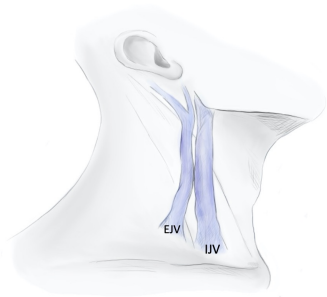
1. Marks SC, Jaques DA, Hirata RM, Saunders JR. Blindness following bilateral radical neck dissection. *Head Neck* 1990; 12: 342–345.
2. Quraishi HA, Wax MK, Granke K, Rodman SM. Internal jugular vein thrombosis after functional and selective neck dissection. *Arch Otolaryngol Head Neck Surg* 1997; 123: 969–973. doi: 10.1001/archotol.1997.01900090085012
3. Popescu B, Berteşteanu S, Grigore R, Scăunaşu R, Popescu C. Functional implications of radical neck dissection and the impact on the quality of life for patients with head and neck neoplasia. *J Med Life* 2012; 5: 410–413.
4. Noguchi S, Yamashita H, Uchino S. Modified radical neck dissection is better than partial dissection of lymph nodes. *World J Surg* 2009; 33: 394–396. doi: 10.1007/s00268-008-9813-4
5. Katsuno S, Ishiyama T, Nezu K, Usami S. Three types of internal jugular vein reconstruction in bilateral radical neck dissection. *Laryngoscope* 2000; 110: 1578–1580. doi: 10.1097/00005537-200009000-00034
6. Kamizono K, Ejima M, Taura M, Masuda M. Internal jugular vein reconstruction: application of conventional type A and novel type K methods. *J Laryngol Otol* 2011; 125: 643–648. doi: 10.1017/S0022215110003038

7. Dulguerov P, Soulier C, Maurice J, Faidutti B, Allal AS, Lehmann W. Bilateral radical neck dissection with unilateral internal jugular vein reconstruction. *Laryngoscope* 1998; 108(11 Pt 1): 1692–1696.
8. Dua A, Desai SS. Utility of internal jugular vein reconstruction in modified radical neck dissection. *Vascular* 2014; 22: 81–84. doi: 10.1177/1708538113476024
9. Shima H, von Luedinghausen M, Ohno K, Michi K. Anatomy of microvascular anastomosis in the neck. *Plast Reconstr Surg* 1998; 101: 33–41. doi: 10.1097/00006534-199801000-00007

Figure captions

Fig. 1. Two new ways to reconstruct the internal jugular vein using the external jugular vein (IJV, internal jugular vein; EJV, external jugular vein; VG, vein graft; Bypass, IJV to IJV bypass; Patch, EJV patch).

Fig. 2. Axial CT scans obtained 3 days (left) and 1 month (right) postoperative. Blue arrows indicate the internal jugular vein.


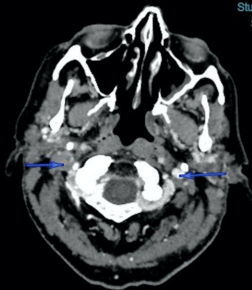


Scanner cervical (parties molles)
ORL, iDose (4)
Se: 201
Im: 136/583

A

COMPARAISON
HCL POLE NORD
Study Date: 28-05-2018
Study Time: 08:58:46

R



L

Iodine
ST: 1 mm

P

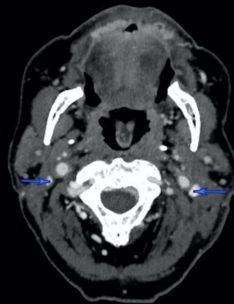WL:70 - WW:260

Scanner cervical (parties molles)
ORL, iDose (4)
Se: 301
Im: 225/581

A

COMPARAISON
HCL POLE NORD
Study Date: 27-06-2018
Study Time: 08:44:23

R



L

Iodine
ST: 1 mm

P

WL:130 - WW:401