



**HAL**  
open science

# Lateral Pterygoid Muscle Biometric Modifications in Pterygoid Process Fractures Associated With Mandibular Fractures

Romain Nicot, Thomas Roland-Billecart, Alexandre Srouji, Florent Barry, Joël Ferri, Matthias Schlund

► **To cite this version:**

Romain Nicot, Thomas Roland-Billecart, Alexandre Srouji, Florent Barry, Joël Ferri, et al.. Lateral Pterygoid Muscle Biometric Modifications in Pterygoid Process Fractures Associated With Mandibular Fractures. *Journal of Oral and Maxillofacial Surgery*, 2020, 78, pp.2258 - 2266. 10.1016/j.joms.2020.07.219 . hal-03493731

**HAL Id: hal-03493731**

**<https://hal.science/hal-03493731>**

Submitted on 15 Dec 2022

**HAL** is a multi-disciplinary open access archive for the deposit and dissemination of scientific research documents, whether they are published or not. The documents may come from teaching and research institutions in France or abroad, or from public or private research centers.

L'archive ouverte pluridisciplinaire **HAL**, est destinée au dépôt et à la diffusion de documents scientifiques de niveau recherche, publiés ou non, émanant des établissements d'enseignement et de recherche français ou étrangers, des laboratoires publics ou privés.



Distributed under a Creative Commons Attribution - NonCommercial 4.0 International License

**Title: Lateral pterygoid muscle biometric modifications in pterygoid process fractures associated with mandibular fractures**

**Full name of 6 Authors :**

Romain Nicot, Thomas Roland-Billecart, Alexandre Srouji, Florent Barry, Joël Ferri, Matthias Schlund

- Romain Nicot, MD, MSc, Senior Lecturer  
-Univ. Lille, CHU Lille, INSERM, Service de Chirurgie Maxillo-Faciale et Stomatologie, U1008 - Controlled Drug Delivery Systems and Biomaterials, F-59000 Lille, France
- Thomas Roland-Billecart, MD, Chief Resident  
-Univ. Lille, CHU Lille, Service de Chirurgie Maxillo-Faciale et Stomatologie, F-59000 Lille, France
- Alexandre Srouji, Resident  
-Univ. Bourgogne, CHU Dijon, Service de Chirurgie Plastique, Maxillo-Faciale et Chirurgie de la Main, F-21000 Dijon, France
- Florent Barry, Resident  
-Univ. Lille, CHU Lille, Service de Chirurgie Maxillo-Faciale et Stomatologie, F-59000 Lille, France
- Joël Ferri, MD, PhD, Professor  
-Univ. Lille, CHU Lille, INSERM, Service de Chirurgie Maxillo-Faciale et Stomatologie, U1008 - Controlled Drug Delivery Systems and Biomaterials, F-59000 Lille, France
- Matthias Schlund, MD, MSc, Chief Resident  
-Univ. Lille, CHU Lille, INSERM, Service de Chirurgie Maxillo-Faciale et Stomatologie, U1008 - Controlled Drug Delivery Systems and Biomaterials, F-59000 Lille, France

**Corresponding author :**

Dr. Romain Nicot  
Service de Chirurgie Maxillo-Faciale et Stomatologie  
Hôpital Roger Salengro – CHU Lille, Rue Emile Laine, 59037 Lille Cedex, France  
Tel : +33320443676. / . Fax : +33320445860. / . e-mail :  
romain.nicot@gmail.com

**Keywords:** pterygoid muscles; basilar skull fracture; mandibular fracture; jaw fracture; mechanical stress; physiopathology.

**Abstract:**

Purpose: Pterygoid process fractures (PPF) is classically associated with Lefort fractures, but can also be encountered in association with other facial fractures such as mandibular fractures. The aim of this study was to estimate the frequency of pterygoid process fractures associated with mandibular fractures and identify factors associated with PPF. Material and Methods: We conducted a retrospective cross-sectional study using computed-tomography scanning of patients having a mandibular fracture between from November 2018 to April 2020. PPF were classified using the An *et al.* classification. Volume, length and width of both lateral pterygoid muscles have been evaluated by using an image processing software. Study population has been divided in two groups: fracture of pterygoid process or absence of pterygoid process fracture. To evaluate the implication of lateral pterygoid muscle in the pathophysiology of PPF, we compared lateral pterygoid muscle volume, its maximal length and width between both groups. Patients with bilateral fractures were excluded from this analysis. Results: 304 patients with at least one mandibular fracture have been included in this study. 18 patients presenting an association of mandibular and PPF were finally selected. 83.33% of the patients were concerned by a fracture of the posterior part of the mandible. The PPF was classified type IIA of An *et al.* classification for 94.4% of patients. The lateral pterygoid muscle volumes were significantly larger on the side of the PP fracture ( $p=0.02$ ). However, there were no significant differences in the maximum length ( $p=0.49$ ) and width ( $p=0.1$ ) of lateral pterygoid muscle. Conclusion: Our study showed an

association between mandibular fractures (mainly ipsilateral posterior) and isolated PPF through a lateral pterygoid muscle volume increase.

**Text:**

## **Introduction:**

Pterygoid processes fractures (PPF) are an essential finding in Le Fort fractures and can be more rarely encountered in other types of blunt head or maxillofacial trauma. Pterygoid processes are therefore one of the first radiologic steps of the diagnosis when the surgeon or the radiologist is looking for a midface trauma<sup>1</sup>. According to the René Le Fort description, the classification of midface fractures includes Le Fort I, II, and III, each of them differentiated by their pattern, but all having PPF<sup>2,3</sup>. It appeared that characteristics of PPF varies from a Le Fort fracture to another. An *et al.* have reported a relationship between maxillary transverse fractures and PPF, in that most unilateral maxillary transverse fractures were accompanied by unilateral PPF, whereas bilateral maxillary transverse fractures were associated with bilateral pterygoid fractures and have proposed a specific classification<sup>4</sup>. This classification is based on the axis of the fracture (vertical or transverse) and the its level (regarding structures as pterygoid fossa and sphenoidal sinus). This PPF pattern suggests that specific mechanisms are leading to specific fractures including specific PPF.

It seems rare for pterygoid processes to be fractured in absence of a Le Fort fracture. Nevertheless, these PPF are not exclusively associated with a Le Fort fracture pattern, pointing out that the surgeon or the radiologist have to pay attention to this anatomical structure during the radiologic examination of a facial trauma. It can be associated with sphenotemporal buttress fractures, temporal bone fractures, zygomaticomaxillary complex fractures, and displaced mandible fractures. Garg *et al.* suggested that some of these fractures result

from the propagation of fracture lines from the primary fracture into the central skull base and pterygoid plates<sup>5</sup>. Another mechanism of PPF could be related to medial and lateral pterygoid muscles traction. This last pattern of fractures seems to be particularly encountered in association with a mandibular fracture. In a recent short case series, Truong *et al.* have explored the hypothesis that if great enough force was placed on the mandible it could lead to a fracture of the pterygoid plates<sup>6</sup>. They found that all 7 patients had an associated ipsilateral subcondylar fracture suggesting as mechanism a transduction force through the pterygoid muscles during mandibular trauma.

Nevertheless, there is a lack of knowledge about this specific association of fractures due to the absence of large series. What about the prevalence, what about characteristics of PPF when they were associated with mandibular fracture? Are pterygoid muscles really implied in the mechanism of these fractures? The main purpose of this retrospective cross-sectional study was to evaluate the prevalence and characteristics of the PPF among the patients presenting mandibular fractures diagnosed with computed tomography scanning (CT). We hypothesized that ipsilateral lateral pterygoid muscle could be associated with PPF through a brutal traction on the lateral hamulus due to a contraction of this muscle or in cases of lateral displacement of the condyle. The specific aims of the study were then to measure biometrics of each lateral pterygoid muscles, and to compare it according to the side of the mandibular fracture.

## **Materials and methods:**

### *Study design*

To address the research purpose, the investigators designed and implemented a retrospective cross-sectional study. The study population was composed of all patients admitted for a mandibular fracture to the Oral and Maxillofacial Department at Lille University Hospital, between November 2018 and April 2020. Patients were excluded as study subjects if they presented an associated Le Fort fracture. Patients without PPF or with a fracture concerning the posterior wall of the maxillary sinus were also excluded from this study.

All procedures performed in the study were in accordance with the ethical standards of the Helsinki declaration. According to French law, no IRB evaluation was required due to the retrospective nature of the study. All data were anonymized and “*Commission Nationale de l’Informatique et des Libertés de France*” (CNIL) declaration was provided.

### *Variables*

Primary predictor variable was the PPF (present or absent).

Secondary variables were considered: age, sex, mechanism of the trauma (fall, sport, assault, traffic accident), side and type of mandibular fracture (symphysis, parasymphysis, corpus, angle and condyle), side of PPF, volume in cm<sup>3</sup> of each lateral pterygoid muscle, maximum length in mm of each lateral pterygoid muscle, pattern of PPF (described in data collection section), and description of other associated facial fractures.

### *Data collection*

Evaluation of mandibular fracture types and patterns of pterygoid processes fractures was jointly performed on CT images by 3 different operators. CT images were reconstructed using image processing software (Intellispace PACS®, Philips, Foster City, CA 94404 U.S.A.), and bone threshold (250 HU) was used to segment these CT. Mandibular and pterygoid processes fractures were identified from axial, coronal, sagittal, and reconstructed three dimensional (3D) images (Figure 1). To obtain the reconstructed 3D images of the pterygoid process, the mandible, the cervical spine, and the rear of the skull, which can obstruct views of the pterygoid process, were removed when necessary.

PPF were then classified using the An *et al.* classification<sup>4</sup>. Fractures have been classified as follows (Figure 2): type I, pterygoid process vertical fracture (simple separation between the medial and lateral plates); type II, pterygoid process transverse fracture, which was further divided into 3 subcategories: II-1, fracture line located within the pterygoid fossa; II-2, fracture line located above the pterygoid fossa, not extending to the floor of the sphenoid sinus; II-3, fracture line located above the pterygoid fossa and involving the floor of the sphenoid sinus.

We hypothesized that ipsilateral lateral pterygoid muscle could be associated with pterygoid process fracture through a brutal traction on lateral hamulus due to a contraction of this muscle or in cases of lateral displacement of the condyle. Thus, we explored this hypothesis by measuring biometrics of both lateral



pterygoid muscles in patients with unilateral PPF (volume, maximal length and width) to highlight its pathophysiologic implication.

Volume of both lateral pterygoid muscles have been evaluated using manual segmentation. The operator delineated the boundaries of the pterygoid muscle attachments manually, section by section, on a series of CT slices. The design was defined in an axial plan and fitted in sagittal and coronal planes. The volume of the segmented muscle was calculated based on the section thickness, area of the lateral pterygoid muscle in section, space between slices, and total number of slices containing the region of interest (Figure 3). Volume was expressed in cm<sup>3</sup> for both lateral pterygoid muscles.

The length and the greatest width of the muscle were measured in multiplanar reconstruction (MPR) mode, after having defined an axial section plane parallel to the plane of the pterygoid muscle fibers. Maximal length was defined as the maximal size parallel to the fibers of the lateral pterygoid muscle, whereas maximal width was defined as the maximal size perpendicular to the muscular fibers. Both were expressed in mm.

#### *Data analysis*

Quantitative variables are expressed as means (standard deviation, SD) in the case of normal distribution or medians (interquartile range Q1;Q3) otherwise. Categorical variables are expressed as numbers (percentage). Normality of distributions was assessed using histograms and the Shapiro-Wilk test. Study population has been divided in two groups: fracture of pterygoid process or absence of pterygoid process fracture. To evaluate the implication of lateral

pterygoid muscle in the pathophysiology of pterygoid process fracture, we compared lateral pterygoid muscle volume, its maximal length and width between both groups. Patients with bilateral mandibular fractures were excluded from this analysis. Bivariate comparisons in baseline characteristics between the two study groups (fracture of pterygoid process vs absence of pterygoid process fracture) were made using Student t test for Gaussian continuous variables, Mann-Whitney U test for non-Gaussian continuous and ordinal categorical variables, as appropriate.

Statistical testing was conducted at the two-tailed  $\alpha$ -level of 0.05. Data were analyzed using the SAS software version 9.3 (SAS Institute, Cary, NC).

### **Results:**

304 patients with at least one mandibular fracture have been included in this study between November 2018 and April 2020. After a systematic CT evaluation, 18 patients presenting an association of mandibular and PPF were finally selected. PPF had a prevalence of 5,9% in all of the mandibular fracture population. A flowchart is presented in Figure 4.

The Table 1 showed the main characteristics of our population study. This population was composed of 14 men (77.8%) and 4 women (22.2%). The median age at the trauma was 35.5 (25.3 ; 47.5) years. 83.33% of the patients were concerned by a fracture of the posterior part of the mandible (angle/ramus/condyle). 61.1% presented a left PPF, 22.2% a PPF, and the PPF were bilateral in 16.6% of the patients. The PPF was classified type IIA of An *et*

*al.* classification for 94.4% of patients and concerned every time the lateral hamulus. In 13/18 cases (72.2%), there was at least an ipsilateral fracture of the posterior part of the mandible included into the combination.

Regarding the descriptive analysis of lateral pterygoid muscles, variables have been described as follow: on the side of the PPF, mean of lateral pterygoid muscle volume was 5.8 (1.2) cm<sup>3</sup>, length was 34.8 (3.9) mm and width was 15.1 (2.1) mm with a median equal to 15.2 (13.9 ; 16.6) mm. On the non-fractured side, mean of lateral pterygoid muscle volume was 4.9 (1.2) cm<sup>3</sup>, mean length was 35.8 (4.0) mm, and mean width was 15.4 (1.8) mm with a median equal to 15.2 (14.3 ; 16.7) mm. Regarding comparative analysis, we found a significant difference in muscle volumes according to the side of the PPF. These volumes were significantly larger on the side of the PPF ( $p=0.02$ ). However, there were no significant differences in the maximum length ( $p=0.49$ ) and width ( $p=1$ ) (Table 2).

### **Discussion:**

Aim of this retrospective cross-sectional study was to evaluate the prevalence and characteristics of the pterygoid processes fractures among the patients presenting mandibular fractures diagnosed with CT. We hypothesized that ipsilateral lateral pterygoid muscle could be associated with pterygoid process fracture through a brutal traction on lateral hamulus due to a contraction of this muscle or in cases of lateral displacement of the condyle. We therefore studied the biometrics of lateral pterygoid muscles through a CT assessment. We

showed that isolated pterygoid process fractures have a prevalence of 5,9% in mandibular fracture population. It appears that concerned mandibular fractures are mainly ipsilateral posterior mandibular fractures. Ipsilateral lateral pterygoid muscle seems to be involved in the onset pathophysiology of pterygoid process fracture through a volume increase.

It is commonly argued that the pterygoid processes fractures are pathognomonic of the Le Fort fracture, whatever the pattern implied. Nevertheless, it appears through rare publications that isolated pterygoid processes fractures could occur alone<sup>7</sup> or be associated with other types of facial fractures, in particular mandibular fractures<sup>5,6,8</sup>. The largest series related to isolated pterygoid processes fractures showed that it can be associated with 4 types of facial fractures, including sphenotemporal buttress fractures, temporal bone fractures, zygomaticomaxillary complex fractures, and displaced fractures of the mandible<sup>5</sup>. Garg *et al.* reported 78 isolated pterygoid processes fractures, most of the time unilaterally (75.6%). 17.9% of them concerned displaced mandibular fractures. In a smaller case series focusing on pterygoid plates fractures related to mandibular fractures, Truong *et al.* have reported the association with an ipsilateral subcondylar fracture in the 7 included patients<sup>6</sup>. Two of these patients had symphyseal fractures, one had a body fracture, another a parasymphyseal fracture, and one a coronoid fracture. In our series, subcondylar fracture were not the only pattern of fractures included into the combination. All isolated pterygoid process fractures seem to be associated with fractures of the posterior part of the mandible. Other studies have more

broadly focused on the posterior maxillary fractures associated with pterygoid plate fractures<sup>8,9</sup>. Simonds *et al.* have first described a retrospective study of 33 patients with posterior maxillary fractures of which 13 presented associated mandibular fractures<sup>9</sup>. Nevertheless, they did not explore the pterygoid plate area. In a CT study of 194 mandibular fractures, Imai *et al.* have reported 13 patients with a posterior maxillary fracture, but only 3 of them presented an isolated pterygoid plate fracture without associated posterior maxillary wall fracture<sup>8</sup>. Mandibular ramus was concerned in two cases while mandibular angle was implied in another case.

The proposed model of posterior maxillary fractures consists in lateral force applied on the posterior part of the mandible, which medially displaces the coronoid process, leading to posterior maxillary fractures simultaneous with transient subluxation or rotation of the temporomandibular joint (TMJ). When a mandibular fracture occurs due to high-energy impact or individual structural predisposition, the fragment that includes the coronoid process could medially displace the posterior sinus wall, the pterygoid plate, or both, leading to fracture of these anatomical structures<sup>8,9</sup>. If this model explain how posterior maxillary area fractures occurs, it is not satisfactory to explain all the pterygoid processes fractures associated with mandibular fractures, particularly when the posterior wall of the maxillary sinus was not fractured. It is more likely that a part of these associated fractures could be related to traction on the pterygoid plates by the medial and lateral pterygoid muscles or to transduction of forces through these muscles or both<sup>5,6</sup>. Medial and lateral pterygoid muscles both insert on the

lateral pterygoid plate of the sphenoid bone. On the mandible, the lateral pterygoid muscle attaches on the condylar neck and fibrous capsule, whereas the medial pterygoid muscle inserts on the medial part of the mandibular angle. From a pathophysiologic point of view, simultaneous contraction of the bilateral inferior belly of the lateral pterygoid muscle with the medial pterygoid muscle results in protrusion of the mandible. The unilateral contraction of the lateral pterygoid muscle with the ipsilateral medial pterygoid muscle results in lateral mandibular movement to the contralateral side<sup>10</sup>. Disorders resulting from acute trauma may occur when transient external loads, which are transmitted through biomechanical loading of the body, exceed internal tolerances of the affected tissues for mechanical strain, resulting in several pathological effects, such as bone fracture. By browsing the literature review, we can find such injuries in orthopedics and traumatology-related regions. It can be quoted, for example, the avulsion fractures of isolated greater tuberosity of the proximal humerus resulting of a forceful contraction of the rotator cuff against a humeral head that is distracted from the glenoid or in an anteriorly subluxed/dislocated position<sup>11</sup>. Therefore, it could be suspected that an acute muscle contraction of the pterygoid muscles due to facial trauma participates to hamulus avulsion fracture by brutally increasing the contraction force of these muscles. Nevertheless, greater trochanter fractures occur when the muscle is pulling against an intact bone that is dislocated so the muscle involved is still attached at both ends. Another possibility is that ipsilateral condyle fractures laterally displaced would exceed the lateral pterygoid muscle maximal stretching capacity leading to the appliance of a major force to the pterygoid plate able to fracture it. In our series,

we described an association between posterior mandibular fractures and fracture type IIA of the pterygoid process concerning mainly the lateral hamulus. This anatomical structure is the area of insertion of the lateral pterygoid muscle, suggesting that a brutal contraction or traction of this muscle could lead to an avulsion fracture of the lateral hamulus. Our results suggest that ipsilateral pterygoid muscle could be implied in the mechanism of the pterygoid process avulsion fracture through a brutal contraction of the fibers inserted on the lateral hamulus or by a traction due to a lateral displacement of the condylar process. Indeed, we finally found that the volume of lateral pterygoid muscle was increased on the side of the pterygoid process fracture. This finding would suggest that the muscle has brutally contracted himself leading the fracture. This could also reflect an edema resulting from a muscular injury due to the transduction force passing through it. Other biometrics were not significantly modified, probably due to the small size of the study population. Moreover, implication of medial pterygoid muscle was not evaluated because of the difficulty to perform the segmentation of this muscle, which is oriented in a vertical way. Nevertheless, as highlighted earlier, medial pterygoid muscle could have a role in the onset of pterygoid process fracture with a shared mechanism.

Surgically treating condylar neck displaced fractures offers a better functional outcome through a restoration of physiologically functional lateral pterygoid muscle<sup>12</sup>. Due to the key role of this muscle in the functioning of the TMJ and its capability to stimulate condyle growth after condylar neck fracture, it is likely that an isolated PPF may be a factor of poor joint health when a displaced

fracture of the condylar area is associated with it. When a PPF associated with condylar area fracture occurs, the superior and inferior heads of the lateral pterygoid muscle, although still inserted in the condylar neck and disc, can no longer apply forces to the rest of the mandible, making protrusive movements difficult or impossible. Action of the remaining muscles is however relatively unaffected<sup>13</sup>. The particularity of this combination of fractures is that the affected lateral pterygoid muscle does not recover its capability to contract itself due to the its pterygoid disinsertion, allowing protrusive movements and lateral excursions in the early phase after a surgical treatment<sup>10,14</sup>. While this could only cause a decrease in masticatory bite force and limit the jaw motion in adulthood<sup>13,14</sup>, it could also affect skeletal growth due to the lack of functional activation of pterygoid muscles in childhood<sup>15</sup>.

Vascularization of the condyle is abundant, provided by the masseteric artery and the posterior deep temporal artery at the front, the superficial temporary artery at the back, branches emanating directly from the maxillary artery destined for the lateral pterygoid muscle and to the condyle in the medial and the transverse artery of the face at the lateral side<sup>16</sup>. Considering that the role of the lateral pterygoid muscle is constant and predominant in the vascularization of the condyle, an avulsion fracture of the medial part of the condyle by disinsertion of this muscle has been pointed out to explain the mechanism of condyle necrosis following a fracture. So, is the association of condyle fracture and PPF a risk factor of condyle necrosis? While the condyle vascularization comes from three main arterial sources, it appears that branches emanating directly from the maxillary artery vascularized the contiguous part from the



lateral pterygoid muscle to the condyle and to the disk and posterior deep temporal artery are passing through the pterygoid muscle but are not impacted by a pterygoid disinsertion<sup>16</sup>. Therefore, it seems that this combination of fracture does not impact the condyle vascularization.

Isolated PPF associated with mandibular posterior fracture is a specific entity, probably unknown and misdiagnosed. Pterygoid muscle seems to have the key role in the pathophysiology of this condition. Surgeon should be aware of this fracture combination because it could affect jaw motion and bite force in the early post-surgical time. Nevertheless, it does not seem to be an additional factor leading to condyle necrosis due to the preservation of vascularization passing through the pterygoid muscle. Additionally, medial pterygoid muscle participation should be explored to explain the pathophysiology by mandibular fracture type.

**Acknowledgements :**

*Authors report no conflict of interest.*

*Authors declare no funding sources.*

*Due to the retrospective nature of this study, it was granted an exemption in writing by the University of Lille IRB.*

## References:

1. Rhea JT, Novelline RA: How to simplify the CT diagnosis of Le Fort fractures. *AJR Am J Roentgenol* 184: 1700-1705, 2005. doi: 10.2214/ajr.184.5.01841700.
2. Tessier P: The classic reprint. Experimental study of fractures of the upper jaw. I and II. René Le Fort, M.D. *Plast Reconstr Surg* 50: 497-506, 1972. doi: 10.1097/00006534-197211000-00012.
3. Tessier P: The classic reprint: experimental study of fractures of the upper jaw. 3. René Le Fort, M.D., Lille, France. *Plast Reconstr Surg* 50: 600-607, 1972.
4. An J, Dai F, Sun Z, Zhang Y: Classification and characteristics of pterygoid process fracture associated with maxillary transverse fracture. *Oral Surg Oral Med Oral Pathol Oral Radiol* 117: 243-252, 2014. doi: 10.1016/j.oooo.2013.11.500.
5. Garg RK, Alsheik NH, Afifi AM, Gentry LR: Pterygoid Plate Fractures: Not Limited to Le Fort Fractures. *J Craniofac Surg* 26: 1823-5, 2015. doi: 10.1097/SCS.0000000000001901.
6. Truong AQ, O'Brien DC, Strong EB, Dublin A: Lateral pterygoid plate fractures associated with mandible fractures. *JAMA Facial Plast Surg* 16: 437-9, 2014. doi: 10.1001/jamafacial.2014.645.

7. Eriksson L, Håkansson H: Unilateral fracture of the pterygoid process. Report of a case. *Oral Surg Oral Med Oral Pathol* 47: 127-30, 1979. doi: 10.1016/0030-4220(79)90165-8.
8. Imai T, Sukegawa S, Kanno T, Fujita G, Yamamoto N, Furuki Y, et al : Mandibular fracture patterns consistent with posterior maxillary fractures involving the posterior maxillary sinus, pterygoid plate or both: CT characteristics. *Dentomaxillofac Radiol* 43: 20130355, 2014. doi: 10.1259/dmfr.20130355.
9. Simonds JS, Whitlow CT, Chen MYM, Williams DW: Isolated fractures of the posterior maxillary sinus: CT appearance and proposed mechanism. *AJNR Am J Neuroradiol* 32: 468-70, 2011. doi: 10.3174/ajnr.A2337.
10. Walker CJ, MacLeod SPR: Anatomy and Biomechanics of Condylar Fractures. *Atlas Oral Maxillofac Surg Clin North Am* 25: 11–6, 2017. Doi: 10.1016/j.cxom.2016.10.002.
11. White EA, Skalski MR, Patel DB, Gross JS, Tomasian A, Heckmann N, et al: Isolated greater tuberosity fractures of the proximal humerus: anatomy, injury patterns, multimodality imaging, and approach to management. *Emerg Radiol* 25: 235-46, 2018. doi: 10.1007/s10140-018-1589-8.

12. Kolk A, Neff A: Long-term results of ORIF of condylar head fractures of the mandible: A prospective 5-year follow-up study of small-fragment positional-screw osteosynthesis (SFPSO). *J Craniomaxillofac Surg* 43: 452-61, 2015. doi: 10.1016/j.jcms.2015.02.004.
13. Throckmorton GS, Talwar RM, Ellis E: Changes in masticatory patterns after bilateral fracture of the mandibular condylar process. *J Oral Maxillofac Surg* 57: 500-8; discussion 508-509, 1999. doi: 10.1016/s0278-2391(99)90061-7.
14. Talwar RM, Ellis E, Throckmorton GS: Adaptations of the masticatory system after bilateral fractures of the mandibular condylar process. *J Oral Maxillofac Surg* 56: 430-9, 1998. doi: 10.1016/s0278-2391(98)90707-8.
15. Defabianis P: TMJ fractures in children: importance of functional activation of muscles in preventing mandibular asymmetries and facial maldevelopment. *Funct Orthod* 19: 34-42, 2002.
16. Toure G: Arterial Vascularization of the Mandibular Condyle and Fractures of the Condyle. *Plast Reconstr Surg* 141: 718e-25e, 2018. doi: 10.1097/PRS.00000000000004295.

**Tables:**

**Table 1:** Characteristics of the population and description of the isolated pterygoid processes fractures

**Table 2:** Comparison of the biometry of the lateral pterygoid muscle according to the side of the pterygoid fracture

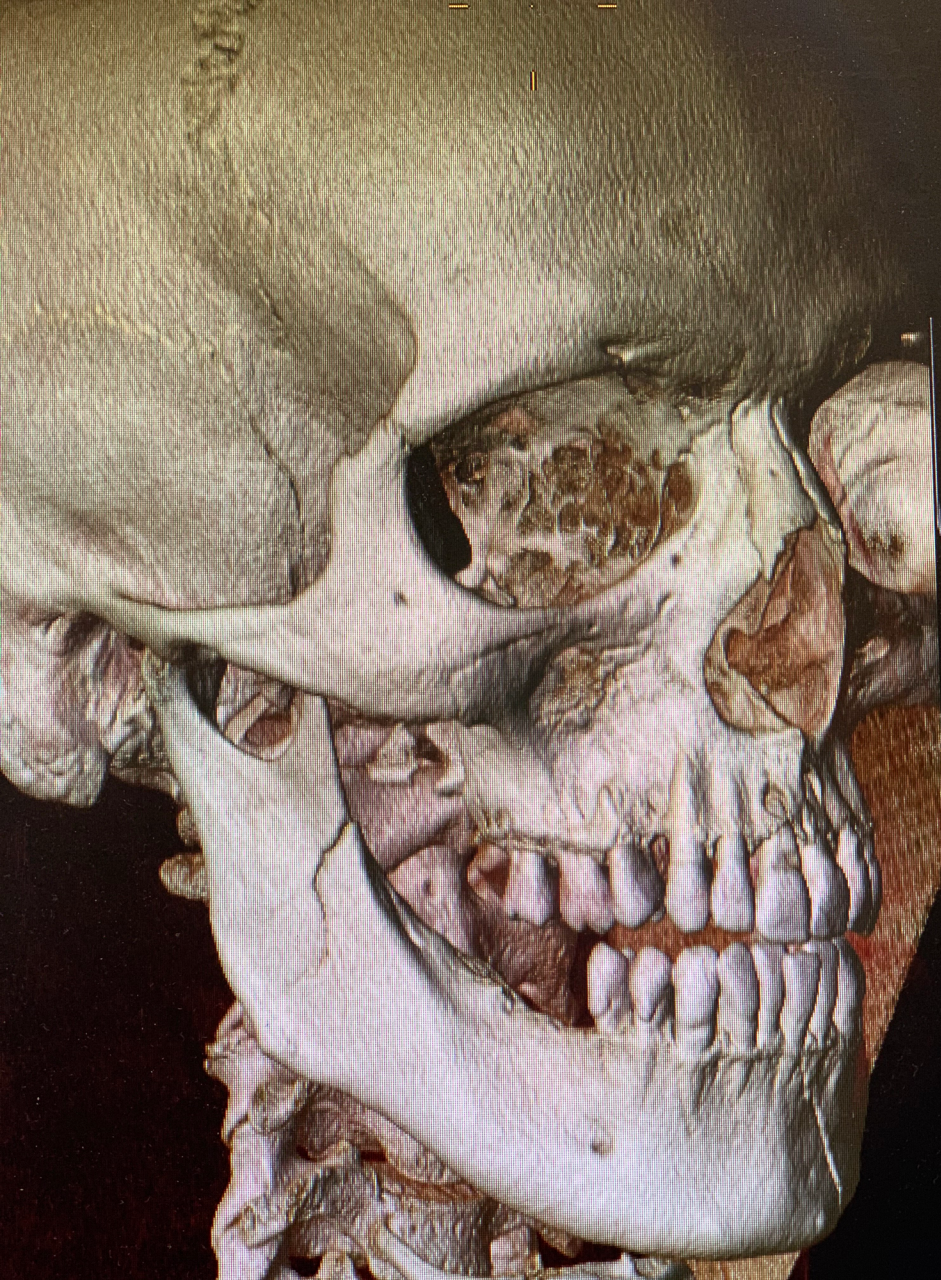**Captions of figures:**

**Figure 1:** 3D reconstruction of a patient with angle fracture of the mandible associated with ipsilateral pterygoid process fracture.

**Figure 2:** An et al. classification of pterygoid processes fractures : Type I, pterygoid process vertical fracture (simple separation between the medial and lateral plates); Type II, pterygoid process transverse fracture, which was further divided into 3 subcategories: II-1, fracture line located within the pterygoid fossa; II-2, fracture line located above the pterygoid fossa, not extending to the floor of the sphenoid sinus; II-3, fracture line located above the pterygoid fossa and involving the floor of the sphenoid sinus. Re-used figure with agreement of authors and editor. (An J, Dai F, Sun Z, Zhang Y. Classification and characteristics of pterygoid process fracture associated with maxillary transverse fracture. *Oral Surg Oral Med Oral Pathol Oral Radiol.* 2014; 117: 243-52.)

**Figure 3:** Segmented volume of right lateral pterygoid muscle in ipsilateral lateral hamulus avulsion fracture.

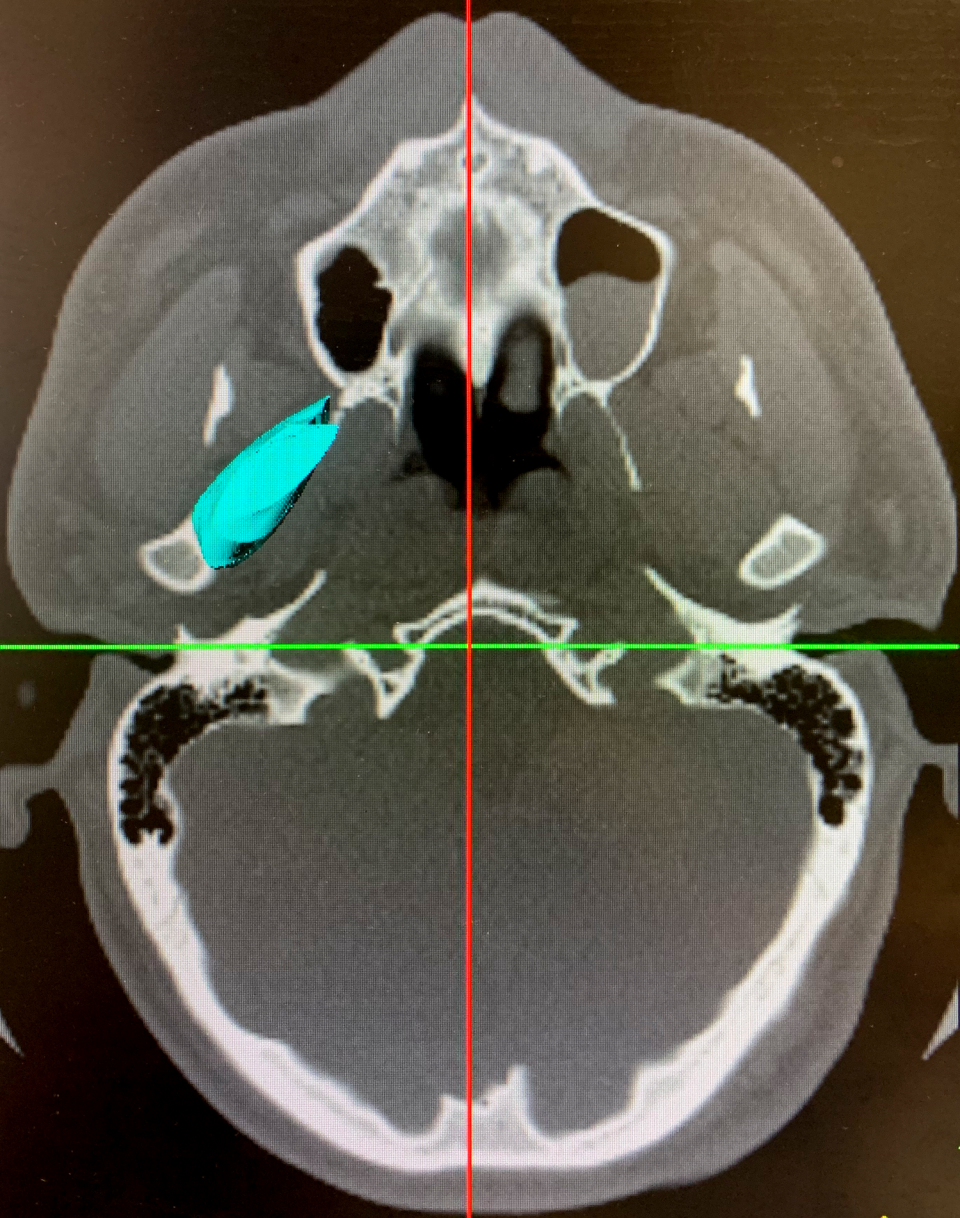
**Figure 4:** Flow-chart of the population study.

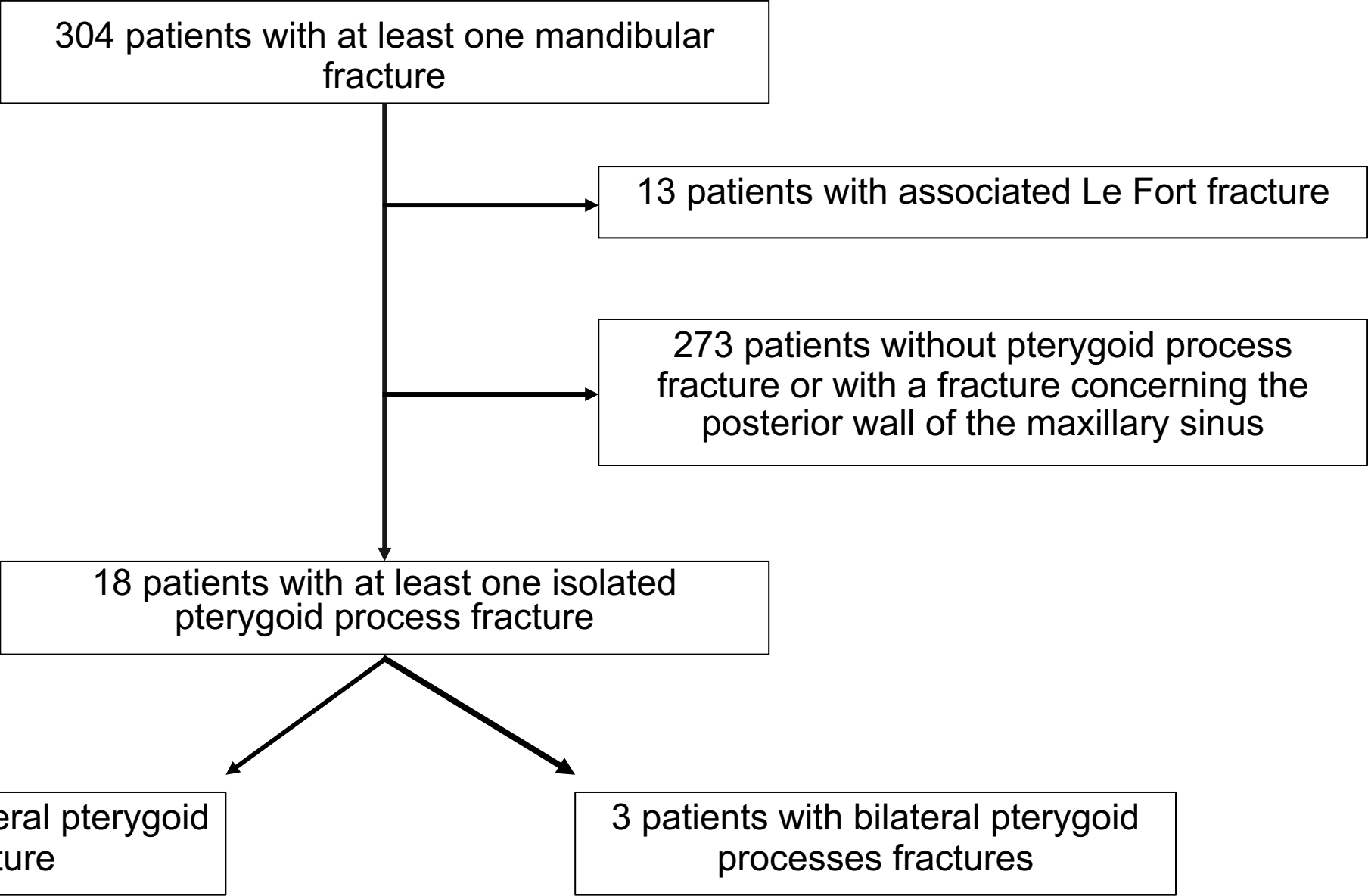






Volume measurement 7.04 cm<sup>3</sup>





Patient	Sex	Age	Mechanism	Type of mandibular fracture	Side of the Pt. process fracture	Volume of left Lat. Pt. muscle	Volume of right Lat. Pt. muscle	Maximum Length of the left Pt. muscle	Maximum Length of the right Pt. muscle	Maximum width of the left Pt. muscle	Maximum width of the right Pt. muscle	Type of Pt. process fracture	Associated fractures
1	F	48	Fall	Parasymphysis (L)	Right	4.34	5.00	31.3	31.3	12.9	10.0	IIA - lateral hamulus	
2	F	80	Fall	Condyle (L)	Bilateral	5.19	4.38	30.6	31.2	16.4	11.3	IIA - lateral hamulus (L) / IIC	Zygomatic fracture (R)
3	M	33	Sport	Symphysis + Corpus (R) + Condyle (L)	Bilateral	2.56	4.89	29.9	34.5	15.5	16.7	IIC (L) / IIA lateral hamulus (R)	Zygomatic fracture (L)
4	F	44	Assault	Condyle (L)	Left	3.4	3.31	26.4	25.9	17.3	13.7	IIA - lateral hamulus	Zygomatic fracture (L)
5	M	21	Fall	Corpus (L)	Left	5.47	4.97	34.6	36.7	13.1	13.6	IIA - lateral hamulus	
6	M	16	Traffic accident	Parasymphysis (R) + Angle (L)	Left	5.82	3.80	38.2	39.1	16.4	16.7	IIA - lateral hamulus	
7	M	53	Assault	Condyle (R)	Left	6.98	6.01	39.6	34.8	14.3	15.5	IIA - lateral hamulus	
8	M	54	Sport	Parasymphysis (L) + Angle (L)	Left	6.42	6.12	35.7	37.0	17.4	15.2	IIA - lateral hamulus	
9	M	36	Assault	Parasymphysis (R) + Condyle (L)	Left	5.19	4.37	35.2	36.6	16.7	15.3	IIB - lateral hamulus	
10	M	25	Traffic accident	Condyle (R)	Right	5.72	7.04	39.0	38.4	19.7	12.5	IIA - lateral hamulus	
11	M	39	Assault	Condyle (R)	Left	4.43	5.12	33.3	33.8	15.3	14.8	IIA - lateral hamulus	
12	M	32	Assault	Parasymphysis (L) + Condyle (R)	Right	5.45	5.1	38.1	36.2	13.3	13.4	IIA - lateral hamulus	
13	M	25	Assault	Parasymphysis (R)	Left	7.73	5.24	34.1	34.6	15.6	15.1	IIA - lateral hamulus	
14	M	23	Assault	Condyle (L)	Left	5.86	4.64	38.7	41.6	16.5	16.7	IIA - lateral hamulus	
15	M	26	Assault	Condyle (R)	Left	7.57	5.03	33.1	35.9	14.7	16.4	IIA - lateral hamulus	
16	M	35	Assault	Parasymphysis (L) + Condyle (R)	Right	5.21	5.64	40.6	39.4	17.1	18.4	IIA - lateral hamulus	
17	F	56	Sport	Symphysis + Condyle (L)	Bilateral	4.00	3.24	36.8	33.7	13.8	14	IIA - lateral hamulus (L) / IIA - medial hamulus (R)	Zygomatic fracture (L)
18	M	46	Assault	Parasymphysis (L) + Condyle (L)	Left	5.97	4.76	28.4	32.6	15.2	14.8	IIA - lateral hamulus	

*F = Female ; M= Male ; L = Left ; R = Right ; Pt = Pterygoid ; Lat = Lateral  
Volume is expressed in cm<sup>3</sup> ; Length and Width are expressed in mm.*



	Side of <i>Pterygoid process fracture</i> (n=15)	Side controlateral to <i>Pterygoid process fracture</i> (n=15)	
<b>Means of <i>Lateral pterygoid muscle volume</i></b>	5.8 (1.2)	4.9 (1.2)	<b>p=0.02</b>
<b>Means of <i>Lateral pterygoid muscle maximum Length</i></b>	34.8 (3.9)	35.8 (4.0)	p=0.49
<b>Medians of <i>Lateral pterygoid muscle maximum width</i></b>	15.2 (13.9 ; 16.6)	15.2 (14.3 ; 16.7)	p=0.99

Volume is expressed in cm<sup>3</sup> ; Length and Width are expressed in mm.